

# Thoracic Radiology

Clifford R. Berry, DVM

Diplomate, ACVR

John P. Graham MVB, MRCVS

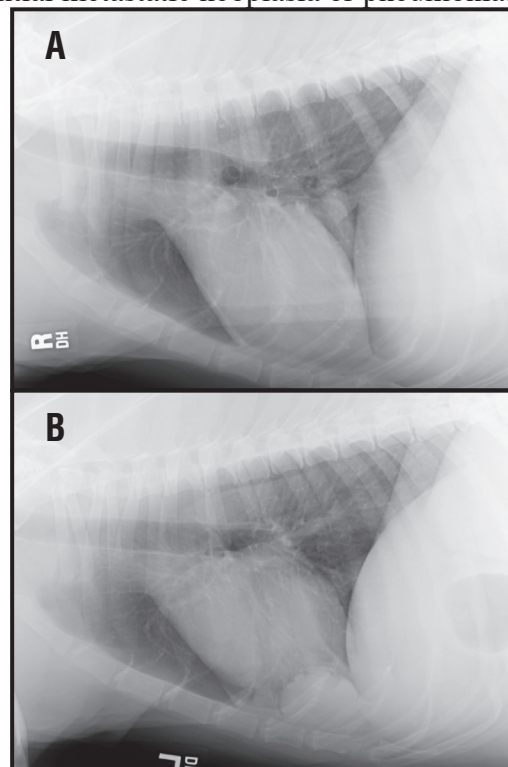
Diplomate, ECVDI and ACVR

## Introduction

Radiology is an invaluable tool in evaluating the organs of the thorax. It is one of the quickest and easiest diagnostic tests to perform and because of the air filled lungs, an ideal window for assessing the heart, great vessels, mediastinal and pleural structures and the pulmonary circulatory system is created. The thorax can also be one of the most intimidating body parts for radiographic evaluation and many students and practitioners struggle with thoracic radiographic interpretation. The purpose of this handout is to guide the student and practitioner in a step-by-step approach to the interpretation of thoracic radiographs. By application of this systematic approach, accurate interpretation of thoracic radiographs can be much more rewarding for the practitioner. A more accurate interpretation of the thoracic radiographic abnormalities will lead to more concise differential diagnoses or even a specific diagnosis.

## General Principles of Interpretation

Some basic principles of how to evaluate thoracic radiographs are in order prior to reviewing film quality and normal radiographic anatomy. First, always obtain at least two orthogonal radiographs. In thoracic radiology a minimum database consists of one lateral and a VD or DV. If a patient cannot be positioned VD or DV, then an examination consisting of both left and right laterals may be used for pulmonary disease, especially when evaluating for potential metastatic neoplasia or pneumonia. Remember that lesions in the downside (recumbent) lung are frequently invisible due to border effacement with normal lung parenchyma that is non-aerated due to recumbency, even when a lesion is quite large. Four to 5 cm masses can be obscured if they are present just lateral to the cardiac silhouette within the recumbent lung field (**Figure 1**). A single lateral radiograph of the thorax should never be considered a complete study! The potential for misses are common with only a single lateral radiograph. If sued, no radiologist called in as an



**Figure 1.** Right (A) versus left lateral (B) thoracic radiographs from a dog with metastatic disease from a limb osteosarcoma. There is a large metastatic mass (5 cm in diameter) seen on the left lateral superimposed over the cardiac silhouette that is not visualized on the right lateral. This is because of the border effacement of the mass with atelectic lung lobe when the dog is in left lateral recumbency. The mass lesion is located in the ventral aspect of the right middle lung lobe. The pattern is a nodular interstitial pulmonary pattern.

expert witness will back anyone with just a single lateral radiograph. More importantly consider the standard of veterinary medicine of which you want to practice.

When reviewing radiographs, use a well-lit light box that was designed for hanging and evaluating radiographs; not the ceiling lights or a window. Radiographic view boxes that have 4 fluorescent (bright lite®) tubes per view box are best as they provide the most amount of luminescence and thereby the highest degree of light transmittance through the radiograph. Also, use blackened film (previously exposed and developed/processed blank sheets of radiographic film as “curtains”) to limit peripheral light that is not covered by the radiograph or various parts of the radiograph and turn off light boxes that are not in use. This will limit the amount of light information that is obscuring the true visual information of the radiograph by your brain. This will also produce a dramatic improvement in apparent film quality and in visualization of potential abnormalities. This simple technique does not replace initial quality control of the radiographic study. A “hot light” should be standard equipment and readily available, particularly for evaluating peripheral lung structures, spinous processes, ribs, sternbrae, or overexposed radiographs.

The basics of interpretation should include a systematic approach so that all structures are evaluated each and every time on every radiograph. The clinician should post a check list as a reminder of the structures that need to be reviewed and a list of common things that should be seen as normal structures on the radiographs (**Table 1**). Review the radiographs in a quiet location so that you can avoid distraction and concentrate on the radiographs at hand. Also, if one gets in the habit of always hanging the radiographs in specific pattern, this will aid in pattern recognition of abnormalities. Although this “gut reaction” approach using pattern recognition will never replace a systematic evaluation, this will help in initial recognition of abnormalities. Since there is a minimum of two orthogonal radiographs available, there are several techniques used for evaluating each radiograph systematically. If you evaluate one radiograph at a time (turn off the other view box), then make a running list of abnormalities (abnormal roentgen signs) so that the perceived abnormality is confirmed or denied on the orthogonal radiograph.

One of the easiest pitfalls in radiographic interpretation is to either force a diagnosis on a radiograph or identify an abnormality and immediately stop your search and evaluation. Don't jump to conclusions and try to divorce yourself from the clinical findings thereby keeping an open mind. This is difficult as a practitioner but you will not miss those serendipitous but nonetheless important lesions. Conversely, after a systematic approach has been used and all radiographs have been evaluated, use clinical data to refine your search and review specific areas again. If you are looking for metastases, search the entire lung field (including over the diaphragm) and pay special attention to the bones and soft tissues for additional abnormalities. Remember - Don't panic. Severe or extensive pathology involving multiple thoracic compartments (see following) can be confusing or intimidating but will almost always yield a diagnosis when a systematic approach is used.

**Table 1: Thoracic Radiographic Paradigm for Interpretation.**

Signalment and reason for thoracic radiographs: \_\_\_\_\_

**Film quality**

Diagnostic quality      Yes No – If no, repeat radiographs to obtain diagnostic quality.  
 RL / LL                      Inspiration? Expiration?  
 VD / DV                      Inspiration? Expiration?

**Film interpretation**

Canine / Feline; Immature / Mature

Roentgen Sign Approach (is there a change in location/position, margins/contours, number, opacity, size and shape)

<b>EXTRATHORACIC STRUCTURES: are they normal?</b>			<b>COMMENTS</b>
Vertebral Column (C6 – L2)	NI	AbN	_____
Soft tissue structures	NI	AbN	_____
Sternebrae	NI	AbN	_____
Ribs (Right and Left – 13 ribs)	NI	AbN	_____
Diaphragm (Cupola and crura)	NI	AbN	_____
Thoracic limbs	NI	AbN	_____
Cranial abdominal structures	NI	AbN	_____
Cervical structures at thoracic inlet	NI	AbN	_____
<b>PLEURAL SPACE</b>			
Identification of pleural fissure lines	NI	AbN	_____
Loss of normal pleural contour along thoracic wall	NI	AbN	_____
Identification of NL diaphragm	NI	AbN	_____
Dorsal or ventral fissures	NI	AbN	_____
Extrapleural Sign	NI	AbN	_____
<b>PULMONARY PARENCHYMA</b>			
Lungs	NI	AbN	_____

**If abnormal parenchyma follow the following chart to help with interpretation.**

Air bronchograms present?	YES	NO	_____
Are there circles and lines?	YES	NO	_____
Are there focal nodules/mass?	YES	NO	_____
Loss of vessel visualization?	YES	NO	_____
Predominant distribution?	Cranioventral, Ventral, Generalized, Caudodorsal, Hilar, Lobar (specific lung lobe)		

**Table 1 continued: Thoracic Radiographic Paradigm for Interpretation.**

<b>PULMONARY PARENCHYMA CONTINUED</b>		<b>COMMENTS</b>	
Distribution within the lung lobe or if generalized: Hilar, mid-zone or peripheral			
Lung Lobes involved? Rcr, Rmid, Rcaud, Racc; LtCr/Cr, Lt Cr/Cd and LtCaud			
Trachea	NL	AbN	_____
Carina location/position normal?	NL	AbN	_____
Principle bronchi	NL	AbN	_____
Pulmonary veins	NL	AbN	_____
Pulmonary arteries	NL	AbN	_____
<b>MEDIASTINUM</b>			
Trachea	NL	AbN	_____
Cardiac Silhouette	NL	AbN	_____
Great vessels	NL	AbN	_____
Visualization of vessels in the Cranial Mediastinum?			
Is there a gas dilated esophagus?	NL	AbN	_____
Any change to the esophagus?	NL	AbN	_____
Cranial mediastinal widening?	NL	AbN	_____
Are there cranial mediastinal contour Abnormalities?			
Is there retraction of the cranial Lung lobes?	NL	AbN	_____
Is there any soft tissue opacities that Can not be localized to the pleural Space or the pulmonary parenchyma?			
	NL	AbN	_____

**Radiographic Problem List – Roentgen Abnormalities**

List all of the abnormalites in order of clinical importance here.

DX/DDX – based on all problems. Can they all be tied together? \_\_\_\_\_

Yes - specific diagnosis? No – then list differentials for each roentgen abnormality.

Where do I stand on the Cone of Certainty? (1 being lowest ranking and 10 being confident in your diagnosis). \_\_\_\_\_

Additional studies/tests/procedures – rule in top differentials? Which tests are likely to give me the diagnosis? Should follow-up thoracic radiographs be considered and if so when?

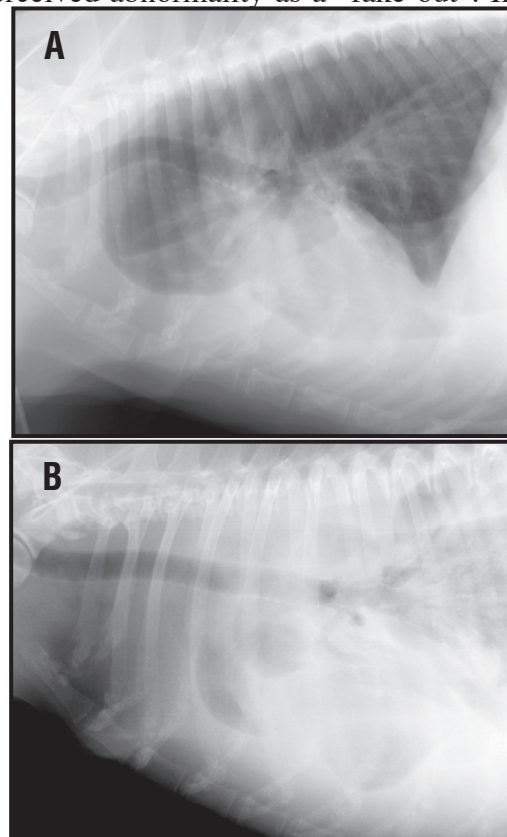
\_\_\_\_\_

## Film quality

For those of you who are contemplating purchasing an ultrasound machine or have already done so, but still do not quality control any of your radiographs, STOP. If you do not have the time to quality control thoracic and other radiographic studies, you certainly do not have the time to learn ultrasound. The single most overlooked factor in interpreting thoracic films is film quality. Good quality films are much easier to interpret and will provide a more accurate assessment of the patient's thorax than poor quality radiographs that are overexposed, inadequately positioned, improper technique for positioning of thoracic limbs and/or the presence of multiple automatic or manually developed processor artifacts. With quality radiographic studies you may not be able to reach a definitive diagnosis but you are more likely to get a useful report from a radiologist if you refer quality radiographs for consultation.

The technique for obtaining good quality thoracic radiographs has been described in detail elsewhere, but will be briefly reviewed here. Several factors that need to be kept in mind include: make the radiographs on peak inspiration and use a latitude technique (high kVp and low mAs). These two factors alone will help to optimize radiographic quality. Center the x-ray beam over the thorax at the level of the caudal border of the scapula dorsally and the cardiac apex ventrally. Open up the collimation so that all structures from the thoracic inlet through the last ribs (T13) are included. Make sure that the remainder of the thorax is collimated in order to reduce scatter. Also, the thoracic limbs need to be pulled forward so that they do not get in the way of interpreting the structures in the cranial thorax. The neck and head should be pulled forward away from the thorax, as the trachea will have a kinked appearance if the head is ventral flexed with the mandible pointing toward the thorax. This will result in the artificial impression of tracheal deviation secondary to a cranial mediastinal mass, (**Figure 2**). Repeating the lateral radiograph with the head extended will result in normal tracheal positioning and thereby confirm this perceived abnormality as a “fake-out”. If the dog has a barrel chest confirmation or changes dramatically in thickness from the cranial to caudal thorax (thicker), then placing a triangular foam wedge or lifting the thoracic limbs off of the table so that a plane between the thoracic vertebrae and sternum is parallel to the radiology table will help with any obliquity.

When evaluating the lateral radiograph, the diaphragm cupola should be to the level of T10 and the crura to the level of T12-13 in dogs and T13-L1 in cats. The rib head should be superimposed over the thoracic vertebral bodies. On a VD/DV the cupola should be back to the same level of T10 and the sternum should be superimposed over the thoracic vertebrae. Some dogs will not allow you to get a VD/DV and should be tranquilized in order



**Figure 2 (A).** Ventral flexion of the neck at the time of exposure of a lateral thoracic radiograph will result in dorsal elevation (tracheal “kink”) of the cranial thoracic trachea leading one to conclude that there is a cranial mediastinal mass. (B). Repeat exposure with the head in extension shows the trachea is in fact normal. A pleural effusion is also present in this dog.

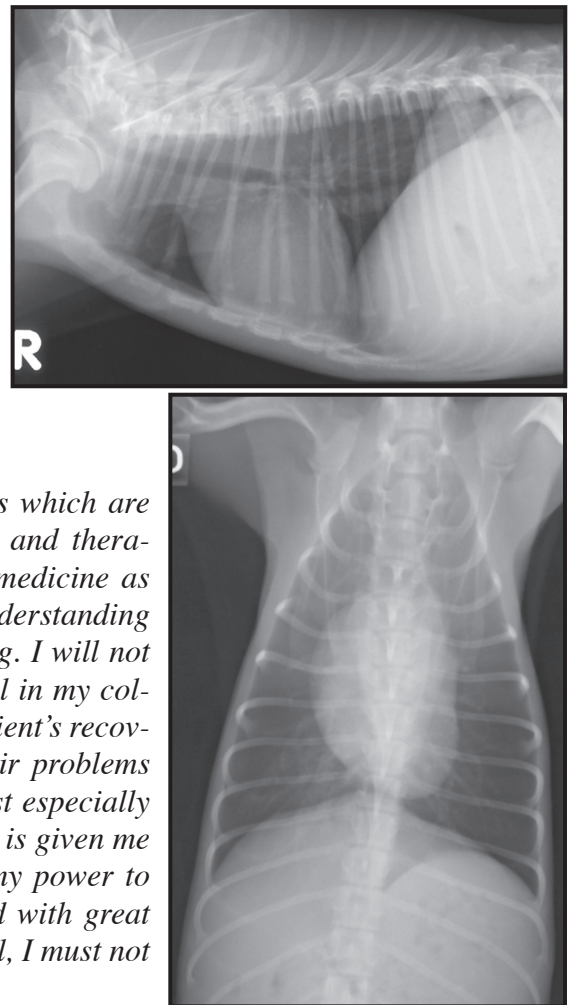
to get this radiograph. If the patient is in critical condition, at least obtaining right and left lateral radiographs will provide a wealth of information compared to just obtaining a single lateral radiograph. For evaluating dogs and cats with congenital heart disease, a right lateral and VD are preferable, but this comes down to personal choice and what one has become accustomed to evaluating. It is critical that the VD in dogs and cats that are being evaluated for congenital heart disease be perfectly positioned so that the heart base and cardiac silhouette can be accurately evaluated.

### The Normal Thorax - Helpful Rules of Thumb

Because of the wide variety of thorax size and shapes based on the various dog breeds, there are some basic rules of thumb that may help in assessing certain structures in the thorax. One must remember, however, that these are just rules of thumb and as quickly as you start treating them like dogma, along comes a breed that breaks all of the rules, yet is still normal. With that in mind, the cardiac size in dogs varies depending on the breed, ranging from 2.5 to 3.5 intercostal spaces wide on lateral films and no more than 50 to 60% of the width of thorax (as measured at the pleural margin to pleural margin around the level of T10) on the ventrodorsal (VD) or dorsoventral (DV) films. Deep chested dogs are always at the lower end of this range on lateral radiographs. Barrel chested, chondrodystrophic breeds and brachycephalic breeds will be at the upper end and will look like the cardiac silhouette is enlarged on the lateral radiograph, BUT normal on the VD/DV (**Figure 3 and 4**). This brings up a common problem in that most practitioners that are taking only lateral radiographs are routinely over diagnosing cardiac disease in dogs that are normal. Add to this an underexposed, expiratory lateral radiograph and the dog is in left heart failure with severe pulmonary edema. Remember that the over diagnosis and/or over treatment or lack of accurate interpretation is part of the modern Hippocratic Oath as stated,

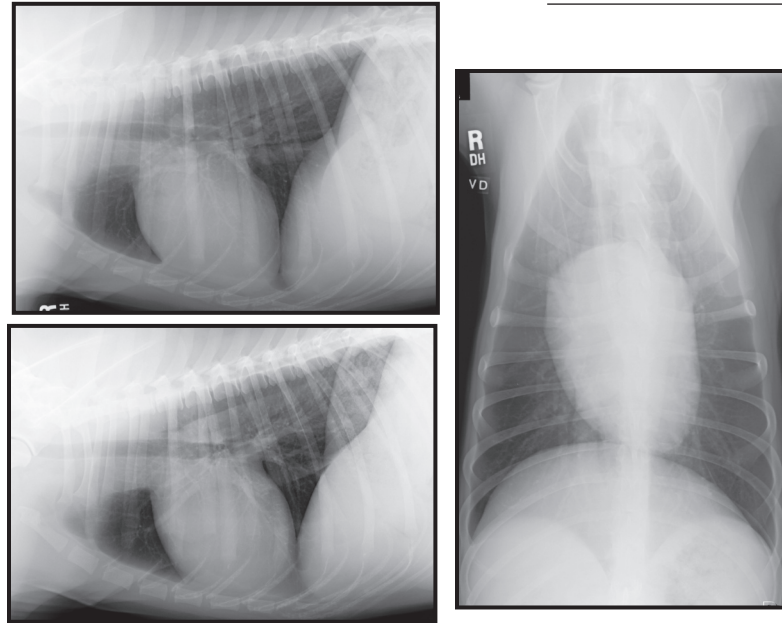
*“I will apply, for the benefit of the sick, all measures which are required, avoiding those twin traps of overtreatment and therapeutic nihilism. I will remember that there is art to medicine as well as science, and that warmth, sympathy, and understanding may outweigh the surgeon’s knife or the chemist’s drug. I will not be ashamed to say “I know not,” nor will I fail to call in my colleagues when the skills of another are needed for a patient’s recovery. I will respect the privacy of my patients, for their problems are not disclosed to me that the world may know. Most especially must I tread with care in matters of life and death. If it is given me to save a life, all thanks. But it may also be within my power to take a life; this awesome responsibility must be faced with great humbleness and awareness of my own frailty. Above all, I must not play at God.”<sup>1</sup>*

Cats should measure between 2 to 2.5 intercostal



**Figure 3.** Normal right lateral and ventrodorsal radiographs of the thorax from a poodle.

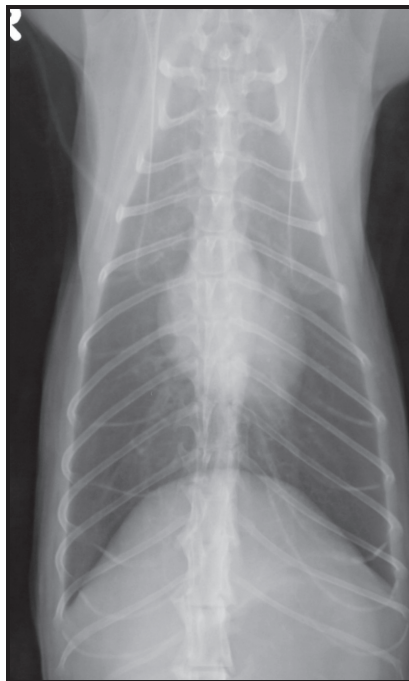
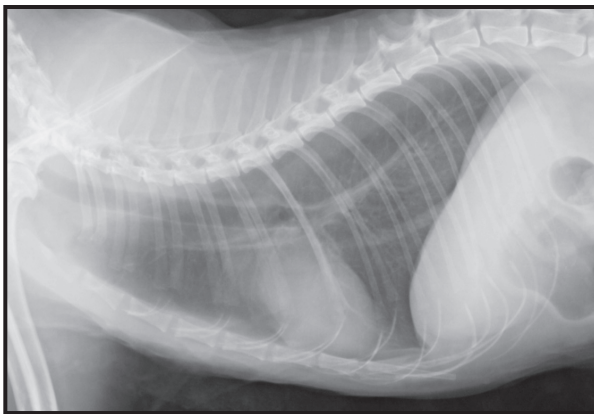
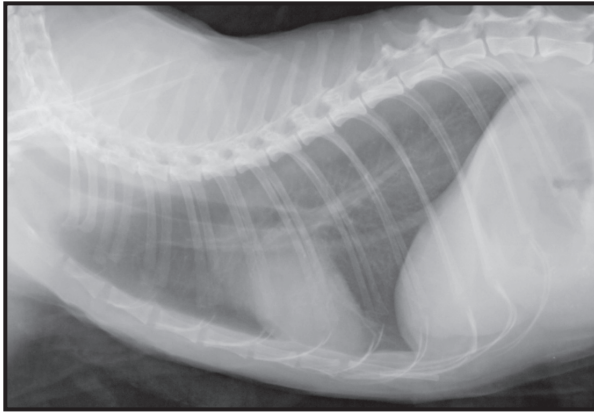
**Figure 4.** Normal right lateral, left lateral and ventrodorsal radiographs of the thorax from a Golden Retriever.



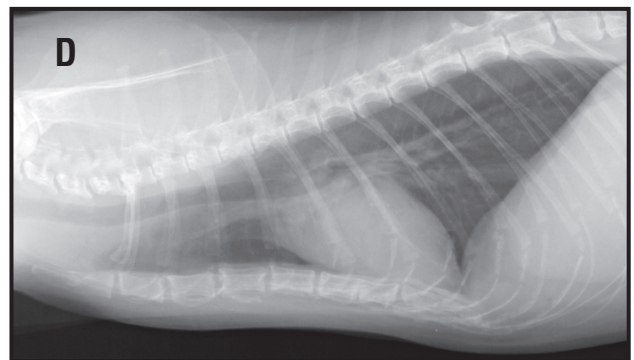
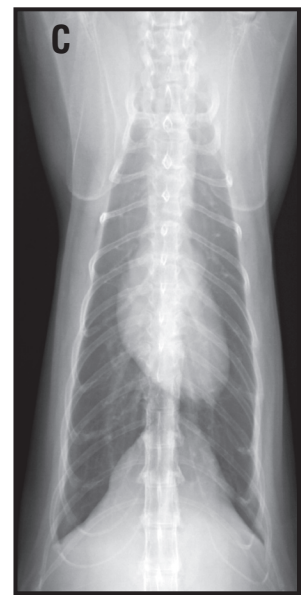
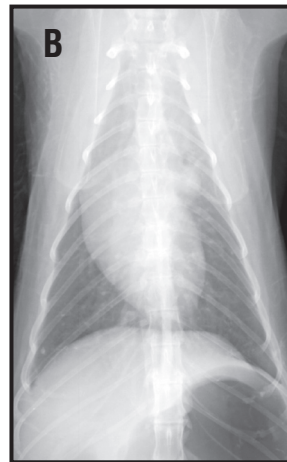
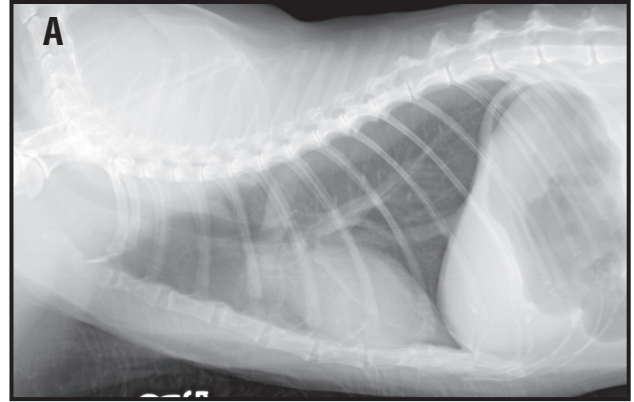
spaces on the lateral, 50% of the width of thorax (as measured above) on the VD/DV radiograph (**Figure 5**). In old cats, the cardiac silhouette will tilt cranially so measure the cardiac width perpendicular to a line from the base to the apex in order to compensate for this common age related change, (**Figure 6**). Expiratory radiographs will always make the cardiac silhouette look larger due to the decreased overall thoracic volume.

Recently, the vertebral heart score (VHS) has been used as an assessment of cardiomegaly. The way this works is that a sheet of paper is placed over the cardiac silhouette on the lateral radiograph and the heart size is marked on the paper for maximal vertical height as well as a second set of marks for maximal width of the cardiac silhouette, (**Figure 7**). These two lengths are compared against the dogs thoracic vertebrae starting at the level of T4 and the number of thoracic vertebral bodies are counted that equal the lengths of both lines (round off to the nearest 1/2). The length and the width measurement are added together to form the VHS. The normal VHS for dogs will be  $9.7 \pm 0.5$  vertebral body lengths and for cats, the normal VHS is  $7.5 \pm 0.3$  vertebral body lengths. Studies have shown that this is no more accurate than a skilled radiologist but may help practitioners that are getting started and do not know where to draw the line in the sand regarding the presence of cardiomegaly in a particular dog. The only caveat is that specific disorders can still be present and one can have a normal vertebral heart score (pulmonic stenosis, right heart disorders or sub aortic stenosis). To be fair, in certain cases the cardiac abnormality is in fact not a size abnormality but a contour or shape abnormality where a specific cardiac chamber or great vessel is enlarged. In these cases, angiocardiology or echocardiography will be necessary for complete intracardiac evaluation.

Normal lungs are relatively black with small pulmonary vessels being visible out into the lung periphery, (**Figure 8**). Pulmonary arteries and veins should be approximately equal in size, measuring 0.5 to 1.0 times the width of the proximal third of the fourth rib (cranial lobar vessels) or 9th rib (caudal lobar vessels) where they cross it. The caudal lobar vessels should form a square with the rib as it crosses the 9th rib on the VD/DV, (**Figure 9**). The cranial mediastinum should not exceed the width of the vertebral bodies except in breeds such as the Boston terrier, Bulldog, Pekinese or Pug, very obese animals or immature animals with a normal thymus (that will extend to the left of the vertebral bodies in the ventral mediastinal reflection).



**Figure 5.** Normal right lateral, left lateral and ventrodorsal radiographs of the thorax from a cat.



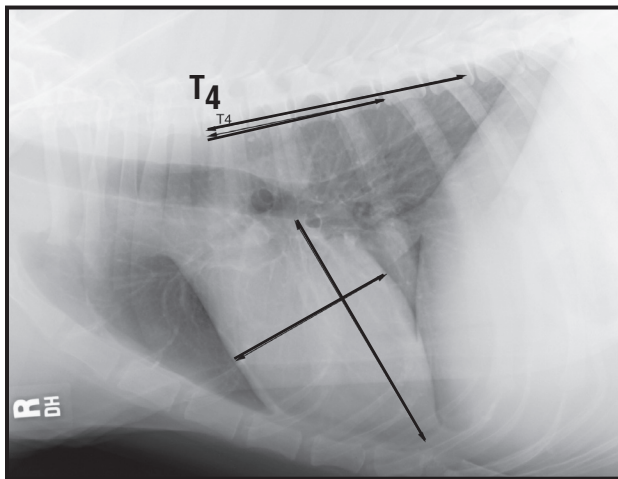
**Figure 6.** Normal right lateral and ventrodorsal radiographs from a 14-year old (A, B) and a 12-year old cat. Notice the way the cardiac silhouette becomes more parallel to the sternum (“lazy heart”) on the lateral radiographs (A,C) and the focal soft tissue rounded structure just to the left of the thoracic vertebrae on the VD radiograph (B,D; redundant aorta). These changes are expected geriatric changes in older cats.



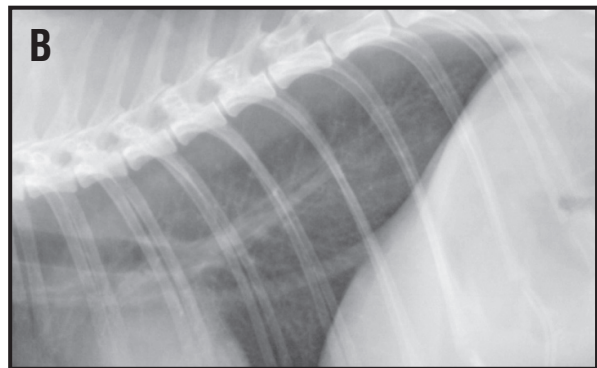
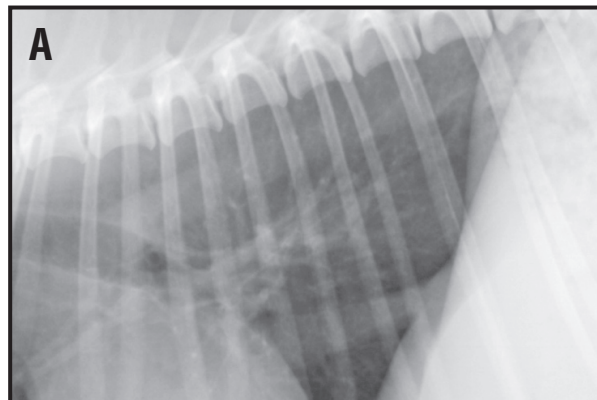
## Normal Anatomy and Normal Variants

It is beyond the scope of these notes to review thoracic anatomy of the dog and cat as well as the specifics regarding individual breed variations. Some general rules of thumb have been previously described. To review some of the basic anatomic features of the thorax, we will start with a lateral radiograph. On a right lateral radiograph, the cardiac silhouette has an oval or egg shape with the base (dorsal) aspect of the cardiac silhouette being located in a craniodorsal position while the apex or pointed end will be located in a caudoventral position. The right and left diaphragmatic crura can be split out and visualized as distinct structures in dogs, but rarely in cats. The right and left crura usually parallel each other. The caudal vena cava is seen to insert into the right crura at the caval hiatal opening. The trachea enters the thorax at the thoracic inlet and there is usually increased soft tissue opacity dorsal and ventral to the cranial thoracic trachea that represents the normal soft tissue structures of the cranial mediastinum (including nerves, cranial vena cava, brachiocephalic trunk, aortic arch, left subclavian, azygous vein, cranial mediastinal lymph nodes, esophagus, etc.).

Ventral to the trachea in the cranial thorax are two circular lucencies. The smaller cranial one lucency represents the lingual portion of the left cranial lung lobe (cranial sub-segment) as it is positioned across the cranioventral mediastinum in a left to right position. This oval usually points in a cranio-dorsal to caudoventral direction. The larger triangular lucency just cranial to the cardiac silhouette is the ventral portion of the right cranial lung lobe that extends from the right thorax across the ventral midline to a left sided position. The structures contained between these ventral lobar crossings are



**Figure 7.** Right lateral radiograph from a dog. The lines indicate the measured height and width of the cardiac silhouette. These distances are then compared with against the number of vertebrae starting at T4 and measuring caudally. The number of vertebral bodies of each line is then added together. In this dog, the VHS is 9.5 vertebral bodies and within normal limits.

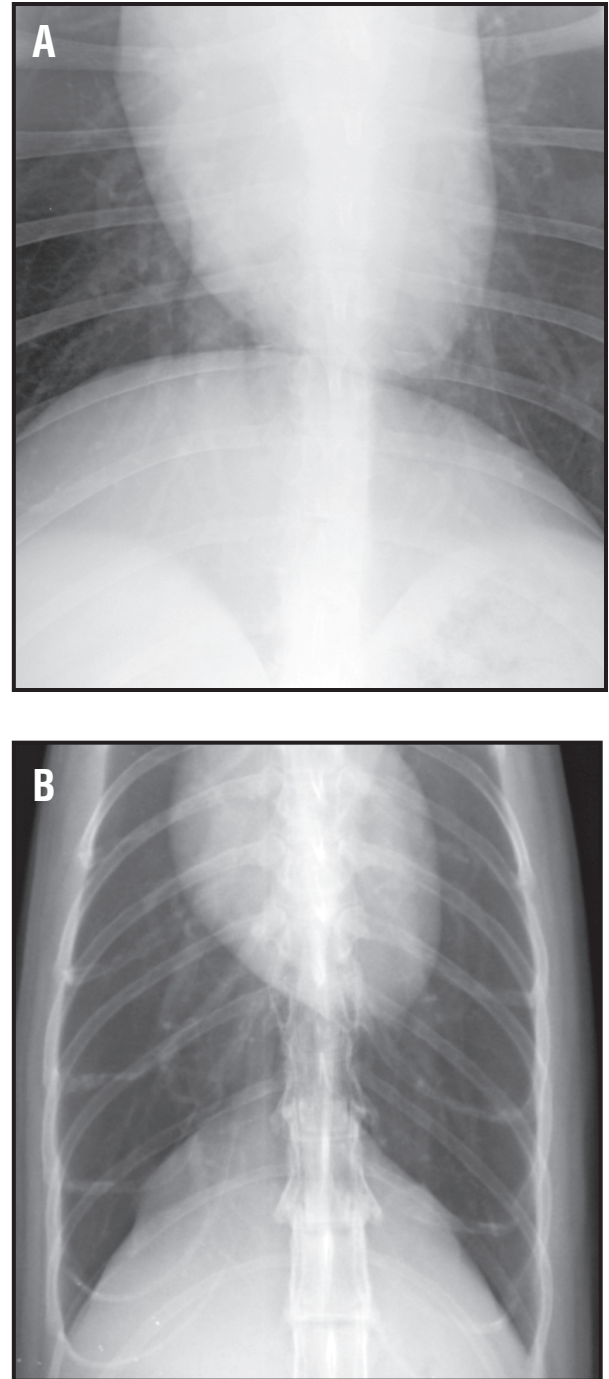


**Figure 8.** Close up of the caudal lung field from a right lateral radiograph from a dog (A) and a cat (B). The pulmonary vessels are visualized because of the contrasting air within the alveolar space of the lung lobes.

found in the cranial mediastinal reflection.

The thymus, sternal lymph nodes and several vascular structures normally reside in these locations (internal thoracic artery, etc.). In young animals, the thymus can be seen in this mediastinal reflection just cranial and to the left of the cardiac silhouette on the VD radiograph. On the lateral radiograph, the thymus typically is not seen. If present, the thymus will be located just cranial to the cardiac silhouette or may even border efface with the cardiac silhouette, (**Figure 10**). Typically the thymus appears as a curvilinear structure seen at the cranial margin of the cardiac silhouette.

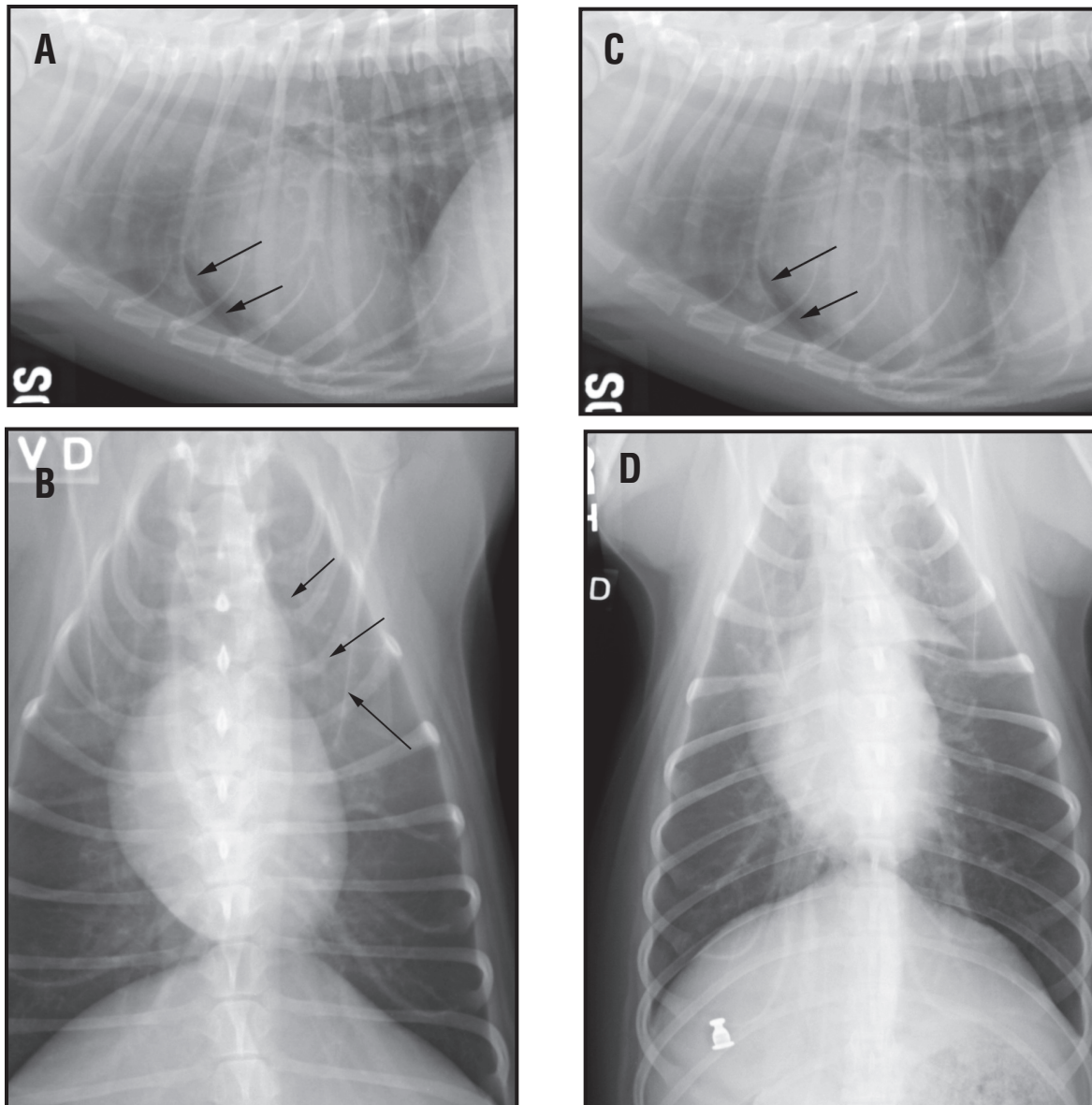
On the left lateral radiograph, the cardiac silhouette will normally shift caudal and dorsal so that it takes on a more circular shape, (**Figure 11**). The caudal vena cava will cross the caudal border of the cardiac silhouette rather than terminating at this point and insert into the right atrium (which is now located in a mid-dorsal cardiac position). The caudal vena cava (CVC) will also insert into the right diaphragmatic crus on the left lateral radiograph at a mid thoracic position as seen on the right lateral radiograph, (**Figure 12**). The CVC tends to slope caudal and dorsal as it moves toward the caval hiatus in the right crus on the left lateral, whereas the CVC tends to be parallel to the vertebral column as it inserts into the right crus on the right lateral radiograph. The two crura will also diverge away from each other as you trace them from a cranioventral (level of the CVC) to a caudodorsal position (level of the thoracic vertebrae). On the left lateral, the cranial lobar pulmonary vessels will parallel each other while on a right lateral the right and left cranial lobar bronchi and vein will cross just cranial to the base of the cardiac silhouette and continue to diverge away from each other. The remaining structures are similar in their radiographic appearance and position on either lateral radiograph. In some large breed dogs, the right cranial lobar pulmonary vein will be larger than the corresponding artery. This should be interpreted as a normal variant and not venous engorgement secondary to left sided heart failure and venous



**Figure 9.** Close up ventrodorsal radiograph of the caudal lung lobes from the same dog (A) and cat (B) as in Figure 8. The pulmonary vessels will summate with the ribs at the level of the 9th or 10th rib forming a square. If the vessels are enlarged then a rectangle will be formed in the horizontal (transverse) direction. If the vessels are small, then a rectangle will be formed in the craniocaudal (sagittal) direction. The pulmonary artery (lateral) and the pulmonary vein (medial) should normally be matched in size.

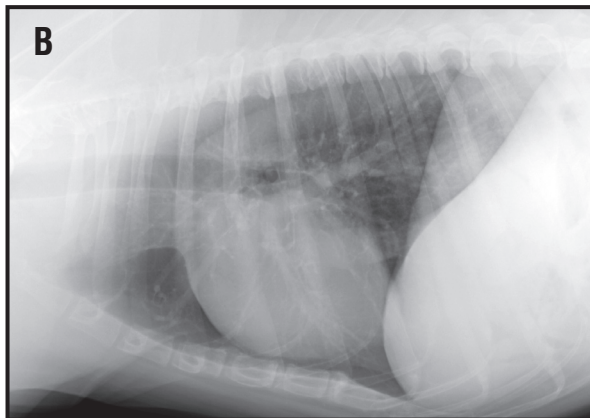
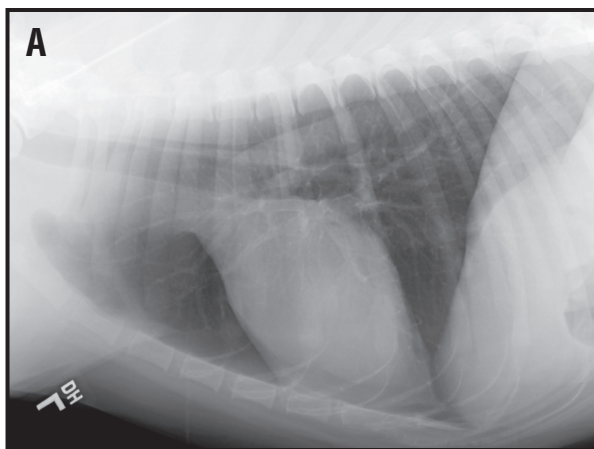
congestion, unless there are other radiographic abnormalities that would corroborate this finding.

On the VD radiograph, the cardiac silhouette has a more oval appearance and is longer from a base to apex length when compared to a DV radiograph from the same animal, (**Figure 13**). On the VD radiograph, the right and left diaphragmatic crura form two convex soft tissue margins that contrast with the caudodorsal aspects of the right and left caudal lung lobes. Again, pulmonary vessels should be seen well into the periphery of the lung fields. There will be a single soft tissue line that extends from the apex of the cardiac silhouette toward the left side of the diaphragm caudally. This represents the caudoventral mediastinal reflection and the leftward most extent of the right



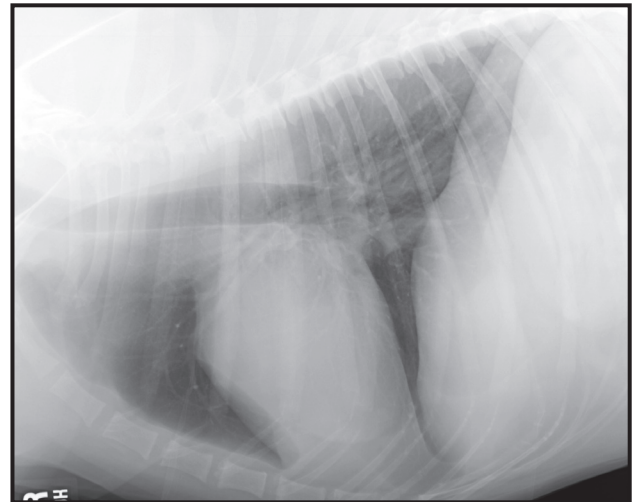
**Figure 10.** Right lateral and ventrodorsal radiographs from two immature dogs. A triangular soft tissue opacity is seen along the left cranial mediastinal reflection on the ventrodorsal radiograph (B, “sail sign”) and there is a curvilinear soft tissue opacity noted along the cranial border of the cardiac silhouette (A). These radiographic findings are consistent with a normal thymus in an immature animal. Second right lateral (C) and ventrodorsal (D) radiographs from an immature dog with a prominent thymic remnant. A metallic foreign body is present in the pylorus of the stomach.

accessory lung lobe. Additionally, there will be the extension of the right cranial lung lobe around the cranial aspect of the cardiac silhouette and into the mid line position or just to the left of the vertebral bodies in the left hemithorax. Additionally, the rightward and cranial extension of the left cranial lung lobe (lingula) across the cranial most extent of the thorax can be seen at the thoracic inlet extending from the left side to the right. These areas where lung lobes from one side of the thorax cross over to the other hemithorax are called mediastinal reflections, (**Figure 14**). All three of the described mediastinal reflections are ventral in position and can be used as useful anatomic landmarks for recognizing location and extent of various pathological processes. The described differences between the right and left lateral radiographs are primarily seen in large breed dogs. Cats and other small breed dogs will not have these dramatic differences. In fact, the diaphragmatic crura in cats will be superimposed over each other in 99% of the normal thorax lateral radiographs evaluated.

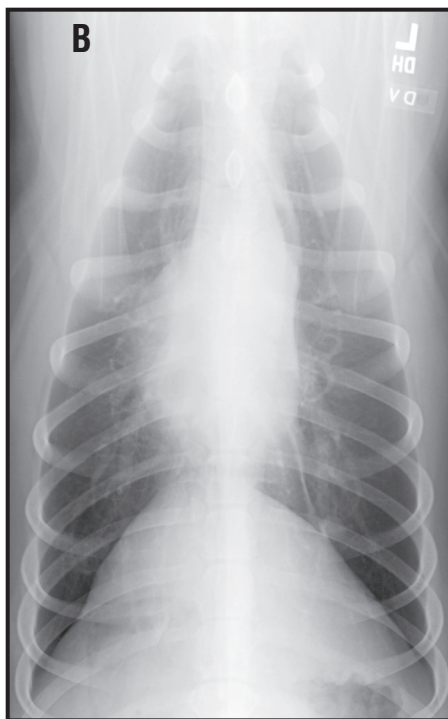
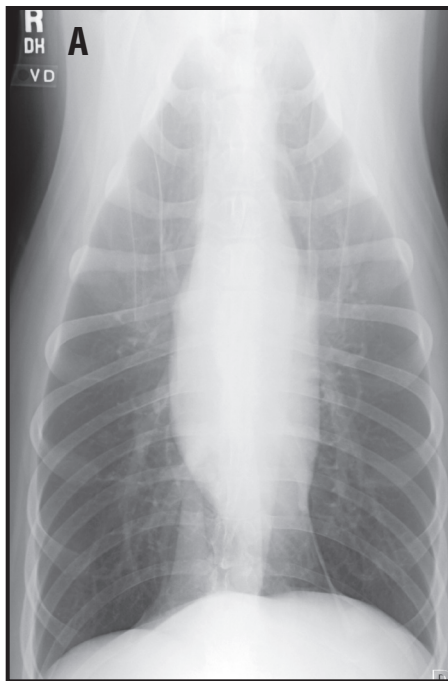


**Figure 11.** Left lateral radiographs (A,B) from two large breed dogs. Notice the divergence of the diaphragmatic crura away from the level of the caudal vena cava (dorsally and caudally). The dorsal border of the caudal vena cava is traced to the right diaphragmatic crus (caudal most crus). The caudal vena caval shadow is also seen extending over the cardiac silhouette caudally (B). This is consistent with the round appearance of the cardiac silhouette as the cardiac apex rotates away from the sternum. This gap between the cardiac silhouette and the sternum should not be misdiagnosed as a pneumothorax.

As previously described the cardiac silhouette on a DV radiograph will be shorter in length but still maintain an oval shape with smooth margins. Normally the apex of the heart points toward the left costophrenic recess and the left sided caudoventral mediastinal reflection, (**Figure 15**). This is called a levocardiac position. If the cardiac apex is pointing toward the right costophrenic recess, then a dextrocardiac position is described. Causes of a dextrocardiac position would include right middle and/or right caudal lung lobe atelectasis, left sided thoracic masses with displacement of the cardiac silhouette away



**Figure 12.** A right lateral radiograph from the same dog in Figure 11(A). Notice how the two diaphragmatic crura remain parallel to each other from the caval hiatus dorsally and caudally. The dorsal border of the cranial vena cava can be traced onto the right diaphragmatic crus, which is the cranial most crus. The caudal vena cava inserts into the right atrium at the level of the caudal cardiac silhouette. The cardiac silhouette is oval in shape.



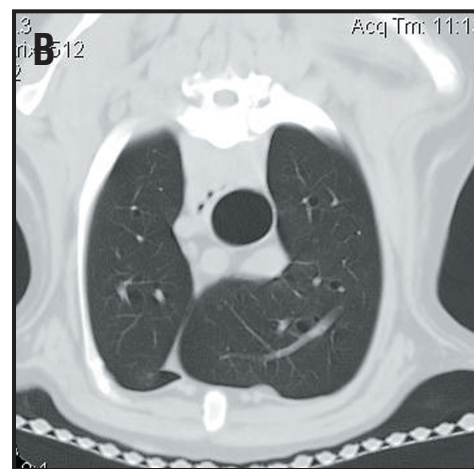
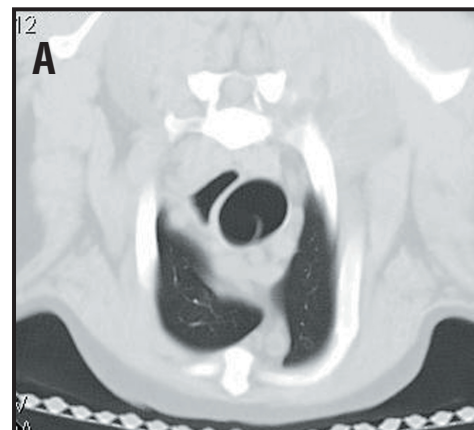
**Figure 13.** Ventrodorsal (A) and dorsoventral (B) radiographs from the same dog as in Figures 11A and 12. On the VD radiograph, the cardiac silhouette appears extended or elongated in the base to apex position. On the DV radiograph, the cardiac silhouette appears foreshortened. The caudal lobar vessels can be seen further into the periphery on the DV radiograph than on the VD radiograph. On the VD radiograph, the right and left diaphragmatic crura appear as two semicircular structures.

from the mass, situs inversus or a normal anatomic variation seen on the DV radiographs of some large breed dogs. The DV radiograph also provides a better look at the caudodorsal lung fields when compared with the VD radiograph. If a nodule or enlargement of a pulmonary artery/vein is suspected in the caudal lung lobes, a DV radiograph may be helpful for further evaluation of this area. More specifics regarding anatomic details of each structure that are normally seen on the lateral and VD/DV thoracic radiograph will be described within the appropriate thoracic compartment.

### Systematic Evaluation or Interpretation Paradigm

The entire right/left lateral and VD/DV radiograph must be reviewed, even if you find a huge mass in the lung or if the cardiac silhouette looks normal and the films were taken because the dog had a murmur. The most reliable systematic approach we have found is to evaluate the thorax organ by organ, structure by structure beginning at the periphery of the film while constantly asking questions of oneself (**Table 1**). Always ask, “What have I missed?” as one tries to tie

**Figure 14.** A transverse CT image from a dog at the level of T1, (A). Notice the rightward extension of the left cranial lung lobe (lingula) ventrally. This is the first ventral cranial mediastinal reflection. Transverse CT image from the same dog at the level of T3, (B). Notice the leftward extension of the right cranial lung lobe ventrally. This is the second ventral cranial mediastinal reflection.



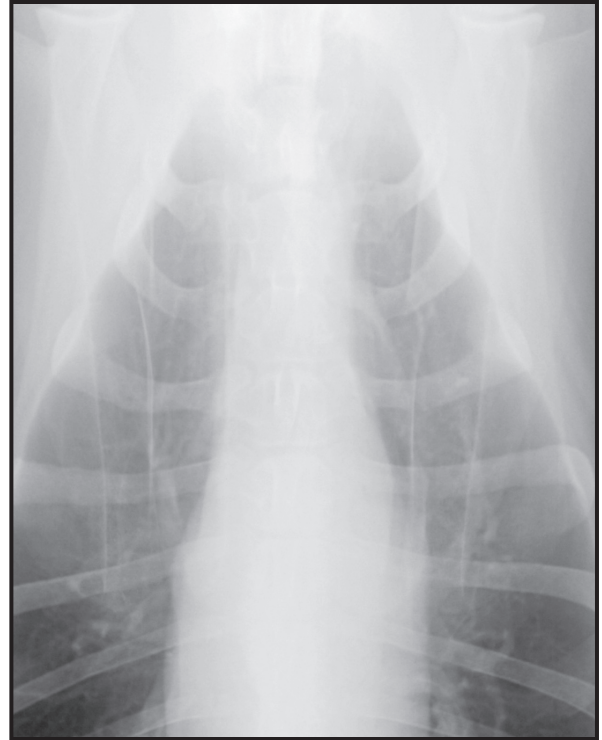together all of the abnormalities, (**Figure 16**). Also, ask if the abnormalities identified can be grouped into a “pattern” that might be characteristic for a specific disease, (**Figure 17**). Anytime one stops one search and focuses on a specific area or structure, the question becomes is the structure normal or abnormal? If the structure is abnormal than one should be able to describe the abnormality in terms of abnormal number, shape, location, size, contour (margin), and opacity. These roentgen descriptors should form the basis for the describing the abnormality. Based on this description one can then formulate differential diagnoses for that specific problem. Keeping a running list is often useful for all of the radiographic abnormalities. In trying to simplify our approach we are going to divide the thorax into four specific compartments. Typically disease processes will respect (not cross over) these boundaries and this will help in terms of localizing abnormalities to a specific space or compartment. The four compartments include the extrathoracic structures (thoracic wall, diaphragm, vertebrae, ribs, sternbrae, thoracic inlet and thoracic limbs), the pleural space, the pulmonary parenchyma and the cranial, middle [cardiac silhouette] and caudal parts of the mediastinum. The list of possible structures to evaluate and review is summarized in **Table 1**.

### **I. Extrathoracic Structures: The Thoracic Wall**

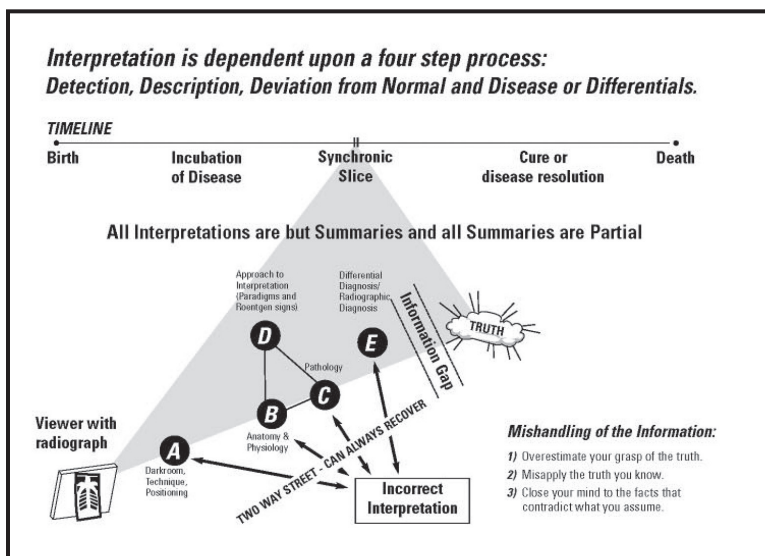
The practitioner when evaluating extrathoracic structures should consider the following questions as a minimum database. These include: Are the soft tissues normal and/or is there any soft tissue mass or swelling? Are all of the ribs normal? Are there any rib fractures or deformities? Is there evidence of a rib tumor? Is the vertebral column and sternbrae normal? Is there a fracture, luxation, subluxation, discospondylitis, vertebral or sternbral tumor, septic spondylitis or congenital deformity of the thoracic vertebrae? Are there any abnormalities of the soft tissues and structures of the cervical area? Are there any abnormalities of the soft tissues and structures of the cranial abdomen? Are there any diaphragmatic abnormalities?

Are the soft tissues normal? Evaluate the soft tissues dorsal to the spinous processes and ventral to the sternum on the lateral radiograph and on the right and left sides of the ribs on the VD/DV radiograph. Is there any soft tissue mass or swelling? Include in the evaluation any fatty masses (lipomas), extraneous soft tissue polyps or nipples on the skin and any fascial planes that can be seen.

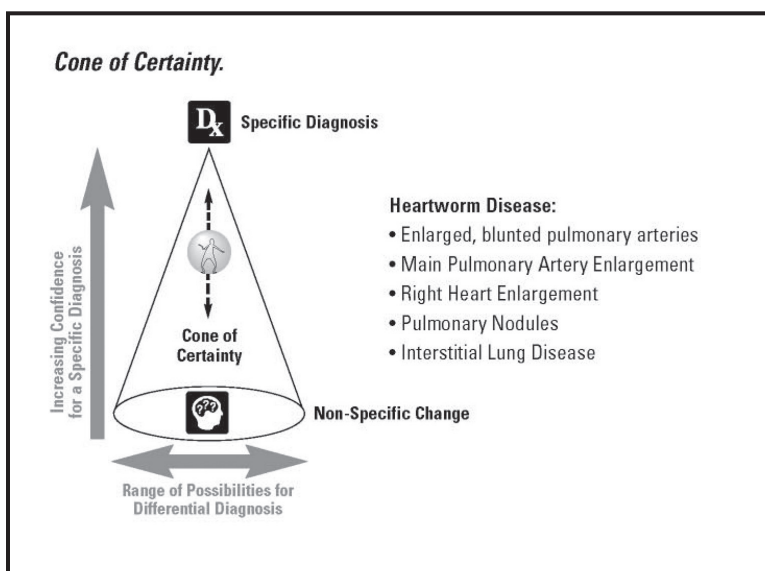
Are all of the ribs normal? Each rib should be evaluated for the rib head and costothoracic articulation on the VD radiograph to the margin of the thorax where the rib turns back on itself and then heads ventrally and cranially toward the sternum. On the lateral radiograph the costochondral junc-



**Figure 15.** A close up VD radiograph from a large breed dog. Notice how the left cranial lung lobe extends cranial to the ventral aspect of the right cranial lobe across the mediastinum (cranial most mediastinal reflection). This part of the left cranial lung lobe is called the lingula. The right cranial lung lobe extends toward the left cranial to the cardiac silhouette.



**Figure 16.** Diagram depicting the need of the radiographic reviewer to step through the interpretation process in a step-by-step fashion. If the technique and positioning are diagnostic, then one should proceed to describing the lesion. Based on these descriptions, the roentgen findings can be summarized and differentials formulated for each radiographic abnormality. One can always re-evaluate the original radiographs with repeat thoracic radiographs to document progression or regression (response) of the disease process. If things are not going the way one would expect, then a re-assessment of the possible differentials should be undertaken.

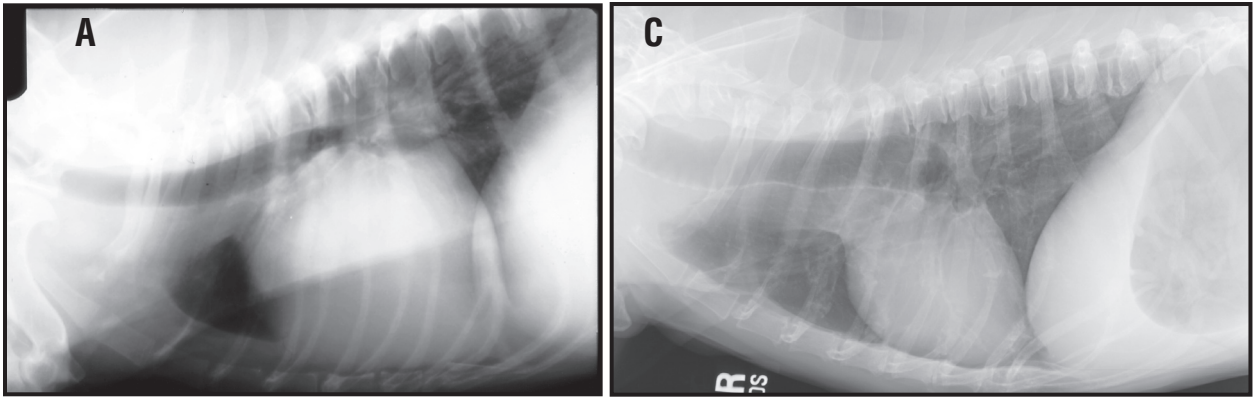


**Figure 17.** The cone of certainty represents ones certainty with which one can ascribe a specific diagnosis to a collection of radiographic abnormalities (pattern recognition). The base of the cone represents an area of extreme uncertainty and one should remember that a definitive diagnosis could be reached only with other testing. The apex of the cone represents the highest possible certainty for a specific diagnosis.

tions should be evaluated for degree of degenerative change (partial mottled mineralization and possible enlargement – particularly prominent in the chondrodystrophic breeds). In these breeds, the costochondral junctions will create an extrapleural sign that is prominent on the VD/DV radiograph, (**Figure 18**). Partial or complete mineralization of the costal cartilages occurs as the dog or cat matures and usually by middle age is complete (e.g., the costal cartilage is completely mineralized).

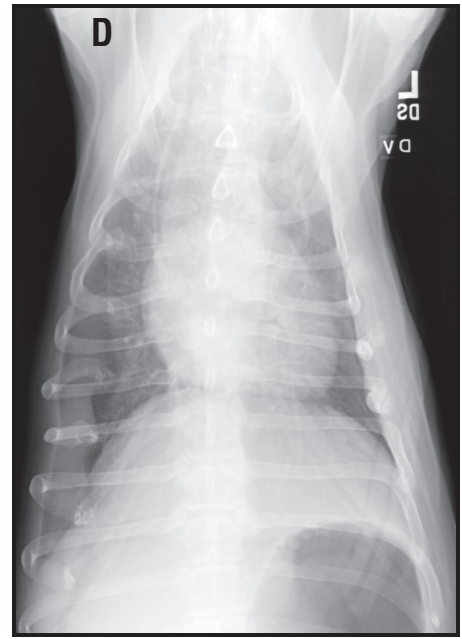
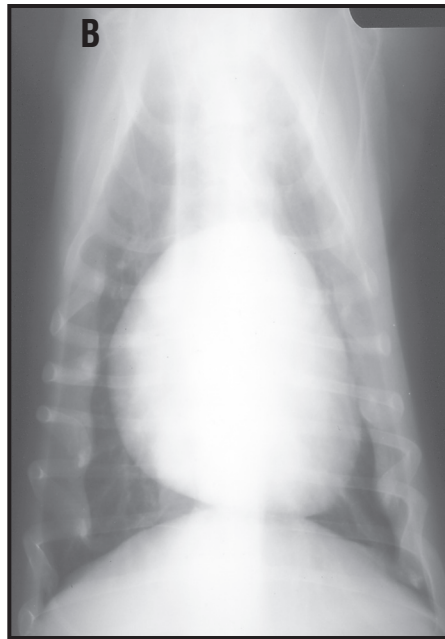Are there any rib fractures or deformities? Sharply margined radiolucent lines within the cortices of the rib are radiographic evidence of acute rib fractures. The actual fracture fragments may or may not be displaced away from each other. If there are chronic rib fractures early or healed callus may be present. Complete cortical continuity does not have to be seen in healed rib fractures.

**Radiology Tip:** Rather than looking at the lateral radiograph with the animal’s head positioned toward the viewer’s right, turn the radiograph 90 degrees so that the head of the animal is pointing up on the view box. One thing that happens over time is that as one concentrates on the intrathoracic structures, one has to ignore or “read through” the ribs. Ultimately, the visual cortex “ignores” the ribs. By



**Figure 18.** Right lateral and ventrodorsal radiographs from a Bassett Hound (A, B) and Dachsund (C,D). Note the prominence to the costochondral junctions. This creates an extra-pleural sign along both the right and left sides of the

turning the radiograph 90 degrees, you have thrown a wrench in the “normal” data base of the brain and visual cortex. Therefore, all of the ribs will stand out and it will be easier to identify



any rib abnormalities. The same thing can be done for the VD/DV radiograph by turning the film 90 degrees from its normal orientation. This does not negate looking at each rib (1 rib at a time), but if the normal pattern is not seen, you will be drawn to the abnormality faster.

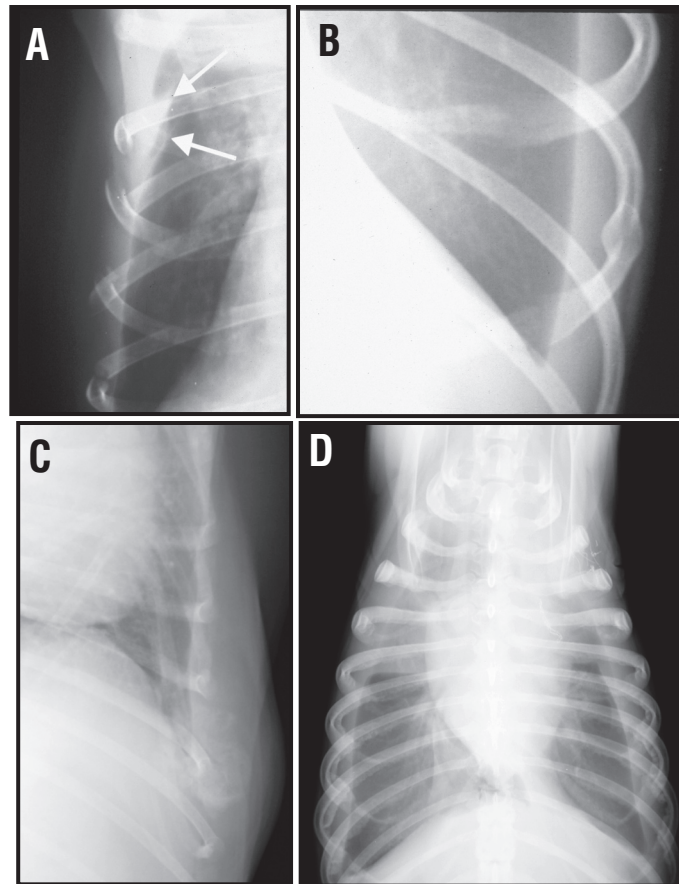
Is there evidence of a rib tumor? Expansile osteolytic lesions with cortical destruction, and disruption of the extra-thoracic soft tissues or an extrapleural sign are indicators of rib tumors. The most common form of rib tumor is a primary bone tumor (osteosarcoma, **(Figure 19)**). Metastasis to bone frequently results in rib involvement. Tumors can originate anywhere on the rib. Several thoracic tumors (metastatic pulmonary adenocarcinoma or mesothelioma) have been associated with generalized periosteal reactions of the ribs along their cranial and caudal borders. This “hypertrophic osteopathic” type of response has only been described with intrathoracic (pulmonary or pleural) neoplasia, **(Figure 19)**. Rib tumors will can cause a focal mild to severe pleural effusion associated with the lesion.

Is the vertebral column and sternebrae normal? Generally, the vertebral bodies are easily seen as block shaped structures that are mineral opacity with radiolucent intervertebral disc spaces between the vertebral bodies. On a perfectly positioned lateral radiograph, the rib heads will be superimposed over each other. Each rib will articulate with the vertebral body at the cranial aspect of the corresponding vertebral body. In cats the last several ribs appear to originate from the middle of T12



and T13. The ventral aspect of each vertebral body has concave surface and there is an increase in bone opacity at the cranial and caudal end plates that are a result of the subchondral bone plate.

Is there a fracture, luxation, subluxation, discospondylitis, vertebral or sternbral tumor, septic spondylitis or congenital deformity of the thoracic vertebrae? Evaluation of the thoracic vertebral column should include alignment relative to each other and changes in opacity and margins. Smooth new bone formation along the ventral aspect of the cranial or caudal endplates is typical findings with spondylosis deformans. This results from the vertebral bodies trying to stabilize an area that is perceived to be unstable (can be micromotion versus overt subluxation). Traumatic fracture and/or luxation(s) of the vertebral bodies can result in complete displacement of the vertebral bodies relative to each other at the site of injury or just intervertebral disc space collapse without radiographic evidence of vertebral body fracture or displacement. There may be a focal area of soft tissue swelling that indents the pleural space in the area consistent with hemorrhage associated with the traumatic injury. Extensive bridging ventral spondylosis deformans can be seen in extreme cases and is called disseminated idiopathic skeletal hyperostosis. Additionally, this can be seen in cats with hypervitaminosis A (fed a raw liver diet). Changes in the articular facets of the thoracic vertebrae are occasionally seen. Sclerosis between adjacent spinous processes can also be seen and is called Baastrup's disease. Intervertebral disc disease is uncommon from T1 through T10-11 due to the presence of interconjugal ligaments between the heads of the ribs. This additional ligamentous stabilization over the intervertebral disc space makes it harder for the nucleus pulposus to protrude or herniate dorsally. The caudal thoracic intervertebral disc space sites are still prone to intervertebral disc disease and in situ disc mineralization, end plate sclerosis and intervertebral disc space narrowing are common abnormalities. Follow up procedures, (CT, MR or myelography), are required for complete evaluation of spinal cord compression.



**Figure 19.** Close up lateral or ventrodorsal radiographs from different dogs with different pathological conditions associated with the ribs. (A). Ventrodorsal radiograph from a dog that presented after being hit by a car. Note the acute rib fractures characterized by sharp margins and discontinuity of the cortices with mild displacement. There is also a pleural effusion. (B). Ventrodorsal radiograph from a dog with a healed rib fracture. There is a smoothly marginated rounded callus noted at the site of a previous fracture. (C). Dog with a primary rib tumor. Notice the expansile nature of the tumor with mixed osteolytic and osteoproliferative characteristics. (D). Ventrodorsal and lateral radiographs from a dog with pleural carcinomatosis from an incompletely resected primary lung tumor. Notice the osteoproliferative response along each rib border consistent with a “hypertrophic osteopathy” type of reaction. This has also been reported in dogs with thoracic mesotheliomas. There is also a pleural effusion.

The hallmark features of discospondylitis include intervertebral disc space narrowing or collapse and concave osteolytic defects in the vertebral end plates. Vertebral developmental anomalies including kyphosis, butterfly vertebral segments, hemivertebrae, block vertebra and spina bifida occulta or cystica can be common findings in the brachycephalic breeds. Osteolysis is a common finding in vertebral body neoplasia. The common neoplastic disorders of the vertebrae include osteosarcoma, myeloma and metastatic (usually carcinoma – pulmonary or urogenital) disease. A compression fracture can be the only clue that there is something wrong where a pathologic fracture has resulted from osteolysis of the central aspect of the vertebral body resulting in collapse and therefore shortened vertebral body relative to the one cranial and one caudal to the abnormal vertebrae. As tumors grow larger, they can expand into the pleural space creating an extrapleural sign in the dorsal aspect of the thorax or may invade the dorsal mediastinum at the site of the vertebral tumor. Sternebral tumors are rare, however fibrosarcoma and osteosarcoma are the most common tumor types. Osteomyelitis of the caudal sternebrae with associated extrapleural masses or accessory lung lobe masses are considered characteristic of Actinomyces or Nocardia infections.

Are there any abnormalities of the soft tissues and structures of the cervical area? Common abnormalities associated with the thoracic inlet include a redundant dorsal tracheal membrane, gas within the esophagus and any ventral neck masses that are extending into the thorax at the thoracic inlet. A redundant dorsal tracheal membrane is not equivalent to a collapsing trachea, (**Figure 20**). However, with a severe redundant trachealis muscle and indentation caused by the esophagus, there can be significant diminution of the overall diameter of the trachea as it passes from the cervical soft tissues into the thoracic cavity. The thoracic inlet is a common site where esophageal foreign bodies can get stuck. Gas in the esophagus should be carefully evaluated for a foreign body. Follow-up radiographic studies with positive contrast medium should be done if clinically indicated to confirm or rule out a foreign body.

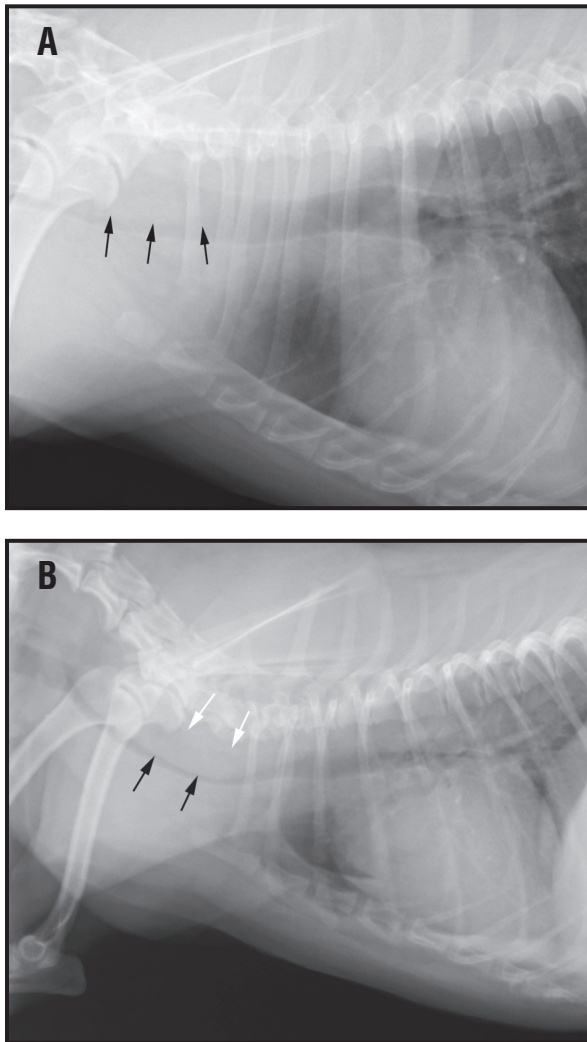
Are there any abnormalities of the soft tissues and structures of the cranial abdomen? Typically four structures are evaluated in the cranial abdomen. These include the diaphragm (cupola and crus as discussed below), the liver/gall bladder, the stomach/gastric axis and ventral fat within the falciform ligament.

Are there any diaphragmatic abnormalities? The thoracic wall is often overlooked and is probably where lesions are most frequently missed. The soft tissues should be assessed for swellings or masses. These may have been found on physical examination but should still be noted on the radiographs. A diffuse swelling of the thoracic wall may cause an apparent increase in lung opacity that could be mistaken for a pulmonary abnormality. Rib fractures can be quite difficult to detect, (**Figure 21**). The ribs should be examined carefully in every case. If a fracture is detected in an animal with no history of trauma the lesion should be evaluated for the possibility that it is a pathologic fracture. Rib tumors are often first noted as apparently small superficial lumps while frequently the internal portion of the tumor is much larger and may cause an extrapleural sign (indentation of the parietal pleural lining into the pleural space). These may be accompanied by pleural fluid that will often obscure the mass within the pleural cavity. In these cases, failure to examine the ribs will result in failure to detect the tumor. These tumors are usually sarcomas and may appear lytic, productive or both (**Figure 19**). Multiple lytic, productive or mixed rib lesions indicate plasma cell tumor, skeletal metastasis or disseminated osteomyelitis. Periosteal reactions along the caudal borders of ribs of both the right and left sides can be seen as a hypertrophic osteopathy type of response for carcinomatosis of the pleural space or in the case of mesothelioma (rare).

## II. The Pleural Space

The questions to ask oneself regarding the pleural space would include: Is the pleural cavity normal? Is there pleural fluid/effusion?, Is there a pleural or extrapleural mass? Is there any radiographic evidence of pleural air?

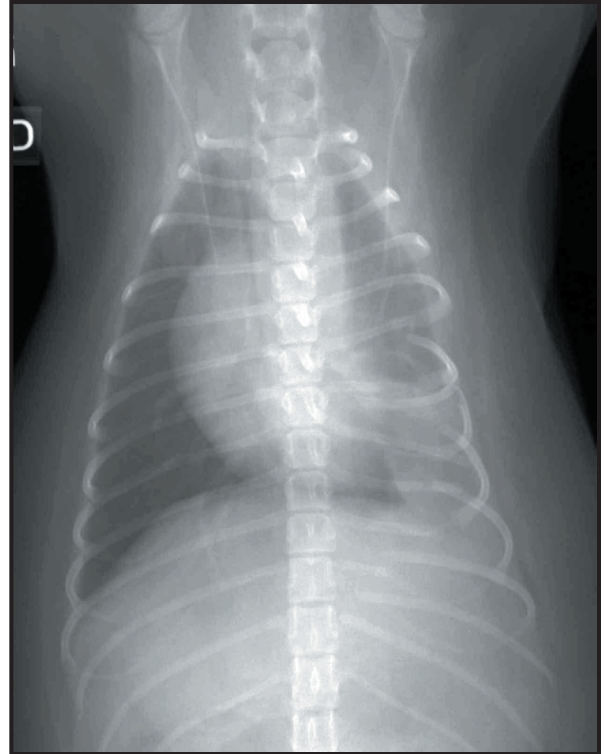
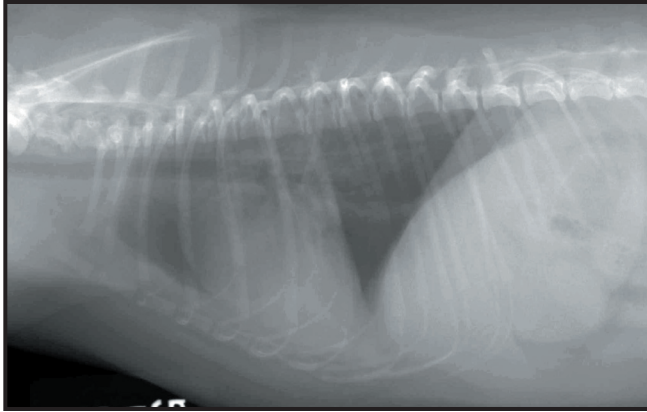
Is the pleural cavity normal? The normal pleural space is a potential space that is located between the visceral (lung surface) and the parietal (layer lining the inside of the thoracic wall and diaphragm) layers of the pleura. There is normally a small amount of pleural fluid that coats this potential space. The dynamics of the capillary pressures (Starling's law of hydrostatic pressures) regulate the production and absorption of the pleural fluid. Radiographically, the pleural space is normally



**Figure 20.** Lateral radiographs of the cranial thorax and thoracic inlet from two different dogs. The dorsal (white arrows) and ventral borders of the trachea are clearly visualized. The trachealis muscle is seen folding into the lumen (black arrows; A and B) of the trachea created a curving soft tissue opacity superimposed over the dorsal aspect of the trachea at the thoracic inlet. This is called a redundant tracheal membrane.

NOT visualized on thoracic radiographs. Review the previous descriptions of where the normal lung lobe anatomy is identified on the VD/DV and lateral radiographs in the pulmonary section (**described below, Figure 22**). Focal amounts of pleural effusion or fluid may be seen next to focal pulmonary abnormalities. Typically pleural fluid or air will accumulate in areas between the normal borders of lung lobes. A normal anatomic variant can be seen on left lateral radiographs between the ventral aspect of the right middle and right caudal lung lobes superimposed over the cardiac silhouette in older dogs, (**Figure 23**). This most likely represents an area of focal pleural thickening (Figure). Sub-pleural/pulmonary osteomas are focal areas of osseous metaplasia located just beneath the visceral parietal pleural surface. These focal areas of mineralization are small (2 to 4 mm in diameter), and typically seen ventrally and cranially. They are common in the Collie, Shetland Sheepdog and Sheltie breeds, (**Figure 24**). If the answer to this question is no, then determine if the pleural space has a soft tissue or air opacity associated with it.

Is there air in the pleural cavity? Air within the pleural space is a common sequela to trauma (hit by car/vehicle). As air accumulates within the pleural space the cardiac silhouette becomes lifted away from the sternum on the lateral radiograph. Pneumothorax is relatively easy to diagnose if the volume is large but can be overlooked if only a small volume is present (**Figure 25**). Care should be taken not to confuse skin folds with lung margins. Skin folds can be present on either the lateral or VD/DV radiograph and can lead to an erroneous diagnosis of pneumothorax if careful

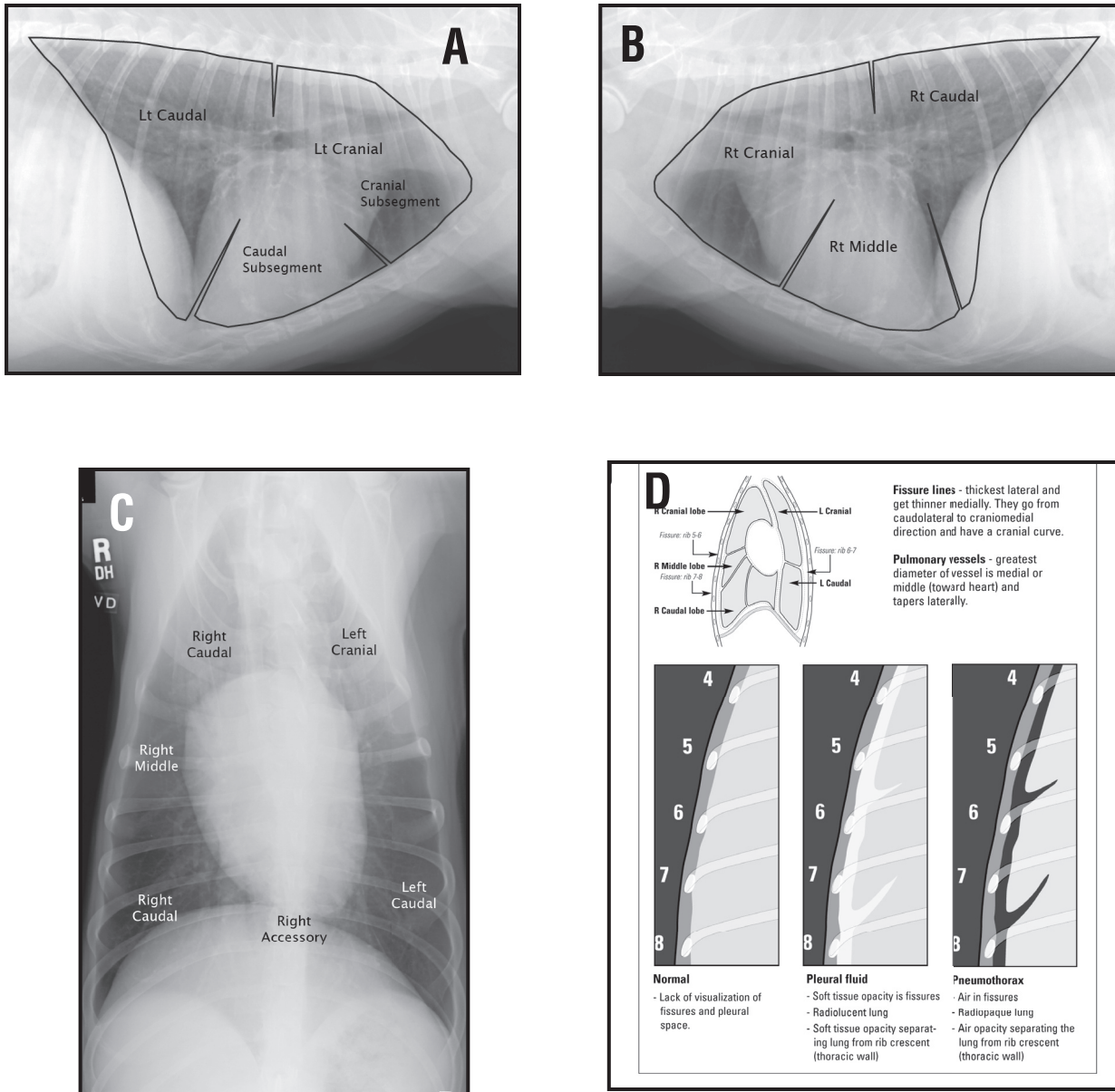


**Figure 21.** Left lateral and ventrodorsal radiographs from a dog that was hit by a car. There are multiple segmental rib fractures associated with the left thoracic wall. There is focal retraction of the left cranial lung lobe away from the thoracic wall cranial to the rib fractures. This is consistent with pleural hemorrhage. There is a severe, lobar area of alveolar lung opacity in the left caudal lung lobe adjacent to the rib fractures consistent with pulmonary contusions.

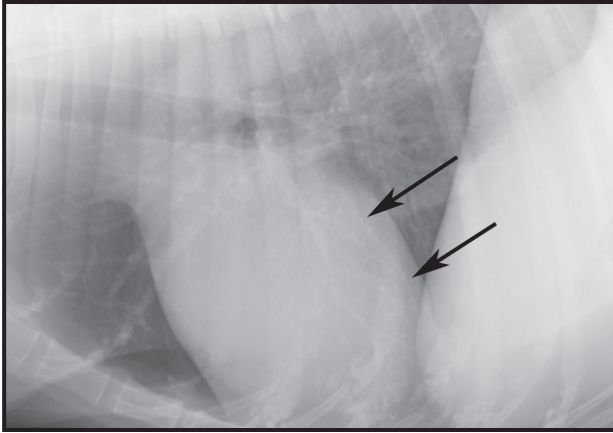
observation of pulmonary vessels beyond the skin fold margin is not evaluated. Pulmonary vessels will cross the skin fold lines but not the borders of a collapsed lung. This differentiation may not be possible except when using a hot light. Also, skin folds usually extend beyond the borders of the pleural cavity. If in doubt a horizontal beam lateral or VD/DV will confirm or exclude a pneumothorax. Other radiographic signs of a pneumothorax would include: an overall hyperlucent thorax (change in thoracic opacity); retraction of the lung margins that are outlined by air (change in margin/border and opacity of the lung and surrounding space); collapsed, small, leaf-like lung lobes that appear soft tissue opaque; absence of any pulmonary markings at the periphery of the thorax (change in opacity, location and normal structures seen in the peripheral lung lobes); and a mediastinal shift of the cardiac silhouette (change in location).

A tension pneumothorax is a life-threatening emergency in which a tear in the lung acts as a one-way valve. As the dog or cat breathes, air is pumped into the pleural space and over time this will progressively collapse the lungs. Radiographic abnormalities can include an overexpanded hyperlucent thorax or hemithorax, collapsed lung lobes and caudal displacement and tenting of part or the entire diaphragm. A tension pneumothorax can be unilateral in which case a contralateral mediastinal shift is present.

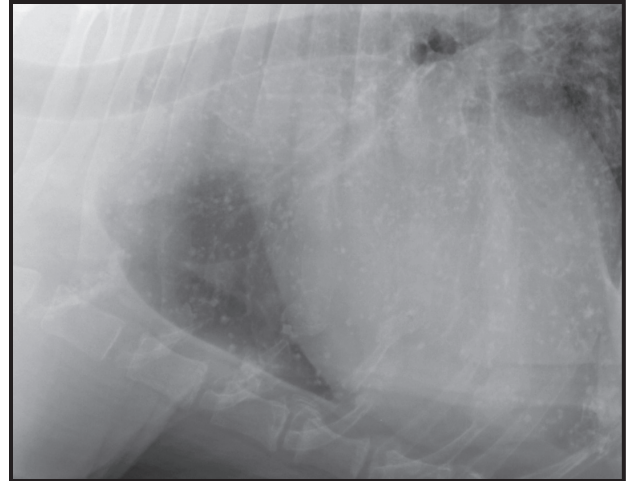
Is there pleural fluid present? Radiographic abnormalities associated with the presence of pleural fluid vary depending on the amount of volume present and the particular radiographic view made (**Figure 26**). A film obtained with the patient in sternal recumbency (DV view) is most insensitive as the cardiac silhouette and diaphragm will border efface with the pleural fluid, as fluid tends to pool in the ventral thorax and surrounds the heart. On VD radiographs, the fluid will move to the left and right of midline in the dorsal thorax. If only a small volume is present, the fluid may not be detected on either the VD or DV radiograph. If a severe volume of pleural fluid is suspected,



**Figure 22.** Right lateral (A), left lateral (B) and (C) ventrodorsal radiographs with the expected locations of the pleural fissures for each of the lung lobes superimposed over the radiograph. Notice the dorsal location of the fissure between the cranial and caudal aspects of the lung lobes on the lateral radiographs. These positions should be memorized. LCr = left cranial; LCa = left caudal; RCr = right cranial; RMid = right middle, RCa = right caudal and Acc = right accessory. (D). Schematic representation of the difference between a pleural effusion and a pneumothorax.



**Figure 23.** Left lateral radiograph from a 10 year-old dog with a history of mammary adenocarcinoma. On the left lateral radiograph there is focal linear soft tissue opacity in the area of the fissure between the right caudal and right middle lung lobes. This represents a focal area of pleural fibrosis or scarring.

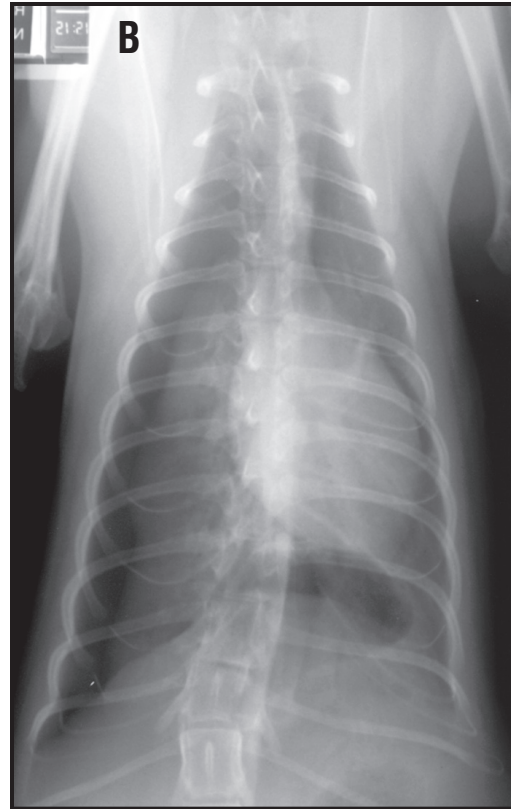
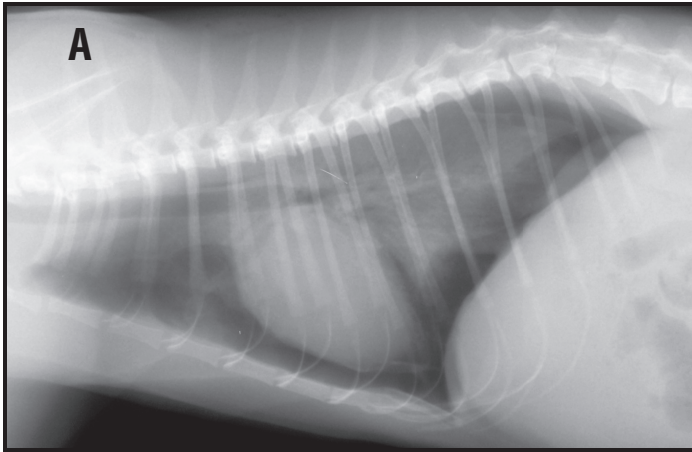


**Figure 24.** Close-up left lateral radiograph from a 10 year-old Collie. Multiple small mineralized nodules are noted over the ventral lung fields. These small nodules are 3 to 4 mm in size and are not superimposed over a pulmonary vessel. These radiographic changes are characteristic for osseous metaplasia or pulmonary osteomas. These are of no clinical significance.

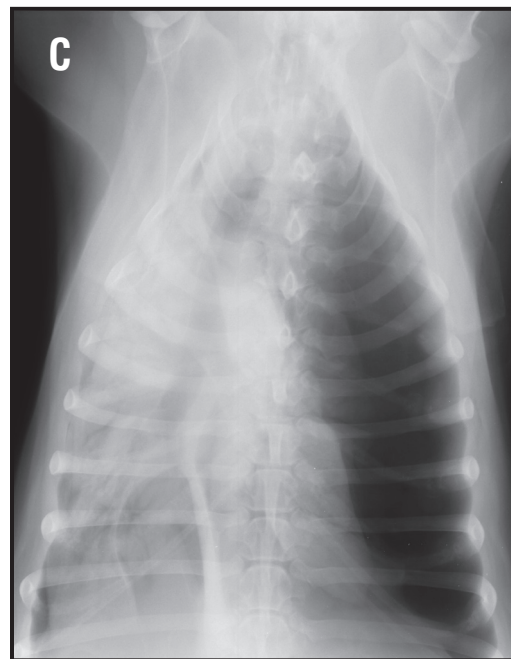
the patient should not be placed in dorsal recumbency as this will result in a severe exacerbation of any respiratory compromise. The pleural fluid can be tapped via aseptic thoracocentesis and then radiographs repeated with a proper VD or DV radiograph.

The following radiographic abnormalities indicate the presence of pleural fluid. Pleural fissure lines will be seen as soft tissue opaque lines within the interlobar fissures between lung lobes. One should not mistake the border of a rib for a fissure line on the VD or DV film. Pleural fissure lines are curved with the concave side facing caudally while the concave surface of the ribs faces cranially. Additionally, the widest point of the lung lobe separation is ventral and lateral, where as the thinnest part of the lung is at the hilus on the VD radiograph. On the lateral radiograph, a linear soft tissue opaque line will be seen separating the cranial and caudal lung lobes at the level of the 5th or 6th intercostal space. This represents the dorsal fissure between the lung lobes and will be filled with fluid if the effusion is severe. The lung margins will be retracted or separated from the thoracic wall by soft tissue opacity. Each of the tips of the lung lobes may become mildly rounded at their lateral points. If the pleural effusion is severe, increased lung opacity will be secondary to atelectasis from lung lobe collapse and compromise. The pleural fluid will partially or completely obscure the cardiac and diaphragmatic outlines that is a manifestation of border effacement or the silhouette sign.

The increase in intrathoracic soft tissue opacity should not be mistaken for pulmonary pathology. The pleural fluid contributes to increased background soft tissue opacity and will cause some degree of atelectasis that will cause the lungs to appear gray, (**Figure 27**). Decisions about pulmonary pathology are best reserved for follow up radiographs obtained after drainage of the pleural



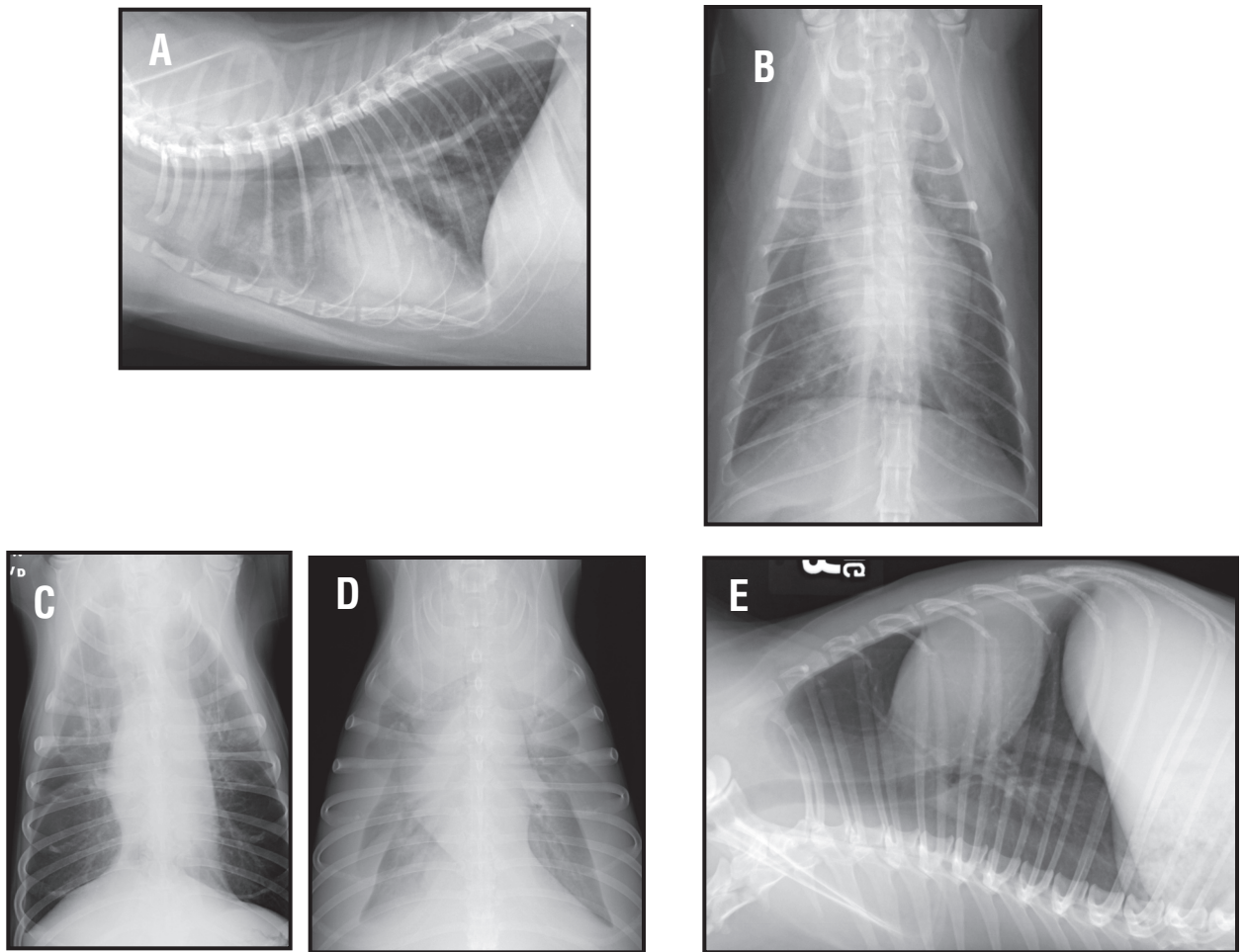
**Figure 25.** Right lateral (A) and ventrodorsal (B) radiographs from a cat that has had thoracic wall trauma. Air is located between multiple pleural fissure lines and there is retraction of the lung lobes away from the thoracic wall. This is consistent with a pneumothorax. In addition there is a comminuted compression fracture of the caudal aspect of T12 with collapse of the T12-13 intervertebral disc space. (C). Tension pneumothorax with flattening of the left diaphragm, collapse of the lung lobes and a contralateral mediastinal shift.



fluid. All fluid samples should be submitted for cytology and culture/sensitivity.

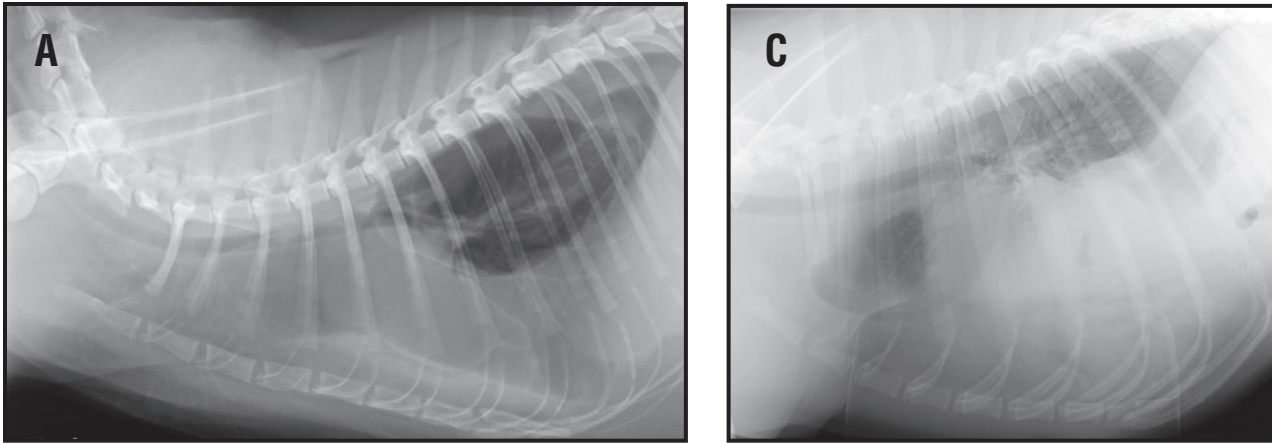
The causes of pleural fluid are many and include right heart failure, hypoproteinemia, hemorrhage, neoplasia (extra or intrathoracic), infection, inflammation, right middle lung lobe torsion, pancreatitis, thoracic duct rupture and diaphragmatic rupture, (**Figure 27**). The thorax should be examined for evidence of cardiac disease, trauma or neoplasia. Asymmetric fluid distribution or fluid that remains fixed in a focal position warrants closer scrutiny. In this case, the ribs and thoracic wall should be examined to ensure a tumor has not been overlooked. The possibility of an incarcerated diaphragmatic hernia containing liver, spleen or part of the gastrointestinal tract should also be considered. Trapped fluid or unilateral fluid accumulation is usually the result of an inflammatory or infectious process. Pyothorax, especially in cats, may be unilateral. The mediastinum in cats and dogs is complete but permeable meaning that transudates will move from the left to the right hemithorax. However, this permeability is usually blocked or sealed by in the case of an inflammatory effusion. Common causes of unilateral pleural effusion include pyothorax, chylothorax, hemothorax and neoplasia. Fixed pockets of fluid may occur if adhesions develop between the parietal and visceral pleura trapping the fluid in place. Ultimately, a sample of fluid must be obtained for analysis to further the diagnostic process. Again, there will be retraction of the visceral pleural surface away from the parietal pleural space. The lung lobe retrac-

## Thoracic Radiology

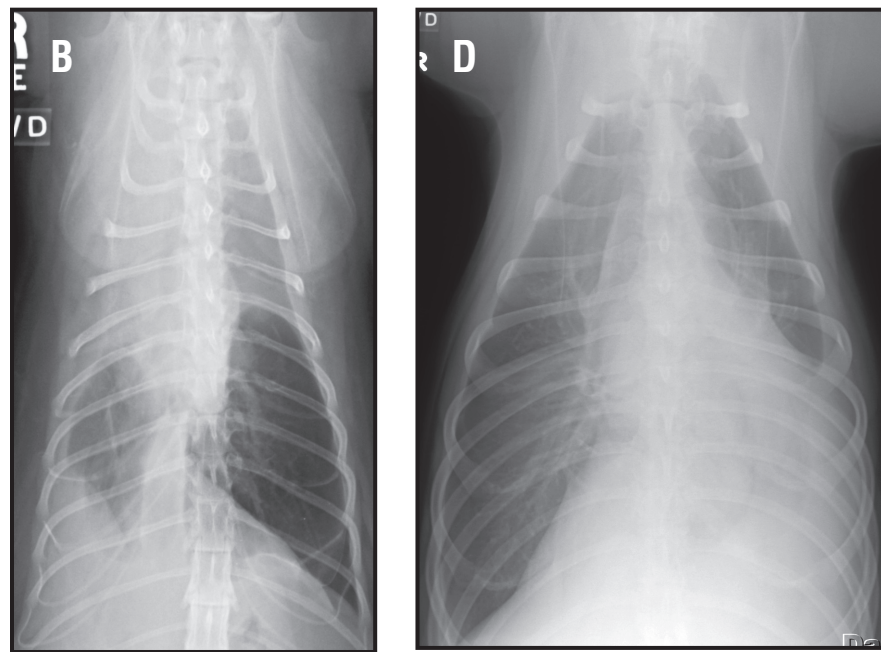


**Figure 26.** Right lateral (A) and ventrodorsal (B) radiographs from a cat with a pleural effusion. Note the location of the lung lobe fissures and retractions of the lung lobes away from the thoracic wall. The cause of this pleural effusion was congestive heart failure secondary to hypertrophic cardiomyopathy. Note that the widest point at the pleural margin whereas the point of the fissure line extends medially toward the cardiac silhouette. Also, the fissure lines on the VD radiograph are noted superimposed over the 6th and 8th intercostal spaces. There is a multifocal ventral interstitial pulmonary pattern present, best seen on the lateral radiograph. These changes are consistent with pulmonary edema. Ventrodorsal (C) radiograph from a dog with a mild pleural effusion. Note the location of the fluid within each of the fissures between the lung lobes. Ventrodorsal (D) radiograph from a dog with severe bilateral pleural effusion. Note the degree of opacity to the lung lobes secondary to atelectasis and superimposed pleural effusion. Also, the borders of the cardiac silhouette can be visualized because the fluid is accumulating dorsally in the paravertebral pleural spaces as the dog is in dorsal recumbency. A right lateral (E) radiograph has been manipulated to be oriented as if a horizontal beam radiograph with the dog in dorsal recumbency were made. Gravity would cause the pleural fluid to collect within the dorsal paravertebral pleural spaces.





**Figure 27.** Right lateral (A) and ventrodorsal (B) radiographs from a cat with a unilateral pleural effusion secondary to a pyothorax. Notice on the lateral radiograph, the degree of soft tissue opacification of the entire lung field. This soft tissue opacity is because of the pleural effusion and not lung lobe pathology within the aerated lung lobe. Right lateral (C) and ventrodorsal (D) radiographs from a dog with a left sided diaphragmatic hernia/tear. There is a focal pleural effusion. There is border effacement between the cardiac silhouette, abdominal structures (liver) and the left side of the diaphragm. Because all of these structures were the same radiographic opacity and touching each other, the borders cannot be visualized.



tion will be caused by soft tissue opacity. The pleural fluid can be caused by a transudate, modified transudate or exudate. If the exudate is chronic there will be rounding of the visceral pleural lung margins. This rounding is caused by fibrous thickening along the visceral pleural margin and is called the pleural peel, (**Figure 28**).

Is there a pleural or extrapleural mass? Masses arising from the thoracic wall and pleura can be accompanied by moderate to severe pleural effusions that will obscure the actual tumor due to border effacement. Even after thoracocentesis, the pleural mass(es) may still be difficult to identify. Radiographic abnormalities might include pleural fluid and a mass with an extrapleural sign. Masses that arise from the parietal pleura or chest wall have a broad base of attachment and blend gradually with the wall of the thorax that is referred to as the extrapleural sign. Additionally, osteolytic or osteoproliferative changes of the ribs may also be present if the mass is originating from the rib itself.

## Thoracic Radiology

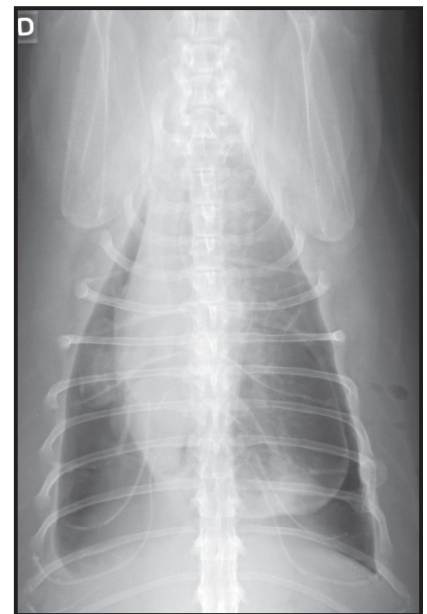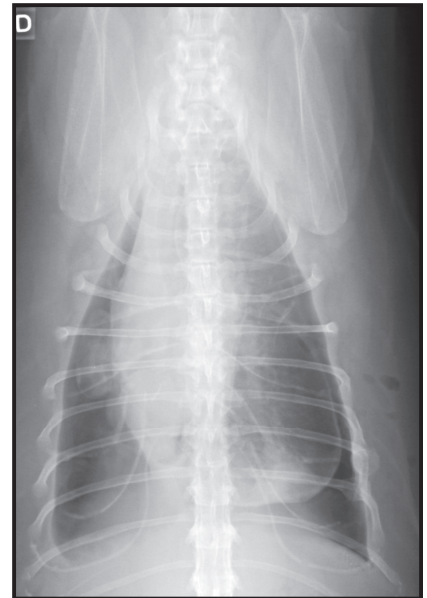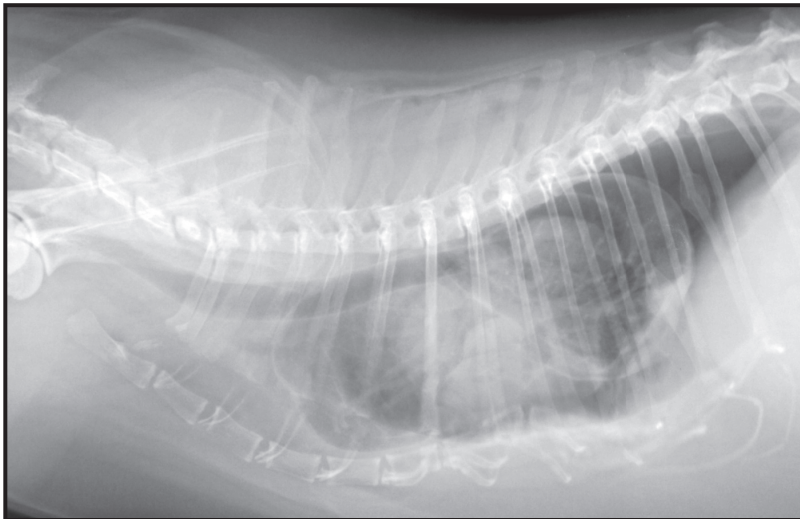
If a chronic pleural effusion is present that is bilateral, there are several diseases that can be difficult to identify, particularly if repeated thoracocentesis only yields a modified transudate. These diseases include right middle (or other lobe) lung lobe torsion, chronic diaphragmatic hernia, or an intrathoracic tumor (including the often overlooked rib tumor). The work up of these cases may require thoracic ultrasound, positional radiographs (horizontal beam hanging VD or left lateral) or peritoneography for complete evaluation.

### **III. Pulmonary Parenchyma (The Lungs)**

The normal lung parenchymal radiographic appearance is defined by two basic structures. The first is the air filled alveoli (majority of the lung being seen as radiolucent or air opacity). The second set of structures includes the pulmonary vessels and bronchi that extend from the pulmonary hilum into the periphery (presents as linear soft tissue opacity). In the dog and cat there are six lung lobes. The right side is divided into four lobes including the right cranial, middle, caudal and accessory lobes. The left side is divided into two lobes including the left cranial (cranial and caudal subsegments) and caudal lung lobes. It is important to know the expected position of the lobar fissures relative to the thoracic cavity (ribs or intercostal spaces). The right cranial lung lobe bronchus is the first oval radiolucent opening as you trace the trachea over the heart base on the right lateral radiograph. This bronchus is readily visualized on the

---

**Figure 28.** Right lateral and ventrodorsal radiograph from a cat with a chronic pleural effusion caused by a chylothorax. There has been chronic scarring and fibrotic changes associated with the caudodorsal aspect of the caudal lung lobes. A therapeutic thoracocentesis was done just prior to radiographs. There is a pneumothorax present and the lung lobes are fixed in their position and ability to inflate due to the chronic inflammatory changes and fibrosis associated with the visceral pleural surface. This is called a pleural peel. Chronic rib fractures are also seen. These types of rib fractures are secondary to a thoracic bellows effect. There is subcutaneous emphysema present along the left thoracic wall consistent with recent thoracocentesis.



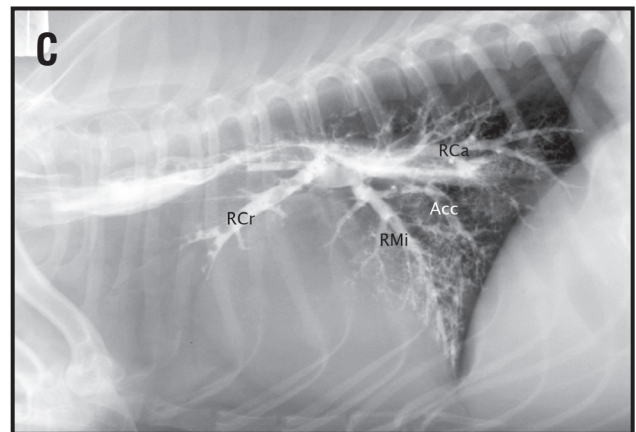
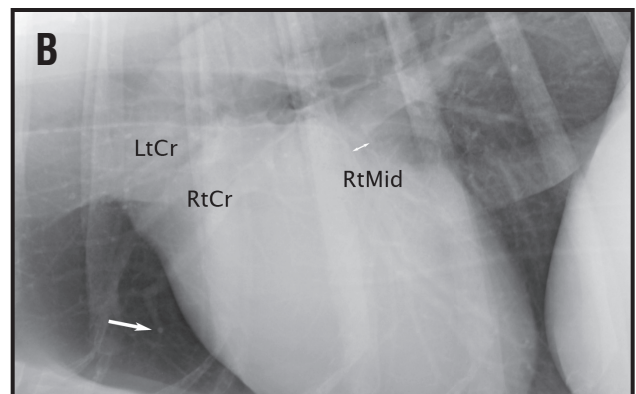
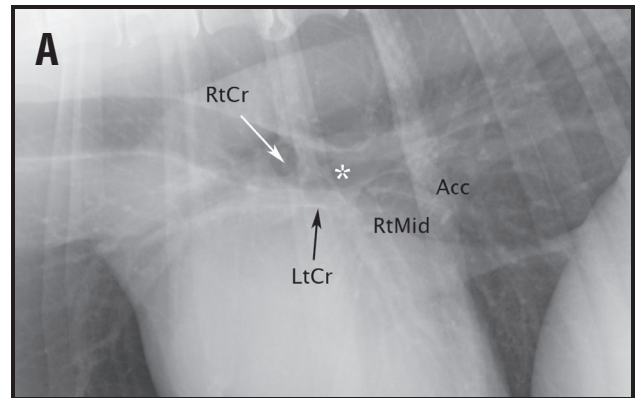
right lateral radiograph (**Figure 29**). If you trace the ventral floor of the trachea caudally, then the left cranial lung lobe bronchus points straight down on the left lateral (**Figure 29**). Within several mm to a cm (depending on the size of the dog), this bronchus bifurcates into the two segmental bronchi into the cranial and caudal subsegment of the left cranial lung lobe respectively. Again, this is best visualized on the right lateral radiograph. The pulmonary carina is the point where the caudal thoracic trachea terminates into the right and left caudal main stem bronchi. On the lateral radiograph, these structures are superimposed and cannot be delineated. On a right lateral radiograph, the right middle and accessory lung lobe bronchi are hard to identify. The right middle lung lobe bronchus comes off of the right caudal bronchus within several cm of the carina, (**Figure 30**). After another several cm, the bronchus to the right accessory lung lobe comes off of the floor of the right caudal main stem bronchus. The right middle and right accessory lung lobe bronchi can be seen on the left lateral radiograph. Typically, the right middle lung lobe is seen over the cardiac silhouette. The accessory lung lobe wraps around the caudal vena cava at the level of the plica vena cava and the ventral mediastinal reflection, (**Figure 31**). The normal anatomic locations of the lobar fissures on all radiographic views are listed in **Table 2**.

Anatomic variants that can be seen involving the lungs and airways include age related changes. Central bronchial mineralization of the tracheal rings and major bronchi can be common, particularly in chondrodystrophic breeds, (**Figure 32**). The mineral lines will be very thin and should not be mistaken for central bronchial pattern. The lungs can also have a generalized, mild to moderate unstructured interstitial lung pattern that represents pulmonary fibrosis when evaluated using routine histology and has been called geriatric fibrosis.

A generalized increase in film blackness in the lung fields is described as a hyperlucent lung field. Technical factors that can cause this appearance include overexposure, overdevelopment, and technical factors that could result in film fog (improper safety light for green film, darkroom light leaks, etc.). Many causes can result in this radiographic appearance. This may be a normal variant, especially in thin deep chested dogs (greyhounds, etc.) or the result of cachexia. Abnormalities that cause generalized hyperlucency include any disease that reduces the circulating vascular volume such as dehydration, haemorrhagic shock, or Addison's disease, (**Figure 33**). Obstructive airway disease can result in air trapping. This results in a hyperlucent pulmonary appearance because the lesion(s) will act as a one-way valve allowing inspiration but preventing complete expiration. An obstructive lesion, however, can have the opposite effect whereby total obstruction results in complete air resorption and resultant atelectasis.

A common cause of hyperinflation secondary to bronchoconstriction is feline asthma or bronchiolitis and mucus plugs secondary to allergic lung disease. Affected animals may have a barrel chested appearance and the diaphragm is pushed caudally and flattened. In cats, as the degree of hyperinflation worsens, the curvilinear soft tissue attachments of the diaphragm to the ribs will become apparent on the VD/DV radiograph. This radiographic change is called diaphragmatic tenting, (**Figure 34**). Only one lung may appear to be affected if compensatory hyperinflation of another lung has occurred or if occlusion involves only one bronchus. Focal hyperlucency may be the result of lobar emphysema, a large bullous lesion or pulmonary thromboembolism. Look for changes in the heart, pulmonary and great vessels size and overall thoracic size and shape that can help to differentiate these various etiologies. Another differential etiology for generalized hyperlucency would include congenital or acquired emphysematous changes. In the case of lobar hyperlucency, there are several differentials to consider. Congenital emphysema is usually a lobar condition. Regional oligemia (decreased perfusion) can be seen with pulmonary thrombo-embolism. Other causes of focal

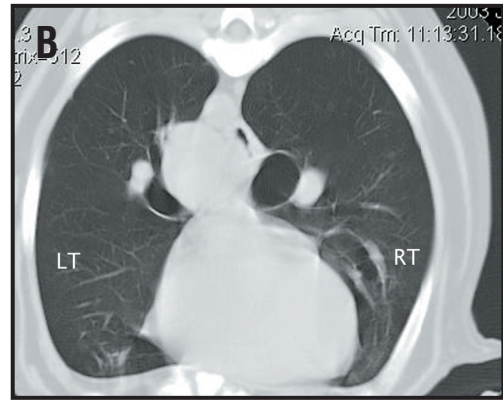
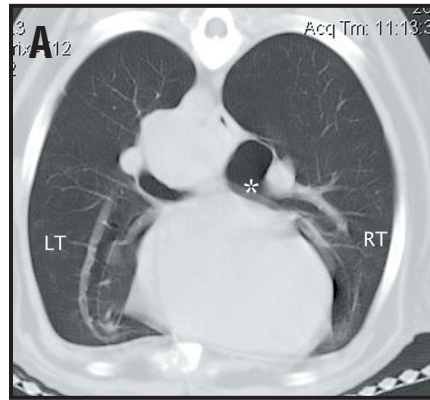
**Figure 29.** (A). Close-up right lateral radiograph from a large breed dog. The origin of the right cranial lung lobe bronchus is seen as a circular lucency superimposed over the trachea. The right cranial bronchus then takes a 90° turn cranial and ventral into the right cranial lobe (white arrow in the middle of the bronchus origin). If you trace the ventral floor of the trachea just caudal to the origin of the right cranial lung lobe, there is a radiolucent tube that points in a ventral direction and bifurcates into the cranial and caudal subsegmental bronchi of the left cranial lung lobe bronchus (black arrow). The right middle (RtMid) and right accessory (Acc) bronchi are labeled. The carina (\*) is the terminal portion of the trachea where the trachea bifurcates into the left and right caudal lobar bronchi. (B). Close-up of a left lateral radiograph from the same dog as in (A). The left cranial (cranial sub-segment) bronchus (Lcr) is dorsal to the right cranial bronchus (Rcr). The difference in size between the right and left cranial bronchi and vessels is because of geometric magnification of the right-sided structures being farther away from the x-ray film and cassette. The right middle bronchus (Rmid, double arrow) is also labeled. An end-on pulmonary vein (right cranial lobe) is highlighted by the white arrow cranial to the heart. Notice that the end on vessel is superimposed over the parent vessel and is very radiopaque relative to the larger linear parent vessel. (C). Right lateral radiograph from a dog that aspirated a large amount of barium sulfate. There is barium sulfate that outlines the right cranial (Rcr), right middle (Rmid), right caudal (Rca) and right accessory (Acc) lobe bronchi.



pulmonary hyperlucency would include: pulmonary cavitated lesions (granulomas, paragonimus granulomas, abscess or tumor), congenital lobar emphysema, pneumatocele or hemothocele, or a pulmonary bulla/bleb, (**Figure 34**).

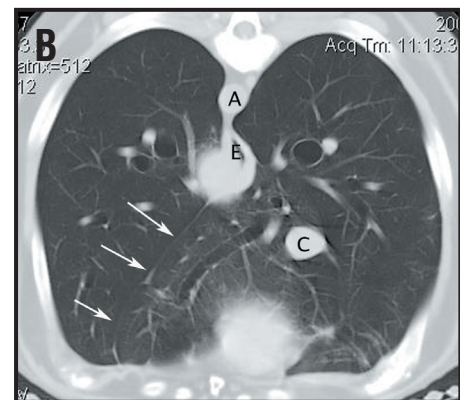
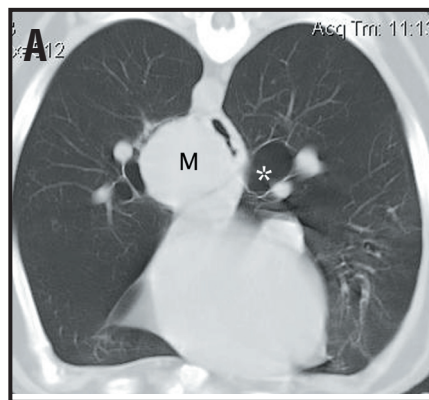
If the lung is too gray or white it may indicate the presence of pathology. Any increase in overall thoracic opacity must be localized to the extrathoracic structures, pleural space, pulmonary parenchyma, mediastinum or a combination of these potential spaces but the increased thoracic opacity may also be an artifact. The artifactual causes of increased generalized soft tissue opacity would include underexposure, underdeveloped, radiographs are taken at end-expiration or an obese dog or cat, (**Figure 35**). A focal or lobar increase in soft tissue pulmonary opacity may be the result of lung lobe collapse due to prolonged recumbency, anesthesia or focal disease process.

**Figure 30.** (A). Transverse computed tomographic section of the thorax study of a dog with a mass in the region of the pulmonary hilum. This section was obtained at the level of T6-7, just caudal to carina. The right middle lung lobe bronchus is seen as a ventral branch



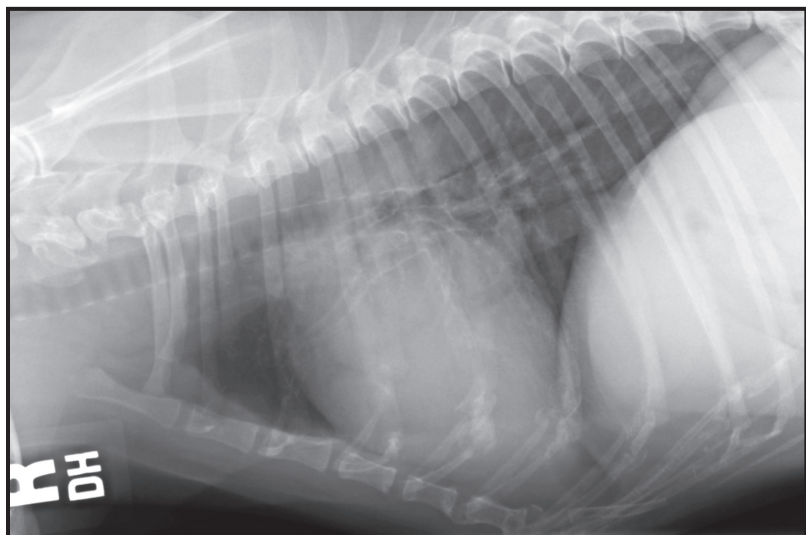
off of the right caudal mainstem bronchus just caudal to the carina. There is also a mass that compresses the left mainstem bronchus. The left cranial lobar bronchus (seen lateral to the heart) is noted to course into the ventral thorax. The branch of the right middle bronchus is seen originating at the ventral aspect of the right caudal lobar bronchus (\*). (B). Sequential caudal computed tomographic slice from (A). The right middle lobe bronchus is noted well into the periphery of the right middle lung lobe, (RT = right; LT = left).

**Figure 31.** Transverse computed tomographic section from the same dog as in Figure 30. (A). Cranial slice at the level just caudal to the heart (caudal to the slices in Figure 30) where the ventral and medial origin of the right accessory lung lobe bronchus is seen (\*). A caudal mediastinal paraesophageal mass is noted (M).



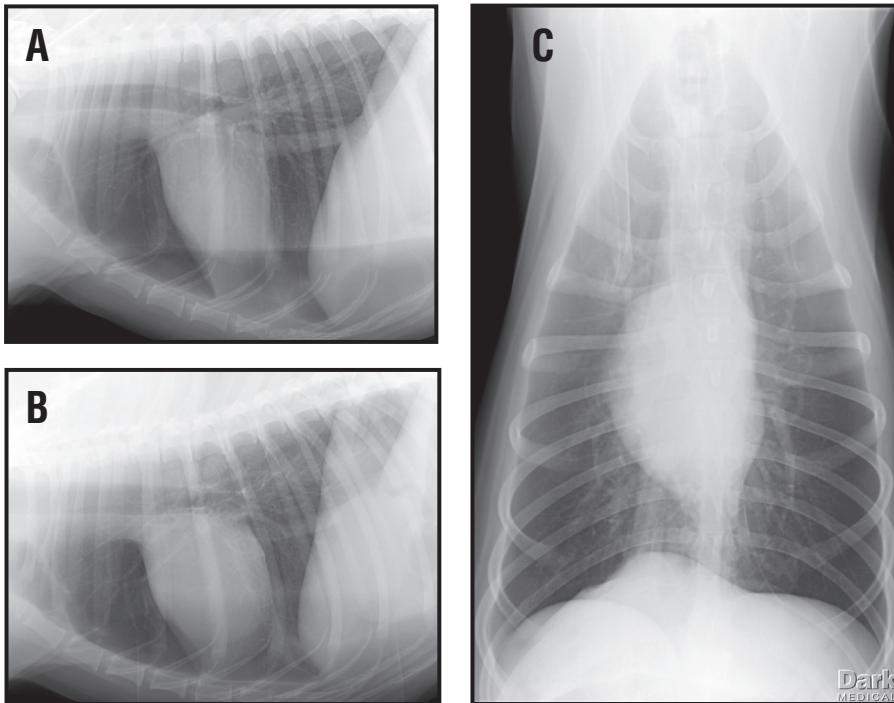
(B). The left lateral extent of the right accessory lung lobe can be seen at the ventral mediastinal reflection. The aorta (A), esophagus (E) and caudal vena cava (C) are visualized. The plica vena cava is the mediastinal reflection that surrounds the caudal vena cava within the accessory lung lobe. The left ventral mediastinal reflection is outlined by two white arrows.

**Figure 32.** Close up right lateral radiograph from a 14-year old dog. There are fine linear mineral opacities noted within the central airways and mineralization of the tracheal rings. These findings are seen in geriatric dogs, chondrodystrophic breeds and dogs with hyperadrenocorticism.



**Table 2: Anatomic position of the left and right lung lobes based on radiographic views.**

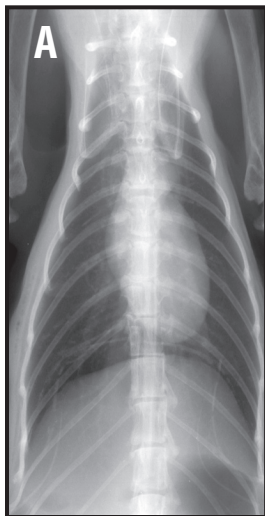
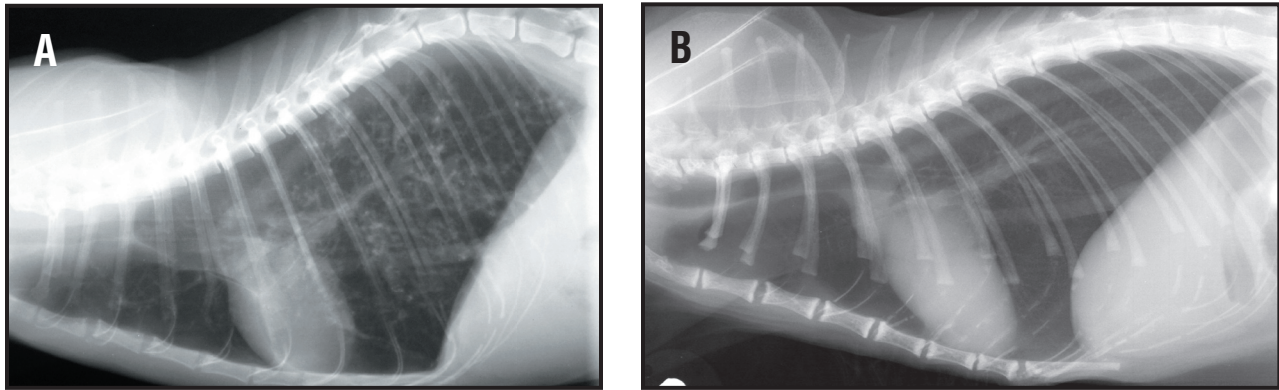
Radiographic View	Lobe Fissure	Anatomic Position
Right Lateral	Left cranial and caudal lung lobe – ventral fissure	7th intercostal space along the caudal border of the cardiac silhouette
Right Lateral	Left cranial and caudal lung lobe – dorsal fissure	6th rib over the heart base region
Left Lateral	Right cranial and Right middle	4th intercostal space
Left Lateral	Right middle and Right Caudal	7th intercostal space along the caudal border of the cardiac silhouette (can be seen as a thin line of fibrosis in geriatric dogs).
VD or DV	Right cranial and Right middle	4th intercostal space
VD or DV	Left cranial and Left caudal	7th intercostal space
VD or DV	Left cranial subsegment and Left caudal subsegment of the Left cranial lung lobe	7th intercostal space
VD or DV	Left caudal and Right accessory	4th intercostal space
VD or DV	Left caudal and Right accessory	4th intercostal space



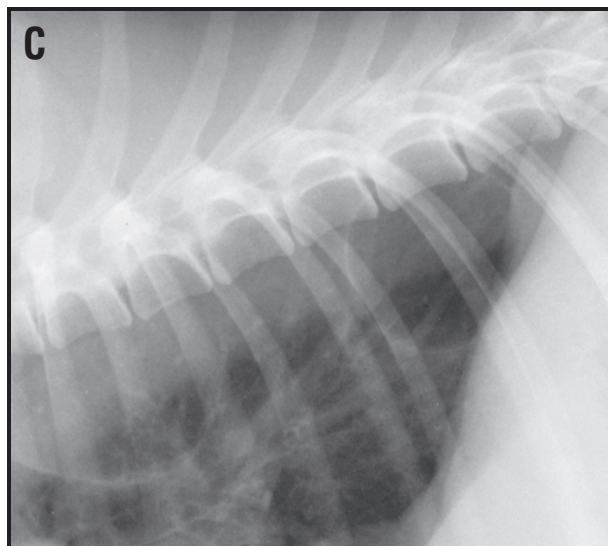
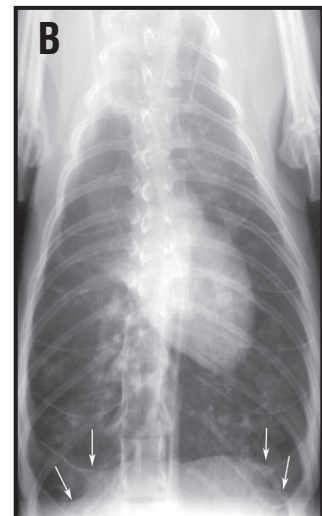
**Figure 33.** Right lateral (A), left lateral (B) and ventrodorsal (C) radiograph from a dog with Addison's disease. The systemic vascular volume depletion has resulted in a small cardiac silhouette (microcardia), small pulmonary vessels (creating an hyperlucent lung field) and a small caudal vena cava.

Having determined that the lung truly has an increased opacity (versus being secondary to the extrathoracic, pleural or mediastinal structures), the next step is to decide which type of pattern or patterns is present. Identifying a specific pulmonary pattern is a process of elimination as some have readily identifiable features that allow one to confirm or exclude their presence. This process has been made more complicated over time thereby increasing the degree of frustration for the practitioner and veterinary student. We have tried to simplify things and the essentials of a pulmonary location/pattern paradigm will be presented below.

**Lung Patterns: the nuts and bolts of pulmonary radiographic interpretation!**

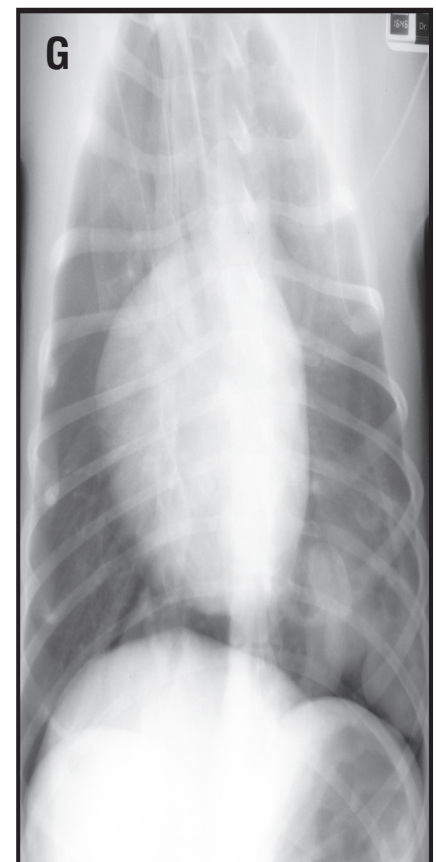
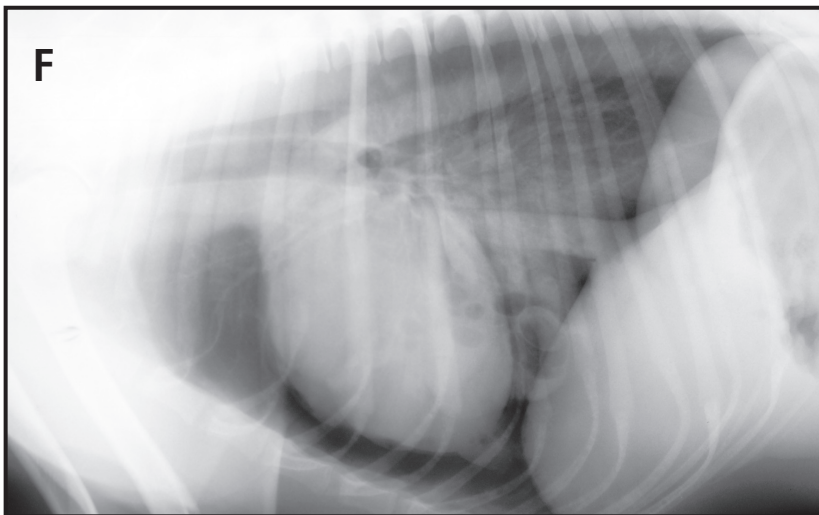
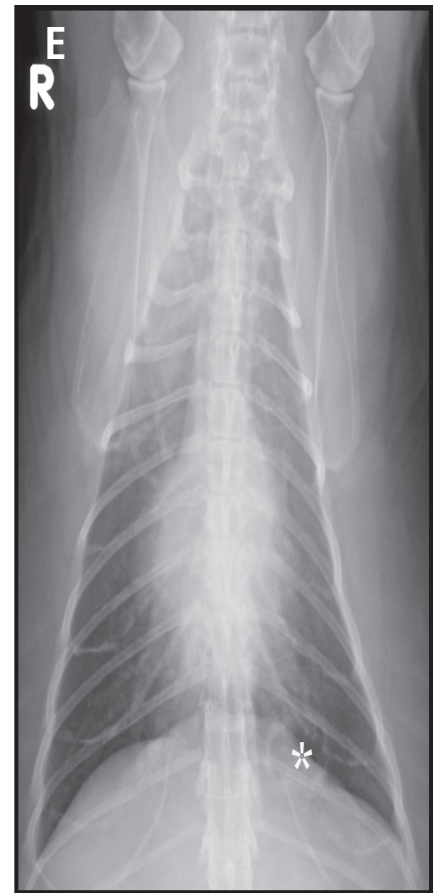
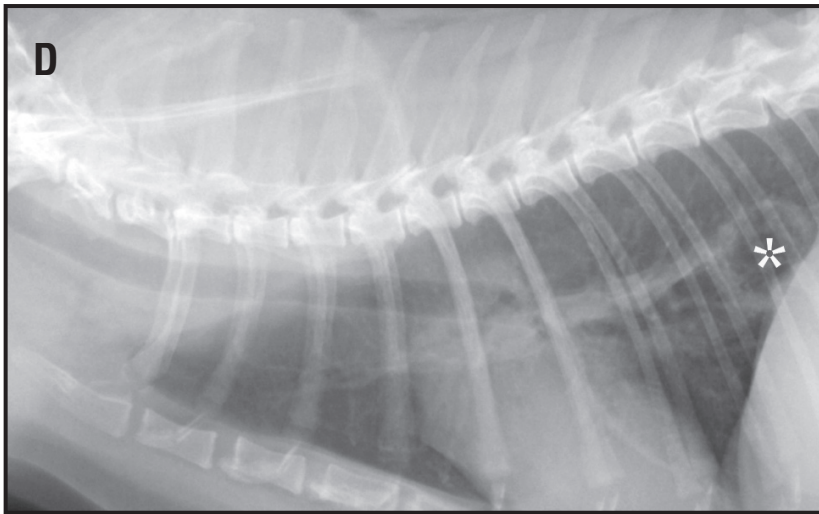


**Figure 34.** Generalized hyperinflation. Right lateral (A) and ventrodorsal (B) radiographs from a cat with hyperinflation secondary to feline allergic lung disease and asthma. On the VD radiograph there are scalloped margins noted to the cranial and lateral borders of the diaphragm consistent with “diaphragmatic tenting” (white arrows). Focal pulmonary lucency. Close-up, right lateral (C) radiograph from a dog. A focal circular lucency is seen just ventral to the descending aorta within the caudodorsal lung field consistent with a pulmonary bulla.

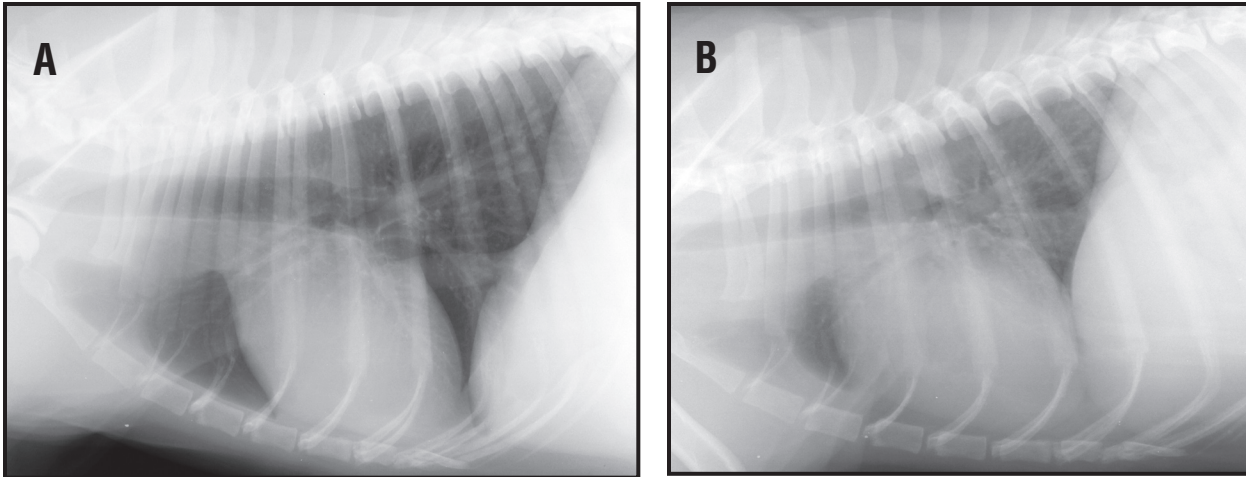


## Thoracic Radiology

**Figure 34 CONTINUED.** Generalized hyperinflation. Right lateral (D) and ventrodorsal (E) radiographs from a 12 year-old cat. An irregularly marginated cavitory pulmonary nodule is present in the left caudal lung lobe (\*). The two primary differentials for a lesion like this would include a primary lung tumor with a necrotic center (liquid has drained via an invaded bronchus) or an abscess with gas-producing bacteria. A lobectomy was done and the histologic diagnosis was a bronchogenic carcinoma. Right lateral (F) and ventrodorsal (G) radiographs from a dog after being hit by a car. There is dorsal elevation of the cardiac silhouette consistent with a pneumothorax. In addition multiple gas filled, thick walled bullae are present. These are consistent with traumatic hematoceles (focal bulla with hemorrhage). A horizontal beam lateral radiograph would document a gas-fluid line within each hematocele.







**Figure 35.** Right lateral radiographs from a dog demonstrating the difference in overall lung opacity between radiographs made at peak inspiration (A) and peak expiration (B).

One of the most confusing areas of thoracic radiology is how to determine the presence of pulmonary pathology and correctly describe the pulmonary pattern present. Aside from calling the cardiac silhouette large or small, the area of interpreting pulmonary patterns can appear to be the most subjective. However, the goal is to again take a systematic approach to interpreting the pulmonary abnormalities. An initial set of questions should be asked of the radiographs that WILL have an impact on your interpretation of the lung parenchyma. The answers to these questions will result in you being able to accurately interpret the thoracic radiographs.

*Are the radiographs correctly exposed? Underexposed radiographs will create increased lung opacity. Overexposed radiographs will give one the false impression of a pneumothorax or absence of lung disease, when interstitial lung disease is in fact present. If the radiographs are extremely overexposed, the pulmonary vessels can be totally obscured, even when using a hot light for evaluation.*

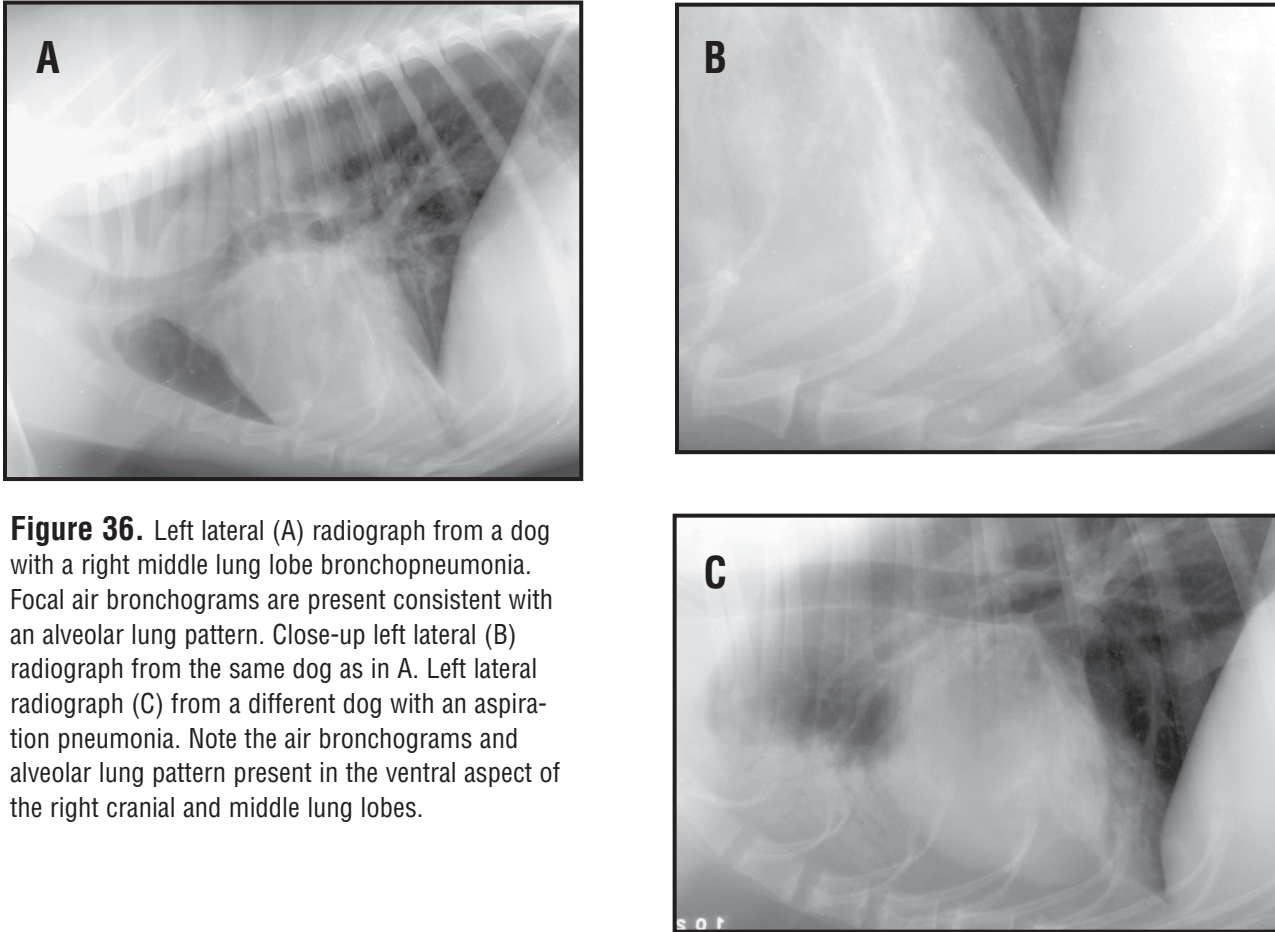
*Is the patient overtly obese? Obesity will also increase the overall lung opacity, again in a generalized fashion. This will result in an over increase hazy soft tissue opacity that is apparent as an unstructured interstitial pulmonary pattern.*

*Is the patient correctly positioned? Marked obliquity will not only render the cardiac silhouette un-interpretable, but will also greatly impact the ability to discern subtle changes in pulmonary opacity.*

*Was the radiograph made on peak inspiration? Radiographs that were made on expiration will result in an increase in overall lung opacity and inability to delineate normal vessels and airways, particularly in the caudodorsal lung field. Overinflation will result in a generalized hyperlucent appearance to the lung fields.*

Once these questions have been answered and any radiographs repeated due to quality control issues, one can then proceed to the evaluation and interpretation of both the lateral and VD radiographs. Increased soft tissue opacity (generalized or focal) to the lung field can be a result of abnormalities within other thoracic compartments (pleural space or mediastinum). Combinations of compartmental pathology (i.e. pulmonary disease and pleural fluid) can make things confusing, but again remember the primary rule for thoracic radiographic interpretation is NOT TO PANIC!!

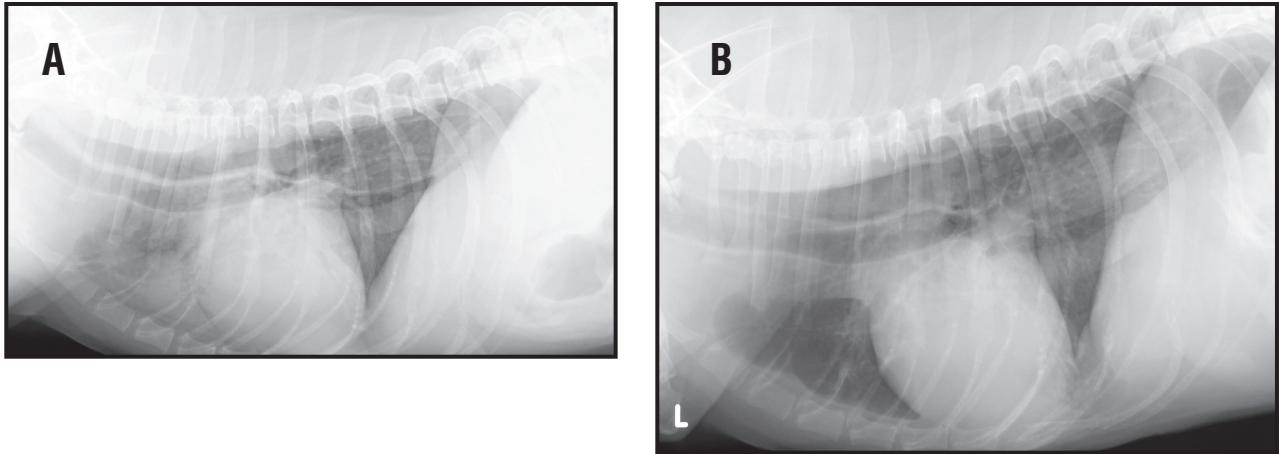
There are four basic things that one needs to know regarding your description of the changes seen within the lung fields. Recognize that if there are multiple lesions or patterns, each must be reviewed systematically. First, WHERE is the pathology located? Not only should you describe specific lung lobes, but also the specific region within the lung lobe that is involved (entire lobe, hilar, mid-zone or peripheral). Now the second aspect of WHERE is really a continuation of the first in that you should ask yourself is the lesion, focal, multi-focal or generalized. This seems like a repeat of the first step as to the specific lung lobe and zone of the lobe, but in reality, it will help you in determining the extent of the disease in a single word! For example, in **Figure 36** there is a focal abnormality. Based on the WHERE question, the answer would be focal, lobar, right middle lung lobe increased soft tissue opacity. This last part of the description is included only because our interpretation paradigm is incomplete. If on the VD/DV radiograph there is a specific focal area of pulmonary pathology present in the down lung lobe on the lateral radiograph (right lung lesion and right lateral radiograph was made), the opposite lateral radiograph should be made, (**Figure 1 and 37**). Again, the reason is that the down lung will have a dramatic decrease in the amount of air present to the point that the lesion will border efface with lung atelectasis from the normal under-inflated down lung. Second, the SEVERITY of the pulmonary abnormality should be described as mild, moderate or severe. This may seem like the most subjective part of the descriptive process, but it helps you know where you stand in being confident that there is truly disease present. If we were to describe to you a mild, generalized increase in interstitial lung opacity, then you should start thinking about artifactual causes of interstitial lung disease (underexposure, underdevelopment, expiration, etc.). However if we were to describe to a severe focal soft tissue alveolar pattern of the entire right middle lung lobe, then the description puts us in the ballpark for common differential diagnoses. Not only that, we would know that because we think it is severe, the lesion is NOT artifact. Third, the POSITION of the cardiac silhouette relative to normal should be determined. If there is an ipsilateral mediastinal shift, then there is volume loss associated with a lobar lesion. If there is a contralateral mediastinal shift, there is displacement due to a mass, “swollen” lung lobe or hyperinflated lung lobe. The two terms that might be used here would include atelectasis and consolidation. In atelectasis, there is increased opacity associated with a specific lung lobe, and there is loss of normal air volume associated with that lung lobe. The cardiac silhouette will then shift toward (ipsilateral shift) the “collapsed” or partially atelectatic lung lobe, (**Figure 37**). Remember that it becomes critical that you have a straight VD or DV radiograph (sternbrae superimposed over vertebrae) in order to document a true mediastinal shift. In the case of consolidation, the lung lobe maintains its shape (margins), the alveoli are replaced by cells and/or fluid, (exudates, neoplastic infiltrate or hemorrhage). BUT there is no volume loss to the lung lobe, the mediastinal structures a normal position within the thorax. Fourth and final, one needs to describe the pulmonary PATTERN of abnormality. Now, the hardest thing for you is going to be to break the habit of immediately jumping to the pulmonary pattern and taking the time to go through the first three steps prior to trying to sort out the pulmonary pattern. Remember with each of the patterns we are describing there will be an increase in soft tissue opacity within the pulmonary parenchyma – no matter which one it is AND more than likely there will be a mixture of patterns, which means that you will need to determine which pattern predominates. In summary, repeat the lung interpretation paradigm – W, S, P2 which related to WHERE, SEVERITY, POSITION and PATTERN.



**Figure 36.** Left lateral (A) radiograph from a dog with a right middle lung lobe bronchopneumonia. Focal air bronchograms are present consistent with an alveolar lung pattern. Close-up left lateral (B) radiograph from the same dog as in A. Left lateral radiograph (C) from a different dog with an aspiration pneumonia. Note the air bronchograms and alveolar lung pattern present in the ventral aspect of the right cranial and middle lung lobes.

## Pulmonary Pattern Recognition

The easiest approach to lung patterns is to be able to recognize the specific roentgen abnormalities associated with a given pulmonary pattern. Since this is the hardest part to the above described interpretation paradigm, these patterns and the specific radiographic abnormalities will be described in detail. Therefore, one needs to know what constitutes an alveolar pattern, what constitutes a bronchial pattern, what constitutes a vascular pattern, what constitutes a definitive structure a nodular pattern and finally, BY DEFAULT, what constitutes an unstructured interstitial pulmonary pattern. Now the list you just read is the exact list and approach to our finding out what type of lung pattern is present. Initially, the emphasis was placed on the pulmonary pattern, because it was felt that the pattern was in fact specific to the disease process (i.e. – hemorrhage equates to alveolar disease, inflammation secondary to hematogenous pneumonia equates with interstitial lung disease). We now know that this is not true (and actually have known it for a long time – old things die hard!!). In fact there can be a progression of a given disease through all of the pulmonary patterns culminating in the alveolar pattern and as the patient is treated (appropriately), then the alveolar disease will become interstitial disease that will then go away all together when the lung tissue returns to



**Figure 37.** (A). Left lateral radiograph from a dog with megaesophagus and right middle lung lobe pneumonia. (B). Follow-up left lateral radiograph taken 14 days after initiation of appropriate antibiotic therapy. There is resolution of the ventral alveolar lung opacity consistent with resolution of the pneumonia. The megaesophagus persists.

**RADIOLOGY TIP: Pulmonary Pattern Interpretation Paradigm**

Remember the Pulmonary Pattern Interpretation Paradigm (Figure 38), single phase generators) of a second “picture” of the disease process, (Figure 38). The most under utilized test for evaluating the response to therapy is the thoracic radiograph. The disease process is a dynamic one and dramatic changes can occur within hours of the previous thoracic radiographic examination. Re-evaluation using thoracic radiographs is critical for complete patient care.

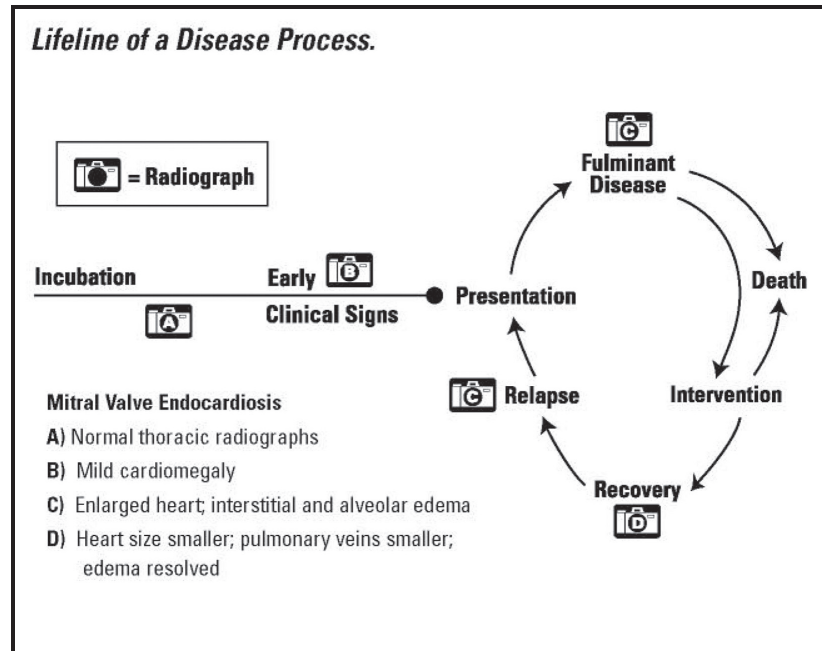
**Alveolar pattern – the easiest pattern to recognize.**

**Alveolar pattern** – Alveolar, bronchial, structures interstitial, vascular or unstructured interstitial. due to lung lobe collapse in the case of atelectasis. The alveolar pattern has a number of specific radiographic abnormalities that will make diagnosis easier. The three classic roentgen abnormalities associated with the alveolar pulmonary pattern include: presence of air bronchograms, presence of border effacement and the lobar sign. Typically an alveolar pattern is going to be focal or multi-focal, but rarely generalized (unless just prior to death!). One can think in terms of severity that the alveolar pattern is the worst and most severe. This is because there is complete obliteration of the air space, thereby allowing no air exchange. The more you replace the air space, the more likely the dog or cat does NOT have any gaseous exchange which ultimately becomes incompatible with life.

The air bronchogram is the gold standard roentgen abnormality for the diagnosis of an alveolar lung pattern. Unfortunately, the air bronchogram is not always present in alveolar lung disease. The air bronchogram represents the air filled bronchus seen against the lung parenchyma that contains no air and is homogenous soft tissue opacity (Figure 39). The air bronchogram appears as branching dark gray tubular structures that are larger in the hilar and mid-zone position and branch into smaller bronchi in the periphery, against the uniform soft tissue opacity of the diseased lung tissue. The air bronchogram requires a lack of visualization of the pulmonary vessels within that specific lung lobe AND the lack of visualization of the bronchial walls.

The silhouette sign is perhaps better described as border effacement or border obliteration. If two objects of the same radiographic opacity are in contact with each other, the edges in contact cannot be separated so the two structures appear as one. In the case of an alveolar pattern, if the portion of affected lung contacts the heart or diaphragm the margin of these structures is obliterated and

**Figure 38.** Representative drawing of various stages of potential thoracic radiographic changes from a dog with mitral valve endocardiosis. At any point in time, the thoracic radiographs can change dramatically if the disease process is also undergoing rapid changes (i.e., progressive pulmonary edema).



the affected lung lobe appears contiguous with the heart or diaphragm. Border effacement can only occur if both objects are the same opacity and both objects are in contact with each other, (**Figure 40**). This can only occur with lung pathology when either an alveolar pattern or a soft tissue pulmonary mass is present.

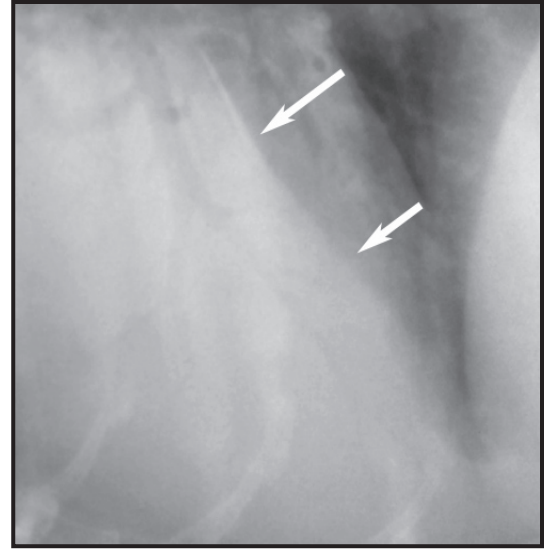
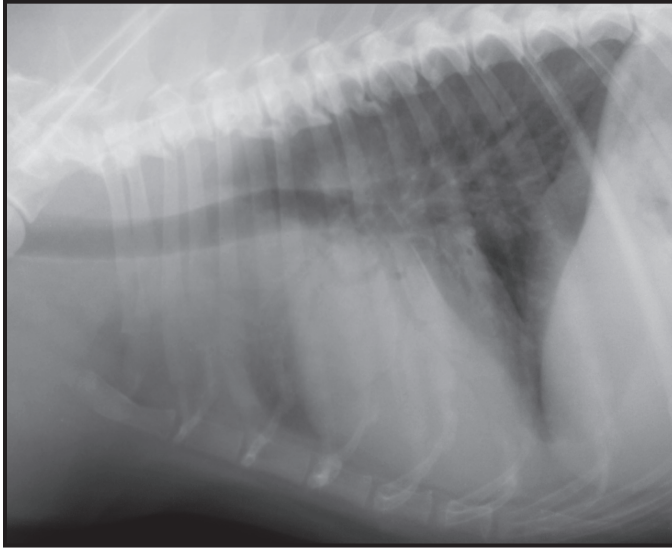
The lobar sign is a line that is created between an abnormal lobe adjacent to a normal lobe at an expected lobar fissure or lung lobe division, (**Figure 41**). A lobar sign is also indicative of an alveolar pattern.

Although air bronchograms are the hallmark feature, an alveolar pattern may still be present, but uniform increased opacity of an alveolar pattern results in the complete disappearance of the pulmonary vessels in the affected lung. In effect this is another manifestation of the silhouette sign. So if you can see vessels it's not alveolar! A common error by novices is to interpret large vessels on either side of a bronchus as it extends away from the hilus as an air bronchograms.

## Bronchial pattern – “Rings and Lines”

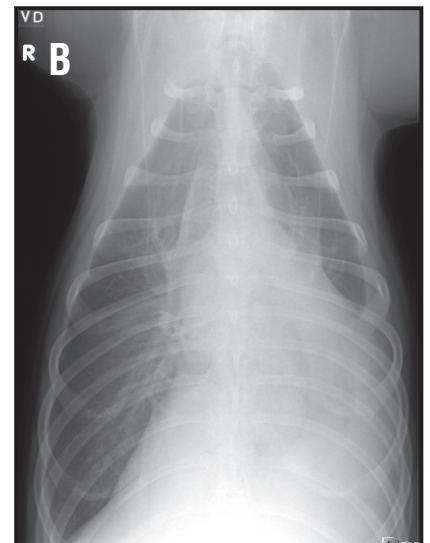
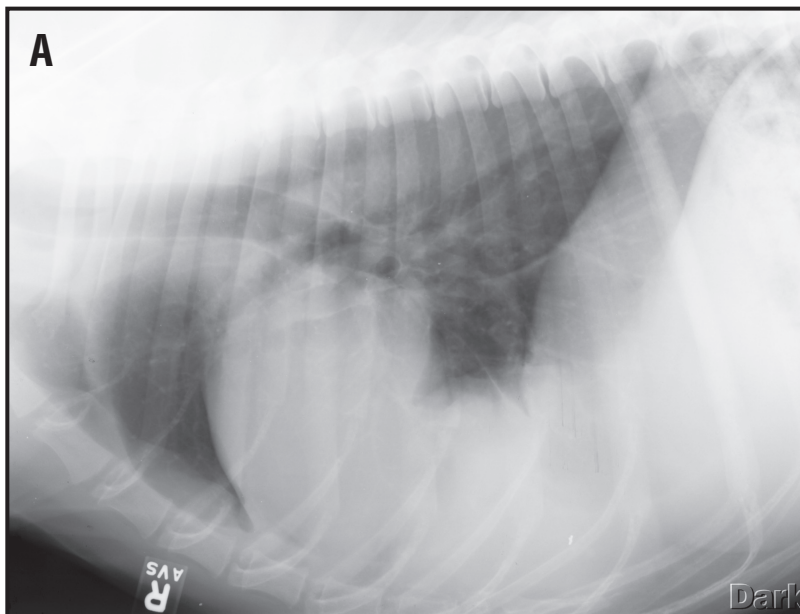
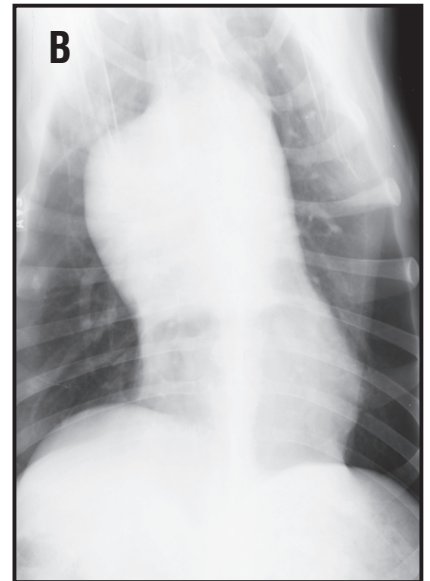
In the normal canine lung, only 1st, 2nd and possibly the 3rd generation bronchi are visible. Thickening of the bronchial walls are described as lines, tramlines or railroad tracks (the bronchus as seen on its length) or rings (**end on bronchi, Figure 42**). Remember it is normal to see the larger bronchi in the hilar region of the lung but they are abnormal if the walls are thickened, which requires some experience to assess. Wall thickening has been reported as the most useful sign of bronchial disease. One should not see small bronchi especially in the mid and peripheral pulmonary zones. Do not confuse central bronchial thickening with bronchial mineralization, a normal aging change. Mineralized bronchial walls are very thin, white and very well defined. Bronchial mineralization is usually accompanied by mineralization of the tracheal rings.

**Interstitial pattern – what is left over after ruling out the rest (see caveat below).**



**Figure 39.** Close-up right lateral radiograph of a dog with aspiration pneumonia. There are multiple radiolucent branching tree-like projections noted in the soft tissue opacity of the lung lobe. The bronchus wall, pulmonary artery or vein cannot be visualized due to the border effacement with the pulmonary pathology. In addition the caudal border of the left cranial lung lobe is demarcated from the adjacent cranial border of the left caudal lung lobe because of the disease present in the left cranial lung lobe. This is called a lobar sign and is characteristic of alveolar lung disease.

**Figure 40.** Right lateral (A) and ventrodorsal (B) radiographs from a dog with an accessory lung lobe mass. There is border effacement of the ventral caudal aspect of the cardiac silhouette and the cranioventral aspect of the diaphragm consistent with a soft tissue mass in the accessory lung lobe causing lack of visualization of normal cardiac and diaphragmatic borders.



Interstitial patterns come in two varieties, nodular and unstructured. Soft tissue nodules that vary in size from 2 to 3 mm to 2 to 3 cm characterize a nodular interstitial pulmonary pattern. When the nodules are larger than 3 cm, they are called masses, **(Figure 43)**. Multiple very small nodules (2 to 3mm range), is called a miliary pattern because of the resemblance to millet seeds. Others have characterized a severe miliary pulmonary pattern as snowstorm effect **(Figure 44)**. In such cases it can be difficult to discern the millet pulmonary nodular pattern. Examination of a relatively thin piece of lung, such as the area overlying the ventral third of the heart or liver, is helpful to identify the actual small millet nodules.

An unstructured interstitial pattern is present if the lung appears too light and we can't call it anything else. This pattern is seen as a poorly defined, hazy increase in opacity, often called a "cotton candy effect" **(Figure 45)**. It alters the appearance of the lung by making small and medium sized vascular structures more difficult to see. This is the test used to decide if a suspected unstructured interstitial pattern is real or not. Large vessels should be visible, although they may be difficult to discern clearly if the pattern is severe while medium and small pulmonary vessels are obscured to a degree that depends on the severity of the pattern. If one can see small peripheral pulmonary vessels then the suspected pattern is a phantom or the result of overzealous imagination. The bronchi may also appear more prominent against a gray lung, although not to the extent of an air bronchogram. If the lung is too gray but some vessels are still visible it is an unstructured interstitial rather than alveolar pattern.

## **Vascular Pattern – The Caveat of Pulmonary Patterns.**

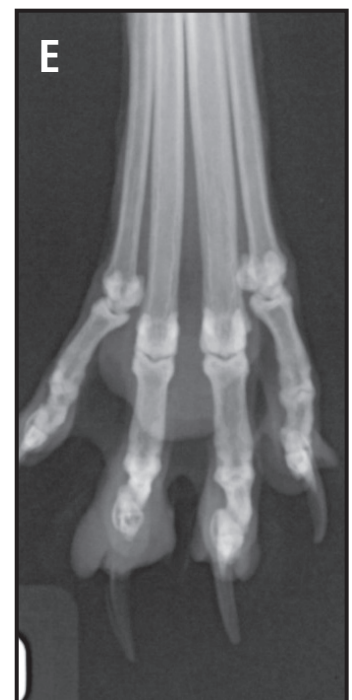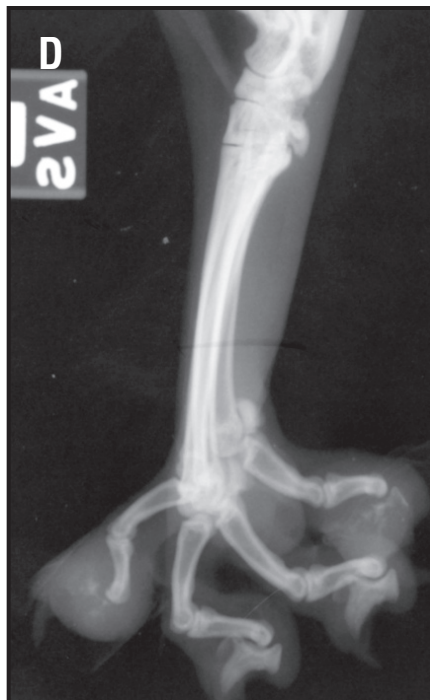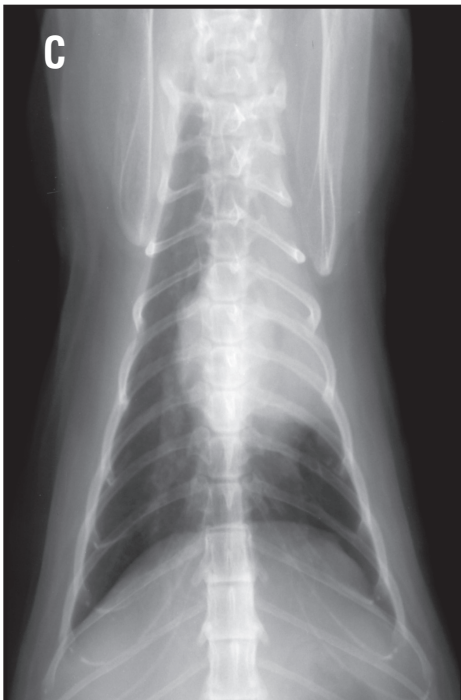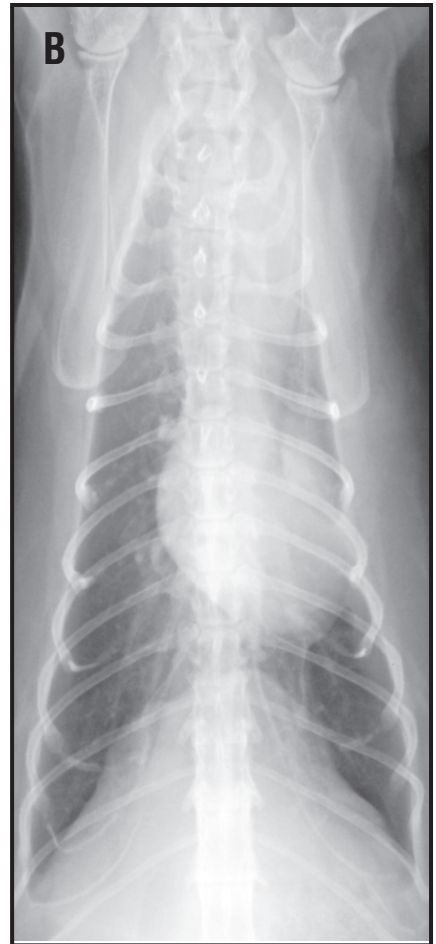
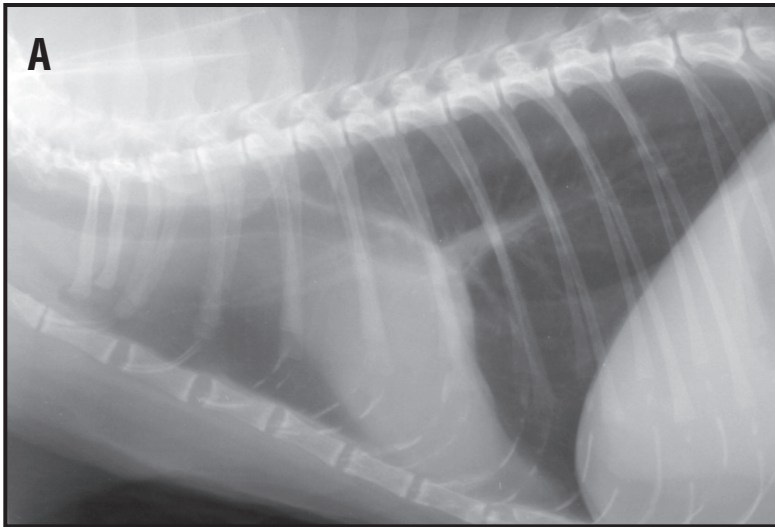
A final pattern that has been classified by some as a pulmonary pattern is called a vascular pattern. It is only because of normal aeration of the lung lobes, that the normal pulmonary artery and vein can be visualized. On the lateral radiograph, the cranial lobar artery is dorsal to the bronchus that in turn is dorsal to the pulmonary vein, **(Figure 46)**. The triad of pulmonary artery, lobar bronchus and pulmonary vein extends from the hilar region into the appropriate lung lobe. The pulmonary triad will progressively get smaller and divide into secondary and tertiary branches in the mid zone and periphery of each lung lobe. On the right lateral radiograph, the right and left cranial pulmonary triad will cross over each other close to their origin from the heart base region and diverge away from each other as they extend into the periphery. On the left lateral radiograph, the pulmonary triad of the left and right cranial lung lobe will parallel each other with the right cranial pulmonary triad being ventral to the left and slightly larger than the left due to magnification. On the right lateral radiograph, the pulmonary triad of the caudal sub-segment of the left cranial lung lobe is seen over the cardiac silhouette, whereas the right middle pulmonary triad will be seen over the cardiac silhouette on the left lateral radiograph.

Alterations in the size of the pulmonary veins and arteries result in increased or decreased overall lung opacity. A hyperlucent lung can be a result of a small pulmonary vessels or absence of a normal vascular pattern within the lung fields, (oligemia). Differentials for a hyperlucent lung field include hypovolemia (small pulmonary vessels), thromboembolic disease, pulmonic stenosis or right to left shunts.

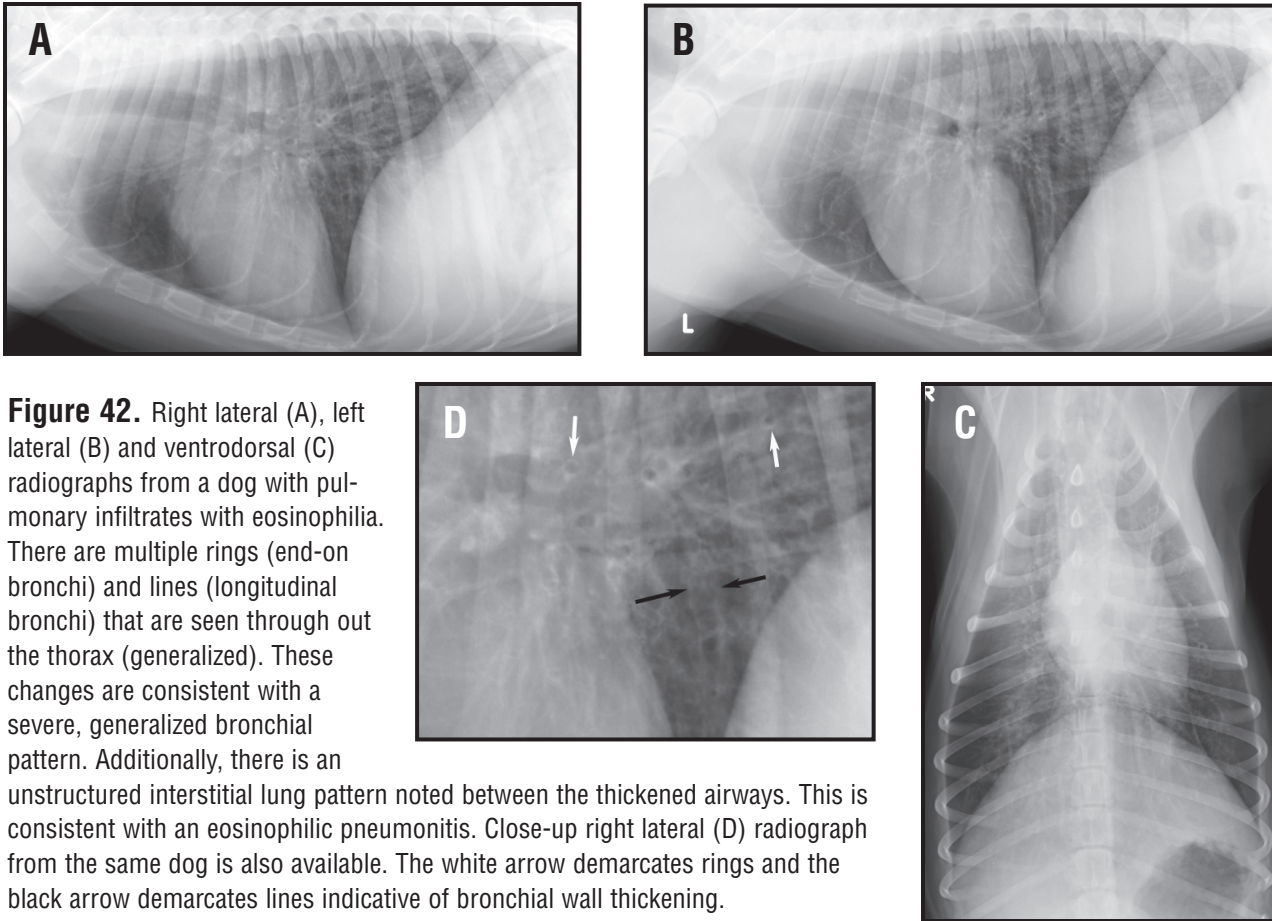
Enlargement of the pulmonary artery, vein or both will cause an overall increase in pulmonary opacity. If the dog has severe pulmonary artery disease secondary to heartworm disease, the pulmonary

## Thoracic Radiology

**Figure 41.** Right lateral (A) and ventrodorsal (B) radiographs from a 12 year-old cat that presented with swelling of multiple digits. There is a left cranial lung lobe mass that has resulted in atelectasis of the left cranial lobe. There is lack of air bronchogram visualization in the left cranial lobe. Ventrodorsal radiograph from a 10-year old cat (C). There is border effacement of the lobar mass and the left, cranial aspect of the cardiac silhouette with a cranial and leftward ipsilateral mediastinal shift. Mediolateral radiograph (D) of the pes and dorsopalmar (E) radiograph of the manus from the cat in C. There are areas of osteolysis of the second and fifth distal phalanges of the pes and soft tissue swelling and osteolysis of the distal phalanx of the 4th digit. These changes are consistent with feline lung-digit syndrome. The primary tumor was a bronchogenic carcinoma and the focal areas of digital osteolysis are metastatic lesions from the carcinoma.





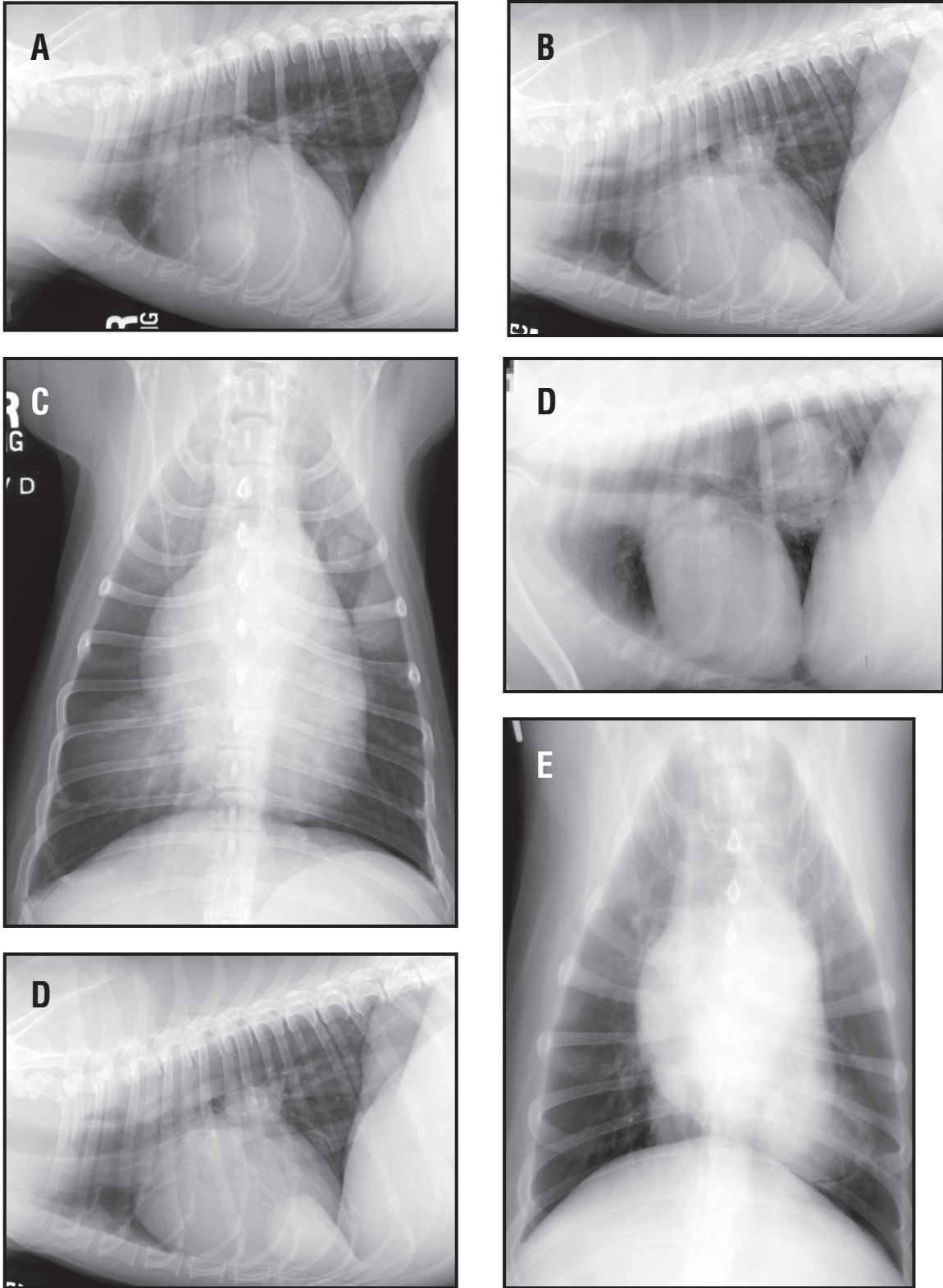


**Figure 42.** Right lateral (A), left lateral (B) and ventrodorsal (C) radiographs from a dog with pulmonary infiltrates with eosinophilia. There are multiple rings (end-on bronchi) and lines (longitudinal bronchi) that are seen through out the thorax (generalized). These changes are consistent with a severe, generalized bronchial pattern. Additionally, there is an unstructured interstitial lung pattern noted between the thickened airways. This is consistent with an eosinophilic pneumonitis. Close-up right lateral (D) radiograph from the same dog is also available. The white arrow demarcates rings and the black arrow demarcates lines indicative of bronchial wall thickening.

arteries can become “nodular” in appearance and thereby look like multiple pulmonary nodules, (Figure 47). In addition, eosinophilic granulomatosis, granulomas and lymphomatoid granulomatosis have all been reported with heartworm disease. In dogs with left to right shunts or large arteriovenous fistulas, the pulmonary arteries and veins can become symmetrically enlarged, (Figure 48). Again this will cause an overall increase to the pulmonary opacity present that is not alveolar, bronchial or interstitial.

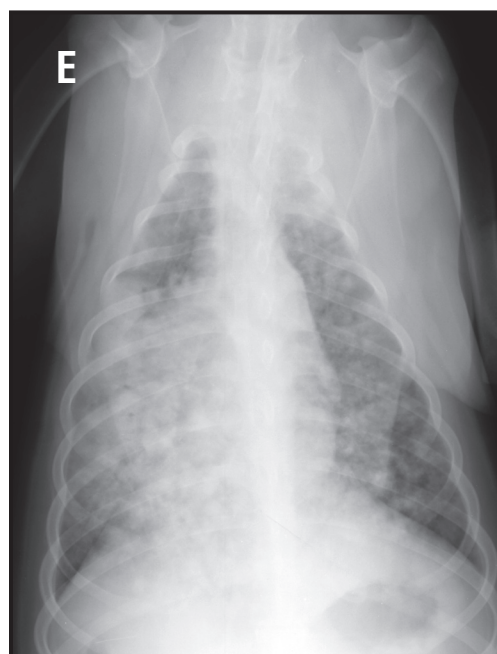
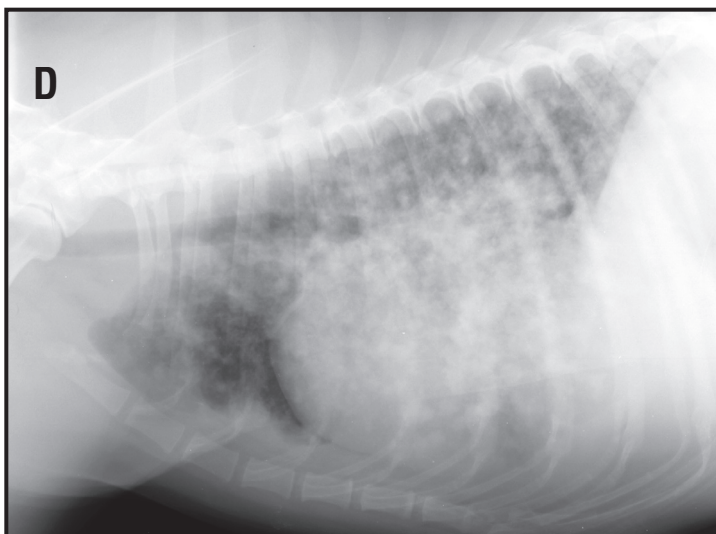
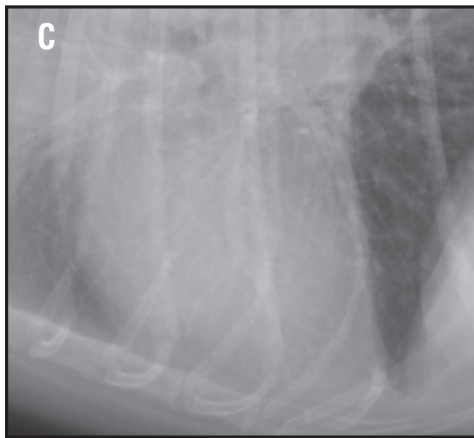
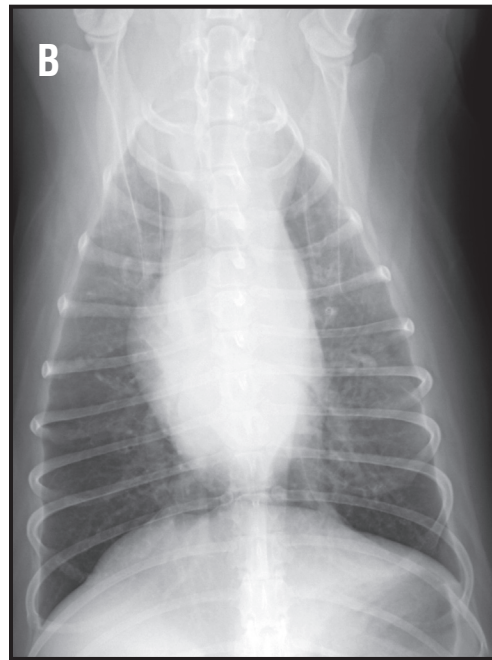
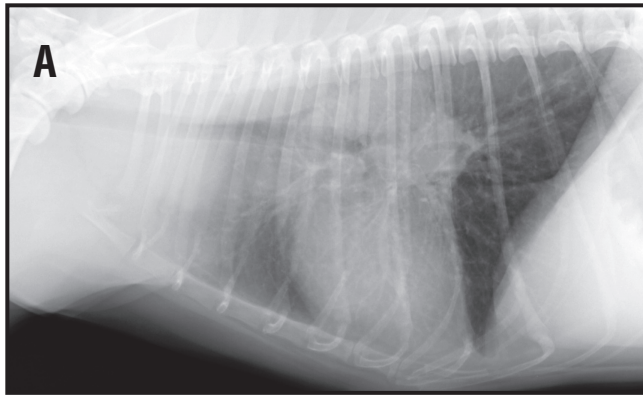
## Differential diagnosis of pulmonary patterns

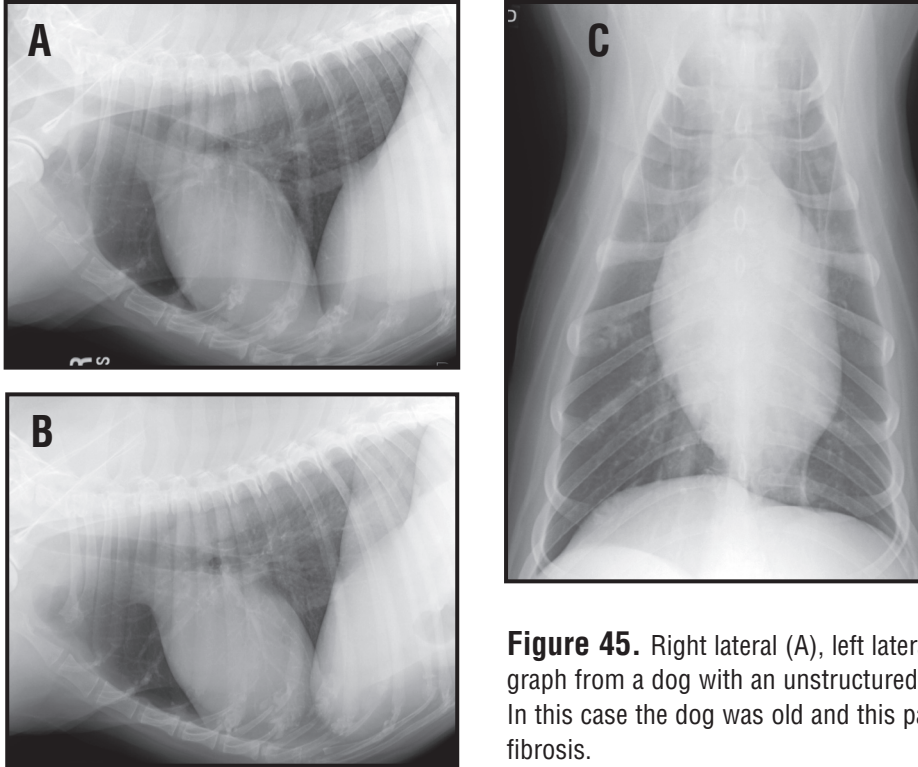
Differential diagnoses can be refined based on pattern recognition, lesion distribution and the presence of secondary lesions, (Tables 3 to 6). The differential for lung patterns is based on a clear understanding of the pathophysiology of lung disease processes. One must realize that the changes present at any given radiograph could represent minimal or early changes (incubation period of the disease process), interstitial changes that may progress to a generalized alveolar pulmonary pattern if not treated or the disease process not reversed. At the same time, if the patient is treated, then the pulmonary pattern could change radiographically from an alveolar pulmonary pattern to an interstitial pulmonary pattern and then resolves to normal. Pathology of the lung can be classified based on the etiology using the DAMNITT<sup>2</sup> approach or the site of origin of the disease process. Pathologic classifications have included: vascular diseases (hemodynamic and microvascular injury edema, Adult respiratory distress syndrome [ARDS], pulmonary arterial endarteritis [Dirofilaria immitis] pulmonary embolism and infarction and pulmonary hypertension); Obstructive and restrictive pulmonary disorders, (emphysema, asthma, chronic bronchitis, bronchiectasis); pulmonary



**Figure 43.** Right lateral (A), left lateral (B) and ventrodorsal (C) radiographs from a dog with variable sized pulmonary nodules (less than 3 cm) in the left cranial lung lobe and a mass (greater than 3 cm) in the right middle (lobar sign caudally on the left lateral) secondary to pulmonary metastatic disease from a distant carcinoma. Right lateral (D) and ventrodorsal (E) radiographs from a dog with a single large pulmonary mass (greater than 3 cm) in the left caudal lung lobe. This is consistent with a primary lung tumor. A bronchogenic carcinoma was resected at surgery.

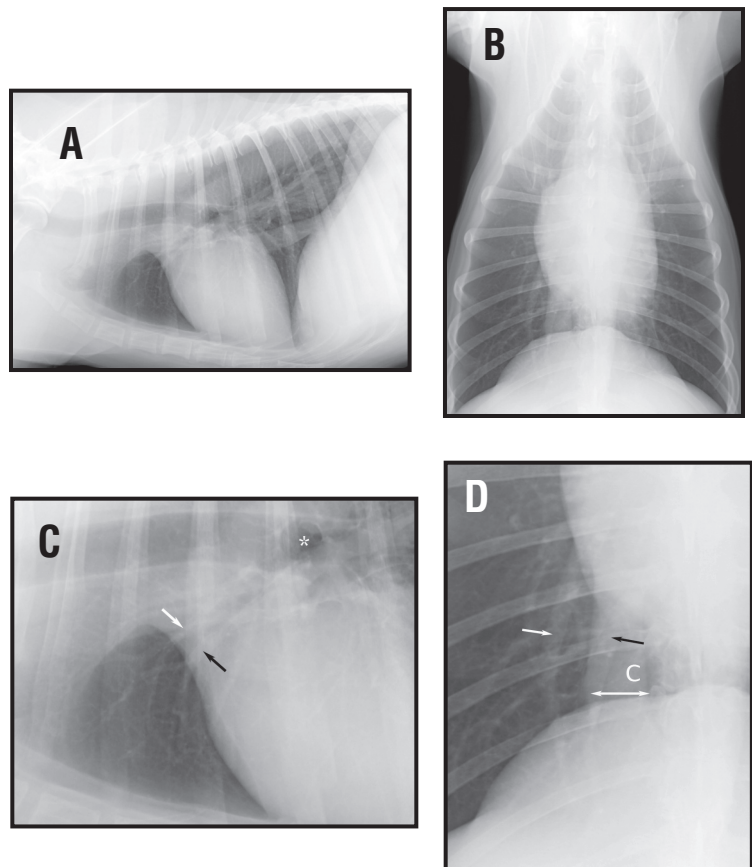
**Figure 44.** Right lateral (A) and ventrodorsal (B) radiographs from a dog with a multicentric lymphoma. There is a generalized interstitial miliary pulmonary pattern present. There is ventral displacement of the caudal lobar bronchi. There is widening of the cranial mediastinum. These changes are consistent with cranial mediastinal and tracheo-bronchial lymph node enlargement. Differential diagnosis for these thoracic radiographic abnormalities would include systemic mycotic infection. Gas is noted in the esophagus cranial to the heart base area. Close up of the right lateral radiograph (C) showing the interstitial pattern. Right lateral (D) and ventrodorsal (E) radiographs from a dog with a systemic blastomycoses. There is a generalized interstitial miliary and nodular pulmonary pattern present throughout all lung fields that is severe. On the DV a mediastinal shift is not present.





**Figure 45.** Right lateral (A), left lateral (B) and ventrodorsal (C) radiograph from a dog with an unstructured interstitial pulmonary pattern. In this case the dog was old and this pattern was attributed to geriatric fibrosis.

**Figure 46.** Right lateral (A) and ventrodorsal (B) radiographs from a dog. Close up right lateral radiograph (C) from the same dog. The pulmonary artery (white arrow) is dorsal and cranial to the bronchus and the pulmonary vein (black arrow). The origin of the right cranial lobar bronchus is marked by the \*. One cannot delineate the difference between the caudal lobar pulmonary arteries and veins caudally on the lateral radiograph. Close up ventrodorsal (D) radiograph from the same dog. The pulmonary artery (white arrow) is lateral to the bronchus and the pulmonary vein (black arrow) in the all lung fields. The white double arrow marks the lateral and medial extend of the caudal vena cava (c).



infections (bacterial and fungal pneumonia, lung granulomas/abscesses, secondary pneumonia such as aspiration or immunocompromised hosts); diffuse interstitial infiltrative diseases, (fibrosis, hypersensitivity pneumonitis, PIE), and tumors (bronchoalveolar carcinoma, metastatic tumors). The pathological basis of description of pulmonary lesions has not equated to a specific pulmonary pattern unless there are other supporting features (other radiographic abnormalities) that are present and recognized. Therefore a thorough understanding of the pathophysiology of cardiac and pulmonary disorders is required in order to completely make any sense of the radiographic changes that one is describing.

## **Alveolar pattern – Differentials.**

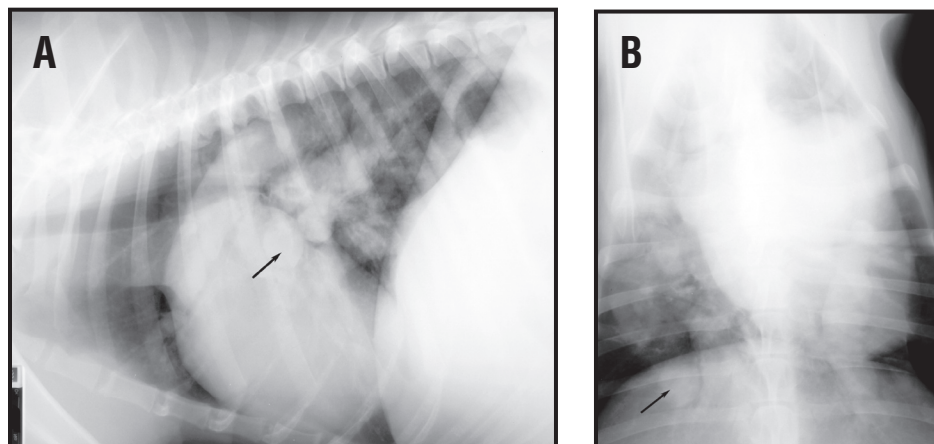
This pattern may occur due to pneumonia, hemorrhage, edema, atelectasis or neoplasia. Regardless what type of disease causes the pattern it looks much the same. The distribution within the lung and the presence of secondary signs are most useful in refining the differential diagnosis list.

1. Blood. Hemorrhage may be due to either trauma (**Figure 49**) or a coagulopathy. The distribution is random and can be quite extensive, especially in diseases such as disseminated intravascular coagulopathy (DIC). Look for other radiographic abnormalities like rib fractures and pleural air as common findings associated with trauma.

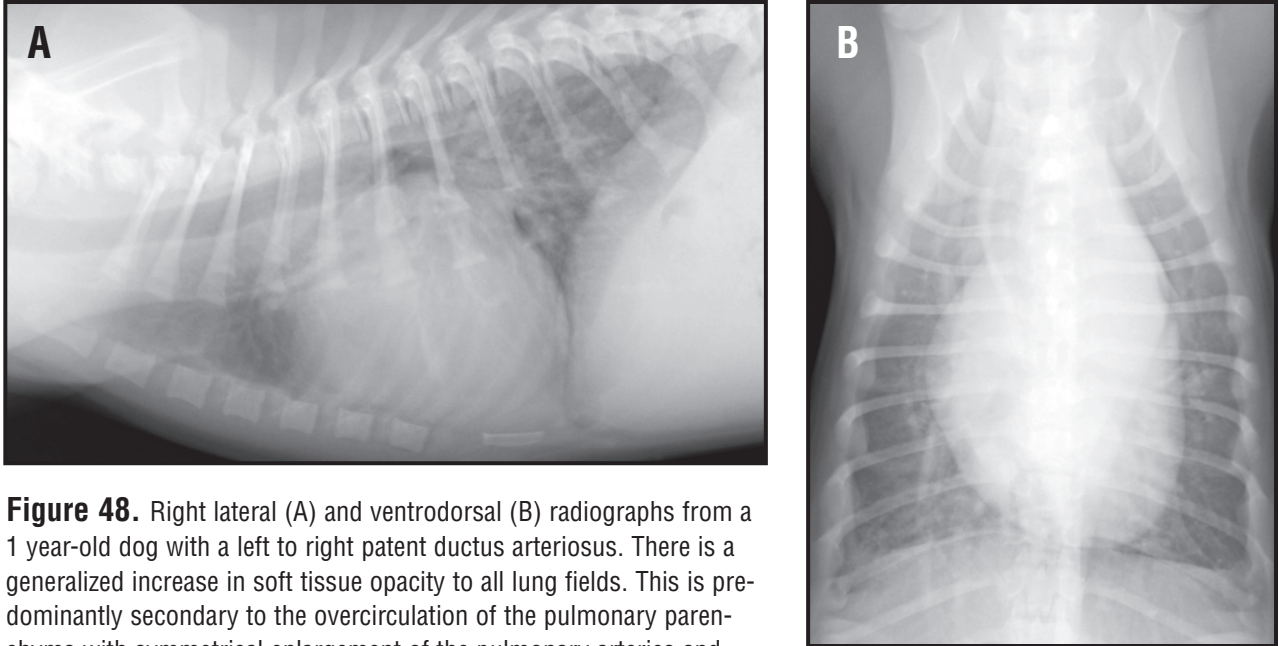
2. Pneumonia. Bronchopneumonia typically has a ventral distribution, affecting the peripheral and mid zones of the right middle, right cranial and left cranial lung lobes (**Figure 50**). The lesions begin at the periphery of the lung lobes and extend to the hilus with increasing severity. Complete alveolar opacification of the right middle lung lobe is a common finding. Aspiration pneumonia has a similar lobar distribution. Look for evidence of esophageal dilation and dysfunction that would support a diagnosis of aspiration pneumonia. But remember, esophageal dilation may be seen in severe pneumonia accompanied by severe dyspnea and it will resolve if the pulmonary lesions can be successfully treated. If severe pneumonia is present one should refrain from diagnosing a megaesophagus until the dyspnea has resolved and repeat radiographs are made. Hematogenous pneumonia or septic thromboembolism are uncommon and tend to have a patchy appearance with a caudodorsal distribution.

3. Edema. Edema is classified according to the immediate cause as cardiogenic (result of left heart

**Figure 47.** Right lateral (A) and dorsoventral (B) radiographs from a dog with severe heartworm infestation. Because of the severe pathologic end-arteritis there is blunting and pruning of multiple pulmonary arteries. These vascular changes can have a circular appearance and appear to be pulmonary nodules (black arrows).



Eosinophilic granulomas and lymphomatoid granulomatosis can be other differentials for these round structures if their origin as a pulmonary artery cannot be confirmed. On the DV radiograph, there is enlargement of the main pulmonary artery segment (1 to 2 o'clock).



**Figure 48.** Right lateral (A) and ventrodorsal (B) radiographs from a 1 year-old dog with a left to right patent ductus arteriosus. There is a generalized increase in soft tissue opacity to all lung fields. This is predominantly secondary to the overcirculation of the pulmonary parenchyma with symmetrical enlargement of the pulmonary arteries and veins. Large vessels can now be seen well into the periphery (compare with dogs with normal radiographs in Figures 3 and 4). There is also left sided cardiac enlargement and enlargement of the descending aorta (in the region of the ductus diverticulum).

---

**Table 3: Differential diagnoses of alveolar lung patterns.**

---

**Localized**

- Bronchopneumonia*
- Edema (cardiogenic or non-cardiogenic)*
- Hemorrhage*
- Primary lung tumor*
- Lobar collapse or atelectasis (compression, anesthesia, foreign body or mucous plug obstruction, pleural effusion)*
- Pulmonary infarction*
- Lung lobe torsion*

**Generalized**

- Severe bronchopneumonia*
- Severe edema*
- Severe hemorrhage (contusion or coagulopathy)*
- Near-drowning*
- Smoke inhalation*
- Acute Respiratory Distress Syndrome*

**Table 4: Differential diagnoses of a bronchial (rings and lines) pulmonary pattern.**

---

**Bronchial mineralization**

**Chronic bronchitis**

- Allergic (inhaled), Feline Asthma*
- Irritant – foreign body or aspiration (early or resolving)*
- Parasitic – Aelurostrongylus*

**Severe Generalized**

- Edema*
  - Pulmonary infiltrates with eosinophilia*
  - Bronchopneumonia*
- 

**Table 5: Differential diagnoses of an unstructured interstitial pulmonary pattern.**

---

**Generalized**

- Artifact (underexposure, underinflated end-expiratory radiograph)*
- Patient conformation (obesity)*
- Geriatric fibrosis*
- Lymphoma*
- Diffuse lymphangetic pulmonary metastasis*
- Pneumonitis*
- Metabolic (uremia, pancreatitis and septicemia)*
- Disease in transition (edema, pneumonia, hemorrhage).*

**Localized**

- Partial lung lobe collapse*
- Hemorrhage*
- Pulmonary embolism*
- Bronchial foreign body*
- Disease in transition*

**Table 6: Differential diagnosis for nodular interstitial pulmonary pattern.**

---

**Non-cavitary, Solitary nodule**

- Thoracic wall artifact (tick, nipple)*
- Primary lung tumor (dog – caudal lung lobe distribution)*
- Focal Granuloma (foreign body, heartworm)*
- Fluid filled bulla (hematocele)*
- Hematoma*
- Abscess*
- Pulmonary Cyst*

**Non-cavitary, Multiple nodules**

- Pulmonary metastatic disease*
- Mycotic granulomas (military type of nodular appearance)*
- Lymphomatoid Granulomatosis*
- Eosinophilic Granulomatosis*
- Malignant Histiocytosis*

**Cavitary, Solitary nodule/mass**

- Primary lung tumor (bronchogenic carcinoma)*
- Abscess (bronchoesophageal fistula)*
- Pneumatocele (trauma)*

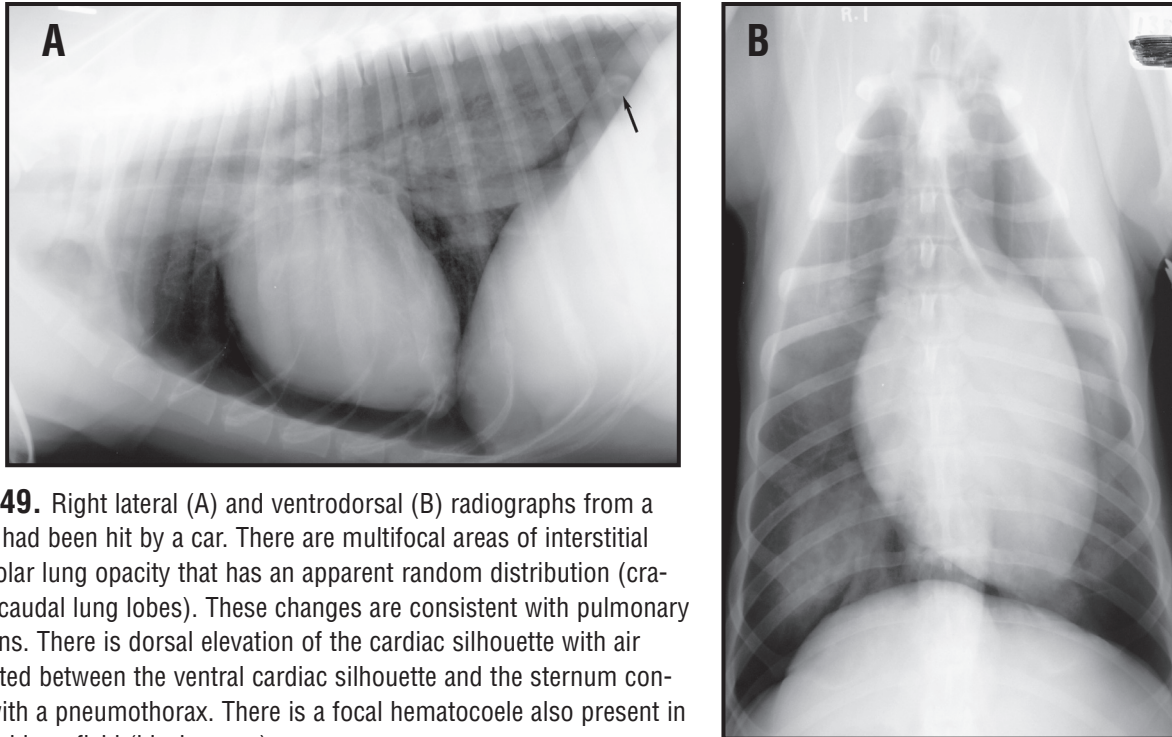
**Cavitary, Multiple Nodules**

- Paragonimus infestation*
- Multiple lung abscesses*
- Multiple traumatic pneumatoceles*

---

failure) or noncardiogenic, (any other cause such as post ictal or neurogenic). Cardiogenic pulmonary edema results from left heart failure, (**Figure 51**). The most common cause of left heart failure in dogs is secondary to mitral valvular degeneration/endocardiosis it begins in the hilar region of the caudal lung lobes and extends to the periphery. Acutely decompensated endocardiosis can result in a focal, lobar, severe alveolar pulmonary pattern in the right caudal lung lobe. Initially it may appear as an interstitial pattern that coalesces to form an alveolar pattern. In dogs with dilated cardiomyopathy (DCM) a more widespread pattern is often seen in overt cardiac failure. The edema may be distributed throughout the lung with a perivascular random, patchy distribution rather than hilar or a discrete lobar distribution. In cats with pulmonary edema, a similar random or patchy alveolar pulmonary pattern may be seen in any portion of multiple lung lobes. In case of endocardiosis and congenital heart disease pulmonary edema is usually accompanied by cardiac changes such as left atrial and ventricular enlargement and pulmonary venous congestion. Similar findings may be seen in cases of DCM in dogs and hypertrophic cardiomyopathy in cats but in some cases of peracute cardiac failure (such as acute aortic insufficiency secondary to bacterial endocarditis) may result in minimal or no change in the overall size and shape of the heart. The response to aggres-



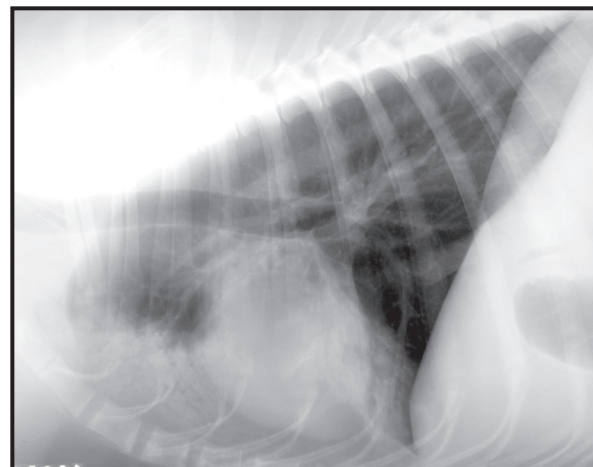


**Figure 49.** Right lateral (A) and ventrodorsal (B) radiographs from a dog that had been hit by a car. There are multifocal areas of interstitial and alveolar lung opacity that has an apparent random distribution (cranial and caudal lung lobes). These changes are consistent with pulmonary contusions. There is dorsal elevation of the cardiac silhouette with air being noted between the ventral cardiac silhouette and the sternum consistent with a pneumothorax. There is a focal hematocoele also present in the caudal lung field (black arrow).

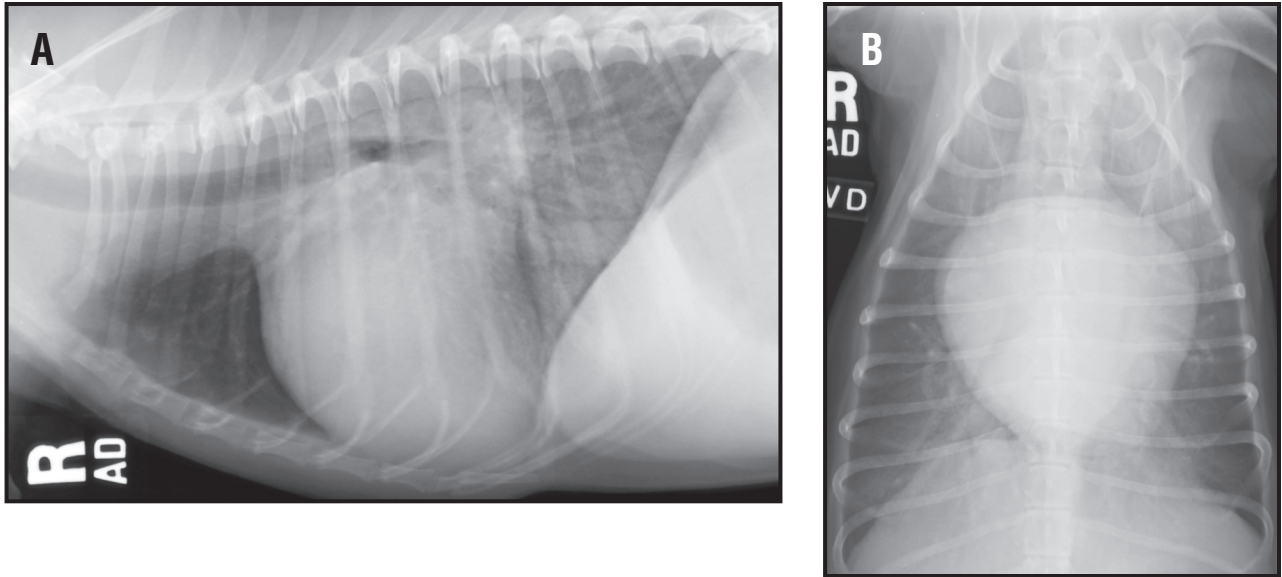
sive diuresis is often dramatic with complete or almost complete resolution of edema within 12 to 24 hours.

Non-cardiogenic pulmonary edema is distributed in the mid and peripheral zones of the caudal lung lobes (**Figure 52**). When severe it may extend to the hilus, resulting in an almost complete “white out”. The cranial lobes are usually spared. Causes include electric shock, status epilepticus, cranial trauma, near drowning/strangulation and severe airway occlusion. Non-cardiogenic pulmonary edema usually responds poorly to diuretic therapy, but will respond to time and should clear within a matter of several days if the inciting cause has resolved (rapid resolution post status epilepticus or acute electric shock).

4. Atelectasis. Most alveolar patterns represent flooding of the lung with a fluid or cellular infiltrate that displaces air out of the alveolus. Atelectasis is the result of collapse of a lung lobe so that the affected area will be reduced in expected size, (**Figure 53**). A radiographic sign that may indicate volume loss is a mediastinal shift of the cardiac silhouette toward the area of



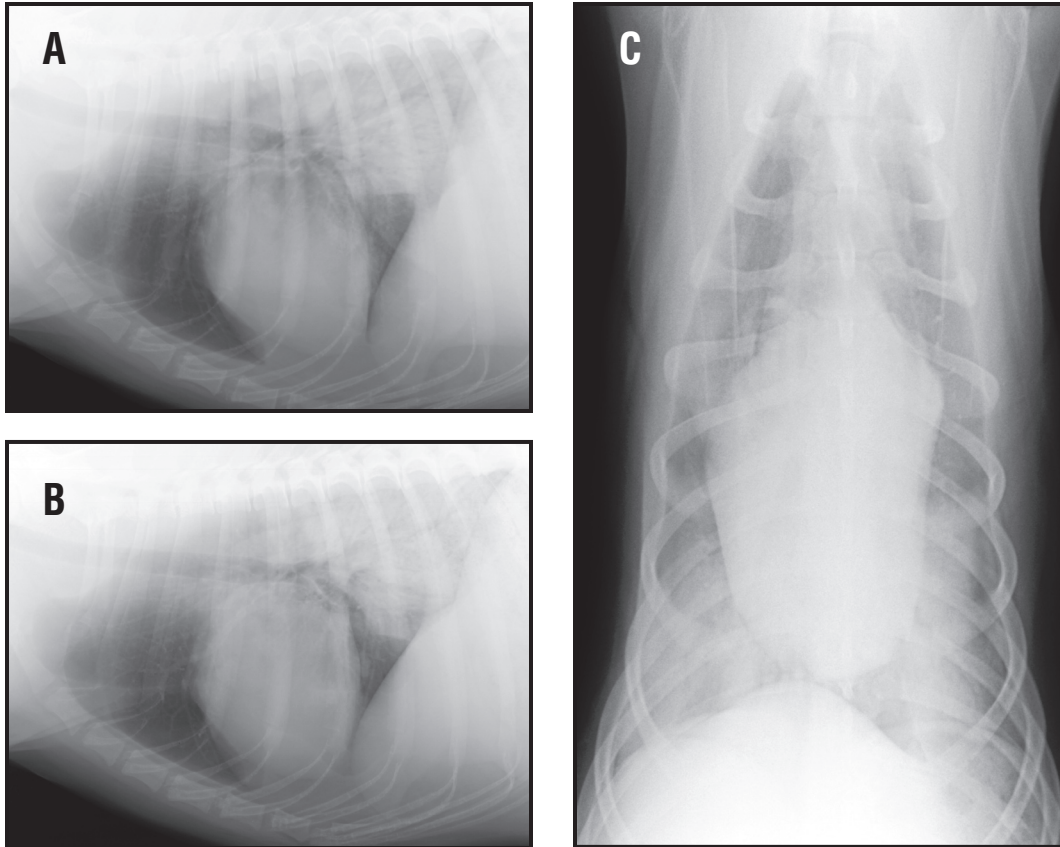
**Figure 50.** Left lateral radiograph from a dog with severe, lobar alveolar lung disease with a cranioventral anatomic distribution in the right cranial and right middle lung lobes (midzone and peripheral). These changes are consistent with bronchopneumonia or aspiration pneumonia.



**Figure 51.** Right lateral (A) and ventrodorsal (B) radiographs from a dog with chronic mitral valve insufficiency secondary to endocardiosis. There is enlargement of the left atrium with dorsal elevation of the trachea. There is enlargement of the pulmonary veins relative to the pulmonary arteries. There is an interstitial pulmonary pattern that has a central and mid-zone distribution with multiple lung lobe involvement. These radiographic abnormalities are consistent with left heart failure and pulmonary edema.

increased opacity and thereby the lung lobe with volume loss. Air bronchograms in collapsed lungs may appear to parallel each other, rather than diverging away from each other as in the case of a consolidated lung lobe, where the lung lobe volume is maintained. Volume reduction and the presence of alveolar fluid can be combined as in the case of a pneumothorax with lobar collapse and a pulmonary contusion. The key question in determining whether an alveolar pattern is due to atelectasis or flooding is whether the increase in opacity is compatible with the reduction in apparent lung volume or is it greater than would be expected (i.e. are we dealing with volume loss alone or is there another process too)? An alveolar pattern that is the result of atelectasis typically requires 80% or greater reduction in lung volume.

5. Neoplasia. Primary or metastatic pulmonary neoplasia that presents as an alveolar pattern is rare. The distribution may mimic the appearance of any of the disease above or be entirely random (**Figure 54**). This differential should be considered with alveolar patterns which have unusual or atypical distributions or which resemble one of the more common causes but fail to respond to appropriate therapy. Replacement of an entire lung lobe with a neoplastic process will cause a lobar sign and the lobe will appear “swollen” or have bulging contours. In cats, however, typically a cranial lung lobe tumor will invade a bronchus centrally and cause the lobe to collapse (**Figure 19B**), resulting in an ipsilateral mediastinal shift. Air bronchograms are usually absent in these radiographic cases.

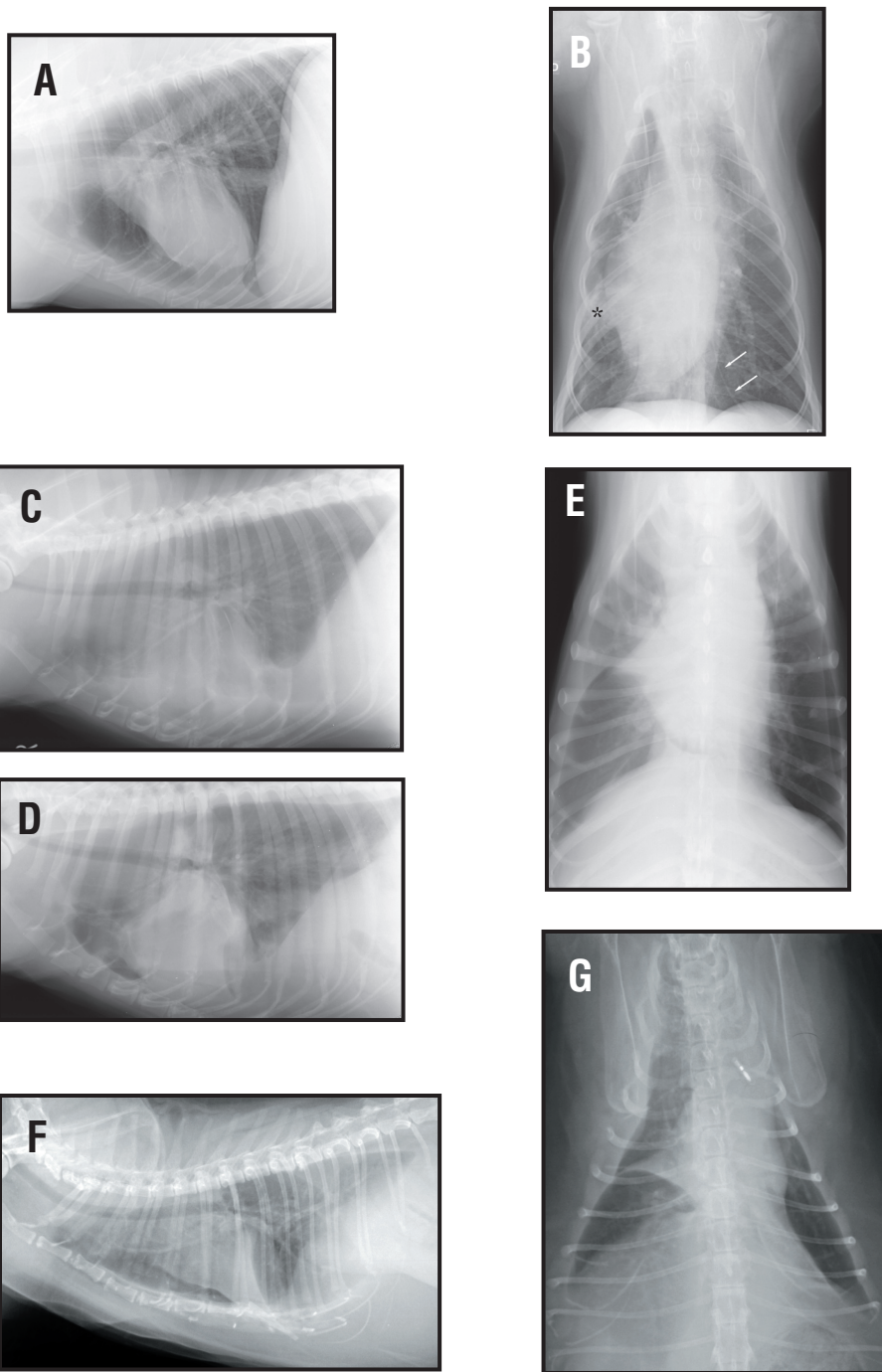


**Figure 52.** Right lateral (A), left lateral (B) and ventrodorsal (C) radiographs from a dog after a grand mal seizure. There is a severe, lobar alveolar pulmonary pattern present in the caudal lung lobes. These changes are consistent with non-cardiogenic pulmonary edema. The cardiac silhouette is within normal limits for size and shape.

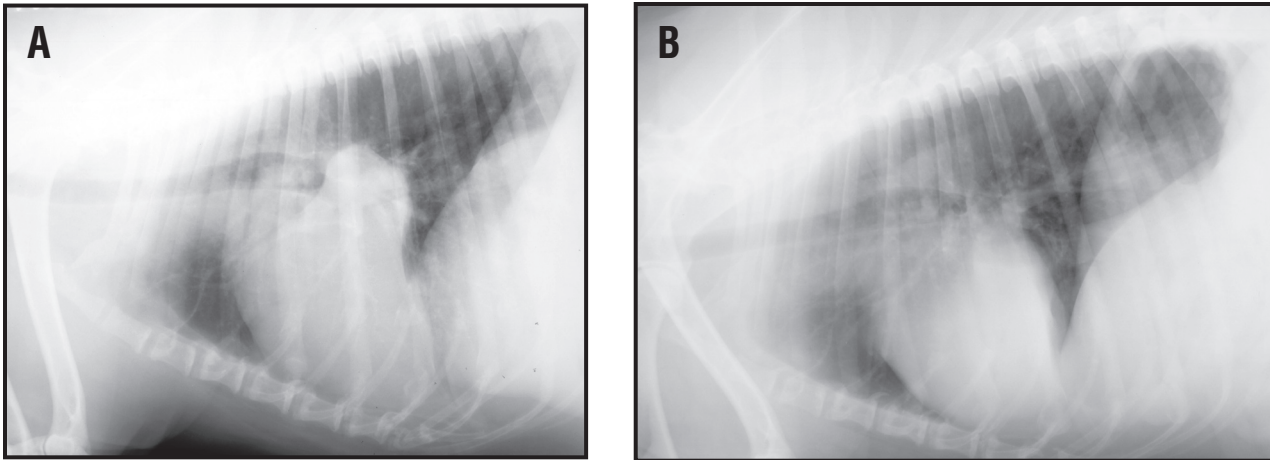
## Bronchial pattern – Differentials.

A bronchial pattern indicates airway disease that may have allergic, infectious or inflammatory etiologies. Radiology is quite insensitive when diagnosing bronchial disease. In cats asthma is the most common diagnosis. Heartworm infestation in dogs and cats may provoke an allergic response, pulmonary infiltrate with eosinophilia (PIE), which is seen as either a bronchial or unstructured interstitial pattern or a mixture of both pulmonary patterns, (**Figure 55**). Although heartworm disease is the most common cause of PIE but it occurs sporadically from other causes. A dramatic resolution of the radiographic changes may be seen in 48 to 72 hours of treatment with anti-inflammatory doses of corticosteroids. Chronic bronchitis can result in central and peripheral airway thickening. If the inflammation of the bronchus is severe, it will “spill” over into the adjacent peribronchial interstitial structures. Chronic bronchial changes, can over time, result in dilation of the bronchi. If this dilation is fixed (repeatable on multiple radiographs) then the term bronchiectasis is used, (**Figure 56**). Bronchiectasis has been shown to be more prevalent in Cocker Spaniels. The bronchiectasis can be focal (right cranial lobar bronchus) or generalized involving all bronchi. Dogs or cats with chronic bronchial changes (bronchial wall thickening) will usually benefit from a transtracheal wash or a bronchoalveolar lavage.

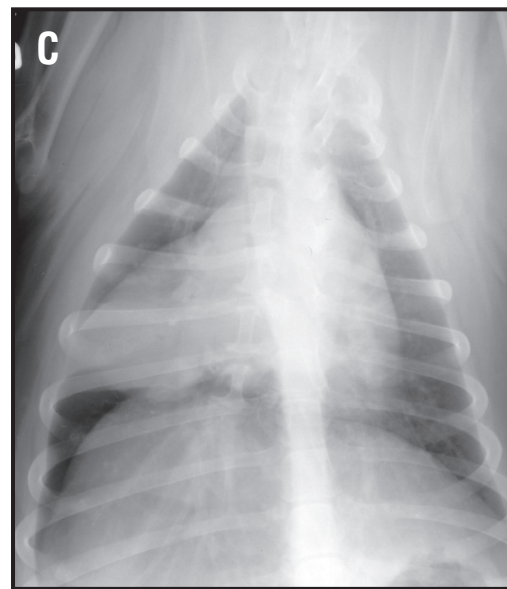
## Interstitial pattern – Differentials.



**Figure 53.** Right lateral (A) and ventrodorsal (B) radiographs from a dog after general anesthesia. There is atelectasis of the right middle lung lobe (\*) with an ipsilateral mediastinal shift toward the right. The caudoventral mediastinal reflection (white arrows) is well visualized on the ventrodorsal radiograph. Right lateral (C), left lateral (D) and ventrodorsal (E) radiographs from a dog with warfarin toxicity. There is right middle lung lobe collapse. In this case, a significant ipsilateral mediastinal shift is not present as the right cranial and right caudal lung lobes have hyperinflated and there is a right-sided pleural effusion. Left lateral (F) and ventrodorsal (G) radiographs from a 10 year-old cat with chronic bronchial disease and lobar sign (alveolar lung pattern) of the entire right middle lung lobe. The triangular shaped lung lobe is seen along the lateral margin of the cardiac silhouette on the VD radiograph and border effaces with the cardiac silhouette. This represents a collapsed right middle lung lobe.

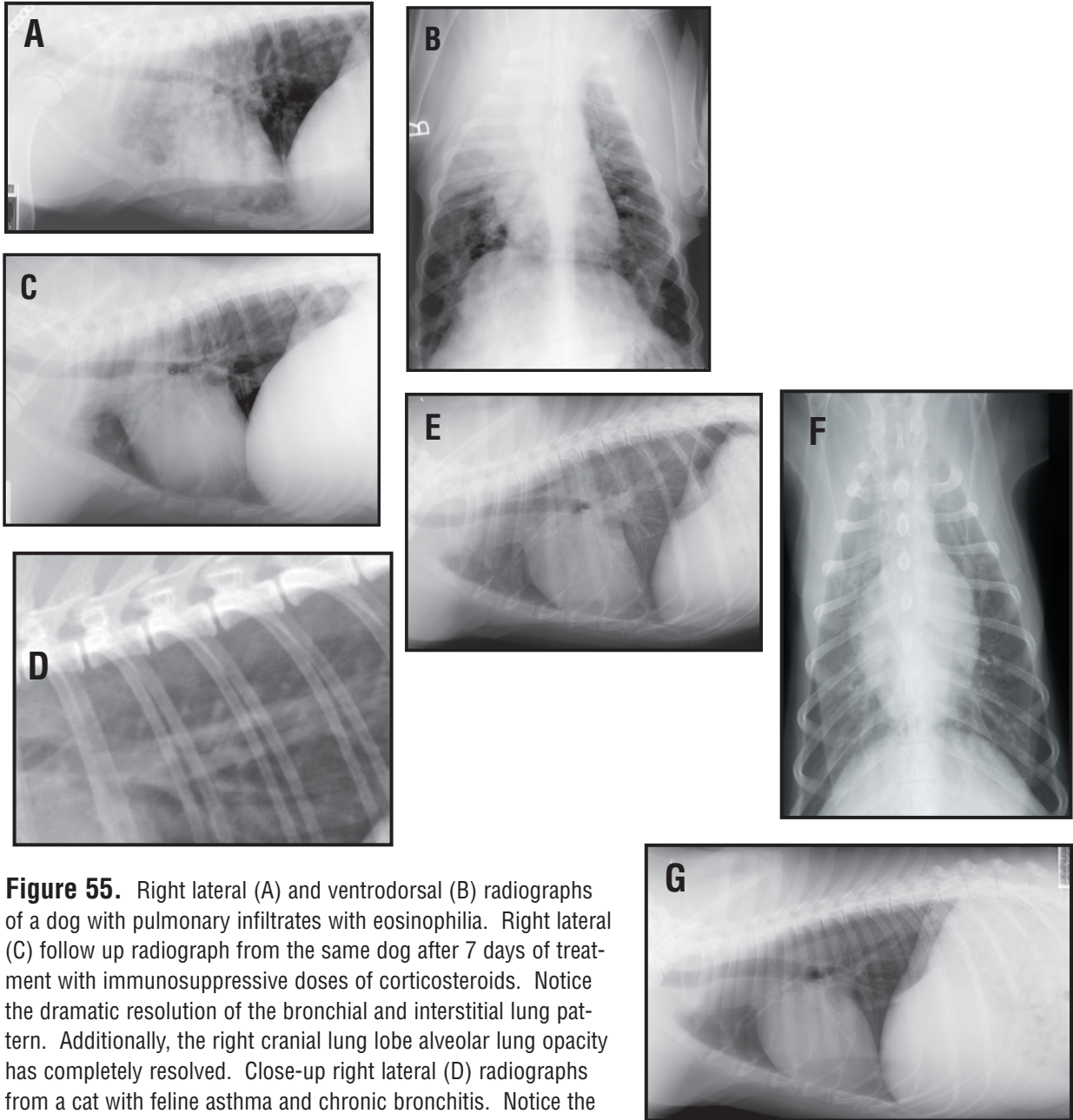


**Figure 54.** Right lateral (A), left lateral (B) and dorsoventral (C) radiographs from a 2 year-old Bernese Mountain dog. There is a right middle lung lobe alveolar pattern with a lobar sign and border effacement between the right middle lung lobe and the cardiac silhouette. There is no mediastinal shift due to the mass and lack of volume loss in the right middle lung lobe. Also, there are no air bronchograms, but the pulmonary pattern is still an alveolar one as a lobar sign and border effacement are still present. The histiologic diagnosis was malignant histiocytosis.

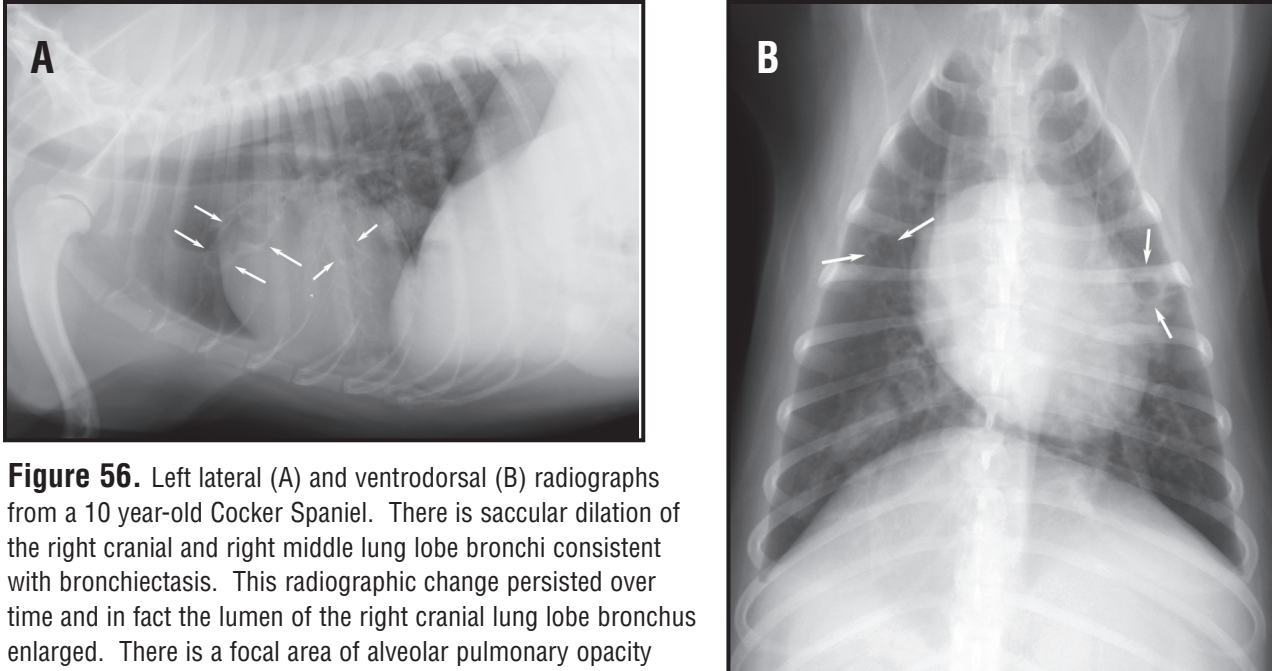


The first type of interstitial pattern is the nodular pattern. The principle differentials for this type of a pattern in the dog or cat include metastatic neoplasia or disseminated fungal disease, (**Figure 57**). Other rule outs include hematogenous pneumonia, abscesses, granulomas and parasitic lesions (e.g. *Toxoplasma gondii* and *Paragonimus kellicotti*). Focal mineralized osteomas or osseous metaplasia is commonly seen on Collies and Shelties, (**Figure 58**). Differentiation between early metastatic disease and osteomas or end-on vessels is sometimes difficult, (**Figure 59**). End-on pulmonary vessels will line up with a pulmonary vessel (proximal or parent vessel), not be larger than the superimposed proximal vessel on which it is found and is usually very radiopaque due to the summation of the vessel throughout its length. True pulmonary nodules have to be at least 5 mm in size in order to be visualized. In most cases pulmonary osteomas and end-on vessels are usually several mm in diameter and very radiopaque. Pulmonary nodules are not as radiopaque (in fact are faintly visualized) and are easily missed in the peripheral lung fields. The area over the diaphragm, cardiac silhouette and over the vertebral bodies are regions that are easily overlooked. If you find a nodule on one radiographic view, try to triangulate the lesion on the other radiographic view to confirm the presence of a nodule. Other potential fake-outs of apparent pulmonary “nodules” from extrathoracic etiologies would include costochondral junction irregularities, nipple artifact, ectoparasites (ticks) or skin nodules or tags, (**Figure 59**). If in doubt, palpate the dog or cat for the source of an external “nodule” and put some barium sulfate on the area. Repeat the radiograph. The barium sulfate should outline the apparent nodule if the it was truly the extrathoracic structure.

The second type of interstitial pulmonary pattern is the pattern that is described by exclusion of the other patterns. This pattern is called the unstructured interstitial pattern. There are a myriad pos-



**Figure 55.** Right lateral (A) and ventrodorsal (B) radiographs of a dog with pulmonary infiltrates with eosinophilia. Right lateral (C) follow up radiograph from the same dog after 7 days of treatment with immunosuppressive doses of corticosteroids. Notice the dramatic resolution of the bronchial and interstitial lung pattern. Additionally, the right cranial lung lobe alveolar lung opacity has completely resolved. Close-up right lateral (D) radiographs from a cat with feline asthma and chronic bronchitis. Notice the prominent rings and lines throughout the pulmonary parenchyma that increases the overall lung soft tissue opacity. Cats with feline asthma the present with a cough can have normal radiographs or just have hyperinflation present. To determine whether or not the hyperinflation is secondary to air trapping from lower airway bronchospasm (asthma reactive airways), one can take an inspiratory and expiratory lateral radiograph. If there is not a significant difference in the overall thoracic volume, then the cat is air trapping. Left lateral (E) and ventrodorsal (F) radiographs from a 6 year old Portuguese water dog. There is a generalized, moderate to severe unstructured interstitial lung opacity. Top differentials would include lymphoma, mycotic pneumonia and pulmonary infiltrates with eosinophilia. A peripheral eosinophilia was noted. Follow-up (G) left lateral radiograph of the same dog after 10 days of immunosuppressive doses of corticosteroids. There has been complete resolution of the previous described unstructured interstitial lung disease.



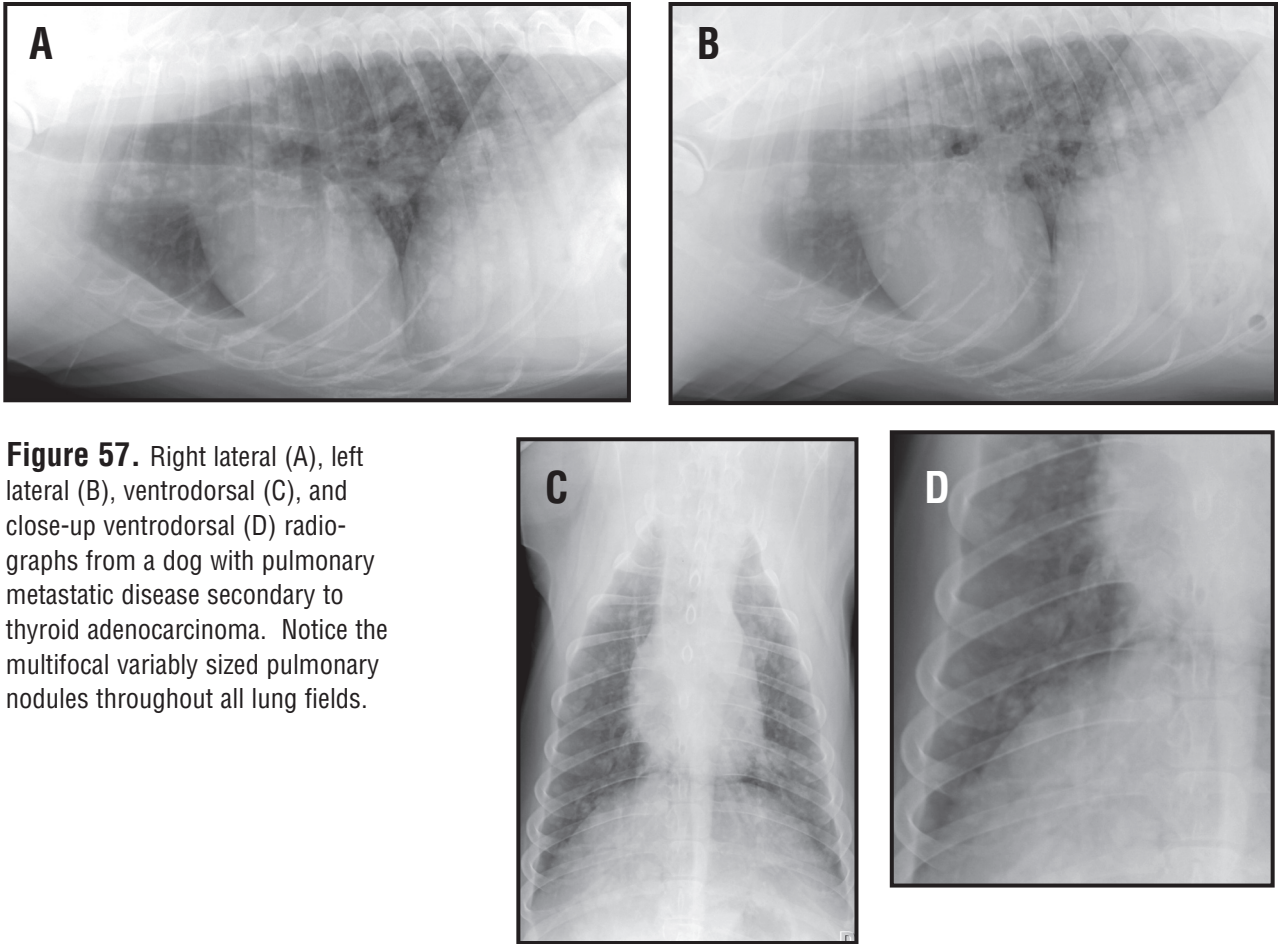
**Figure 56.** Left lateral (A) and ventrodorsal (B) radiographs from a 10 year-old Cocker Spaniel. There is saccular dilation of the right cranial and right middle lung lobe bronchi consistent with bronchiectasis. This radiographic change persisted over time and in fact the lumen of the right cranial lung lobe bronchus enlarged. There is a focal area of alveolar pulmonary opacity noted in the right caudal lung lobe on the VD radiograph. These dogs are predisposed to recurrent bronchopneumonia secondary to abnormal mucociliary clearance.

sible differential diagnoses for this pulmonary pattern. These include pulmonary fibrosis, neoplasia (lymphoma, primary lung tumors and lymphangitic metastases or metastatic disease from hemangiosarcoma), allergic lung disease/PIE (often associated with heartworm disease), interstitial pneumonia (viral, early fungal, early or resolving bacterial), interstitial edema, poisoning, hemorrhage, inhalational injury, uraemia, toxoplasmosis, aluerostrongylus, metastatic bronchogenic carcinoma and FIP. This is probably the least helpful radiographic finding and additional tests are required to determine the etiology of lung disease. This pattern can also be caused by artifacts or disease processes that would reduce the pulmonary volume (pleural effusion). An important consideration is that an unstructured interstitial pattern may represent disease in transition. Such a pattern is commonly seen with developing or resolving edema or bronchopneumonia or in the transition between normal and affected lung with these diseases.

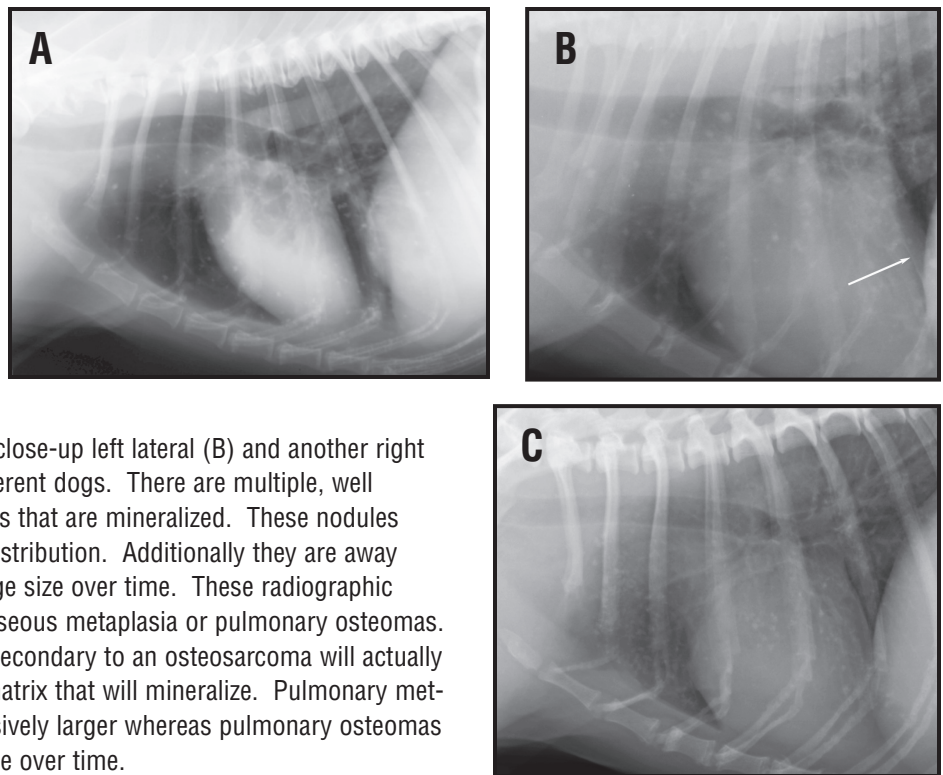
#### IV. The Mediastinal Space

The mediastinum is formed by the reflection of the two pleural mesothelial linings. The mediastinum is a central portion of the extrapleural space that is has a dorsal midsagittal position and a leftward ventral position. Major structures contained within the mediastinum include thymus, lymph nodes, trachea and bronchi, esophagus, great vessels (arteries and veins) and pericardial sac (containing all structures of the heart). Mediastinal abnormalities that are evident radiographically can be categorized as one of four abnormalities. These include the presence of mediastinal air, mediastinal mass(es), mediastinal fluid or a mediastinal shift.

Some questions that are pertinent to the mediastinal space, aside from the cardiac silhouette would include: Is the mediastinum normal for size, margins, shape and opacity? Is there a mediastinal mass or any fluid? Is there mediastinal air and if yes, is it focal and contained in a mediastinal structure or is it generalized within the mediastinal space? Is there a mediastinal shift? If the answer to any



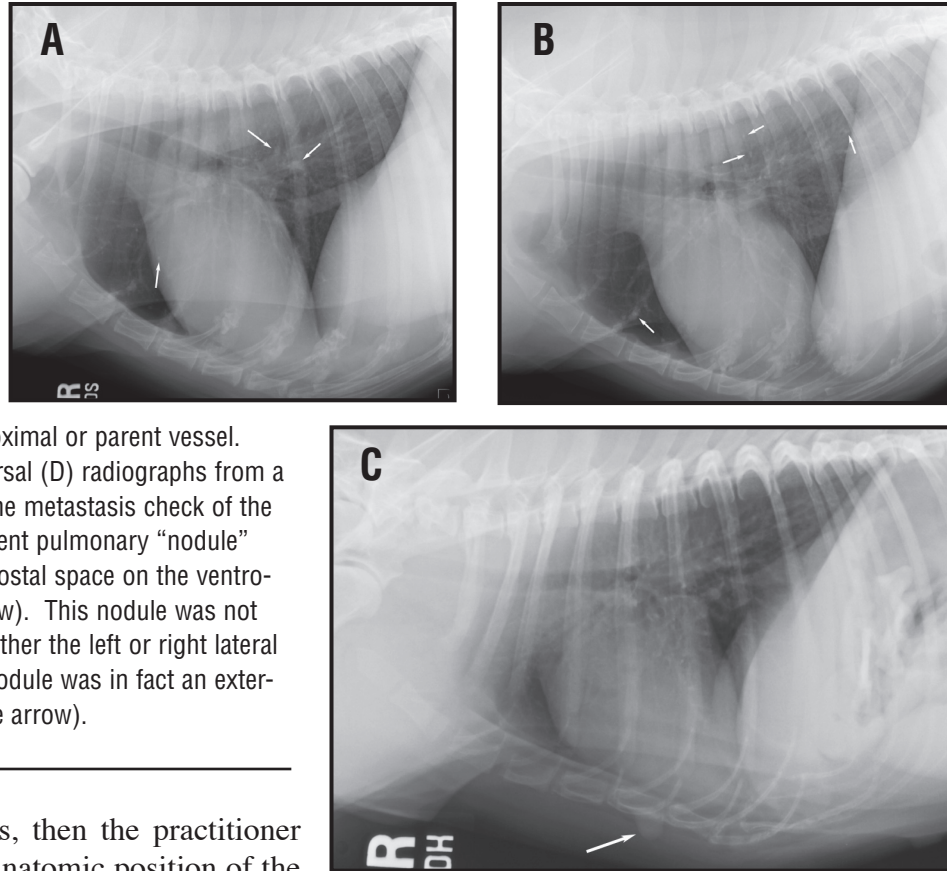
**Figure 57.** Right lateral (A), left lateral (B), ventrodorsal (C), and close-up ventrodorsal (D) radiographs from a dog with pulmonary metastatic disease secondary to thyroid adenocarcinoma. Notice the multifocal variably sized pulmonary nodules throughout all lung fields.



**Figure 58.** Right lateral (A), close-up left lateral (B) and another right lateral (C) radiograph from different dogs. There are multiple, well defined small interstitial nodules that are mineralized. These nodules have a predominantly ventral distribution. Additionally they are away from vessels and will not change size over time. These radiographic changes are consistent with osseous metaplasia or pulmonary osteomas. Rarely, pulmonary metastasis secondary to an osteosarcoma will actually lay down the organic osteoid matrix that will mineralize. Pulmonary metastatic lesions will get progressively larger whereas pulmonary osteomas are typically static in appearance over time.



**Figure 59.** Right lateral (A) and left lateral (B) radiographs from a dog that presented for a routine metastasis check of the thorax. There are multiple end-on pulmonary vessels that can be mistaken for pulmonary metastatic disease. Several of the end-on vessels are highlighted by white arrows. These end-on vessels are seen superimposed over a proximal or parent vessel. Right lateral (C) and ventrodorsal (D) radiographs from a dog that presented for a routine metastasis check of the thorax. There is a focal apparent pulmonary “nodule” noted over the right 5th intercostal space on the ventrodorsal radiograph, (white arrow). This nodule was not seen in the lung field on the either the left or right lateral radiograph. The pulmonary nodule was in fact an external structure, the nipple (white arrow).



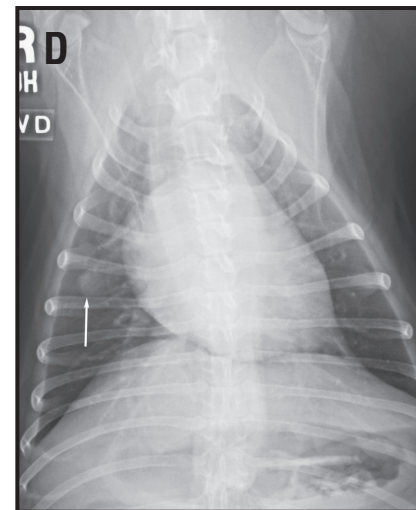
of these questions is yes, then the practitioner should define the exact anatomic position of the abnormality. In other words is the abnormality focal (cranial, middle caudal and dorsal or ventral in position) or generalized.

The mediastinum can be divided into three potential (arbitrary) spaces including the cranial, middle and caudal spaces. Each of these areas can be then be further divided into a dorsal and ventral compartment. Normal structures in each area will be described first and then, radiographic abnormalities associated with anatomic structures will be reviewed.

### A. The Cranial Mediastinum

The dorsal aspect of the cranial mediastinum is characterized by soft tissue opacity that is divided by a radiolucent tube called the trachea, (**Figure 60**). Other anatomic structures that are present in the dorsal aspect of the cranial mediastinum include the cranial thoracic vessels (aortic arch, brachiocephalic trunk, left subclavian, azygous vein, cranial vena cava), fat, nerves (vagosympathetic trunk), esophagus and cranial mediastinal lymph nodes. The trachea and its walls are normally the only structure that is visualized on the lateral and VD/DV radiograph. The trachea is normally located in a central to right sided position on the VD/DV radiograph. The trachea normally diverges away from the vertebral column on the lateral radiograph.

The ventral compartment of the cranial mediastinum is made up the mediastinal reflection of the

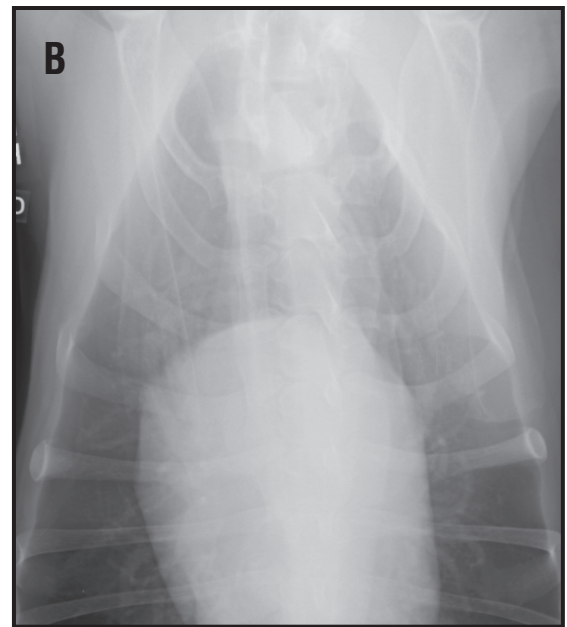
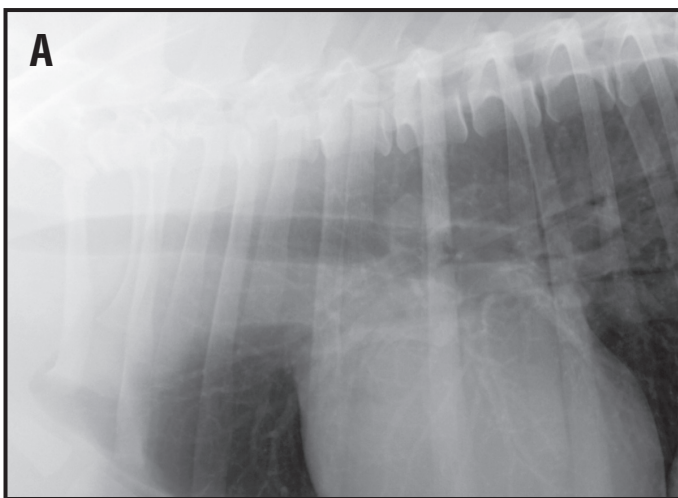


right and left cranial lung lobes. On the VD radiograph the ventral mediastinal reflection can be seen and defined by the left and right cranial lung lobes. The left cranial lingula will extend into the right cranial hemithorax in large breed dogs, but not cats, brachiocephalic dogs or obese small dogs.

The thymus is a normal structure seen in immature cats and dogs that has a typical appearance of a triangular soft tissue opacity extending from a craniomedial position to a caudolateral position in the cranioventral mediastinal reflection. This called the “sail” sign, (**Figure 10**). On the lateral radiograph a curvilinear soft tissue structure may be seen (inconsistent even if the thymus is present on the VD/DV radiograph). While the thymus is located on the left of the vertebral column, enlargement of the sternal lymph node will result in widening of the ventral mediastinal reflection in a fusiform to oval shape on a rightward or midline position superimposed over the cranial thoracic vertebral bodies on the VD/DV radiograph. Also within the cranial ventral mediastinal reflection, the internal thoracic vessels (artery and vein) are found. On the VD radiograph, the cranial vena cava and trachea will be located just rightward of the thoracic vertebral bodies.

Is there air present in the Mediastinum? Is the air focal or generalized? Generalized gas accumulation within the cranial or caudal mediastinum must be distinguished from air within the esophagus. Cervical trauma, external penetrating wounds, esophageal or tracheal rupture/tear, venipuncture or transtracheal washes can result in a pneumomediastinum. As air accumulates within the cranial mediastinum, various structures and edges of soft tissues that normally will border efface and become apparent, (**Figure 61**). If the pneumomediastinum becomes severe then the air will dissect caudally into the retroperitoneal space via the aortic hiatus through the diaphragm. A pneumomediastinum will only be seen on the lateral radiograph unless the VD/DV is obliqued. A pneumomediastinum may lead to a pneumothorax but a pneumomediastinum will not result from a pneumothorax as the air collapses the mediastinal space between the two pleural reflections. The key to diagnosing a pneumomediastinum is the ability to see soft tissue structures within the cranial mediastinum that are usually not seen on normal radiographs. These structures would include

**Figure 60.** Close-up right lateral (A) and ventrodorsal (B) radiographs from a dog showing the cranial mediastinum. On the lateral radiograph, there uniform soft tissue opacity with a smooth ventral margin that represents the normal soft tissue structures of the dorsal, cranial mediastinum. The trachea can be identified only because of the air within the tracheal lumen. The cranioventral mediastinal reflections are seen on the ventrodorsal radiograph.



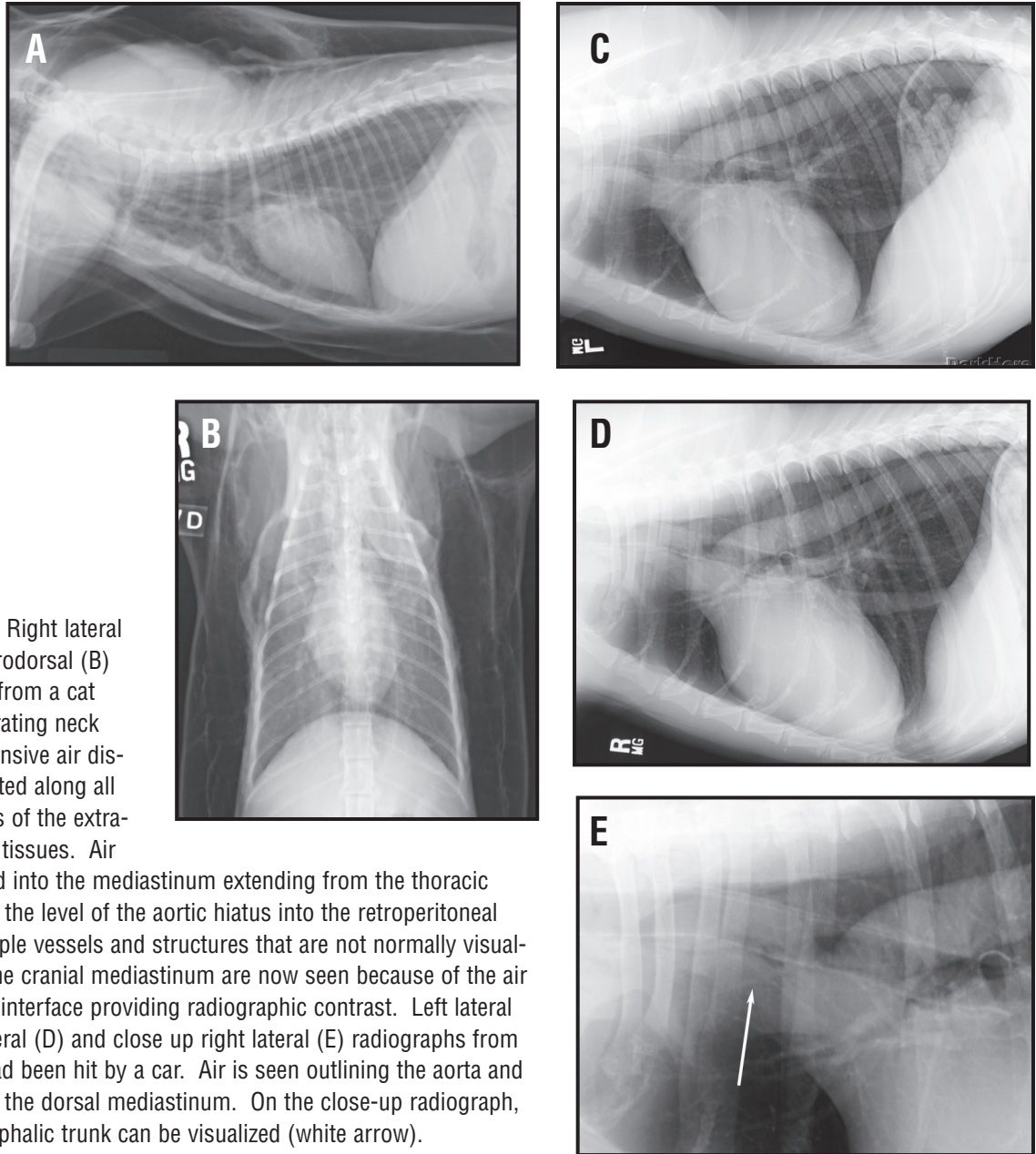
the outer (normally not seen) and the inner (normally seen) margins of the tracheal wall, the entire thoracic aorta, the great vessels of the cranial mediastinum, the azygous vein, and the longus colli muscles. Gas on the outside of the trachea, is called the tracheal stripe sign and is consistent with a pneumomediastinum. Gas within the cranial thoracic esophagus will cause the ventral border of the esophagus to border efface with the dorsal border of the trachea creating what is called the tracheoesophageal stripe sign.

Is there a mediastinal mass or fluid? Common causes of mediastinal masses include lymph node mass(es) or enlargement, thymic mass (thymoma or thymic lymphoma), esophageal enlargement (dilated as with generalized or partial megaesophagus), mediastinal hemorrhage (thymic rupture in an immature dog or hemorrhage secondary to trauma or coagulopathies). Typically, on radiographs of animals with craniodorsal mediastinal masses, there will be symmetrical widening of the cranial mediastinum on the ventrodorsal radiograph with caudal displacement of the right and left cranial lung lobes, (**Figure 62**). Mediastinal tumors usually arise from the thymus, lymph nodes, ectopic thyroid tissue or connective tissues of the dorsal and cranial mediastinal structures. Mediastinal fluid may accumulate due to the presence of a mass, hemorrhage or mediastinitis, or can be secondary to esophageal perforation.

Mediastinal masses can also be accompanied by pleural fluid. The presence of the fluid can make diagnosis of the mediastinal masses difficult. Dorsal deviation of the trachea in the presence of a moderate or severe volume of pleural fluid cannot be used to infer the presence of a mediastinal mass, even with caudal displacement of the tracheal carina. Repeating radiographs following thoracocentesis can be helpful. Positional films may be more useful for evaluating the cranial mediastinum, (**Figure 63**). An erect horizontal beam DV or VD film is preferred. Using this positional radiograph, the pleural fluid will drain to the caudal thorax (now in a down, gravity position) and the lungs to outline the lateral margins of the cranial mediastinum quite clearly. An alternative technique is to perform a non-selective angiogram cranial vena cava. A large bore catheter is placed in either jugular vein and a bolus of water-soluble iodinated contrast medium (400 to 800 mg I/kg) is injected as quickly as possible. Mid way or simultaneous to the end of the contrast medium injection, a lateral radiograph is obtained centered over the thorax. If a cranial mediastinal mass is present there will be dorsal displacement, compression and/or distortion of the cranial vena cava. The cranial vena cava should also be evaluated for the presence of intraluminal abnormalities. Filling defects within the contrast that have a consistent appearance on multiple films suggest thrombus formation or vascular invasion by tumor. A crude assessment of cardiac size may also be made by this technique. If a pericardial abnormality is suspected (pericardial effusion or peritoneopericardial diaphragmatic hernia), the true heart versus the cardiac silhouette can be determined.

Radiographic signs of a mass or fluid can include increased overall soft tissue opacity on the lateral film, elevation of the trachea, widening of the cranial mediastinum to exceeds the width of the spine on the VD or DV film (except in brachycephalic breeds or obese patients), blurring or obliteration of the cranial border of the heart.

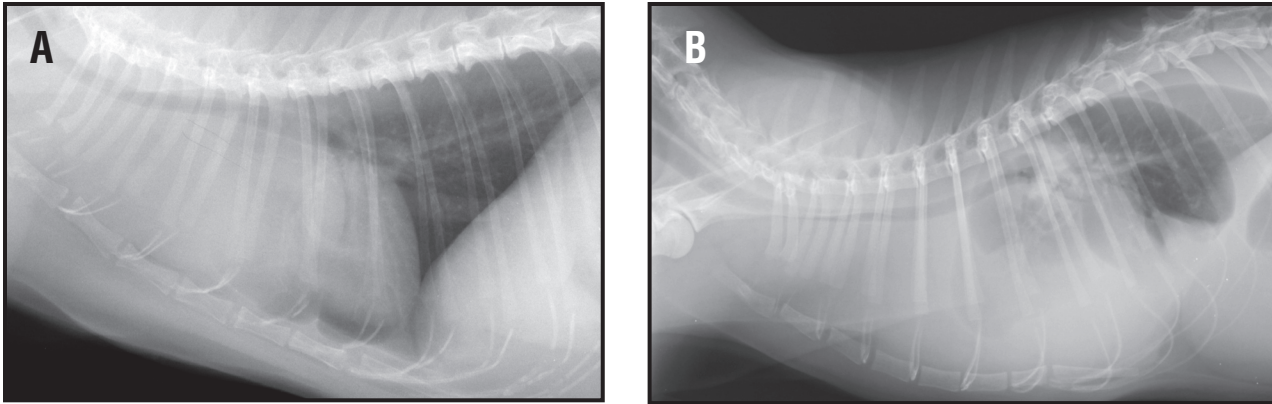
Is there an ipsilateral or contralateral mediastinal shift? A mediastinal shift is secondary to a pleural or pulmonary abnormality. It may occur either due to volume loss or increased volume in the adjacent lung lobe or the pleural space in one hemithorax. An ipsilateral mediastinal shift is secondary to volume loss (atelectasis) of a cranial lung lobe or a pleural or lobar mass resulting in a contralateral mediastinal shift. The lungs should be evaluated for evidence of a mass, overinflation or volume loss and the pleural space for a mass and/or fluid. A mediastinal shift will occur within minutes after the animal is anesthetized. A common cause of atelectasis can be secondary to prolonged lateral



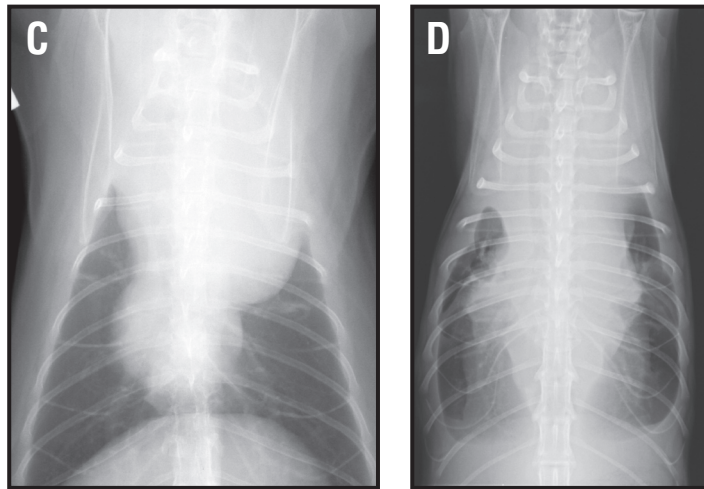
**Figure 61.** Right lateral (A) and ventrodorsal (B) radiographs from a cat with a penetrating neck wound. Extensive air dissection is noted along all fascial planes of the extra-thoracic soft tissues. Air has dissected into the mediastinum extending from the thoracic inlet through the level of the aortic hiatus into the retroperitoneal space. Multiple vessels and structures that are not normally visualized within the cranial mediastinum are now seen because of the air – soft tissue interface providing radiographic contrast. Left lateral (C), right lateral (D) and close up right lateral (E) radiographs from a dog that had been hit by a car. Air is seen outlining the aorta and structures of the dorsal mediastinum. On the close-up radiograph, the brachycephalic trunk can be visualized (white arrow).

recumbency, general anesthesia or following thoracic surgery.

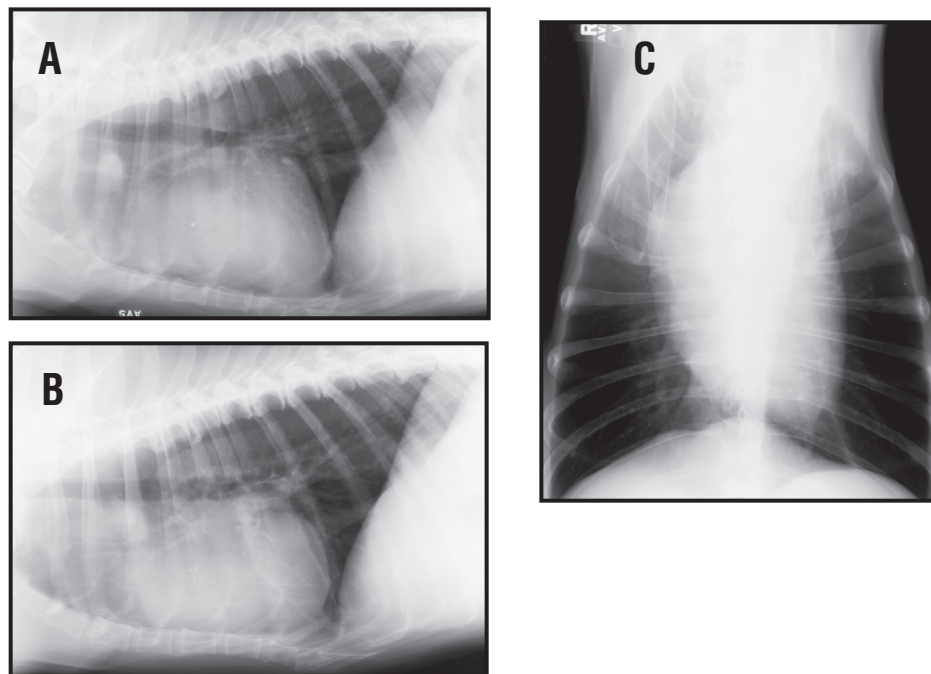
The sternal lymph node is located in the ventral compartment of the cranial mediastinum, (**Figure 64**). It is located dorsal to the second or third sternbrae on the lateral radiograph. The sternal lymph node receives lymphatic drainage from the pleural and peritoneal surfaces of the diaphragm and organs of the abdomen. Sternal lymphadenopathy is commonly associated with multicentric lymphoma in dogs or peritoneal inflammatory or neoplastic disorders. The sternal lymph node is easier to recognize in the dog than the cat because of the ventral lung lobe mediastinal reflections. These mediastinal reflections are not as prevalent in the cat and thereby the sternal lymph node is seen as an ill-defined oval increase in soft tissue opacity dorsal to the second sternbrae. On the VD radiograph of a dog with sternal lymphadenopathy, there will be an “S” deformity and widen-



**Figure 62.** Right lateral (A) and ventrodorsal (B) radiographs from a cat with a cranial mediastinal mass. There is lateral displacement of the right and left cranial lung lobes. The cardiac silhouette is displaced caudally. This mass was aspirated and a diagnosis of lymphoma made. Right lateral (C) and ventrodorsal (D) radiographs from a cat. There is a pleural effusion. The trachea is elevated dorsally and caudally. The cardiac silhouette and diaphragm are not visualized. An erect beam ventral to dorsal radiograph would document that there was a cranial mediastinal mass in addition to the severe pleural effusion. Cytologic examination of a sample of the pleural fluid was consistent with lymphoblastic lymphoma.



**Figure 63.** Right lateral (A), left lateral (B) and ventrodorsal (C) radiographs from a dog with a thymoma. A cranioventral mediastinal mass can be seen on the lateral radiographs. On the lateral radiographs there is border effacement of the mass with the cardiac silhouette. Differential diagnoses would include a right cranial lung lobe neoplasm, ectopic thyroid neoplasm or a bronchial cyst.

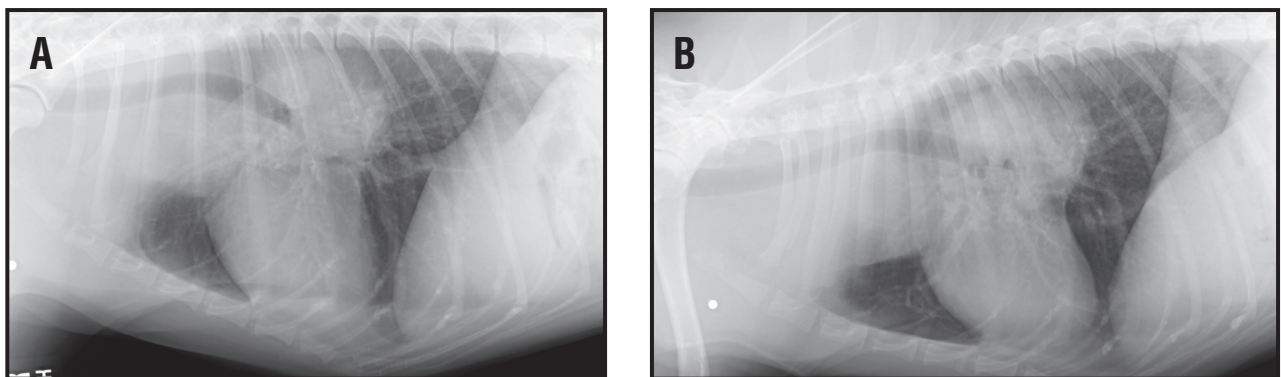


ing to the ventral cranial mediastinal reflection with focal retraction of the cranial lung lobes (not symmetrical widening as with a dorsal cranial mediastinal mass).

### The esophagus

Is the esophagus normal? The normal esophagus is not visualized. The esophagus runs from a dorsal cranial mediastinal position to a caudodorsal mediastinal position over the heart base area. The esophagus inserts into a slightly leftward opening in the mid dorsal diaphragm, at the esophageal hiatus. The esophagus lies just to the left and dorsal aspect of the trachea. In the caudal mediastinum the esophagus is in a central position superimposed over the caudal thoracic vertebrae. In the cranial thorax and just cranial to the thoracic inlet, the esophagus lies in a dorsolateral position (leftward) and can cause the trachealis muscle and dorsal tracheal membrane to indent in to the tracheal lumen. This is called a redundant dorsal tracheal membrane and has been considered a type I tracheal collapse, (**Figure 65**). However, this can be seen in numerous dogs without clinical signs of coughing and should not be considered a significant abnormality without the appropriate clinical context.

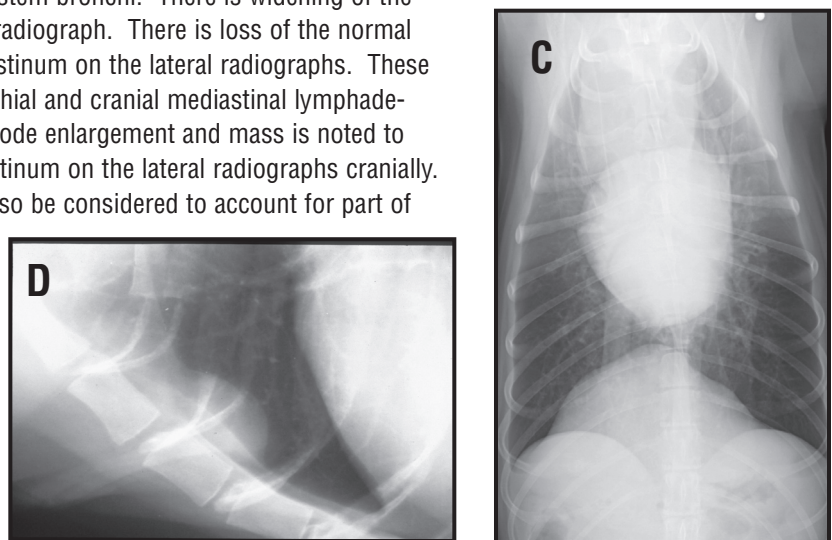
Many normal dogs will have a short, thin, linear gas shadow within the esophagus just cranial to the tracheal bifurcation, most commonly identified on the left lateral radiograph. This should only be



**Figure 64.** Right lateral (A), left lateral (B) and ventrodorsal (C) radiographs from a dog with thoracic lymphoma.

There is a soft tissue mass dorsal to the cardiac silhouette on the lateral radiographs with ventral displacement of the caudal thoracic trachea (carina) and mainstem bronchi. There is widening of the cranial mediastinum on the ventrodorsal radiograph. There is loss of the normal ventral border of the cranial dorsal mediastinum on the lateral radiographs. These changes are consistent with tracheobronchial and cranial mediastinal lymphadenopathy. The cranial mediastinal lymph node enlargement and mass is noted to encompass the area of the ventral mediastinum on the lateral radiographs cranially. An enlarged sternal lymph node should also be considered to account for part of this abnormal soft tissue opacity.

Close-up right lateral (D) radiograph of the cranioventral thorax. There is an oval soft tissue opacity noted in the ventral and cranial thorax just dorsal to the second and third sternbrae. These changes are consistent with sternal lymph node enlargement.

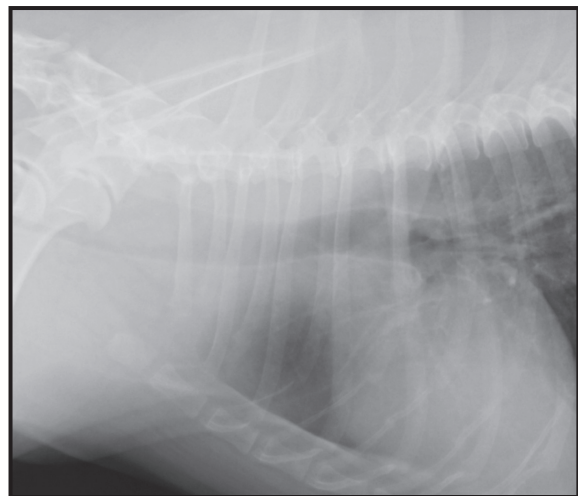


regarded as abnormal if it persists unchanged on multiple films. Heavy sedation and anesthesia frequently cause esophageal dilation so megaesophagus can only be diagnosed in conscious animals. Moderate to severe dilation of the cranial thoracic esophagus will cause a mass effect and displace the trachea in a ventral and rightward position. The apposed esophageal and tracheal walls are seen as a soft tissue stripe if the esophagus is gas filled and may be confused with a pneumomediastinum. But this stripe is thicker than the tracheal stripe. The walls of the caudal esophagus are outlined by luminal gas as two thin soft tissue stripes converging on the esophageal hiatus of the diaphragm , **(Figure 66)**. A fluid filled dilated esophagus does not usually have radiographically discrete margins and appears as an increased opacity in the caudodorsal thorax on the lateral film. A VD or DV view confirms the increased opacity is on midline and prevents confusion with pulmonary pathology. Sharpei breeds will have a redundant esophagus at the thoracic inlet that can be seen without clinical signs and thereby the clinical significance of this finding is not known.

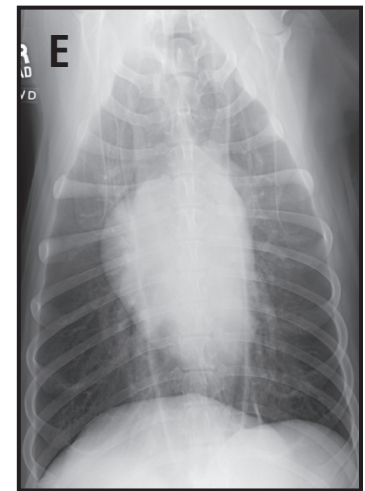
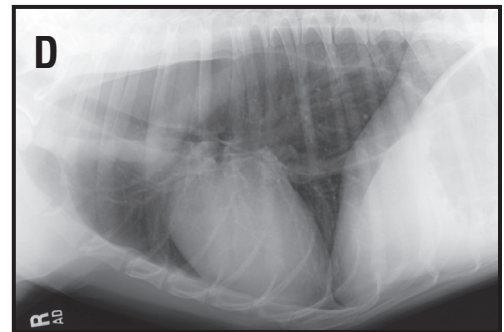
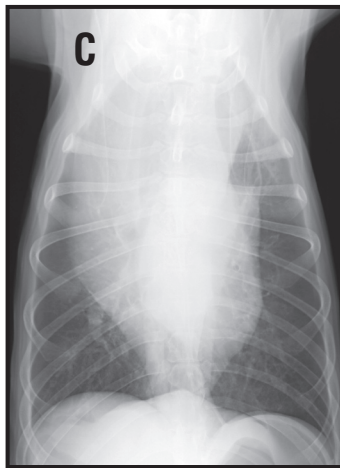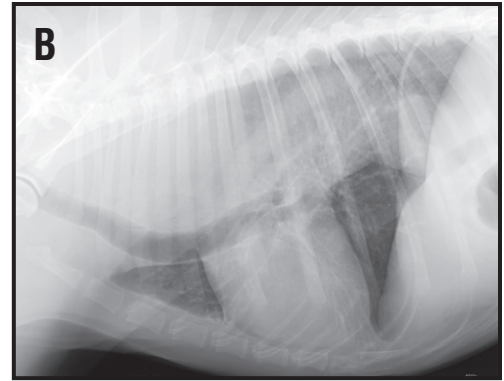
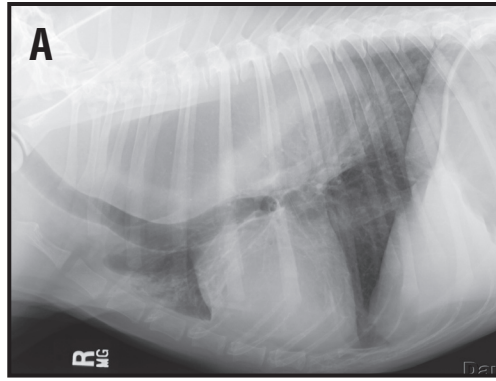
Is the esophagus dilated? It is important to distinguish segmental from generalized megaesophagus, **(Figure 66)**. Dilation of the esophagus cranial to the heart base in immature animals is consistent with a vascular ring anomaly or a cranial/middle mediastinal esophageal stricture, **(Figure 67)**. Acquired segmental megaesophagus is rare but may occur as the result of esophageal stricture formation or secondary to a focal partial obstruction (foreign body or mass). Generalized megaesophagus is diagnosed if the entire esophagus is dilated. It may be congenital or acquired. The list of causes of acquired megaesophagus is too numerous to mention here and the reader is referred to textbooks of small animal medicine for the appropriate work up of dysphagia and regurgitation. Several common causes of acquired generalized megaesophagus may be due to myasthenia gravis, neuromuscular disorders, and primary esophageal disorders (esophagitis, diverticulum or partial/complete obstruction), acetylcholinesterase inhibitors (organophosphate toxicity) or endocrinopathies but is commonly idiopathic. Megaesophagus is often accompanied by aspiration pneumonia that is sometimes best evaluated using right and left lateral radiographs. Careful inspection of the lung parenchyma over the cardiac silhouette is required to visualize the presence of parenchymal abnormalities. However, animals with severe pulmonary disease and dyspnea may exhibit esophageal dilation due to aerophagia, so the presence of esophageal disease can only be accurately assessed when the dyspnea has resolved.

Is there an esophageal foreign body? Is the esophagus perforated? Esophageal foreign bodies are more commonly seen in dogs and only rarely in cats. The common sites for objects to become trapped are the thoracic inlet, heart base and esophageal hiatus, **(Figure 68)**. In cats foreign bodies

**Figure 65.** Lateral radiograph of the cranial thorax and thoracic inlet from a dog. The dorsal and ventral borders of the trachea are clearly visualized. The trachealis muscle is seen folding into the lumen of the trachea created a curving soft tissue opacity superimposed over the dorsal aspect of the trachea at the thoracic inlet. This is called a redundant tracheal membrane.



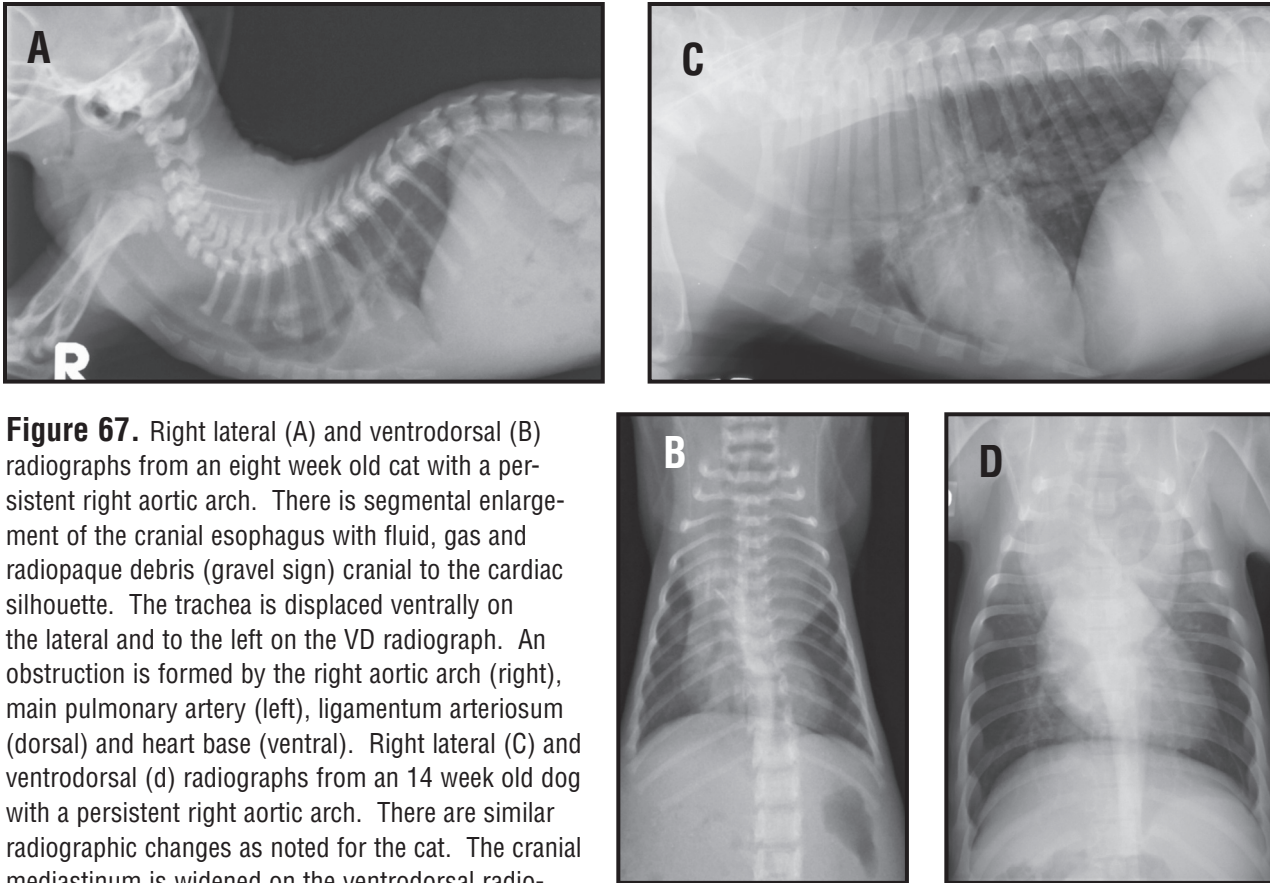
**Figure 66.** Right lateral (A), left lateral (B) and ventrodorsal (C) radiographs from a dog with megaesophagus. The esophagus is abnormally fluid distended. There is widening of the entire dorsal mediastinum noted on the VD radiograph. On the lateral radiograph, there is marked ventral displacement of the trachea and cardiac silhouette. Air bronchograms are seen on the right lateral radiograph cranial to the cardiac silhouette corresponding to an aspiration pneumonia in the left cranial lung lobe. On the left lateral radiograph, air bronchograms are seen in the periphery of the right middle lung lobe superimposed over the ventral cardiac silhouette. Right lateral (D) and ventrodorsal (E) radiographs from a dog with myasthenia gravis and a gas dilated esophagus. There is ventral displacement of the trachea and cardiac silhouette.



may also become trapped at the cricopharyngeal sphincter. Bones are easy to identify but soft tissue opaque objects (cloth material, rubber material) are often overlooked. This is especially true as owners can confuse vomiting with regurgitation thereby directing the clinician's attention to the abdomen. The esophagus is usually dilated cranial to the lesions and gas may outline the foreign object. The mediastinum should be carefully evaluated for evidence of an esophageal perforation. Perforation results in a mediastinitis that is seen as a peri-esophageal accumulation of fluid and mediastinal gas. This may progress to pleural effusion and a pneumothorax.

Is there an esophageal mass? An esophageal mass effect can be seen with foreign bodies, parasitic granulomas or primary esophageal tumors. Differentiation may not be able to be done without an appropriate contrast medium study (esophagram) using a barium sulfate paste, liquid and barium sulfate mixed with food. Esophageal tumors are rare, but can occur, (**Figure 69**). Squamous cell carcinomas and leiomyomas are the more tumors of the esophagus. A tumor can be present at the gastroesophageal junction and may not be seen unless fluoroscopy is used to dynamically evaluate this area. Parasitic granulomas secondary to *Spirocerca lupi* will be seen in the mid thoracic esophagus. These parasites are rare in the United States. Any esophageal mass can cause hypertrophic osteopathy with resulting palisading periosteal reactions along the diaphyses of long bones. The





**Figure 67.** Right lateral (A) and ventrodorsal (B) radiographs from an eight week old cat with a persistent right aortic arch. There is segmental enlargement of the cranial esophagus with fluid, gas and radiopaque debris (gravel sign) cranial to the cardiac silhouette. The trachea is displaced ventrally on the lateral and to the left on the VD radiograph. An obstruction is formed by the right aortic arch (right), main pulmonary artery (left), ligamentum arteriosum (dorsal) and heart base (ventral). Right lateral (C) and ventrodorsal (d) radiographs from an 14 week old dog with a persistent right aortic arch. There are similar radiographic changes as noted for the cat. The cranial mediastinum is widened on the ventrodorsal radiograph. There is segmental dilation of the cranial thoracic esophagus and the trachea is displaced ventrally.

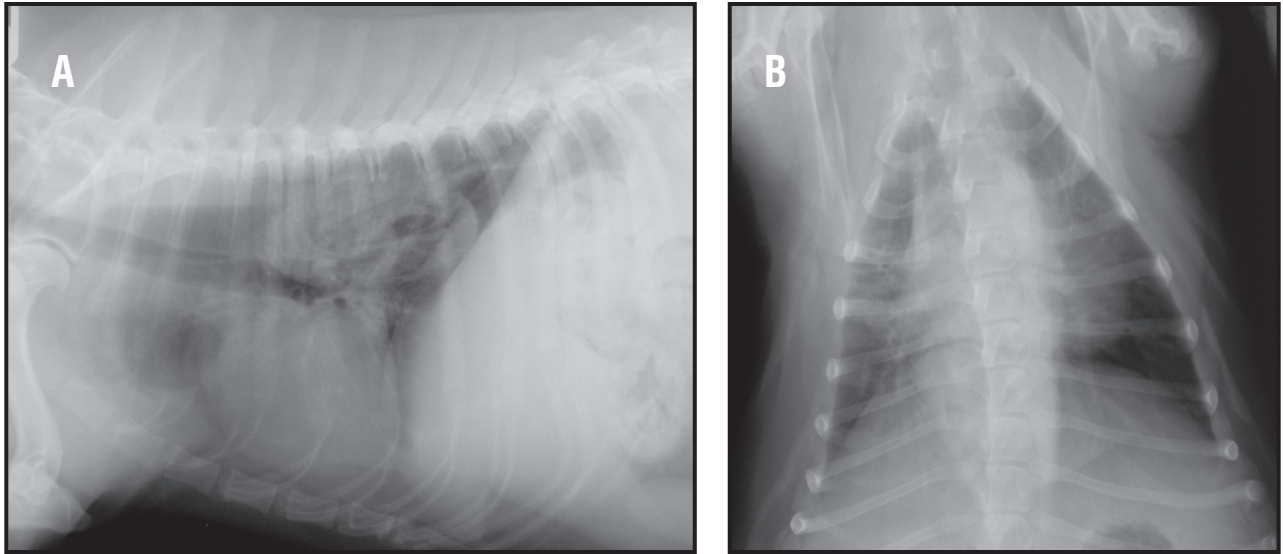
original presentation in these dogs is because of the limb swelling and lameness.

## Trachea

Is the trachea normal? The caudal cervical trachea is usually included on a lateral thoracic radiograph. The trachea can be seen as the radiolucent (gas filled) tube extending from the caudal cervical region through the thoracic inlet and in a dorsal 2/3 position within the cranial thorax. The trachea terminates at the carina, which is the bifurcation of the caudal thoracic trachea into the caudal main-stem bronchi. The normal trachea at the thoracic inlet is between 15 and 20% of the thoracic inlet internal dimension as measured on the lateral radiograph. For bulldogs and other brachycephalic breeds this measurement can approach 12% and still be considered normal.

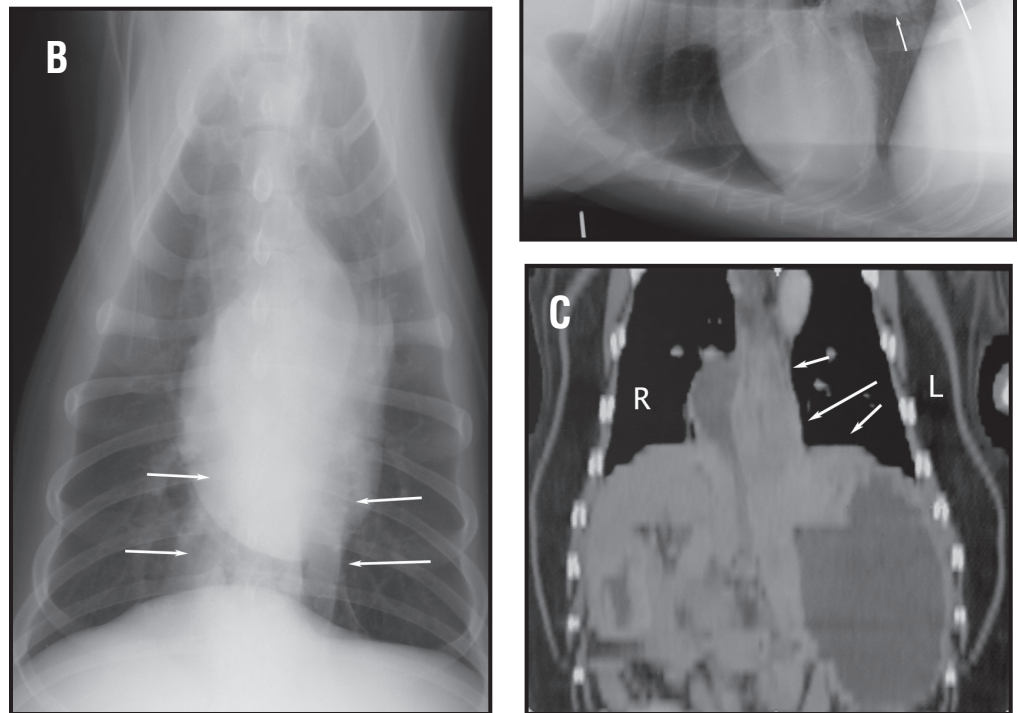
Is the size of the trachea narrow (small luminal diameter)? If the trachea is narrowed is the lesion focal, generalized, fixed or dynamic? A hypoplastic trachea will be seen throughout the length of the cervical and thoracic trachea. A hypoplastic trachea exists if the measured luminal diameter is less than 12% of the thoracic inlet internal measured dimension. Typically dogs with hypoplastic tracheas will present early in life and will have other components of a brachycephalic syndrome.

If a clinical suspicion of tracheal disease exists radiographs of the entire trachea should be obtained during inspiration and expiration. Tracheal collapse is a common clinical entity in small and toy breed dogs, (**Figure 70**). Incompletely formed tracheal rings and a flaccid or redundant tracheal membrane cause narrowing of the lumen. This is usually a dynamic lesion that is it changes with



**Figure 68.** Right lateral (A) and dorsoventral (B) radiographs from a dog with an esophageal foreign body. There is a focal area of ill-defined soft tissue opacity within the esophagus. Gas is noted cranial to and superimposed over this area. There is widening of the caudal mediastinum on the dorsoventral radiograph. A rawhide chew toy was retrieved on endoscopy.

**Figure 69.** Left lateral (A), ventrodorsal (B) radiographs and multi-planar reformatted dorsal plane computed tomographic (CT) image from a dog with an esophageal tumor. There is a focal area of increased soft tissue opacity (white arrows) in the caudal thorax at the level of the esophagus on the lateral radiograph with widening of the caudal mediastinum noted on the ventrodorsal radiograph (white arrows). On the CT image there is a soft tissue dense mass that extends into the cardiac portion of the stomach (white arrows). A distal esophageal adenocarcinoma was diagnosed.

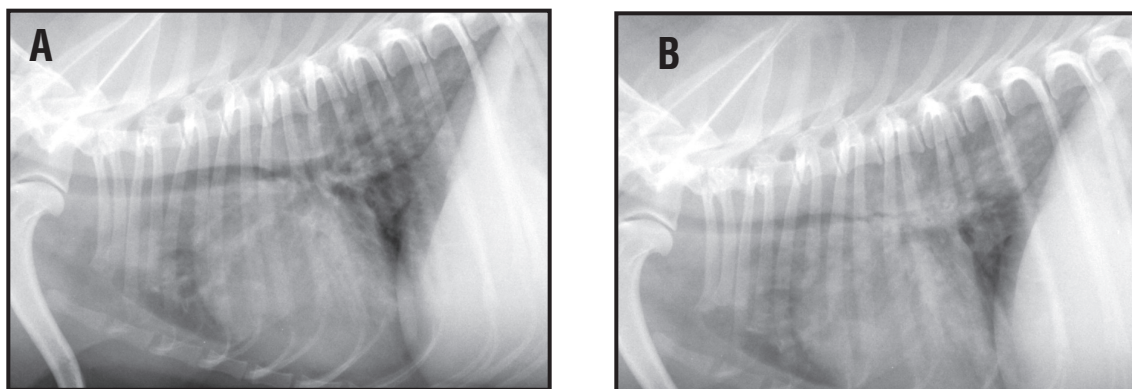


the phase of respiration. On inspiration there is negative pressure within the cervical portion of the trachea and it will collapse or narrow. On expiration, positive pressure within the thorax causes narrowing or collapse of the intrathoracic trachea and in some cases the main stem bronchi. Uniform narrowing of the tracheal lumen is seen in tracheal hypoplasia, especially in brachycephalic breeds. Apparent uniform narrowing of the trachea may be seen in dogs due to hemorrhage caused by intoxication by vitamin K antagonist rodenticides. In these cases, the air shadow of the lumen will be much smaller than the outline of the tracheal rings. A focal fixed narrowing of the trachea is most likely a post-traumatic stricture (**Figure 7**). These are usually located at or just caudal to the thoracic inlet. These lesions are easily overlooked as they are small and may be partly obscured by the overlying shoulder musculature. The stenosis is the result of a traumatic tear of the trachea or overenthusiastic inflation of the cuff of an endotracheal tube.

Is there a mass or nodules within the trachea? Is there a foreign body present? Occasionally tumors arise from the tracheal mucosa and result in mass or nodule formation. Multiple nodules located at the tracheal bifurcation are caused by infestation with the filarial nematode, *Osleris osleri*. Tracheal foreign bodies are rare. Mineral opacity or metallic objects are easy to detect but fragment of wood or leaves are more common and being soft tissue opacity are more difficult to detect.

**Is the trachea displaced (mass effect resulting in tracheal displacement)?**

Displacement of the trachea is a very useful radiographic sign. Dorsal displacement of the cranial thoracic trachea occurs as a result of a cranial mediastinal mass. Keep in mind this appearance can be seen in some dogs, especially if the head is tucked down when the radiograph is taken. Before concluding a mass is present the cranial mediastinum should be evaluated on both radiographic views. Also repeating the lateral radiograph with the dog's neck in an extended position will confirm that the apparent dorsal deviation was secondary to neck flexion (positional) and not a true mediastinal mass. In young dogs with a persistent right aortic arch or other vascular ring anomalies will result in ventral deviation of the trachea on the lateral radiograph. On the VD radiograph the trachea will be displaced toward the left side and can be seen to the left of the vertebrae at the thoracic inlet. A heart base mass may cause dorsal and rightward displacement of the distal trachea while generalized cardiomegaly causes dorsal displacement of the trachea.



**Figure 70.** Right lateral inspiratory (A) and expiratory (B) radiographs from a dog with intrathoracic tracheal collapse. Notice the overall decrease to complete lack of ability to identify the tracheal lumen on the expiratory radiograph (B).

Ventral displacement of the trachea at the level of the carina on the lateral radiograph is usually secondary to either tracheobronchial lymph node enlargement or a dorsal and central pulmonary or mediastinal mass, (**Figure 71**). There are three primary lymph centers associated with the tracheobronchial lymph nodes. Depending on the abnormality, there is one or more of these lymph nodes that will enlarge. The right tracheobronchial lymph node is located between the right cranial lobe bronchus and the trachea. Enlargement of this lymph node will cause lateral and ventral displacement of the right cranial lobar bronchus. The central tracheobronchial lymph node is located between the right and left caudal mainstem bronchi just caudal to the carina. There will be ventral displacement of the carina and caudal mainstem airways as well as widening of the caudal mainstem bronchi when the central tracheobronchial lymph node is enlarged. The left tracheobronchial lymph node is located between the cranial sub-segmental bronchus of the left cranial lung lobe and the trachea. Enlargement of this bronchus will cause ventral and lateral displacement of the associated left cranial lung lobe bronchus. Tracheal displacement is not a reliable radiographic sign if a moderate or large volume of pleural fluid is present. The trachea can appear to be dorsally and caudally displaced in this situation and a cranial mediastinal mass can neither be denied or confirmed. As previously mentioned, erect, horizontal beam radiographs after thoracocentesis may help define the presence of any cranial mediastinal abnormalities.

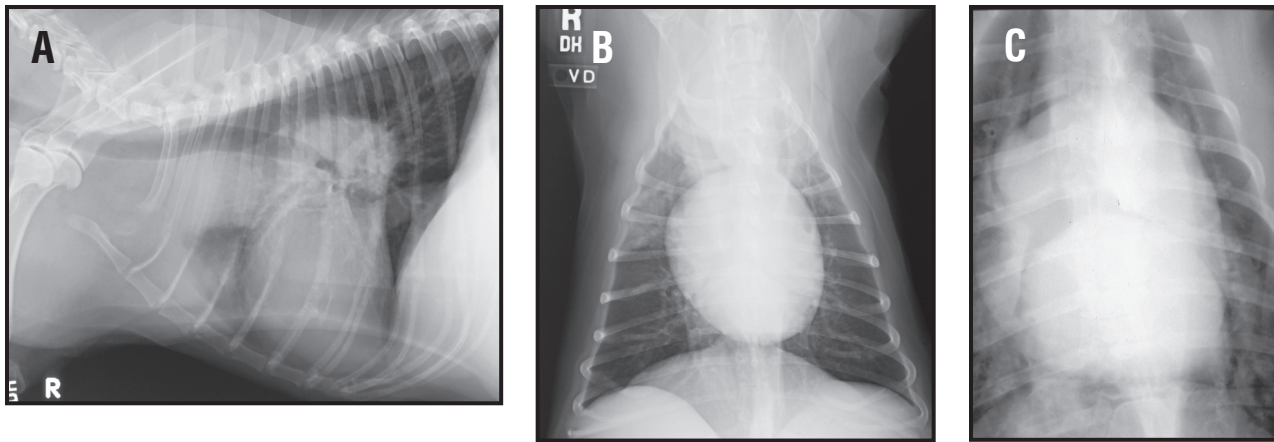
Pulmonary masses can displace the trachea and mainstem airways in any direction depending on the anatomic origin and size of the pulmonary mass. Evaluation of the bronchi for possible mass invasion should be done, as bronchoscopy may then be beneficial for obtaining a diagnosis.

### **Major bronchi**

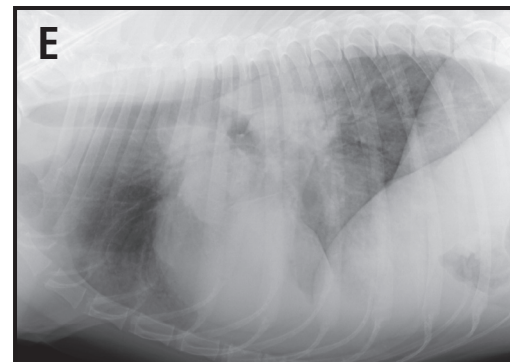
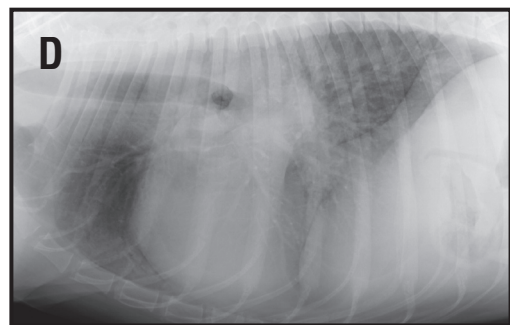
Are the bronchi normal? The major bronchi have walls that are thick enough to be radiographically visible and should not be mistaken for an abnormal bronchial pattern. Each bronchus should be carefully evaluated for evidence of narrowing, enlargement, foreign bodies or displacement. One has to be familiar with the normal bronchial anatomy and origin of each bronchus from the trachea for accurate interpretation. Straight lateral radiographs are required for best evaluation of the lobar bronchi. Lobar bronchi can be typically seen to the level of the second and third generation. Linear mineralizations can be seen within the walls of the trachea and mainstem airways in older geriatric dogs and considered normal. Dystrophic mineralization of the tracheal rings is also an inconsistent finding that is considered normal. This change can also be seen in dogs that have pituitary dependent hyperadrenocorticism. As the bronchi move away from the central trachea, the airways will narrow or converge into the periphery. At times the only indication of where the bronchus is located may be because of the location of the pulmonary artery and vein.

Are the bronchi narrowed? Collapse of the mainstem bronchi during expiration is common in dogs with tracheal collapse. This is an important finding as bronchial collapse is not amenable to surgical correction. In some cases collapse of the bronchi can only be demonstrated by fluoroscopy.

Are the bronchi enlarged? Bronchiectasis is defined as the chronic, abnormal dilation of the bronchi or bronchioles as a sequela of inflammatory lung disease or chronic obstructions associated with pneumonia and heavy mucous secretions. These changes are commonly associated with bronchopneumonia or recurrent lung infections as the ciliary apparatus of the bronchi and trachea is normally abnormal as well. A dilated bronchus can be seen into a lobe that has acute pneumonia, but returns to normal after treatment. In true bronchiectasis, the diameter of the bronchi will not return to normal and in fact may get larger over time. The different types of bronchiectasis include saccular, cylindrical or a mixture of both. These are just anatomic descriptions as to what the abnormally



**Figure 71.** Right lateral (A) and ventrodorsal (B) radiographs from a dog with multicentric lymphoma. There is ventral displacement of the trachea at the level of the carina. Close-up (C) ventrodorsal radiograph from a dog with multicentric lymphoma and severe enlargement of the tracheobronchial lymph nodes. There is tracheal and caudal mainstem airway compression with a “bow-legged” cowboy sign being noted. Right lateral (D) and left lateral (E) radiographs from another dog with lymphoma. There is displacement of the major bronchi away from the hilus area on the lateral radiographs consistent with enlargement of the right, central and left tracheobronchial lymph nodes.



dilated airways look like on radiographs and have nothing to do with the underlying pathophysiology of the disease process. At times the saccular form may appear like a cavitated lung lesion and horizontal beam, sternal recumbency radiographs may be necessary in order to differentiate between these two different radiographic lesions. In young dogs with recurrent infections, hereditary disorders of the ciliary apparatus (ciliary dyskinesia) should be evaluated for using electron microscopy or nuclear medicine studies that are specific for ciliary clearance.

Are the bronchi displaced? Displacement of the mainstem bronchi indicates enlargement of adjacent structures. Left atrial enlargement causes dorsal displacement of the left caudal lobar bronchus and rather than both bronchi being superimposed the bronchi are split on the lateral film. Severe enlargement will cause dorsal displacement of the right caudal lobar bronchus too. On the VD or DV film the caudal lobar bronchi are displaced laterally, resulting in a stirrup like appearance also described as the bowlegged cowboy. Enlargement of the left atrium is most often caused by mitral endocardiosis or dilated cardiomyopathy (DCM) in dogs and hypertrophic cardiomyopathy (HCM) in cats. Similar lateral displacement of the bronchi is seen with tracheobronchial lymph node enlargement. However on the lateral film, enlargement of these lymph nodes causes ventral displacement of the mainstem bronchi. Common causes of tracheobronchial lymph node enlargement include lymphoma, metastasis from primary pulmonary neoplasia, malignant histiocytosis or systemic mycosis.

## **B. The Middle Mediastinum.**

### **The Cardiac Silhouette**

Depending upon the cardiac abnormality radiology can be both highly sensitive and specific in diagnosing specific cardiac disorders. However, radiology can also be extremely insensitive and non-specific for other cardiac disorders. This may seem contradictory but keep in mind that we cannot see internal cardiac chambers, vessels, leaflets, etc. We can, however, extrapolate specific changes in the cardiac chambers from relatively non-specific changes in the overall size and shape of the heart. Radiology is most limited in the diagnosis of congenital heart disease and more useful for evaluating acquired cardiac disease. Although a disease specific diagnosis may not be made, valuable information about the severity of cardiac changes, degree of heart failure and response to therapy can be obtained from radiographs. Serial radiographic examinations over time can also document progression of cardiac changes, chamber enlargement and heart failure.

### **Radiographic Assessment of Cardiac Disease**

There are a series of 5 questions that one should ask oneself when evaluating the cardiac silhouette for abnormality. The answers to these five questions should make sense based on the final diagnosis one makes. It may not be possible to arrive at a specific diagnosis, but render list of potential differentials that could fit the radiographic abnormalities that have been described. The five questions include: Is there any roentgen sign abnormalities associated with the cardiac silhouette? Is there evidence of cardiac enlargement? If so, can it be characterized as right sided, left sided or generalized. Is there any radiographic evidence of heart failure (specifically pulmonary edema or left heart failure and pleural effusion or right heart failure in the dog)? Is there any abnormality of the heart base area with abnormal enlargement of the descending aorta, aortic arch or main pulmonary artery segment on the VD/DV radiograph (must be positioned straight!!)? Is there any radiographic evidence of pulmonary overcirculation or undercirculation or are there asymmetric changes associated with lobar pulmonary arteries and veins.

Each of these questions will be broken down and further reviewed in the following discussion. Remember that because of the tremendous breed variation in the dog, it is difficult to arrive at a basic formula for say confidently on every radiograph that the cardiac silhouette is normal or abnormal or even enlarged.

Based on the position of the heart, where is the apex located on the lateral and the VD/DV radiograph? The apex is the best external cardiac landmark that documents the division between the left and right sides of the cardiac silhouette. Remember though that the external structure that one is looking at is really the outer border of the pericardial lining and not the epicardial surface of the heart. Locating the apex is necessary to determine if the left or right side of the heart is enlarged, **(Figure 72)**. On the VD radiograph, the apex of the heart is can be determined by using the caudoventral mediastinal reflection. This reflection is located between the apex of the cardiac silhouette and the caudal left ventral aspect of the diaphragm. The apex of the cardiac silhouette is seen along the caudoventral aspect of the heart on the right lateral radiograph. On the left lateral radiograph, the cardiac silhouette shifts dorsal and lateral and the cardiac apex cannot be identified. Severe left-sided cardiomegaly may cause rightward displacement of the apex on VD or DV films and mimic the appearance of right-sided cardiomegaly. On right lateral radiograph, severe right-sided cardiomegaly will lift the apex off the sternum. On VD films leftward deviation of the apex may occur with right-sided cardiomegaly.

Is the overall cardiac size normal, reduced or enlarged? The size of a normal cardiac silhouette will vary considerably with breed and conformation in dogs and with age in cats. Additionally, since one is evaluating a disease process, the size of the cardiac silhouette will be dependent upon the specific etiology and the previous course of the disease. For example, a heart that is 3.5 intercostal spaces wide on a lateral radiograph would be quite normal in a Golden Retriever but enlarged in a Doberman Pinscher. A reduced cardiac size is usually the result of a depleted circulating volume (**Figure 26A and 26B**). Dehydration, hemorrhage and Addison's disease are common causes of this appearance. Microcardia may or may not be accompanied by a hyperlucent appearance to the lung and small pulmonary vessels.

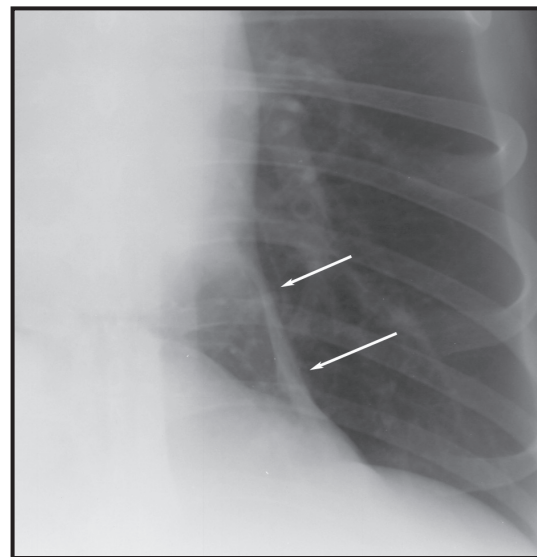
Are any specific chambers or great vessels enlarged? Specific cardiac chambers and great vessels cannot be identified as such on radiographs but form specific portion of the cardiac outline (**Figure 73**). The outline of the heart is treated as a clock face and bulges or bumps described based on this clock analogy.

Left atrial enlargement in dogs is seen as a triangular bulge at the caudodorsal aspect of the heart on the lateral film (**Figure 74**). In cats the enlarged left atrium appears as a rounded bulge in the same location, altering the normal lemon like shape of the heart to kidney bean shaped, (**Figure 75**). Left atrial enlargement causes elevation and sometimes compression of the left caudal stem bronchus and if severe the right also. On the VD, the enlarged left atrium spreads the mainstem bronchi, the "bowlegged cowboy" sign, and may result in a double edge at the caudal border of the heart silhouette (6 o'clock). In severe enlargement, the left atrial appendage is seen as a bulge on the left lateral border of the heart (3 o'clock) on the VD/DV radiograph.

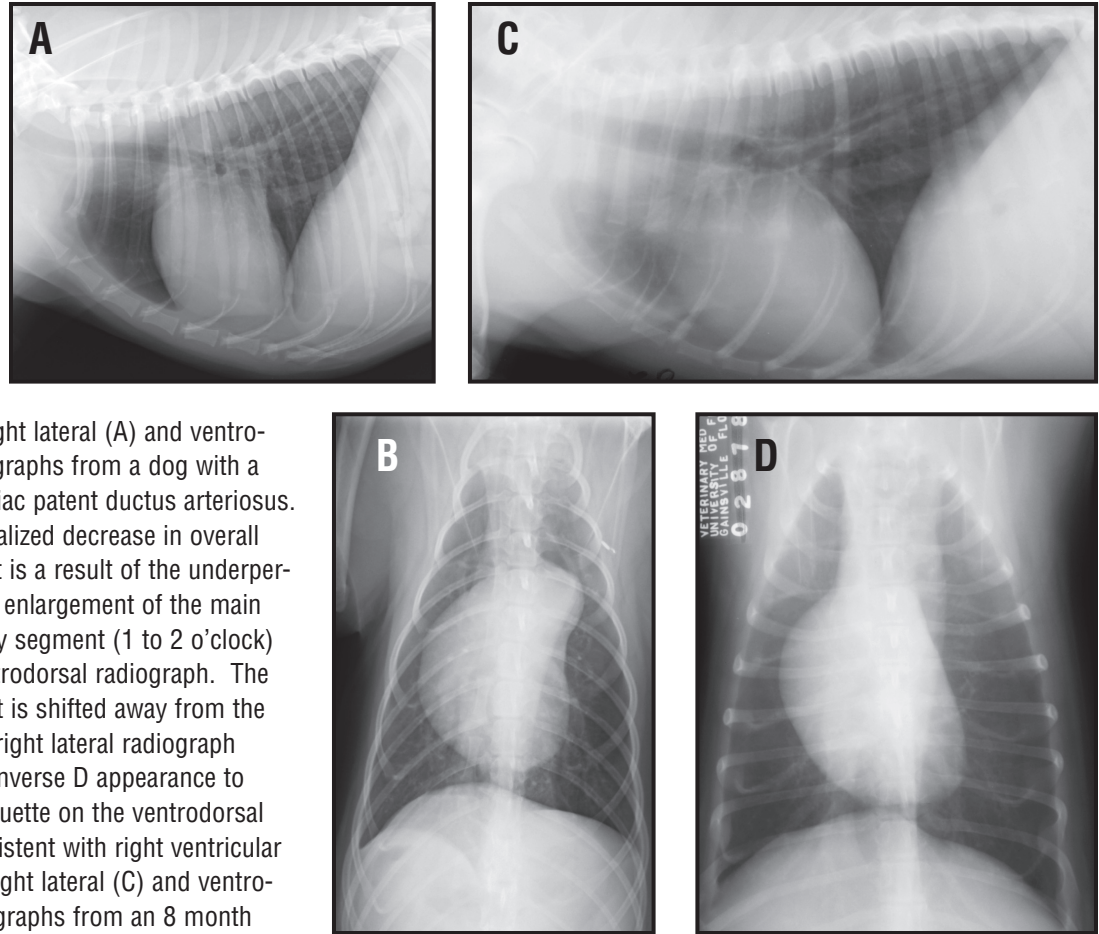
Left ventricular enlargement results in straightening on the caudal cardiac border on the lateral film and an elongated heart on the VD. On the VD, the left heart border bulges and is closer to the thoracic wall than normal. The cardiac apex may be shifted to the right creating the impression of right cardiomegaly, so before deciding if an enlargement is left or right sided, always located the apex. Left ventricular hypertrophy is usually concentric (hypertrophic cardiomyopathy in cats, sub-aortic stenosis in dogs) and may produce minimal radiographic change in the size and shape of the heart unless the left atrium is enlarged or myocardial failure has occurred resulting in ventricular dilation.

Right atrial enlargement is rare as a discrete change with the exception of hypertrophic cardiomyopathy in the cat and tricuspid dysplasia in dogs or cats, (**Figure 77**). It is seen as expansion and rounding of the cranial cardiac border just ventral to the trachea on the lateral film and a bulge on the right cranial heart border on the VD (9 - 11 o'clock).

Right ventricular enlargement results in rounding and cranial expansion of the cranial cardiac border on the lateral film and rounding of the right cardiac border



**Figure 72.** Close-up ventrodorsal radiograph of the caudal left thorax from a dog. The ventral mediastinal reflection (white arrows) extends from the apex of the cardiac silhouette caudally and laterally to insert on the diaphragm.



**Figure 73.** Right lateral (A) and ventrodorsal (B) radiographs from a dog with a right to left cardiac patent ductus arteriosus. There is a generalized decrease in overall lung opacity that is a result of the underperfusion. There is enlargement of the main pulmonary artery segment (1 to 2 o'clock) seen on the ventrodorsal radiograph. The apex of the heart is shifted away from the sternum on the right lateral radiograph and there is an inverse D appearance to the cardiac silhouette on the ventrodorsal radiograph consistent with right ventricular enlargement. Right lateral (C) and ventrodorsal (D) radiographs from an 8 month old dog with generalized cyanosis. There is relatively mild right-sided cardiomegaly and a dramatic undercirculation of all lung fields. This is secondary to a tetralogy of Fallot. The four components of a tetralogy include: right ventricular hypertrophy, a right to left ventricular septal defect, pulmonic stenosis and an overriding aorta. A non-selective angiogram would have confirmed this diagnosis.

which is closer to the thoracic wall than normal on the VD film (**Figure 78**). In some cases this produces the reverse D appearance on VD or DV radiographs.

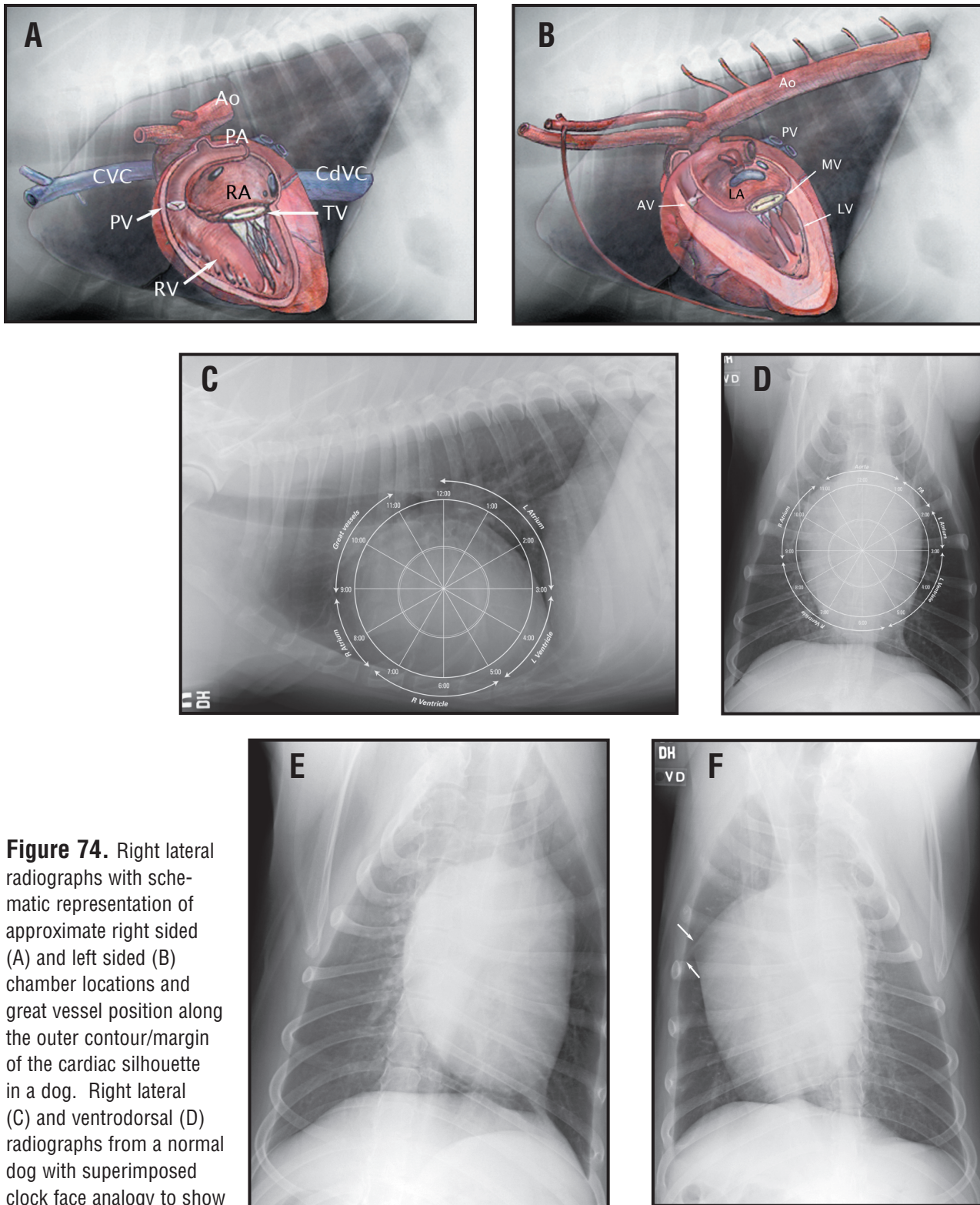
Aortic enlargement is seen as a bulge at the cranial aspect of the heart which blends with the cranial mediastinum on the lateral and a rounded “cap” on the cranial border of the heart on midline of the VD (**12 o'clock, Figure 79**).

An enlarged main pulmonary artery may be seen as an increased opacity just cranial to the tracheal bifurcation on the lateral film when enlarged and a bulge at the left cranial border of the heart on the VD (**1-2 o'clock, Figure 78**).

The size of the caudal vena cava varies considerably with the phases of the cardiac and respiratory cycles but it has been shown not to exceed the diameter of the descending aorta within the dog or cat being evaluated.

Are the pulmonary vessels small, normal or enlarged? Normal pulmonary arteries and veins should be approximately the same size. The cranial lobar vessels are assessed on the lateral film, where the artery is the more cranial and dorsal of the pair. The caudal lobar vessels are assessed on a VD or preferably DV film where the artery is the lateral vessel and the vein lies medially. An objec-

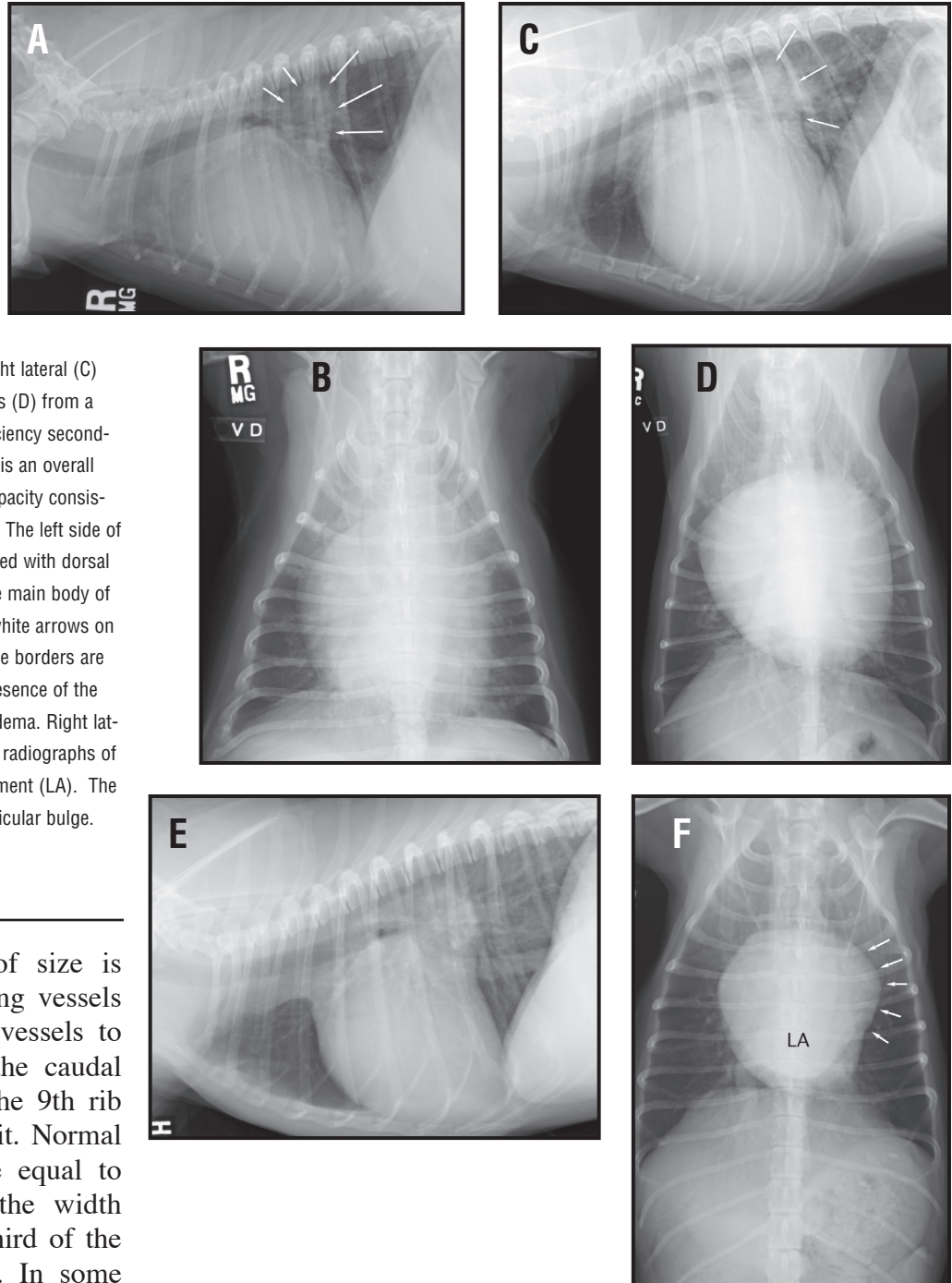




**Figure 74.** Right lateral radiographs with schematic representation of approximate right sided (A) and left sided (B) chamber locations and great vessel position along the outer contour/margin of the cardiac silhouette in a dog. Right lateral (C) and ventrodorsal (D) radiographs from a normal dog with superimposed clock face analogy to show relative positions for the great vessels and the cardiac chambers. Oblique ventrodorsal radiographs (E and F). In Figure 74E, the sternum is oblique to the left of midline and the main pulmonary artery is artifactually enlarged. Any right sided cardiac changes will be minimized. In Figure 74F, the sternum is oblique to the right and the right atrial area is artifactually enlarged. There is fat noted in the ventral fissure between the right cranial and right middle lung lobes (white arrows). Left sided cardiac enlargement and changes in the great vessels will not be adequately assessed.

## Thoracic Radiology

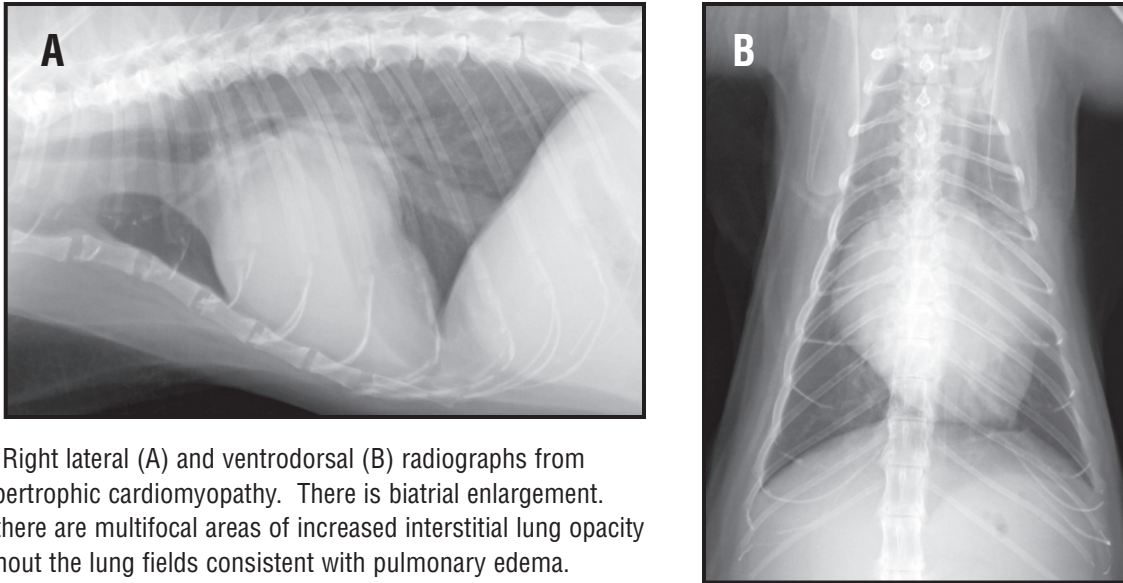
**Figure 75.** Right lateral (A) and ventrodorsal (B) radiographs from a dog with mitral valvular insufficiency secondary to endocardiosis. There is marked enlargement of the left atrium (white arrows, 12 to 3 o'clock) on the right lateral radiograph causing dorsal elevation of the trachea. Right lateral (C) and ventrodorsal radiographs (D) from a dog with mitral valve insufficiency secondary to endocardiosis. There is an overall increase in interstitial lung opacity consistent with pulmonary edema. The left side of the heart is markedly enlarged with dorsal elevation of the trachea. The main body of the left atrium is enlarged (white arrows on the lateral radiograph) but the borders are poorly defined due to the presence of the hilar or central pulmonary edema. Right lateral (E) and ventrodorsal (F) radiographs of a dog with left atrial enlargement (LA). The arrows point to the left auricular bulge.



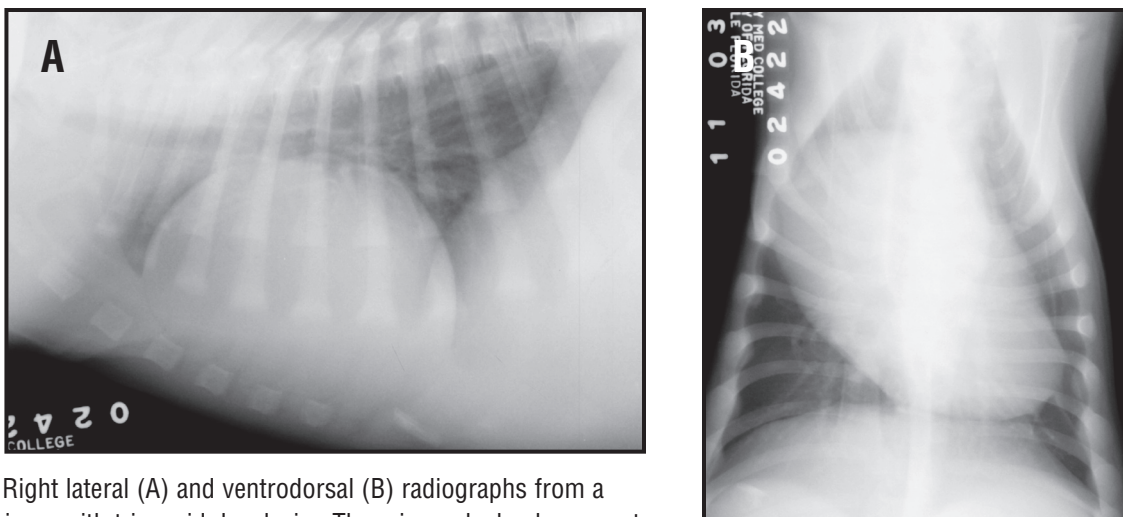
tive assessment of size is made by comparing vessels the cranial lobar vessels to the 4th rib and the caudal lobar vessels to the 9th rib where they cross it. Normal vessels should be equal to or smaller than the width of the proximal third of the corresponding rib. In some

cases, especially congenital shunt lesions, there may be an increase in number of radiographically visible pulmonary vessels rather than enlargement of the hilar and mid zone portions of the vessels. In such cases, examination of the periphery and mid zones reveals an increased number of small vascular markings or a moderate to severe unstructured or reticular (honeycomb like) interstitial pattern. This is true for left to right shunting lesions such as a patent ductus arteriosus or a ventricular septal defect.

Is there evidence of Left Heart Failure (pulmonary edema in dogs)? Pulmonary venous enlargement is an early indicator of elevated left ventricular and left atrial diastolic pressures. As the left atrial pressure increases, the amount of fluid retention within the interstitial space will increase. This will



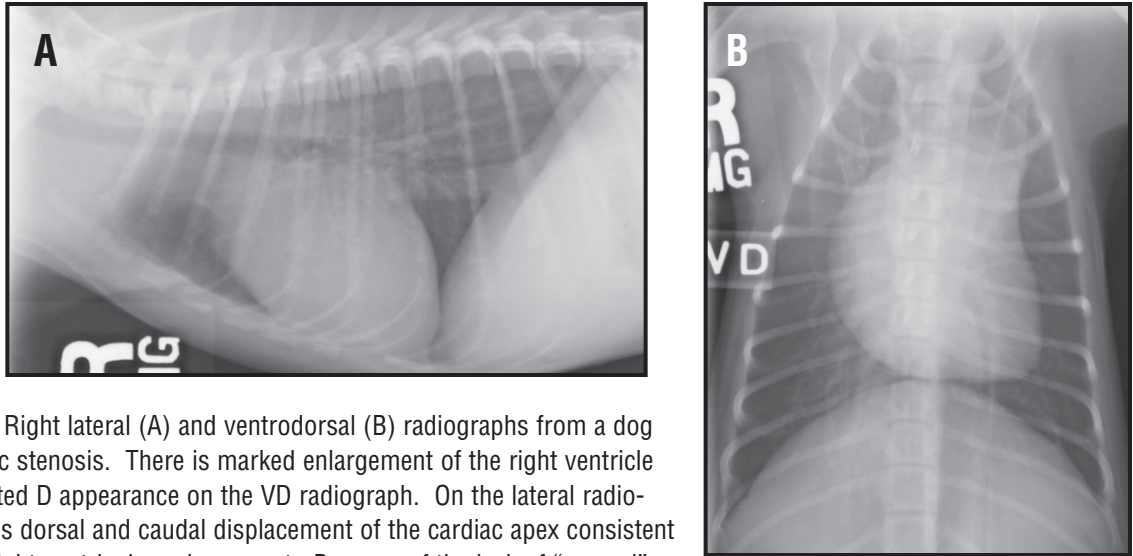
**Figure 76.** Right lateral (A) and ventrodorsal (B) radiographs from a cat with hypertrophic cardiomyopathy. There is biatrial enlargement. Additionally, there are multifocal areas of increased interstitial lung opacity noted throughout the lung fields consistent with pulmonary edema.



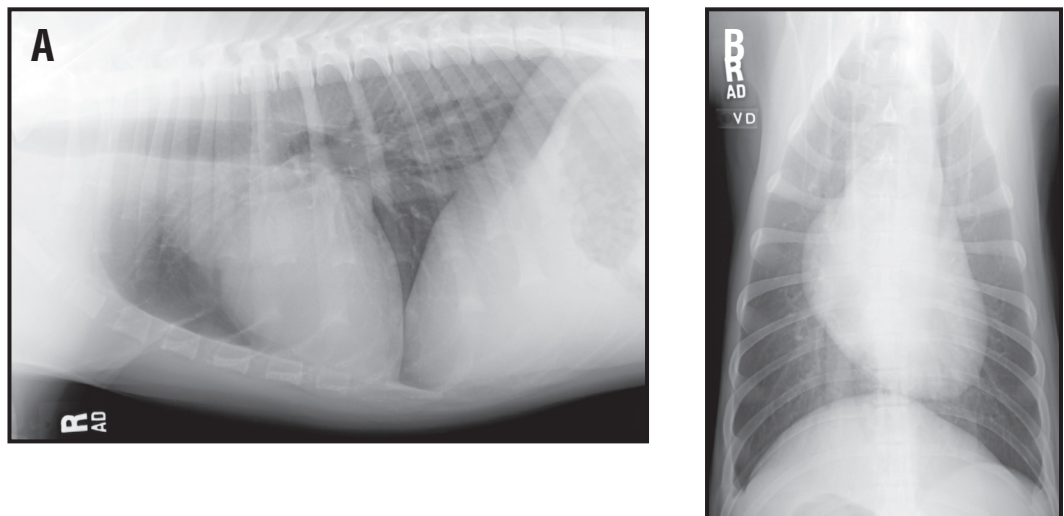
**Figure 77.** Right lateral (A) and ventrodorsal (B) radiographs from a Labrador Retriever with tricuspid dysplasia. There is marked enlargement of the right atrium and auricle seen on both radiographic views. On the lateral radiograph the cardiac silhouette has a rounded appearance. On the ventrodorsal radiograph the primary enlargement is seen between 8 and 11 o'clock (right atrium) causing a leftward shift of the cardiac apex in the left thorax.

result increased pulmonary opacity. As the interstitial edema progresses there will be flooding of the alveoli and an alveolar lung pattern can be seen. In dogs with chronic endocardiosis that acutely decompensate, a right caudal lung lobe distribution may be apparent, (**Figure 80**). In our experience (although this has not been scientifically proven) dogs on chronic cardiac medications (enalapril and lasix) will have normal or small sized pulmonary veins, even when there is radiographic evidence of pulmonary edema.

Is there pleural fluid, hepatosplenomegaly or ascites? Right-sided congestive heart failure typically will result in caudal vena caval enlargement, hepatosplenomegaly and ascites prior to pleural effusion in the dog. In the cat, congestive heart failure can result in strictly pulmonary edema, pleural



**Figure 78.** Right lateral (A) and ventrodorsal (B) radiographs from a dog with pulmonic stenosis. There is marked enlargement of the right ventricle with an inverted D appearance on the VD radiograph. On the lateral radiograph, there is dorsal and caudal displacement of the cardiac apex consistent with severe right ventricular enlargement. Because of the lack of “normal” definition and breed variations, we do not use the term sternal contact when describing right ventricular enlargement in small animals. There is enlargement of the main pulmonary artery segment on the VD radiograph at the 1 to 2 o'clock position. In addition the lung fields are hyperlucent due to the undercirculation created by the pulmonic stenosis.



**Figure 79:**

Right lateral (A) and ventrodorsal (B) radiographs from a dog with sub-aortic stenosis. On the VD radiograph the heart is elongated. There is widening of the cranial mediastinum at the level of the heart base on the VD radiograph due to post stenotic dilation of the ascending aorta and aortic arch. There is enlargement of the cranial and dorsal part (10 – 12 o'clock) portion of the cardiac silhouette on the right lateral radiograph caused by the post stenotic dilation of the ascending aorta and aortic arch.

effusion or a combination of both. Usually ascites is a late feature of chronic cardiac decompensation in the cat.

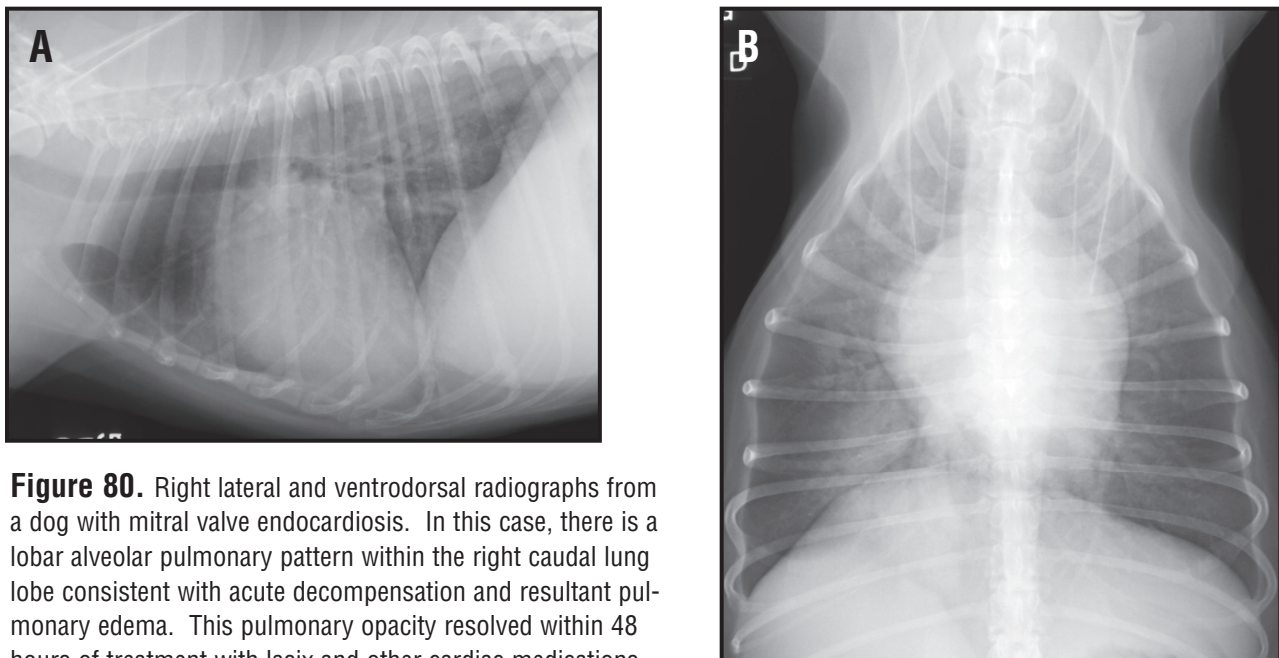
Remember that the diagnosis of right-sided or left-sided congestive heart failure is a syndrome and is not a specific clinical diagnosis. The presence of right or left sided congestive heart failure is used to formulate a differential diagnosis for the other radiographic abnormalities that are present.

## Differential diagnosis of cardiac disease

Formulating a differential diagnosis is simplified by considering heart disease as either acquired or congenital. Generally animals with signs of cardiac disease and aged under 5 years are more likely to have a congenital lesion, (**Table 8**). However, acquired diseases such as dilated and hypertrophic cardiomyopathy and heartworm disease occur in young animals.

Congenital cardiac disease may be classified into four major categories, which include: valvular stenotic lesions; valvular incompetence (atrioventricular dysplasias) lesions; shunting lesions; and complex congenital lesions that include combinations of these basic defects. A review of cardiac embryology is beyond the scope of these notes, but a basic understanding is needed in order to try to understand and evaluate dogs or cats with congenital heart defects. Echocardiography (including Doppler and Color flow imaging) and possibly angiocardiology may be required in order to fully define the extent and severity of the congenital defect. If right to left intracardiac lesions are suspected, the use of contrast (saline bubble) echocardiography can be useful. In small dogs and in cats, non-selective angiography is useful for the evaluation of right-sided lesions (atrioventricular dysplasia or pulmonic stenosis or complex lesions such as a tetralogy of Fallot).

Stenotic lesions most commonly affect the aortic or pulmonic valves. The outflow tract may be narrowed below the valve (sub-aortic stenosis most common), at the valve (valvular pulmonic stenosis most common), or distal to the valve (supravalvular lesion). The narrowing causes increased resistance to ventricular output resulting in concentric myocardial hypertrophy. Concentric hypertrophy may cause little alteration of the size and shape of the left ventricle. The right ventricle tends to become rounded, causing a rounded bulging right cardiac border on both lateral and VD films. The high-speed jet of blood pushed through the stenosis results in post stenotic dilation secondary of the artery just distal to the lesion to turbulence. Enlargement of the main pulmonary artery is best seen on the VD or DV film at the left cranial aspect of the cardiac silhouette (1-2 o'clock). Moderate or severe pulmonic stenosis can cause a reduction in size of the pulmonary vessels. Enlargement of the aortic arch and ascending aorta can be seen as a bulge on the cranial aspect of the heart on the lateral VD films (12 o'clock). If severe, this dilation will create the impression of an elongated



**Figure 80.** Right lateral and ventrodorsal radiographs from a dog with mitral valve endocardiosis. In this case, there is a lobar alveolar pulmonary pattern within the right caudal lung lobe consistent with acute decompensation and resultant pulmonary edema. This pulmonary opacity resolved within 48 hours of treatment with lasix and other cardiac medications.

**Table 8: Summary of Congenital Heart Disease.**

DISEASE	PATHO-PHYSIOLOGY	CARDIOMEGALY	AORTA/MPA ENLARGEMENT	CONGESTIVE HEART FAILURE	PULMONARY VESSELS
<b>SHUNTS</b>					
<b>Left to Right PDA</b>	Over-circulation of left heart and pulmonary circulation	LAE/LVE	Enlarged Aorta (descending) and main pulmonary artery	± Left Heart Failure	Both PA and PV enlarged (overcirculation)
<b>Right to Left PDA</b>	Pulmonary Hypertension	RVE (hypertrophy)	Enlarged Aorta (descending) and main pulmonary artery	± Right Heart Failure	Enlarged centrally but truncate and taper peripherally
<b>Left to Right VSD</b>	Over-circulation of left heart and pulmonary circulation	LAE/LVE	Normal	± Left Heart Failure	Both PA and PV enlarged (overcirculation)
<b>STENOSIS</b>					
<b>Pulmonic Stenosis (Valvular)</b>	Pressure overload (right heart)	Right ventricular hypertrophy	Enlarged main pulmonary artery	± Right Heart Failure	Normal to undercirculated
<b>Aortic Stenosis (sub-valvular)</b>	Pressure overload (left heart)	LVE (concentric hypertrophy, ± left atrial enlargement)	Widened Aortic Arch	± Left Heart Failure	Normal
<b>DYSPLASIAS</b>					
<b>Mitral valve Dysplasia</b>	Volume overload of the left heart	LAE and LVE	Normal	LHF	PV>PA or both enlarged
<b>Tricuspid valve Dysplasia</b>	Volume overload of the right heart	RAE and RVE	Normal	RHF	Normal
<b>COMBINATION DEFECT:</b>					
<b>Tetralogy of Fallot</b>	R to L VSD Pulmonic Stenosis RVH Over-riding aorta	“Boot” shaped heart ± RVH	± MPA	± RVH	Undercirculated
<b>PPDH ± other cardiac defects</b>	Failure of normal diaphragmatic development	Cardiomegaly (± change in intrapericardial opacities)	Normal	Normal	Normal

LHE = left heart enlargement (includes Left atrium and ventricle); LHF = left heart failure (pulmonary edema); RHF = right heart failure (pleural effusion); RHE = right heart enlargement; PV>PA = pulmonary veins are bigger than pulmonary arteries; PPDH = peritoneopericardial diaphragmatic hernia; PDA = patent ductus arteriosus; LAE = left atrial enlargement; LVE = left ventricular enlargement; PV = pulmonary vein; RVE = right ventricular enlargement; RAE = right atrial enlargement; MPA = main pulmonary artery; and RVH = right ventricular hypertrophy.

cardiac shadow on the VD or DV film.

Valvular incompetence occurs due to dysplasia of the atrioventricular valves. This is a common anomaly in cats and may affect either or both the mitral or tricuspid valves. Moderate to severe atrial enlargement develops due to regurgitation of blood from the ventricle during systole. Myocardial failure ensues and severe generalized cardiomegaly is seen radiographically. These lesions are usually severe and significant cardiomegaly and failure occurs in quite young animals.

Intra or extra cardiac left-to-right shunting lesions are the result of a persistence of a portion of the fetal circulation (patent ductus arteriosus, PDA) or maldevelopment of cardiac structures (atrial and ventricular septal defects). Flow through the shunt is from left to right unless severe pulmonary hypertension exists. The radiographic changes in the heart are variable and nonspecific. Classically, a left to right PDA will result in enlargement of the descending aortic arch (ductus diverticulum), the main pulmonary artery and the left atrial appendage. If all three are present the three bulges results in the “three knuckle sign” on the VD or DV radiograph but more commonly only one or both of the great arteries is enlarged. Septal defects may exhibit no radiographic abnormalities if the shunt is small or nonspecific changes. The best indicator of the presence of a shunt lesion is pulmonary overcirculation seen as symmetrical enlargement of the pulmonary arteries and veins, an increased number of small vascular markings in the peripheral lung fields and a diffuse unstructured interstitial pattern.

Complex lesions can be challenging and may not be amenable to diagnosis from survey radiographs. One of the more common lesions is the tetralogy of Fallot, which is a combination of pulmonic stenosis, right ventricular hypertrophy, ventricular septal defect and overriding aorta. This combination of lesions may result in quite variable radiographic signs depending upon the severity of the anomalies. It is principally of interest as it may mimic an uncomplicated pulmonic stenosis.

### Differential diagnosis of acquired cardiac disease

When evaluating radiographs for suspected acquired cardiac disease the same standard interpretation paradigm, (**Table 9**). The signalment of the patient is potentially helpful for formulating a reasonable differential diagnosis list. Valvular incompetence due to endocardiosis is most commonly a clinically significant lesion in older toy and small breed dogs. Both atrioventricular valves are affected but the mitral valve lesion is the one that typically produces clinical signs. As valvular incompetence worsens left atrial enlargement develops. This may cause a cough at night due to pressure on the left caudal lobar bronchus before any radiographic signs of failure are seen. The disease progresses to left ventricular dilation as the myocardium fails and pulmonary venous congestion and edema are seen in decompensated cases. Cardiogenic pulmonary edema due to mitral endocardiosis is first visible in the hilar zone of the lungs and spreads to the periphery. Rarely, edema may affect the right caudal lung lobe only. Tricuspid endocardiosis seldom causes purely right-sided cardiac failure but this is seen in late stage left side disease.

Acquired left sided cardiac disease in large and giant breed dogs is usually cause by dilated cardiomyopathy (DCM). The heart size may range from normal to severe generalized cardiomegaly (**Figure 81**). Cardiogenic edema is common and may have a rapid onset and is often quite severe. The distribution may be similar to that seen in mitral endocardiosis but often has a diffuse interstitial location or a caudodorsal interstitial and alveolar pulmonary appearance. Acute onset myocardial failure from mitral valve endocardiosis can result in a localized to the right caudal lung lobe.

The most common acquired cardiac disease of cats is hypertrophic cardiomyopathy (HCM). Radiographic changes include mild to severe left atrial enlargement and mild to moderate right atrial enlargement (**Figure 82**). Biatrial enlargement is seen as bulges at the right craniolateral (10 o'clock) and left borders (3 o'clock) of the heart on the VD or DV film that is described as having a "valentine heart" appearance. There is usually no alteration in the left ventricle's size or shape. Radiographic evidence of failure includes pulmonary venous congestion that is best appreciated in the hilar zone on the lateral film. Pulmonary edema appears as unstructured interstitial, alveolar or mixed patterns with a patchy random or perivascular distribution. Pleural effusion can be seen by itself or in combination with pulmonary edema when cats present in congestive heart failure.

Infestation by the heartworm *Dirofilaria immitis* occurs in both dogs and cats. Clinically normal or minimally affected animals usually have no appreciable radiographic changes. The mildest abnormalities which may be detected are enlargement of the mid and peripheral zone portions of the caudal lobar pulmonary arteries. Larger parasite burdens cause right sided cardiomegaly, main pulmonary artery enlargement and enlargement and tortuosity of the pulmonary arteries. Pulmonary infiltrate with eosinophilia (PIE) is a common allergic response to the heartworms (**Figure 83**). The radiographic features of PIE include a moderate to severe unstructured interstitial pattern, moderate to severe bronchial pattern and rarely interstitial nodules. This pattern may make it difficult to see the enlarged pulmonary arteries. PIE may also occur with a small parasite load with no cardiac or vascular changes.

Pulmonary thrombo-embolism (PTE) is a possible complication to heartworm infestation especially following adulticide treatment. Although HWD is the most common cause of PTE but it also occurs with many other diseases that result in hypercoagulable states and disseminated intravascular coagulation, (**Figure 84**). The disease has a range of radiographic appearance. Radiographs may be completely normal which may explain why this disease is diagnosed more frequently post mortem than in the live patient. Radiographic abnormalities associated with PTE can include: focal or lobar hyperlucency due to absence of blood flow, focal pleural effusion or lobar alveolar lung patterns. Additionally, focal alveolar patterns are located at the periphery of the lungs and are wedge shaped in appearance with the apex of the lesion pointing toward the hilus while the base towards the pleural surface. Truncation (abrupt termination, or pruning) is the absence of normal branching of the peripheral pulmonary arteries. These changes are consistent with regional oligemia, (**Figure 85**). Definitive diagnosis of PTE is difficult and often requires tests such as selective pulmonary arteriography, pulmonary perfusion scintigraphy or computed tomography angiography.

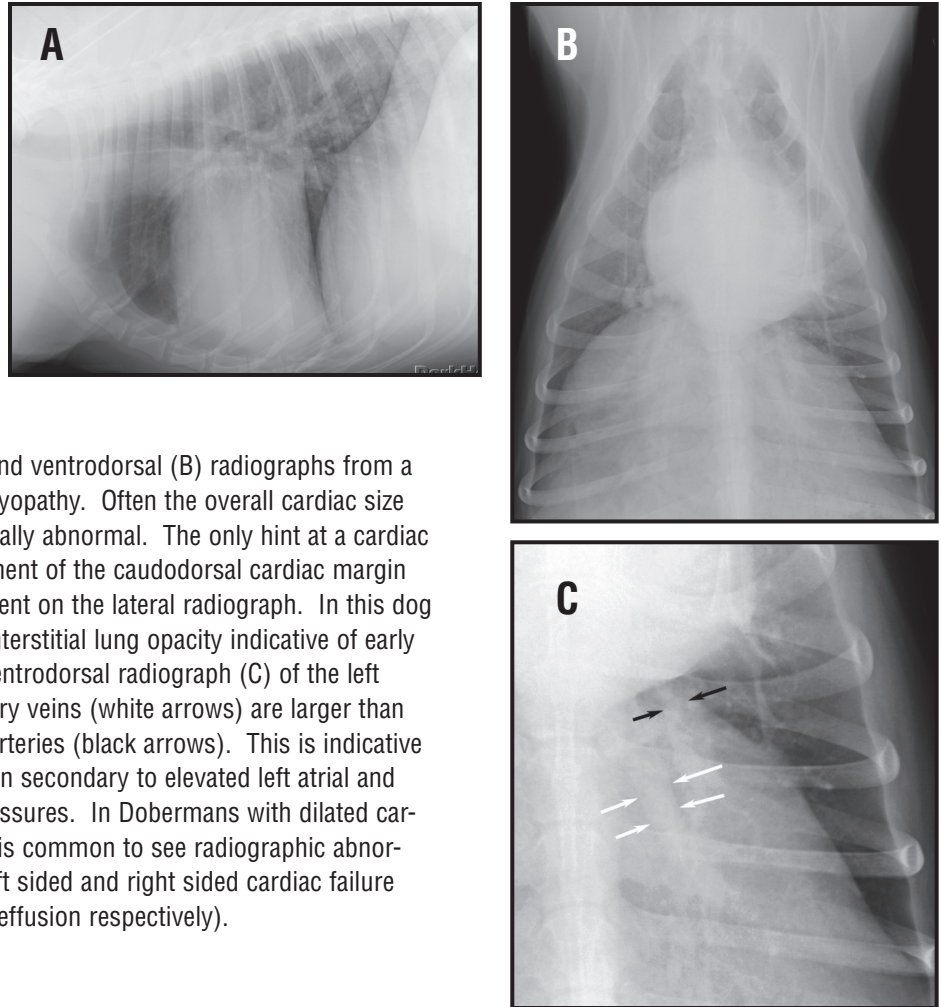
Pericardial Effusion. Accumulation of fluid within the pericardial sac may occur secondary to neoplasia, infection, and hemorrhage. However in some cases an underlying cause cannot be found (idiopathic). In pericardial effusions, the cardiac silhouette will become enlargement without specific vessel or chamber enlargement, (**Figure 86**). The result is often a severe enlargement has been described as basketball or pumpkin like. DCM or atrioventricular valve dysplasia can cause similar severe enlargement. One characteristic feature is a very smooth arcing curve forming the caudodorsal border of the heart on the lateral film. Pericardial effusion results in right heart failure and pleural fluid accumulation that may partly obscure the outline of the heart. Congenital peritoneopericardial hernias may mimic pericardial effusion. The lack of normal development of the diaphragm results in a continuum between the pericardial and peritoneal cavities allows abdominal organs to pass into the pericardium. These hernias are often clinically silent and are discovered by accident. The cardiac silhouette is severely enlarged, abnormally shaped, and of can be of inhomogeneous opacity due to the presence of omental and mesenteric fat and gas filled small intestinal loops if



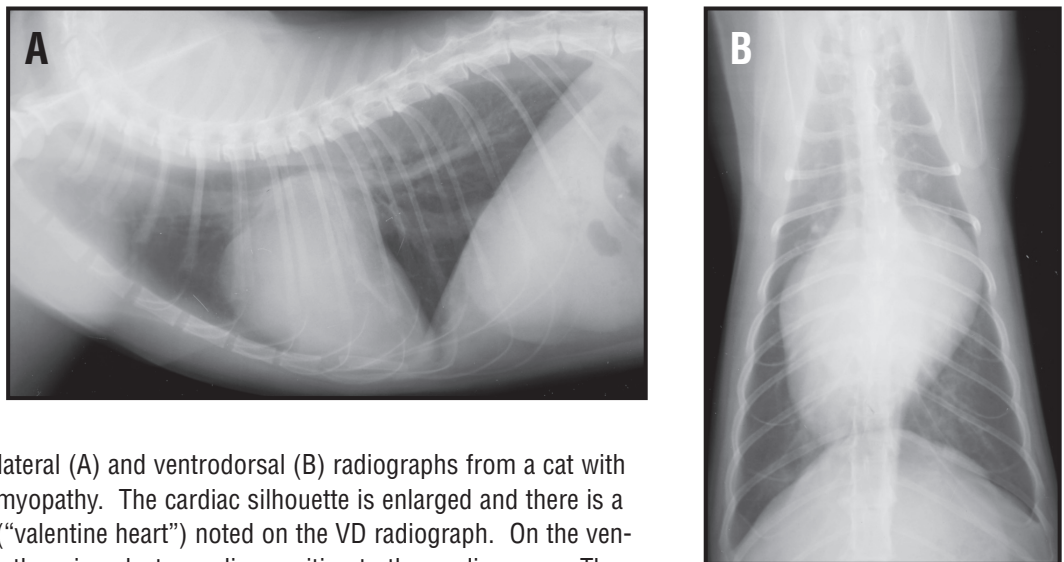
**Table 9 – Acquired heart disease**

DISEASE	PATHO-PHYSIOLOGY	LHF/RHF	MPA/AO/VESSELS	CARDIOMEGALY	OTHER FEATURES
<b>Myocardium</b>					
<b>Cardiomyopathy Dilated – Canine</b>	Systolic (pump) failure	LHF (±RHF)	PV>PA	LHE	Dobermans --> left atrial enlargement maybe all that is seen
<b>Cardiomyopathy Hypertrophic – Feline</b>	Diastolic (filling) failure	Both	PA and PV big -or- PV>PA	Biatrial or Valentine heart appearance	Left atrial thrombus & thrombo-embolism in caudal aorta
<b>Tumor</b>	Restriction of heart motion	Either or normal, RHF (Pericardial Effusion)		Possible with Pericardial Effusion	Usually metastatic to the myocardium
<b>Endocardium</b>					
<b>Endocardiosis Mitral valve (most common) ± Tricuspid valve</b>	Volume overload (eccentric hypertrophy)	LHE or RHE or both	PV>PA or both enlarged	LHF or RHF or both	May decompensate due to ruptured chordae, arrhythmias or left atrial tears.
<b>Endocarditis Aortic valve Mitral valve</b>	Volume overload	LHF	PV>PA or both enlarged	LHE – may be normal early in disease	Acutely may decompensate
<b>Pericardium</b>					
<b>Tumor – right atrial Hemgiosarcoma; heartbase tumor; lymphoma – cat</b>	Filling restriction with elevated intracardiac end diastolic pressures	Globoid enlargement (RHF)	Enlarged Caudal Vena Cava	Generalized	Cardiac tamponade with pulsus paradoxus
<b>Idiopathic</b>		Globoid enlargement (RHF)	Enlarged Caudal Vena Cava		Cardiac tamponade with pulsus paradoxus
<b>FIP (cat)</b>		Globoid enlargement (RHF)	Enlarged Caudal Vena Cava		Cardiac tamponade with pulsus paradoxus
<b>Left atrial tear – endocardiosis</b>		Globoid enlargement (RHF)	Enlarged Caudal Vena Cava; PV>PA		Cardiac tamponade with pulsus paradoxus
<b>Mesothelioma</b>		Globoid enlargement (RHF)	Enlarged Caudal Vena Cava		Cardiac tamponade with pulsus paradoxus
<b>Infectious pericarditis</b>		May be normal size (+/- RHF)	Enlarged Caudal Vena Cava		Cardiac tamponade with pulsus paradoxus
<b>Vessels</b>					
<b>Heartworms</b>	Vascular intimal and tunica medial proliferation; pulmonary hypertension, and pulmonary inflammatory changes	+/-RHF	Enlarged and tortuous, blunted pulmonary arteries, and enlarged Caudal Vena Cava	RHE	Pulmonary infiltrates with eosinophilia; eosinophilic granulomas; PTE and LYG.

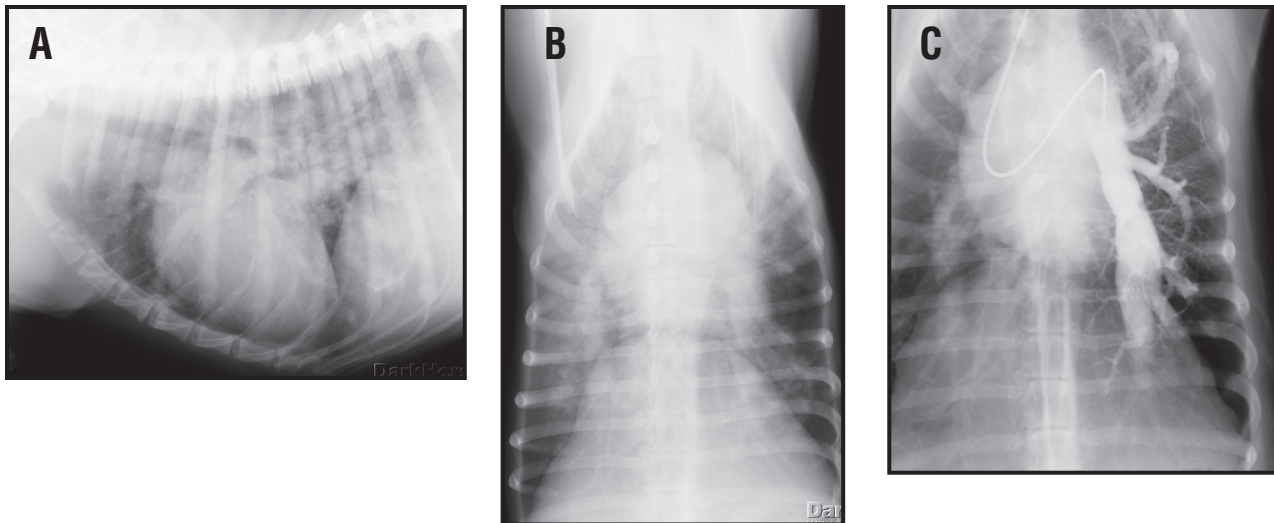
LHE = left heart enlargement (includes Left atrium and ventricle); LHF = left heart failure (pulmonary edema); RHF = right heart failure (pleural effusion); RHE = right heart enlargement; PV>PA = pulmonary veins are bigger than pulmonary arteries; LSA = lymphoma; FIP = feline infectious peritonitis; PTE = pulmonary thromboembolism and LYG = lymphomatoid granulomatosis.



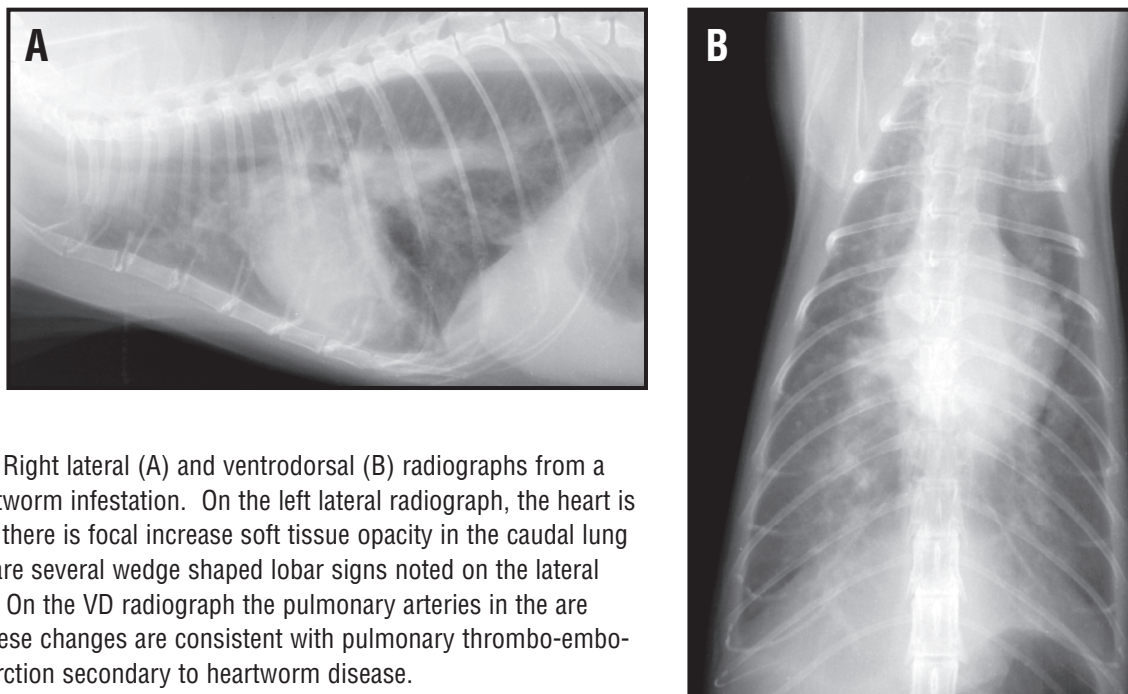
**Figure 81.** Right lateral (A) and ventrodorsal (B) radiographs from a Doberman with dilated cardiomyopathy. Often the overall cardiac size in a Doberman is NOT dramatically abnormal. The only hint at a cardiac abnormality is caudal displacement of the caudodorsal cardiac margin indicative of left atrial enlargement on the lateral radiograph. In this dog there is an overall increase in interstitial lung opacity indicative of early pulmonary edema. Close-up ventrodorsal radiograph (C) of the left caudal lung lobe. The pulmonary veins (white arrows) are larger than the corresponding pulmonary arteries (black arrows). This is indicative of pulmonary venous congestion secondary to elevated left atrial and end diastolic left ventricular pressures. In Dobermans with dilated cardiomyopathy in heart failure, it is common to see radiographic abnormalities consistent with both left sided and right sided cardiac failure (pulmonary edema and pleural effusion respectively).



**Figure 82.** Right lateral (A) and ventrodorsal (B) radiographs from a cat with hypertrophic cardiomyopathy. The cardiac silhouette is enlarged and there is a biatrial appearance (“valentine heart”) noted on the VD radiograph. On the ventrodorsal radiograph there is a dextrocardiac position to the cardiac apex. There is dorsal elevation of the trachea noted on the lateral radiograph. Increased pulmonary opacity is noted in the caudodorsal lung field consistent with pulmonary edema. Cats with cardiomyopathy (whether restrictive or hypertrophic) can present with pulmonary edema, pleural effusion or both in varying degrees.



**Figure 83.** Right lateral (A) and ventrodorsal (B) radiographs from a dog with heartworm infestation and eosinophilic pneumonitis. The pulmonary vessels are enlarged, tortuous and blunted. There are multifocal areas of interstitial lung opacity consistent with an eosinophilic pneumonitis. Close-up ventrodorsal radiograph of the same dog during a selective angiogram (C) of the left caudal lobar pulmonary artery. There is marked enlargement and tortuosity of the left caudal lobar artery. Blunted and pruned vessels are also noted. Multiple linear filling defects are present in the left caudal lobar artery consistent with heartworms.



**Figure 84.** Right lateral (A) and ventrodorsal (B) radiographs from a cat with heartworm infestation. On the left lateral radiograph, the heart is enlarged and there is focal increase soft tissue opacity in the caudal lung field. There are several wedge shaped lobar signs noted on the lateral radiographs. On the VD radiograph the pulmonary arteries in the are enlarged. These changes are consistent with pulmonary thrombo-embolism and infarction secondary to heartworm disease.

herniated into the pericardial space. Portions of the gastrointestinal tract may be found within the pericardium and occasionally animals present with acute onset intestinal obstruction due to incarceration of the hernia. Echocardiography is required for definitive diagnosis of pericardial disease. The most causes of pericardial effusion in the dog are secondary to a right atrial hemangiosarcoma

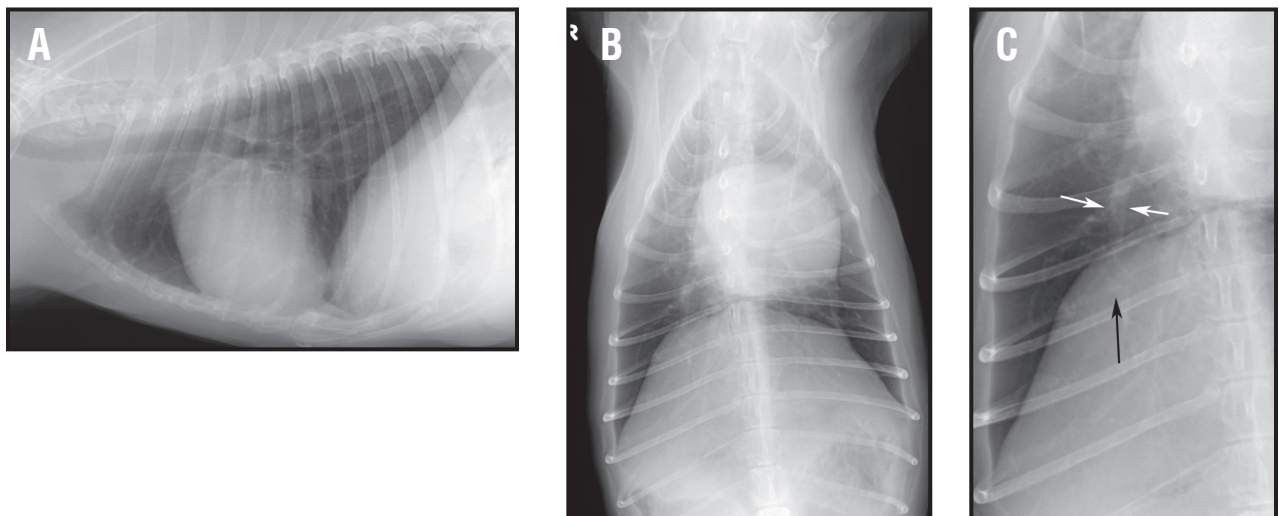
or heart base tumor (chemodectoma most common). Idiopathic hemorrhagic effusions can be seen in large breed dogs. Small breed dogs with chronic endocardiosis can develop a hemorrhagic effusion because of acute left atrial tears.

### C. The Caudal Mediastinum.

Abnormalities of the caudal mediastinum have been covered in the section of the esophagus. Several gastro-esophageal abnormalities should be mentioned however. This includes paraesophageal hernias, hiatal or sliding esophageal hernia and a gastroesophageal intussusception, (**Figure 87**). These abnormalities can be seen as discrete soft tissue mass effect in the caudal esophagus with widening of the caudal mediastinum being present on the VD radiograph. Left lateral radiographs will aid in documenting a sliding hernia more readily than the right lateral radiograph. The Sharpei breed is predisposed to gastroesophageal hernias. Gastro-esophageal intussusceptions are rare and are characterized by a soft tissue and gas filled mass in the caudal esophagus. Gastric rugal folds in the esophagus can be identified characteristic of this abnormality. As with other esophageal disorders, aspiration pneumonia can be present. Esophageal masses can be located at the gastroesophageal junction. Caudodorsal mediastinal masses can originate in and around any of the soft tissues of the caudal mediastinum. These tumors are rare in the dog and cat.

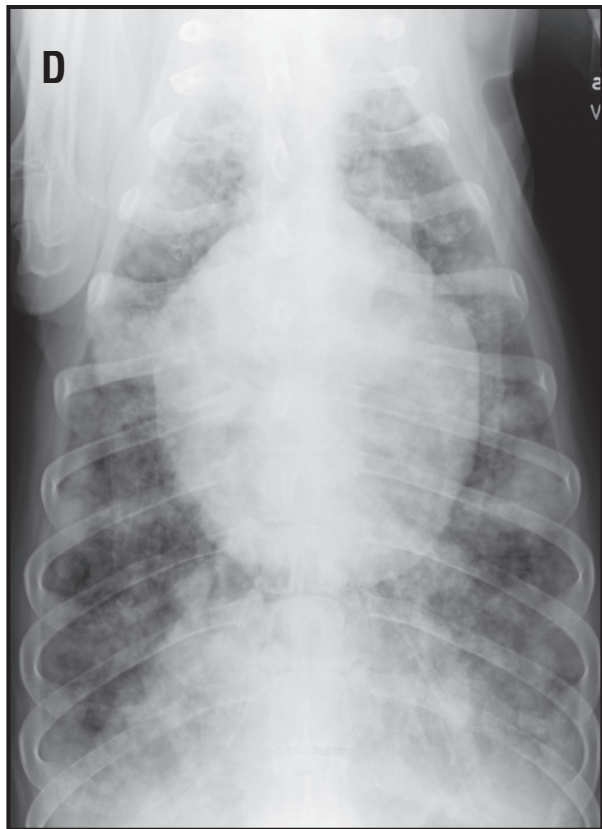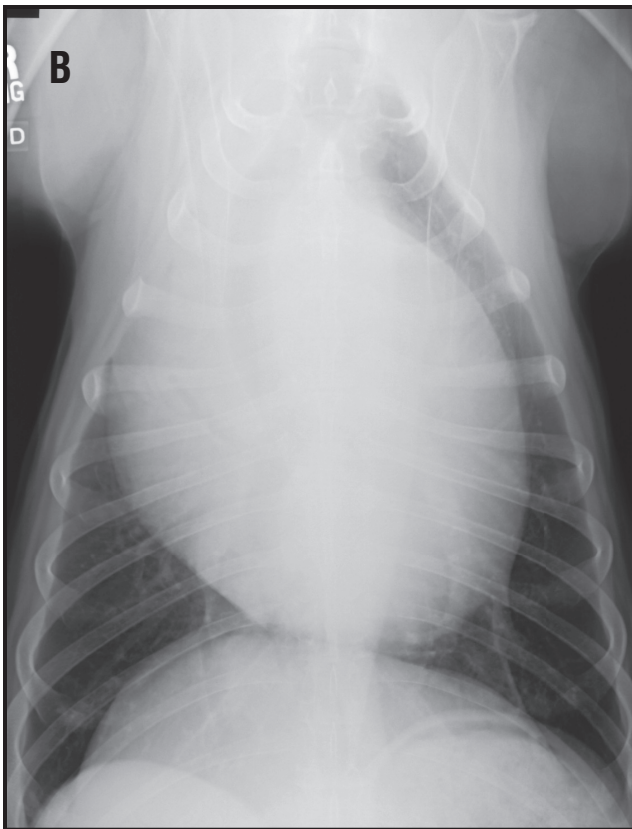
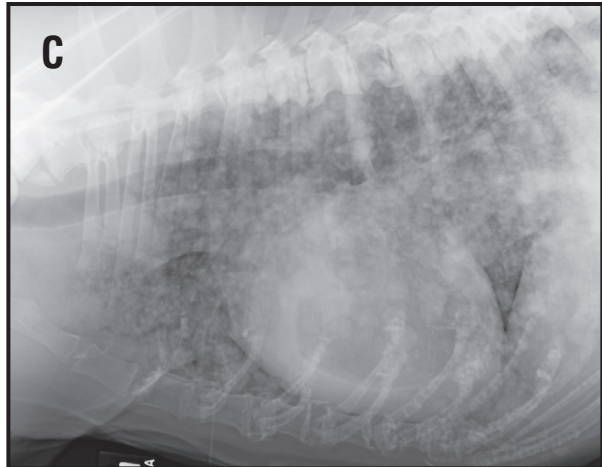
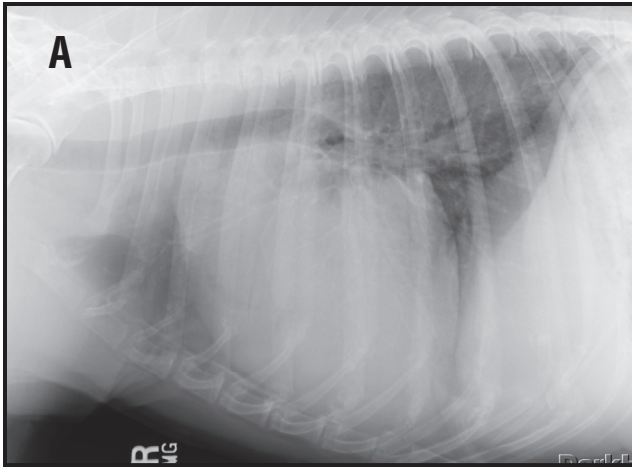
### Alternate Imaging of the Thorax

Although the thorax is well suited to radiographic examination, its complexity also means that other imaging techniques may be needed to obtain a definitive diagnosis. Echocardiography is especially useful in the diagnosis of congenital cardiac disease and assessing the severity of acquired cardiac disease. Ultrasound may also be used to image noncardiac structures. Aerated lung effectively



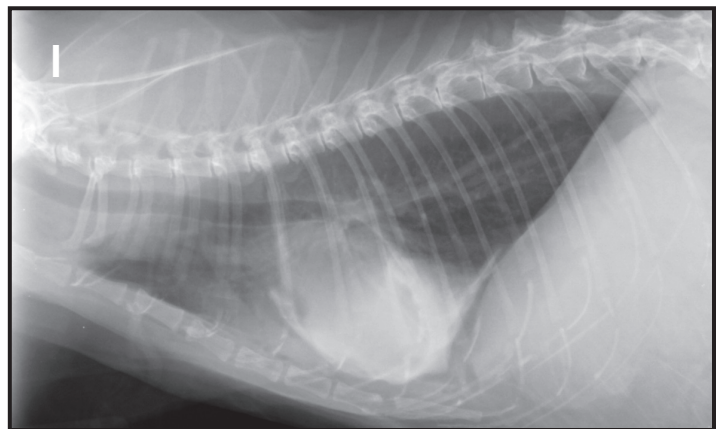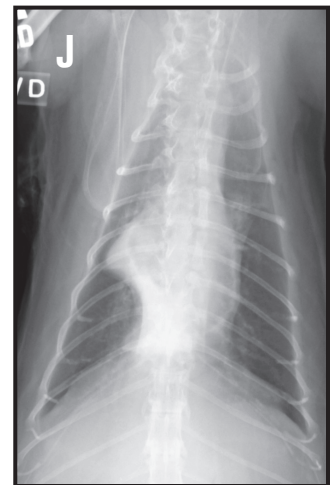
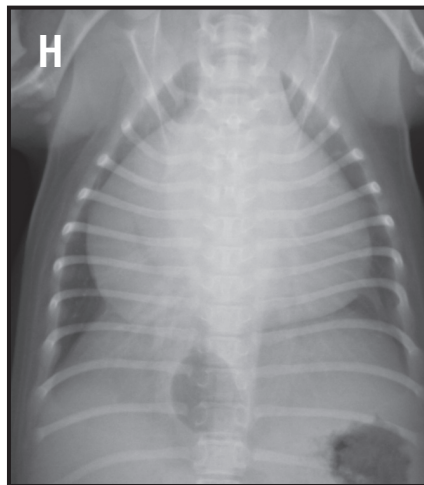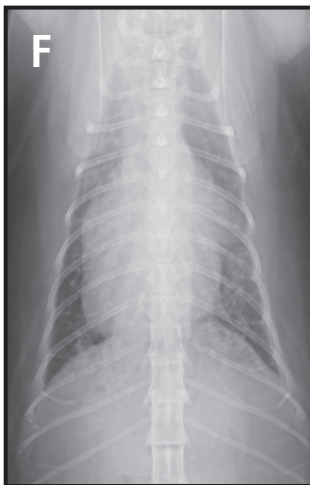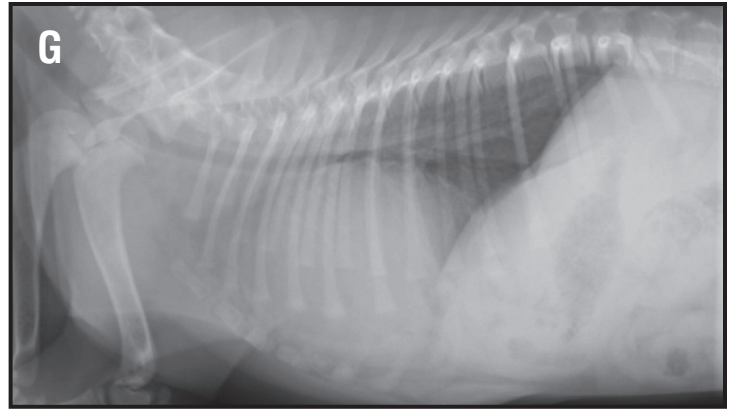
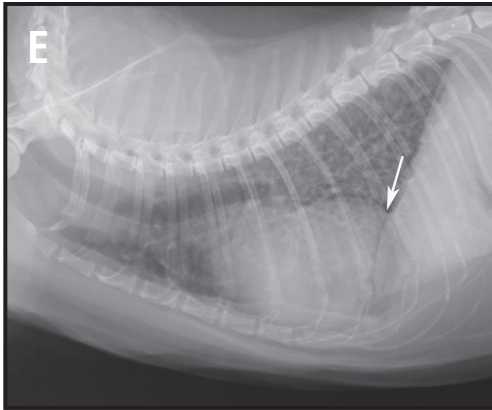
**Figure 85.** Right lateral (A) and dorsoventral (B) radiographs from a dog with immune mediated thrombocytopenia. On the VD radiograph there is a relative hyperlucency associated with the right caudal lung lobe. This change is consistent with pulmonary acute thromboembolism. Close-up dorsoventral (C) radiograph of the right caudal lung field. The peripheral right caudal lobar artery is small (white arrows) and terminates abruptly (black arrow) consistent with regional oligemia and pulmonary thrombo-embolism.

**Figure 86.** Right lateral (A), and ventrodorsal (B) radiographs from a dog with a pericardial effusion. Note the globoid appearance and marked enlargement to the cardiac silhouette. The is dorsal and rightward deviation of the trachea. A heart base mass (chemodectoma on histology) is seen causing this tracheal displacement. Pericardial effusions result in right heart failure secondary to the cardiac tamponade and a restrictive diastolic filling physiology. Right lateral (C), and ventrodorsal (D) radiographs from a dog with a pericardial effusion secondary to a right atrial tumor. There are multiple variably sized pulmonary nodules and masses noted throughout the lung fields. Positive contrast medium (Omnipaque 240®, white) had been place into the pericardial space during pericardiocentesis. The large central filling defect is the heart with a focal oval filling defect noted along the cranial dorsal border of the heart on the lateral radiograph.



## Thoracic Radiology

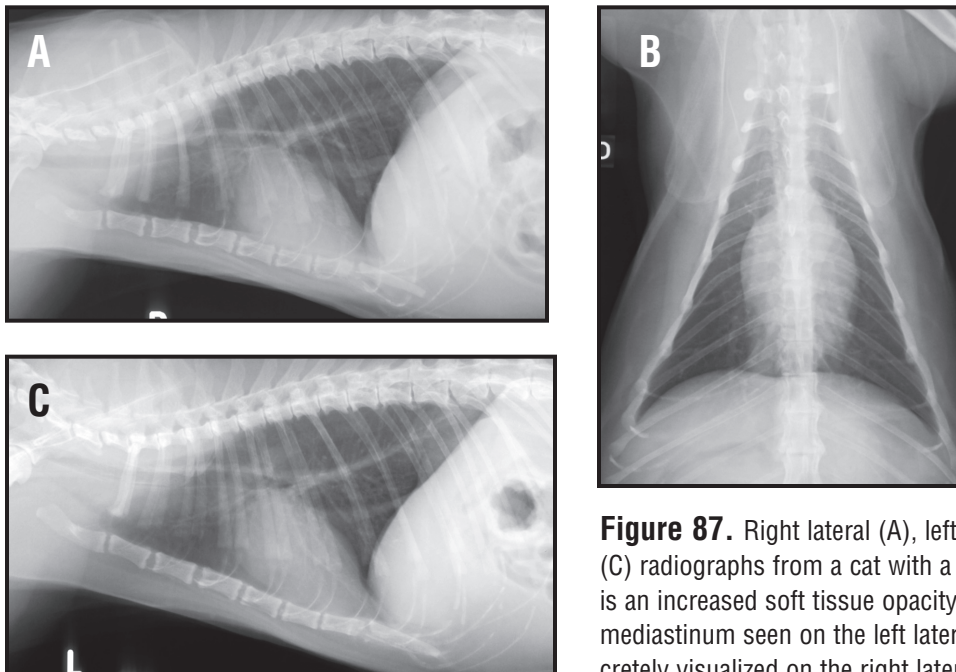
**Figure 86 CONTINUED.** Right lateral (E), and ventrodorsal (F) radiographs from a cat with a peritoneal pericardial diaphragmatic hernia. This cat also has severe bronchial changes consistent with chronic bronchitis and allergic airway disease. There is a dorsal peritoneal-pericardial mesothelial remnant that connects the pericardial and the peritoneal spaces (white arrow). There is enlargement of the cardiac silhouette with unusual contour and margin changes that do not fit typical patterns of cardiomegaly for the cat. Right lateral (G), and ventrodorsal (H) radiographs from a puppy with a congenital peritoneal-pericardial diaphragmatic hernia. Right lateral (I), and ventrodorsal (J) radiographs cat with a peritoneal-pericardial diaphragmatic hernia. Positive contrast medium has been placed into the pericardial space. The DPMR is outlined by the positive contrast medium, but there is not contrast medium in the peritoneal space (visualized on the radiographs). At surgery, omentum was within the hernia effectively blocking the passage of the positive contrast medium from the pericardial to the peritoneal space.



blocks the ultrasound beam if lesions are superficial, or there is pleural fluid a window may be available. This technique may be used to confirm the presence of a mediastinal mass and to evaluate pulmonary masses or consolidations. Perhaps more usefully, ultrasound is used to provide guidance for needle aspirates or biopsies. Computed tomography is more commonly used for thoracic imaging. It is more sensitive than conventional radiographs for subtle pulmonary changes, especially detecting small nodules. CT is not compromised by air filled lung as ultrasound is so it may be used for guidance when obtaining a biopsy from lesions deep to aerated lung.

## References

1. Suter P and Lord P. Text Atlas of Thoracic Radiography: Thoracic diseases of the dog and cat. Switzerland, 1984. (Out of print).
2. Muller NL, Fraser RS, Colman NC and Pare PD. Radiologic Diagnosis of Diseases of the Chest. Philadelphia: WB Saunders, 2001.
3. Lange S and Walsh G. Radiology of Chest Diseases. New York: Thieme Stuttgart, 1998.
4. Thrall DE (ed). Textbook of Veterinary Diagnostic Radiology, fourth edition. Philadelphia: WB Saunders, 2002.
5. Reed JC. Chest Radiology: Plain film patterns and differential diagnoses, fourth edition. St. Louis: Mosby, 1997.
6. Burk RL and Feeney D. Small Animal Radiology and Ultrasonography: A diagnostic atlas and text, 3rd edition. Philadelphia: WB Saunders, 2003.
7. King LG (editor). Textbook of Respiratory Disease in Dogs and Cats. Philadelphia: WB Saunders, 2003.
8. Fox P, Sisson D, and Moise S. Textbook of Canine and Feline Cardiology: Principles and Clinical Practice, second edition. Philadelphia: WB Saunders, 1999.
9. Milne ENC and Pistolesi M. Reading the Chest Radiograph: A Physiologic Approach. St. Louis: Mosby, 1993.
10. Kittleson MD and Kienle RD. Small Animal Cardiovascular Medicine. St. Louis: Mosby, 1998.
11. Opie LH. The Heart: Physiology, from Cell to Circulation. Philadelphia: Lippincott-Raven, 1998.
12. Katz AM. Physiology of the Heart. Philadelphia: Lippincott Williams & Wilkins, 2001.
13. Coulson A and Lewis N. An atlas of interpretative radiographic anatomy of the dog & cat. Ames, Iowa: Blackwell Science, 2002.



**Figure 87.** Right lateral (A), left lateral (B) and ventrodorsal (C) radiographs from a cat with a sliding hiatal hernia. There is an increased soft tissue opacity noted in the caudal dorsal mediastinum seen on the left lateral radiograph that is not discretely visualized on the right lateral radiograph. Bulldogs and Sharpeis are predisposed to paraesophageal or hiatal hernias.

## **Thoracic Radiology**

14. Fuentes VL and Swift S. BSAVA Manual of Small Animal Cardiorespiratory Medicine and Surgery. Dorset, UK: British Small Animal Veterinary Association, 1998.
15. Dennis R, Kirberger RM, Wrigley RH and Barr FJ. Handbook of Small Animal Radiological Differential Diagnosis. Philadelphia: WB Saunders, 2001.
16. Kealy JK and McAllister H. Diagnostic Radiology and Ultrasonography of the Dog and Cat, third edition. Philadelphia: WB Saunders, 2000.