

A RELATIVE ASSESS ON WOUND HEALING AND ANTI SCAR ACTIVITY OF CRUDE *Echinops heterophyllus* EXTRACT AND SOME OF ITS BIOACTIVE FRACTIONS

ALAA A. ABDULRASOOL*, ZENA M. FAHMI**, ENAS J. KHADEEM**

* Baghdad University, ** Department of Pharmacognosy and Medicinal plants, College of Pharmacy, University of Baghdad, Baghdad Iraq.

Received: 02 Apr 2013, Revised and Accepted: 12 May 2013

ABSTRACT

Objective: This study was conducted to identify the active constituents of local Iraqi *Echinops heterophyllus* plant and to study the effect of the crude extract and some of its bioactive fractions in wound healing and as an anti scar agent in vivo.

Materials and Methods: Phytochemical tests were conducted to identify the bioactive fractions. Twenty four adult male rabbits were used. Aged between six months to one year, obtained from the local market and placed in sterilized cages subjected to constant environmental conditions. Twenty four adult male rabbits were used and divided into four equal groups. The effect of crude *Echinops* extract and its bioactive fractions (Alkaloids and flavonoids) was evaluated visually and through histological changes. Treatment was applied three times daily using a cotton swab. First group: was considered as a control group, and left without treatment. Second group: was considered as a treatment group, and treated with crude *Echinops* extract. Third group: was also considered as a treatment group, and treated with alkaloids fraction obtained from *Echinops* extract. Fourth group: was considered as a treatment group, wounded rabbits were treated with flavonoids fraction obtained from *Echinops* extract.

Results: *Echinops* extract served to accelerate the wound healing process and specifically increased epithelialization in treatment groups compared to the untreated group. The group treated with the crude extract gave best result. Alkaloid fraction was more potent than the flavonoids fraction in treating wounds. Both groups treated with the crude extract and alkaloid showed no scar formation.

Conclusion: It can be concluded that this study is a good step to show that *Echinops* extract is effective in stimulating the enclosure of wounds and as anti-scar agent.

Keywords: *Echinops heterophyllus*, Bioactive fractions, Wound healing, Anti scar agent.

INTRODUCTION

A large number of plants has been used by folk medicine at diverse parts of Iraq to treat different human ailments. *Echinops heterophyllus* P.H.Davis (Compositae), is naturally inhabitant in the Kurdistan region. It has been traditionally used for various skin problems including cuts, abrasion, burns and snake bites.

Echinops, is a genus includes many plants which are independently referred to as globe thistle. *Echinops* has more than 120 species of perennials, annuals, and biennials [1,2]. The genus belongs to the daisy family Asteraceae, and its species are found in eastern and Southern Europe, North Africa and Asia [3]. Prof. Dr. Ali Al-Raw an Iraqi plant classification specialist mention 11 species of *Echinops* in his book [4], one of them was *Echinops heterophyllus* P.H.Davis. This plant is indigenous in Iraq mainly in the Kurdistan region, especially in Erbil and Sulaimani cities. In Hanara village and surrounding area in Wadi Bastora and shaklawa in Erbil governorate, the plant is called (Shakroka). The term (Shakroka) is come from that the circle-like part of the plant, before getting harder in the late spring, is eaten and the taste is sweet, therefore, it is called shakroka, Shakr means sugar, Shakroka----- sweet like sugar. (in local Iraqi language). The *Echinops heterophyllus* (figure-1) is a perennial, 40-100 cm high. Stems are simple or branching from the base, sparsely cobwebby-cane scent. Leaves are lance late or oblong-lance late, the lower ones are 10-15 cm long, 4-6cm wide, with triangular-lance late, prickly lobes, greenish, shiny, sub glabrous above, densely whitish-tomentose below. [5] *Echinops* plant was reported to possess variety of compounds belonging to various classes like: alkaloids, flavonoids, terpenoids, lipids, steroids and polyacetylenes [6]. And many literatures survey revealed different pharmacological activities of *Echinops* plant like, antibacterial activity [7], Antifungal [8], Antioxidant activity [9], Protective effects on testosterone-induced prostatic hyperplasia [10], hepato-protective [11] and anti-ulcerogenic activity [12]. So this study was emphasized on the identification of active constituents in the Iraqi species of *Echinops* plant, and investigated the pharmacological activity of this plants crude extract and some of its bioactive fractions in promoting wound healing and as anti-scar agent.



Fig. 1: Iraqi *Echinops heterophyllus*

Plant materials

The whole plant of *Echinops heterophyllus* of the Family (Compositae) was collected from Nazali, 71Km north of Erbil. The plant was authenticated by Dr. Abdul-hussien alkhat (an Iraqi plant classification specialist). The plant were cleaned and dried at room temperature in the shade and then pulverized by mechanical mills and weighed.

Preliminary qualitative phytochemical analysis

Chemical tests were carried out using the ethanolic extracts from plants and or the powdered specimens, using standard procedures to identify the active constituents [13-15].

Test for alkaloids

Ten (10ml) of alcoholic extract was stirred with 5 ml of 1% HCL on a steam bath. Mayer's (1.35gm mercuric chloride in 60ml water + 5gm potassium iodide in 10ml water) and Wagner's reagents (1.27g of iodine and 2g of potassium iodide in 100ml of water) were added, white and reddish brown color precipitate respectively, were taken as evidence for the presence of alkaloids.

Test for flavonoids

Lead acetate test: to 5ml of alcoholic extract, 1ml of 10% lead acetate solution was added. The formation of a yellowish- white precipitate was taken as a positive test for flavonoids.

Tests for steroids

Liebermann-Burchard test: extract (3ml) was treated with chloroform, acetic anhydride and drops of sulphuric acid was added. The formation of dark pink or red color indicates the presence of steroids.

Test for tannins

About 10mg plant material in 10ml distilled water was filtered, then 3ml of the filtrate + 3ml of FeCl₃ solution (5%w/v) were mixed. The formation of a dark green or blue black precipitate was considered an indication for the presence of tannins.

Test of saponins

Five ml of aqueous extract was shaken vigorously with 5ml of distilled water in a test tube and warmed. The formation of stable foam, honey comb in shapes, was taken as an indication for presence of saponins.

Tests for anthraquinoin

Borntrager's test: 3ml of alcoholic extract was shaken with 3 ml of benzene, filtered and 5 ml of 10% ammonia solution was added to the filtrate. The mixture was shaken and the development of a pink, red or violet color in the ammoniac (lower) phase indicates the presence of free anthraquinoin.

Test for terpenoids

Two ml of the organic extract was dissolved in 2 ml of chloroform and evaporated to dryness. 2 ml of concentrated sulphuric acid was then added and heated for about 2 min. A grayish color was considered an indication for the presence of terpenoids.

Extraction and fractionation of different active constituents

A (200gm) of shade-dried coarsely powdered plant materials separately were defatted with hexane for 24 hours then allowed to dry at room temperature. The defatted plant materials was extracted with (2 L) of 80% ethanol in soxhlet apparatus until complete exhaustion. The alcoholic extract was evaporated to dryness, under reduced pressure at a temperature not exceeding 40 °C to give a dark greenish-yellow residue designated as a crude fraction. Crude fraction was acidify with 300ml of 5% hydrochloric acid to pH 2 and partitioned (three times) with equal volume of ethyl acetate to get two layers (aqueous acidic and ethyl acetate layer). The aqueous acidic layer was then separated and basify with 5% sodium hydroxide to pH 10 and extracted with chloroform in the separatory funnel to get two layers, the chloroform layer which was separated and evaporated under reduced pressure at a temperature not exceeding 40 °C to give blackish residue designated as fraction 1 (F-1 which contained alkaloids) and aqueous basic layer. The ethyl acetate layer of the original alcoholic extract (crude fraction) was evaporated to dryness under reduced pressure and basify with 300ml of 5% sodium hydroxide to pH 10 and extracted with ethyl acetate in the separatory funnel to get two layers, the aqueous basic layer which was separated, evaporated to dryness and acidify with 5% HCL to pH 2 then extracted with ethyl acetate to get fraction designated as fraction 2 (F-2 which contained flavonoids)[14].

A relative assess on wound healing activity of crude *Echinops heterophyllus* extract and some of its bioactive fractions (F-1 and 2) was done as follow

In vivo experiment

Plant material

Crude plant extract, bioactive fractions (Alkaloids and flavonoids).

Experiment Animals

Twenty four adult male rabbits were used. Aged between six months to one year, obtained from the local market and placed in sterilized cages subjected to constant environmental conditions.

Induction of wounds

Surgical preparations were made at the upper back region after clipping, shaving and washing the area with tap water and drying. Then, standard longitudinal incisions (1x2 cm²) were implemented using a surgical scalpel[16,17].

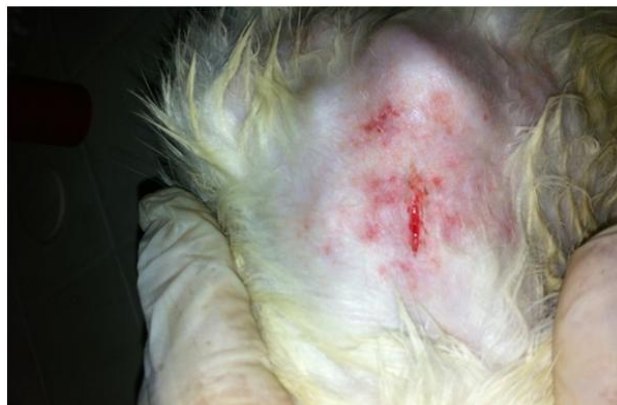

Fig. 2: (1x2 cm²) Wound incision at the back region.

Blood collecting

Blood samples were obtained from each animal at day one, four, six and twelve. Measuring the blood glucose, protein, albumin, GOT and GPT, to ensure that animals are in a healthy state and the wound healing process was not affected by other factors. Two ml of blood was obtained through percutaneous cardiocentesis in anesthetized rabbits approaching the heart from the **lateral** left side and the midline under the sternum side aiming the needle toward the heart. Using 19 to 25G needle with 3 to 5 ml syringe; and blood sample collection tubes with an anticoagulant agent[18-20].

Animal groups

Twenty four adult male rabbits were used and divided into four equal groups. The effect of crude *Echinops* extract and its bioactive fractions (Alkaloids and flavonoids) was evaluated visually and through histopathological changes. Treatment was applied three times daily using a cotton swab.

First group: was considered as a control group, each rabbit was wounded and left without treatment.

Second group: was considered as a treatment group, rabbits were wounded and treated with crude *Echinops* extract.

Third group: was also considered as a treatment group, wounded rabbits were treated with alkaloid fraction obtained from *Echinops* extract.

Fourth group: was considered as a treatment group, wounded rabbits were treated with flavonoids fraction obtained from *Echinops* extract.

Histological Evaluation

Specimens were taken from day one, fourth, sixth and twelfth. Animals were anesthetized using (Xylazine and Ketamine) in a dose of 5mg/Kg and 15 mg/Kg respectively[21]. Later, the specimens were kept in buffered formalin (10%) solution and examined.

RESULTS

Preliminary qualitative phytochemical analysis

The results of phytochemical screening are given in table-1.

Table 1: Phytochemical Screening of Echinops heterophyllus

Alkaloids	Flavonoids	Steroids	Tannins	Saponins	Anthraquinoin	Terpenoids
+	+	-	-	-	-	+
Traces	+	+	-	-	-	+
+	+	+	-	-	-	+

+, - represent presence and absence of phytoconstituents respectively.

Phytochemical screening of Iraqi Echinops plant indicated that the plant contains different chemical classes of active constituents, alkaloids (basic compounds), flavonoids (acidic compounds) and steroids (neutral compounds) so the fractionation based on the conversion of basic compound to its salt by aqueous mineral acids, and when the salt of an alkaloid is treated with hydroxide ion, nitrogen gives up a hydrogen ion and the free amine is liberated which is taken or extracted by specific organic solvent like (chloroform) to get free

alkaloids (F-1) leaving quaternary alkaloids and water soluble compounds in the aqueous layer. The same principle is applied to the acidic compounds to get flavonoids as a free aglycon in fraction-2 leaving neutral components in the organic layer.

Blood test

Results demonstrated normal levels for glucose, protein, albumin, GOT and GPT as in tables-2, 3, 4 and 5.

Table 2: Blood Samples from Day One.

	Glucose mg/dl	Protein gm.	Albumin g/dL	GOT U/liter	GPT U/liter
Group 1	100	8.0	3.5	20	40
Group 2	185	7.5	4.5	30	45
Group 3	120	8.0	4.0	32	53
Group 4	275	8.0	4.0	44	62

Table 3: Blood Samples from Day Four

	Glucose mg/dl	Protein gm.	Albumin g/dL	GOT U/liter	GPT U/liter
Group 1	95	8.0	3.5	28	39
Group 2	156	7.2	4.6	34	46
Group 3	170	6.3	4.2	43	67
Group 4	185	8.2	3.8	22	64

Table 4: Blood Samples from Day Six

	Glucose mg/dl	Protein gm.	Albumin g/dL	GOT U/liter	GPT U/liter
Group 1	97	5.6	4.4	31	39
Group 2	160	7.4	5.0	26	33
Group 3	146	7.2	7.0	37	45
Group 4	158	8.3	4.5	29	58

Table 5: Blood Samples from Day Twelve

	Glucose mg/dl	Protein gm.	Albumin g/dL	GOT U/liter	GPT U/liter
Group 1	206	5.5	3.6	24	47
Group 2	189	5.4	4.4	36	44
Group 3	123	6.3	5.9	33	46
Group 4	99	5.8	4.8	32	45

Visual remarks

Group one (wounding without treatment)

Normal healing took place which involves continuous cell-cell and cell-matrix interactions that allow the process to proceed in three

overlapping phases : inflammation (0-3 days), cellular proliferation (3-12 days) and remodeling (3-6 months) , so in this group there is some inflammatory signs seen from the first day with partial wound closure starting from the 4th day and some scar tissue at the 12th day. Figures (3-5).

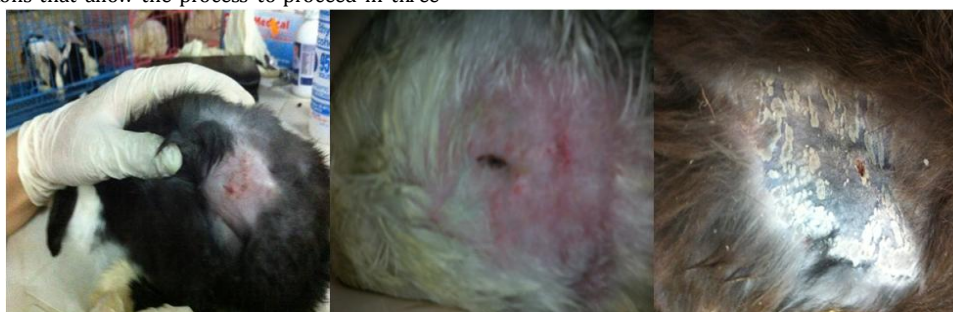

Fig. 3: Group-1 day-1 Fig. 4: Group-1 day-6 Fig. 5: Group-1 day-12

Group two (wounding with treatment with crude *Echinops* extract) : healing signs were very clear starting from day one. The complete fading of any inflammatory signs at day four and six. Finally, a complete wound closure at day twelve. Figures(6-8).

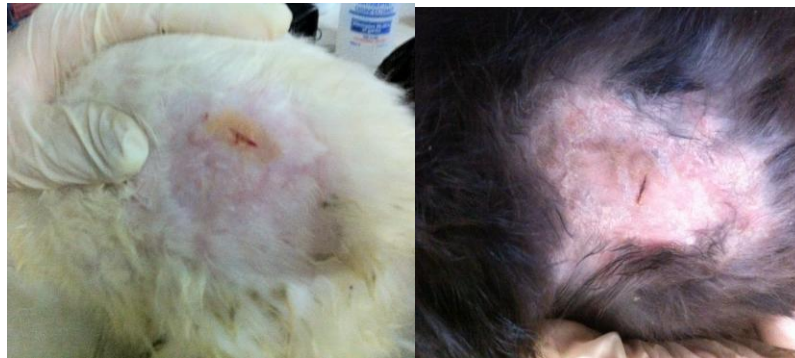

Fig. 6: Group-2 day-1 Fig. 7: Group-2 day-6

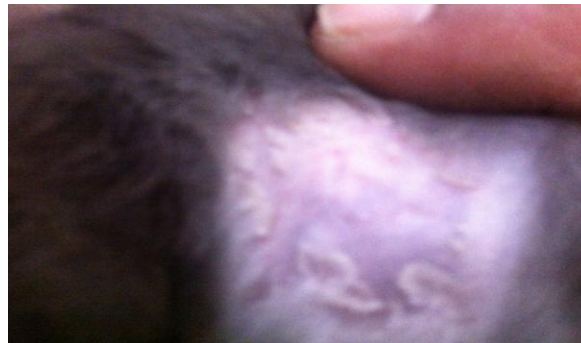

Fig. 8: Group-2 day-12

Group three (wounding with treatment with alkaloid fraction): remarkable wound healing signs from day one as there was no inflammatory signs. At day six wound edges started to convene. Lastly, an absolute wound closing at day twelve. Figures (9-11).

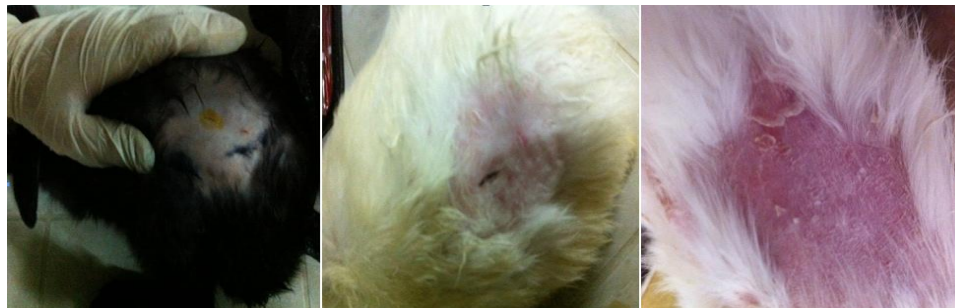

Fig. 9: Group-3 day-1 Fig. 10: Group-3 day-6 Fig. 11: Group-3 day-12

Group four (wounding and treatment with flavonoids fraction): mild inflammatory signs occurred at day one. A gradual healing appeared from day four till day twelve and few scar tissue at day 12th. Figures (12-14)

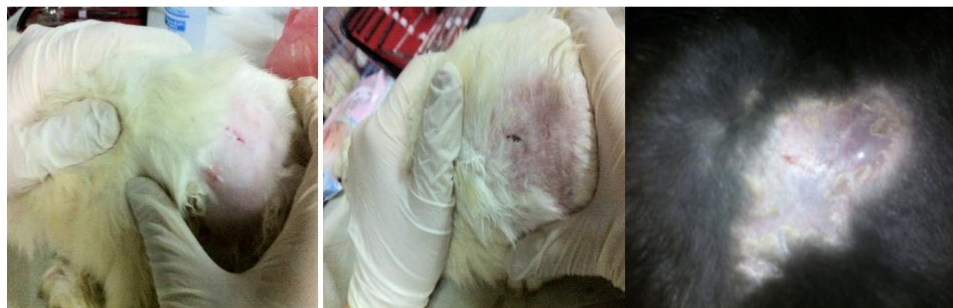

Fig. 12: Group-4 day-1 Fig. 13: Group-4 day-6 Fig. 14: Group-4 day-12

Histology

The control group was used as a model to be compared with the other three groups treated with the crude *Echinops* extract, alkaloid

and flavonoids bioactive fractions obtained from *Echinops heterophyllus* extract. Hematoxylin and Eosin (H&E) Staining were used. Results demonstrated that the treatment group with the crude

Echinops extract gave the best results, while the alkaloid bioactive fraction was more potent than flavonoids bioactive fraction. The following figures demonstrates these results.

Group one (wounding without treatment): normal histological signs was observed.

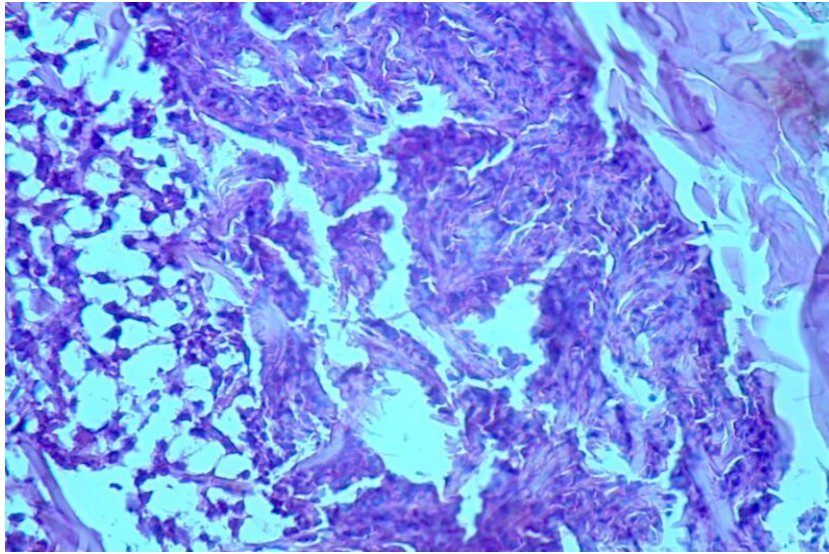


Fig. 15: Group one day one: a very clear appearance of inflammatory signs at the wound area during the first 24hrs, Fibrous threads to ok place and new epidermal layer formed the marginal ends started to thicken.

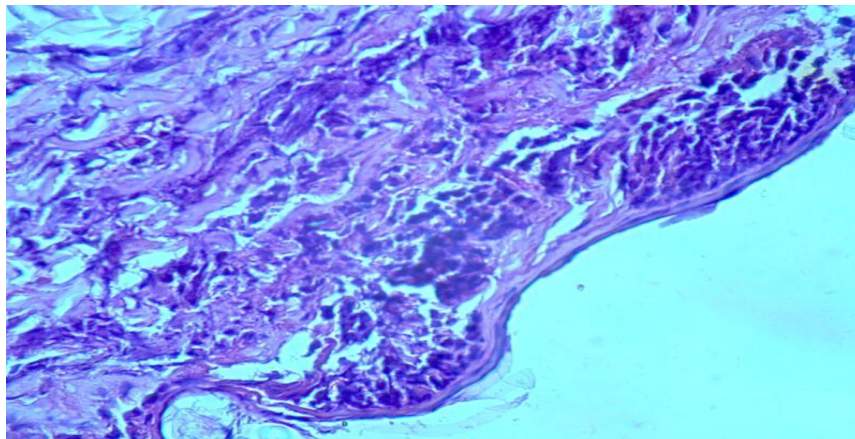


Fig. 16: Group one day 12: There was no signs of inflammation. There was also an increase in collagen proliferation. Wound is not healed yet.

Group two (wounding with treatment with crude *Echinops* extract)

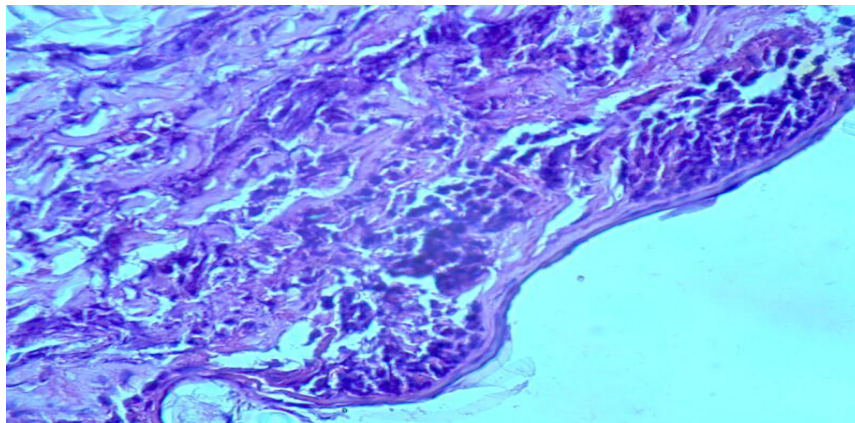


Fig. 17: Group two-day one: (X 200) A selection of skin showing few amounts of inflammatory cells at the upper dermis layer and oedema, a clear migration of epidermal cells.

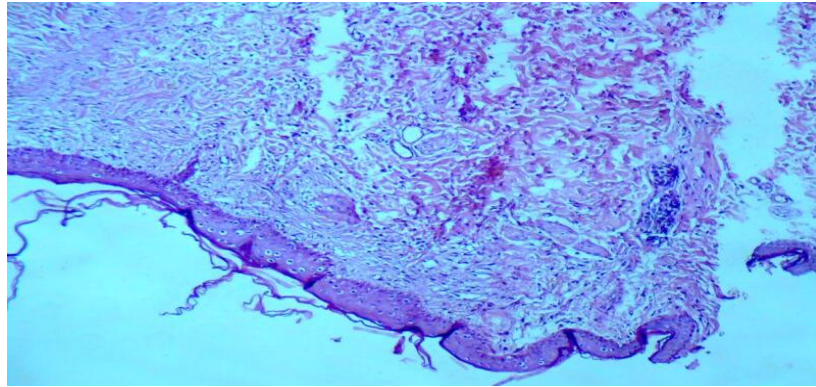


Fig. 18: Group two- day six: normal healing of dermis and epidermis layer.

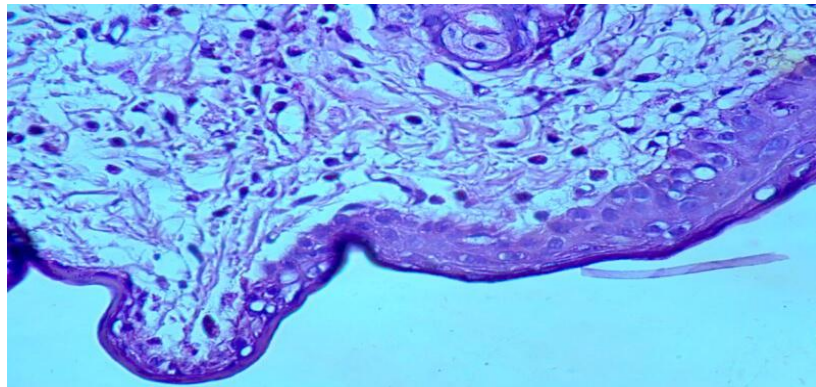


Fig. 19- Group two- day 12: there was a full thickness epidermal regeneration which covered completely the wound area.

Group three (wounding with treatment with alkaloids fraction)

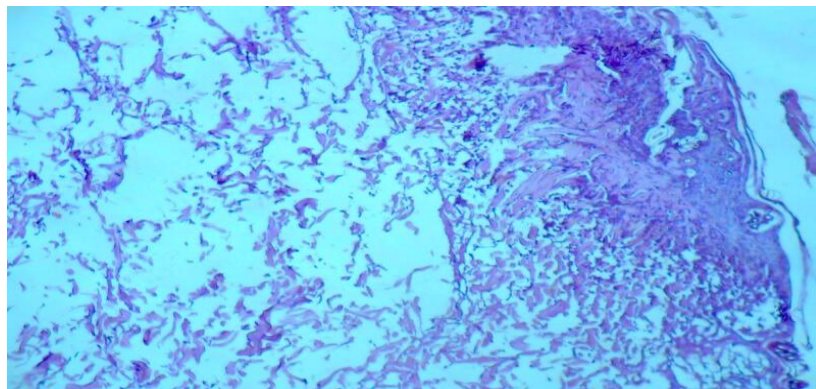


Fig. 20: Group three day one: some inflammatory cells at the upper dermis layer and oedema

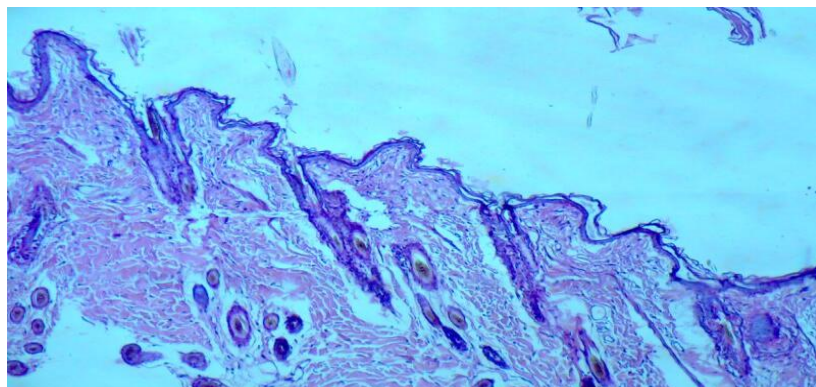


Fig. 21: Group three day six: marked infiltration of the inflammatory cells, increased blood vessel formation and enhanced proliferation of cells as a result of treatment with alkaloids fraction

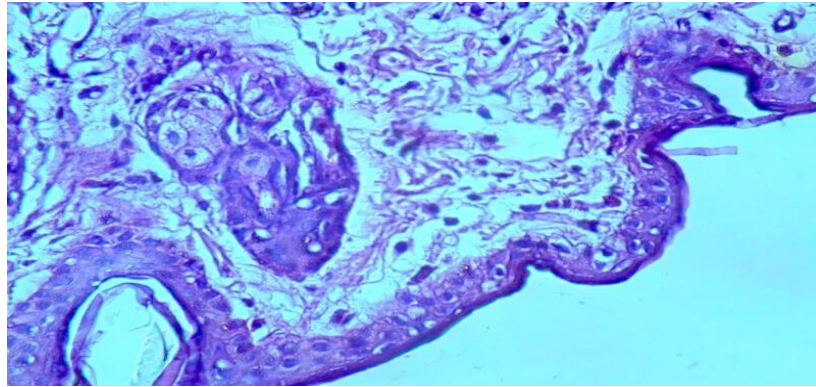


Fig. 22: Group 3 day 12: No inflammation, accumulation of granulation tissue, increase in the tensile strength. No scar formation

Group four (wounding and treatment with flavonoids fraction)

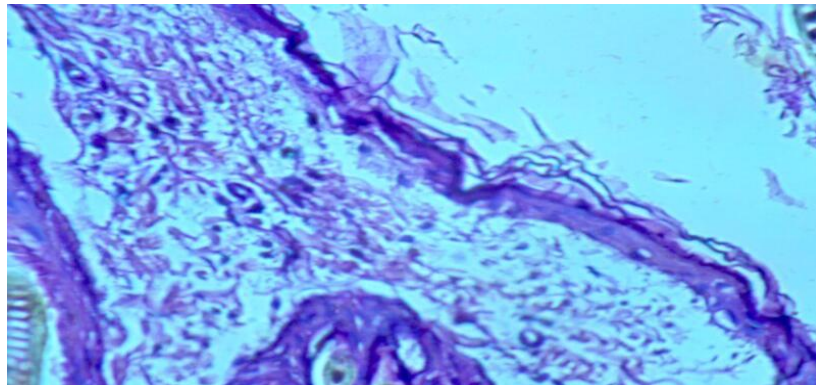


Fig. 23: Group 4 day 1: a very clear appearance of inflammatory signs with oedema

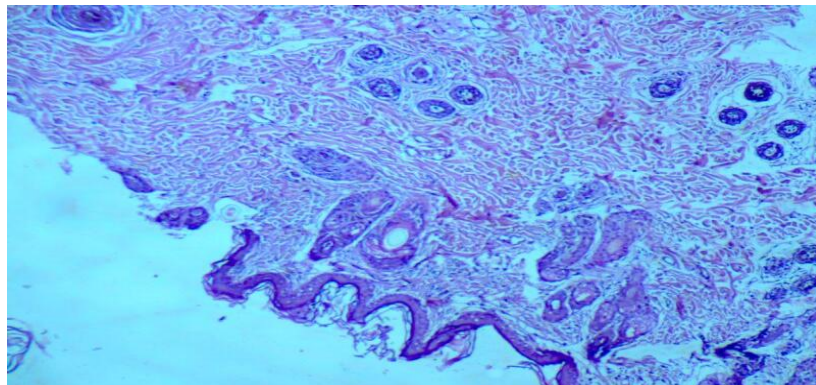


Fig. 24- Group 4 day 6: almost complete healing

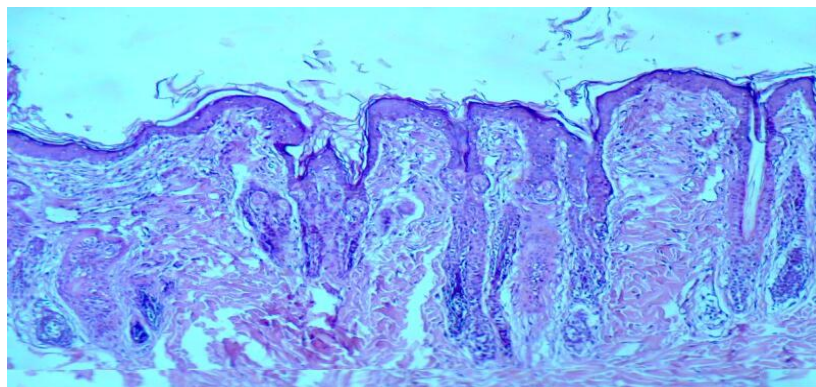


Fig. 25- Group 4 day 12: There was no signs of inflammation, accumulation of granulation tissue, increase in the tensile strength.

DISCUSSION

Wounds are referred to as disruption of normal anatomic structure and function. Skin wounds could happen through several causes like physical injuries resulting in opening and breaking of the skin[22]. The most common symptoms of wounds are bleeding, loss of feeling or function below the wound site, heat and redness around the wound, painful or throbbing sensation, swelling of tissue in the area and pus like drainage[23]. Wound healing is a very complex, multifactor sequence of events involving several cellular and biochemical processes. The aim in these processes is to regenerate and reconstruct the disrupted anatomical continuity and functional status of the skin. Healing process, a natural body reaction to injury, initiates immediately after wounding and occurs in four stages. The first phase is coagulation which controls excessive blood loss from the damaged vessels. The next stage of the healing process is inflammation and debridement of wound followed by re-epitheliasation which includes proliferation, migration and differentiation of squamous epithelial cells of the epidermis. In the final stage of the healing process collagen deposition and remodeling occurs within the dermis[24]. The results showed wound healing and repair, accelerated by applying crud extract of Echinops plant, which was highlighted by the full thickness coverage of the wound area by an organized epidermis. The enhanced capacity of wound healing with the plant could be explained on the basis of anti-inflammatory effects of the active constituents of the plant (quinoline alkaloids, flavonoids, steroids and terpenoids).

Study on animal models showed enhanced rate of wound contraction and drastic reduction in healing time than control, which might be due to enhanced epitheliasation. The animals treated with plant extract showed significant results when compared with untreated groups. The treated wound after six days itself exhibit marked dryness of wound margins with tissue regeneration.

REFERENCES

- Bobrov E.G.: *Echinops* L. Flora of the USSR. Volume 27, Shishkin BK & Bobrov EG (eds.), Dehra Dun: Bishen Singh, Mahendra Pal Singh and Koelz Scientific Books 1997, 1-70
- Susanna A., Garcia-Jacas N.: The tribe Cardueae In: Kadereit J & Kubitzki K (eds.). :Compositae: The Families and Genera of Vascular Plants. Heidelberg: Springer-Verlag 2007, 135-58
- Shukla Y.N.: Chemical, botanical and pharmacological studies on the genus Echinops: Review. J Medic Aromat Plant Sci 2003; 25(3):720-32.
- Al-Rawi A. :Wild plants of Iraq with their distribution. Volume 14,1964, 114p.
- Rechinger KH. : Flora Iranica Compositae III- Cynareae Akademische Druck-u. Verlagsanstalt Graz-Austria No. 139a, 1979.
- Y.N. Shukla, chemical, botanical and pharmacological studies on the genus Echinops : a review , J Med Arom Pl Sci 2003 25 :720-732
- 7 Abdel Rahman S.M., Abd-Ellatif S.A., Deraz S.F., Khalil A.A. : Antibacterial activity of some wild medicinal plants collected from western Mediterranean coast, Egypt: Natural alternatives for infectious disease treatment. Afr J Biotechnol 2011; 10(52):10733-10743.
- Toroğlu S., Keskin D., Vural C., Kertmen M., Çenet M. : Comparison of antimicrobial activity of *Echinops viscosus* Subsp. *Bithynicus* and *E. microcephalus* leaves and flowers extracts from Turkey. Int J Agric Biol 2012; 14(4):637-40.
- Bhanot A., Sharma R., Noolvi N. : Natural sources as potential anti-cancer agents: A review. International Journal of Phytomedicine 2011; 3: 09- 26.
- Agrawal M., Nahata A., Dixit K.:Protective effects of Echinops echinatus testosterone-induced prostatic hyperplasia in rats. Eu J I M 2012; 4(2):177-85.
- Abdulrazzaq H.M., Kadeem J.E. , Al-Mohannadi S.S. : Hepatoprotective effect of *Echinops tenuisetus* (Compositae) on CCl4 induced hepatic damage in rats. Iraqi J Pharm Sci 2008; 17 (1):16-24.
- Rad A., Najafzadeh H. , Farajzadeh A.: Evaluation of anti-ulcer activity of *Echinops persicus* on experimental gastric ulcer models in rats. Veterinary Research Forum 2010; 1(3):188-91.
- Evans W. C.:Trease and Evans Pharmacognosy (16th ed.); Elsevier: Science limited, UK, (2009), pp. 353-56
- J.B. Harborne, Phytochemical Methods, a guide to modern techniques of plant analysis, Chapman and Hall, New York, 1973
- Satyajit D. Sarker, Zahid latif, Alexander I. Gray Natural products isolation second edition 2006 humana Press Inc.
- Al-Sammak, A.M : A study of antimicrobial effect of oil extract of black seed (*Nigella sativa* L.) on some pathogenic microorganisms isolated from clinical pathogenic cases. Master Thesis. College of Veterinary Medicine, University of Baghdad. 2001
- Fahmi, Z. M : The effect of Aloe vera leaf gel in promoting wound healing and as an antibacterial agent. Msc. thesis. college of vet. Medicine. Uni of Baghdad. (2007)
- Parasuraman S. , Raveendran R. , Kesavan R : Blood sample collection in small laboratory animal. J Pharmacol Pharmacother 2010; 1(2): 87-93.
- Paulose CS, Dakshinamurti K. Chronic catheterization using vascular-access-port in rats: Blood sampling with minimal stress for plasma catecholamine determination. J Neurosci Methods 1987;22:141-6.
- Yoburn BC, Morales R, Inturrisi CE. Chronic vascular catheterization in the rat: Comparison of three techniques. Physiol Behav 1984;33:89-94.
- Mahmut Selvi, 2Fehmi Karataş, 3Şule Coşkun, 2Deniz Erbaş: Effect of L-NAME Administration on Plasma, Heart Tissue NO and MDA Levels in Rabbit Turkish Journal of Biochemistry-Turk J Biochem] 2007; 32 (4) ; 160-164
- Narendra Nalwaya, Gaurav Pokharna, Lokesh Deb, Naveen Kumar Jain: Wound Healing Activity Of Latex Of *Calotropis Gigantea*. International Journal Of Pharmacy And Pharmaceutical Sciences, Vol. 1, Issue 1, July-Sep. 2009
- Phillips GD, Whitehe RA, Kington DR. 1991. Initiation and pattern of angiogenesis in wound healing in the rats. American J Anatomy 192: 257-262.
- Rashed AN, Afifi FU, Disi AM. 2003. Simple evaluation of the wound healing activity of a crude extract of *Portulaca oleracea* L. growing in Jordan. J Ethnopharmacology 88:131-136.