

Anatomy 9535b. THE CRANIAL NERVES

CRANIAL NERVES

Twelve pairs of nerves that connect with the brain and pass through foramina in the base of the skull. They are:

- I. Olfactory (about 20 on each side)
- II. Optic (Not a nerve; part of the brain)
- III. Oculomotor
- IV. Trochlear
- V. Trigeminal
- VI. Abducent (or abducens)
- VII. Facial (= n. intermedius & facial n.)
- VIII. Vestibulocochlear (= vestibular & cochlear)
- IX. Glossopharyngeal
- X. Vagus
- IX. Accessory (also called spinal accessory)
- XII. Hypoglossal.

- I. Olfactory (about 20 on each side)

SPECIAL VISCERAL AFFERENT

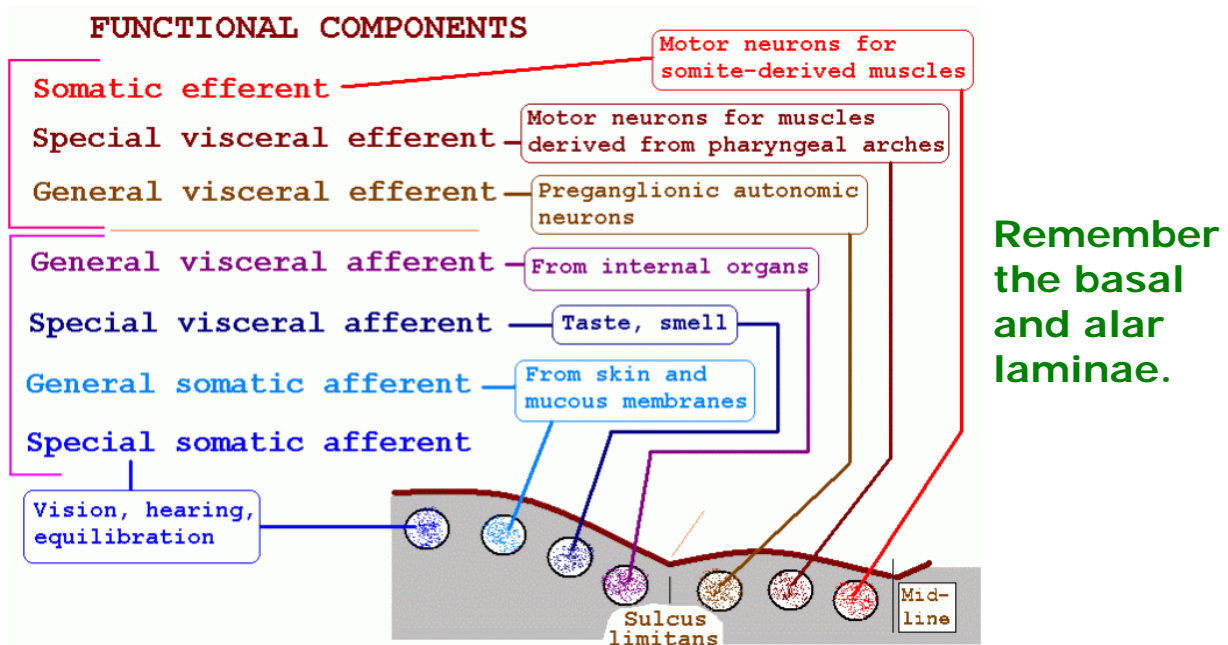
Neurons in the olfactory epithelium send axons through cribriform plate to the olfactory bulb.

— II. Optic (Not a nerve; part of the brain)

SPECIAL SOMATIC AFFERENT

Principal cells ("ganglion cells") of retina send axons through optic nerve, chiasma and tract

to: - pretectal area
- superior colliculus
- lateral geniculate body.



This is the traditional scheme of Charles Judson Herrick (1868-1960), based on comparative anatomy and descriptive embryology. C. J. Herrick, an American neuroanatomist, was for 54 years the editor of the *Journal of Comparative Neurology*, which was founded by his brother Clarence.

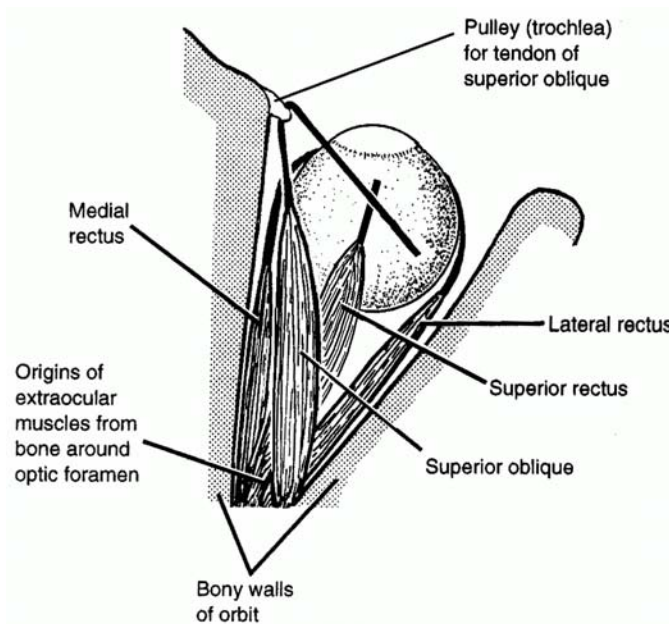
Note that **somatic efferent** is not subdivided into special and general, although ordinary muscle innervation is “**general**” in character, because most skeletal muscles develop from somites.

The term “**special somatic efferent**” could be used for centrifugal fibres of the vestibulocochlear nerve (and, in birds and perhaps other vertebrates, in the optic nerve). The centrifugal fibres in VIII were discovered in 1942, long after the publication and general acceptance of Herrick’s classification of nerve components.

Some authorities do not agree with the separation of nuclei of motor neurons into the SE and SVE categories, and the axons in the pituitary stalk (with cell bodies in the hypothalamus) have been proposed as a midline cranial nerve. See Butler, A. B. & Hodos, W. (1996) *Comparative Vertebrate Neuroanatomy*. New York: Wiley-Liss.

Classifications of nerve components disregard **postganglionic fibres** of the autonomic system, even though they are present in all branches of spinal nerves and most branches of cranial nerves. Functionally, these unmyelinated axons of cells in sympathetic, parasympathetic and enteric ganglia are general visceral efferent.

EYE MOVEMENTS. First, we must look at the muscles and their actions.



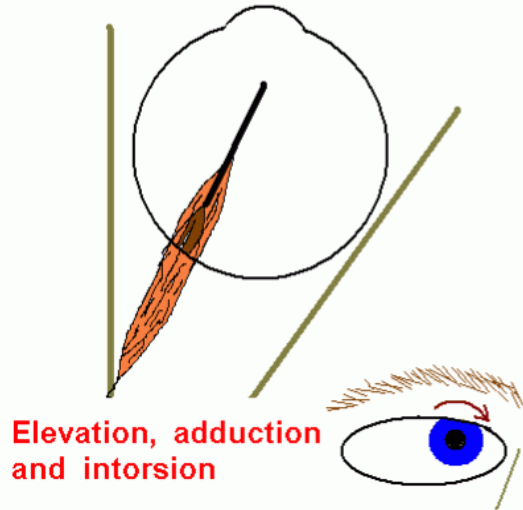
Right orbit, viewed from above.

Not shown: Inferior rectus
Inferior oblique
Levator palpebrae superioris

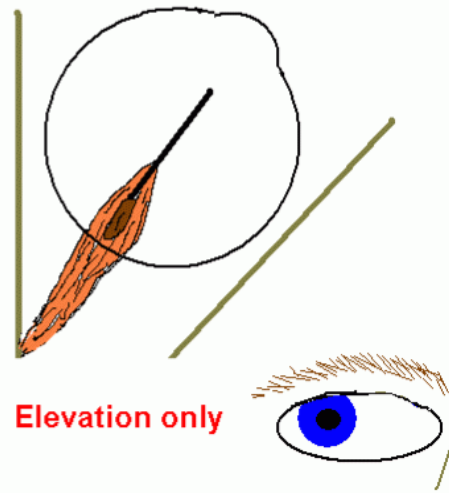
A muscle's action varies with the initial position of the eye.

Example: Right superior rectus

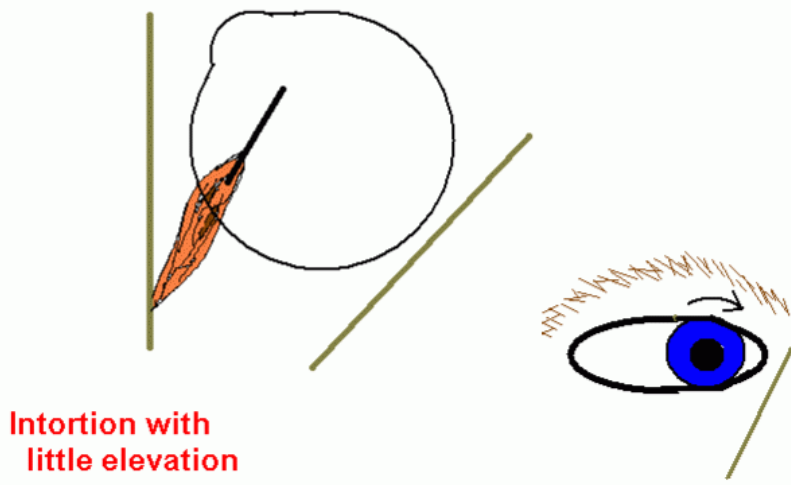
Eye looking straight forward



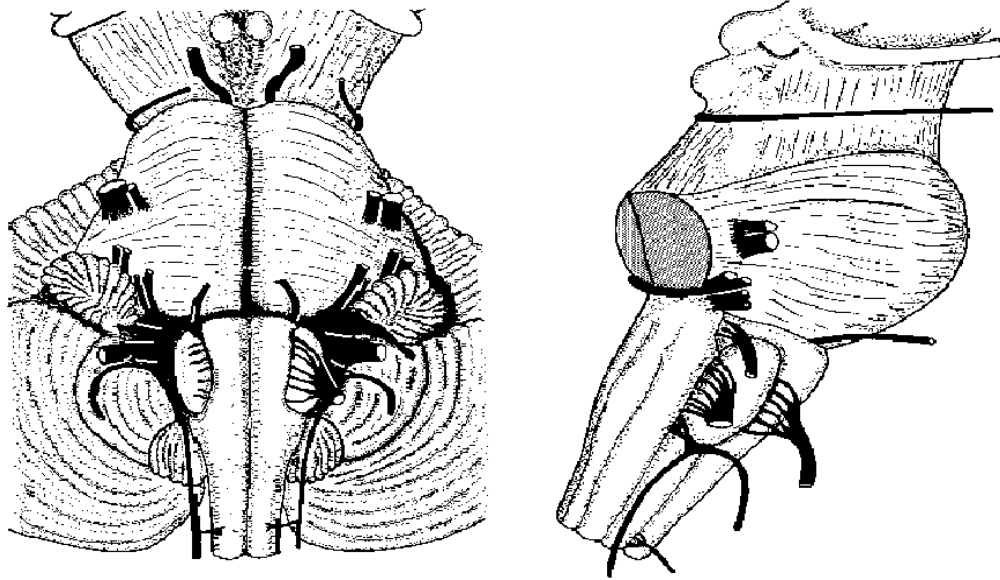
Eye abducted



Eye adducted



The oculomotor nerve emerges from the medial surface of the cerebral peduncle of the midbrain.

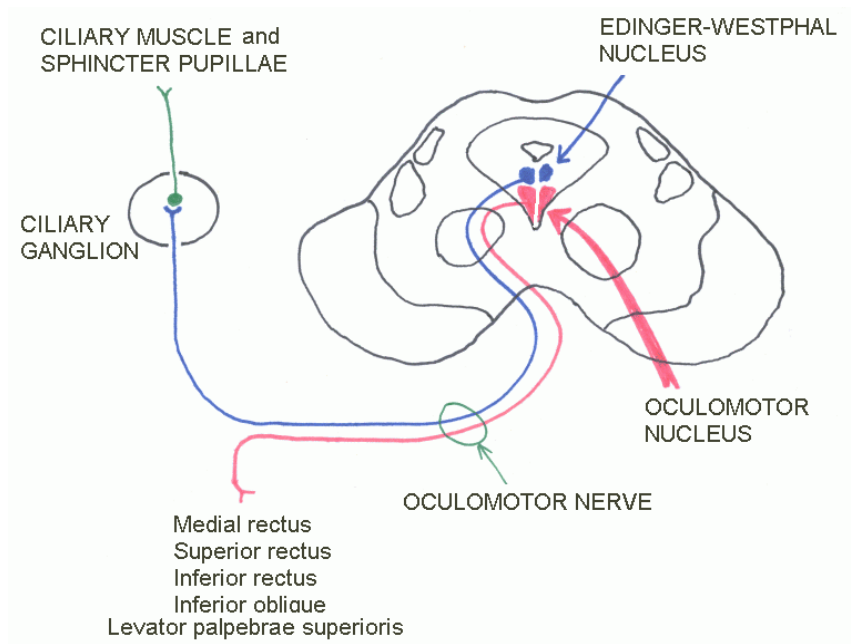


Trochlear nerve emerges from dorsal surface of midbrain, below the inferior colliculus.

Abducens nerve emerges from ponto-medullary junction, rostral to the pyramid of the medulla.

Cranial nerve III has two components: Somatic motor
 Preganglionic parasympathetic

Midbrain at the level of the superior colliculus



Accommodation of the lens - 1.



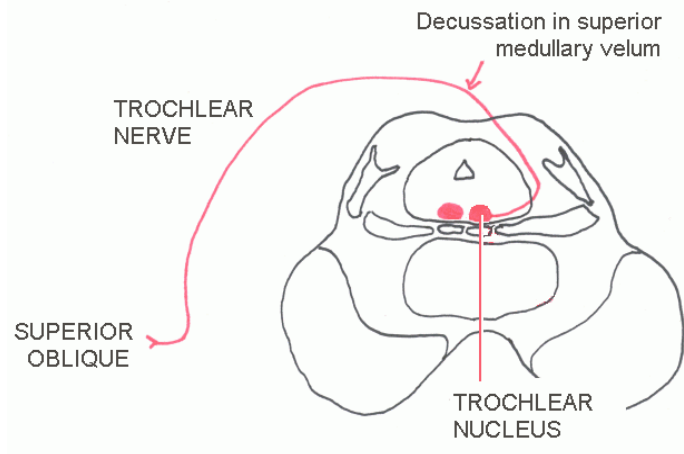
Ciliary muscle relaxed. Intra-ocular pressure keeps suspensory ligament of lens taut, so that lens is flattened. Distant objects are then focussed on the retina.

Accommodation of the lens - 2.

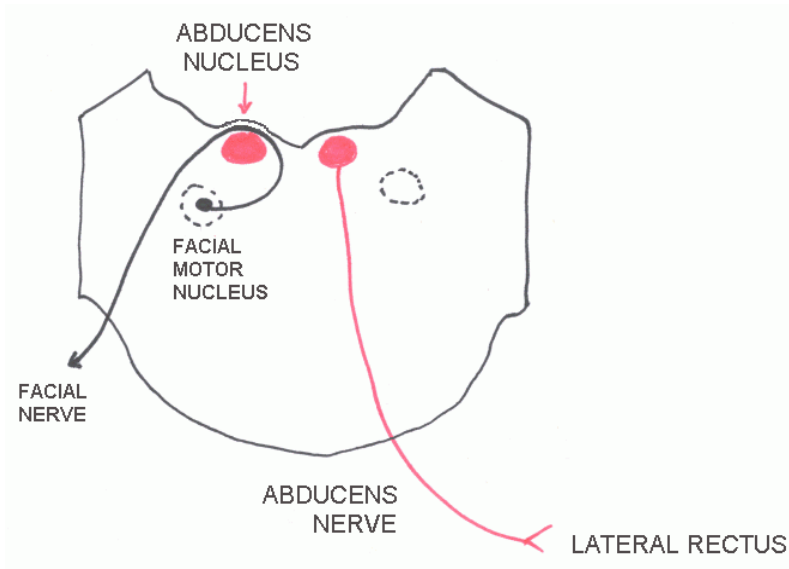


Ciliary muscle contracted. This takes tension off the suspensory ligament, so that the lens can assume a more globular form. This tendency to become globular is a physical property of the lens and its capsule.

Refraction occurs at the air-cornea and lens-vitreous interfaces. Thickening of the lens in accommodation shortens the focal length of the whole cornea-aqueous-lens system.

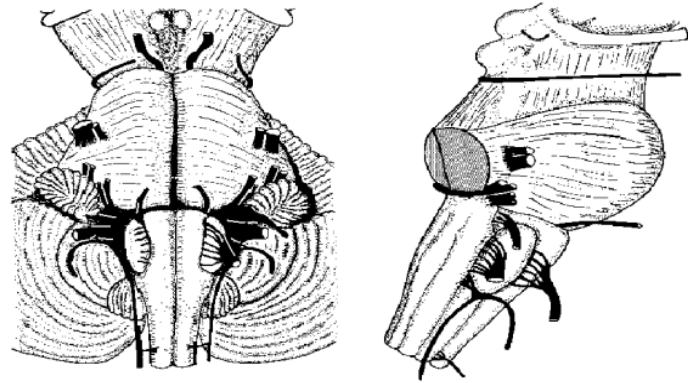


Midbrain at the level of the inferior colliculus



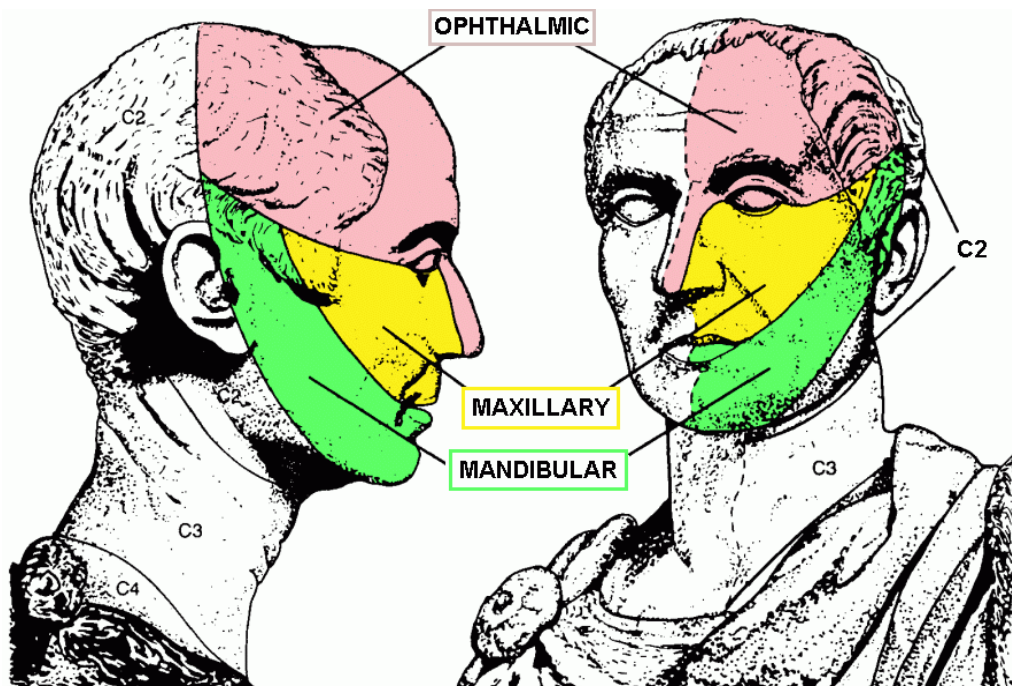
Caudal pons, just rostral to its junction with the medulla

The trigeminal nerve emerges as a large motor and a small sensory root at mid-pontine level, marking the junction of the basal pons with the middle cerebellar peduncle.

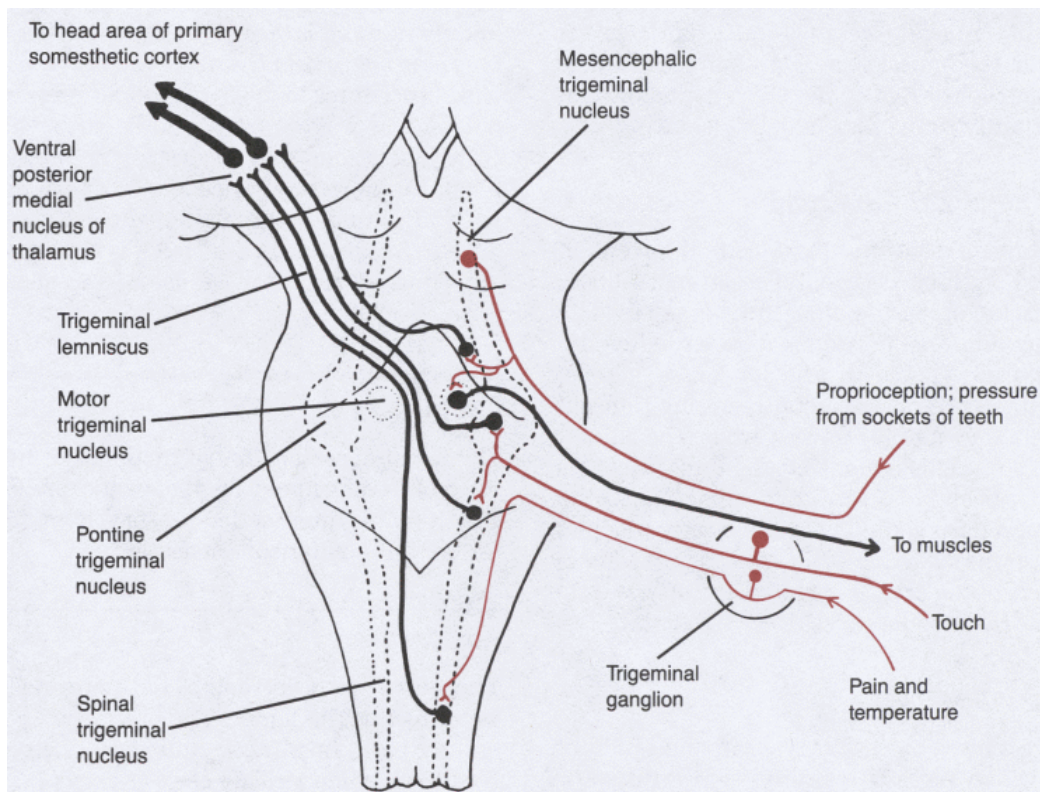


The nerve has three major branches (divisions) with different sensory territories.

Motor fibres are all in the mandibular division.



The sensory trigeminal nuclei serve different sensory modalities.



Spinal trigeminal nucleus also receives somatic sensory fibres from all other cranial nerves that have general somatic afferent components: VII, IX and X.

TRIGEMINAL NERVE

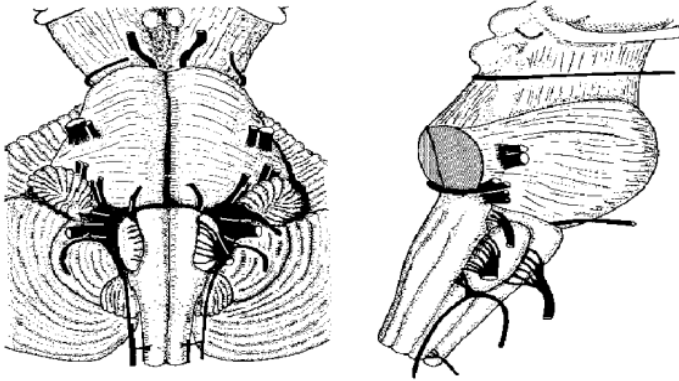
Sensory – skin and mucous membranes of head

Different central connections for proprioception, touch, pain & temp.

Motor – muscles of mastication, and a few others

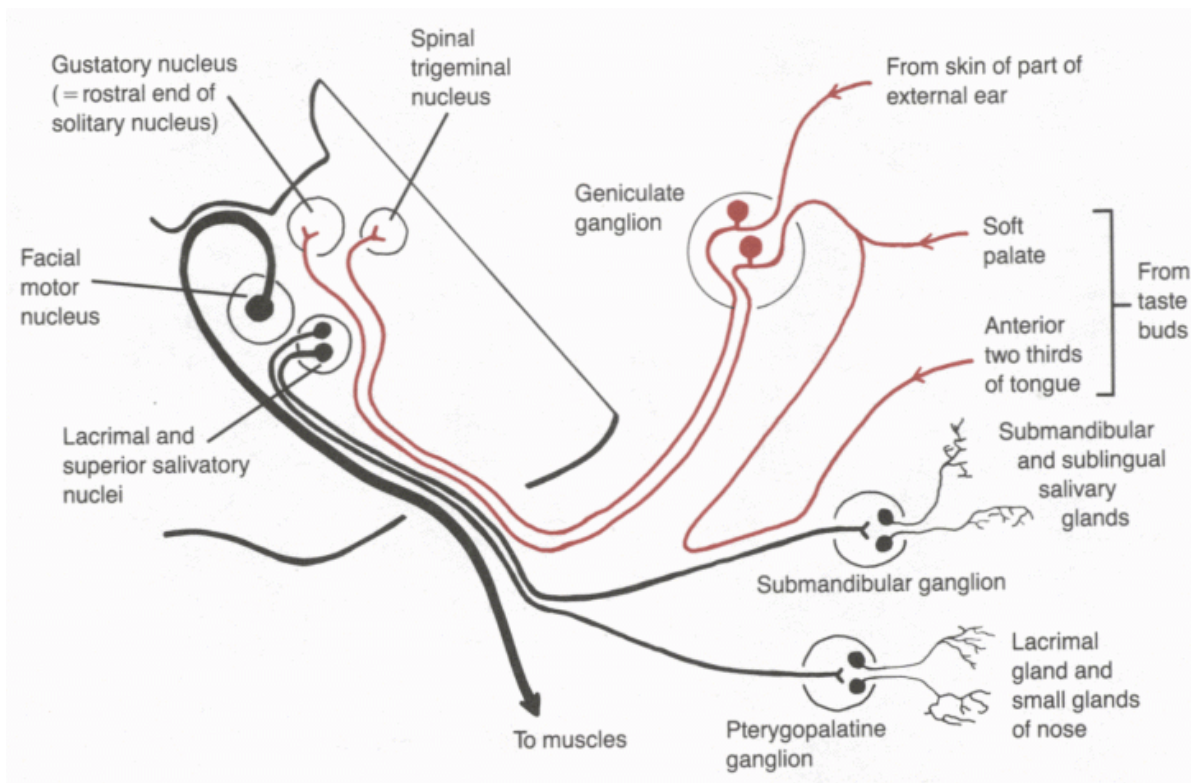
Disorders.

Herpes zoster
Trigeminal neuralgia



The facial nerve emerges from the pontocerebellar angle, as two roots: motor (larger), and the nervus intermedius (sensory and preganglionic parasympathetic).

As it leaves the cranial cavity the nerve passes through the region of the middle ear, where it gives off its small sensory and preganglionic branches (and one motor branch). Only fibres that supply facial muscles emerge from the stylomastoid foramen.



FACIAL NERVE

Motor - Muscles of face Stapedius

Preganglionic parasympathetic

- to pterygopalatine ganglion (for lacrimal and nasal glands)
- to submandibular ganglion (for submandibular and sublingual glands)

Sensory - Taste, anterior 2/3 of tongue

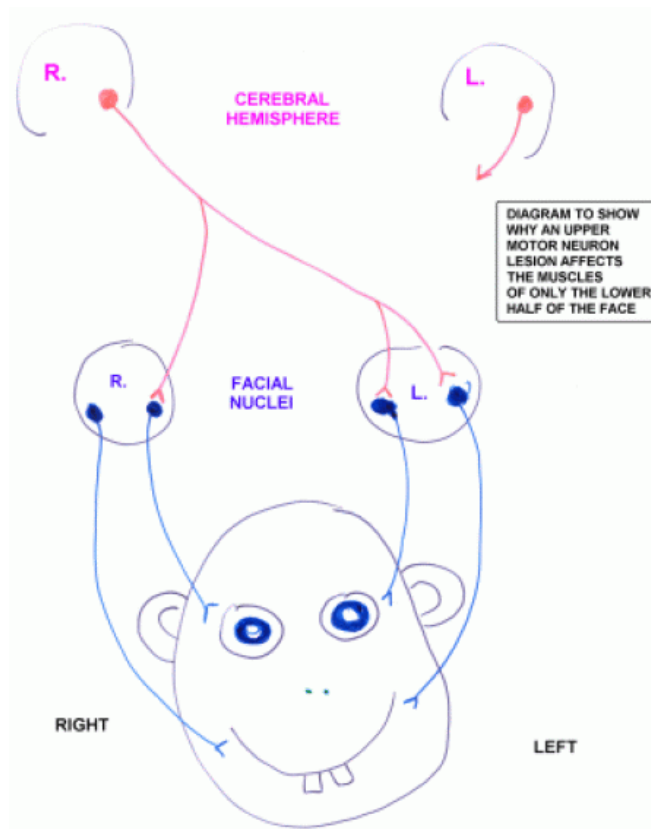
- small area of skin of ear

The masticatory (V), facial (VII) and pharyngeal (IX, X) muscles are traditionally considered “visceral” — innervated by special visceral efferent or “branchiomotor” fibres. Motor neurons are in the facial motor nucleus.

The preganglionic autonomic fibres constitute the general visceral efferent component of the facial nerve. Cell bodies are in the lacrimal and superior salivatory nuclei.

Taste is a special visceral afferent sensation. Fibres go to rostral end of the solitary nucleus, in the medulla.

Central projection of the small general somatic afferent component is to the spinal trigeminal nucleus.



FACIAL PARALYSIS

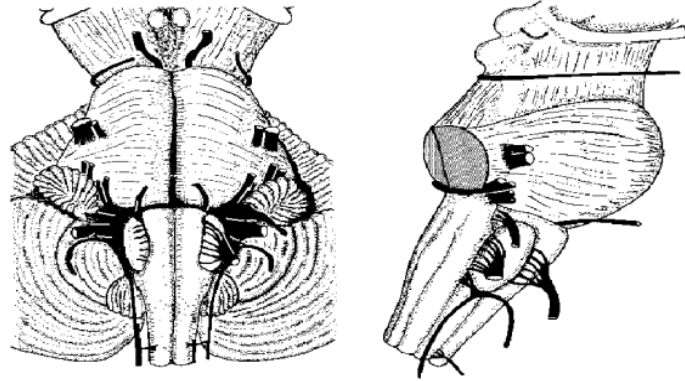
Lower motor neuron lesion: cell bodies in facial motor nucleus or their axons in brain stem or facial nerve. Ipsilateral paralysis or weakness of upper and lower facial muscles.

Upper motor neuron lesion: cerebral cortex or corticobulbar fibres (*e.g.* internal capsule). Contralateral paralysis or weakness of only the lower facial muscles.

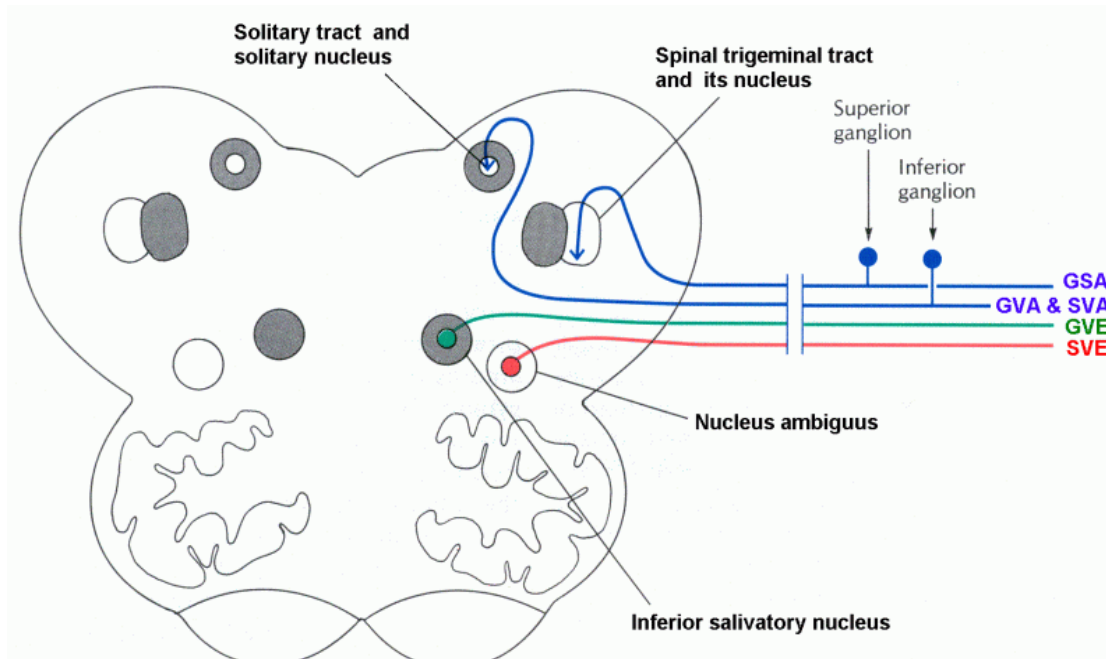
The glossopharyngeal and vagus nerves emerge from the medulla as rootlets, from the sulcus between the olive and the inferior cerebellar peduncle.

The cranial root of the accessory nerve is formed from caudal vagal rootlets.

The rootlets of the hypoglossal nerve emerge more ventrally, from the sulcus between the olive and the pyramid.



GLOSSOPHARYNGEAL NERVE. Nuclei and components.



GLOSSOPHARYNGEAL NERVE

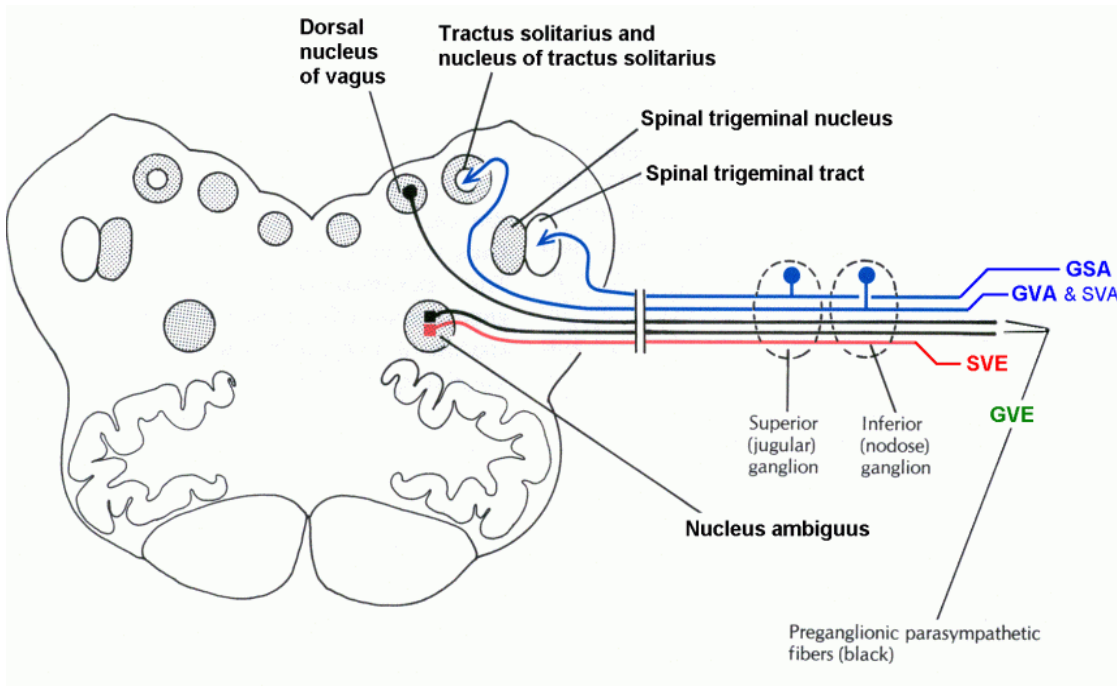
Sensory – Posterior 1/3 of tongue
Pharynx
Middle ear

Preganglionic parasympathetic

– to otic ganglion (parotid gland)

Motor – One small muscle (stylopharyngeus)

VAGUS NERVE. Nuclei and components.



VAGUS NERVE

Motor – Muscles of larynx and pharynx

Sensory – visceral reflexes
– small area of skin of ear

Preganglionic parasympathetic

– small ganglia associated with internal organs.

Slows heart

Stimulates gastric secretion

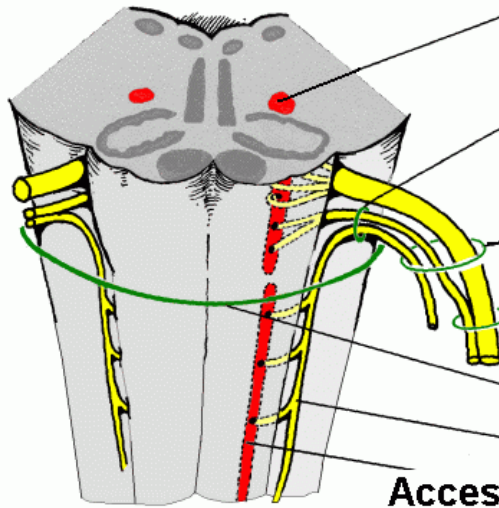
Empties stomach

In terms of gross anatomy the vagus nerve “supplies” the heart, stomach etc. In fact the vagal fibres are preganglionic: they synapse with autonomic neurons in cardiac and enteric ganglia. Neurons in these autonomic ganglia innervate cardiac and smooth muscle and glands.

ACCESSORY NERVE. Nuclei, roots, branches.

XI Special visceral efferent

Nucleus ambiguus



**Accessory nerve,
composed of cranial
and spinal roots**

Jugular foramen

Vagus nerve

Foramen magnum

**Spinal root
of XI**

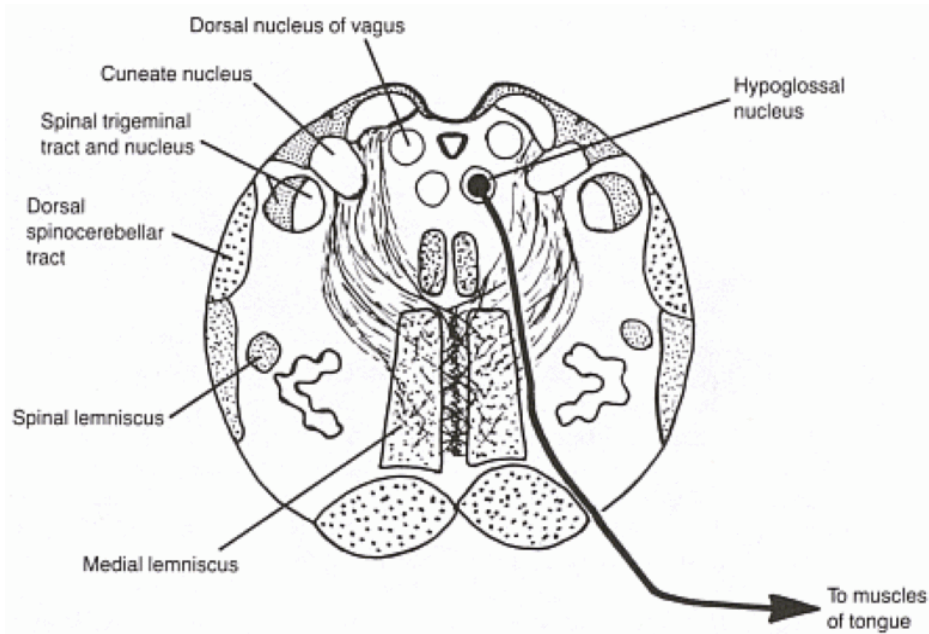
**Accessory
nucleus
(C1 – C5)**

(The spinal rootlets of XI
emerge just dorsal to the
denticulate ligament.)

Larynx (nucleus ambiguus);
Trapezius and
sternocleidomastoid (spinal
root of XI)

HYPOGLOSSAL NERVE

The skeletal muscles that move and compose the tongue develop from somites rather than branchial arches. The nerve that supplies these muscles is traditionally classified as somatic efferent, not special visceral efferent.



HYPOGLOSSAL NERVE

Motor - Extrinsic and intrinsic muscles of tongue

Hypoglossal nerve palsy

When protruded, the tongue deviates towards the paralysed side.