

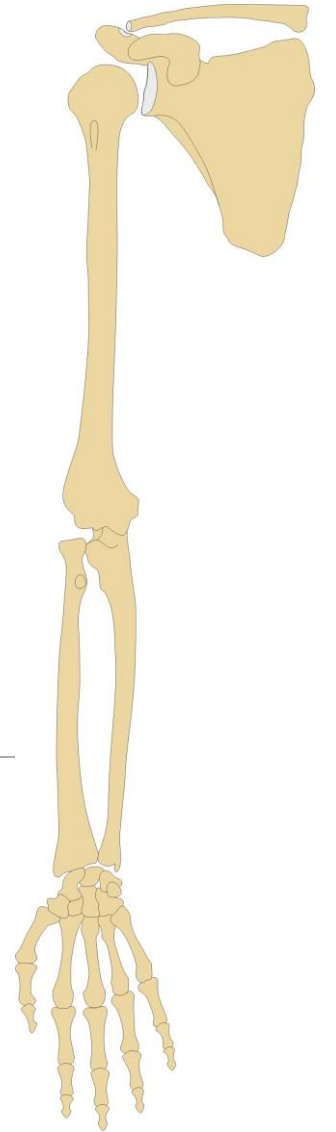
# SPECIAL ARTHROLOGY

## Connections of the upper limb (*juncturae ossium membri superioris*)

---

RNDr. Michaela Račanská, Ph.D.

Lecture 8 – DENTISTRY – Autumn 2016

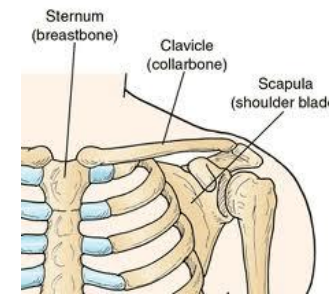


## Connections of the shoulder girdle:

scapula + clavicle – art. acromioclavicularis

clavicle + sternum – art. sternoclavicularis

## Syndesmoses of the shoulder blade



## Connections of the free upper limb:

Humerus + scapula – art. humeri

Humerus + radius + ulna – art. cubiti

Radius + ulna – membrana interossea antebrachii  
– art. radioulnaris distalis

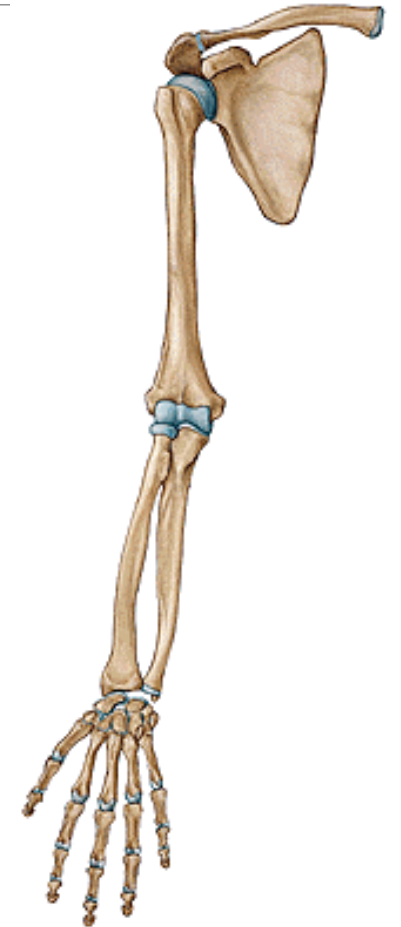
Radius + carpal bones – art. radiocarpea

Carpal bones – art. mediocarpea

carpal + metacarpal bones – art. carpometacarpea

Metacarpal bones + phalanges proximales – art. metacarpophalangea

Phalanges – art. interphalangea manus



## I. Articulatio sternoclavicularis

*Type:* compound joint- discus articularis  
ball and socket (movements in connection to the scapula movements)

*A. head:* facies articularis sternalis claviculae

*A. fossa:* incisura clavicularis manubrii sterni

*AC:* tough, short

*Ligaments:*

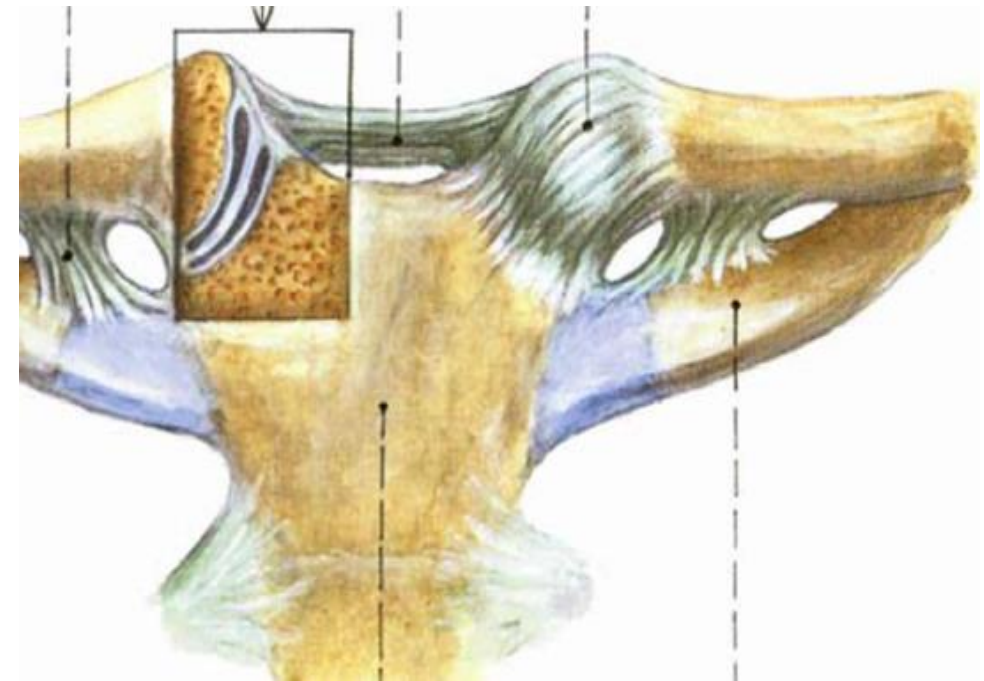
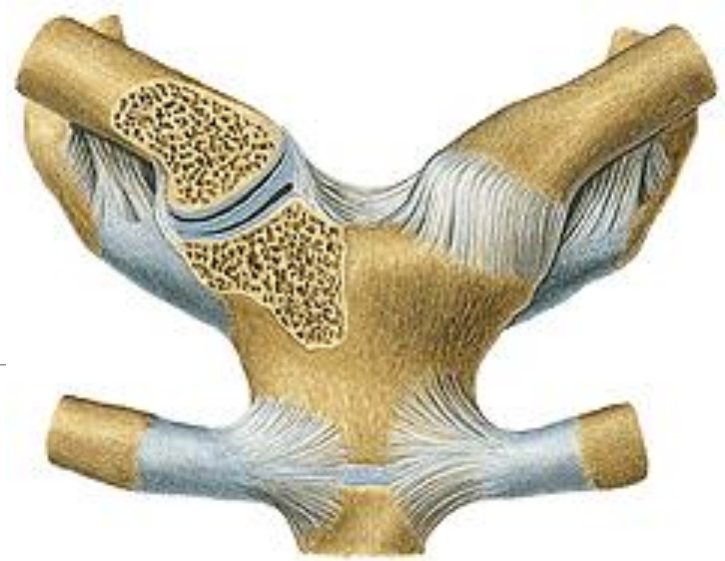
lig. sternoclaviculare anterius

lig. sternoclaviculare posterius

lig. interclaviculare

lig. costoclaviculare

*Movements:* small, to all direction



## II. Articulatio acromioclavicularis

*Type:* ball and socket, sometimes discus articularis

*AS:* facies art. acromialis (clavicula) + facies art. acromii (scapula)

*AC:* tough, short

*ligaments:*

lig. acromioclaviculare

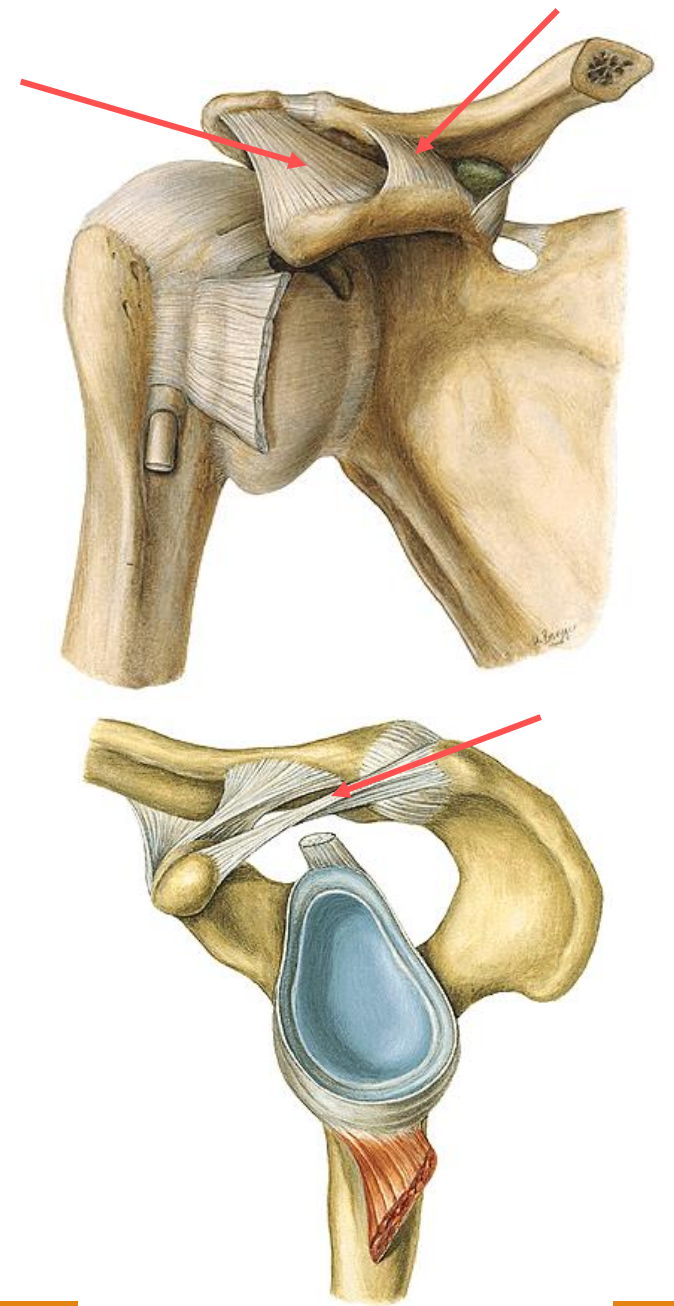
lig. coracoclaviculare (lig. trapezoideum + lig. conoideum)

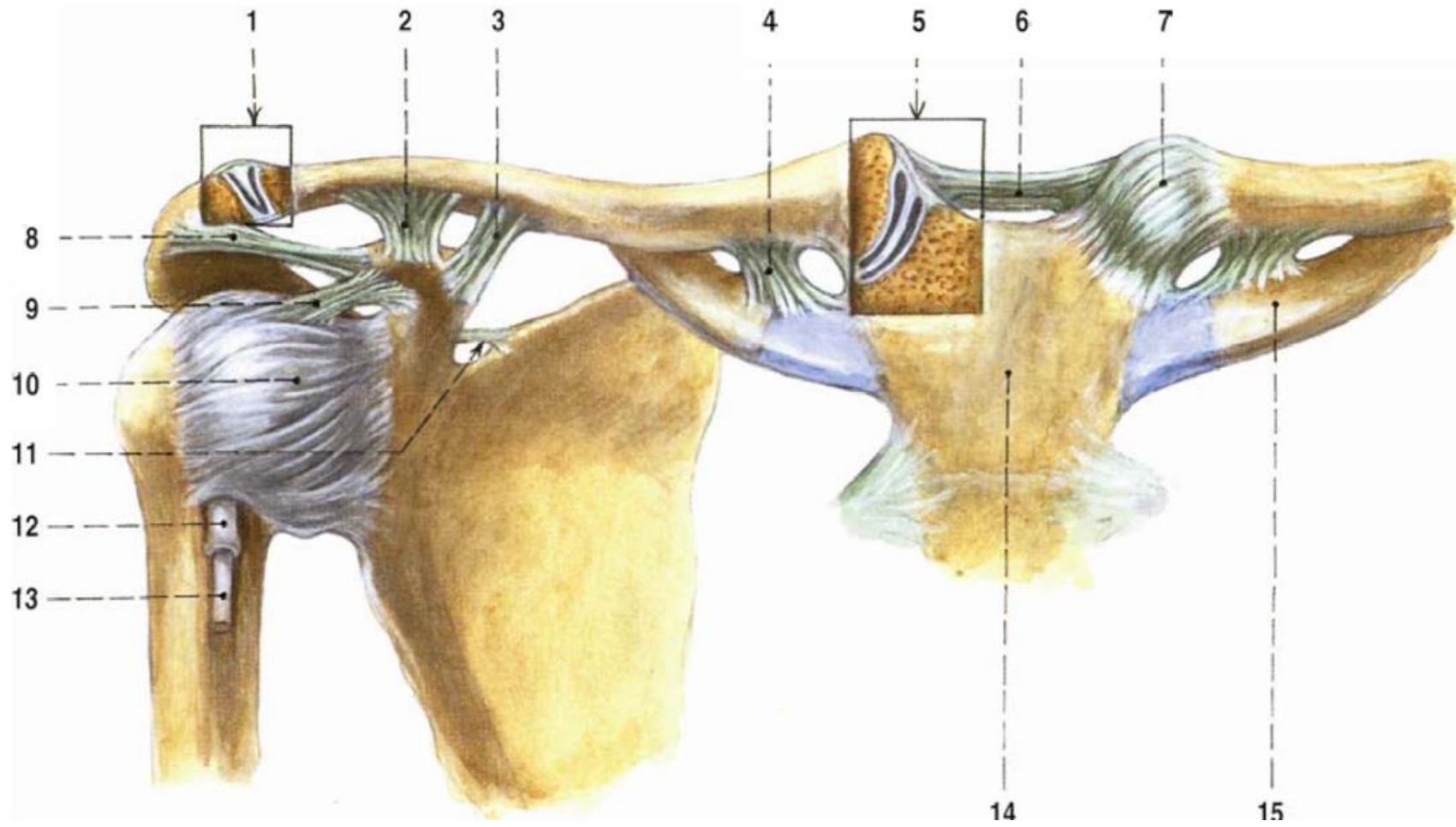
lig. coracoacromiale - fornix humeri

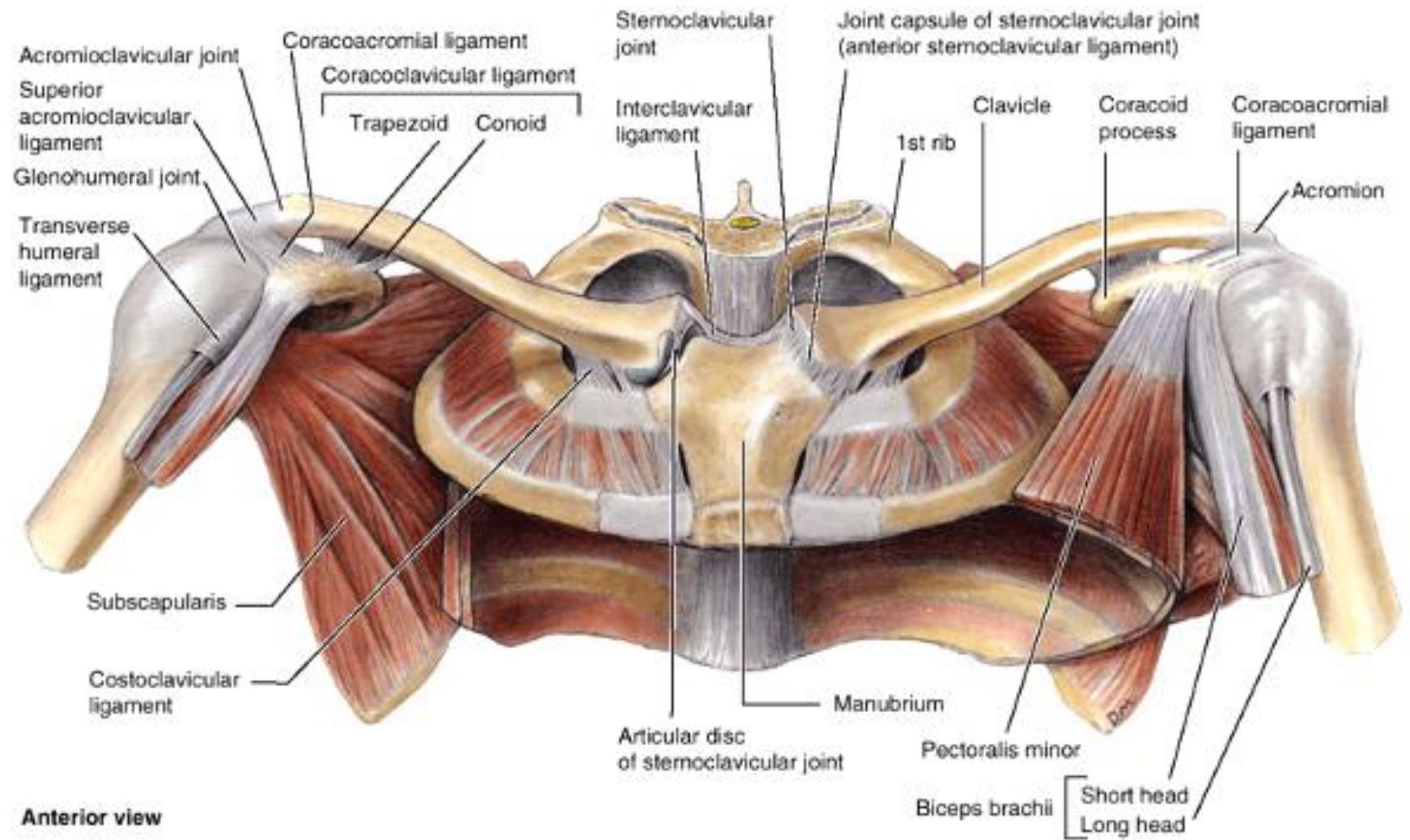
lig. transversum scapulae

*movements:*

restricted, in connections with movements in sternoclavicular joint







## Syndesmoses of the shoulder blade:

lig. transversum scapulae

lig. coracoacromiale - fornix humeri

## Movements of the scapula:

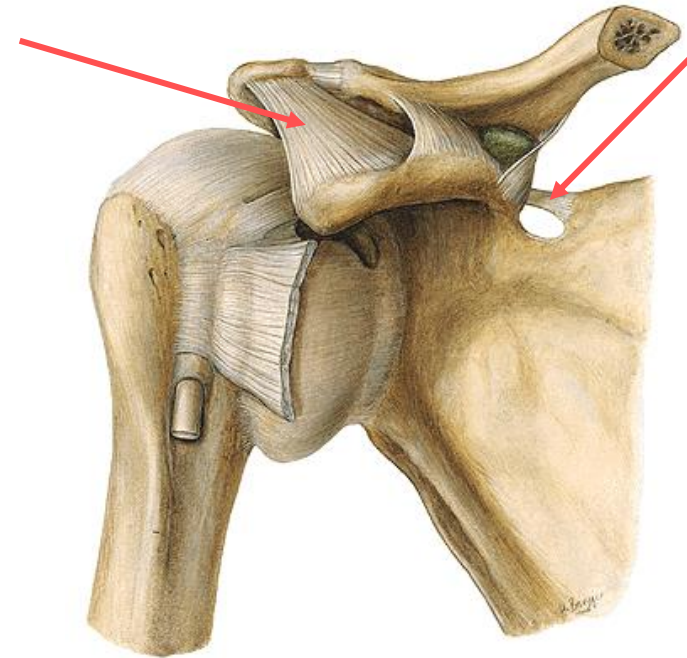
Retraction

Protraction

Elevation

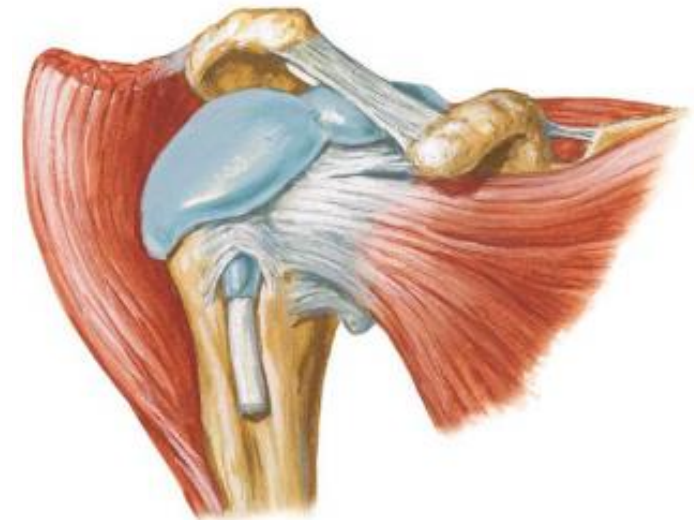
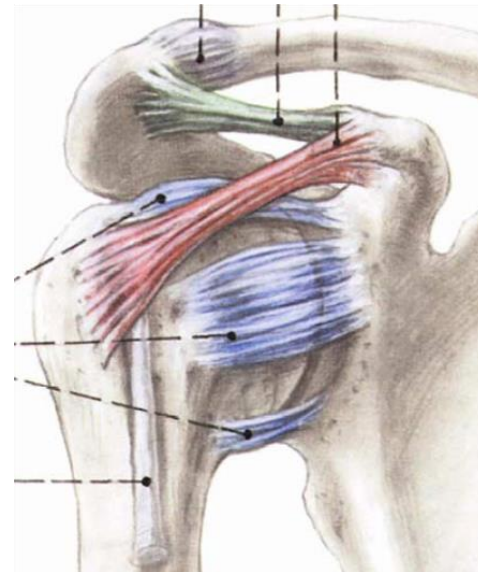
Depression

Rotation

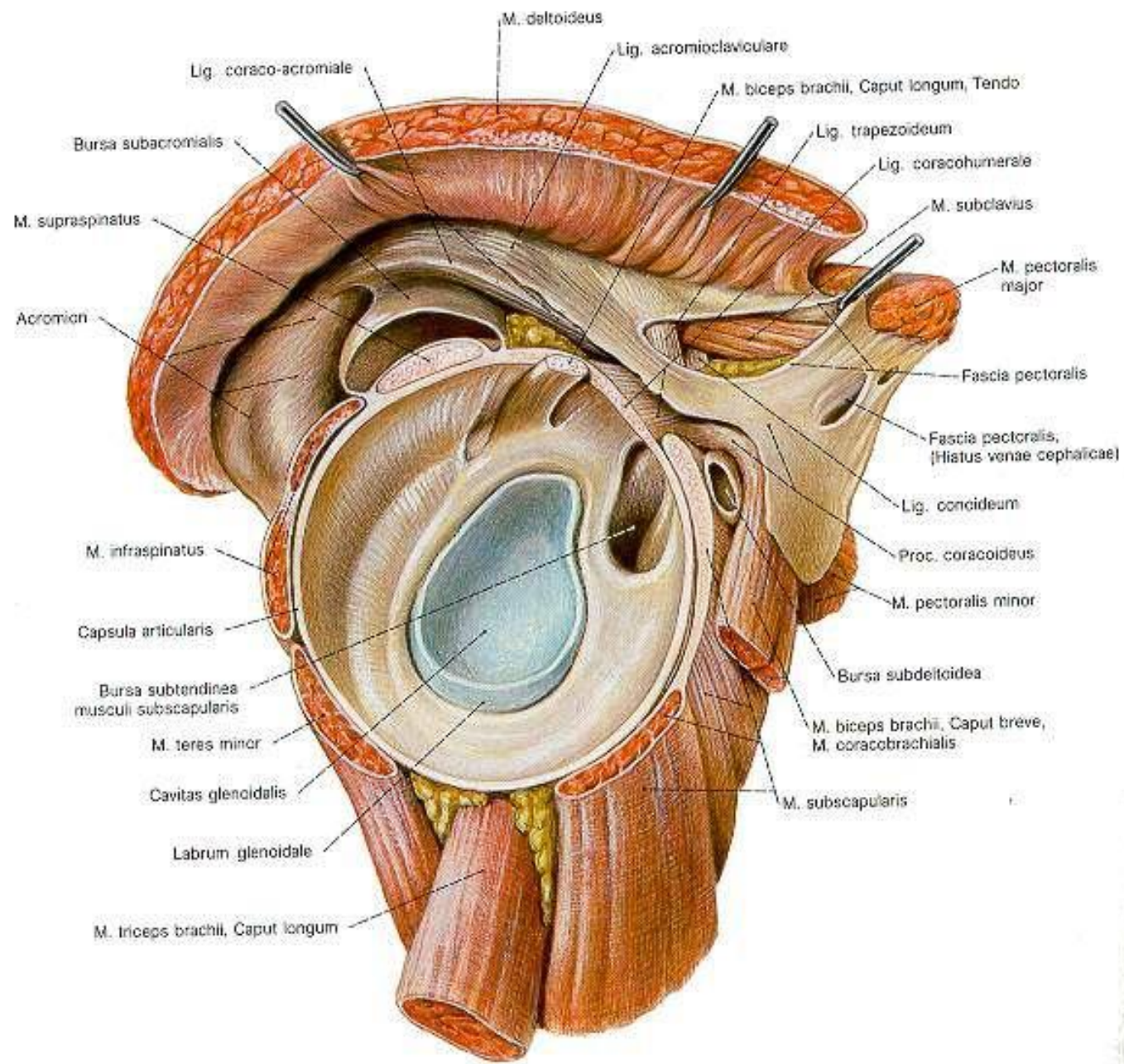


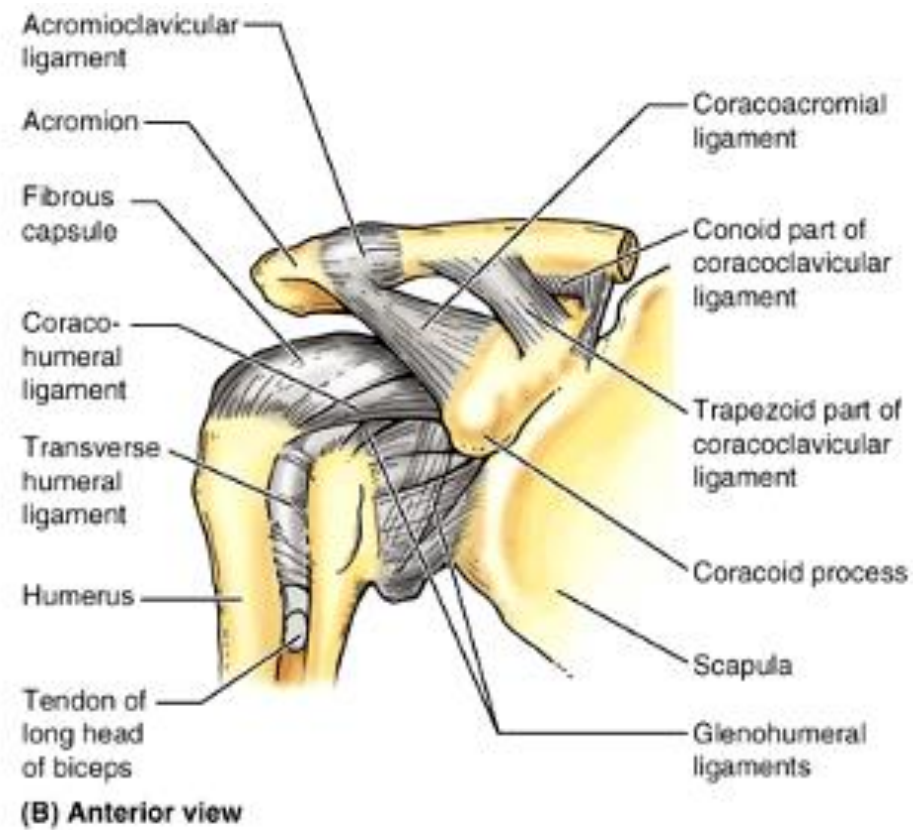
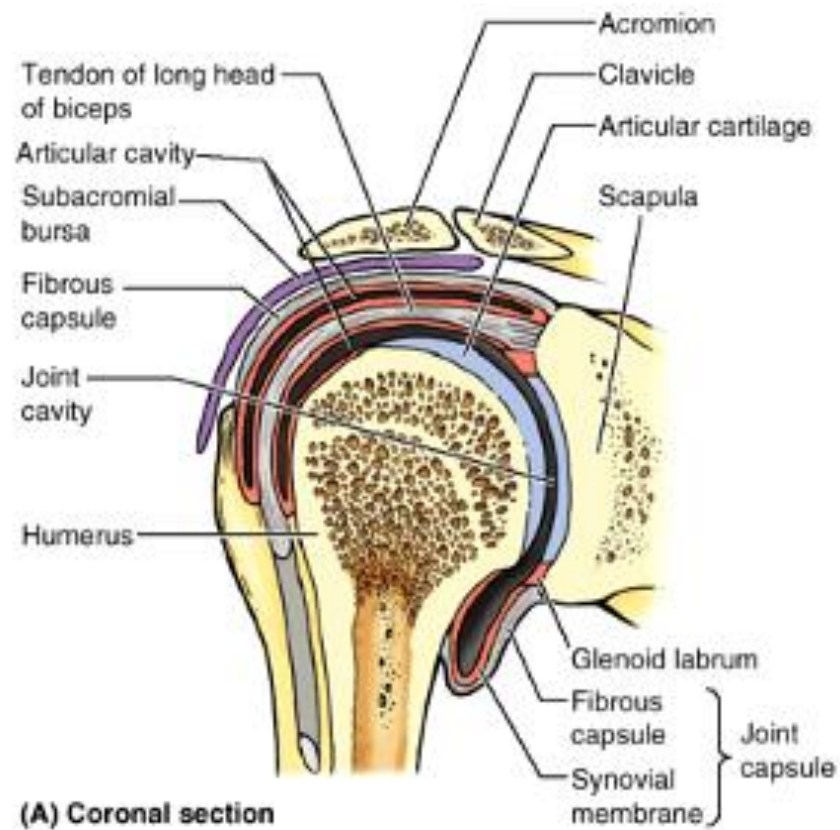
# Glenohumeral joint (art. humeri)

- Ball-and-socket → wide range of movement ARTHRODIA (its mobility makes the joint relatively unstable)
- AS: humeral head articulates with the relatively shallow glenoid cavity of the scapula – deepened by the ring-like fibrocartilaginous glenoid labrum
- AC: from the margins of the pits to the collum anatomicum humeri, at the ventral side makes synovial layer around the long head of biceps
- Ligaments:
  - **lig. coracohumerale**
  - **ligg. glenohumeralia**
  - **lig. coracoacromiale (fornix humeri)**
  - **Bursa subacromialis, subcoracoidea, subdeltoidea**









**MOVEMENTS:**

**Ventral and dorsal flexion**

**abduktion**

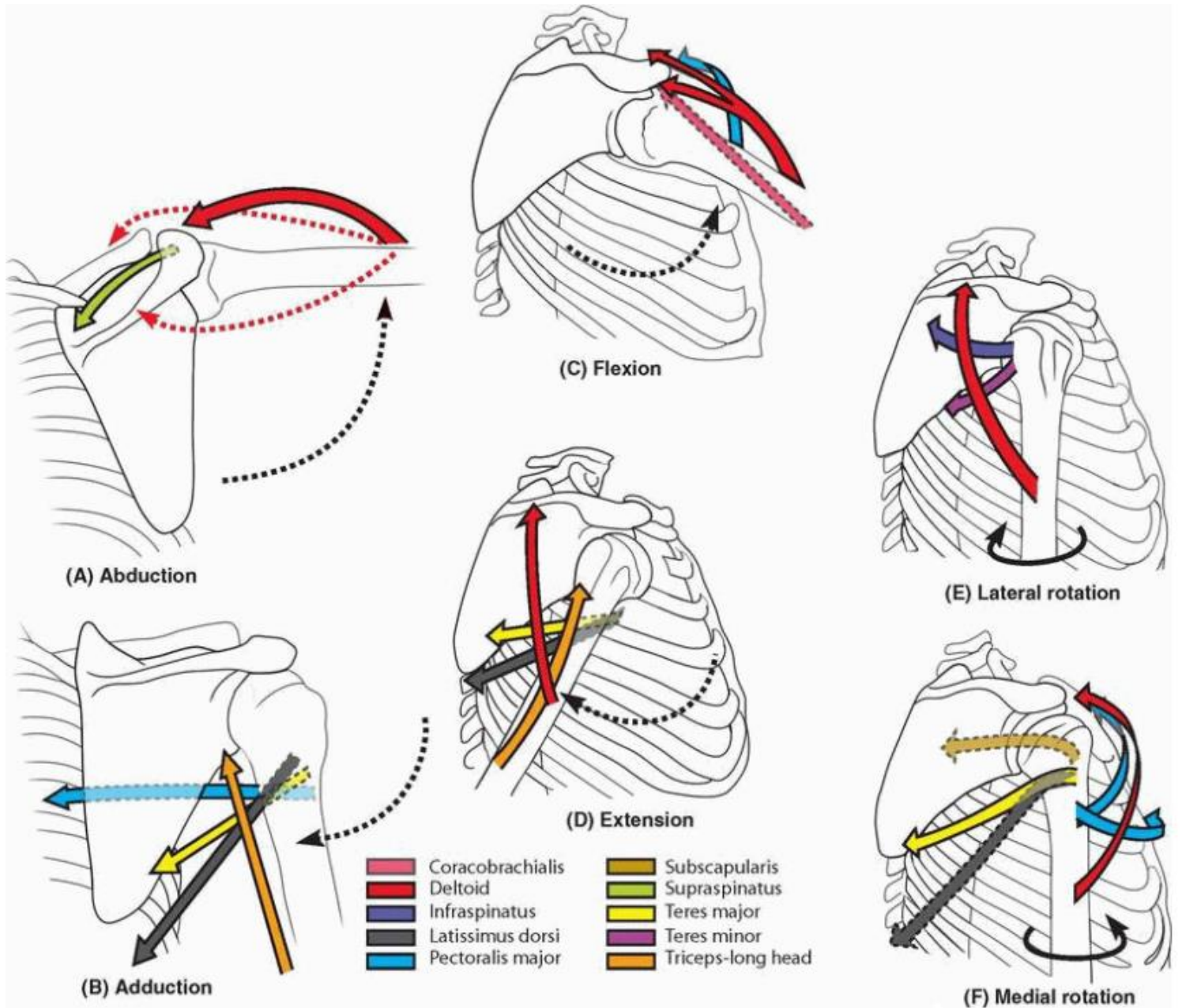
**(from the horizontal plane together  
with movements of the scapula)**

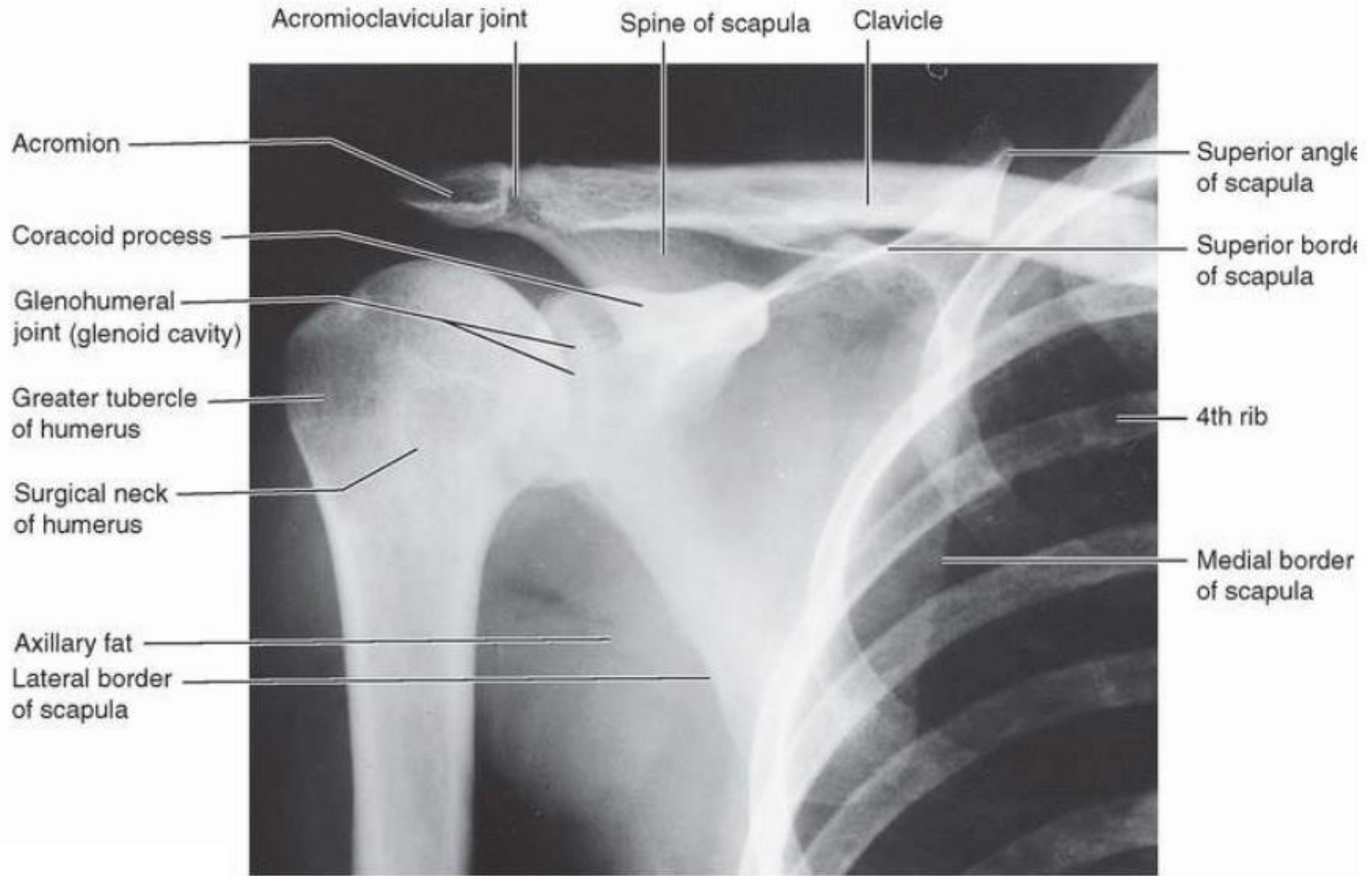
**adduktion**

**rotation - supination, pronation**

*Middle position:*

**Slow flexion and small abduktion**





# Articulations of the forearm

## ELBOW JOINT (ART. CUBITI)

Type: compound joint

### Articulatio humeroulnaris

Type: hinge

A. head: trochlea humeri

A. fossa: incisura trochlearis ulnae

### Articulatio humeroradialis

Type: ball and socket

A. head: capitulum humeri

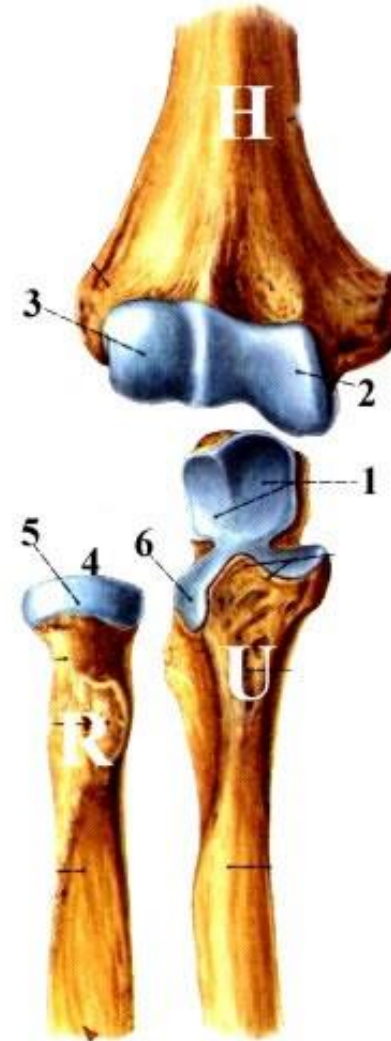
A. fossa: fovea articularis radii

### Articulatio radioulnaris proximalis

Type: pivot

A. head: circumferentia articularis radii

A. fossa: incisura radialis ulnae



AC: common for all three parts, attach to the margins of AS, at radius to the collum - recessus sacciformis

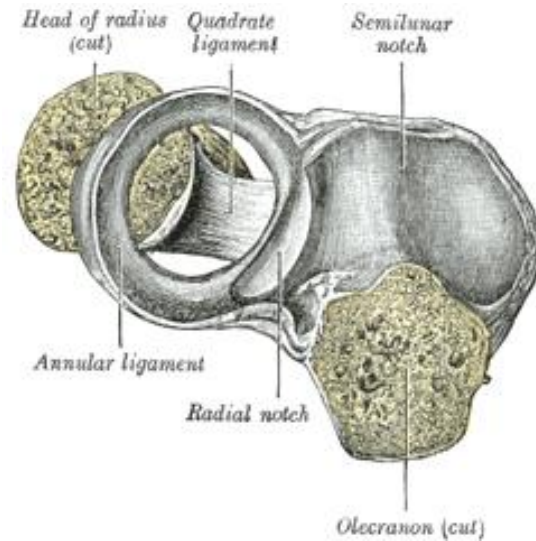
*Ligaments:*

lig. collaterale radiale

lig. collaterale ulnare

lig. obliquum

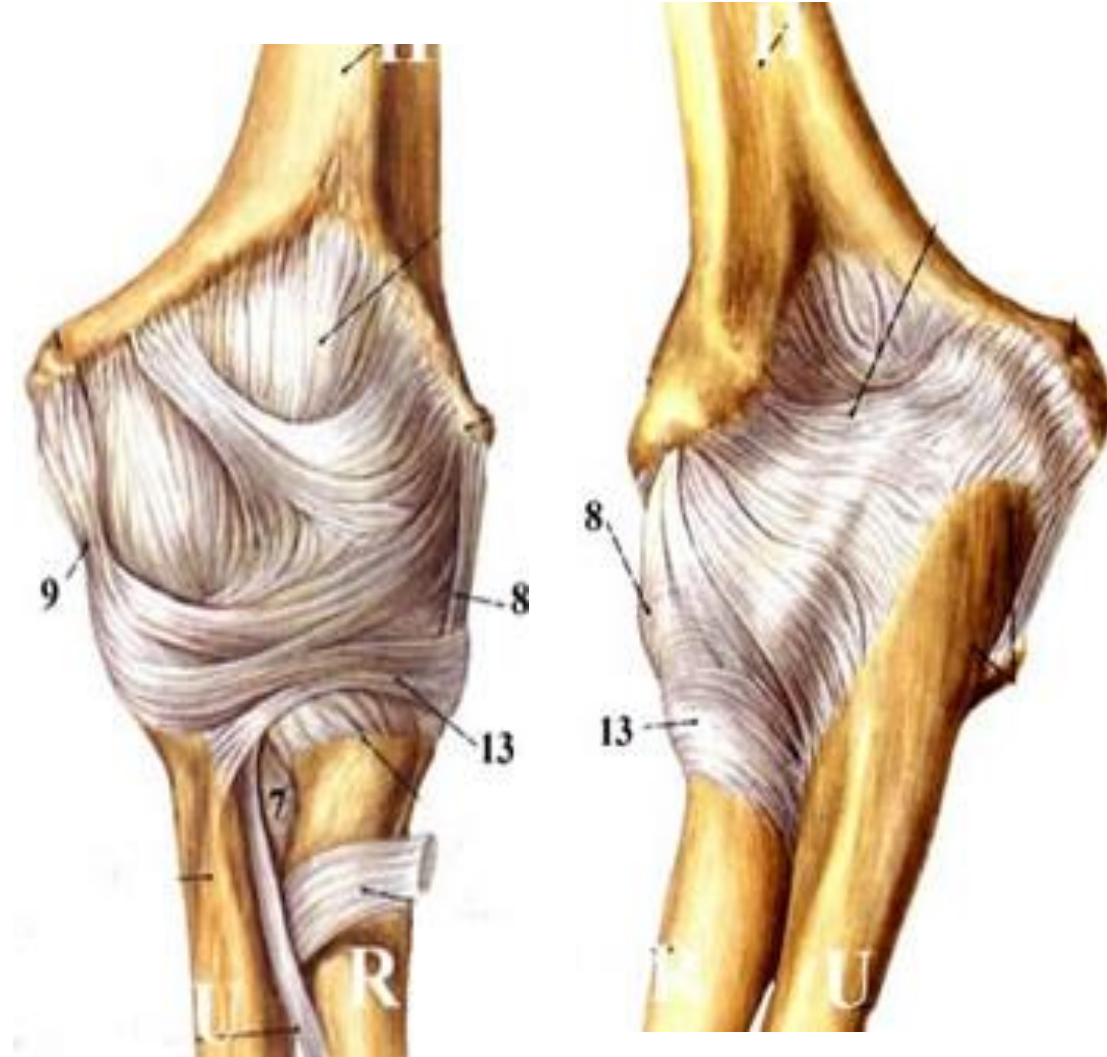
lig. anulare radii

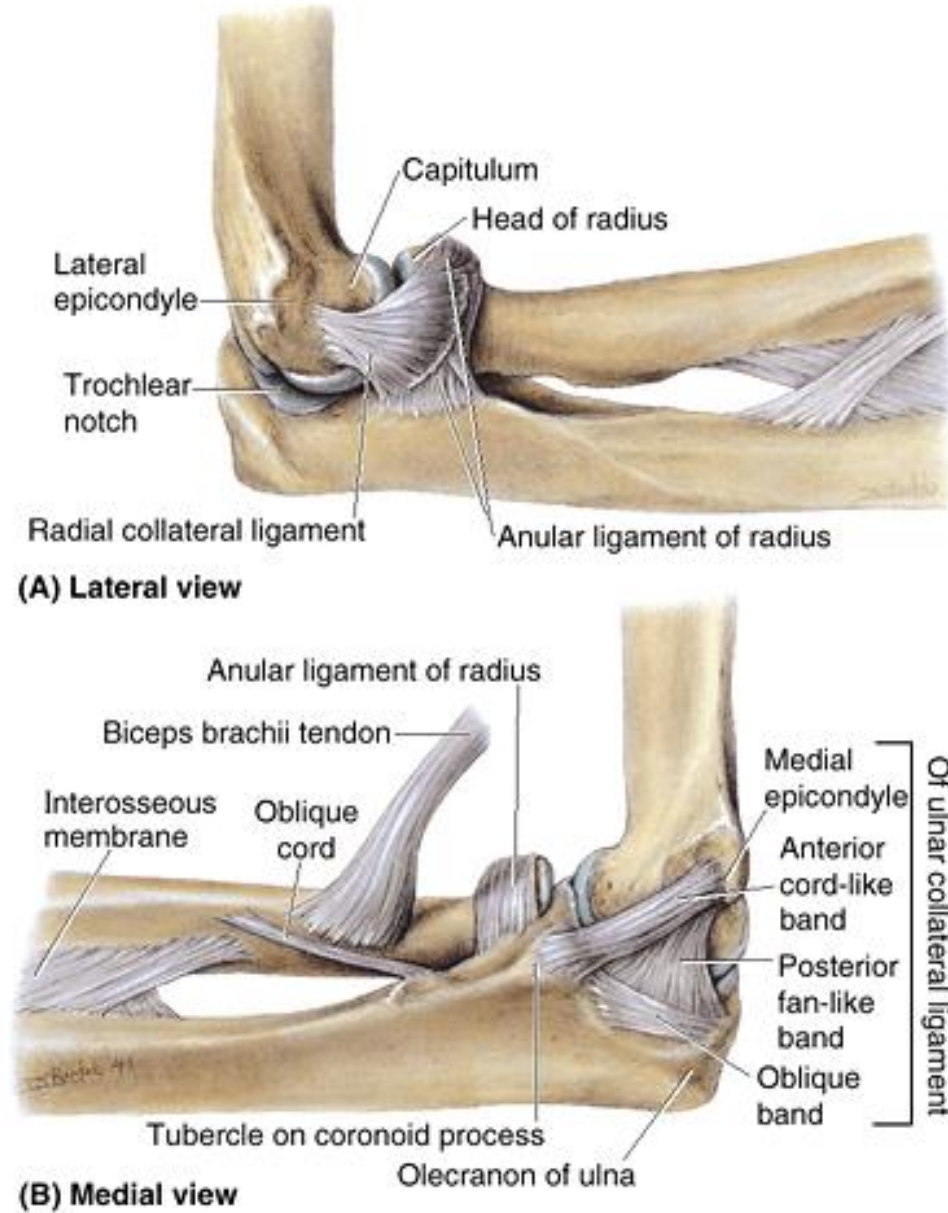
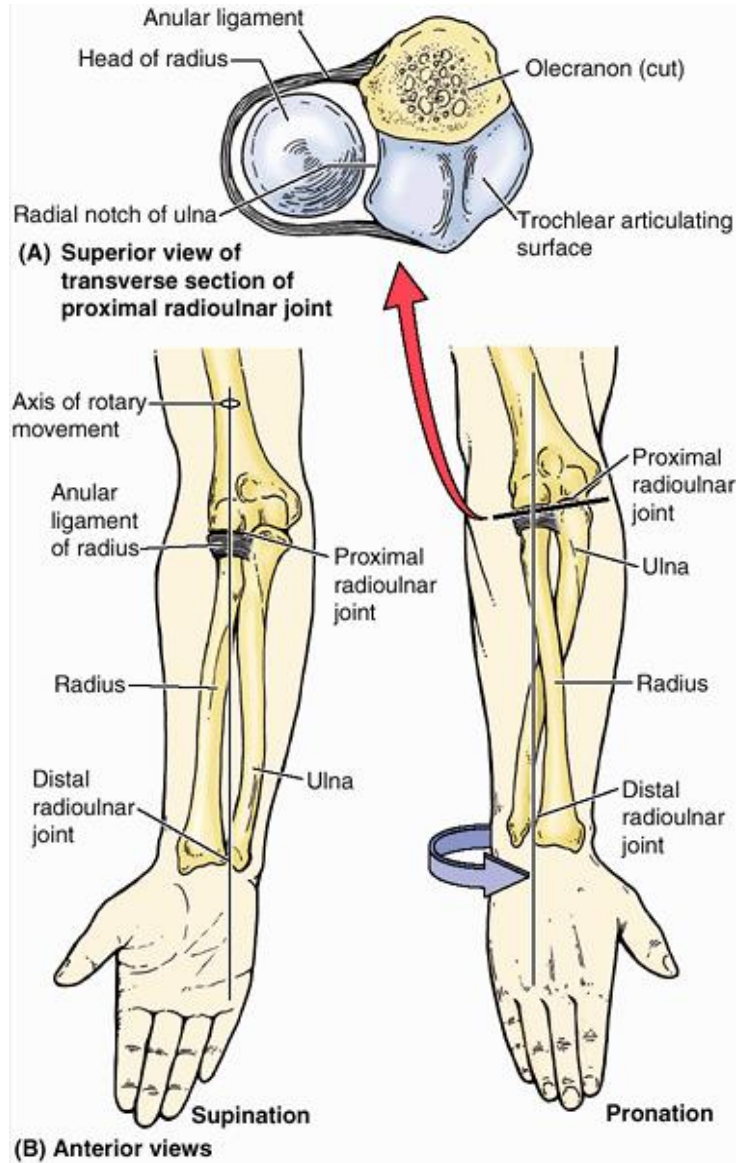


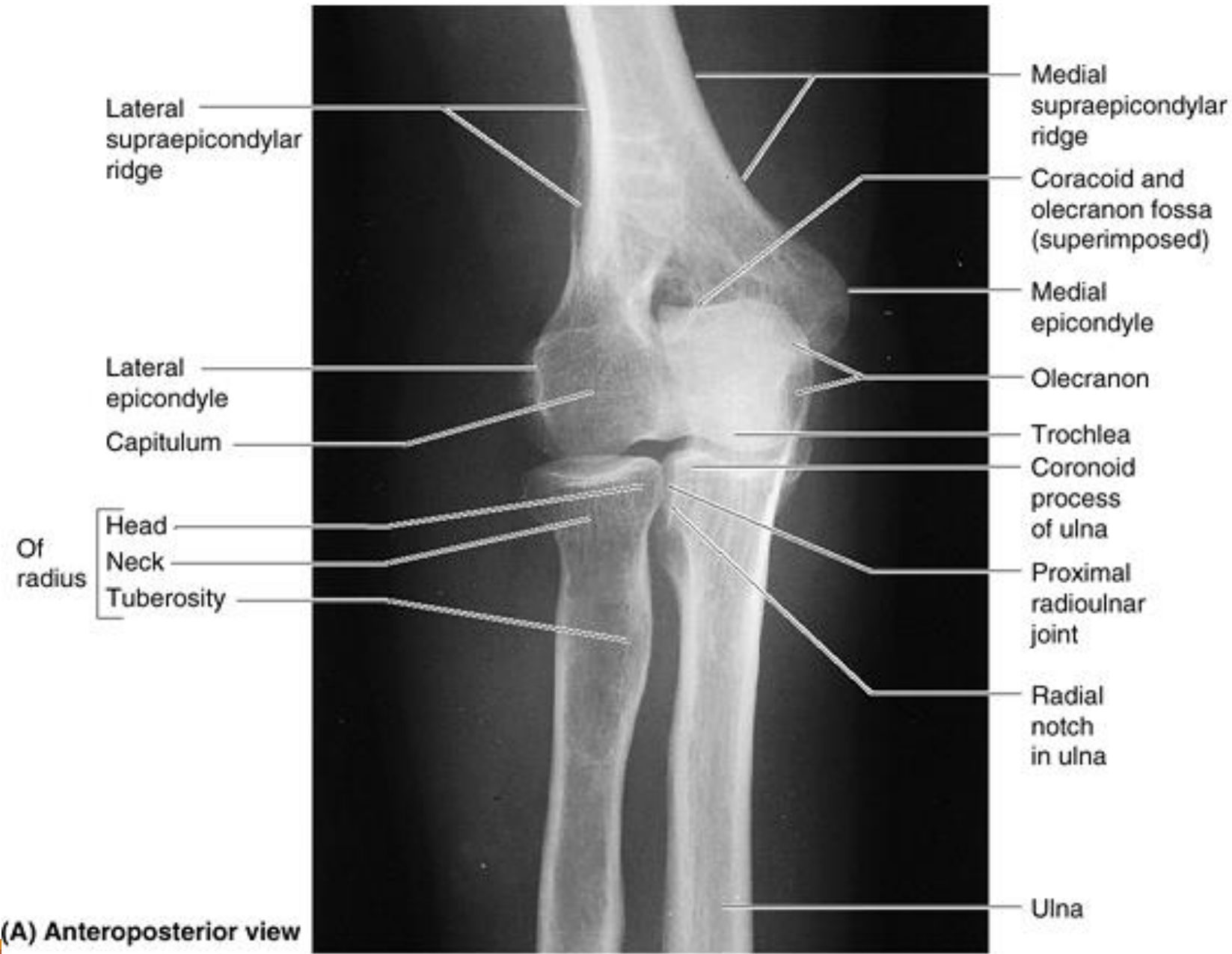
*Movements:* flexion, extension

Art. radioulnaris proximalis together with art. radioulnaris distalis – pronation and supination

*Middle position:* in slight flexion and pronation

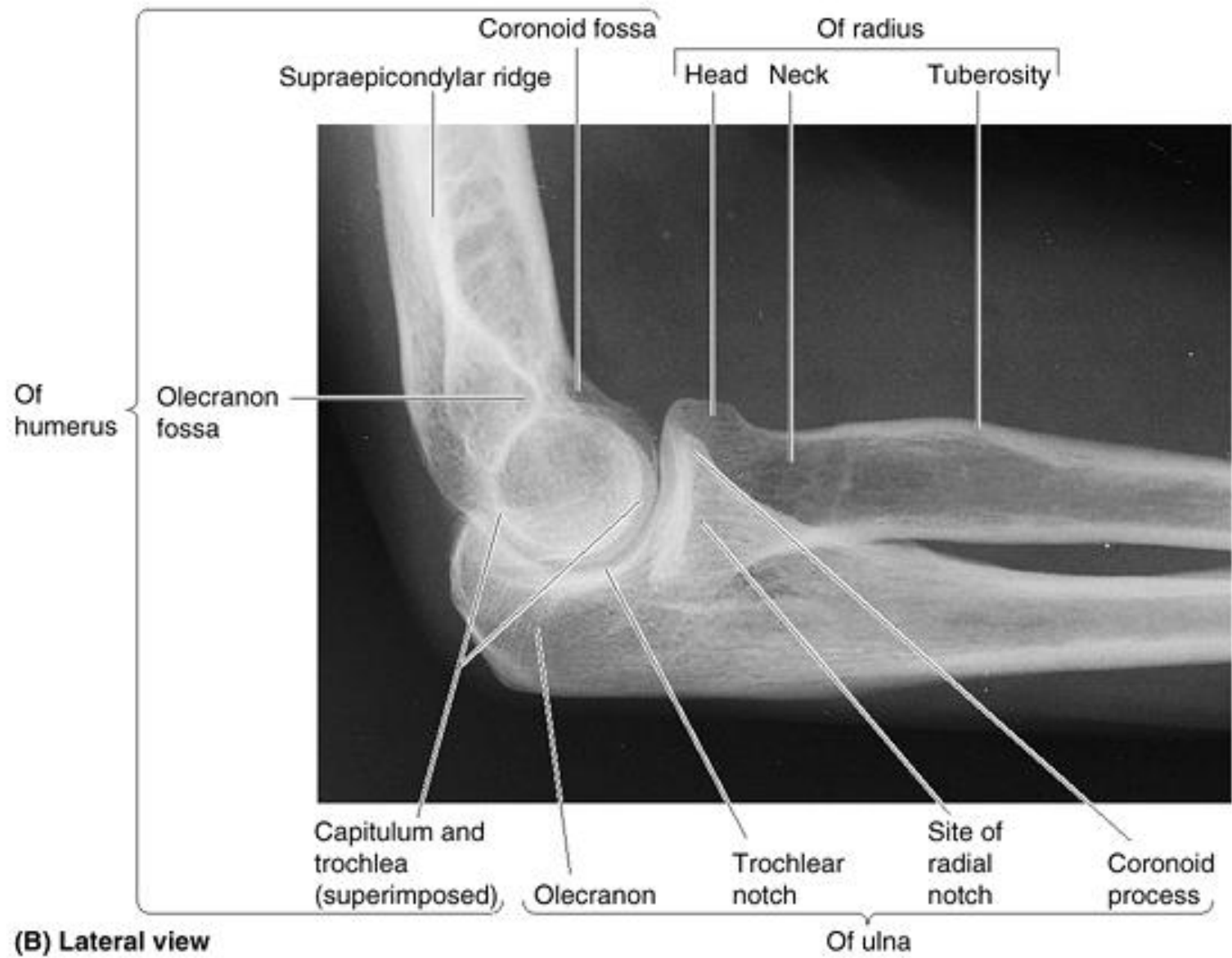






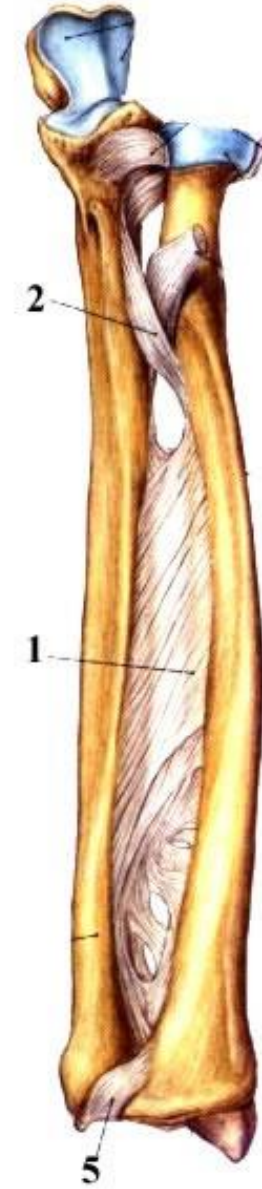
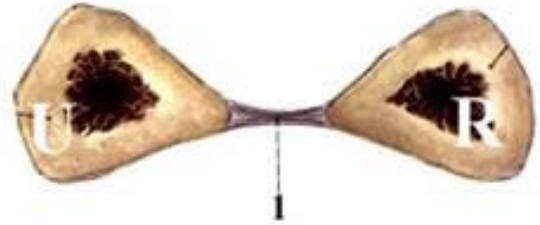
(A) Anteroposterior view





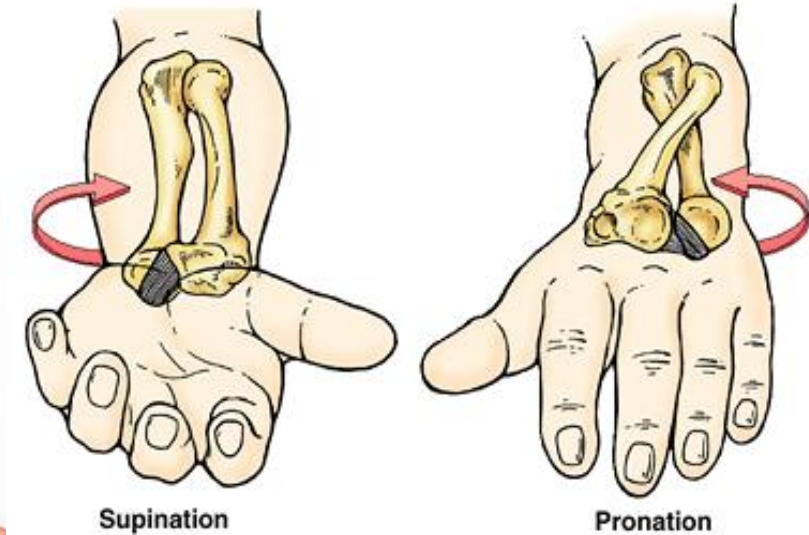
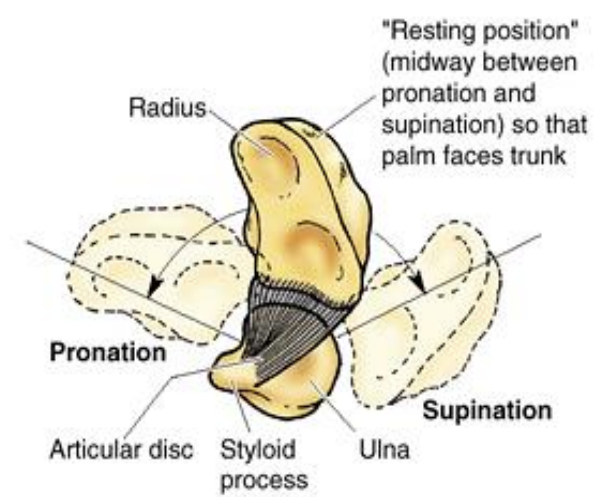
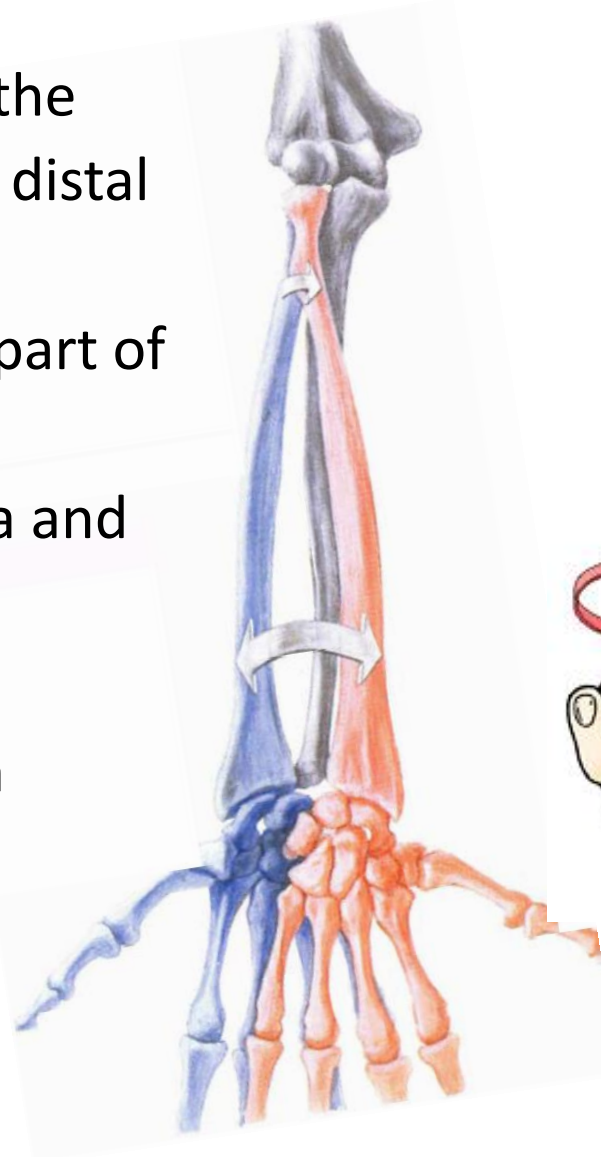
## SYNDESMOSES RADIOULNARIS

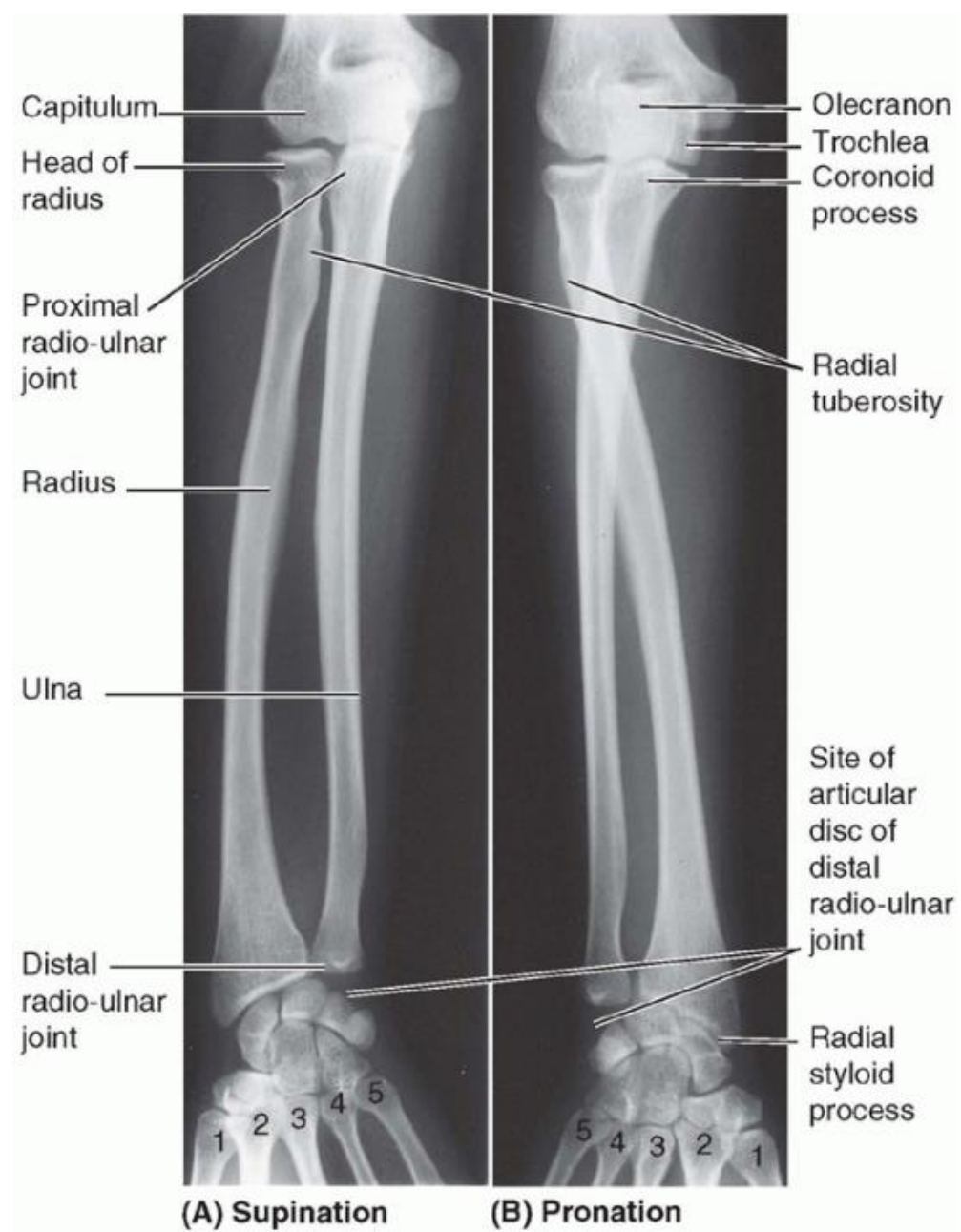
Interosseous membrane (chorda obliqua)



## Distal Radioulnar Joint

- AS: head of the ulna articulates with the ulnar notch on the medial side of the distal end of the radius
- AC: free, enables rotation of the distal part of the radius around the head of the ulna
- **articular disc** binds the ends of the ulna and radius together
- (pivot)
- movements - supination and pronation





## Articulationes manus

### ARTICULATIO RADIOCARPALIS

Radius and carpal bones

### ARTICULATIO MEDIOCARPALIS

between proximal and distal row of carpal bones

### ARTICULATIONES INTERCARPALES

connections between carpal bones

### ARTICULATIONES CARPOMETACARPALES

distal row of carpal bones with metacarpals

### ARTICULATIONES INTERMETACARPALES

between bases of metacarpal bones

### ARTICULATIONES METACARPOPHALANGEALES

heads of the metacarpals with the proximal row of phalanges

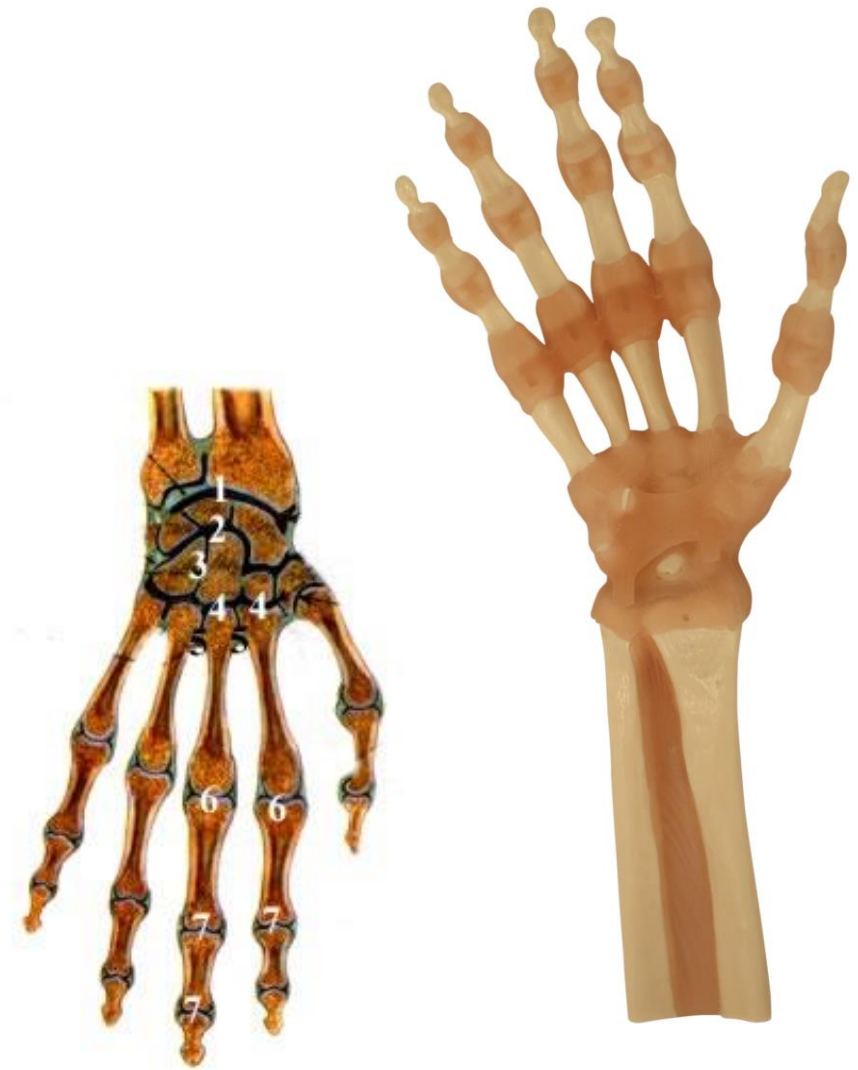### ARTICULATIONES INTERPHALANGEALES

Between phalanges

retinaculum musculorum flexorum

(lig. carpi transversum)

between eminentia carpi radialis et ulnaris -> canalis carpi



## Articulatio radiocarpalis

Type: compound, ellipsoid

A. head: os scaphoideum, os lunatum, os triquetrum

A. fossa: facies articularis carpalis radii, discus articularis

AC: firm and short

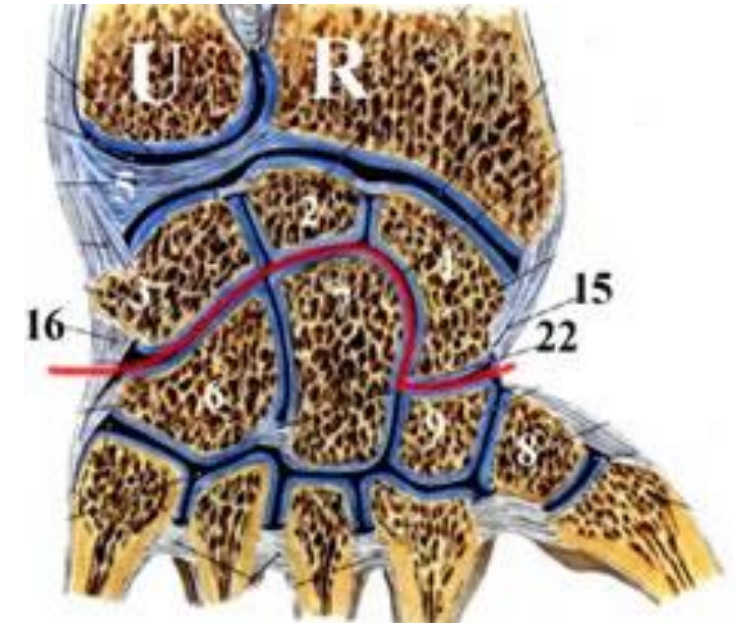
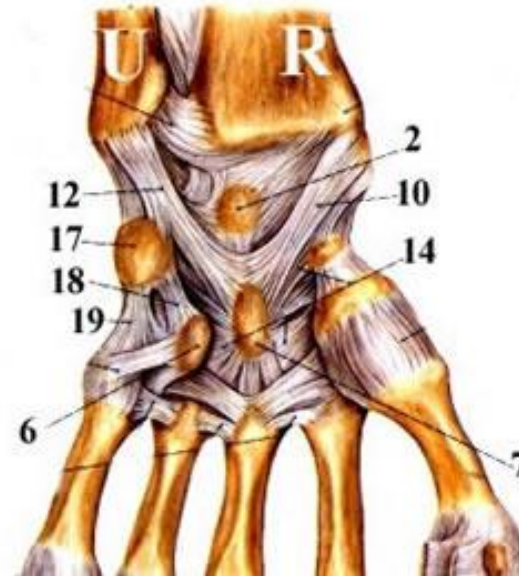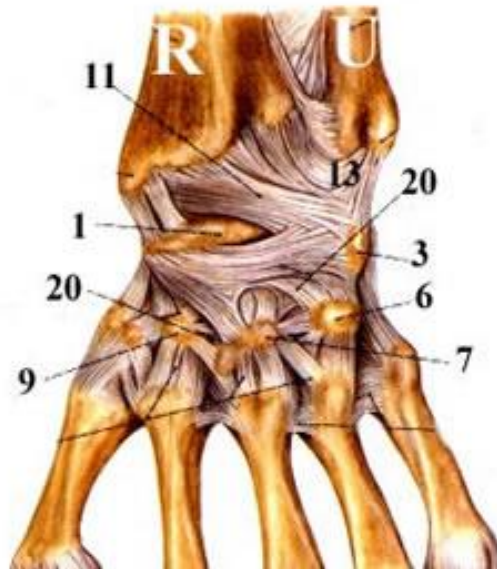
Ligaments: common with art. mediocarpalis

Movements: functional unit with medicarpal, intercarpal, carpometacarpal joints

Palmar and dorsal flexion

radial and ulnar duktion

circumduktion



## Articulatio mediocarpalis

Type: *elipsoid*, compound, in the shape of horizontally placed "S"

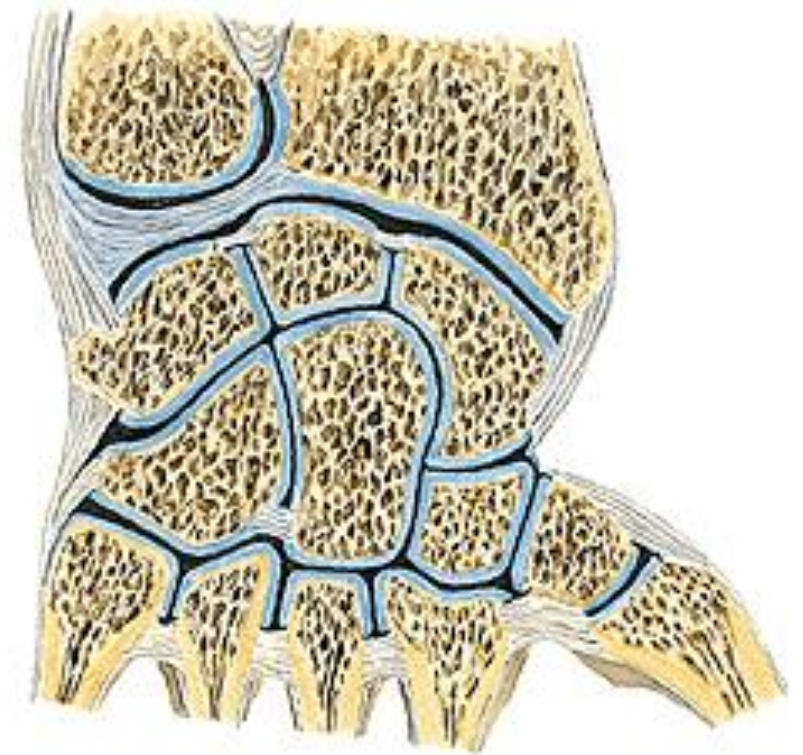
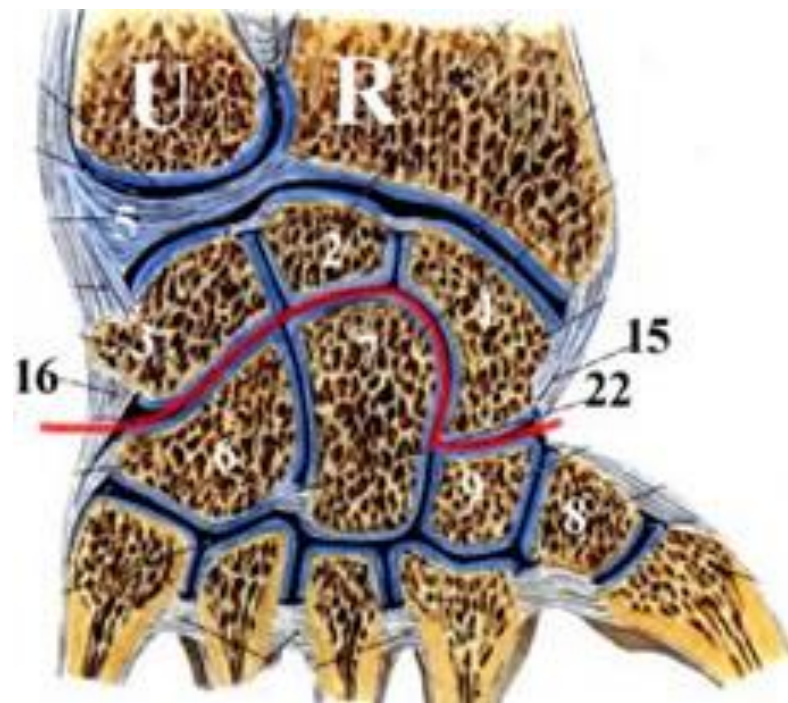
A. head, ulnar side: os hamatum, os capitatum

A. head, Radial side: os scaphoideum

A. fossa, ulnar side: os scaphoideum, os lunatum, os triquetrum

A. fossa, radila side: os trapezium, os trapezoideum

AC: firm and short



*ligaments:*

lig. intercarpea dors., ventr., interossea

lig. radiocarpale palmare et dorsale

lig. ulnocarpale palmare et dorsale

lig. carpi radiatum

lig. collaterale carpi radiale et ulnare

*Movements:*

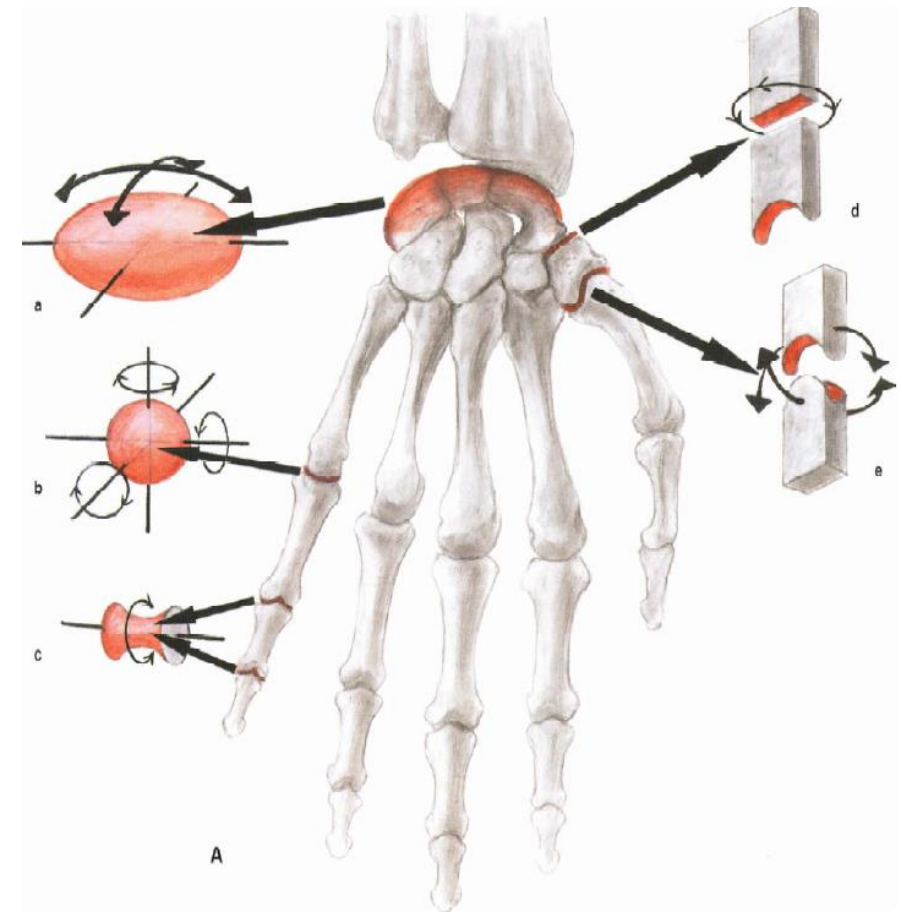
functional unit with mediocarpal, intercarpal  
and carpometacarpal joints

Palmar and dorsal flexion,

Radial and ulnar duktion, cirkumduktion

*midle position:* same as the anatomical one

- Wrist and digits are in continuation of the forarm long axes





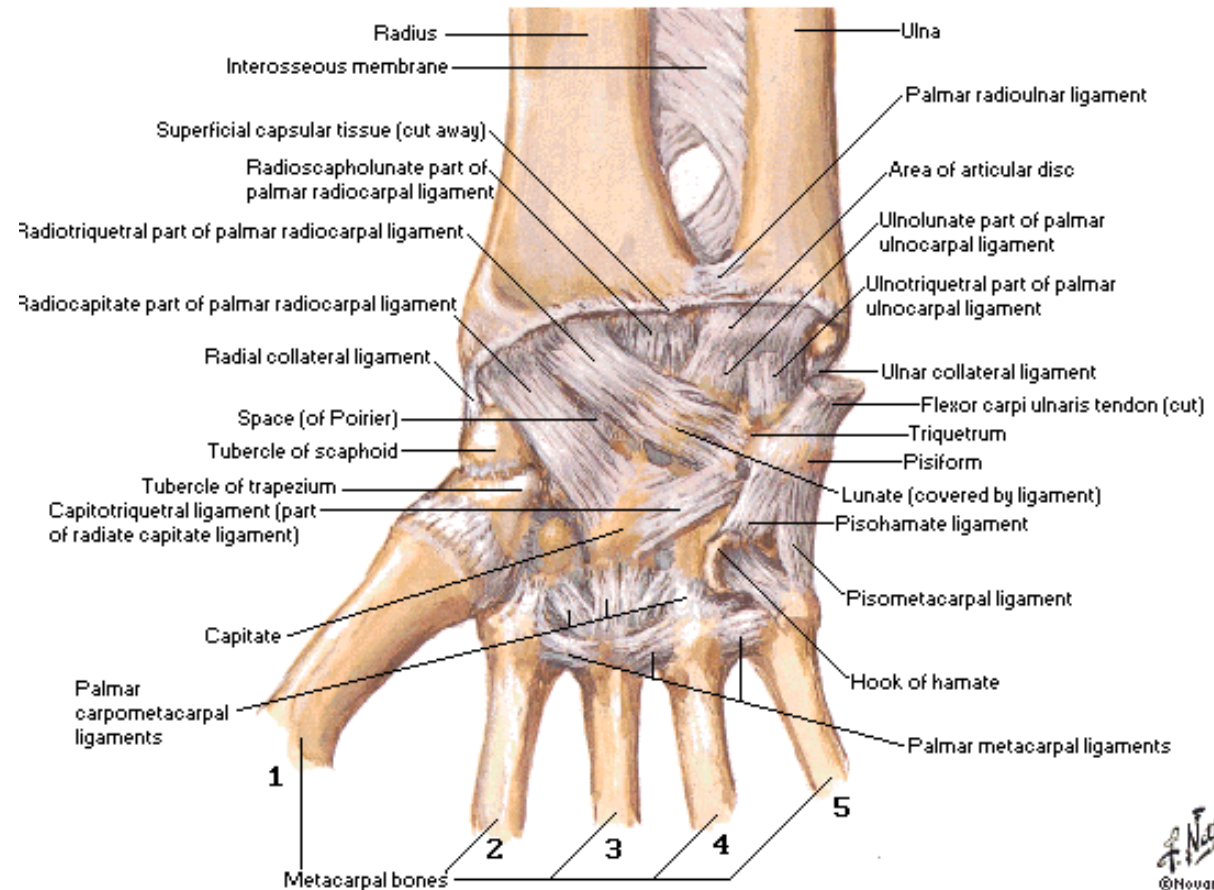
## Articulatio ossis pisiformis:

os pisiforme and os triquetrum - amphiarthrosis

lig. pisohamatum

lig. pisometacarpeum

(continuation of the tendon of m. flexor carpi ulnaris)



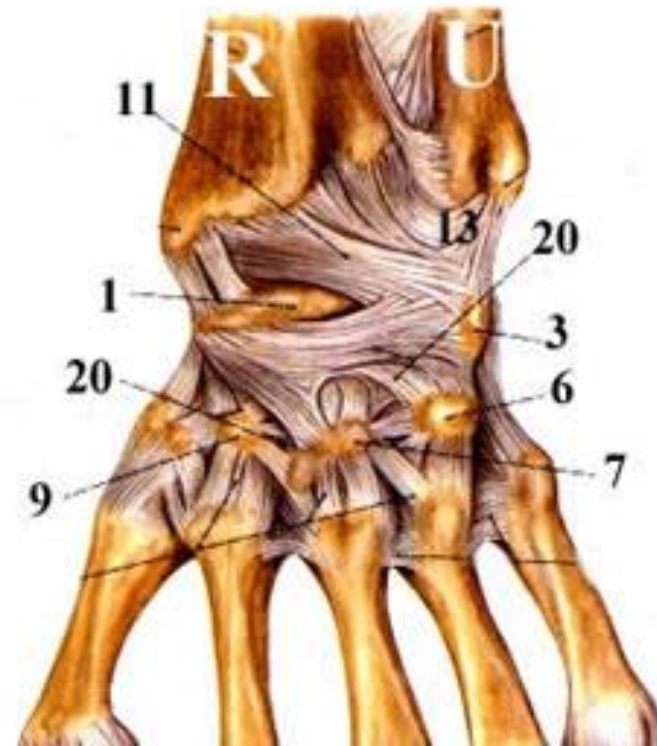
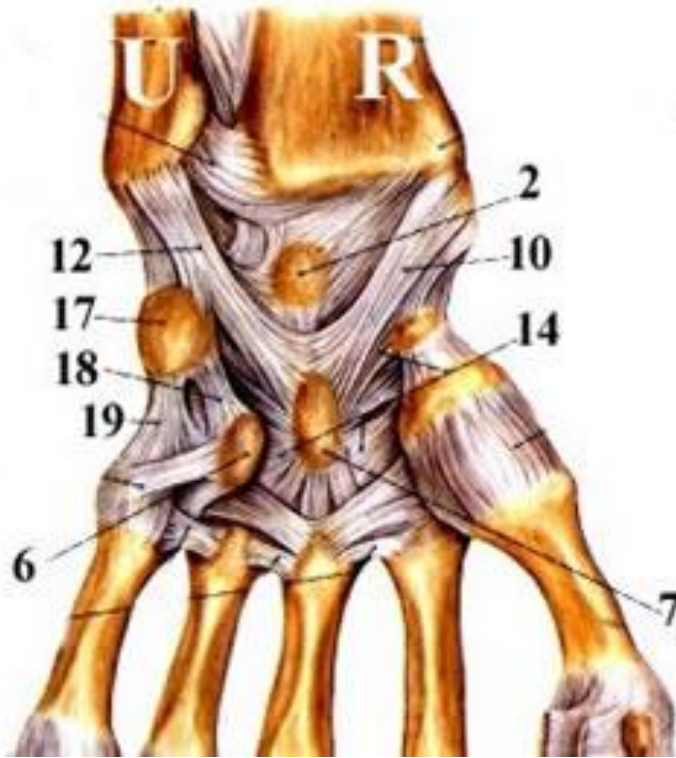## Articulaciones intercarpales

Connection of bones of the proximal and distal row of the wrist

ligg. intercapalia dorsalia

ligg. intercarpalia palmaria

ligg. intercarpalia interossea



## Articulationes carpometacarpales II.-V.

*Type:* compound

*AS:* base of the MC II - os trapezium, os trapezoideum, os capitatum

base of the MC III - os capitatum

base of the MC IV and V - os hamatum

MC bases in between

*AC:* short, tough

ligaments:

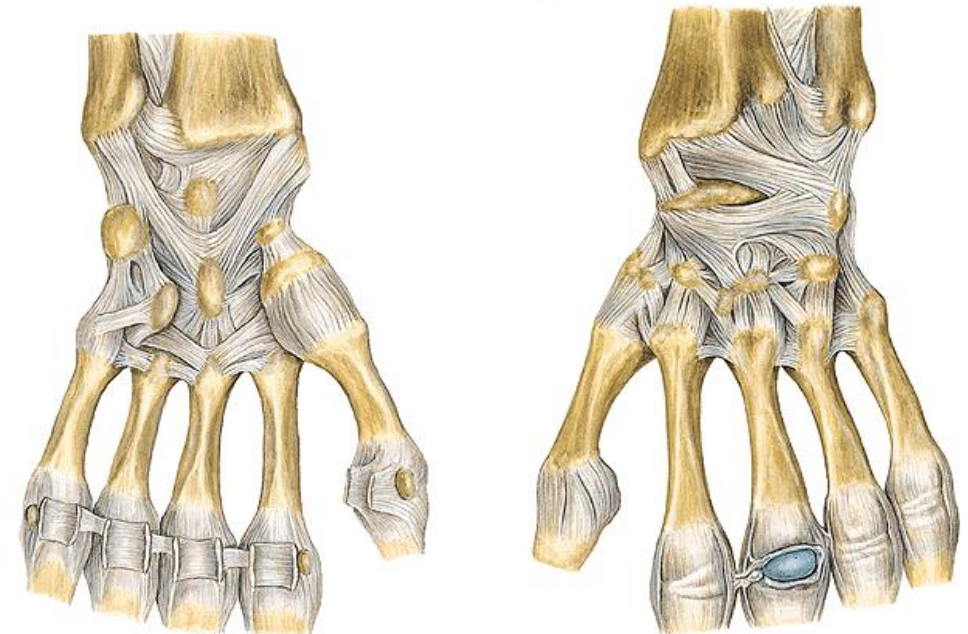
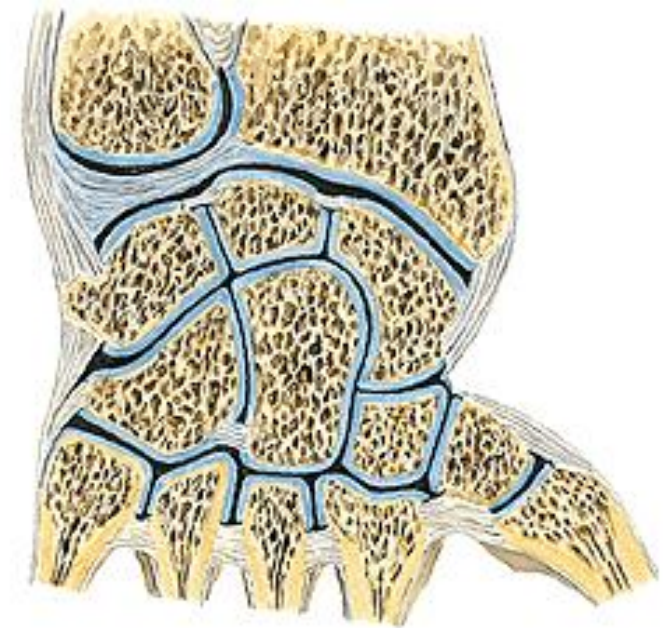
ligg. carpometacarpalia dorsalia

ligg. carpometacarpalia palmaria

ligg. carpometacarpalia interossea

ligg. metacarpea palm., dors., interossea

*Movements:* amphiarthrosis



## Articulatio carpometacarpalis pollicis

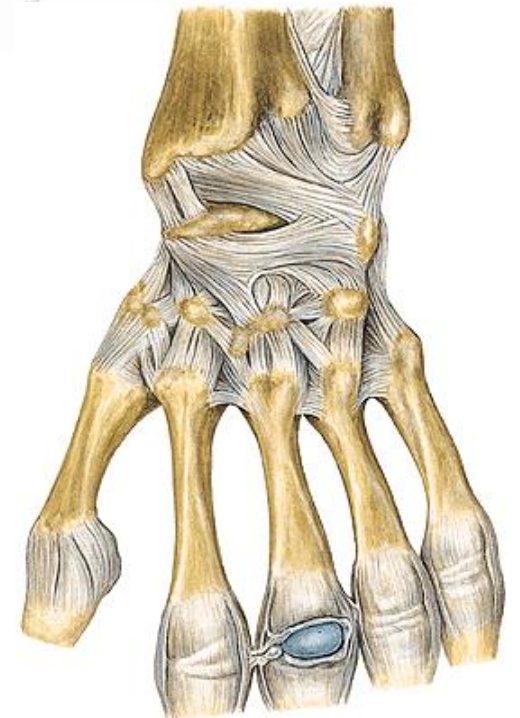
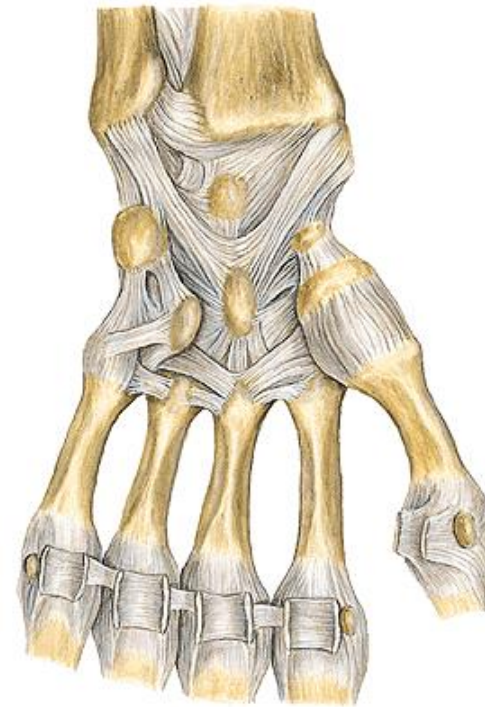
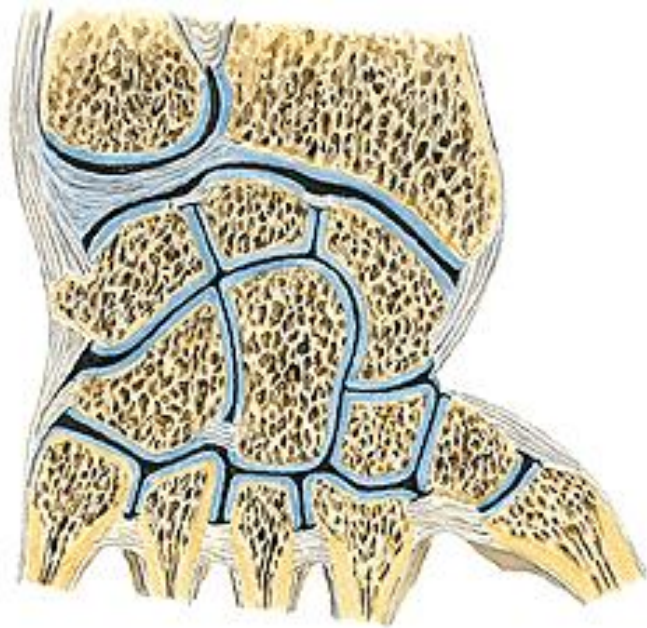
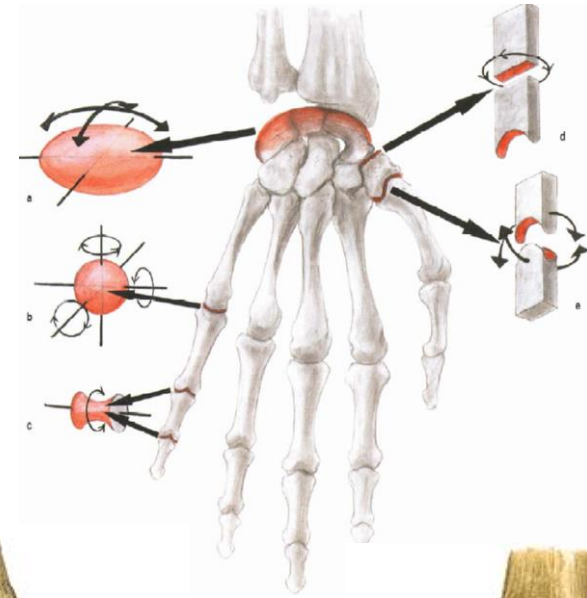
Type: saddle

AH: basis ossis metacarpale I

AF: os trapezium

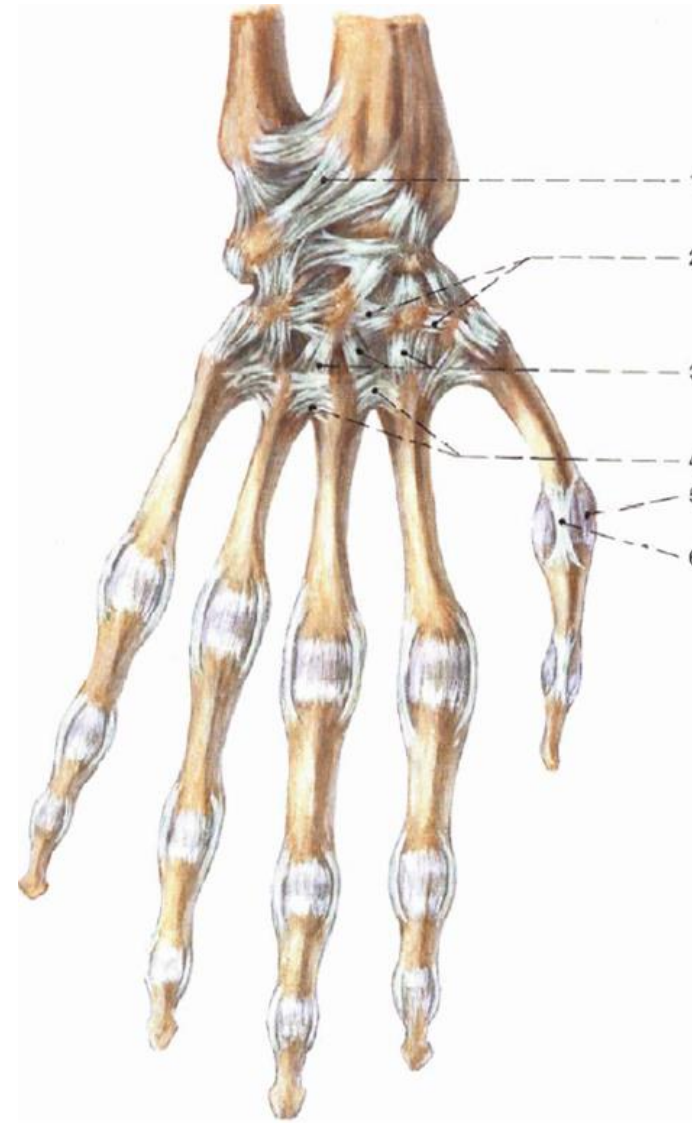
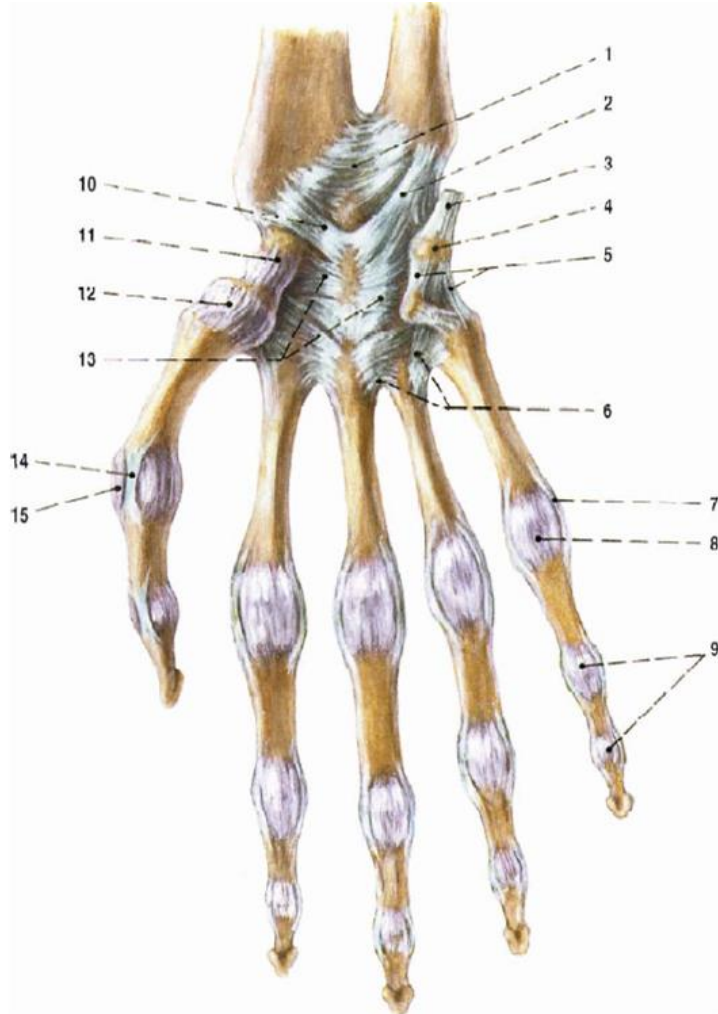
AC: free

Movements: abduktion, adduktion  
opposition, reposition



# Articulaciones intermetacarpales

Ligg. intermetacarpalia



## Art. metacarpophalangeales

Type: ball and socket

AH: caput ossis metacarpalis

AF: basis phalangis

AC: free

Ligaments:

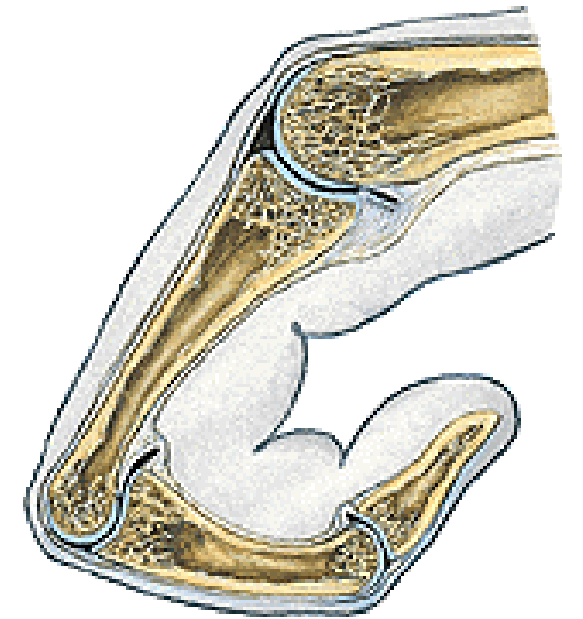

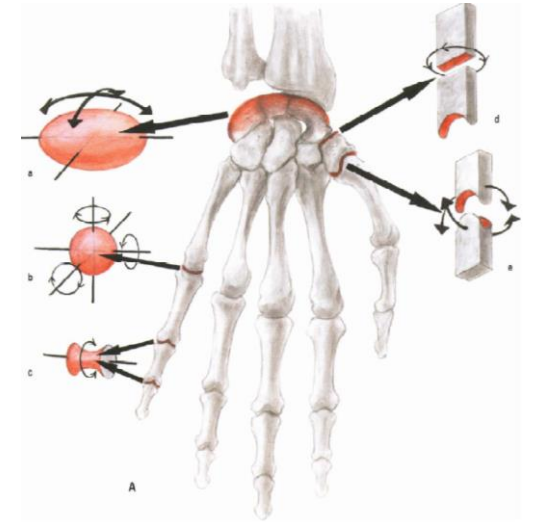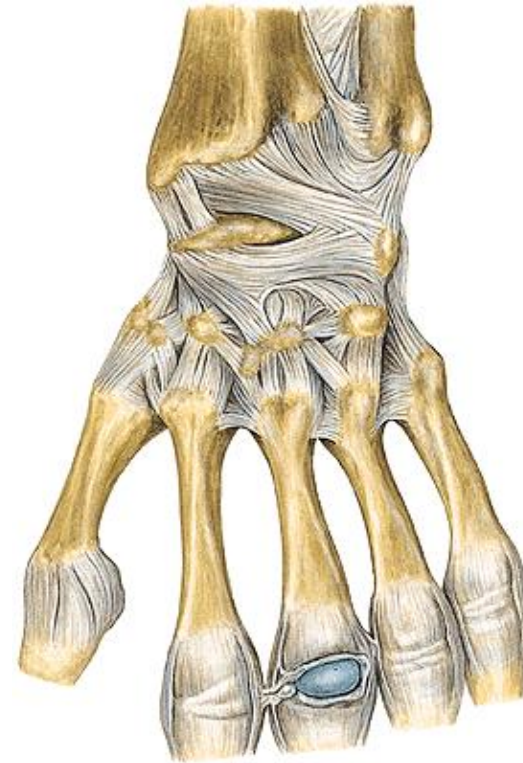
ligg. collateralia

ligg. palmaria - fibrocartilago palmaris

lig. metacarpale transversum profundum

Movements: flexion a etension

abduktion and adduktion – in not flexed finger



## Articulationes interphalangeales

Type: hinge

AH: caput (trochlea) phalangis

AF: basis phalangis

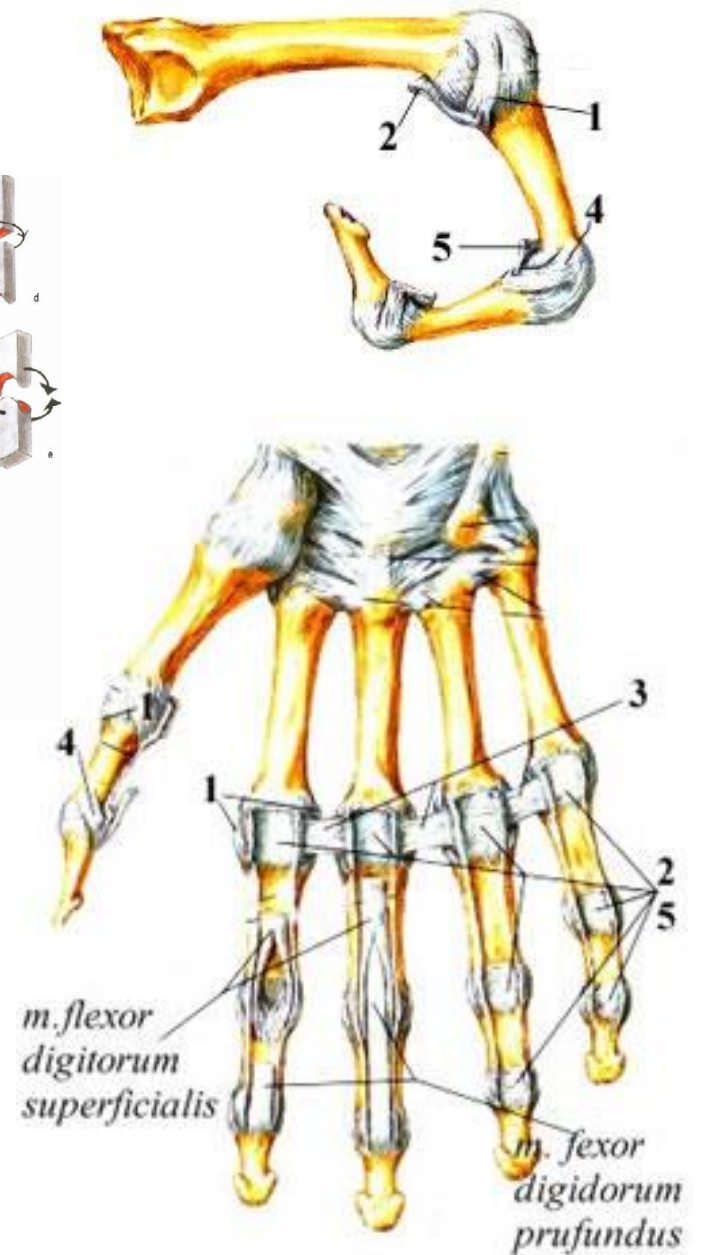
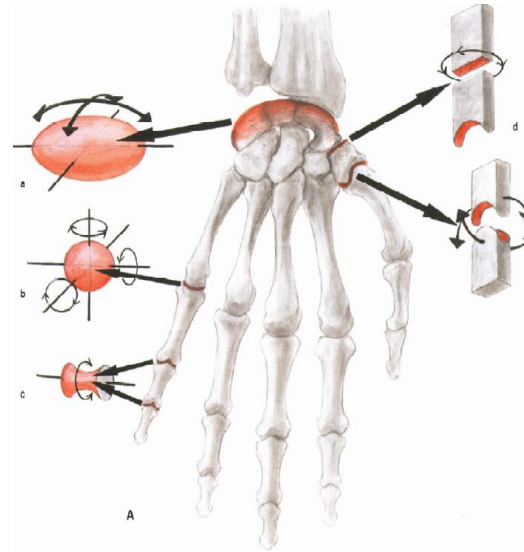
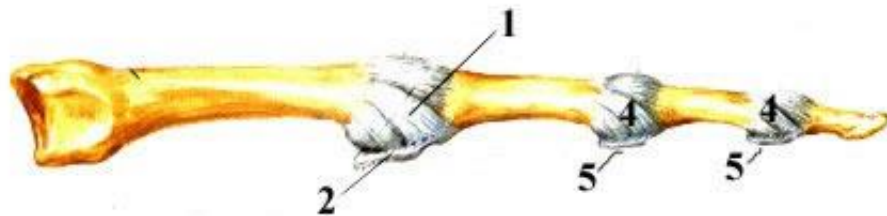
AC: free

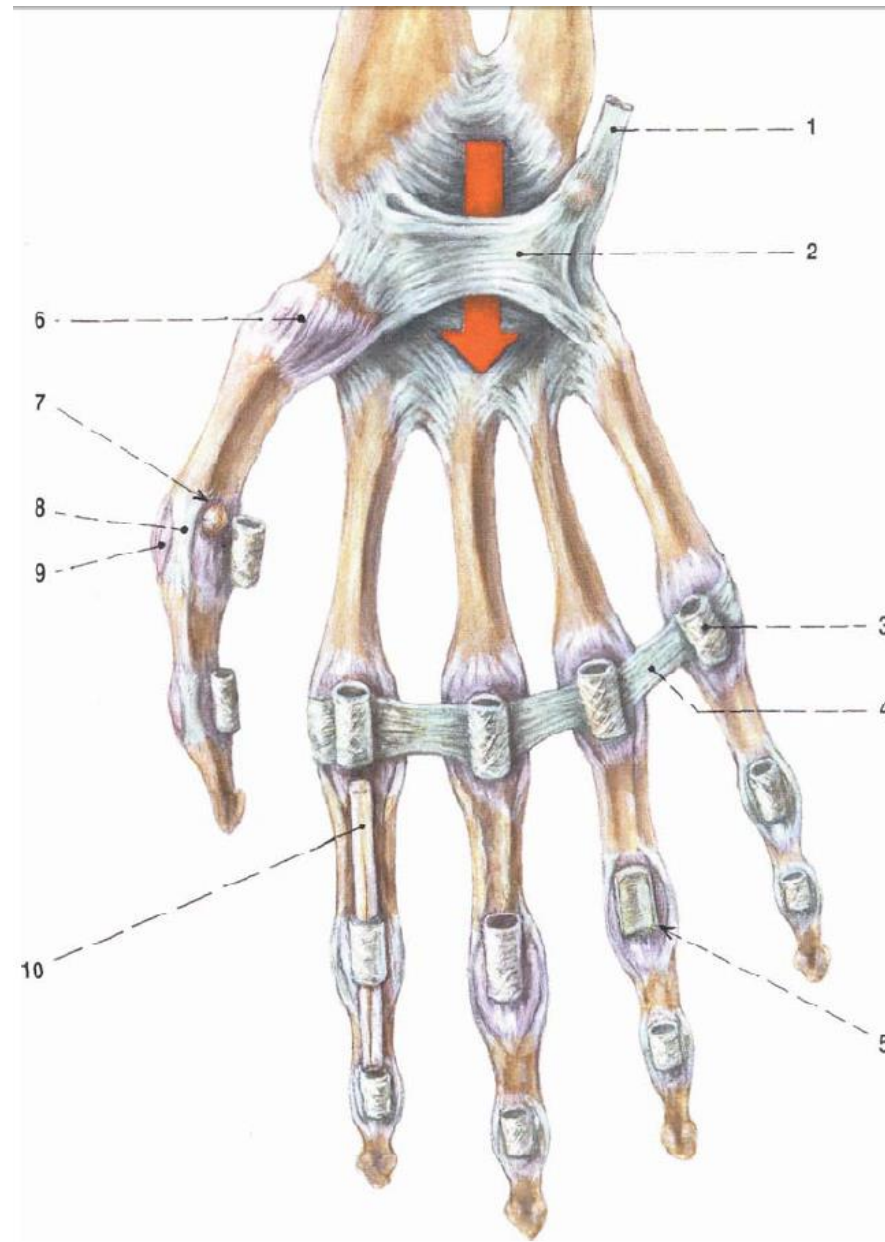
Ligaments:

ligg. collateralia

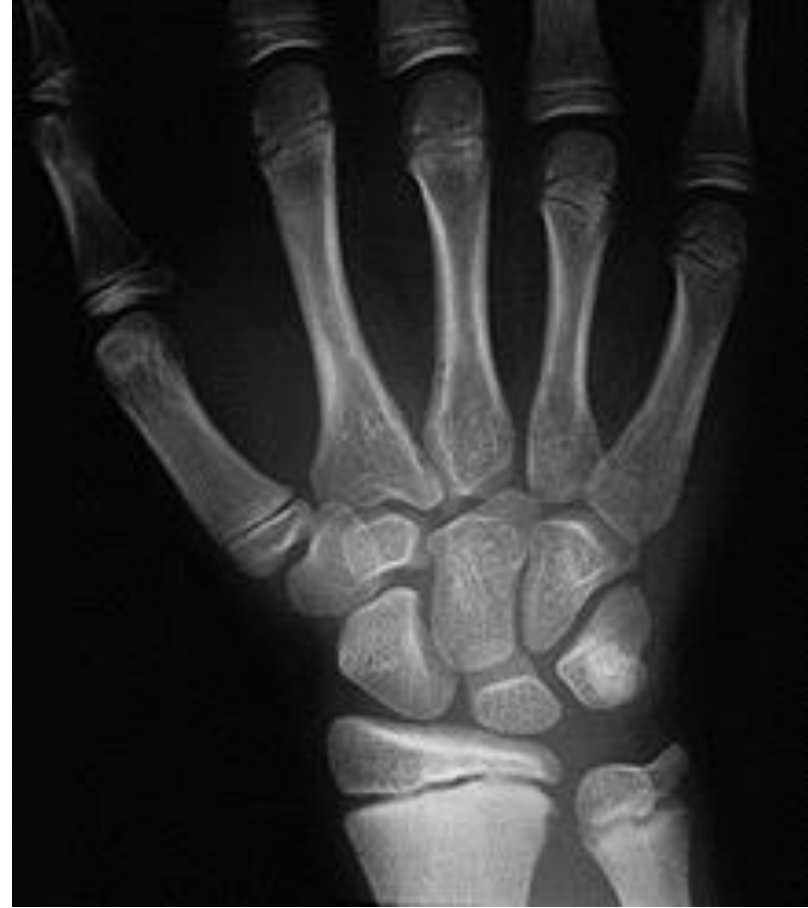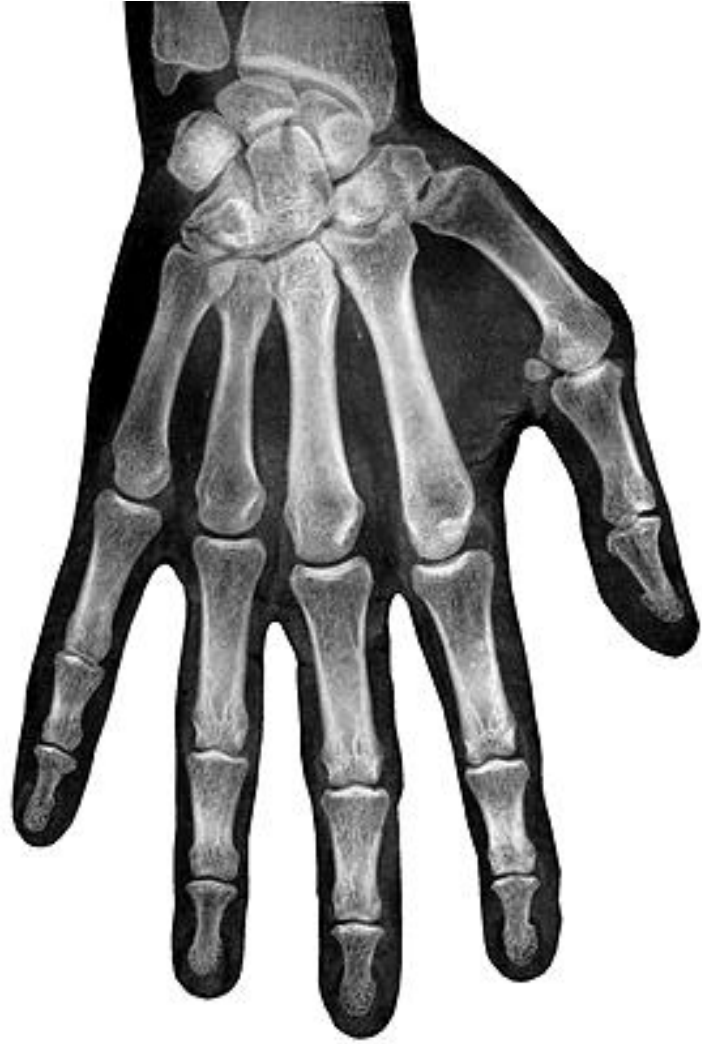ligg. palmaria - fibrocartilaginea palmares

Movements: flexion and extension







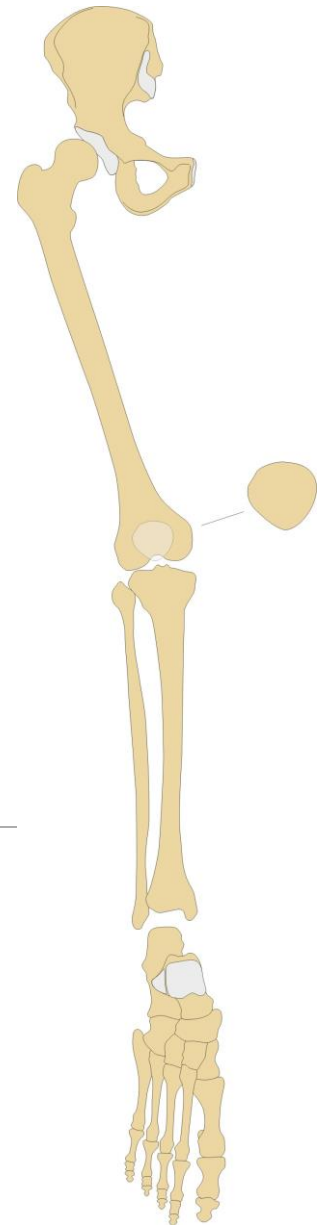


# Connection of the lower limb bones

*(juncturae ossium extremitatis inferioris)*

includes connection of pelvic girdle and free part of lower limb

---



# Connection of pelvic girdle (*juncturae ossium cinguli extremitatis inferioris*)

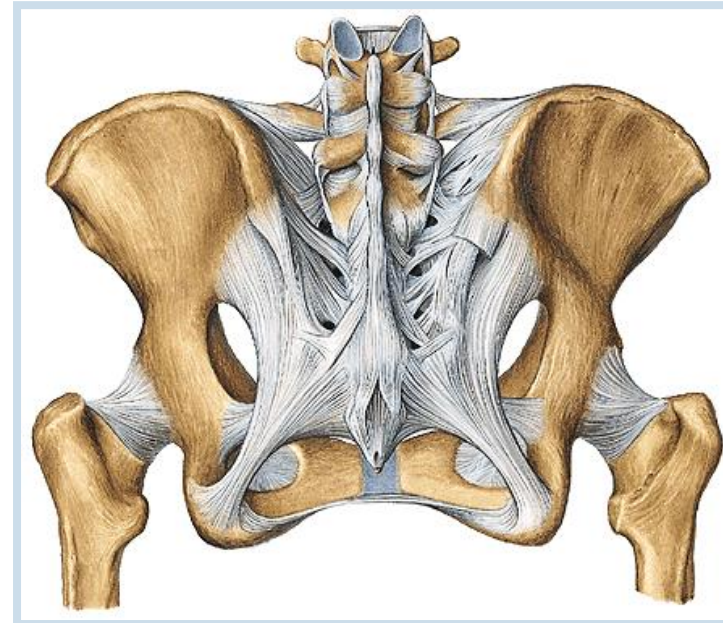
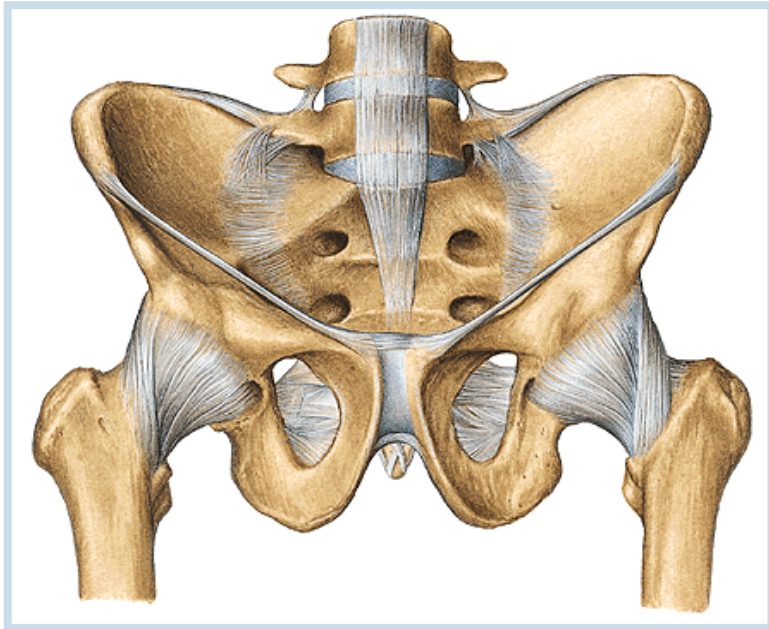
## 1. Sacroiliac joint (*Articulatio sacroiliaca*)

**Articular surfaces:** *facies auriculares ossis sacri et illii*

**Articular capsule:** tight and is attached to margins of AS

**Auxiliary facilities:** capsule is strengthened by *ligg. sacroiliaca ventralia* and *dorsalia* (ventral and dorsal sacroiliac ligaments), *ligg. sacroiliaca interossea* (interosseal sacroiliac ligaments)

**Type of joint:** amphiartrosis



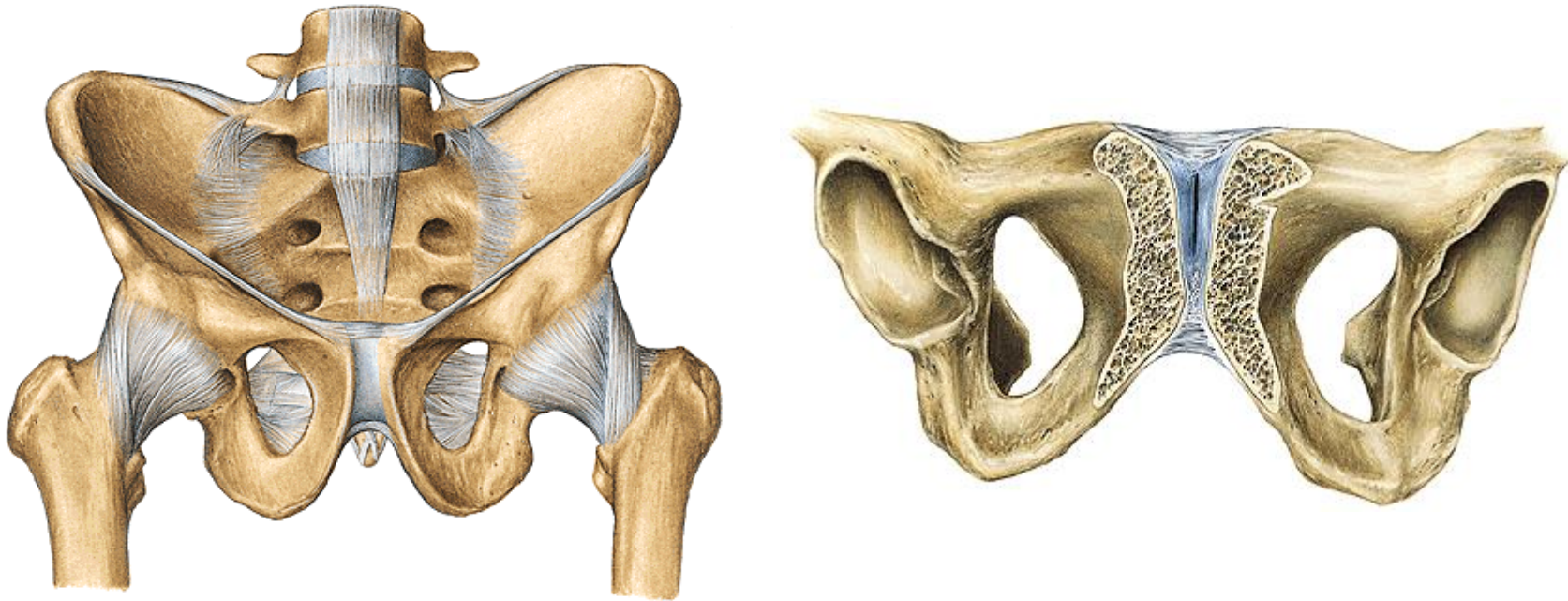
## 2. *Symphysis pubica*

Is formed by cartilagenous *discus interpubicus* which connects both pubic bones. Symphysis pubica is 4,5 – 5 cm in height.

*lig. pubicum superius* and stronger *lig. arcuatum pubis*

## 3. *Membrana obturatoria*

a stiff membrane which closes *foramen obturatum (canalis obturatorius)*



## 4. Ligaments in the pelvic region

**Lig. sacrospinale** (Sacrospinal ligament)

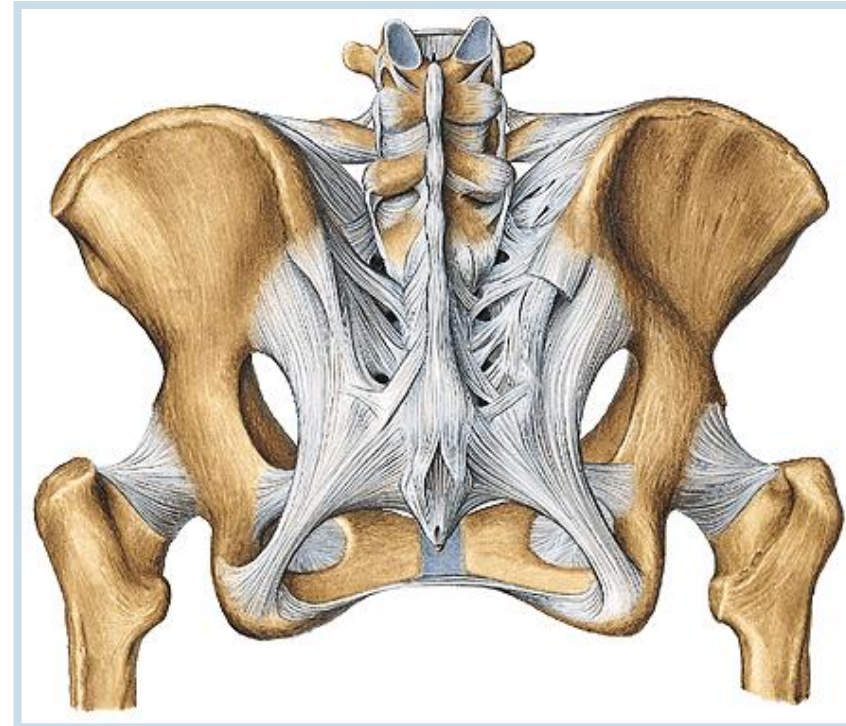
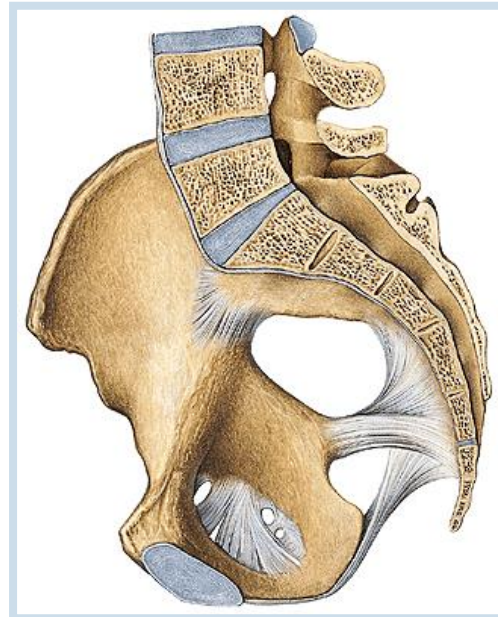
**Lig. sacrotuberale** (Sacrotuberous ligament)

**Foramen ischiadicum majus** (Greater sciatic foramen)

**Foramen suprapiriforme and foramen infrapiriforme** (Supra- and infrapiriform foramen)

**Foramen ischiadicum minus** (Lesser sciatic foramen)

**Lig. iliolumbale**

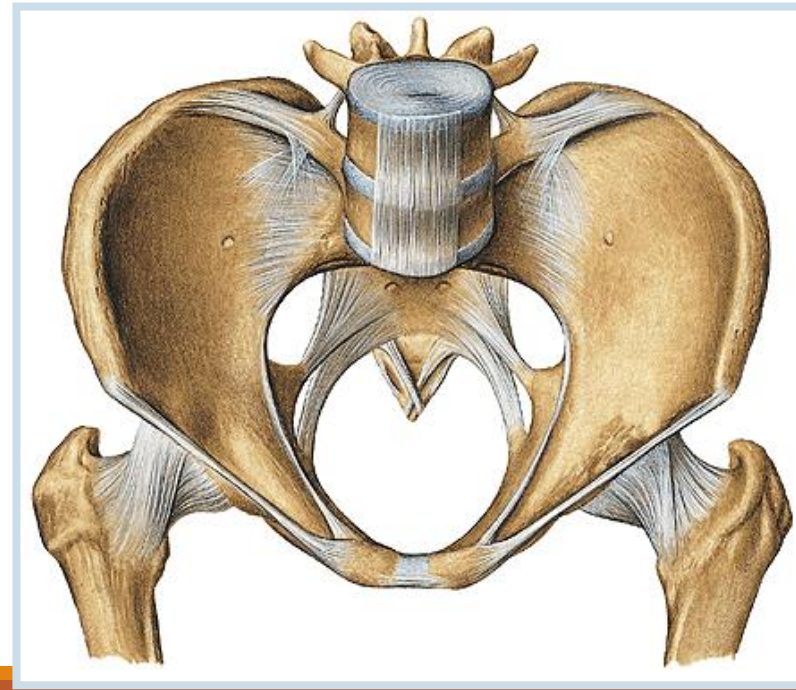
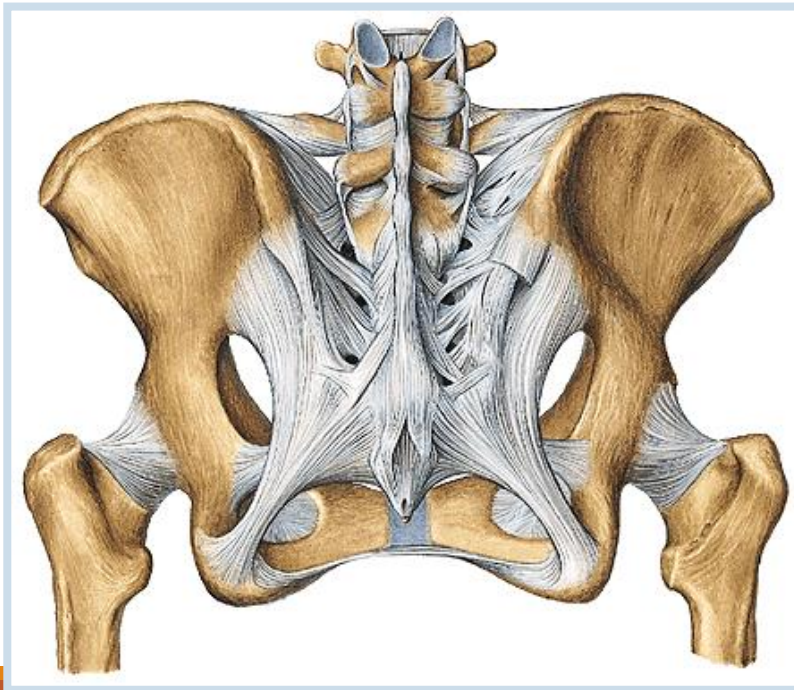


## 5. Pelvis

**Aditus pelvis** (the pelvic inlet) is bordered by linea terminalis which separates pelvis major and pelvis minor.

**Exitus pelvis** (the pelvic outlet) is the region between the subpubic angle, tubera ischiadica and os coccygis.

**Pelvis minor** (lesser pelvis) is „true pelvis“ (genital organs, a part of urinary system), an important childbirth way in female and it has great intersexual differences.



# Sexual differences of pelvis

**Male pelvis** is higher and narrower.

**Female pelvis** is lower and wider than in the male.

**arcus pubicus** (subpubic arch)

**ala ossis ilii** (*ala of iliac bone*)

**tubera ischiadica** (sciatic tuberosity)

**symphysis pubis**

**angulus x arcus subpubicus** (subpubic angle x arch)

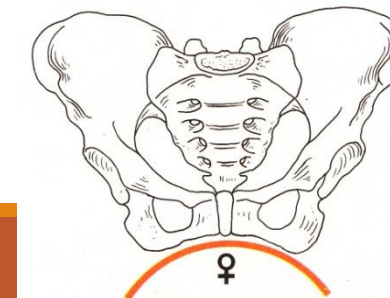
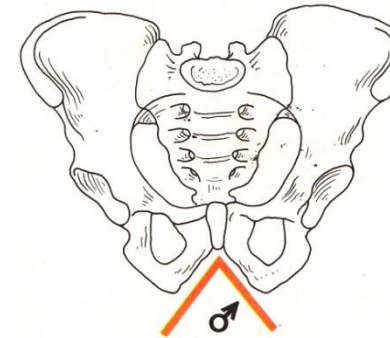
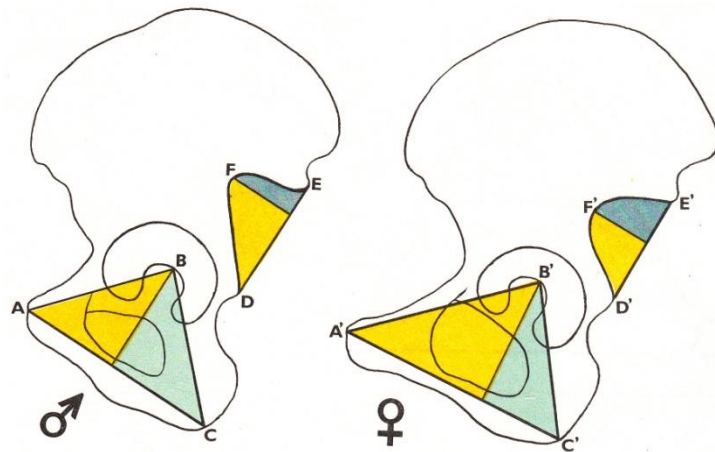
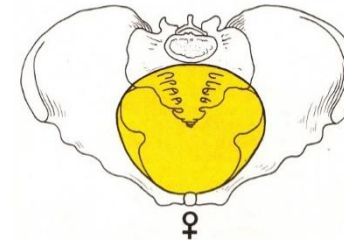
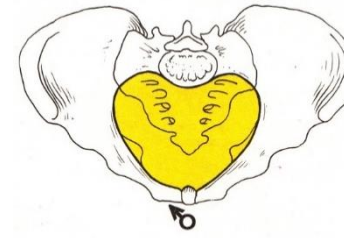
**shape of aditus pelvis** (shape of pelvic inlet)

**incisura ischiadica major** (greater sciatic notch)

**Length of superior ramus of pubic bone** – prominence of mons pubis

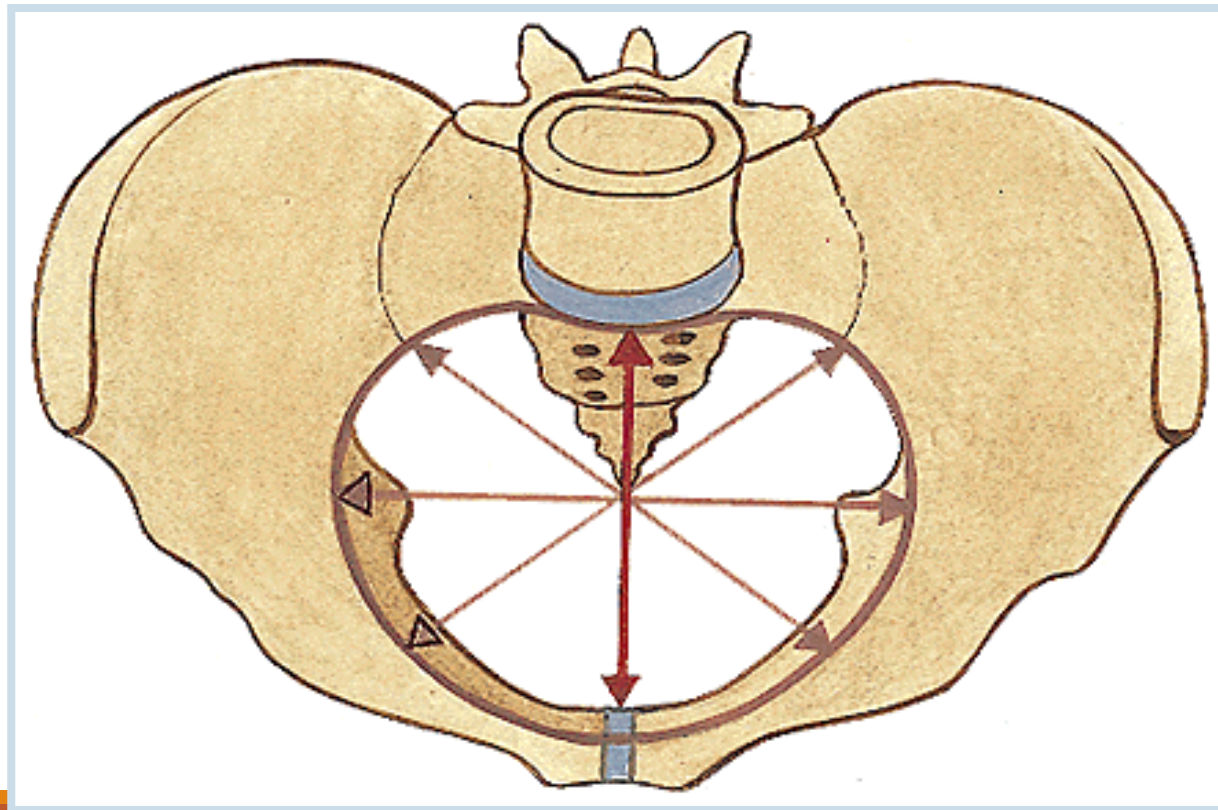
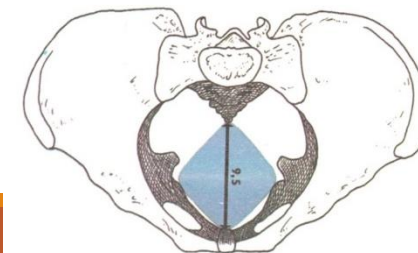
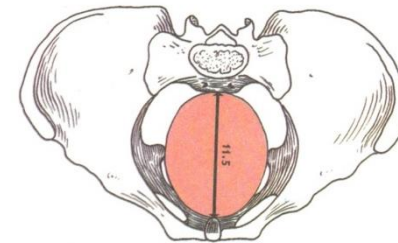
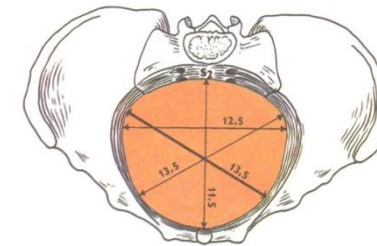
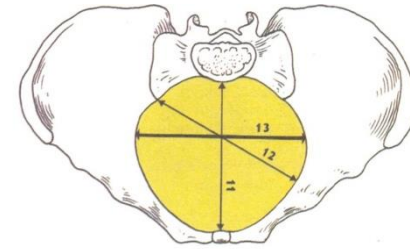
**Foramen obturatum**

**Os sacrum**



# Internal diameters of pelvis

1. **Aditus pelvis** = apertura pelvis superior (**inlet**) transverse diameter about 13 cm
2. **Amplitudo pelvis** (width of pelvis) about 12 cm
3. **Angustia pelvis** (narrow part of bone pelvis) about 10 cm
4. **Exitus pelvis** = apertura pelvis inferior (**outlet**) about 9 cm
5. **Conjugata diagonalis** 12.5 – 13 cm (per vaginam)





## B. External diameters of pelvis

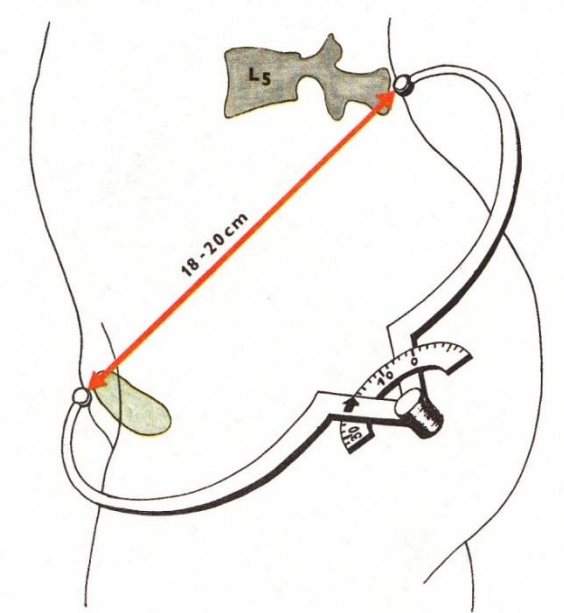
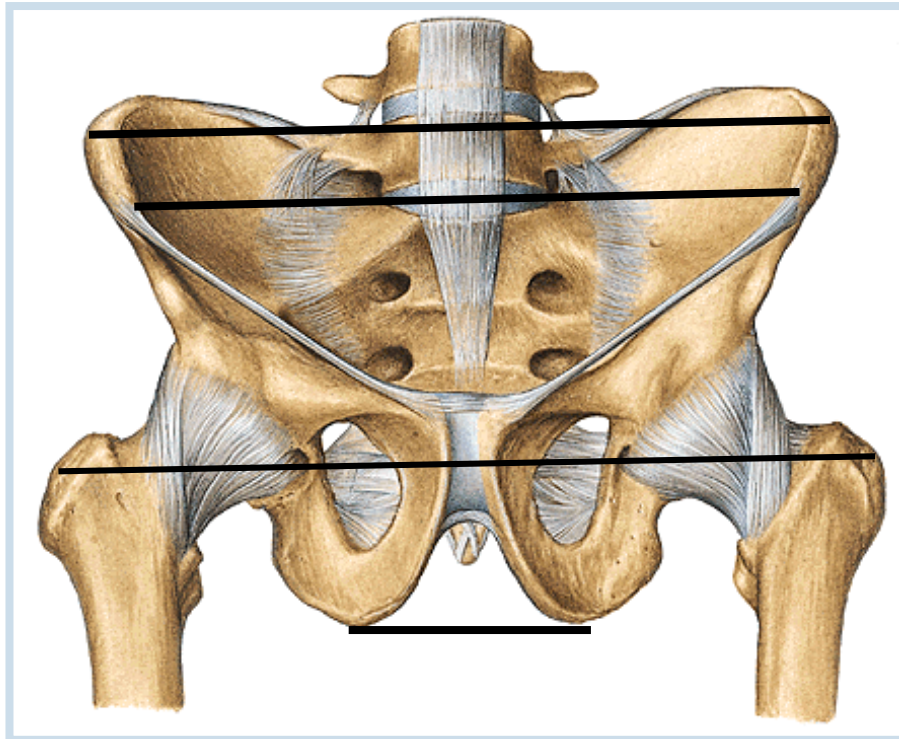
**Distantia bispinalis** (bispinal diameter) (about 26 cm)

**Distantia bicristalis** (bicristal diameter) (about 29 cm)

**Distantia bitrochanterica** (bitrochanteric diameter) (about 31 cm)

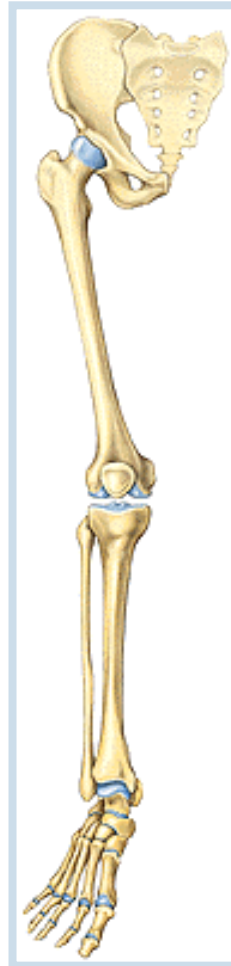**Distantia bituberalis** (bituberal diameter) (about 12 cm)

**Conjugata externa** (min. 18 cm)



# Connection of free part of lower limb

(juncturae ossium extremitatis liberae inferioris)



# 1. Articulatio coxae (hip joint)

**Articular surfaces:** *facies lunata* of an acetabulum !!!!! + head of the femur

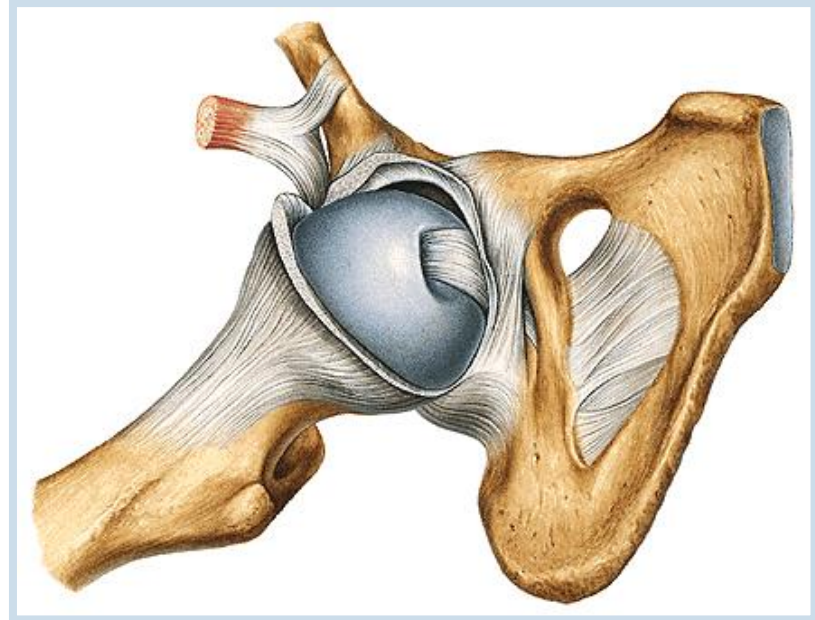
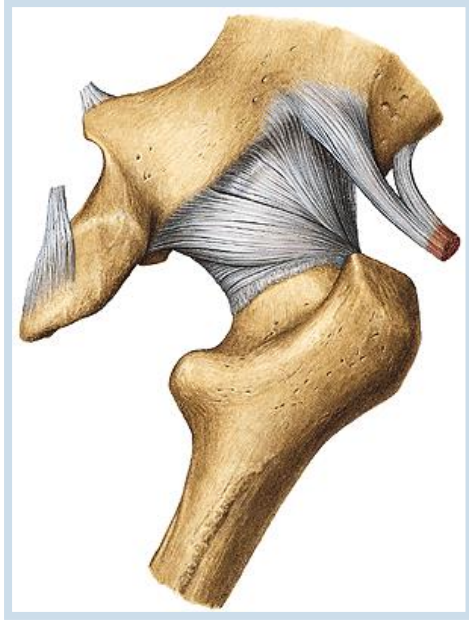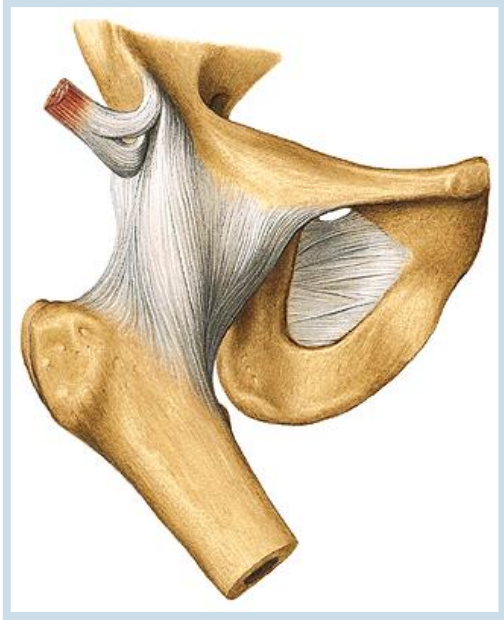
**Articular capsule:** is attached to the margins of acetabulum. It reaches ventrally linea intertrochanterica of femur, dorsally is attached to the collum femoris (neck of femur) medially away from fossa trochanterica.

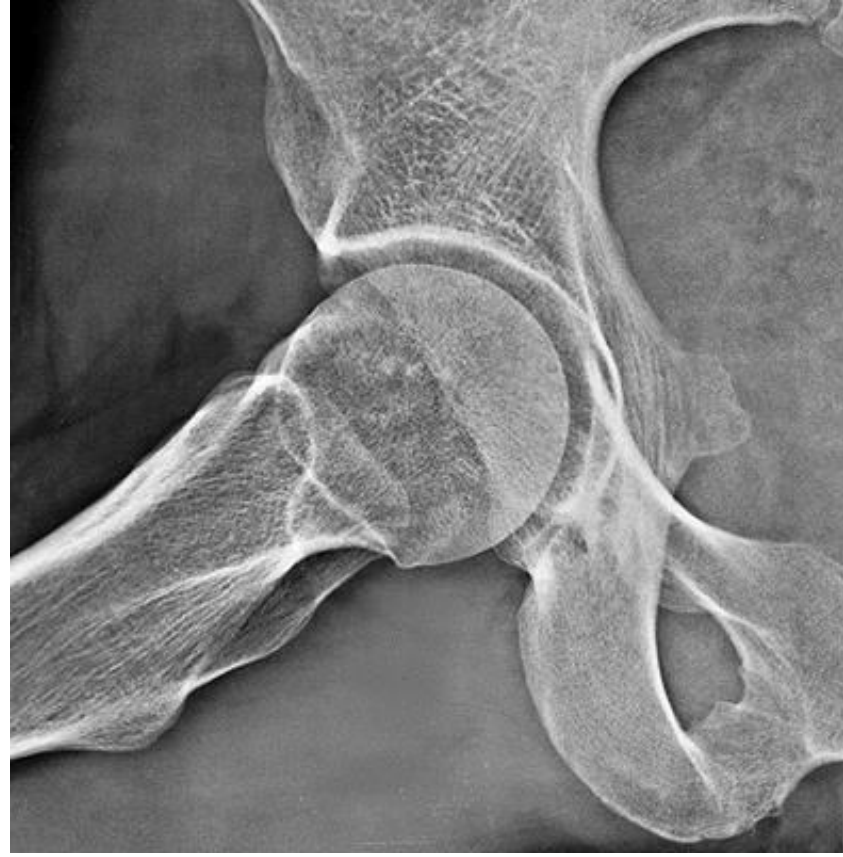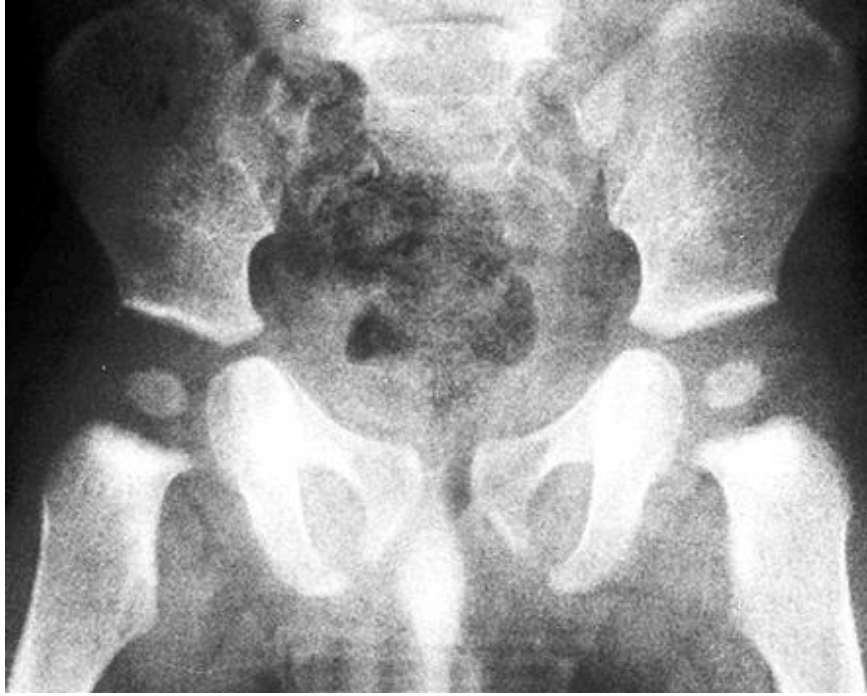**Auxiliary facilities :**

- a) *Labrum acetabulare* formed by cartilage.
- b) *Lig. transversum acetabuli* runs through *incisura acetabuli*.
- c) *Lig. iliofemorale*
- d) *Lig. pubofemorale*
- e) *Lig. ischiofemorale*
- f) *Zona orbicularis*
- g) *Lig. capitis femoris*

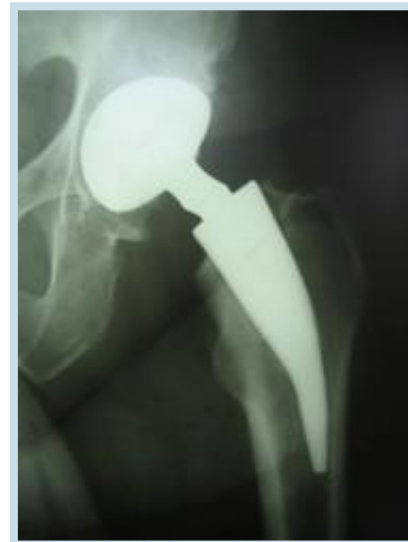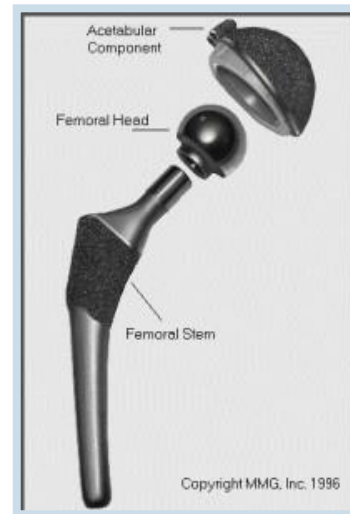
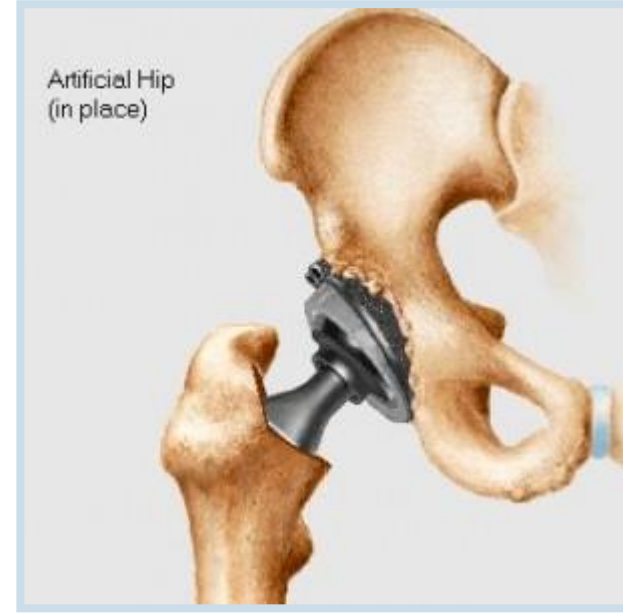
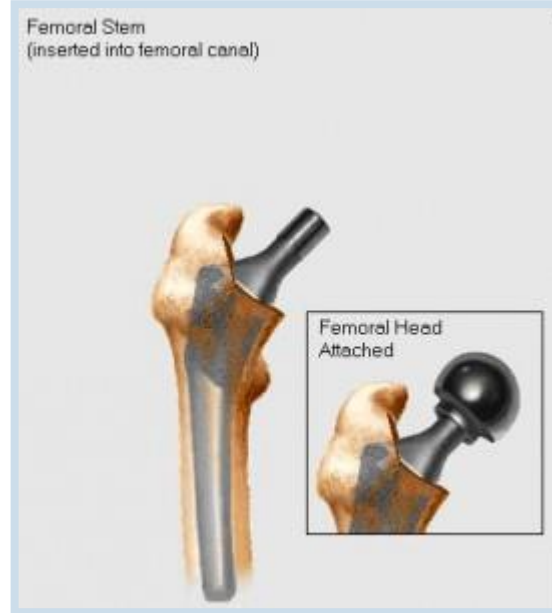
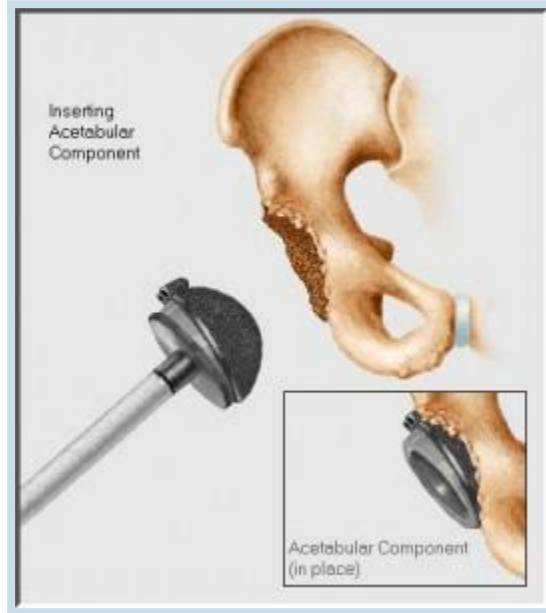**Type of joint:** typical spheroid joint (ball-and-socket) with limited movements (*enarthrosis*).

**Movements** – flexion, extension, abduction, adduction and internal and external rotation.





# Total endoprosthesis of hip joint

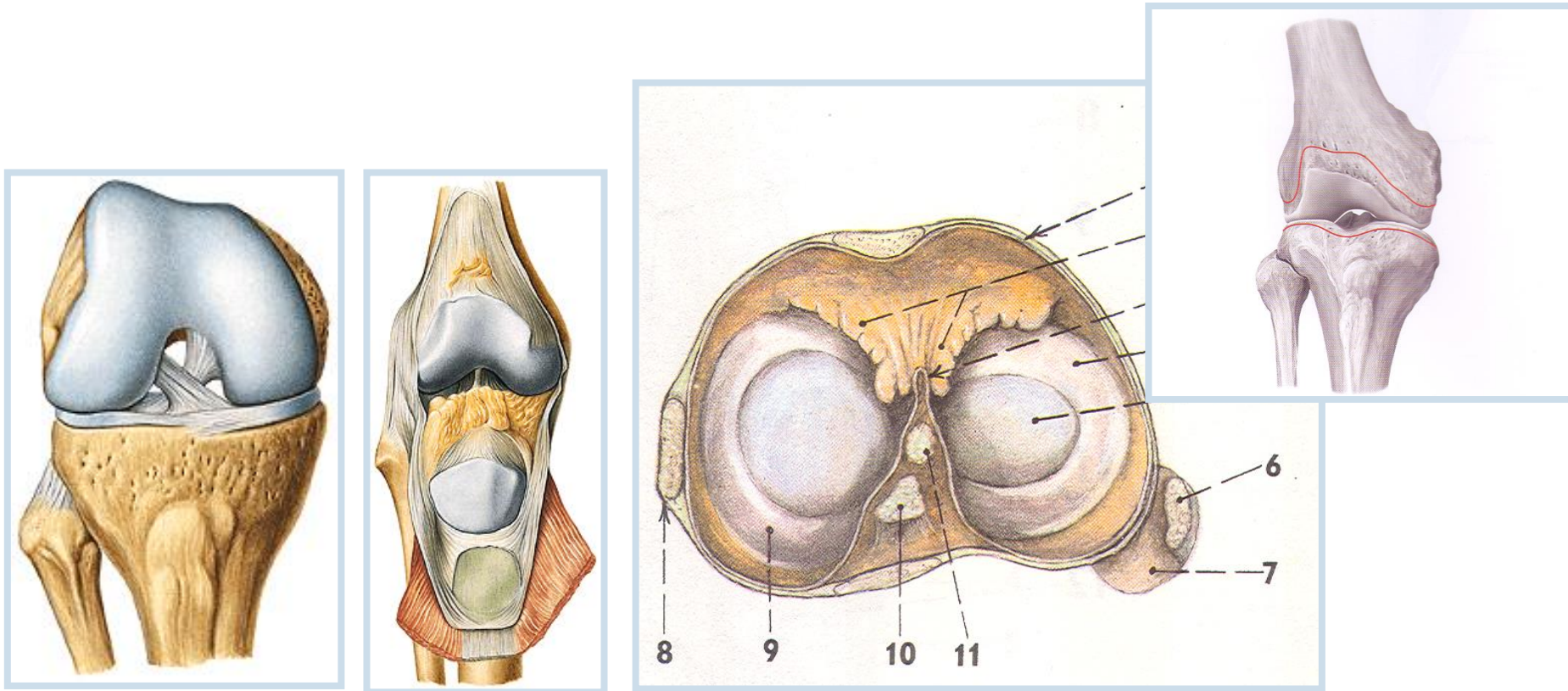


## 2. Articulatio genus (knee joint)

**Articular surfaces:**

**Articular capsule:** is strong, attached proximally a little above articular surface of the femur.

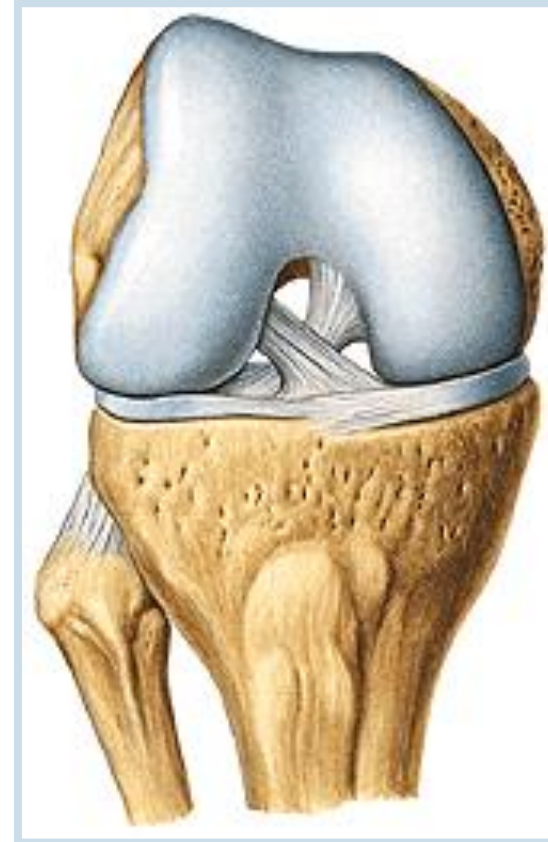
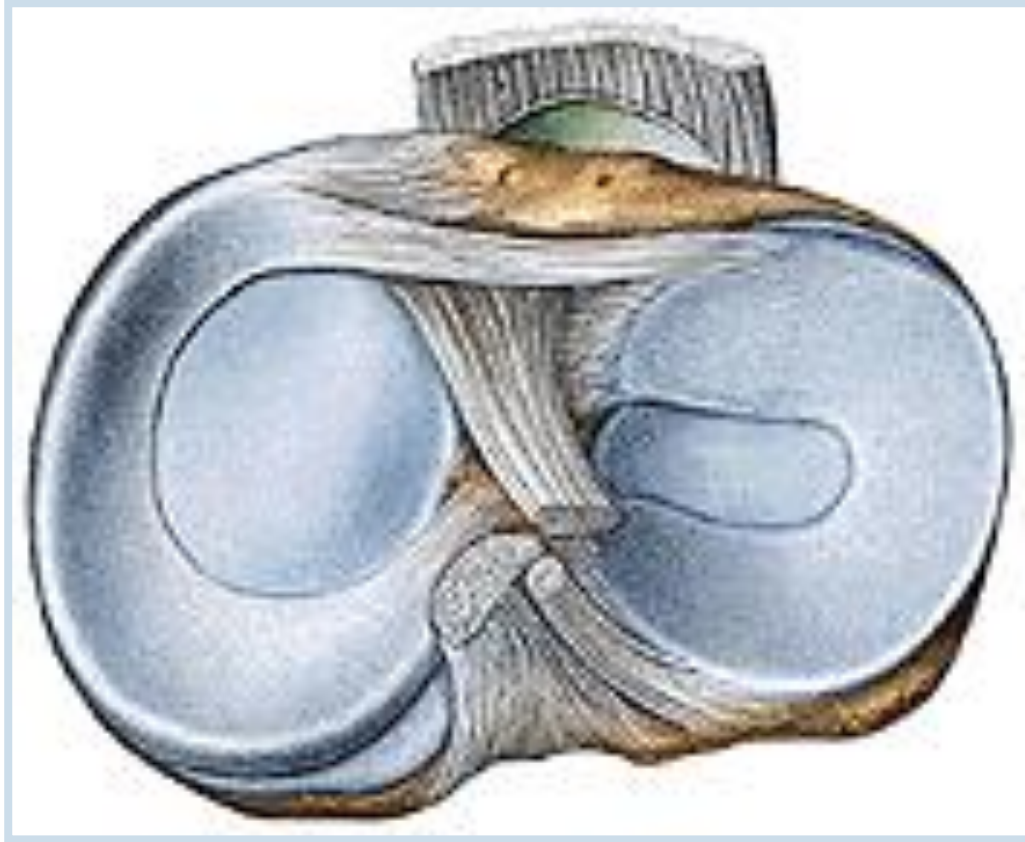
*Capsula synovialis* lines all articular cavity and runs from the sides to intraarticular ligaments and continues ventrally as a **plica synovialis patellaris** (synovial patellar plica), ventrally is divided into two **plicae alares** (alar plicae).



**Intraarticular auxiliary facilities of an *articulatio genus*** (knee joint):

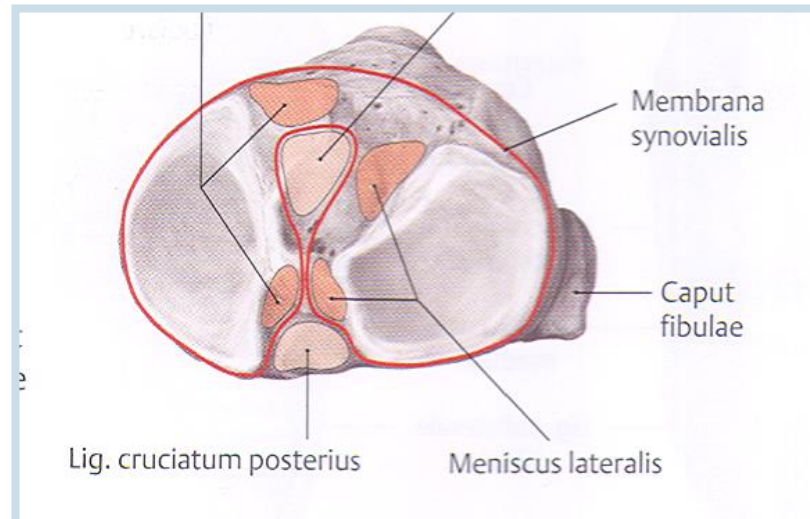
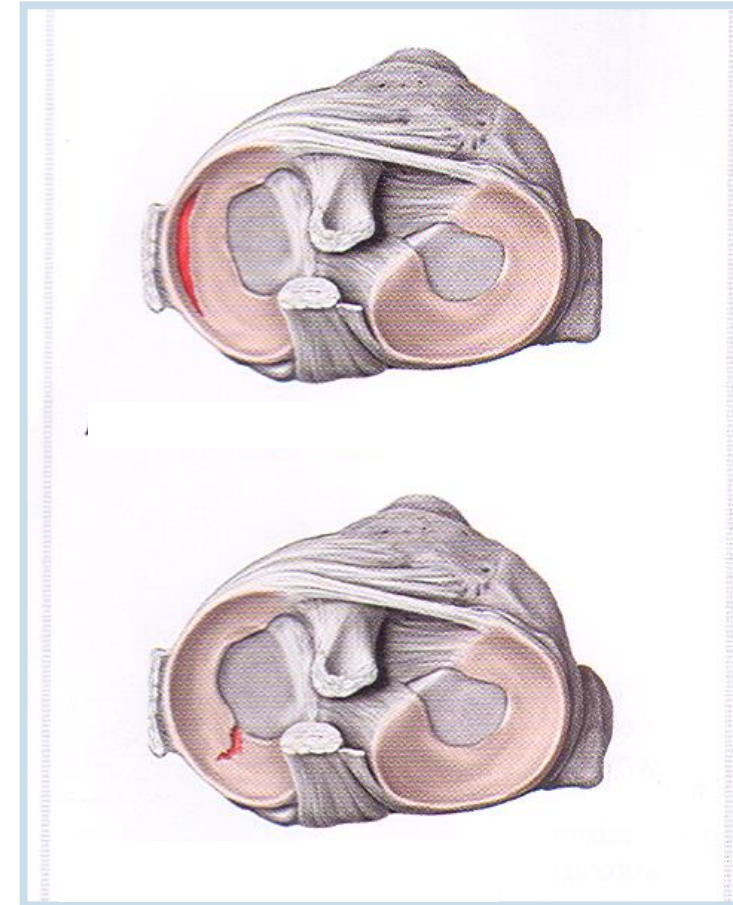
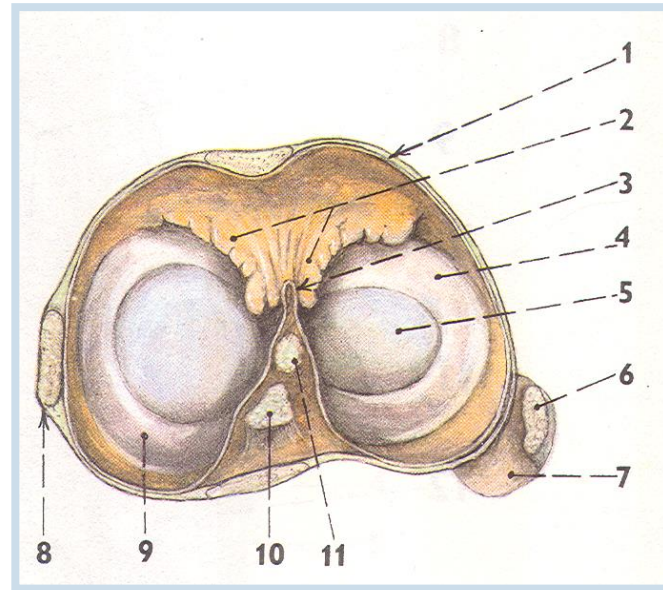
**1. Meniscus** – Medial and lateral

**2. Ligamenta cruciata genus** – *anterior* - limits extension and medial rotation  
*posterior* - limits extension and keeps stability of the joint



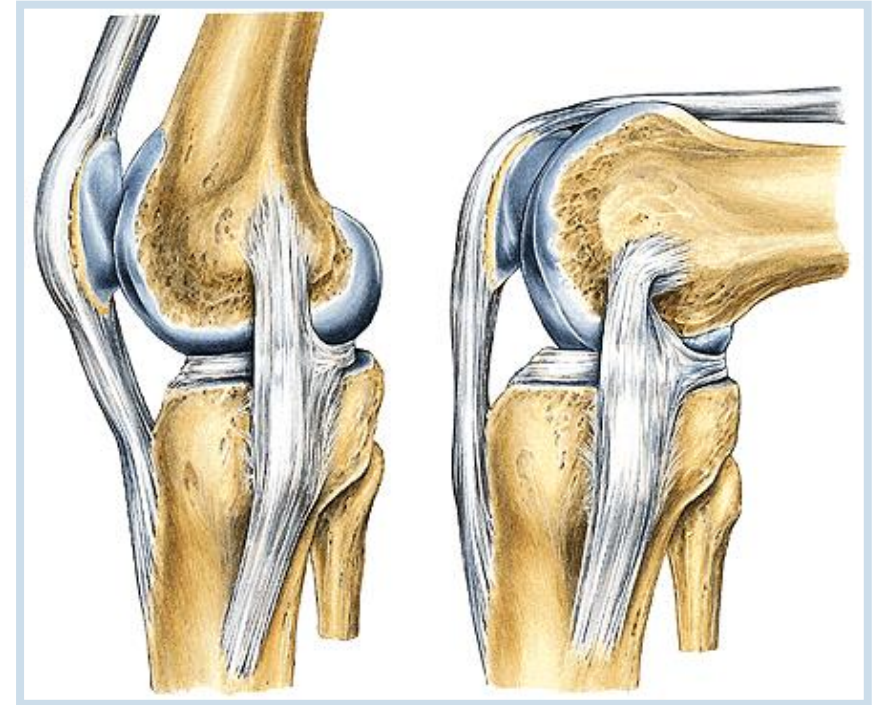
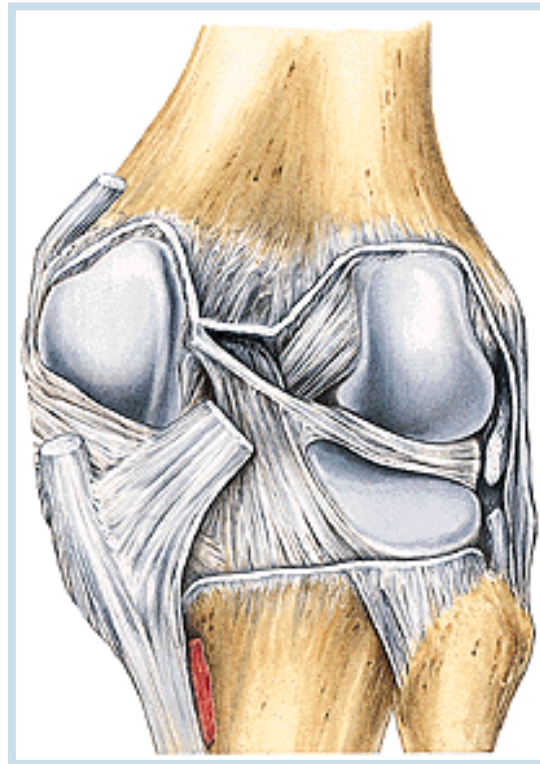
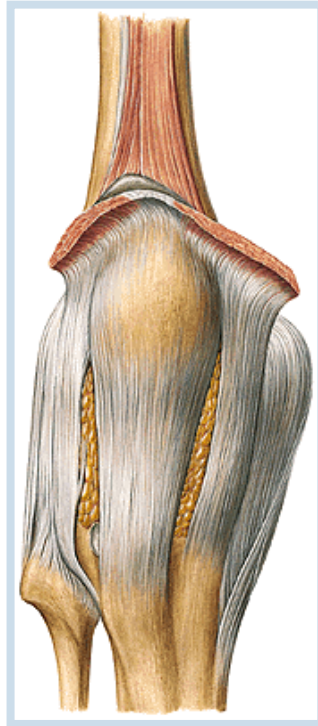


## Synovial membrane and position of corpus adiposum genus



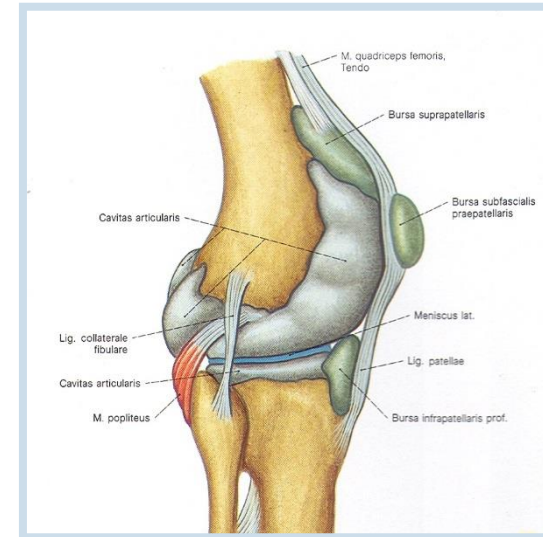
## 2. Extraarticular auxiliary facilities (articulatio genus)

- a) **lig. patellae** - tendon of m. quadriceps femoris
- b) **retinacula patellae mediale** and **laterale**
- c) **lig. collaterale tibiale** (collateral tibial ligament)
- d) **lig. collaterale fibulare** (collateral fibular ligament)
- e) **lig. popliteum obliquum** (oblique popliteal ligament)



# Bursae synoviales

Suprapatellaris, praepatellaris (subcutanea)

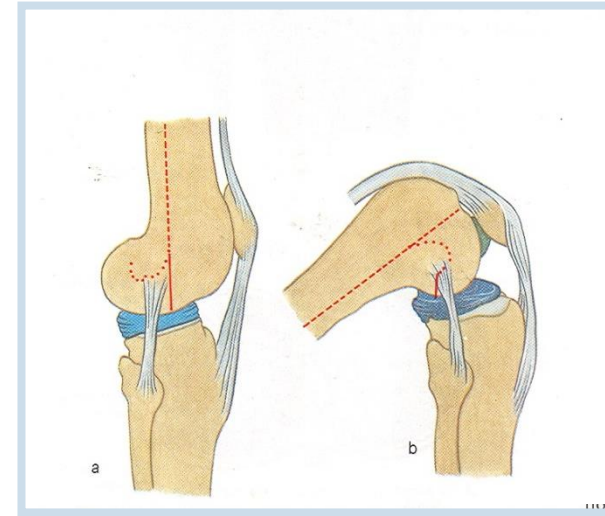
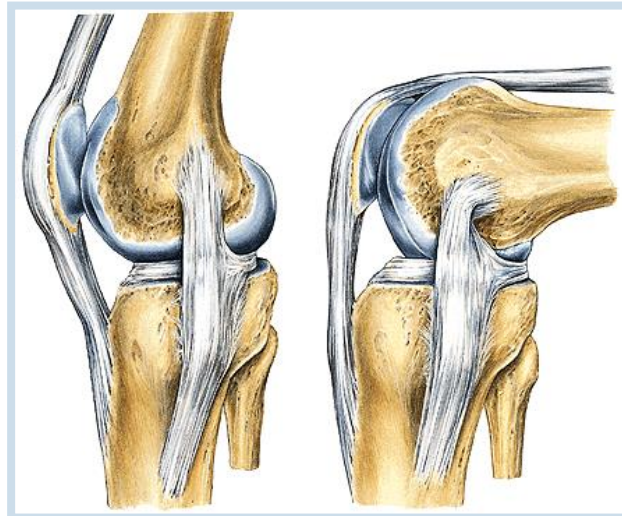


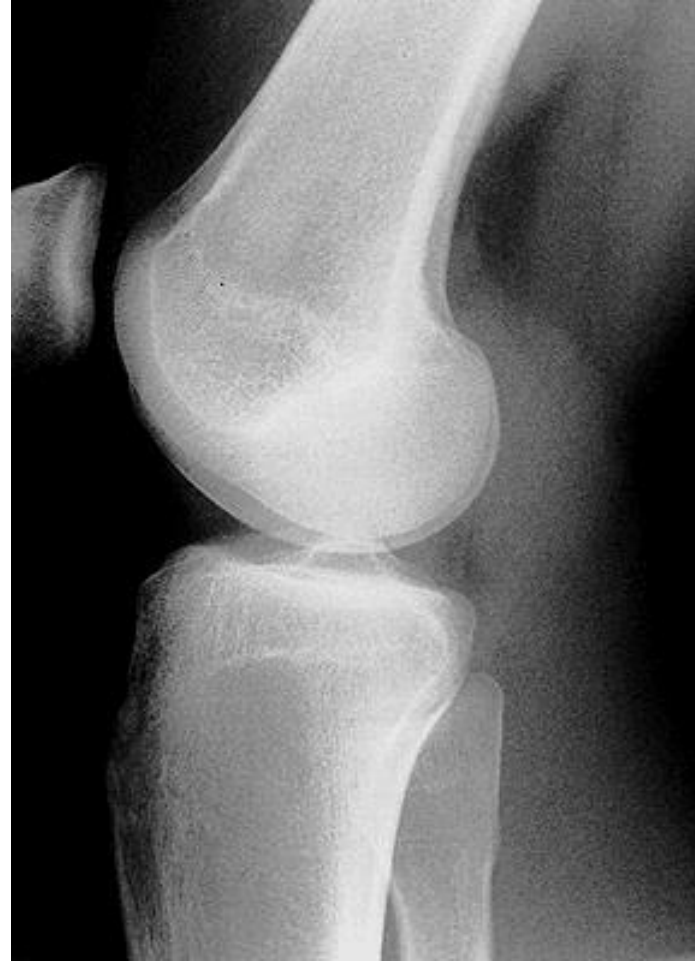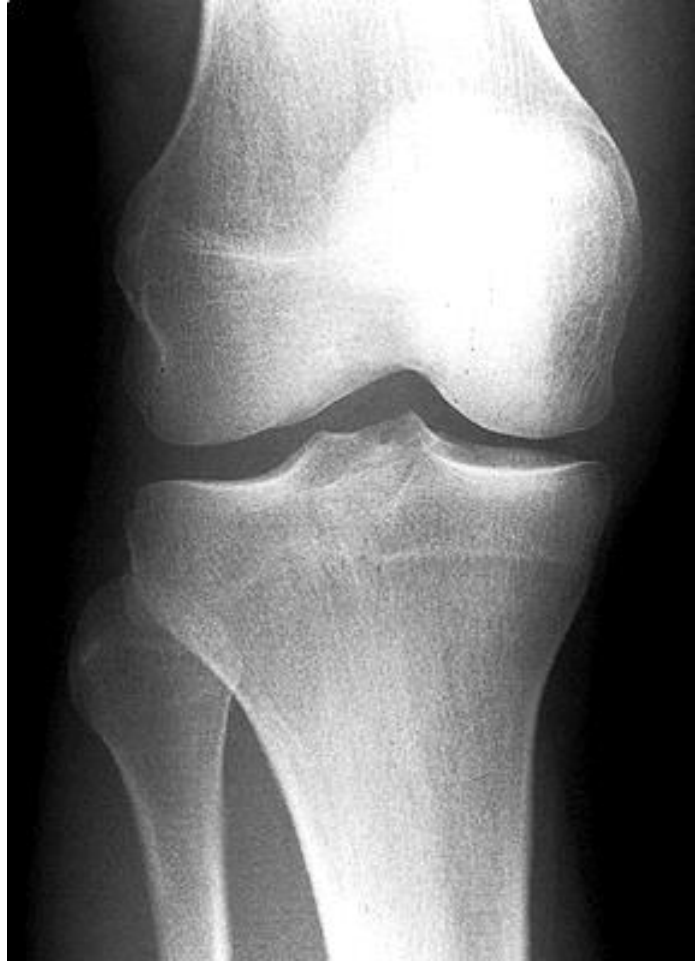**Type of joint:** hinge joint (trochlear)

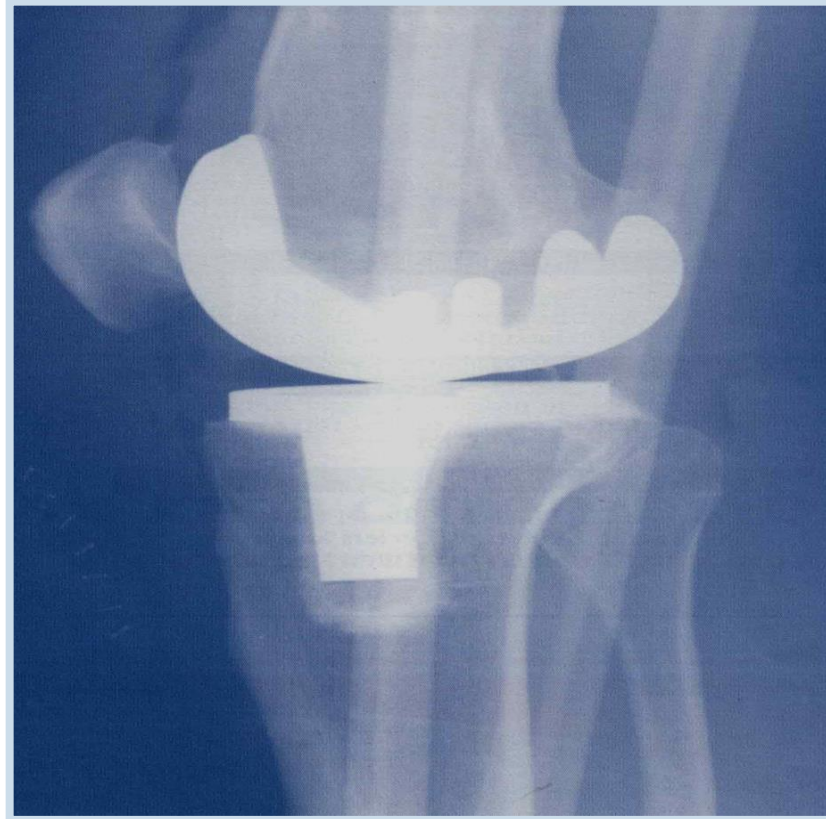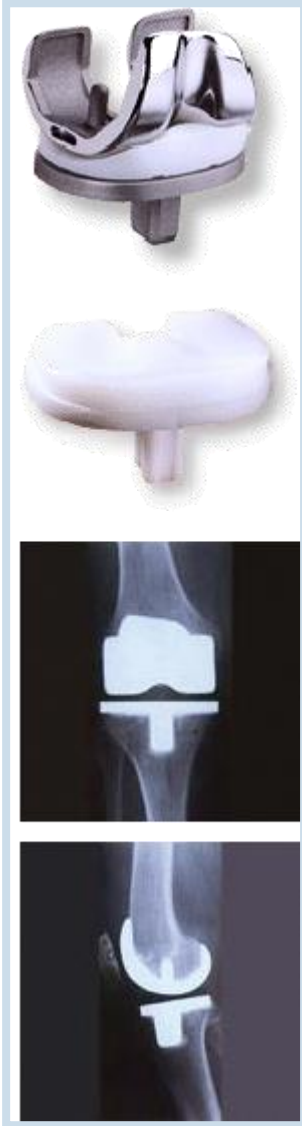**Movements:** flexion and extension.

During a mild flexion is possible slight external and internal rotation.

**Middle position of the joint – mild flexion**







### 3. **Juncturae tibiofibulares** (Tibiofibular connections)

Consist of *articulatio tibiofibularis*, *membrana interossea cruris* and *syndesmosis tibiofibularis*.

#### **A. Articulatio tibiofibularis** (tibiofibular joint)

**Articular surfaces:**

**Articular capsule:** is short, stiff and attached to margins of AS

**Auxiliary facilities :** *lig. capitis fibulae anterius* and *posterius*

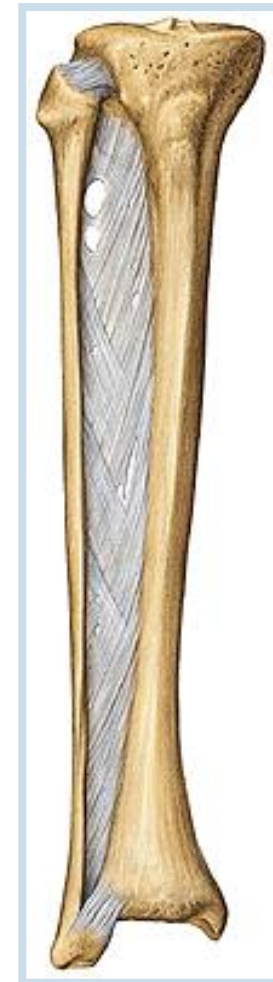
**Type of joint kloubu:** plane, slight movements ahead and back.

#### **B. Membrana interossea cruris**

stiff membrane. Serves as a place of attachment for some muscles.

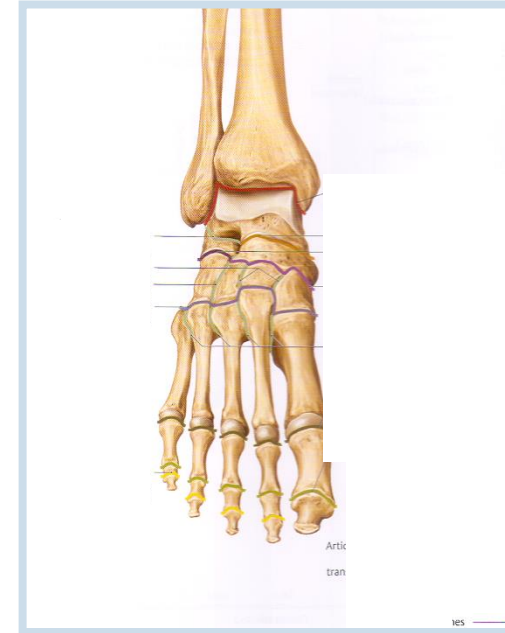
#### **C. Syndesmosis tibiofibularis** = *fibrous joint between distal ends of tibia and fibula*

In *incisura fibularis tibiae* is placed distal end of fibula. Syndesmosis is reinforced by *lig. tibiofibulare anterius* and *lig. tibiofibulare posterius* (tibiofibular anterior and posterior ligaments).



# Articulationes pedis (Joints of foot)

1. **Articulatio talocruralis** (Talocrural joint)
2. **Articulationes intertarseae** (Intertarsal joints)
  - Articulatio subtalaris (subtalar joint)
  - Art. talocalcaneonavicularis (talocalcaneal joint)
  - Art. calcaneocuboidea (calcaneocuboid joint)
  - „Articulatio tarsi transversa“ (Chopart’s joint)
  - Articulatio cuneonavicularis (Cuneonavicular joint)
  - Articulatio cuneocuboidea (Cuneocuboid joint)
3. **Articulationes tarsometatarsae** (Tarsometatarsal joints) – Lisfranck’s joint
4. **Articulationes metatarsophalangeae** (Metatarsophalangeal joints)
5. **Articulationes interphalangeae pedis** (Interphalangeal joints)



## A. Articulatio talocruralis (talocrural joint)

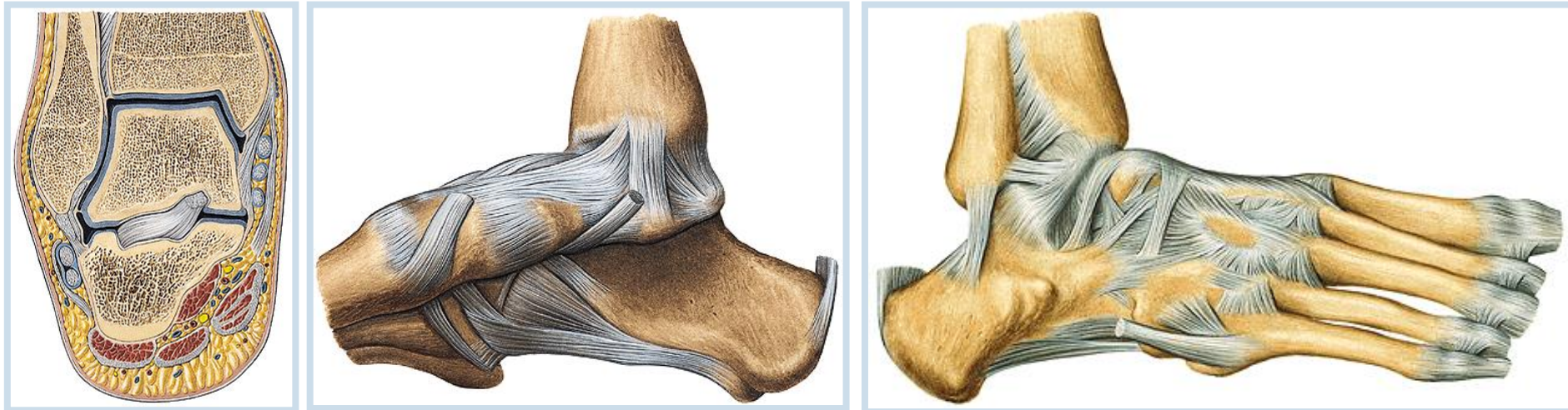
**Articular surfaces:**

**Articular capsule:** is attached to margins of AS

**Auxiliary facilities:** **Lig. collaterale mediale** consists of four parts running from medial ankle to adjacent bones (**pars tibionavicularis**, **tibiotalaris anterior**, **tibiotalaris posterior** and **pars tibiocalcanearis**).

From the lateral ankle run three ligaments: **lig. talofibulare anterius**, **lig. talofibulare posterius** and **lig. calcaneofibulare**.

**Type of the joint:** hinge joint, movements – plantar and dorsal flexion, slight side-to-side movements





## B. Articulationes intertarseae (Intertarsal joints)

### a) Articulatio subtalaris (Lower ankle joints)

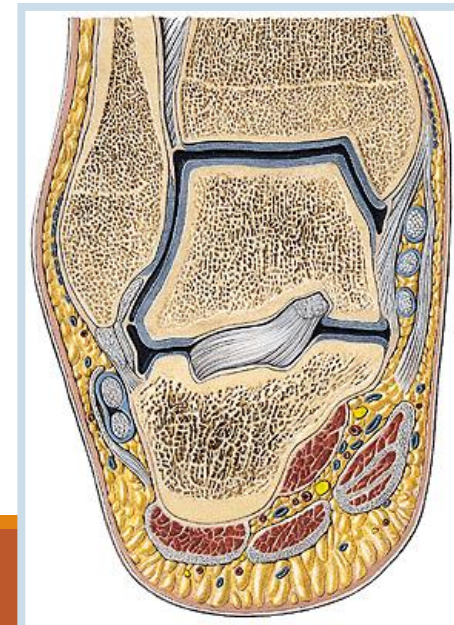
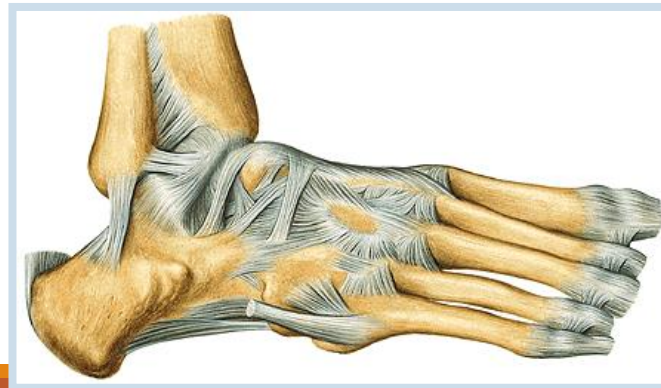
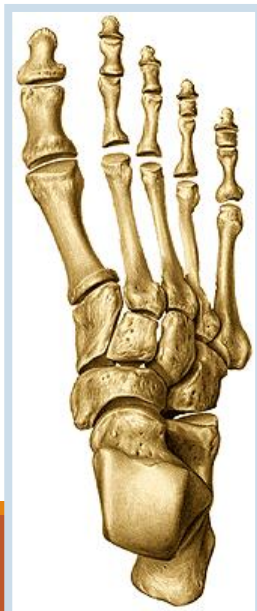**Articular surfaces:** facies articularis calcanea posterior and facies articularis talaris posterior.

**Articular capsule:** is short and is attached to...

**Auxiliary facilities:** lig. talocalcaneum laterale, mediale and inside of sinus tarsi is located lig. talocalcaneum interosseum.

**Type of joint:** together with art. talocalcaneonavicularis and calcaneocuboidea - functional unit.

Axis of **movements** - through **sinus tarsi**, inner rotation (pronation) and external rotation (supination).



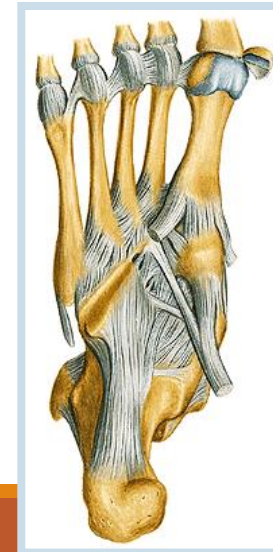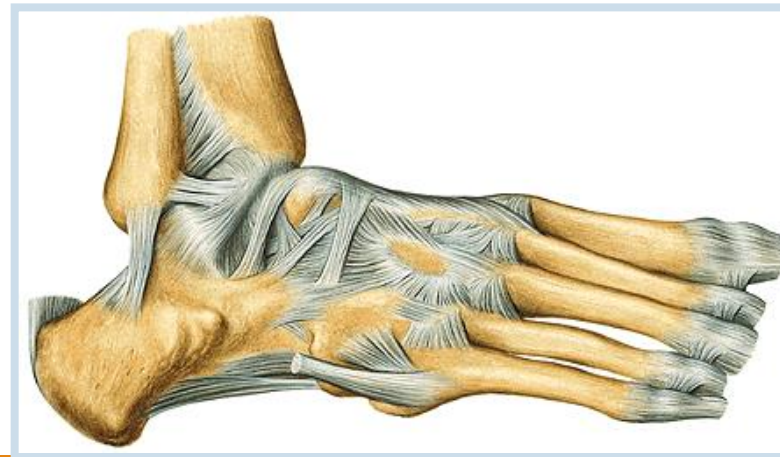
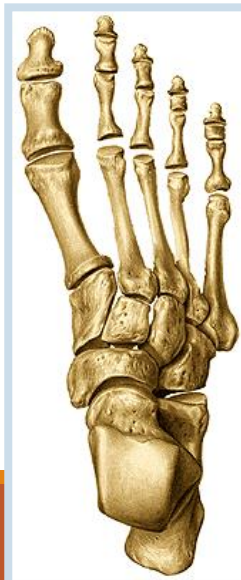## b) **Articulatio talocalcaneonavicularis** (Talocalcaneonavicular joint)

**Articular surfaces:** facies articularis calcanea anterior and media of talus and facies articularis talaris anterior and media of calcaneus, caput tali and articular surface of os naviculare.

**Articular capsule:** very thin and is attached to margins of AS

**Auxiliary features:** lig. calcaneonaviculare plantare. Dorsally forms lig. calcaneonaviculare dorsale a part of lig. bifurcatum. Small dorsal, plantar and interosseal ligaments join talus, calcaneus and os naviculare.

**Type of joint:** together with art. subtalaris and calcaneocuboidea form a functional unit. The axis of **movements** - through sinus tarsi, inner rotation (pronation) and external rotation (supination).



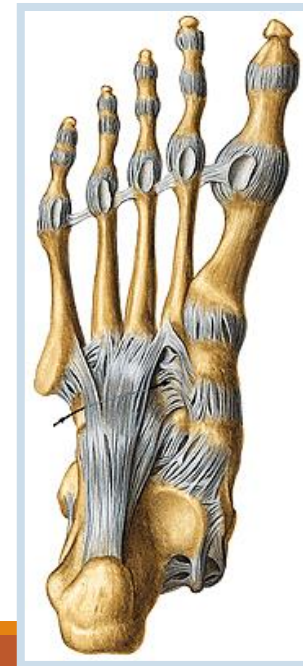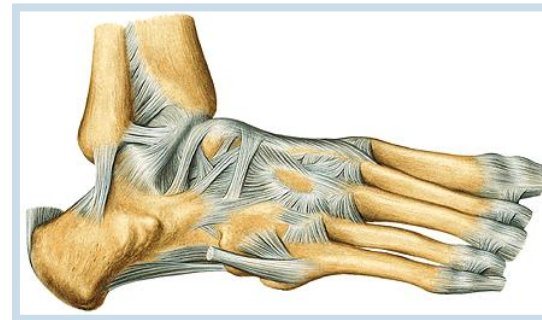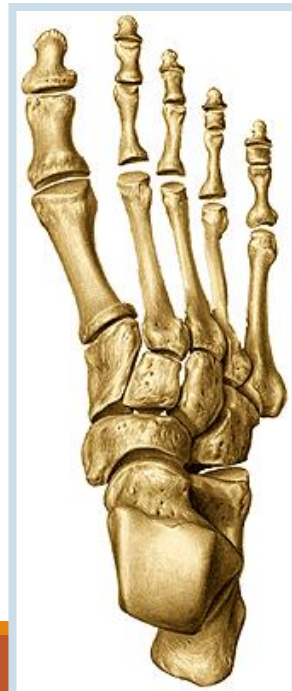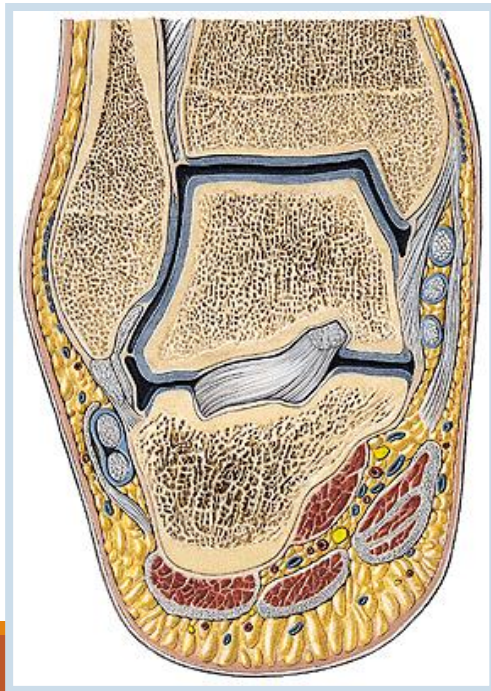
## c) **Articulatio calcaneocuboidea** (Calcaneocuboid joint)

**Articular surfaces:**

**Articular capsule:** thin and is attached to margins of AS

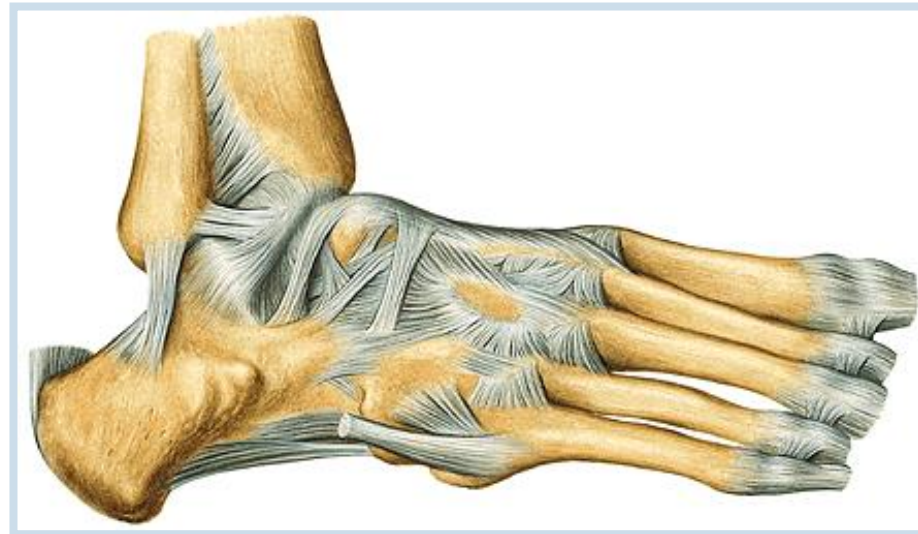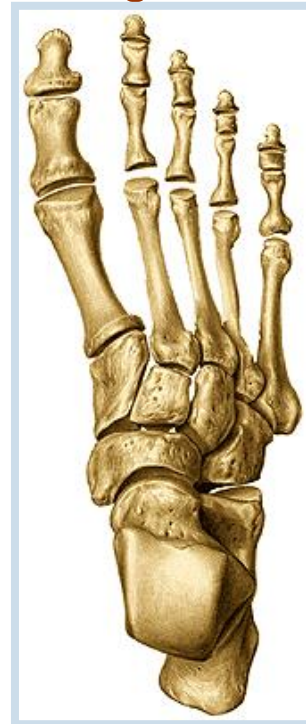**Auxiliary features:** *lig. calcaneocuboideum dorsale* (a part of *lig. bifurcatum*), *lig. plantare longum* and small ligaments between bones.

**Type of joint:** amphiarthrosis.



**d) Chopart's joint – *articulatio tarsi transversa*** – it is a fissure between *talus* and *os naviculare* medially and between *calcaneus* and *os cuboideum* laterally. Opening of this fissure - by cut of *lig. bifurcatum* (*lig. calcaneonaviculare* and *lig. calcaneocuboideum*).

**e) Articulationes cuneonavicularis, cuneocuboidea and intercuneiformia** are joints between adjacent tarsal bones; dorsal, plantar and interosseous ligaments.



## C. Articulationes tarsometatarseae (Lisfranc's joint)

Joint consists of three separated joints:

**Articular surfaces:**

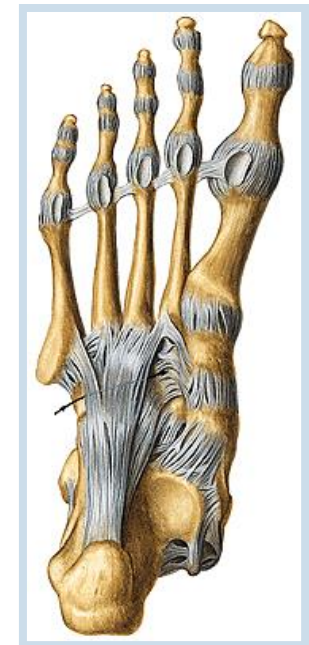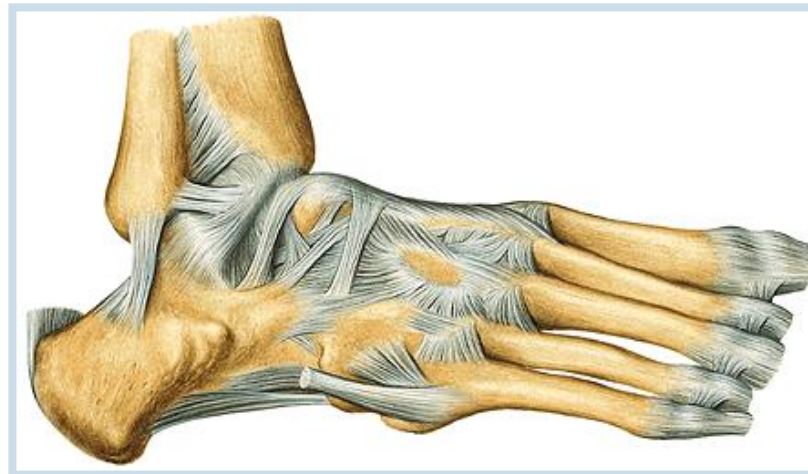**Articular capsule:** is thin and is attached to margins of AS

**Auxiliary facilities:** *lig. tarsometatarsea dorsalia, plantaria and interossea.*

**Type of joint:** amphiarthrosis, slight movements, specially during loading of plantar arch.

Between bases of metatarsal bones - (*articulationes intermetatarseae*)  
– *lig. metatarsea dorsalia, plantaria and interossea.*

In the fissure of Lisfranc's joint could be exarticulated toes of the foot.



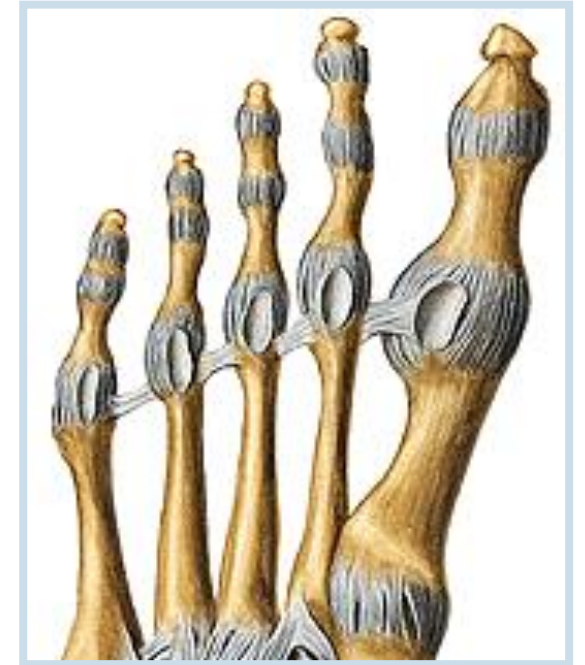## D. *Articulationes metatarsophalangeae*

**Articular surfaces:**

**Articular capsule:** is attached to margins of AS

**Auxiliary facilities:** *fibrocartilaginee plantares*, in the joint of the big toe are two *ossa sesamoidea*. Collateral ligaments and *lig. metatarsium transversum profundum*.

**Type of joint:** art. **spheroidea** (ball-and-socket joint), their mobility is restricted by collateral ligaments – flexion, extension, abduction and adduction.



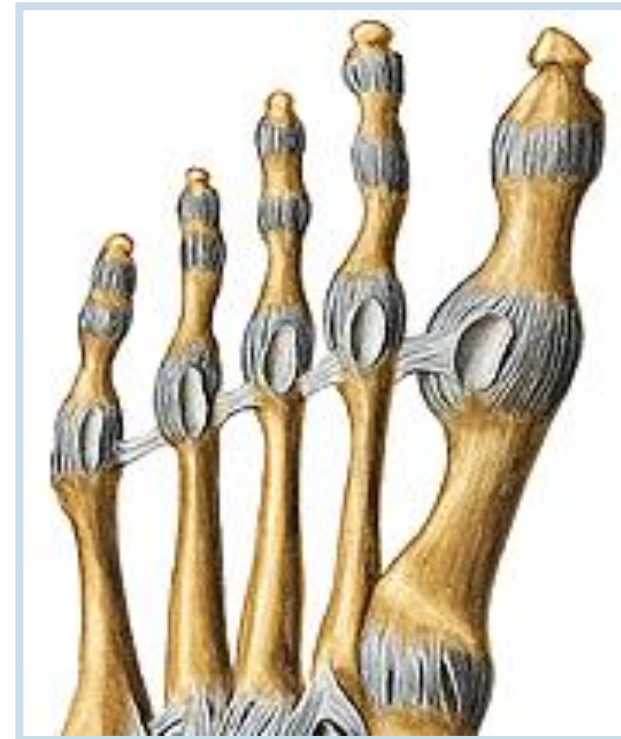## ***E. Articulationes interphalangeae pedis***

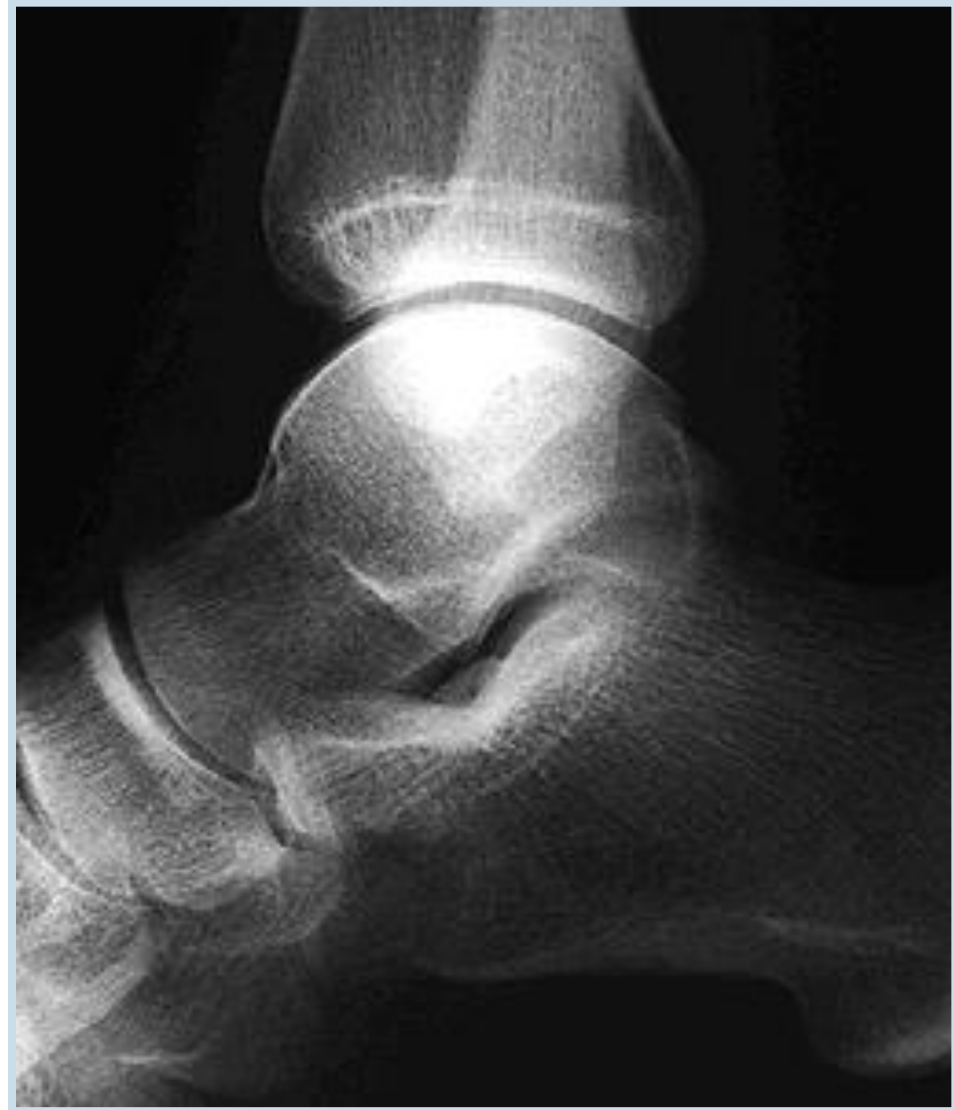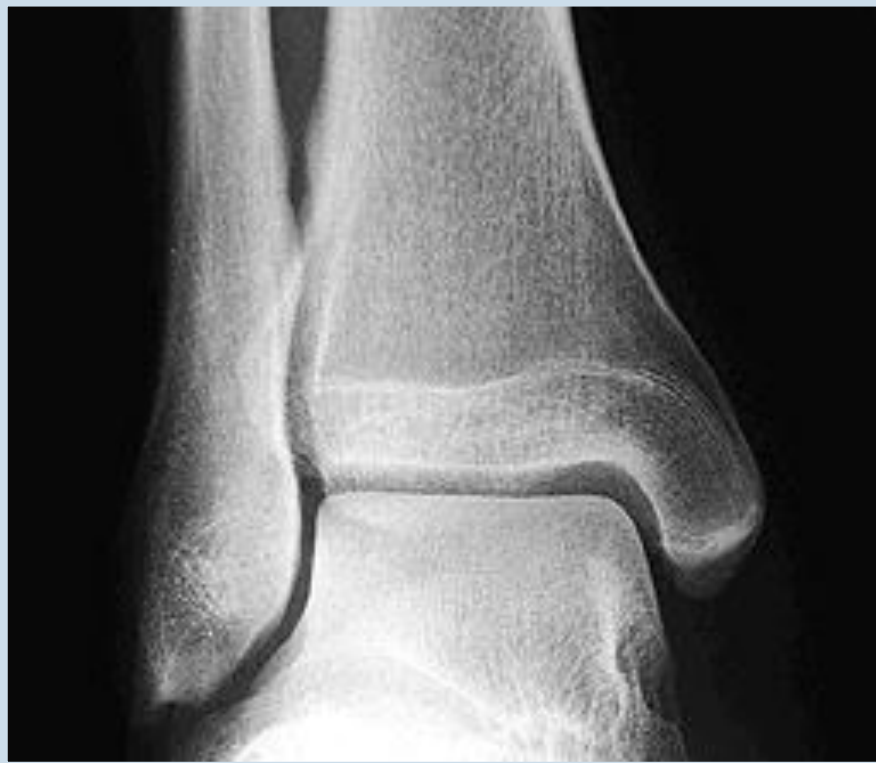**Articular surfaces:**

**Articular capsule:** are attached to margins of AS dorsally fuse with tendons of extensor muscles.

**Auxiliary facilities:** *collateral ligaments, fibrocartilagineae plantares*

**Type of joint:** **art. trochlearis** (hinge joint) - flexion and extension of phalanges.





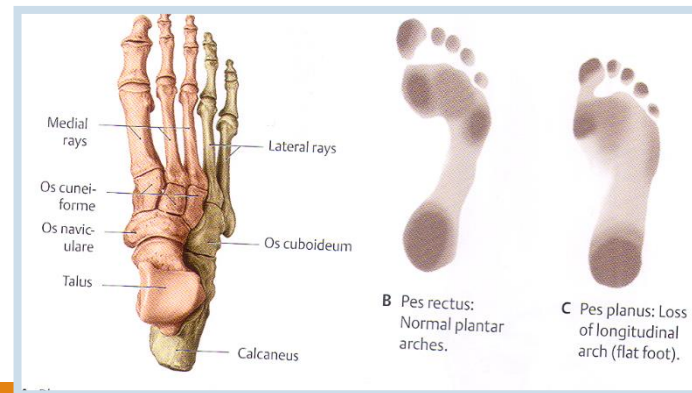


**F. Plantar arch** protects (vessels, nerves) before press, especially during long standing. Weight-bearing points are *tuber calcanei* and caput of the I. and V. metatarsal bones.

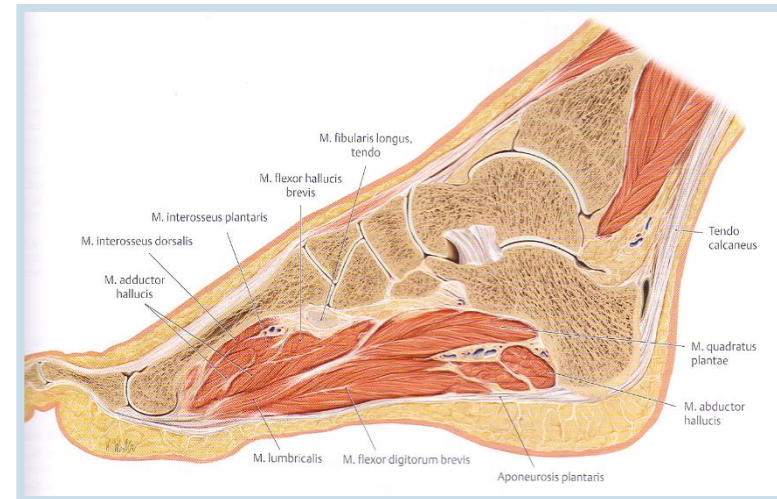
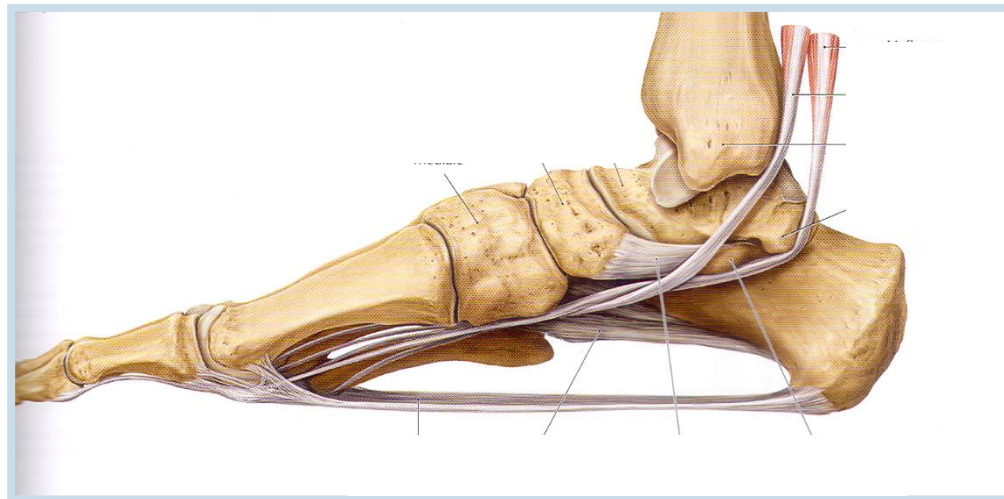
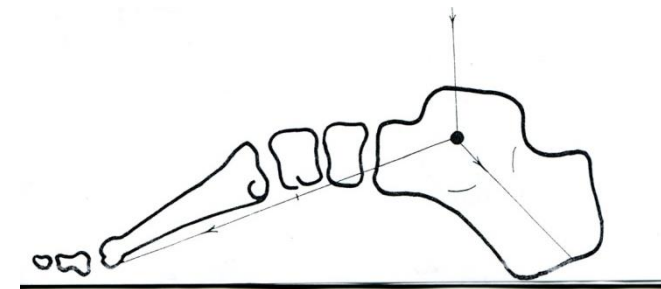
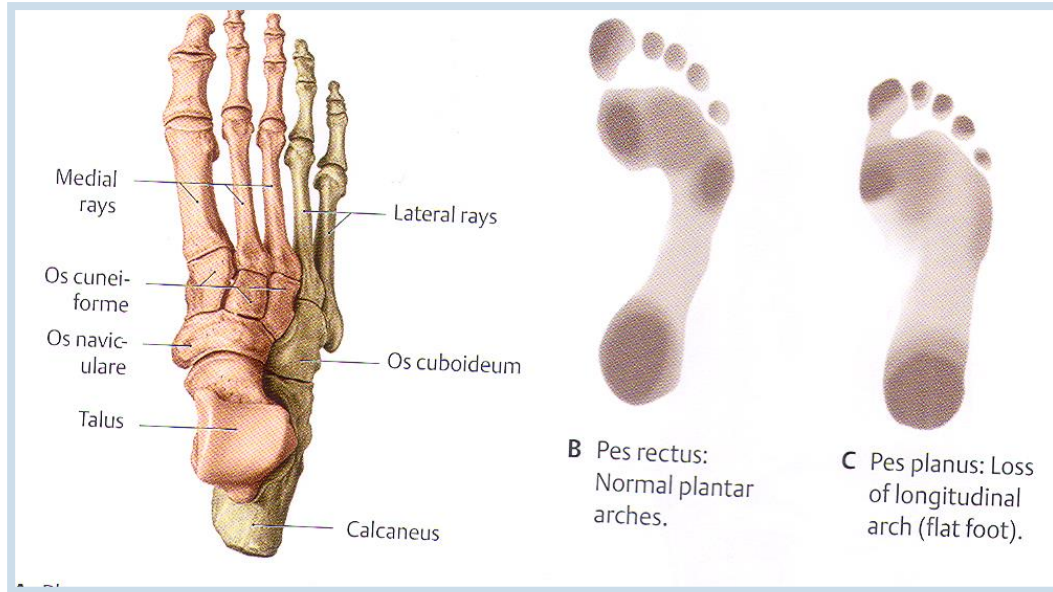
Two longitudinal plantar arches (medially *talus, os naviculare* and *ossa cuneiformia* and the I.–III. metatarsus, laterally *calcaneus, os cuboideum* and the IV. – V. metatarsus) and one transverse arch (*ossa cuneiformia*).

Medial plantar longitudinal arch is higher. Plantar arch is supported by ligaments and muscles of the foot.

Transverse plantar arch is done by the shape and position of the cuneiform bones (***ossa cuneiformia***), and it is carried by *m. fibularis longus* **mainly**.

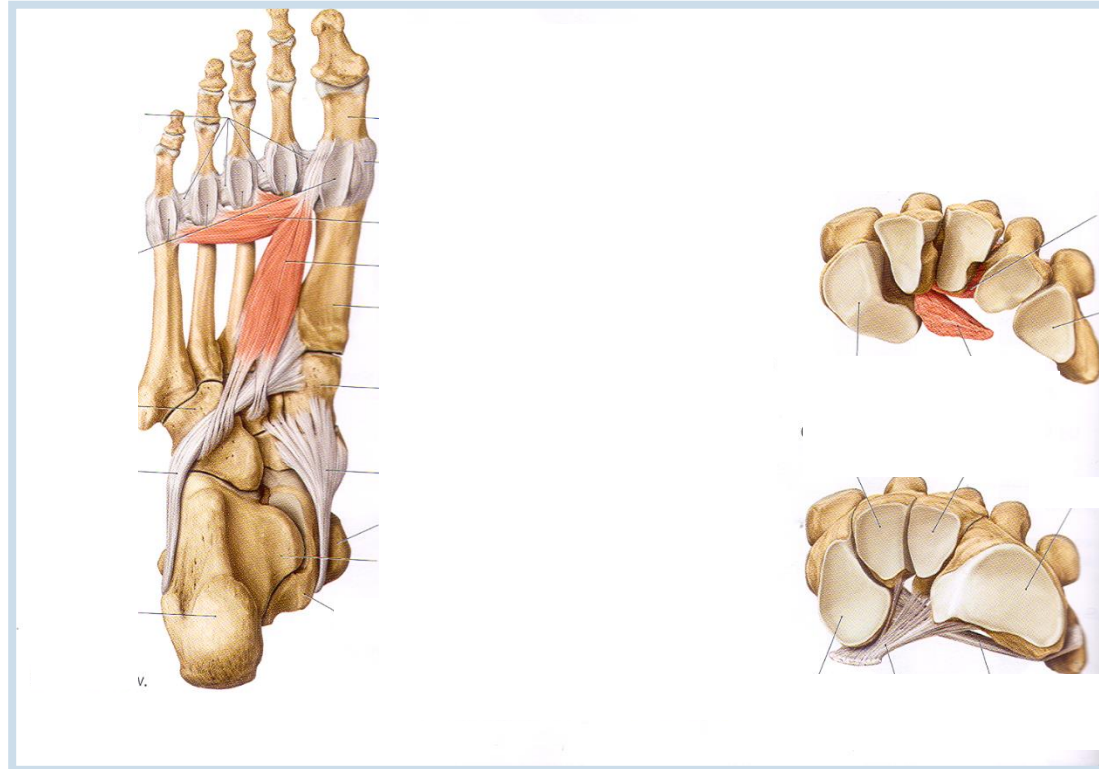
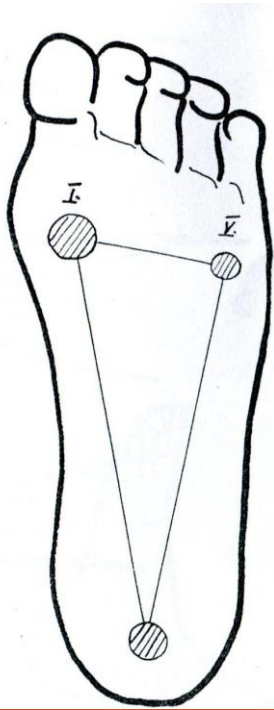


# Longitudinal plantar arch



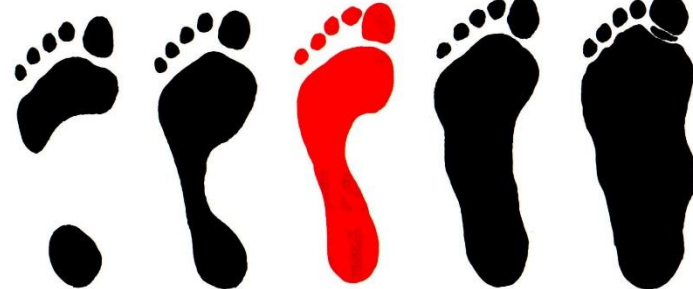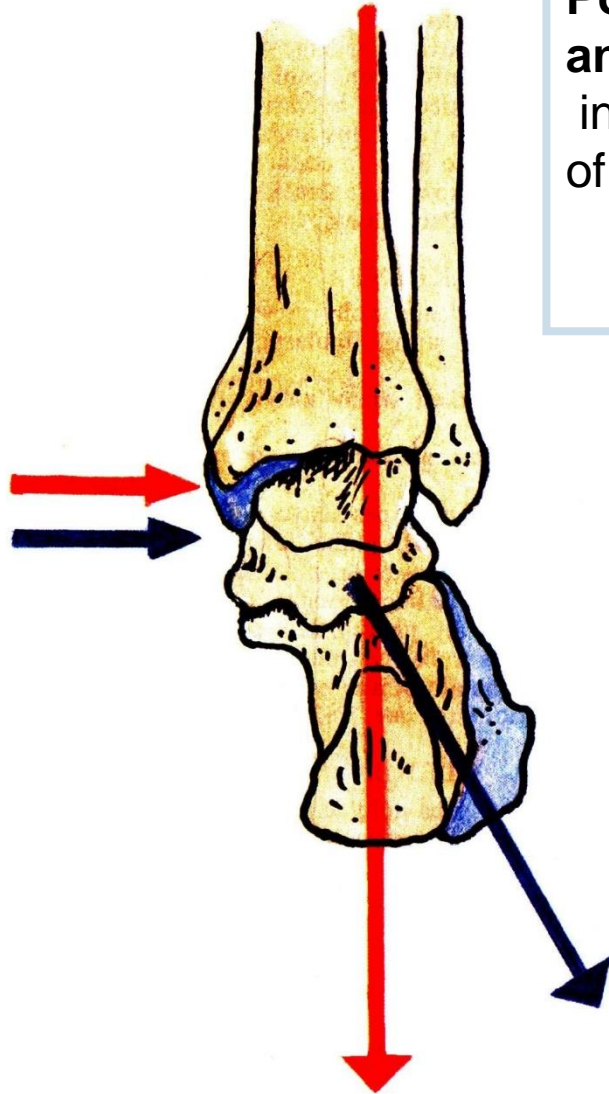
Lig. plantare longum, m. tibialis posterior et anterior, flexors of toes, aponeurosis plantaris

# Transverse plantar arch



m. fibularis longus  
m. tibialis ant.  
transverse ligaments

**Position of calcaneus – normal foot  
and flatfoot („Flatfoot“ – *pes planus* – severe pain  
in the foot and leg occurs, due to overstretching  
of the long muscles and nerves and vessels of the sole.**



**Pes cavus**

**Pes planus**

**Pes planovalgus**

# Thank you for your attention!!

---

The pictures for the presentation were taken from:

Netter: Interactive Atlas of Human Anatomy.

Naňka, Elišková: Přehled anatomie. Galén, Praha 2009.

Čihák, R. (1987): Anatomie I. Avicenum, Zdravotnické nakladatelství.

Platzer, W., Kahle, W., Leonhardt H. (1992): Locomotor system. Georg Thieme Verlag, Stuttgart,

New York, 4th edition.

Drake et al: Gray's Anatomy for Students. 2010

Archiv of the lecturer, archiv of the Department of Anatomy, MU, Brno

Moore, K. L. (1992): Clinical oriented anatomy. Third edition. Williams&Wilkins, A Waverly Company.

Gilroy, A. M. et all. (2009): Atlas of Anatomy. Thieme New York, Stuttgart.

Putz, R. (2008): Atlas of Human Anatomy Sobotta. Elsevier Books.