

REVIEW

The Role of High-Resolution Computed Tomography in the Evaluation of Pneumoconiosis

 Levent Soydan

Department of Radiology, University of Health Sciences Turkey, Hamidiye Faculty of Medicine, Haydarpaşa Numune Health Application and Research Center, Istanbul, Turkey

Abstract

Inhalation of dust, noxious agents, or fume in certain occupational environments may cause pulmonary damage in exposed workers. Recognition of these pneumoconiosis is important both for treatment and prevention of the disease condition. Although may pneumoconiosis may be detected by chest X-ray, the use of high-resolution computed tomography (HRCT) combined with exposure history and clinical features allows to reach to a specific diagnosis or at least to narrow the differential diagnosis thanks to its ability to demonstrate lung parenchymal architecture in a superior way. In this article, we review the common HRCT appearances of a spectrum of occupational lung diseases.

Keywords: High-resolution computed tomography; occupational diseases; pneumoconiosis.

Occupational lung disease is a condition where inhalational exposure to dusts, fumes, or noxious substances causes pulmonary damage in people working in certain specific occupations. High-resolution computed tomography (HRCT) is superior to conventional chest radiography (CR) in showing pulmonary architecture and pathology. Characteristic radiological-pathological features of HRCT may suggest the diagnosis in certain specific pneumoconiosis while a combination of HRCT findings, occupational history, and clinical findings is necessary to reach the diagnosis in other occupational lung diseases.

There is a rising concern of adverse health effects of harmful exposures in workplaces in recent decades. Diagnosis of pneumoconiosis is important both in workers and in coworkers to enable primary and secondary prevention of disease progression. Differential diagnosis of pneumo-

coniosis from a non-occupational lung disease may sometimes be needed as both conditions may have resembling features due to the limited capacity of the lung to injuries. In these cases, a definite history including exposure to a particular agent known to cause interstitial lung disease and an appropriate latency period should be obtained. Furthermore, a history and presence of consistent clinical findings related to the suspected occupational disease should also be assessed. A combination of appropriate clinical, radiological, and physiological findings suggestive of a particular pneumoconiosis may suffice for establishing a diagnosis obviating the need for a lung biopsy. However, in atypical radiological and/or clinical presentations or in cases, where the occupational agent is poorly characterized, a lung biopsy becomes necessary. CR has been conventionally used in the detection of pneumoco-

Correspondence (İletişim): Levent Soydan, M.D. Sağlık Bilimleri Üniversitesi Hamidiye Tıp Fakültesi, Haydarpaşa Numune Sağlık Uygulama ve Araştırma Merkezi, Radyoloji Anabilim Dalı, İstanbul, Turkey

Phone (Telefon): +90 533 395 64 90 **E-mail (E-posta):** levent.soydan@gmail.com

Submitted Date (Başvuru Tarihi): 10.08.2020 **Accepted Date (Kabul Tarihi):** 30.08.2020

Copyright 2021 Haydarpaşa Numune Medical Journal

OPEN ACCESS This is an open access article under the CC BY-NC license (<http://creativecommons.org/licenses/by-nc/4.0/>).



niosis as the diagnosis may be established with CR in the presence of suggestive radiological findings and known history of occupational exposure. Despite its wide availability and low inherent cost, CR has a low sensitivity and can miss the diagnosis in 10–15% of pathologically proven cases.

CT, in particular HRCT, has been shown to have superiority to CR both in diagnosing pneumoconiosis and making the differential diagnosis with a low interobserver variability. Due to its limited availability and inherent cost, HRCT is usually not considered a screening modality for pneumoconiosis but is rather indicated as a thorough investigation method for patients positively identified by CR. HRCT not only enables to make a more accurate diagnosis compared to CR but also thanks to its ability to recognize the disease patterns in earlier stages therapeutic intervention becomes possible with a more favorable prognostic outcome. HRCT has the known hazard of radiation and attempts have been made to reduce the radiation dose during patient examinations by low-dose CT techniques and by limiting the number of acquired slices, especially if HRCT is used for screening purposes.

In this study, we review the HRCT appearances of a variety of occupational lung diseases including those identified in a group of workers with biopsy-proven pneumoconiosis and respective occupational histories.

Silicosis

Silicosis is caused by inhalation of crystalline silicone dioxide particles. Silicosis may be seen in people working in mining, drilling, ceramics and glass manufacturing, sandblasting, construction, roadwork, and tunneling. Silicosis can be acute or chronic. Tuberculosis and malignancy are the complications of silicosis.

Acute Silicosis

Acute silicosis is mainly seen in sandblasters who have been exposed to high amounts of silica dust within a short time. Multiple bilateral centrilobular densities, multifocal patchy ground-glass densities, and consolidation with crazy paving pattern (Fig. 1) constitute the HRCT findings seen in acute silicosis^[1,2].

Classic Silicosis

Chronic silicosis can be seen in simple or complicated forms. In simple form, multiple small nodules (2–5 mm) with calcifications are seen especially in posterior zones of upper lobes (Fig. 2). On HRCT, these nodules are centrilobular, paraseptal, or subpleural in perilymphatic distribution.

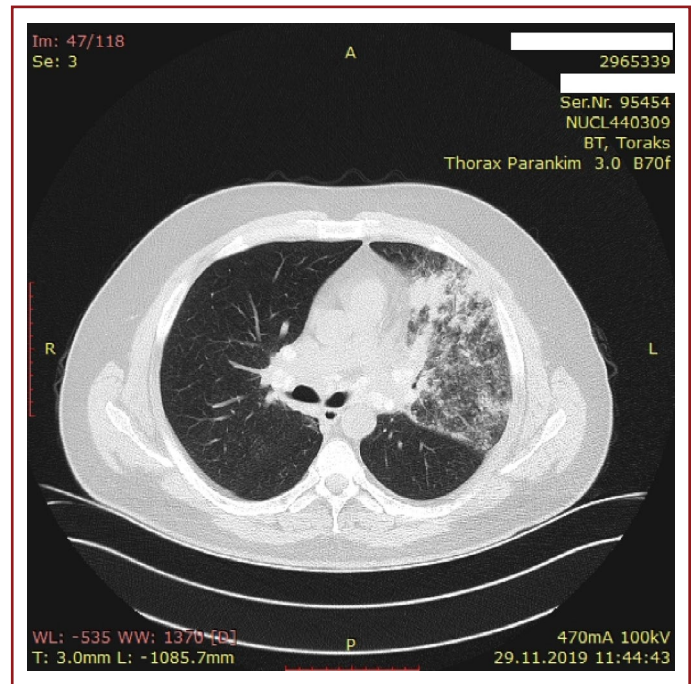


Figure 1. Silicosis in a 50-year-old stone crusher. Axial high-resolution computed tomography with lung window (W: 1500, C: –500) shows coalescing diffuse ground-glass opacities and interlobular septal thickenings on the left upper lobe.

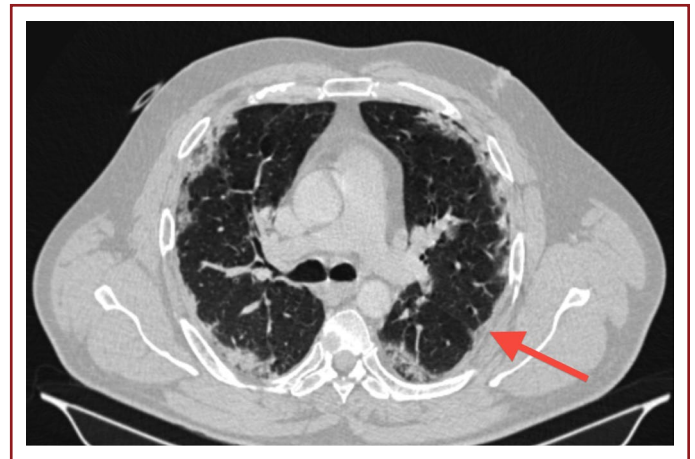


Figure 2. Silicosis in a 65-year-old mason. Axial high-resolution computed tomography with lung window (W:1500, C: –500) shows micronodules on both upper lobes, best seen on the right side, with bilateral subpleural pseudo plaque formation (arrow).

These parenchymal lesions may follow hilar or mediastinal lymphadenopathy. Some lymph nodes may calcify in eggshell pattern (Fig. 3)^[3–5]. Acute silicosis should be differentiated from sarcoidosis in that the nodules are more uniform and diffuse in silicosis whereas they are clustered centrally with a peribronchovascular distribution in sarcoidosis.

In complicated silicosis, individual nodules coalesce into

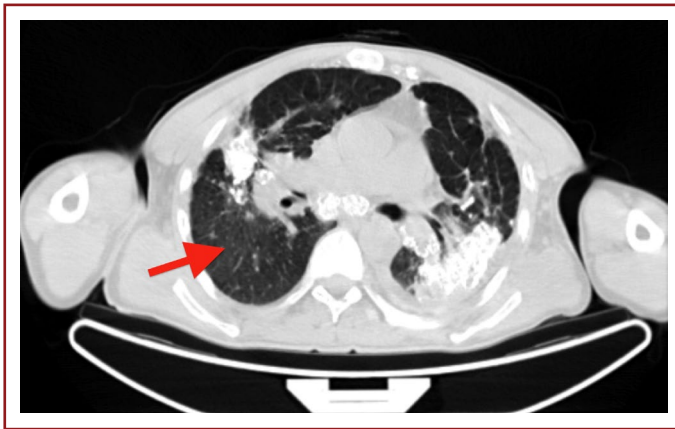


Figure 3. Complicated silicosis in a 53-year-old stone worker. Axial high-resolution computed tomography (W:1500, C: -500) shows bilateral upper lobar massive fibrosis with pleuroparenchymal scarring and extensive calcification. There are also ill-defined micronodules on the right superior basal lobe (arrow) and eggshell calcifications on mediastinal lymph nodes.

massive fibrosis seen as soft-tissue masses larger than 1 cm diameter with irregular borders, often with calcifications in apical and posterior segments of upper lobes, accompanied with emphysematous changes (Fig. 3). With progression, these fibrotic masses extend toward the hila causing traction-associated emphysema^[6,7].

In silico tuberculosis that can arise as a complication asymmetric nodule, consolidation, cavitation, and progression of findings is common (Fig. 4).

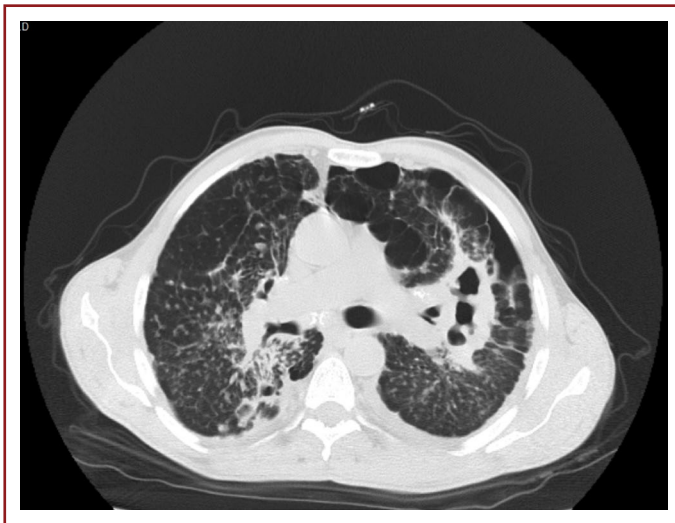

Figure 4. Silicotuberculosis in a 47-year-old man working in manufacturing industry. Axial high-resolution computed tomography image (W:1500, C: -500) shows thick-walled cavitary lesion with irregular borders on the left upper lobe, suggestive of tuberculosis. There are also diffuse ill-defined nodules on both lungs, bilateral pleuroparenchymal fibrotic changes on both lower lobes, and paracatricial emphysema on the left upper lobe.

Coal Worker's Pneumoconiosis (CWP)

Simple CWP is caused by exposure to washed coal or mixed dust of coal, kaolin, mica, and silica. On HRCT, 1–5 mm nodules are found mainly in perilymphatic distribution of upper lung zones (Fig. 5). Compared to silicosis, these nodules have less distinct margins and when subpleural they can aggregate to appear as pseudo plaques. Calcification is seen in 30% of patients^[8,9].

Complicated CWP occurs less common than silicosis and is the progressive massive fibrosis seen as soft-tissue masses >1 cm at lung mid-zones and periphery which progressively migrate toward the hila causing subpleural or paracatricial emphysema which may cavitate with or without infection (Fig. 6). In 20% of cases, interstitial pulmonary fibrosis may follow with an increased incidence of carcinoma^[10,11].

Asbestosis

Asbestos exposure occurs in construction workers, building maintenance, mining, milling, industries manufacturing brake pads, furnaces, ovens, tiles, bricks, insulation material, automobile, and shipbuilding industry. Exposure

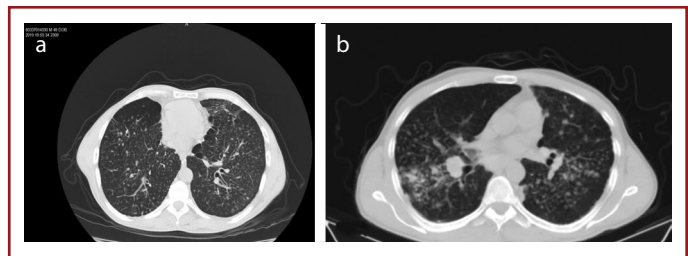


Figure 5. Coal workers pneumoconiosis in a 57-year-old-man (a) and 53-year-old man (b) who worked for 23 years and 21 years in coal mines, respectively. There are diffusely scattered centrilobular and subpleural nodules in both cases.

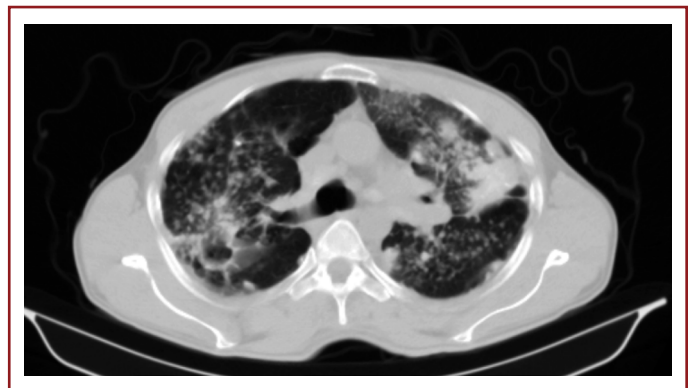


Figure 6. Progressive massive fibrosis in a 60-year-old coal worker. There are fibrotic conglomerates on both upper lobes surrounded by diffusely scattered nodules.

to asbestos may cause pleural disease, round atelectasis, asbestosis, or mesothelioma.

Unilateral or bilateral exudative pleural effusion may be the earliest sign of pleural involvement. As the effusion regresses, diffuse thickening of the visceral pleura is seen in 50% of patients^[12]. More commonly distinct parietal pleural plaques develop usually adjacent to the posterior arches of the sixth and tenth ribs and/or along the central diaphragm (Fig. 7)^[13,14]. Differential diagnosis includes rheumatoid arthritis, lymphangiomyomatosis, CWP, tuberculosis, and lymphangitic spread of carcinoma.

Rounded atelectasis is seen as a round or oval mass adjacent to the pleura with a comet tail sign comprised of curving bronchovascular structures leading into the mass (Fig. 8)^[15].

Asbestosis is the interstitial fibrosis caused by exposure to asbestos. On HRCT, ground-glass opacity, subpleural curvilinear densities, interlobular septal thickening, parenchymal bands traction bronchiectasis, and poorly defined subpleural centrilobular nodules may be seen^[13]. The presence of the latter and pleural disease differentiates asbestos from other conditions causing pulmonary fibrosis^[14].

Mesothelioma manifests itself as unilateral pleural effusion and nodular or diffuse pleural thickening including the mediastinal pleura (Fig. 9).

Calcinosis

Inhalation of limestone dust causes calcinosis. Limestone consists mainly of calcium carbonate, but also of magne-

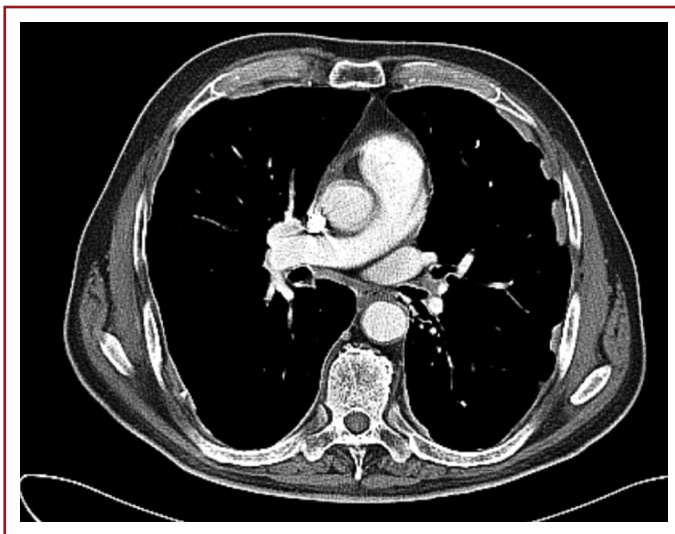


Figure 7. Mediastinal window of an axial high-resolution computed tomography image (W: 350, C: 50) shows asbestos-related pleural plaques on the left lung in a 65-year-old man who has worked for 25 years in a clutch plate manufacturing factory.

sium oxide, silica dioxide, and aluminum oxide. HRCT findings are not well established, however, small nodules have been described^[16,17].

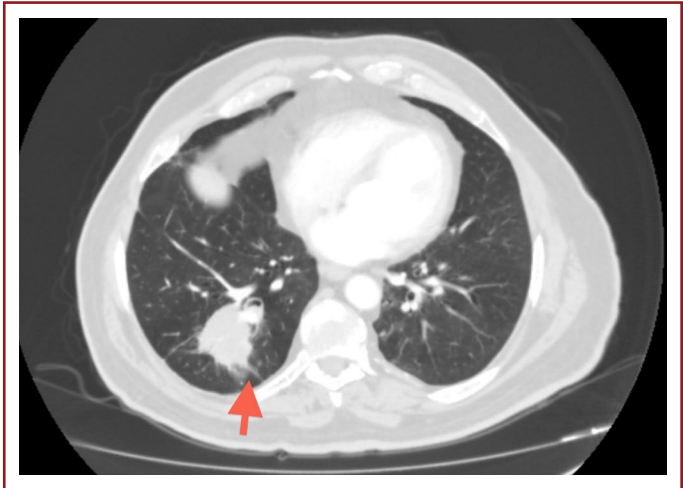


Figure 8. Asbestos-related round atelectasis on the superior segment of the right lower lobe in a 49-year-old man. Axial high-resolution computed tomography image (W: 1500, C: -500) shows a round consolidation with a curving tail called the comet tail sign (arrow).

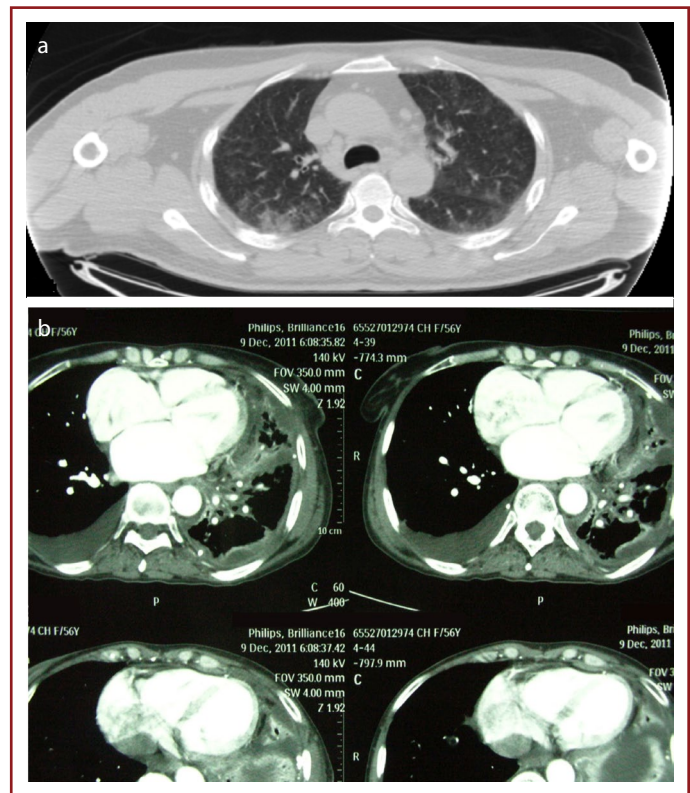


Figure 9. Patchy areas of ground-glass densities on bilateral upper lobes suggestive of early asbestosis in a 49-year-old man who worked in a car factory for 25 years (a) and enhancing pleural thickening along both pleural surfaces adjacent to the left lung on a contrast-enhanced axial image (W: 350, C: 50), suggestive of mesothelioma in a 61-year-old man (b).

Talcosis

Hydrated magnesium silicate is known as talc and is used in leather, plastics, rubber, ceramic, paper, cosmetics, and paint. Exposure to talc occurs by inhalation. HRCT findings include small centrilobular and subpleural nodules. Furthermore, conglomerate masses containing dens foci corresponding to talc deposition may be seen^[18,19].

Berylliosis

Berylliosis is a chronic granulomatous hypersensitivity reaction. The acute form is no longer encountered thanks to tight workplace regulation rules. Chronic form, however, may be seen following exposure in industries including ceramics, metal manufacturing, aerospace, and nuclear power. HRCT findings in chronic berylliosis resemble those seen in sarcoidosis and include peribronchovascular micronodules, smooth or nodular interlobular septal thickening, ground-glass opacity, and bronchial wall thickening. In 25% of cases, hilar or mediastinal lymphadenopathy may be seen^[20]. The pathological features of berylliosis are similar to sarcoidosis. The presence of chronic granulomatous inflammation on a lung biopsy and evidence of beryllium sensitivity on beryllium lymphocyte proliferation test are required to make the diagnosis.

Hard Metal Pneumoconiosis

Exposure to tungsten carbide, cobalt, and diamond dust produced in hard metal industry may cause a spectrum of diseases ranging from occupational asthma and obliterative bronchiolitis as early manifestations to giant cell interstitial pneumonia and interstitial fibrosis as late features.

HRCT findings include bilateral ground-glass opacities, micronodules, traction bronchiectasis, consolidation, and reticular opacities, seen preferentially in lower lobes^[21].

Siderosis

Oxyacetylene and electric arc welders, miners, workers processing iron ores, foundry workers, and silver polishers are at risk to develop siderosis. HRCT findings include widespread and ill-defined tiny centrilobular nodules, emphysema, and less commonly patchy ground-glass opacities without lobar preference. In some arc welders, interstitial lung fibrosis with septal thickening and with or without honeycombing has been reported, although fibrosis and functional impairment are not a typical feature of the disease^[22,23].

Aluminum Dust Pneumoconiosis

Aluminum production industries, aluminum arc welding, and manufacturing of aluminum-based grinding products

expose workers to aluminum dust which may cause pulmonary fibrosis, desquamative interstitial pneumonia, alveolar proteinosis, and granuloma formation. HRCT findings may include centrilobular nodules similar to silicosis, subpleural, or diffuse honeycombing similar to interstitial pulmonary fibrosis, predominantly in upper lobes (Fig. 10)^[24,25].

Hypersensitivity Pneumonitis (HP)

Exposure to some inorganic and organic antigens such as isocyanates (paint sprays), plastics, Mycobacterium avium complex, agricultural Aspergillus, and thermophilic Actinomyces may induce HP, also known as extrinsic allergic alveolitis. There are acute, subacute, and chronic forms of HP.

In acute form, HRCT findings are diffuse ground-glass and reticular opacities, ill-defined tiny nodules, mainly in lower lobes (Fig. 10).

In subacute HP, there are patchy or diffuse ground-glass opacities, ill-defined tiny centrilobular nodules, lobular air trapping, and less commonly thin-walled cysts on HRCT. Mild mediastinal lymphadenopathy is seen in 50% of cases^[26].

Chronic HP is associated with fibrosis in middle and lower lung zones which is reflected in a wide range of HRCT findings including reticulation, traction bronchiectasis, bronchiolectasis, and honeycombing^[26,27]. Findings of subacute HP may overlap with those of chronic HP in a patient.

Flavor Worker's Lung

Flavor worker's lung is an obliterative bronchiolitis induced by exposure to diacetyl (2,3-butanedione) which is used in butter flavoring of microwave popcorn. HRCT findings are air trapping on expiratory scan, bronchial wall thickening, and bronchiectasis^[28].

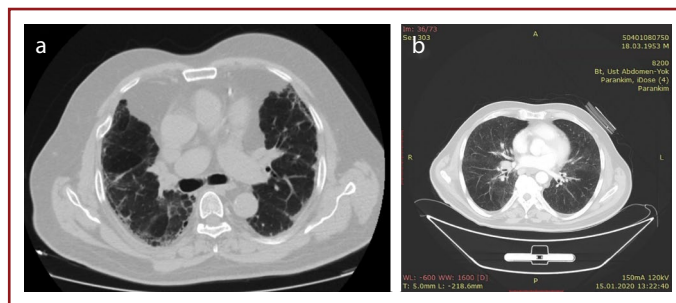


Figure 10. Aluminum dust pneumoconiosis in a 57-year-old man with an exposure history to aluminum for 20 years. Bilateral subpleural honeycombing with interlobular septal thickening and patchy ill-defined ground-glass areas is seen (a). Hypersensitivity pneumonitis in a 45-year-old man working in dye industry showing bilateral ill-defined patchy ground-glass densities on both lungs and air trapping in lower lobes (b).

Chemical Pneumonitis

Inhalation of some organic and inorganic chemicals including organophosphates, polyvinyl chloride, polymer fumes, smoke, ammonia, nitrous oxide, hydrogen sulfide, sulfur dioxide, and some metals (cadmium, vanadium, nickel, and mercury) may induce chemical pneumonitis. Associated HRCT findings include centrilobular or patchy ground-glass opacities, possibly reflecting pulmonary edema. Bronchiectasis, bronchiolectasis, mosaic perfusion, and air trapping may reflect bronchiolitis obliterans which can develop in weeks or months following exposure^[29].

Organic Toxic Dust Syndrome (OTDS)

Exposure to organic dust may cause a febrile condition called OTDS. In this condition, there is no evidence of HP. Humidifier fever seen in office and hospital workers, pulmonary mycotoxicosis, grain fever, cotton fever (byssinosis), and wood chip fever can be associated with OTDS.

HRCT findings of byssinosis have been reported to include ground-glass opacities and centrilobular nodules preferentially in lung bases^[30].

Conclusion

HRCT plays an important role in diagnosing diffuse lung diseases including pneumoconioses. In symptomatic patients and in patients with abnormal pulmonary function tests, the use of HRCT is indicated even when the chest X-ray is normal. HRCT enables to reach a specific diagnosis or at least to limit the differential diagnosis list.

The identification of ground-glass opacities or nodules on a HRCT scan indicates active disease which can be reversible while demonstration of fibrosis suggests irreversible disease. As such HRCT can be used to monitor disease activity. Finally, HRCT can also show the optimum site and type of a lung biopsy when necessary.

Pneumoconiosis comprises a wide spectrum of preventable occupational diseases. In some cases, the findings on HRCT can help make a specific diagnosis, while in other cases, a combination of clinical and radiological findings combined with the knowledge of exposure history is necessary for the diagnosis.

Peer-review: Externally peer-reviewed.

Financial Disclosure: The authors declared that this study received no financial support.

References

1. Marchiori E, Ferreira A, Müller NL. Silicoproteinosis: High-resolution CT and histologic findings. *J Thorac Imaging* 2001;16:127–9. [\[CrossRef\]](#)
2. Talini D, Paggiaro PL, Falaschi F, Battolla L, Carrara M, Petrozzino M, et al. Chest radiography and high resolution computed tomography in the evaluation of workers exposed to silica dust: Relation with functional findings. *Occup Environ Med* 1995;52:262–7. [\[CrossRef\]](#)
3. Chong S, Lee KS, Chung MJ, Han J, Kwon OJ, Kim TS. Pneumoconiosis: Comparison of imaging and pathologic findings. *Radiographics* 2006;26:59–77. [\[CrossRef\]](#)
4. Antao VC, Pinheiro GA, Terra-Filho M, Kavakama J, Müller NL. High-resolution CT in silicosis: Correlation with radiographic findings and functional impairment. *J Comput Assist Tomogr* 2005;29:350–6. [\[CrossRef\]](#)
5. Falaschi F, Battolla L, Paolicchi A, Paggiaro P, Talini D, Carrara M, et al. High-resolution computed tomography compared with the thoracic radiogram and respiratory function tests in assessing workers exposed to silica. *Radiol Med* 1995;89:424–9.
6. Ferreira AS, Moreira VB, Ricardo HM, Coutinho R, Gabetto JM, Marchiori E. Progressive massive fibrosis in silica-exposed workers. High-resolution computed tomography findings. *J Bras Pneumol* 2006;32:523–8. [\[CrossRef\]](#)
7. Bégin R, Ostiguy G, Fillion R, Colman N. Computed tomography scan in the early detection of silicosis. *Am Rev Respir Dis* 1991;144:697–705. [\[CrossRef\]](#)
8. Lamers RJ, Schins RP, Wouters EF, van Engelshoven JM. High-resolution computed tomography of the lungs in coal miners with a normal chest radiograph. *Exp Lung Res* 1994;20:411–9.
9. Remy-Jardin M, Degreef JM, Beuscart R, Voisin C, Remy J. Coal worker's pneumoconiosis: CT assessment in exposed workers and correlation with radiographic findings. *Radiology* 1990;177:363–71. [\[CrossRef\]](#)
10. Cox CW, Rose CS, Lynch DA. State of the art: Imaging of occupational lung disease. *Radiology* 2014;270:681–96. [\[CrossRef\]](#)
11. Katabami M, Dosaka-Akita H, Honma K, Saitoh Y, Kimura K, Uchida Y, et al. Pneumoconiosis-related lung cancers: Preferential occurrence from diffuse interstitial fibrosis-type pneumoconiosis. *Am J Respir Crit Care Med* 2000;162:295–300.
12. Cugell DW, Kamp DW. Asbestos and the pleura: A review. *Chest* 2004;125:1103–17. [\[CrossRef\]](#)
13. Norbet C, Joseph A, Rossi SS, Bhalla S, Gutierrez FR. Asbestos-related lung disease: A pictorial review. *Curr Probl Diagn Radiol* 2015;44:371–82. [\[CrossRef\]](#)
14. Akira M. High-resolution CT in the evaluation of occupational and environmental disease. *Radiol Clin North Am* 2002;40:43–59. [\[CrossRef\]](#)
15. Azour L, Billah T, Salvatore MM, Cham MD, Mendelson DS, Eber CD, et al. Causative factors, imaging findings, and CT course of round atelectasis. *Clin Imaging* 2018;50:250–7. [\[CrossRef\]](#)
16. Crummy F, Carl I, Cameron CH, Heaney LG. A possible case of pneumoconiosis in a limestone quarry worker. *Occup Med (Lond)* 2004;54:497–9. [\[CrossRef\]](#)
17. Satija B, Kumar S, Ojha UC, Gothi D. Spectrum of high-resolution computed tomography imaging in occupational lung disease. *Indian J Radiol Imaging* 2013;23:287–96. [\[CrossRef\]](#)
18. Verlynde G, Agneessens E, Dargent JL. Pulmonary talcosis due to daily inhalation of talc powder. *J Belg Soc Radiol*

- 2018;102:12. [\[CrossRef\]](#)
19. Marchiori E, Souza Júnior AS, Müller NL. Inhalational pulmonary talcosis: High-resolution CT findings in 3 patients. *J Thorac Imaging* 2004;19:41–4. [\[CrossRef\]](#)
 20. Sharma N, Patel J, Mohammed TL. Chronic beryllium disease: Computed tomographic findings. *J Comput Assist Tomogr* 2010;34:945–8. [\[CrossRef\]](#)
 21. Chiarchiaro J, Tomsic LR, Strock S, Veraldi KL, Nourai M, Selares J, et al. A case series describing common radiographic and pathologic patterns of hard metal pneumoconiosis. *Respir Med Case Rep* 2018;25:124–8. [\[CrossRef\]](#)
 22. Takahashi M, Nitta N, Kishimoto T, Ohtsuka Y, Honda S, Ashizawa K. Computed tomography findings of arc-welders' pneumoconiosis: Comparison with silicosis. *Eur J Radiol* 2018;107:98–104. [\[CrossRef\]](#)
 23. McCormick LM, Goddard M, Mahadeva R. Pulmonary fibrosis secondary to siderosis causing symptomatic respiratory disease: A case report. *J Med Case Rep* 2008;2:257. [\[CrossRef\]](#)
 24. Kraus T, Schaller KH, Angerer J, Letzel S. Aluminium dust-induced lung disease in the pyro-powder-producing industry: Detection by high-resolution computed tomography. *Int Arch Occup Environ Health* 2000;73:61–4. [\[CrossRef\]](#)
 25. Akira M. Uncommon pneumoconioses: CT and pathologic findings. *Radiology* 1995;197:403–9. [\[CrossRef\]](#)
 26. Silva CI, Churg A, Müller NL. Hypersensitivity pneumonitis: Spectrum of high-resolution CT and pathologic findings. *AJR Am J Roentgenol* 2007;188:334–44. [\[CrossRef\]](#)
 27. Sahin H, Kaproth-Joslin K, Hobbs SK. Hypersensitivity pneumonitis. *Semin Roentgenol* 2019;54:37–43. [\[CrossRef\]](#)
 28. Sauler M, Gulati M. Newly recognized occupational and environmental causes of chronic terminal airways and parenchymal lung disease. *Clin Chest Med* 2012;33:667–80. [\[CrossRef\]](#)
 29. Wright JL. Inhalational lung injury causing bronchiolitis. *Clin Chest Med* 1993;14:635–44.
 30. Gothi D, Joshi JM. An unusual interstitial lung disease. *Ann Thorac Med* 2012;7:162–4. [\[CrossRef\]](#)