

**Clinical Image***Open Access, Volume 2***Unilateral seminal vesicle agenesis in patient presenting with epididymo-orchitis****\*Corresponding Authors: Varsha Mary Khalkho**Meherbai Tata Memorial Hospital, Dhadkedi, Jamshedpur,  
Jharkhan 831001, India.

Tel: 0776-380-7876; Email: varshakhalkho@gmail.com

Received: Jun 07, 2021

Accepted: Jul 16, 2021

Published: Jul 21, 2021

Archived: www.jcimcr.org

Copyright: © Khalkho VM (2021).

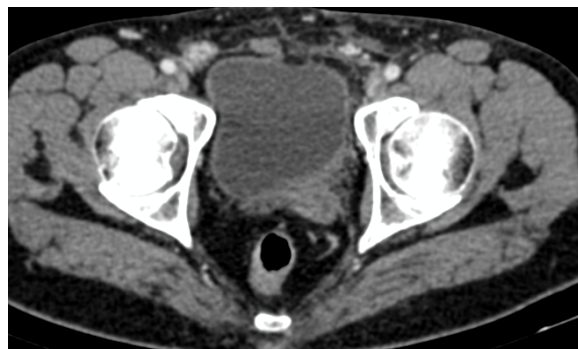
**Introduction**

Seminal vesicle anomalies are rare. It includes agenesis, hypoplasia, duplication, fusion and cyst. Agenesis of seminal vesicle is usually associated with anomalies of ipsilateral kidney and can be the cause of infertility in male [1]. We report a case with seminal vesicle agenesis with ipsilateral renal hypoplasia.

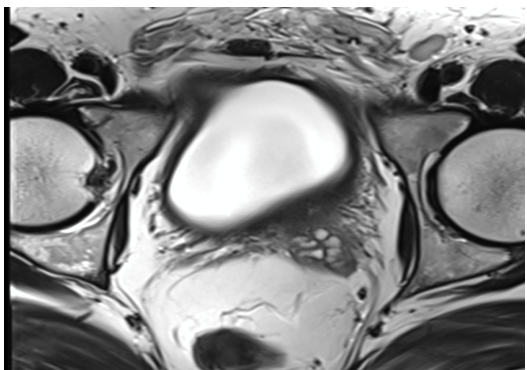
**Description**

A 35 years old male patient presented with pain in left inguinoscotal region for 2 days radiating to the left lower abdomen. USG abdomen was done which showed enlarged left kidney with moderated hydronephrosis and with proximal hydroureter. Right kidney was hypoplastic. USG scrotum was done which showed features of left epididymo-orchitis.

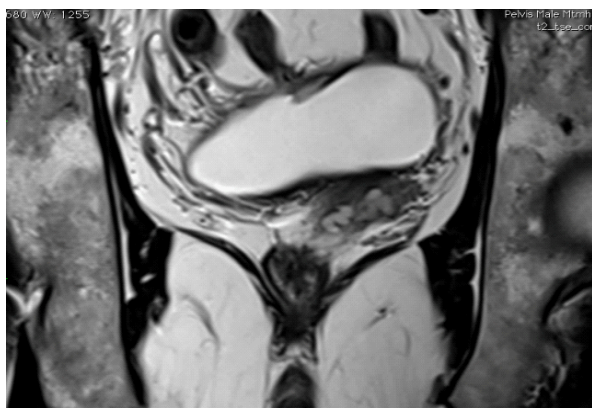
CT scan showed the same findings without evidence of calculus in left ureter. Incidentally it was found that right seminal vesicle is absent and left seminal vesicle was bulky. Prostate gland was normal in size. There was no history of infertility in our patient. Ureteroscopy showed stricture in left ureter.



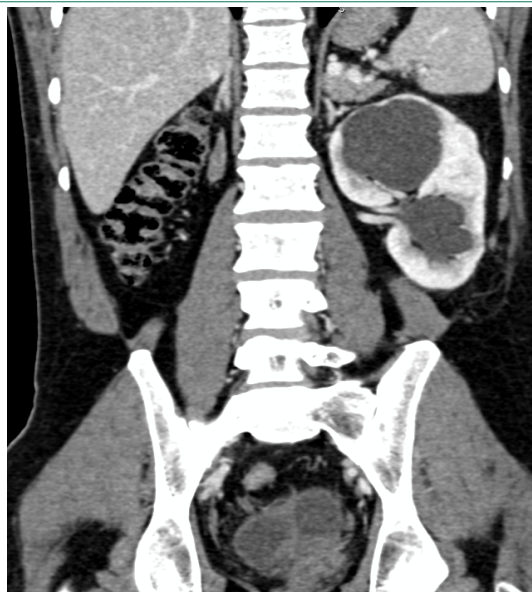
**Figure 1:** Axial CT image at the level of urinary bladder showing absent right and bulky left seminal vesicle.



**Figure 2:** Axial MRI image at the level of urinary bladder showing absence of right seminal vesicle and dilated ducts in left seminal vesicle.



**Figure 3:** Coronal MRI image at the level of urinary bladder showing absence of right seminal vesicle and dilated ducts in left seminal vesicle.



**Figure 4:** Coronal Contrast CT of abdomen showing hypoplastic right kidney and bulky left kidney with hydronephrosis.

#### Conclusion

Unilateral seminal vesicle agenesis in our patient was not associated with infertility.

#### Reference

1. Ocal O, Karaosmanoglu AD, Karcaaltıncaba M, Akata D, Ozmen M. Imaging findings of congenital anomalies of seminal vesicles. Polish J Radiol. 2019; 84: e25.