

“REFLEXES AND SIGNS”

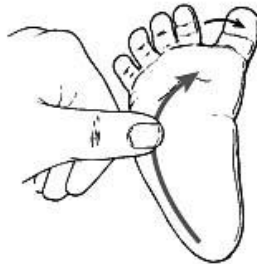A. List of Reflexes from Dorland’s Medical Dictionary

In neurological examination the term “reflex” refers to specific motor responses elicited by specific stimuli (e.g., the asymmetric tonic neck reflex). In ophthalmic examination the term refers to incident light retroreflected from various ocular optical surfaces (i.e., retina, cornea, lens).

reflex (re-flex) (re'fleks) [L. *reflexus*, past participle of *reflectere* to bend he **involuntary** activity. See *reflex arc* and *reflex action*. 3. a reflection or a reflected image of an object.

1. **abdominal reflexes**, contractions of the abdominal muscles on scratching of the abdominal wall.
2. **abdominocardiac reflex**, any reflex in the heart produced by stimulating the abdominal sympathetic nerves. See also *Livierato's sign*, under *sign*.
3. **Abrams' heart reflex**, contraction of the myocardium, with reduction in the area of cardiac dullness, which results when the skin of the precordial region is irritated. It is observed with the fluoroscope.
4. **accommodation reflex**, the coordinated changes that occur when the eye adapts itself for near vision; they are constriction of the pupil, convergence of the eyes, and increased convexity of the lens.
5. **Achilles tendon reflex**, *triceps surae r.*
6. **acoustic reflex**, contraction of the stapedius muscle in response to intense sound. Called also *cochleostapedial r.* and *stapedial r.*
7. **acquired reflex**, *conditioned response*.
8. **adductor reflex of foot**, *Hirschberg's sign*.
9. **adductor reflex of thigh**, on tapping the tendon of the adductor magnus with the thigh in abduction, contraction of the adductors results.
10. **allied reflexes**, reflexes in which two afferent stimuli use the same common pathway or produce effects on two synergistic muscles.
11. **anal reflex**, contraction of the anal sphincter on scratching or other irritation of the skin of the anus.
12. **ankle reflex**, *triceps surae r.*
13. **antagonistic reflexes**, reflex movements occurring not in the muscle which has been stretched but in its antagonist.
14. **anticus reflex**, *Piotrowski's sign*.
15. **antigravity reflexes**, reflexes that keep the antigravity muscles in extension to hold the body upright.
16. **Aschner's reflex**, *oculocardiac r.*
17. **atriopressor reflex**, rise in arterial blood pressure (vasoconstriction) attributed to a change of pressure in the right atrium and great veins.
18. **attention reflex of pupil**, alteration of size in the pupil when the attention is suddenly fixed; called also *Piltz's r.*
19. **attitudinal reflexes**, those reflexes having to do with the position of the body, primarily controlled by input from receptors in the utriculus; called also *statotonic r's*.
20. **audito-oculogyric reflex**, a turning of both eyes in the direction of a sudden sound.
21. **auditory reflex**, any reflex caused by stimulation of the auditory (vestibulocochlear) nerve, especially momentary closure of both eyes produced by a sudden sound.
22. **auricle reflex**, involuntary movement of the auricle of the ear produced by auditory stimuli (more pronounced in some other animals than in humans).
23. **auriculocervical nerve reflex**, *Snellen's r.*
24. **auriculopalpebral reflex**, *Kisch's r.*

25. **autonomic reflex**, a response of smooth muscle, glands, and conducting tissue of the heart, which alters the functional state of the innervated organ.
26. **axon reflex**, a reflex resulting from a stimulus applied to one branch of a nerve which sets up an impulse that moves centrally to the point of division of the nerve where it is reflected down the other branch to the effector organ.
27. **Babinski's reflex**, dorsiflexion of the big toe on stimulating the sole of the foot; normal in infants but in others a sign of a lesion in the central nervous system, particularly in the pyramidal tract. Called also Babinski's phenomenon or sign and toe phenomenon or sign.



28. **Babkin reflex**, pressure by the examiner's thumbs on the palms of both hands of the infant results in opening of the infant's mouth; it is elicited in many newborn infants, normal and abnormal, except when lethargic or comatose.
29. **Bainbridge reflex**, rise in pressure in, or increased distention of, the large somatic veins or the right atrium, results in acceleration of the heart beat.
30. **bar reflex**, a pathological reflex in which movement of one leg is followed by similar movements of the other leg when the patient is recumbent; indicative of a lesion, often a tumor, in the prefrontal area.
31. **Barkman's reflex**, contraction of the rectus abdominis muscle on the same side after stimulation of the skin just below one of the nipples.
32. **baroreceptor reflex**, the reflex responses to stimulation of baroreceptors of the carotid sinus and aortic arch, regulating blood pressure by controlling heart rate, strength of heart contractions, and diameter of blood vessels.
33. **basal joint reflex**, finger-thumb r.
34. **Bechterew's reflex**, Bekhterev's r.
35. **behavior reflex**, conditioned response.
36. **Bekhterev's reflex**, 1. Bekhterev's deep r. 2. hypogastric r. 3. nasal r. 4. paradoxical pupillary r.
37. **Bekhterev's deep reflex**, with corticospinal tract lesions, if the toes and foot are passively flexed in a plantar direction and then released, they will flex in a dorsal direction and the knees and hip will also flex.
38. **Bekhterev-Mendel reflex**, Mendel-Bekhterev r.
39. **Bezold reflex**, **Bezold-Jarisch reflex**, a cardiovascular reflex occurring upon stimulation of chemoreceptors, primarily in the left ventricle, by certain antihypertensive alkaloids and similar substances; afferent vagal fibers carry the impulses to the medulla oblongata, after which impulses carried back by efferent vagal fibers cause reflex bradycardia and hypotension.
40. **biceps reflex**, contractions of the biceps muscle of the arm when its tendon is tapped; this reflex is normal but when greatly increased it indicates the same disease as increased knee jerk.

41. **bladder reflex**, the reflex contracting and emptying of the bladder in response to filling, the first step in the micturition reflex; it can be voluntarily inhibited by impulses from the brain in patients with normal neurological function.
42. **blink reflex**, 1. corneal r. (def. 1). 2. blink responses considered together.
43. **brachioradialis reflex**, tapping on the lower end of the radius produces flexion of the forearm.
44. **Brain's reflex**, an extension of the hemiplegic flexed arm when the patient assumes the quadrupedal position; called also quadrupedal extensor r.
45. **brain stem reflexes**, reflexes regulated at the level of the brain stem, such as pupillary, pharyngeal, and cough reflexes and the control of respiration. Their prolonged absence is one criterion of brain death.
46. **bregmocardiac reflex**, pressure upon the bregmatic fontanelle slows the action of the heart.
47. **Brissaud's reflex**, contraction of the tensor muscle of fascia lata on tickling the sole.
48. **Brudzinski's reflex**, see under sign.
49. **bulbocavernosus reflex**, bulbospongiosus r.
50. **bulbomimic reflex**, in coma from apoplexy, pressure on the eyeball causes contraction of the facial muscles on the side opposite to the lesion; in coma from toxic causes, the reflex occurs on both sides. Called also facial r. and Mondonesi's r.
51. **bulbospongiosus reflex**, contraction of the bulbospongiosus muscle in response to a tap on the dorsum of the penis; called also penile or virile r.
52. **carotid sinus reflex**, pressure on, or in, the carotid artery at the level of its bifurcation causing reflex slowing of the heart rate; this reflex originates in the wall of the sinus of the internal carotid artery. See carotid sinus syndrome, under syndrome.
53. **cat's eye reflex**, see under amaurosis.
54. **cerebral cortex reflex**, Haab's r.
55. **Chaddock's reflex**, stimulation below the external malleolus produces extension of the great toe; it occurs in lesions of the pyramidal tract.
56. **chain reflex**, a series of reflexes, each serving as a stimulus to the next one, representing a complete activity.
57. **chin reflex**, jaw r.
58. **choked reflex**, in fluoroscopy, absence of movement of the retinal illumination on reaching the point of reversal.
59. **ciliary reflex**, the movement of the pupil in accommodation.
60. **cilio-spinal reflex**, painful stimulation of the skin of the neck, face, or another body part dilates the ipsilateral pupil. Called also Parrot's sign.
61. **clasp-knife reflex**, see under rigidity.
62. **closed loop reflex**, a reflex, such as a stretch reflex, in which the stimulus (such as muscle stretch) decreases when it receives feedback from the response mechanism.
63. **cochleo-orbicular reflex**, **cochleopalpebral reflex**, contraction of the orbicularis palpebrarum muscle when a sharp, sudden noise is made close to the ear; does not occur in total deafness from labyrinthine disease.
64. **cochleopupillary reflex**, a reaction of the iris (contraction of the pupil followed by dilatation) to a loud sound.
65. **cochleostapedial reflex**, acoustic r.
66. **cold pressor reflex**, immersion of the hand in ice water for several minutes causes vasoconstriction, tachycardia, and transient hypertension due to activation of the sympathetic nervous system.
67. **concealed reflex**, one elicited by a stimulus but concealed by a more dominant reflex elicited by the same stimulus.
68. **conditioned reflex**, see under response.
69. **conjunctival reflex**, closure of the eyelid when the conjunctiva is touched.
70. **consensual reflex**, crossed r.
71. **consensual light reflex**, stimulation of one eye by light produces a reflex response in the opposite pupil.
72. **convergency reflex**, convergence of the visual axes with fixation on a near point.

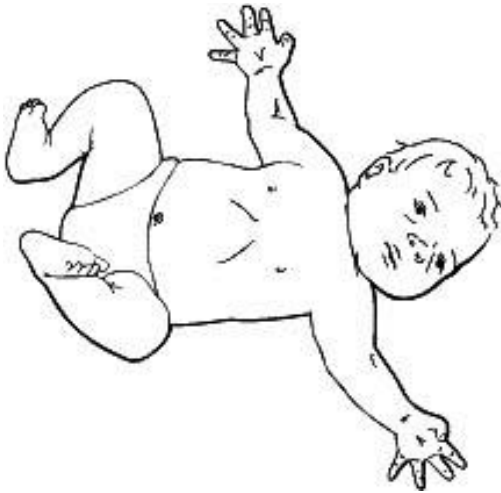73. **convulsive reflex**, one in which several muscles contract convulsively without coordination.
74. **coordinated reflex**, one in which several muscles react so as to produce an orderly and useful movement.
75. **corneal reflex**, 1. irritation of the cornea results in reflex closure of the lids; called also *blink r.*, *eyelid closure r.*, and *lid r.* 2. reflection of light from the cornea.
76. **corneomandibular reflex**, movement of the lower jaw toward the side opposite the eye whose cornea is lightly touched, the mouth being open.
77. **corneomental reflex**, unilateral wrinkling of the muscles of the chin when pressure is applied to the cornea.
78. **corneopterygoid reflex**, *corneomandibular r.*
79. **coronary reflex**, the reflex that controls the caliber of the coronary blood vessels.
80. **cough reflex**, the sequence of events initiated by the sensitivity of the lining of the airways and mediated by the medulla as a consequence of impulses transmitted by the vagus nerve, resulting in coughing, i.e., the clearing of the passageways of foreign matter.
81. **cranial reflex**, any reflex whose paths are connected directly with the brain.
82. **cremasteric reflex**, stimulation of the skin on the front and inner side of the thigh retracts the testis on the same side. The presence of this reflex indicates integrity of the first lumbar nerve segment of the spinal cord or its root; absence indicates damage of the first lumbar nerve segment or its root or lesion of the corticospinal tract. Cf. *Geigel's r.* and *hypogastric r.*
83. **crossed reflex**, a response on the side of the body opposite to the side being stimulated, such as the *consensual light reflex* or the *crossed adductor reflex*.
84. **crossed adductor reflex**, adduction of one leg when an attempt is made to elicit the quadriceps jerk on the opposite side.
85. **crossed extension reflex**, reflex extension of a limb or body part in response to a flexion reflex in the contralateral part.
86. **cuboidodigital reflex**, *Mendel-Bekhterev r.*
87. **cutaneous pupillary reflex**, *cilio-spinal r.*
88. **dartos reflex**, vermicular contractions of the dartos muscle when a cold or stroking stimulus is applied to the perineum; called also *scrotal r.*
89. **dazzle reflex**, a reflex by which a strong light shining on the eyes causes an immediate closing of the eyelids which lasts as long as the stimulus.
90. **deep reflex**, *tendon r.*
91. **defecation reflex**, *rectal r.*
92. **delayed reflex**, a reflex which occurs some time after the stimulus provoking it has been received.
93. **depressor reflex**, a response to stimulation resulting in decreased motor activity.
94. **digital reflex**, *Hoffmann's sign* (def. 2).
95. **direct light reflex**, when a ray of light is thrown upon the retina through the pupil there is immediate contraction of the sphincter iridis, reducing the size of the pupillary aperture.
96. **diving reflex**, a reflex involving cardiovascular and metabolic adaptations to conserve oxygen occurring in animals during diving into water; observed in reptiles, birds, and mammals, including man.
97. **doll's eye reflex**, when the head is rotated laterally, the eyes deviate synergistically in the opposite direction; assessed in premature infants and the comatose to test for integrity of function of the oculomotor nerves and brain stem. Called also *Cantelli's sign* and *doll's eye sign*.
98. **dorsal reflex**, contraction of the back muscles in response to stimulation of the skin over the erector spinae muscle; called also *erector spinae r.*
99. **dorsocuboidal reflex**, *Mendel-Bekhterev r.*
100. **elbow reflex**, *triceps r.*
101. **embrace reflex**, *Moro's r.*
102. **emergency light reflex**, excessive stimulation of the retina by light produces contraction of the pupils, closure of the eyelids, and lowering of the eyebrows.

103. **enterogastric reflex**, inhibition of gastric motility when irritants enter the duodenum.
104. **epigastric reflex**, contraction of the abdominal muscles caused by stimulating the skin of the epigastrium or over the fifth and sixth intercostal spaces near the axilla.
105. **Erben's reflex**, slowing down of the pulse upon bending the head and trunk strongly forward, due to vagal excitability, called also *Erben's phenomenon* or *sign*.
106. **erector spinae reflex**, dorsal r.
107. **Escherich's reflex**, see under *sign*.
108. **esophagosalivary reflex**, excessive salivation due to irritation of the esophagus, as by a tumor or gastroesophageal reflux; called also *Roger's r.*
109. **external auditory meatus reflex**, Kisch's r.
110. **eyeball compression reflex**, **eyeball-heart reflex**, oculocardiac r.
111. **eyelid closure reflex**, 1. corneal r. (def. 1). 2. conjunctival r.
112. **facial reflex**, bulbomimic r.
113. **faucial reflex**, reflex vomiting caused by irritation of the fauces, cf. *pharyngeal r.*
114. **femoral reflex**, Remak's r.
115. **finger-thumb reflex**, passive flexion of the metacarpophalangeal joint of one of the fingers causes flexion of the basal joint and extension of the terminal joint of the thumb; called also *basal joint r.* and *Mayer's r.*
116. **flexion reflex**, a reflex that results in movement of a limb or part toward the body, often in response to a painful stimulus; it may cause a crossed extension reflex in the contralateral body part.
117. **flexor reflex, paradoxical**, dorsiflexion of the great toe or of all the toes when the deep muscles of the calf are pressed upon, seen in cases of pyramidal tract disease; called also *Gordon's r.*
118. **fontanelle reflex**, Grünfelder's r.
119. **foveal reflex**, the dotlike reflex of light caused by the foveola retinae, seen during ophthalmoscopy.
120. **front-tap reflex**, a tap on the skin muscles of the extended leg contracts the gastrocnemius.
121. **fundus reflex**, red r.
122. **fusion reflex**, the reflex which tends to merge the images on the two retinas into a single impression.
123. **gag reflex**, pharyngeal r.
124. **gastrocolic reflex**, an increase in intestinal and colonic peristaltic activity following entrance of food into the empty stomach.
125. **gastroileal reflex**, an increase in ileal motility and opening of the ileocecal valve when food enters the empty stomach.
126. **gastropancreatic reflex**, an increase in pancreatic secretion induced by distention of the corpus of the stomach; it is mediated by the vagus nerve.
127. **Gault's cochleopalpebral reflex**, cochleopalpebral r.
128. **Geigel's reflex**, a reflex in the female corresponding to the cremasteric reflex in the male; i.e., on stroking of the inner anterior aspect of the upper thigh there is a contraction of the muscular fibers at the upper edge of Poupart's ligament; cf. *hypogastric r.* Called also *inguinal r.*
129. **Gifford's reflex**, **Gifford-Galassi reflex**, orbicularis pupillary r.
130. **gluteal reflex**, a stroke over the skin of the buttock contracts the glutei muscles.
131. **Gordon's reflex**, flexor r., paradoxical.
132. **grasp reflex**, **grasping reflex**, a reflex consisting of a grasping motion of the fingers or of the toes in response to stimulation; normal in infancy, but in later life indicative of a frontal lobe lesion.
133. **Grünfelder's reflex**, dorsal flexion of the great toe with a fanwise spreading of the other toes elicited by continued pressure at the corner of the posterior lateral fontanelle; normal in infants but a sign of middle ear disease in older children.
134. **gustolacrimal reflex**, syndrome of crocodile tears.

135. **H-reflex**, a monosynaptic reflex elicited by stimulating a nerve, particularly the tibial nerve, with an electric shock. See also H wave.
136. **Haab's reflex**, bilateral pupillary contraction when the patient sits in a darkened room, and without accommodation or convergence directs attention to a bright object already within the field of vision. Called also cerebral cortex r.
137. **heart reflex**, Abrams' heart r.
138. **heel-tap reflex**, a reflex occurring in disease of the pyramidal tract and consisting of fanning and plantar flexion of the toes produced by tapping the patient's heel.
139. **hepatjugular reflex**, incorrect term for hepatjugular reflux.
140. **Hering-Breuer reflex**, the nervous mechanism that tends to limit respiratory excursions. Stimuli from the sensory endings in the lungs and perhaps in other parts passing up the vagi tend to limit both inspiration and expiration in ordinary breathing.
141. **Hirschberg's reflex**, see under sign.
142. **Hoffmann's reflex**, Hoffmann's sign (def. 2).
143. **Hughes' reflex**, virile r. (def. 2).
144. **hypochoondrial reflex**, sudden inspiration caused by quick pressure beneath the lower border of the ribs.
145. **hypogastric reflex**, contraction of the muscles of the lower abdomen on stroking the skin of the inner surface of the thigh; cf. cremasteric r. and Geigel's r. Called also Bekhterev's r.
146. **ileo gastric reflex**, inhibition of gastric motility by distention of the ileum.
147. **inborn reflex**, unconditioned response.
148. **indirect reflex**, crossed r.
149. **infraspinatus reflex**, tapping a spot over the shoulder blade on a line bisecting the angle formed by the spine of the bone and its inner border causes outward rotation of the arm and straightening of the elbow.
150. **inguinal reflex**, Geigel's r.
151. **interscapular reflex**, a stimulus applied between the scapulae contracts the scapular muscles; called also scapular r.
152. **intestinointestinal reflex**, when a part of the intestine becomes overdistended or its mucosa becomes excessively irritated, activity in other parts of the intestine is inhibited as long as the distention persists.
153. **inverted radial reflex**, a flexion of the fingers without movement of the forearm, produced by tapping the lower end of the radius; it indicates disease of the fifth cervical segment of the spinal cord associated with damage of the pyramidal tract below that level.
154. **iris contraction reflex**, pupillary r.
155. **ischemic reflex**, the elevation of arterial pressure in response to cerebral ischemia.
156. **jaw reflex**, **jaw jerk reflex**, closure of the mouth caused by a downward blow on the lower jaw while it hangs passively open. It is seen only rarely in health, but is very noticeable in lesions of the corticospinal tract. Called also jaw jerk, chin r., and mandibular r.
157. **Joffroy's reflex**, twitching of the gluteal muscles on pressure against the buttocks in spastic paralysis.
158. **Juster reflex**, extension of the fingers instead of flexion on stimulation of the palm.
159. **juvenile reflex**, a glistening white reflection from the smooth surface of the retina in young people.
160. **Kehrer's reflex**, **Kisch's reflex**, closure of the eye as a result of tactile or thermal stimulation of the deepest part of the external auditory meatus and tympanum.
161. **knee jerk reflex**, patellar r.
162. **Kocher's reflex**, contraction of the abdominal muscle on compression of the testicle; called also testicular compression r.
163. **labyrinthine reflexes**, vestibular r's.

164. **lacrimal reflex**, secretion of tears elicited by touching or otherwise irritating the conjunctiva or the cornea.
165. **Landau reflex**, when an infant is held in the prone position, the entire body forms a convex upward arc; gentle pressure on the head or gravity flexes the neck and hip, reversing the arc.
166. **laryngeal reflex**, a type of cough reflex in which irritation of the fauces and larynx causes cough.
167. **laughter reflex**, laughter brought on by tickling.
168. **let-down reflex**, the ejection or release of milk from the alveoli of the breast into the ducts, caused by a combination of neurogenic and hormonal reflexes involving the hormone oxytocin and, to a lesser extent, vasopressin; called also *milk ejection r.* and *milk let-down r.*
169. **lid reflex**, *corneal r.* (def. 1).
170. **Liddell and Sherrington reflex**, *stretch r.*
171. **light reflex**, 1. *cone of light*. 2. a circular spot of light seen reflected from the retina with the retinoscopic mirror. 3. *pupillary r.* (def. 1).
172. **lip reflex**, a reflex movement of the lips of sleeping babies which occurs on tapping near the angle of the mouth.
173. **local reflex**, a reflex whose arc does not pass through the spinal cord, such as occurs in the enteric nervous system. See also *intramural plexus*, under *plexus*.
174. **Lovén reflex**, general vasodilatation of an organ when its afferent nerve is stimulated; this secures a maximal supply of blood to the organ, together with a general rise of blood pressure.
175. **lumbar reflex**, *dorsal r.*
176. **Lust's reflex**, see under *phenomenon*.
177. **McCarthy's reflex**, *supraorbital r.*
178. **McCormac's reflex**, *patelloadductor r.*
179. **McDowall reflex**, a decrease in systemic blood pressure following vagotomy, due to abolishment of the afferent impulses from the atria, which normally induce vasoconstriction.
180. **macular reflex**, in ophthalmoscopy, an annular reflection of light surrounding the macula retina.
181. **Magnus and de Kleijn neck reflexes**, extension of both ipsilateral limbs, or one, or part of a limb, and increase of tonus on the side to which the chin is turned when the head is rotated to the side, and flexion with loss of tonus on the side to which the occiput points; a sign of *decerebrate rigidity* except in infants. See also *tonic neck r.*
182. **mandibular reflex**, *jaw r.*
183. **Marinesco-Radovici reflex**, *palm-chin r.*
184. **mass reflex**, in severe injury of the spinal cord, stimulation below the level of the lesion produces flexion reflexes of the lower extremity, evacuation of the bowels and bladder, and sweating of the skin below the level of the lesion. Called also *Riddoch's mass r.*
185. **Mayer's reflex**, *finger-thumb r.*
186. **Mendel's reflex**, **Mendel's dorsal reflex of foot**, *Mendel-Bekhterev r.*
187. **Mendel-Bekhterev reflex**, percussion of the dorsum of the foot normally causes dorsal flexion of the second to fifth toes; in certain organic nervous conditions it causes plantar flexion of the toes. Called also *Bekhterev-Mendel r.*, *cuboidodigital r.*, *dorsocuboidal r.*, *Mendel's r.*, *Mendel's dorsal r. of foot*, and *tarsophalangeal r.*
188. **micturition reflex**, any of the reflexes necessary for effortless evacuation of urine and subconscious maintenance of continence: vesical contraction following distention of the bladder, vesical contraction evoked by urethral flow, vesical contraction evoked by proximal urethral distention, relaxation of the urethra resulting from running liquid in the urethra, distention of the bladder resulting in relaxation of the external sphincter, relaxation of the proximal urethral smooth muscle by distention of the bladder, and vesical contraction related to running liquid through the urethra.
189. **milk ejection reflex**, **milk let-down reflex**, *let-down r.*

190. **Mondonesi's reflex**, bulbomimic r.
191. **Morley's peritoneocutaneous reflex**, when any of the cerebrospinal nerve endings in the peritoneum or subperitoneal tissues are irritated, pain will be referred to the corresponding segmental skin area.
192. **Moro's reflex**, **Moro embrace reflex**, flexion of an infant's thighs and knees, fanning and then clenching of the fingers, with arms first thrown outward then brought together as if in an embrace, produced by a sudden stimulus such as the table being struck next to the child, or by sudden extension of the neck when the head is allowed to fall backward or the child is pulled up by both hands from a lying position and then let go. It is seen normally in infants up to 3 to 4 months of age. Called also embrace r. and startle r.



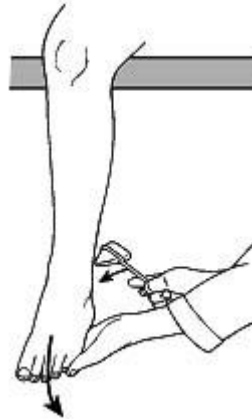
193. **myenteric reflex**, peristaltic r.
194. **myopic reflex**, Weiss' r.
195. **myotatic reflex**, stretch r.
196. **nasal reflex**, tickling of the mucosa of the nasal cavity produces contraction of the facial muscles on the same side of the face; called also Bekhterev's r.
197. **nasolabial reflex**, sudden retroversion of the head, stretching of the back, retroversion of the arms at the shoulder, extension and pronation of the forearms, and extension and adduction of the legs, elicited by a slight vertical sweeping motion touching the tip of the nose; it frequently occurs in healthy infants, and disappears around the fifth month of age.
198. **nasomental reflex**, contraction of the mentalis muscle on tapping the side of the nose with a percussion hammer.
199. **neck reflexes**, reflex adjustments in trunk posture and limb position caused by stimulation of proprioceptors in the neck joints and muscles when the head is turned; this tends to maintain a constant orientation between the head and the body.
200. **neck righting reflex**, rotation of the trunk in the direction in which the head of the supine infant is turned; this reflex is absent or decreased in infants with spasticity.
201. **nociceptive reflexes**, reflexes initiated by painful stimuli.
202. **oblique reflex**, stimulation of the skin below Poupart's ligament contracts a part of the external oblique muscle.
203. **oculoauricular reflex**, slight flattening of the pinna of one ear against the skull when the eyes deviate strongly to the opposite side. Absence on one side indicates facial nerve palsy at or proximal to the stylomastoid foramen.
204. **oculocardiac reflex**, a slowing of the rhythm of the heart following compression of the eyes. A slowing of from 5 to 13 beats per minute is normal; one of from 13 to 50 or more is exaggerated; one of from 1 to 5 is diminished. If ocular compression produces

- acceleration of the heart, the reflex is called *inverted*. Called also Aschner's r. or phenomenon.
205. **oculocephalogyric reflex**, the reflex by which the movements of the eye, the head, and the body are directed in the interest of visual attention.
206. **oculopharyngeal reflex**, rapid deglutition together with spontaneous closing of the eyes in response to irritation of the conjunctiva.
207. **oculopupillary reflex**, stimulation of the cornea or of the eyelid results in dilation and then contraction of both pupils; called also oculosensory r. and trigeminus r.
208. **oculosensory reflex**, oculopupillary r.
209. **oculovagal reflex**, pressure on the eyeball induces ectopic atrioventricular beats or rhythm.
210. **open loop reflex**, a reflex, such as a flexion reflex, in which the stimulus causes activity that it does not further control and that does not give it feedback.
211. **Oppenheim's reflex**, dorsiflexion of the big toe on stroking downward along the medial side of the tibia, seen in pyramidal tract disease.
212. **opticrofacial winking reflex**, closure of the lids when an object is brought suddenly into the field of vision.
213. **orbicularis reflex**, orbicularis pupillary r.
214. **orbicularis oculi reflex**, normal contraction of the orbicularis oculi muscle, with resultant closing of the eye, on percussion at the outer aspect of the supraorbital ridge, over the glabella, or around the margin of the orbit.
215. **orbicularis pupillary reflex**, unilateral contraction of the pupil, followed by dilatation after closure or attempted closure of eyelids that are forcibly held apart. Called also Galassi's pupillary, orbicularis, or Westphal-Piltz phenomenon and Gifford's, Gifford-Galassi, or Westphal's pupillary r.
216. **orienting reflex**, the response of an animal to an unexpected or novel stimulus or alteration of a stimulus; it involves adjustments of head, body, or sensory organs to pay close attention to the stimulus. In higher vertebrates including humans it is mediated at the brain stem level. Called also orienting response.
217. **palatal reflex, palatine reflex**, stimulation of the palate causes swallowing; called also swallowing r.
218. **palmar reflex**, flexion of the fingers in response to scratching of the palm.
219. **palm-chin reflex, palmomentary reflex**, twitching of the chin produced by stimulating (scratching) the palm; called also Marinesco-Radovici r. and Radovici's sign.
220. **paradoxical pupillary reflex**, 1. reversed pupillary r. 2. dilatation of the pupil on exposure to light; sometimes seen in conditions such as tabes dorsalis. Called also Bekhterev's r. and paradoxical pupillary phenomenon.
221. **patellar reflex**, contraction of the quadriceps and extension of the leg when the patellar ligament is tapped; called also knee jerk, quadriceps jerk, knee jerk r., and quadriceps r.
222. **patelloadductor reflex**, crossed adduction of the thigh produced by tapping the quadriceps tendon as in the patellar reflex; called also McCormac's r.
223. **pathologic reflex**, one which is not normal, but is the result of a pathologic condition, and may serve as a sign of disease.
224. **pectoral reflex**, the subject's arm is placed half way between adduction and abduction and the examiner's finger in the muscle tendon near the humerus: a sharp blow of the finger elicits adduction and slight internal rotation.
225. **penile reflex, penis reflex**, bulbospongiosus r.
226. **perianal reflex**, anal r.
227. **periosteal reflex**, contraction of a muscle after tapping of a nearby bone that lies just below the surface of the skin; see radial r., tibioadductor r., and ulnar r.
228. **peristaltic reflex**, when a portion of the intestine is irritated or distended, the area just proximal contracts and the area just distal relaxes.
229. **peritoneointestinal reflex**, inhibition of motility of the stomach and intestine resulting from retroperitoneal irritation or hemorrhage.

230. **pharyngeal reflex**, contraction of the constrictor muscle of the pharynx elicited by touching the back of the pharynx; called also gag r.
231. **phasic reflex**, coordinated r.
232. **Philippson's reflex**, excitation of the knee extensor in one leg induced by inhibition in the knee extensor of the other leg.
233. **pilomotor reflex**, the production of goose flesh on stroking the skin; trichographism.
234. **Piltz's reflex**, attention r. of pupil.
235. **placing reflex**, flexion followed by extension of the leg when the infant is held erect and the dorsum of the foot is drawn along the under edge of a table top; it is obtainable in the normal infant up to the age of six weeks.
236. **plantar reflex**, irritation of the sole contracts the toes; cf. Babinski's r.
237. **platysmal reflex**, contraction of the pupil upon nipping of the platysma.
238. **pollicomental reflex**, palm-chin r.
239. **postural reflex**, a reflex which consists of some assumption of posture.
240. **pressor reflex**, a reflex that increases the blood pressure.
241. **Preyer's reflex**, auricle r.
242. **proprioceptive reflex**, a reflex that is initiated by a stimulus to a proprioceptor.
243. **psychic reflex**, a reflex aroused by a stored-up impression of memory, such as the secretion of saliva at the sight or thought of good-tasting food.
244. **psychocardiac reflex**, increase in the pulse rate on recalling an individual emotional experience.
245. **psychogalvanic reflex**, galvanic skin response.
246. **pulmonocoronary reflex**, reflex vasoconstriction of the coronary arteries, mediated by the vagus nerves, such as with a pulmonary embolism.
247. **pupillary reflex**, 1. contraction of the pupil on exposure of the retina to light. Called also light r. 2. any reflex involving the iris, changing the size of the pupil in response to a stimulus, e.g., change in illumination, change in point of fixation, sudden loud noise, or emotional stimulus.
248. **Puusepp's reflex**, abduction of the little toe on stimulating the posterior external part of the sole of the foot; indicative of lesions of the extrapyramidal and pyramidal tracts.
249. **quadriceps reflex**, patellar r.
250. **quadrupedal extensor reflex**, Brain's r.
251. **radial reflex**, flexion of the forearm, following tapping on the lower end of the radius; when the fingers flex as well, it indicates hyperreflexia.
252. **rectal reflex**, the process by which the accumulation of feces in the rectum excites defecation; called also defecation r.
253. **rectoanal inhibitory reflex**, relaxation of the internal anal sphincter in response to increased pressure in the rectum; it can be tested by inflating a balloon in the lumen. It is absent in cases of congenital megacolon.
254. **red reflex**, a luminous red appearance seen upon the retina during retinoscopy; called also fundus r.
255. **regional reflex**, segmental r.
256. **Remak's reflex**, plantar flexion of the first three toes and sometimes of the foot, with extension of the knee on stroking of the upper anterior surface of the thigh, a sign of a spinal cord lesion; called also femoral r.
257. **renointestinal reflex**, inhibition of motility of the intestine resulting from renal irritation.
258. **renorenal reflex**, a reflex pain or anuria in a sound kidney in cases in which the other kidney is diseased.
259. **retrobulbar pupillary reflex**, slight dilation of the pupil, which contracts under light stimulation and then dilates while the light stimulation is still present.
260. **reversed pupillary reflex**, any abnormal pupillary r. opposite to that which occurs normally; e.g., stimulation of the retina by light dilates the pupil. Called also paradoxical pupillary r. or phenomenon.

261. **Riddoch's mass reflex**, mass r.
262. **righting reflex**, the ability to assume optimal position when there has been a departure from it.
263. **Roger's reflex**, esophagosalivary r.
264. **rooting reflex**, a reflex in the newborn in which stimulation of the side of the cheek or the upper or lower lip causes the infant to turn his mouth and face to the stimulus.
265. **Rossolimo's reflex**, on tapping the plantar surface of the toes, plantar flexion of the toes occurs when there are lesions of the pyramidal tract.
266. **Ruggeri's reflex**, acceleration of the pulse following strong convergence of the eyeballs toward something very close to the eyes; it indicates sympathetic excitability.
267. **Saenger's reflex**, see under sign.
268. **scapular reflex**, interscapular r.
269. **scapulohumeral reflex**, adduction with outward rotation of the humerus produced by percussing along the inner edge of the scapula.
270. **Schäffer's reflex**, dorsiflexion of the great toe on pinching the Achilles tendon at its middle third; seen in organic hemiplegia.
271. **scratch reflex**, a spinal reflex by which an itch or other irritation of the skin causes a nearby body part to move over and briskly rub the affected area.
272. **scrotal reflex**, dartos r.
273. **segmental reflex**, a reflex controlled by a single segment or region of the spinal cord.
274. **senile reflex**, a gray reflection from the pupil of aged people due to hardening of the lens.
275. **sexual reflex**, the reflex of erection and ejaculation produced by stimulation of the genitals.
276. **shot-silk reflex**, shot-silk retina.
277. **simple reflex**, a reflex involving a single muscle.
278. **skin reflex**, a reflex occurring on stimulation of the skin.
279. **skin pupillary reflex**, ciliospinal r.
280. **Snellen's reflex**, unilateral congestion of the ear upon stimulation of the distal end of the divided great auricular nerve; called also auriculocervical nerve r.
281. **sole reflex**, plantar r.
282. **somatointestinal reflex**, inhibition of intestinal motility when the skin over the abdomen is stimulated.
283. **spinal reflex**, any reflex whose arc is connected with a center in the spinal cord.
284. **stapedial reflex**, acoustic r.
285. **startle reflex**, 1. Moro's r. 2. see under reaction.
286. **static reflex**, any of the reflexes for maintenance of position and righting of the body, such as the postural reflex, righting reflex, or vestibular reflexes.
287. **statotonic reflexes**, attitudinal r's.
288. **stepping reflex**, 1. movements of progression elicited when the infant is held upright and inclined forward with the soles of the feet touching a flat surface; it is obtainable in the normal infant up to the age of six weeks. 2. extension of the hind leg of a dog when the plantar surface of the foot is pressed.
289. **Stookey's reflex**, with the leg semiflexed at the knee, the tendons of the semimembranosus and the semitendinosus muscles are tapped: flexion of the leg results.
290. **stretch reflex**, reflex contraction of a muscle in response to passive longitudinal stretching; called also Liddell and Sherrington r. and myotatic r. See also muscle spindle, under spindle.
291. **Strümpell's reflex**, leg movement with adduction of the foot produced by stroking the thigh or abdomen.
292. **sucking reflex**, sucking movements of the mouth elicited by the touching of an object to an infant's lips.

293. **superficial reflex**, any withdrawal reflex elicited by noxious or tactile stimulation of the skin, cornea, or mucous membrane, including the corneal reflex, pharyngeal reflex, cremasteric reflex, etc.
294. **supinator longus reflex**, brachioradialis r.
295. **supraorbital reflex**, contraction of the orbicularis oculi muscle on tapping the supraorbital nerve; called also McCarthy's r.
296. **suprapatellar reflex**, with the subject's leg extended the index finger of the examiner is crooked above the patella and is struck; the result is a kick-back of the patella.
297. **suprapubic reflex**, stroking the abdomen above Poupart's ligament causes deviation of the linea alba toward the side that is stroked.
298. **supraumbilical reflex**, epigastric r.
299. **swallowing reflex**, palatal r.
300. **tapetal light reflex**, the glowing of eyes in the dark, as occurs in some carnivorous animals.
301. **tarsophalangeal reflex**, Mendel-Bekhterev r.
302. **tendon reflex**, involuntary contraction of a muscle after brief stretching caused by percussion of its tendon; tendon reflexes include the biceps reflex, triceps reflex, quadriceps reflex, and others. Called also deep r. and tendon jerk or reaction.
303. **testicular compression reflex**, Kocher's r.
304. **threat reflex**, sudden closure of the eyes at a sign of danger.
305. **Throckmorton's reflex**, a variation of the Babinski reflex elicited by percussion of the metatarsophalangeal region in the dorsum of the foot.
306. **tibioadductor reflex**, tapping of the tibia on the inner side of the leg results either in homolateral adduction of the leg or crossed adduction from side to side.
307. **toe reflex**, strong flexion of the great toe flexes all the muscles of the lower extremity in pathologic states accompanied by hyperreflexia.
308. **tonic reflex**, 1. one in which an appreciable period of time passes between muscle contraction and relaxation. 2. a reflex which maintains the reflex contractions that are the basis of posture and attitude.
309. **tonic neck reflex**, a reflex in the newborn consisting of extension of the arm and sometimes of the leg on the side to which the head is forcibly turned, with flexion of the contralateral limbs; cf. Magnus and de Kleijn neck r's.
310. **trained reflex**, conditioned response.
311. **triceps reflex**, contraction of the belly of the triceps muscle and slight extension of the arm when the tendon of the muscle is tapped directly, with the arm flexed and fully supported and relaxed. Called also elbow r. or jerk.
312. **triceps surae reflex**, plantar flexion of the foot caused by a twitchlike contraction of the triceps surae muscle, elicited by a tap on the Achilles tendon preferably while the patient kneels on a bed or chair, the feet hanging free over the edge; called also Achilles jerk, ankle jerk, triceps surae jerk, Achilles tendon r., and ankle r.



313. **trigeminus reflex**, oculopupillary r.
314. **ulnar reflex**, tapping of the styloid process of the ulna results in pronation of the hand.
315. **unconditioned reflex**, see under response.
316. **urinary reflex**, micturition r.
317. **vagus reflex**, abnormal sensitiveness to pressure over the course of the vagus nerve.
318. **vascular reflex**, **vasopressor reflex**, vasoconstriction with a rise in blood pressure caused by neural stimulation.
319. **vertebra prominens reflex**, pressure upon the last cervical vertebra of an animal reduces the tone of all four limbs.
320. **vesical reflex**, bladder r.
321. **vesicointestinal reflex**, inhibition of intestinal motility due to irritation of the bladder.
322. **vestibular reflexes**, the reflexes for maintaining the position of the eyes and body in relation to changes in orientation of the head; the neural pathways are complex, traveling from the vestibular nerve to the vestibular nuclei and thence to the involved muscles of the eye and body; cf. static r.
323. **vestibulo-ocular reflex**, nystagmus or deviation of the eyes in response to stimulation of the vestibular system by angular acceleration or deceleration or when the caloric test is performed (irrigation of the ears with warm or cool water or air). See caloric test and harmonic acceleration test, under test.
324. **virile reflex**, 1. bulbospongiosus r. 2. in the flaccid penis, a sudden reflexive downward jerk elicited by pulling upward the foreskin or glans penis. Called also Hughes' r.
325. **visceral reflex**, that in which the stimulus is set up by some state of an internal organ.
326. **viscerocardiac reflex**, reflex alteration in cardiac rhythm or contractility caused by visceral excitation.
327. **visceromotor reflex**, contraction of abdominal muscles (abdominal rigidity) over a diseased viscus.
328. **viscerosensory reflex**, a response or reaction to pressure on some part of the body due to disease of some internal organ.
329. **viscerotrophic reflex**, degeneration of any peripheral tissue as a result of chronic inflammation of any of the viscera.
330. **vomiting reflex**, vomiting due to reflexive stimulation of muscles of the gastrointestinal tract and throat, allowing their contents to be forcibly expelled; it is mediated by centers in the medulla oblongata and can be set in motion by many different stimuli such as touching the back of the pharynx. See also pharyngeal r.

331. **von Mering reflex**, relaxation of overlying abdominal muscles following ingestion of food.
332. **water-silk reflex**, shot-silk retina.
333. **Weiss' reflex**, a curved reflection seen with the ophthalmoscope on the fundus of the eye to the nasal side of the disk; believed to be indicative of myopia.
334. **Westphal's pupillary reflex**, **Westphal-Piltz reflex**, orbicularis pupillary r.
335. **withdrawal reflex**, a nociceptive reflex in which a body part is quickly moved away from a painful stimulus.
336. **zygomatic reflex**, lateral motion of the lower jaw to the percussed side on percussion over the zygoma.

B. List of “signs” from Dorland’s Medical Dictionary

sign (sign) (s[imacr]n) [L. *signum*] an indication of the existence of something; any objective evidence of a disease, i.e., such evidence as is perceptible to the examining physician, as opposed to the subjective sensations (symptoms) of the patient.

1. **Aaron's sign**, a sensation of pain or distress in the epigastric or precordial region on pressure over McBurney's point in appendicitis.
2. **Abadie's sign**, 1. [Charles *Abadie*] spasm of the levator palpebrae superioris muscle; a sign of Graves' disease. 2. [Jean *Abadie*] insensibility of the Achilles tendon to pressure; seen in tabes dorsalis.
3. **accessory sign**, any nonpathognomonic sign of disease.
4. **air-cushion sign**, Klemm's s.
5. **Allis' sign**, relaxation of the fascia between the crest of the ilium and the greater trochanter: a sign of fracture of the neck of the femur.
6. **Amoss' sign**, in painful flexure of the spine, the patient, when rising to a sitting posture from lying in bed, does so by supporting himself with his hands placed far behind him in the bed.
7. **André Thomas sign**, 1. if during the finger to nose test, the patient is directed to raise his arm over his head and is then suddenly ordered to let it fall to his head, the arm will rebound; seen in disease of the cerebellum. Cf. rebound phenomenon. 2. pinching of the trapezius muscle causes gooseflesh above the level of a spinal cord lesion.
8. **Anghelescu's sign**, inability to bend the spine while lying on the back so as to rest on the head and heels alone, seen in tuberculosis of the vertebrae.
9. **antecedent sign**, any precursory indication of an attack of disease.
10. **anterior drawer sign**, see under test.
11. **anterior tibial sign**, tibialis s.
12. **anticus sign**, Piotrowski's s.
13. **Argyll Robertson pupil sign**, see under pupil.
14. **Arroyo's sign**, asthenocoria.
15. **assident sign**, accessory s.
16. **Auenbrugger's sign**, a bulging of the epigastrium, due to extensive pericardial effusion.
17. **Auspitz sign**, the appearance of multiple fine bleeding points when a scale is removed from a psoriatic plaque, caused by thinning of the epidermis over the dermal papillae.
18. **Babinski's sign**, 1. loss or lessening of the Achilles tendon reflex in sciatica: this distinguishes it from hysteric sciatica. 2. a misnomer for Babinski's reflex. 3. in hemiplegia, the contraction of the platysma muscle in the healthy side is more vigorous than on the affected side, as seen in opening the mouth, whistling, blowing, etc. 4. when a hemiplegic patient is lying with arms crossed upon the chest, and makes an effort to sit up, the thigh on the paralyzed side is flexed upon the pelvis and the heel is lifted from the ground, while on the healthy side the limb does not move. 5. when the paralyzed forearm is placed in supination, it turns over to pronation: seen in organic paralysis. Called also pronation s.
19. **Babinski's toe sign**, Babinski's reflex.
20. **Baccelli's sign**, aphonic pectoriloquy.
21. **Baillarger's sign**, inequality of the pupils in general paresis.
22. **Ballance's sign**, resonance of right flank when the patient lies on the left side; said to be present in splenic rupture.
23. **Ballet's sign**, external ophthalmoplegia, with loss of all voluntary eye movements, the pupillary movements and reflex eye movements persisting; seen in Graves' disease and hysteria.

24. **Bamberger's sign**, 1. alochiria. 2. presence of signs of consolidation at the angle of the scapula, which disappear when the patient leans forward; a sign of pericardial effusion.
25. **banana sign**, a flattened and curved, bananalike shape of the cerebellar hemispheres seen in axial section in sonography of the fetal skull; a sign of the Arnold-Chiari deformity.
26. **Búrúny's sign**, caloric test; see under *test*.
27. **Bard's sign**, in organic nystagmus the oscillations of the eye increase as the patient's attention follows the finger moved alternately from one side to the other; but in congenital nystagmus the oscillations disappear in like condition.
28. **Barré's sign**, contraction of the iris is retarded in mental deterioration.
29. **Barré's pyramidal sign**, the patient lies face down and the legs are flexed at the knee; he is unable to hold the legs in this vertical position if there is disease of the pyramidal tracts.
30. **Bastian-Bruns' sign**, see under law.
31. **Battle's sign**, discoloration over the skin of the mastoid region of the skull, in the line of the posterior auricular artery, the ecchymosis first appearing near the tip of the mastoid process; seen in fracture of the base of the skull.
32. **Becker's sign**, see under phenomenon.
33. **Béclard's sign**, a sign of the maturity of the fetus consisting of a center of ossification in the lower epiphysis of the femur.
34. **Beevor's sign**, 1. a sign of functional paralysis consisting of inability of the patient to inhibit the antagonistic muscles. 2. upward deviation of the umbilicus on attempting to lift the head, caused by contraction of the upper but not the lower abdominal muscles and indicative of a spinal cord lesion in the region of the lower thoracic vertebrae.
35. **Bekhterev's sign**, 1. see under reflex. 2. paralysis of the facial muscles for automatic movements.
36. **Bell's sign**, see under phenomenon.
37. **Berger's sign**, an irregularly shaped or elliptical pupil in the early stages of tabes dorsalis, paralytic dementia, and certain paralyses.
38. **Bergman's sign**, in urologic radiography, (a) the ureter is dilated immediately below a neoplasm, rather than collapsed as below an obstructing stone and (b) the ureteral catheter tends to coil in this dilated portion of the ureter.
39. **Bethea's sign**, when the examiner, standing behind the patient, places his fingertips on the upper surfaces of corresponding ribs high in the patient's axillae, unilateral impairment of chest expansion is indicated by less respiratory movement of the ribs on the side affected. Called also Bethea's method.
40. **Bezold's sign**, an inflammatory swelling below the apex of the mastoid process; evidence of mastoiditis.
41. **Biederman's sign**, a dark red color (instead of the normal pink) of the anterior pillars of the throat, seen in some patients with syphilis.
42. **Biernacki's sign**, analgesia of the ulnar nerve in general paresis and tabes dorsalis.
43. **Biot's sign**, see under respiration.
44. **Bird's sign**, a definite zone of dullness with absence of the respiratory sounds in hydatid disease of the lung.
45. **Bjerrum's sign**, see under scotoma.
46. **Blatin's sign**, hydatid thrill.
47. **Blumberg's sign**, pain on abrupt release of steady pressure (rebound tenderness) over the site of a suspected abdominal lesion; seen in peritonitis.
48. **Boas' sign**, see under point.
49. **Bonnet's sign**, pain on thigh adduction in sciatica.
50. **Bordier-Fränké's sign**, Bell's phenomenon.
51. **Borsieri's sign**, when the fingernail is drawn along the skin in early stages of scarlet fever, a white line is left which quickly turns red; called also Borsieri's line.
52. **Boston's sign**, Graefe's s.
53. **Bouillaud's sign**, permanent retraction of the chest in the precordial region; a sign of adherent pericardium.

54. **bowler hat sign**, a shadow resembling a bowler hat, seen on a radiograph of the colon; it represents the filling defect of either a sessile polyp on the inferior wall or a diverticulum.
55. **Boyce's sign**, a gurgling sound heard on pressure by the hand on the side of the neck, in diverticulum of the esophagus.
56. **Bozzolo's sign**, a visible pulsation of the arteries within the nostrils; said to indicate aneurysm of the thoracic aorta.
57. **Bragard's sign**, with the knee stiff, the lower extremity is flexed at the hip until the patient experiences pain; the foot is then dorsiflexed. Increase of pain points to disease of the nerve root.
58. **Branham's sign**, bradycardia produced by digital closure of an artery proximal to an arteriovenous fistula.
59. **Braunwald sign**, occurrence of a weak pulse instead of a strong one immediately after a premature ventricular contraction.
60. **Braxton Hicks' sign**, see under *contraction*.
61. **Broadbent's sign**, a retraction seen on the left side of the back, near the eleventh and twelfth ribs, related to pericardial adhesion.
62. **Broadbent's inverted sign**, pulsations synchronizing with ventricular systole on the posterior lateral wall of the chest in gross dilatation of the left atrium.
63. **Brockenbrough's sign**, occurrence of a weak pulse instead of a strong one immediately after a premature ventricular contraction; indicative of idiopathic hypertrophic subaortic stenosis.
64. **Brodie's sign**, a black spot on the glans penis, a sign of gangrene due to urinary extravasation into the corpus spongiosum.
65. **broken straw sign**, a sharply angulated spindle cell resembling a broken straw; characteristic of the spindle cell form of embryonal rhabdomyosarcoma.
66. **Brown's sign**, blanching of the tympanic membrane and of the area behind it, seen with pneumatic pressure on the membrane; it indicates presence of a vascular tumor or other lesion in the middle ear.
67. **Brown-Séquard's sign**, see under *syndrome*.
68. **Brudzinski's sign**, 1. in meningitis, flexion of the neck usually results in flexion of the hip and knee; called also *neck s.* 2. in meningitis, when passive flexion of the lower limb on one side is made, a similar movement will be seen in the opposite limb; called also *contralateral s.*
69. **Brunati's sign**, the appearance of opacities in the cornea during the course of pneumonia or typhoid fever.
70. **Bruns' sign**, see under *syndrome*.
71. **Bryant's sign**, lowering of the axillary folds in dislocation of the shoulder.
72. **Burton's sign**, *lead line*.
73. **Cantelli's sign**, *doll's eye reflex*.
74. **Carabelli's sign**, see under *cusp*.
75. **cardinal signs**, (of inflammation), dolor, calor, rubor, tumor, and functio laesa; see *inflammation*.
76. **cardiorespiratory sign**, a change in the normal pulse-respiration ratio from 4:1 to 2:1; seen in infantile scurvy.
77. **Carman's sign**, **Carman-Kirklin sign**, **Carman-Kirklin meniscus sign**, *meniscus s.*
78. **Carnett's sign**, a test for parietal tenderness: the abdomen is palpated while the patient holds the anterior abdominal muscles tense; the tense muscles prevent the examiner's fingers from coming in contact with the underlying viscera and any tenderness elicited over them will be parietal in location. Tenderness elicited over relaxed muscles may be either parietal or intra-abdominal in origin; that present with relaxed muscles and absent with tense muscles is due to a subparietal lesion and its cause is inside the abdomen; that found with both relaxed and tensed muscles is due to an anterior parietal lesion and its cause is outside the abdominal cavity.
79. **Carvalho's sign**, in tricuspid regurgitation, augmentation of the pansystolic murmur by inspiration.

80. **Cegka's sign**, invariability of the cardiac dullness during the different phases of respiration; a sign of adherent pericardium.
81. **Chaddock's sign**, see under reflex.
82. **Chadwick's sign**, a dark bluish or purplish-red and congested appearance of the vaginal mucosa, an indication of pregnancy.
83. **Charcot's sign**, the raising of the eyebrow in peripheral facial paralysis, and the lowering of the same part in facial contraction.
84. **Cheyne-Stokes sign**, see under respiration.
85. **Chilaiditi's sign**, hepatoptosis (def. 2).
86. **Chvostek's sign**, **Chvostek-Weiss sign**, spasm of the facial muscles elicited by tapping the facial nerve in the region of the parotid gland; seen in tetany. Called also Schultze's s. and Schultze-Chvostek s.
87. **Claude's hyperkinesis sign**, reflex movements of paretic muscles elicited by painful stimuli.
88. **clavicular sign**, a tumefaction on the inner third of the right clavicle; seen in congenital syphilis. Called also Higouménaki's s.
89. **Cleeman's sign**, creasing of the skin just above the patella, indicative of fracture of the femur with overriding of fragments.
90. **Codman's sign**, in rupture of the supraspinatus tendon, the arm can be passively abducted without pain, but when support of the arm is removed and the deltoid contracts suddenly, pain occurs again.
91. **cogwheel sign**, see under rigidity.
92. **coiled spring sign**, a concentric ring pattern of the mucosa of the intestine, seen on barium enema examination in a variety of diseases, including posttraumatic hematoma of the duodenum, acute appendicitis, intussusception of the appendix, mucocele, endometriosis of the appendix, and carcinoma.
93. **Cole's sign**, deformity of the duodenal contour as seen in the radiograph, a sign of the presence of duodenal ulcer.
94. **colon cutoff sign**, a radiographic sign of appendiceal perforation or colonic spasm, consisting of absence of gas and feces in the right lower quadrant, reflex dilatation of the transverse colon, and sharp cutoff of gas at the hepatic flexure.
95. **commemorative sign**, any sign of a previous disease.
96. **Comolli's sign**, a sign of scapular fracture consisting of the appearance in the scapular region, shortly after the accident, of a triangular swelling reproducing the shape of the body of the scapula.
97. **complementary opposition sign**, Grasset-Gaussel-Hoover s.
98. **contralateral sign**, Brudzinski's s., def. 2.
99. **Coopernail's sign**, ecchymosis on the perineum and scrotum or labia: a sign of fracture of the pelvis.
100. **Cope's sign**, psoas s.
101. **Corrigan's sign**, 1. see under line. 2. see under pulse.
102. **coughing sign**, Huntington's s.
103. **Courvoisier's sign**, see under law.
104. **Cowen's sign**, when light is shone into one pupil, there is jerky constriction of the contralateral pupil in Graves' disease.
105. **crescent sign**, meniscus s.
106. **Crichton-Browne's sign**, tremor of the outer angles of the eyes and of the labial commissures in the earlier stages of general paresis.
107. **Crowe's sign**, axillary freckling seen in neurofibromatosis.
108. **Cullen's sign**, a bluish discoloration of the skin around the umbilicus sometimes associated with intraperitoneal hemorrhage, especially following rupture of the uterine tube in ectopic pregnancy. A similar discoloration is seen in acute hemorrhagic pancreatitis.
109. **Dalrymple's sign**, one manifestation of Graves' orbitopathy, consisting of retraction of the eyelids so that the palpebral opening is abnormally wide. See also Stellwag's s.

110. **D'Amato's sign**, in pleural effusion, the location of dullness is altered from the vertebral area in the sitting position to the heart region when the patient assumes a lateral position on the side opposite the effusion.
111. **Darier's sign**, urtication and itching occurring on rubbing the lesions of urticaria pigmentosa.
112. **Dawbarn's sign**, in acute subacromial bursitis, when the arm hangs by the side palpation over the bursa causes pain, but when the arm is abducted this pain disappears.
113. **Dejerine's sign**, aggravation of symptoms of radiculitis produced by coughing, sneezing, and straining at stool.
114. **Delbet's sign**, in aneurysm of the main artery of a limb, if the nutrition of the part distal to the aneurysm is maintained, although the pulse may have disappeared, the collateral circulation is sufficient.
115. **Demarquay's sign**, fixation or lowering of the larynx during phonation and deglutition; a sign of syphilis of the trachea.
116. **Demianoff's sign**, with the patient in dorsal decubitus position, extreme pain when the attempt is made to lift an extended leg above ten degrees, a sign of a lesion in the erector spinae muscles of the lumbar region. Cf. Lasèque's s.
117. **de Musset's sign**, Musset's s.
118. **Dennie's sign**, Morgan's line.
119. **Desault's sign**, a sign of intracapsular fracture of the femur, consisting of alteration of the arc described by rotation of the great trochanter, which normally describes the segment of a circle, but in this fracture rotates only as the apex of the femur as it rotates about its own axis.
120. **d'Espine's sign**, in the normal person, on auscultation over the spinous processes, pectoriloquy ceases at the bifurcation of the trachea, and in infants opposite the seventh cervical vertebra. If pectoriloquy is heard lower than this, it indicates enlargement of the bronchial lymph nodes.
121. **Dew's sign**, in diaphragmatic hydatid abscess beneath the right cupola, the area of resonance moves caudally with the patient on hands and knees.
122. **Dixon Mann's sign**, Mann's s.
123. **doll's eye sign**, see under reflex.
124. **Dorendorf's sign**, fullness of the supraclavicular groove on one side in aneurysm of the aortic arch.
125. **double bubble sign**, the appearance on the radiograph of the abdomen of two foci of gas, one in the stomach and the other in the duodenum; a sign of duodenal obstruction. The same sign, in this case consisting of the stomach and duodenum distended by fluid, may be observed in the fetus by ultrasonography.
126. **drawer signs**, see under test.
127. **Drummond's sign**, a whiff heard at the open mouth during respiration in cases of aortic aneurysm.
128. **DTP sign**, (*distal tingling on percussion*), Tinel's s.
129. **Dubois' sign**, shortness of the little finger in congenital syphilis.
130. **Duchenne's sign**, the sinking in of the epigastrium on inspiration in paralysis of the diaphragm or in certain cases of hydropericardium.
131. **Duckworth's sign**, see under phenomenon.
132. **Dugas' sign**, see under test.
133. **Dupuytren's sign**, 1. a crackling sensation on pressure over a sarcomatous bone. 2. in congenital dislocation of the head of the femur, there is a free up-and-down movement of the head of the bone.
134. **Duroziez's sign**, see under murmur.
135. **E sign**, reversed three s.
136. **echo sign**, 1. a percussion sound resembling an echo which is heard over a hydatid cyst. 2. the repetition of the last word or clause of a sentence, seen in certain brain diseases; echolalia.
137. **Elliot's sign**, 1. induration of the edge of a syphilitic skin lesion. 2. a scotoma extending from the blind spot and made up of numerous points or spots.

138. **Ely's sign**, see under *test*.
139. **Enroth's sign**, abnormal fullness of the eyelids, a manifestation of Graves' orbitopathy.
140. **Erben's sign**, see under *reflex*.
141. **Erichsen's sign**, when the iliac bones are sharply pressed toward each other pain is felt in sacroiliac disease but not in hip disease.
142. **Escherich's sign**, in tetany, percussion of the inner surface of the lips or tongue produces contraction of the lips, tongue, and masseter muscles. Called also Escherich's reflex.
143. **Eustace Smith's sign**, Smith's s.
144. **Ewart's sign**, bronchial breathing and dullness on percussion at the lower angle of the left scapula in pericardial effusion.
145. **Ewing sign**, tenderness at the upper inner angle of the orbit: a sign of obstruction of the outlet of the frontal sinus.
146. **external malleolar sign**, Chaddock's reflex.
147. **fabere sign**, see Patrick's test, under *test*.
148. **facial sign**, Chvostek's s.
149. **Fajersztajn's crossed sciatic sign**, in sciatica, when the leg is flexed, the hip can also be flexed, but not when the leg is held straight; flexing the sound thigh with the leg held straight causes pain on the affected side.
150. **fan sign**, spreading apart of the toes following the stroking of the sole of the foot; it forms part of the Babinski reflex.
151. **fat pad sign**, distention and displacement of the fat adjacent to a joint capsule, usually in the elbow or knee, visible on a radiograph when the joint is flexed; a sign of a fracture within the joint that involves little or no bone displacement.
152. **Federici's sign**, on auscultation of the abdomen, the cardiac sounds can be heard in cases of intestinal perforation with gas in the peritoneal cavity.
153. **figure three sign**, a pair of bulges in the wall of the aortic arch, one above and one below the aortic knuckle, seen on a radiograph and signifying coarctation of the aorta. See also reversed three s. Called also three s.
154. **Filipovitch's sign**, **Filipowicz's sign**, the yellow discoloration of prominent parts of the palms and soles in typhoid fever; called also palmoplantar s.
155. **flag sign**, dyspigmentation of the hair occurring as a band of light hair, seen in children who have recovered from kwashiorkor.
156. **floating tooth sign**, on radiographic examination of the mandible, erosion of the bony alveoli around the teeth so that they seem to be floating in space; it occurs in some forms of histiocytosis X.
157. **flush-tank sign**, the passage of a large amount of urine and the coincident temporary disappearance of a lumbar swelling; a sign of hydronephrosis.
158. **forearm sign**, Léri's s.
159. **formication sign**, Tinel's s.
160. **Fränkel's sign**, excessive range of passive movement of the hip joint, indicating diminished tone of the surrounding musculature in tabes dorsalis.
161. **Friedreich's sign**, diastolic collapse of the cervical veins due to adherent pericardium.
162. **Froment's paper sign**, flexion of the distal phalanx of the thumb when a sheet of paper is held between the thumb and index finger; a sign of a lesion of the ulnar nerve.
163. **Gaenslen's sign**, with the patient in the supine position, the knee and hip of one leg are held in flexed position by the patient, while the other leg, hanging over the edge of the table, is pressed down by the examiner to produce hyperextension of the hip: pain occurs on the affected side in lumbosacral disease.
164. **Galeazzi sign**, in congenital dislocation of the hip, apparent shortening of the femur, as shown by the difference of knee levels with the knees and hips flexed at right angles with the patient lying on a flat table.
165. **Gauss' sign**, an increase in uterine mobility seen early in pregnancy.
166. **Gianelli's sign**, Tournay's s.

167. **Gilbert's sign**, opsiuria indicative of hepatic cirrhosis.
168. **Glasgow's sign**, a systolic sound in the brachial artery in latent aneurysm of the aorta.
169. **Goggia's sign**, in health, the fibrillary contraction produced by striking and then pinching the brachial biceps extends throughout the whole muscle: in debilitating disease, such as typhoid fever, the contraction is local.
170. **Goldstein's sign**, wide space between the great toe, and the adjoining toe seen in cretinism and Down's syndrome.
171. **Goldthwait's sign**, the patient lying supine, his leg is raised by the examiner with one hand, the other hand being placed under the patient's lower back; leverage is then applied to the side of the pelvis. If pain is felt by the patient before the lumbar spine is moved, the lesion is a sprain of the sacroiliac joint. If pain does not appear until after the lumbar spine moves, the lesion is in the sacroiliac or lumbosacral articulation.
172. **Goodell's sign**, softening of the cervix uteri as a sign of pregnancy.
173. **Gordon's sign**, finger phenomenon (def. 1).
174. **Gorlin's sign**, the ability to touch the tip of the nose with the tongue, frequently a sign of Ehlers-Danlos syndrome.
175. **Gottron's sign**, 1. a cutaneous sign pathognomonic of dermatomyositis, consisting of symmetrical macular violaceous erythema, with or without edema, overlying the dorsal aspect of the interphalangeal joints of the hands, olecranon processes, patellas, and medial malleoli. 2. see under papule.
176. **Gowers' sign**, 1. abrupt intermittent oscillation of the iris under the influence of light; seen in certain stages of tabes dorsalis. 2. a sign of pseudohypertrophic muscular dystrophy; to stand from the supine position, the patient rolls to the prone position, kneels, and raises himself to a standing position by pushing with his hands against shins, knees, and thighs. Called also Gowers' maneuver or phenomenon.
177. **Graefe's sign**, failure of the upper lid to move downward promptly and evenly with the eyeball in looking downward; instead it moves tardily and jerkily, a manifestation of Graves' orbitopathy. Called also Boston's s. and von Graefe's s.
178. **Grancher's sign**, equality of pitch between expiratory and inspiratory murmurs; a sign of obstruction to expiration.
179. **Granger's sign**, if in the radiograph of an infant two years old or less, the anterior wall of the lateral sinus is visible, extensive destruction of the mastoid is indicated.
180. **Grasset's sign**, **Grasset-Bychowski sign**, Grasset's phenomenon.
181. **Grasset-Gaussel-Hoover sign**, when a recumbent patient with hemiparesis attempts to lift the paretic limb, there is greater downward pressure on the examiner's hand with the sound limb than is observed in the test with a normal person.
182. **Grey Turner's sign**, Turner's s.
183. **Griesinger's sign**, edematous swelling behind the mastoid process; seen in thrombosis of the transverse sinus.
184. **Griffith's sign**, lower lid lag on upward gaze, a manifestation of Graves' orbitopathy.
185. **Grocco's sign**, 1. see under triangle. 2. extension of the liver dullness to the left of the midspinal line, indicating enlargement of the organ.
186. **Gubler's sign**, see under tumor.
187. **Guilland's sign**, brisk flexion at the hip and knee joint when the contralateral quadriceps muscle is pinched; a sign of meningeal irritation.
188. **Gunn's sign**, 1. Gunn's crossing s. 2. Marcus Gunn's pupillary phenomenon. 3. see under syndrome.
189. **Gunn's crossing sign**, a crossing of an artery over a vein in the fundus of the eye, indicative of essential hypertension.
190. **Gunn's pupillary sign**, Marcus Gunn's pupillary phenomenon.
191. **Guyon's sign**, the ballottement and palpation of a floating kidney.
192. **Hahn's sign**, persistent rotation of the head from side to side in cerebellar disease of childhood.

193. **Hall's sign**, a tracheal diastolic shock felt in aneurysm of the aorta.
194. **halo sign**, a halo effect produced in the radiograph of the fetal head between the subcutaneous fat and the cranium; said to be indicative of intrauterine death of the fetus.
195. **Hamman's sign**, a precordial crunching, clicking, or knocking sound, synchronous with each heart beat, heard on auscultation in such conditions as acute mediastinitis, pneumomediastinum, and pneumothorax. Called also *Hamman's murmur*.
196. **harlequin sign**, reddening of the lower half of the laterally recumbent body and blanching of the upper half, due to temporary vasomotor disturbance in newborn infants.
197. **Hatchcock's sign**, tenderness on running the finger toward the angle of the jaw in mumps.
198. **Haudek's sign**, a projecting shadow in radiographs of penetrating gastric ulcer, due to settlement of bismuth in pathologic niches of the stomach wall; called also *Haudek's niche*.
199. **Hawkins sign**, in fractures of the talar neck, a radiolucent zone beneath the subchondral plate of the head of the talus, indicative of disuse osteoporosis; its absence reflects increased risk of talar avascular necrosis.
200. **Heberden's signs**, see under *node*.
201. **Hefke-Turner sign**, a widening and change in contour of the normal obturator x-ray shadow, indicative of pathologic condition of the hip joint; called also *obturator s.*
202. **Hegar's sign**, softening of the lower segment of the uterus, an indication of pregnancy.
203. **Heilbronner's sign**, see under *thigh*.
204. **Heim-Kreysig sign**, a depression of the intercostal spaces occurring along with the cardiac systole in adherent pericarditis.
205. **Helbing's sign**, medialward curving of the Achilles tendon as viewed from behind; seen in flatfoot.
206. **Hennebert's sign**, rotatory nystagmus when positive or negative pressure is applied to the tympanic membrane, indicative of labyrinthitis with leakage of perilymph; positive pressure (air compression) causes nystagmus toward the affected side, and negative pressure (air rarefaction) causes nystagmus away from the affected side.
207. **Hennings' sign**, an angular deformity of the angulus of the stomach, in which it assumes a Gothic arch shape; a sign of chronic gastric ulcer. Called also *Gothic arch formation*.
208. **Higouménaki's sign**, *clavicular s.*
209. **Hill's sign**, disproportionate femoral systolic hypertension, seen in aortic regurgitation and certain other conditions involving increased stroke volume.
210. **Hirschberg's sign**, adduction, inversion, and slight plantar flexion of the foot on stroking the inner aspect (not the sole) of the foot from the great toe to the heel; called also *adductor reflex of foot*.
211. **Hitzelberger's sign**, anesthesia of medial, posterior, or superior areas of the external auditory canal caused by an *acoustic neuroma* that is pressing against the facial nerve.
212. **Hochsinger's sign**, see under *phenomenon*.
213. **Hoehne's sign**, absence of uterine contractions during delivery despite repeated injections of oxytocics, regarded as a sign of rupture of the uterus.
214. **Hoffmann's sign**, 1. see under *phenomenon*. 2. in hemiplegia, a sudden nipping of the nail of the index, middle, or ring finger will produce flexion of the terminal phalanx of the thumb and of the second and third phalanges of some other finger; called also *digital reflex* and *Hoffmann's reflex*.
215. **Holmes' sign**, *rebound phenomenon*.
216. **Homans' sign**, pain on passive dorsiflexion of the foot; a sign of thrombosis of deep calf veins.
217. **Hoover's sign**, 1. in the normal state or in genuine paralysis, if the patient, lying on a flat surface, is directed to press the leg against the surface, there will be a lifting movement in the other leg; this phenomenon is absent in hysteria and

- malingering. 2. movement of the costal margins toward the midline in inspiration, occurring bilaterally in pulmonary emphysema and unilaterally in conditions causing flattening of the diaphragm, such as pleural effusion and pneumothorax.
218. **Hope's sign**, double heart beat in aortic aneurysm.
219. **Horn's sign**, pain produced by traction on the right spermatic cord in acute appendicitis.
220. **Horner's sign**, Spalding's s.
221. **Horsley's sign**, if there is a difference in the temperature in the two axillae, the higher temperature will be on the paralyzed side.
222. **Howship-Romberg sign**, pain passing down the inner side of the thigh to the knee due to pressure on the obturator nerve by an obturator hernia.
223. **Hoynes sign**, a sign elicited in paralytic or nonparalytic poliomyelitis: with the patient in the supine position, his head falls back when his shoulders are elevated.
224. **Huetter's sign**, the absence of the transmission of osseous vibration in cases of fracture with fibrous material interposed between the fragments.
225. **Huntington's sign**, the patient is recumbent, with his legs hanging over the edge of a table, and is told to cough. If the coughing produces flexion of the thigh and extension of the leg in the paralyzed limb, it indicates that the paralysis is due to an upper motor neuron lesion.
226. **Hutchinson's sign**, 1. interstitial keratitis and a dull-red discoloration of the cornea in congenital syphilis. 2. see under tooth. 3. see under triad.
227. **hyperkinesis sign**, Claude's hyperkinesis s.
228. **interossei sign**, Souques' phenomenon.
229. **Jendrassik's sign**, paralysis of the extraocular muscles, one manifestation of Graves' orbitopathy.
230. **jugular sign**, Queckenstedt's s.
231. **Kanavel's sign**, a point of maximum tenderness in the palm 1 inch proximal to the base of the little finger in infection of tendon sheath.
232. **Kantor's sign**, string s. (def. 1).
233. **Karplus' sign**, a modification of the vocal resonance, in which, on auscultation over a pleural effusion, the vowel *u* spoken by the patient is heard as *a*.
234. **Keen's sign**, increased diameter of the leg at the malleoli in Pott's fracture of the fibula.
235. **Kehr's sign**, severe pain in the left shoulder in some cases of rupture of the spleen.
236. **Kellock's sign**, increase of the vibration of the ribs on sharp percussion with the right hand, the left hand being placed firmly on the thorax under the nipple; a sign of pleural effusion.
237. **Kelly's sign**, if the ureter is teased with an artery forceps, it will contract like a snake or worm.
238. **Kerandel's sign**, deep hyperesthesia accompanied by pain, often retarded, after some slight blow upon a bony projection of the body; seen in African trypanosomiasis.
239. **Kergaradec's sign**, uterine souffle.
240. **Kernig's sign**, a sign of meningitis: the patient can easily and completely extend the leg when in dorsal decubitus position but not when in the sitting posture or when lying with the thigh flexed upon the abdomen.
241. **Kerr's sign**, alteration of the texture of the skin below the somatic level in lesions of the spinal cord.
242. **Kestenbaum's sign**, a decrease in number of arterioles traversing the optic disk margin as a criterion for optic atrophy.
243. **Kleist's sign**, the fingers of the patient when gently elevated by the fingers of the examiner will hook into the examiner's fingers; indicative of frontal and thalamic lesions.
244. **Klemm's sign**, in the radiograph in chronic appendicitis, there is often an indication of tympanites in the right lower quadrant.

245. **Klippel-Weil sign**, flexion and adduction of the thumb when the patient's flexed fingers are quickly extended by the examiner; indicative of pyramidal tract disease.
246. **Knies' sign**, unequal dilatation of the pupils, one manifestation of Graves' orbitopathy.
247. **Kocher's sign**, a sign of Graves' orbitopathy: the examiner places one hand on a level with the patient's eyes and then lifts it higher; the patient's upper lid springs up more quickly than the eyeball does.
248. **Koplik's sign**, see under spot.
249. **Kreysig's sign**, Heim-Kreysig s.
250. **Krisovski's sign**, **Krisowski's sign**, cicatricial lines radiating from the mouth in congenital syphilis.
251. **Kussmaul's sign**, 1. distention of the jugular veins on inspiration, seen in constrictive pericarditis and mediastinal tumor. 2. paradoxical pulse.
252. **Küstner's sign**, a cystic tumor on the median line anterior to the uterus in cases of ovarian dermoids.
253. **Lafora's sign**, picking of the nose regarded as an early sign of cerebrospinal meningitis.
254. **Langoria's sign**, relaxation of the extensor muscles of the thigh; a symptom of intracapsular fracture of the femur.
255. **Lasègue's sign**, in sciatica, flexion of the hip is painful when the knee is extended, but painless when the knee is flexed. This distinguishes the disorder from disease of the hip joint. Cf. Demianoff's s.
256. **Laugier's sign**, a condition in which the styloid process of the radius and of the ulna are on the same level; seen in fracture of the lower part of the radius.
257. **leg sign**, 1. Schlesinger's s. 2. Neri's s.
258. **Leichtenstern's sign**, in cerebrospinal meningitis, tapping lightly any bone of the extremities causes the patient to wince suddenly.
259. **lemon sign**, scalloping of the frontal bones giving the skull a lemon-shaped configuration in axial section in sonography of the fetal skull during the second trimester of pregnancy; a sign of the Arnold-Chiari deformity.
260. **Lenhoff's sign**, a furrow appearing on deep inspiration below the lowest rib and above an echinococcus cyst of the liver.
261. **Léri's sign**, passive flexion of the hand and wrist of the affected side in hemiplegia shows no normal flexion at the elbow.
262. **Leser-Trélat sign**, sudden appearance and rapid increase in size and number of seborrheic keratoses, which may be a sign of internal malignancy, especially of the gastrointestinal tract.
263. **Lhermitte's sign**, the development of sudden, transient, electric-like shocks spreading down the body when the patient flexes the head forward; seen mainly in multiple sclerosis but also in compression and other disorders of the cervical cord.
264. **Lichtheim's sign**, in some types of motor aphasia the patient cannot speak but can indicate with fingers the number of syllables in a word being thought of. Called also Dejerine-Lichtheim phenomenon.
265. **ligature sign**, in hematuria, the development of ecchymoses in the distal part of a limb to which a ligature has been applied.
266. **Linder's sign**, with the patient recumbent or sitting with outstretched legs, passive flexion of the head will cause pain in the leg or the lumbar region in sciatica.
267. **Livierato's sign**, vasoconstriction when the abdominal sympathetic nerve is irritated by striking the anterior abdomen along the xiphoumbilical line.
268. **Lloyd's sign**, a symptom of renal calculus, consisting of pain in the loin on deep percussion over the kidney, even when pressure causes no pain.
269. **Lucas' sign**, distention of the abdomen in the early stages of rickets.
270. **Ludloff's sign**, swelling and ecchymosis at the base of Scarpa's triangle together with inability to raise the thigh when in a sitting posture, a sign of traumatic separation of the epiphysis of the greater trochanter.
271. **Lust's sign**, see under phenomenon.

272. **McBurney's sign**, tenderness at a point two-thirds the distance from the umbilicus to the anterior superior spine of the ilium; indicative of appendicitis. See also under *point*.
273. **Macewen's sign**, on percussion of the skull behind the junction of the frontal, temporal, and parietal bones, there is a more resonant note than normal in internal hydrocephalus and cerebral abscess. Called also *cracked-pot sound* and *cranial cracked-pot sound*.
274. **McGinn-White sign**, a Q wave and late inversion of the T wave in lead III, low ST intervals and T waves in lead II, and inverted T waves in chest leads V₂ and V₃, the electrocardiographic evidence of right ventricular dilatation due to massive pulmonary embolism, plus the clinical signs of acute cor pulmonale.
275. **McMurray sign**, see under *test*.
276. **Magendie's sign**, **Magendie-Hertwig sign**, *skew deviation*.
277. **Magnan's sign**, *formication*.
278. **Mahler's sign**, a steady increase of pulse rate without corresponding elevation of temperature; seen in thrombosis.
279. **Maisonneuve's sign**, marked hyperextensibility of the hand; a symptom of Colles' fracture.
280. **Mann's sign**, with *Graves' orbitopathy*, the two eyes appear not to be on the same level. Called also *Dixon Mann's s.*
281. **Mannkopf's sign**, increase in the frequency of the pulse on pressure over a painful spot; not present in simulated pain.
282. **Marcus Gunn's pupillary sign**, see under *phenomenon*.
283. **Marfan's sign**, a red triangle at the tip of a coated tongue indicates typhoid fever; a rarely observed phenomenon.
284. **Marie's sign**, tremor of the body or extremities in *Graves' disease* and other types of *hyperthyroidism*.
285. **Marie-Foix sign**, withdrawal of lower leg on transverse pressure of tarsus or forced flexion of toes when the leg is incapable of voluntary movement.
286. **Marinesco's sign**, *Marinesco's succulent hand*; see under *hand*.
287. **Mean's sign**, *Kocher's s.*
288. **Meltzer's sign**, loss of the normal second sound, heard on auscultation of the heart after swallowing; symptomatic of occlusion or contraction of the lower part of the esophagus.
289. **Mendel-Bekhterev sign**, see under *reflex*.
290. **meniscus sign**, the radioscopic appearance of a crescentic shadow made by the crater of a gastric ulcer: when the convexity of the crescent points outward the ulcer is on the lesser curvature; when the convexity points downward the ulcer is distal to the angular incisure. Called also *Carman's s.*, *Carman-Kirklin s.*, and *crescent s.*
291. **Mennell's sign**, an examining thumb is placed over the posterosuperior spine of the sacrum and then made to slide, first outward and then inward. If on pressure over the former point tenderness is detected, it is due to a sensitive deposit in the structures of the gluteal aspect of the posterosuperior spine. If the tenderness is over the inner point, it is probable that the superior ligaments of the sacroiliac joint are strained and sensitive. If the tenderness is increased by pressure backward on the anterosuperior aspect of the ilium and decreased by pulling forward the crest from behind, this is positive proof that it is caused by the sensitive ligaments.
292. **Mercedes-Benz sign**, shadows shaped like the logo of the Mercedes-Benz automobile, seen on radiographs of the gallbladder; they indicate the presence of gas-filled fissures within gallstones, although the gallstones themselves may not be visible.
293. **Mexican hat sign**, a shadow resembling a large-brimmed Mexican hat, seen on a radiograph of the colon; it represents the filling defect caused by a pedunculated polyp on the inferior wall.
294. **Minor's sign**, the method of rising from a sitting position characteristic of the patient with sciatica; he supports himself on the healthy side, placing one hand on the back, bending the affected leg and balancing on the healthy leg.

295. **Mirchamp's sign**, when a sapid substance, such as vinegar, is applied to the mucous membrane of the tongue, a painful reflex secretion of saliva in the gland about to be affected is indicative of sialadenitis, e.g., mumps.
296. **Möbius' sign**, **Moebius' sign**, inability to keep the eyeballs converged due to insufficiency of the internal rectus muscles; a manifestation of Graves' orbitopathy.
297. **Morquio's sign**, the patient lying supine resists all attempts to raise the trunk to a sitting posture until the legs are passively flexed; noticed in epidemic poliomyelitis.
298. **Moschcowitz's sign**, see under test.
299. **Mosler's sign**, sternal tenderness in acute myeloblastic leukemia.
300. **moulage sign**, a waxy cast appearance of bowel segments, a radiographic sign of celiac disease.
301. **Müller's sign**, a sign of aortic insufficiency consisting of pulsation of the uvula and redness of the tonsils and velum palati, occurring synchronously with the action of the heart.
302. **Munson's sign**, abnormal bulging of the lower lid when the patient rolls his eyes downward, caused by abnormal curvature of the cornea (keratoconus).
303. **Murphy's sign**, a sign of gallbladder disease consisting of interruption of the patient's deep inspiration when the physician's fingers are pressed deeply beneath the right costal arch, below the hepatic margin.
304. **Musset's sign**, rhythmical jerking movement of the head; seen in cases of aortic aneurysm and aortic insufficiency.
305. **Myerson's sign**, ready induction of blepharospasm when the frontalis muscle is tapped, a sign of Parkinson's disease.
306. **neck sign**, Brudzinski's s. (def. 1).
307. **Negro's sign**, cogwheel rigidity.
308. **Neri's sign**, 1. a sign of organic hemiplegia, consisting in the spontaneous bending of the knee of the affected side as the leg is passively lifted, the patient being in the dorsal position. 2. with the patient standing, forward bending of the trunk will cause flexion of the knee on the affected side in lumbosacral and iliosacral lesions.
309. **Neon sign**, A luminous graphic sign made by passing electric current through neon gas (typically contained in glass tubing bended in the form of graphics or text characters).
310. **niche sign**, Haudek's s.
311. **Nicoladoni's sign**, Branham's s.
312. **Nikolsky's sign**, ready separation of the outer layer of the epidermis from the basal layer with sloughing of the skin produced by minor trauma, such as by exerting a sliding or rubbing pressure on the area involved, which may occur in pemphigus and in other conditions such as certain hereditary blistering skin diseases, scalded skin syndrome, adult toxic epidermal necrolysis, and thermal burns.
313. **Ober's sign**, see under test.
314. **objective sign**, one that can be seen, heard, or felt by the diagnostician; called also physical s.
315. **obturator sign**, 1. hypogastric or adductor pain elicited by passive internal rotation of the flexed thigh, due to contact between an inflammatory process and the internal obturator muscle; a sign of appendicitis. 2. Hefke-Turner s.
316. **Oliver's sign**, tracheal tugging; see under tugging.
317. **Oppenheim's sign**, see under reflex.
318. **orbicularis sign**, in hemiplegia, inability to close the eye on the paralyzed side without closing the other.
319. **Ortolani's sign**, the presence of a palpable click in and out as the hip is reduced by abduction and dislocated by adduction in congenital dislocation of the hip; called also Ortolani's click.
320. **Osler's sign**, small, painful, erythematous swellings (Osler's nodes) in the skin of the hands and feet, pathognomonic of subacute bacterial endocarditis.
321. **palmoplantar sign**, Filipovitch's s.
322. **Parkinson's sign**, see under facies.

323. **Parrot's sign**, 1. ciliospinal reflex. 2. bony nodes on the outer table of the skull of infants with congenital syphilis, so that it has a hot cross bun or buttock shape; called also Parrot's nodes, hot cross bun skull, and natiform skull.
324. **Pastia's sign**, see under line.
325. **patent bronchus sign**, the radiologic finding of an unobstructed bronchus supplying a collapsed lung, lobe, or segment.
326. **Patrick's sign**, see under test.
327. **Pende's sign**, André Thomas s.
328. **Perez's sign**, a friction sound heard over the sternum when the patient raises and drops his arms; a sign of mediastinal tumor or of aneurysm of the arch of the aorta.
329. **peroneal sign**, Lust's phenomenon.
330. **Pfuhl's sign**, inspiration increases the force of flow in paracentesis in the case of subphrenic abscess, but lessens it in the case of pyopneumothorax. This distinction is lost when the diaphragm is paralyzed.
331. **physical sign**, objective s.
332. **Piltz's sign**, 1. attention reflex of pupil; see under reflex. 2. orbicularis pupillary reflex.
333. **Pins' sign**, Ewart's s.
334. **Piotrowski's sign**, percussion of the anterior tibialis muscle produces dorsal flexion and supination of the foot. When this reflex is excessive it indicates organic disease of the central nervous system. Called also anticus s. or reflex.
335. **Piskacek's sign**, asymmetrical enlargement of the corpus uteri due to enlargement of the pregnant uterus in the cornual region, usually over the site of implantation.
336. **Pitres' sign**, hypoesthesia of the scrotum and testes in tabes dorsalis.
337. **pivot shift sign**, see under phenomenon.
338. **placental sign**, implantation bleeding.
339. **Plummer's sign**, inability to step up onto a chair or to walk up steps, seen in Graves' disease and other forms of hyperthyroidism.
340. **Pool-Schlesinger sign**, Schlesinger's s.
341. **Porter's sign**, tracheal tugging; see under tugging.
342. **posterior drawer sign**, see under test.
343. **Potain's sign**, 1. extension of percussion dullness over the arch of the aorta, in dilatation of the aorta, from the manubrium to the third costal cartilage on the right-hand side. 2. timbre métallique.
344. **Prehn's sign**, elevation and support of the scrotum will relieve the pain in epididymo-orchitis, but not in torsion of the testicle.
345. **Prévost's sign**, conjugate deviation of the head and eyes, the eyes looking toward the affected hemisphere and away from the palsied extremities; seen in hemiplegia.
346. **pronation sign**, 1. Babinski's s. (def. 5). 2. pronation of the forearm caused by passive flexion, seen in hemiplegia; called also Strümpell's s.
347. **pseudo-Babinski's sign**, in poliomyelitis the Babinski reflex is modified so that only the big toe is extended, because all the foot muscles except the dorsiflexors of the big toe are paralyzed.
348. **pseudo-Graefe's sign**, slow descent of the upper lid on looking down, and quick ascent on looking up; seen in conditions other than Graves' disease.
349. **psoas sign**, flexion of or pain on hyperextension of the hip due to contact between an inflammatory process and the psoas muscle; a sign often seen in appendicitis. Called also Cope's s.
350. **puddle sign**, in examination for ascites, a method for detecting free fluid in the abdominal cavity. The patient lies prone for five minutes, then rises to his hands and knees. While the examiner lightly flicks a finger against one flank, a Bowles stethoscope is moved slowly from the most dependent part of the abdomen to the flank. That part of the ventral abdomen containing the fluid "puddle" shows a loss of high-frequency

- vibration, which will be detected as soon as the edge of the fluid is reached, indicating the amount of fluid.
351. **pyramid sign, pyramidal sign**, any sign pointing to disease of the pyramidal tract.
 352. **Quant's sign**, a T-shaped depression in the occipital bone, sometimes seen in rickets.
 353. **Queckenstedt's sign**, when the veins in the neck are compressed on one or both sides, in healthy persons there is a rapid rise in the pressure of the cerebrospinal fluid, which returns quickly to normal when pressure is taken off the neck. When there is a block in the vertebral canal the pressure of the cerebrospinal fluid is affected little or not at all by this maneuver. Called also Queckenstedt's phenomenon or test.
 354. **Quénu-Muret sign**, in aneurysm, the main artery of the limb is compressed and then a puncture is made at the periphery; if blood flows, the collateral circulation is probably established.
 355. **Quincke's sign**, see under pulse.
 356. **radialis sign**, inability to close the fist without marked dorsal extension of the wrist, seen in hemiplegia; called also Strümpell's s.
 357. **Radovici's sign**, palm-chin reflex.
 358. **Ramond's sign**, rigidity of the erector spinae muscle indicative of pleurisy with effusion; the rigidity relaxes when the effusion becomes purulent.
 359. **Raynaud's sign**, acrocyanosis.
 360. **Remak's sign**, see under symptom.
 361. **reservoir sign**, the ability of a patient to produce cerebrospinal fluid rhinorrhea at will by moving the head, indicating presence of a fistula with pooling in a paranasal sinus.
 362. **reversed three sign**, a pair of indentations, one on either side of the aortic knuckle, seen on barium contrast imaging of the esophagus and representing mirror images of a figure three sign; it signifies coarctation of the aorta. Called also E s.
 363. **Revilliod's sign**, orbicularis s.
 364. **Riesman's sign**, 1. Snellen's s. 2. softening of the eyeball in diabetic coma.
 365. **Robertson's sign**, 1. fibrillary contraction of the pectoralis muscle over the cardiac area in approaching death from heart disease. 2. absence of pupillary dilatation on pressure over alleged painful areas in malingering. 3. in ascites, fullness and tension in the patient's flanks, felt by the examiner with the patient supine.
 366. **Rocher's sign**, in torsion of the testis, the epididymis cannot be distinguished from the body of the testis, whereas in epididymitis the body of the testis can be felt in the enlarged crescent of the epididymis.
 367. **Romaña's sign**, unilateral ophthalmia with palpebral edema, conjunctivitis, and swelling of regional lymph glands as a sign of Chagas' disease.
 368. **Romberg's sign**, swaying of the body or falling when standing with the feet close together and the eyes closed; the result of loss of joint position sense, seen in tabes dorsalis and other diseases affecting the posterior columns. Called also rombergism, Brauch-Romberg symptom, and Romberg-Howship symptom; see also Romberg test, under test.
 369. **Rommelaere's sign**, an abnormally small proportion of normal phosphates and of sodium chloride in the urine in cancerous cachexia.
 370. **rope sign**, acute angulation between chin and larynx, due to weakness of hyoid muscles, noted in bulbar poliomyelitis.
 371. **Rosenbach's sign**, 1. absence of the abdominal skin reflex in inflammatory disease of the intestines. 2. absence of the abdominal skin reflex in pinching the skin of the abdomen on the paralyzed side in hemiplegia.
 372. **Rossolimo's sign**, see under reflex.
 373. **Rotch's sign**, dullness on percussion of the right fifth intercostal space, a sign of pericardial effusion.
 374. **Rovighi's sign**, a fremitus felt on percussion and palpation of a superficial hepatic hydatid cyst.

375. **Rovsing's sign**, pressure on the left side over the point corresponding to McBurney's point will elicit the typical pain at McBurney's point in appendicitis.
376. **Ruggeri's sign**, see under *reflex*.
377. **Rumpel-Leede sign**, see under *phenomenon*.
378. **Rust's sign**, see under *phenomenon*.
379. **Saenger's sign**, a light reflex of the pupil that has ceased returns after a short stay in the dark; observed in cerebral syphilis but not in tabes dorsalis.
380. **Sansom's sign**, 1. marked increase of the area of dullness in the second and third intercostal spaces, due to pericardial effusion. 2. a rhythmical murmur heard with a stethoscope applied to the lips in aneurysm of the thoracic aorta.
381. **Saunders' sign**, on wide opening of the mouth there take place in children associated movements of the hand consisting of opening of the hand and extension and separation of the fingers; called also *mouth-and-hand synkinesia*.
382. **Schepelmann's sign**, in dry pleurisy, the pain is increased when the patient bends his body toward the normal side, whereas in intercostal neuralgia it is increased by bending toward the affected side.
383. **Schick's sign**, stridor heard on expiration in an infant with tuberculosis involving the bronchial glands.
384. **Schlesinger's sign**, in tetany, if the patient's leg is held at the knee joint and flexed strongly at the hip joint, there will follow within a short time an extensor spasm at the knee joint, with extreme supination of the foot. Called also *Pool's* or *Schlesinger's phenomenon*.
385. **Schultze's sign**, **Schultze-Chvostek sign**, **Chvostek's s.**
386. **Schwartz's sign**, a pink blush behind the tympanic membrane, sometimes seen in otosclerosis because of hyperemia of the mucous membrane around the promontory.
387. **scimitar sign**, on a radiograph of the chest, a scimitar-shaped shadow to the right of the lower border of the heart, representing the anomalous vein of the scimitar syndrome.
388. **Séguin's sign**, *Séguin's signal symptom*; see under *symptom*.
389. **Seidel's sign**, see under *scotoma*.
390. **setting-sun sign**, downward deviation of the eyes, so that each iris appears to "set" beneath the lower lid, with white sclera exposed between it and the upper lid; indicative of intracranial pressure (hemorrhage or meningoependymitis), hydrocephalus, or pineal tumor.



391. **Shibley's sign**, in the presence of consolidation of the lung or a collection of fluid in the pleural cavity, all spoken vowels are heard through the stethoscope as "ah."
392. **Siegert's sign**, in Down's syndrome, the little fingers are short and curved inward.
393. **Silex's sign**, furrows radiating from the mouth in congenital syphilis.
394. **Simon's sign**, 1. [C. E. *Simon*] retraction or fixation of the umbilicus during inspiration. 2. [J. *Simon*] absence of the usual correlation between the movements of the diaphragm and thorax; seen in beginning meningitis.
395. **Sisto's sign**, constant crying as a sign of congenital syphilis in infancy.
396. **Skoda's sign**, *skodaic resonance*.

397. **Smith's sign**, a murmur heard in cases of enlarged bronchial glands on auscultation over the manubrium with the patient's head thrown back.
398. **Snellen's sign**, the bruit heard with a stethoscope over the closed eye in Graves' disease; see also Graves' orbitopathy, under orbitopathy.
399. **Soto-Hall sign**, with the patient flat on his back, on flexion of the spine beginning at the neck and going downward, pain will be felt at the site of the lesion in back abnormalities.
400. **Souques' sign**, 1. when the patient seated in a chair is suddenly thrown back, the lower extremities do not extend normally or otherwise attempt to counteract the loss of balance; it indicates advanced striatal disease. 2. see under phenomenon.
401. **Spalding's sign**, in the x-ray film of the fetus in utero, overriding of the bones of the vault of the skull indicates death of the fetus.
402. **spinal sign**, tonic contraction of the spinal muscles on the diseased side in pleurisy.
403. **spine sign**, disinclination to flex the spine anteriorly on account of pain; seen in poliomyelitis.
404. **square root sign**, in constrictive pericarditis, the diastolic level of the right ventricular pressure curve is initially normal but rapidly rises abnormally.
405. **stairs sign**, difficulty in descending a stairway in tabes dorsalis.
406. **Stellwag's sign**, a sign of Graves' orbitopathy: infrequent and incomplete blinking accompanied by Dalrymple's sign (retraction of the upper eyelids producing apparent widening of the palpebral opening).
407. **Sternberg's sign**, sensitiveness to palpation of the muscles of the shoulder girdle in pleurisy.
408. **Stewart-Holmes sign**, rebound phenomenon.
409. **Stierlin's sign**, absence of the normal shadow on a radiographic image of the colon after a barium enema, due to an indurating or ulcerating process such as tuberculosis of the cecum or colon.
410. **Strauss' sign**, increase of fat following the use of fatty foods in chylous ascites.
411. **string sign**, 1. in radiography of the colon, a stringlike configuration of contrast material through a filling defect; called also Kantor's s. 2. the stringing out of tubules, observed on pulling the tissues of an intact testis or one in which there is active spermatogenesis, a phenomenon which is prevented by the fibrosis and hyalinization about the tubules when the testis is atrophic.
412. **string of beads sign**, a series of round shadows resembling a string of beads or pearls, seen on a radiograph of the small intestine, indicating bubbles of trapped gas surrounded by the fluid of an obstructed and distended bowel.
413. **Strümpell's sign**, 1. tibialis s. 2. radialis s. 3. pronation s. (def. 2).
414. **Strunsky's sign**, a sign for detecting lesions of the anterior arch of the foot. The examiner grasps the toes and flexes them suddenly. This procedure is painless in the normal foot, but causes pain if there is inflammation of the anterior arch.
415. **Suker's sign**, deficient complementary fixation in lateral eye rotation, one manifestation of Graves' orbitopathy.
416. **Sumner's sign**, on gentle palpation of the iliac fossa, a slight increase in tonus of the abdominal muscles may indicate appendicitis, stone in the ureter or kidney, or a twisted pedicle of an ovarian cyst.
417. **swinging flashlight sign**, Marcus Gunn's pupillary phenomenon.
418. **Tay's sign**, see cherry-red spot, under spot.
419. **Theimich's lip sign**, a protrusion or pouting of the lips elicited by tapping the orbicularis oris muscle.
420. **Thomas' sign**, 1. [Hugh Owen *Thomas*] the flexion deformity seen in a hip in the Thomas test. 2. [André *Thomas*] André Thomas s.
421. **Thomson's sign**, Pastia's lines.
422. **Thornton's sign**, severe pain in the region of the flanks in nephrolithiasis.
423. **three sign**, figure three s.
424. **Throckmorton's sign**, see under reflex.

425. **tibialis sign**, dorsal flexion of the foot when the thigh is drawn up toward the body; seen in spastic paralysis of the lower limb. Called also Strümpell's s. or phenomenon and anterior tibial s.
426. **Tinel's sign**, a tingling sensation in the distal end of a limb when percussion is made over the site of a divided nerve. It indicates a partial lesion or the beginning regeneration of the nerve. Called also DTP s., formication s., and distal tingling on percussion.
427. **toe sign**, Babinski's reflex.
428. **Tournay's sign**, unilateral dilatation of the pupil of the abducting eye on extreme lateral fixation.
429. **Traube's sign**, a loud sound like a pistol shot heard in auscultation over the femoral arteries in aortic regurgitation. Called also pistol-shot sound.
430. **Trendelenburg's sign**, Trendelenburg's test (def. 2).
431. **trepidation sign**, patellar clonus.
432. **Tresilian's sign**, a reddish appearance in Stensen's duct in mumps.
433. **Trimadeau's sign**, if the dilatation above an esophageal stricture is conic, the stricture is fibrous; if cup shaped, the stricture is malignant.
434. **Troisier's sign**, signal node.
435. **Trousseau's sign**, 1. see under phenomenon. 2. tache cérébrale.
436. **Turner's sign**, discoloration (bruising) and induration of the skin of the costovertebral angle caused by extravasation of blood in acute hemorrhagic pancreatitis.
437. **Tury'n's sign**, in sciatica, if the patient's great toe is bent dorsally, pain will be felt in the gluteal region.
438. **twin peak sign**, a sonographic sign of dichorionic twinning consisting of a triangular zone whose echotexture is similar to that of the placenta, wider at the chorionic surface of the placenta and tapering to a point within the intertwin membrane.
439. **Unschuld's sign**, a tendency to cramp in the calves of the legs; a nonspecific early indication of diabetes.
440. **Vanzetti's sign**, in sciatica the pelvis is always horizontal in spite of scoliosis, but in other lesions with scoliosis the pelvis is inclined.
441. **vein sign**, a bluish cord along the midaxillary line formed by the swollen junction of the thoracic and superficial epigastric vein; seen in tuberculosis involving the bronchial glands and in superior vena cava obstruction.
442. **vital signs**, the pulse, respiration, and temperature.
443. **von Graefe's sign**, Graefe's s.
444. **Wartenberg's sign**, 1. a sign of ulnar palsy, consisting of a position of abduction assumed by the little finger. 2. reduction or absence of the pendulum movements of the arm in walking; seen in patients with cerebellar disease.
445. **Weber's sign**, see under syndrome.
446. **Wegner's sign**, a broadened, discolored appearance of the epiphyseal line in infants who have died from congenital syphilis.
447. **Weill's sign**, absence of expansion in the subclavicular region of the affected side in infantile pneumonia.
448. **Wernicke's sign**, hemiopic pupillary reaction.
449. **Westermarck's sign**, transient clearing (avascularity) of the normal radiologic shadow of pulmonary tissue distal to a pulmonary embolism.
450. **Westphal's sign**, loss of the knee jerk in tabes dorsalis.
451. **Widowitz's sign**, protrusion of the eyeballs and sluggish movements of the eyeballs and eyelids seen in diphtheritic paralysis.
452. **Wilder's sign**, an early sign of Graves' orbitopathy, consisting of a slight twitch of the eyeball when it changes its movement from adduction to abduction or vice versa.
453. **Williamson's sign**, markedly diminished blood pressure in the leg as compared with that in the arm on the same side; seen in pneumothorax and pleural effusion.
454. **Wimberger's sign**, symmetrical erosions of the proximal tibia seen radiographically in infants with congenital syphilis.

455. **Winterbottom's sign**, enlargement of posterior cervical lymph nodes in African trypanosomiasis.
456. **Wood's sign**, relaxation of the orbicularis muscle, fixation of the eyeball, and divergent strabismus, indicative of profound anesthesia.