



Case Report

Volume 17 Issue 2 - November 2019
DOI: 10.19080/JGWH.2019.17.555960

J Gynecol Women's Health

Copyright © All rights are reserved by Tobe S Momah

A Rare Case of *Tabes Dorsalis*



Tobe S Momah*, Bhavsar Parth, Jones Shawntiah, Berry Kelsey and Duff David

Department of Family Medicine, University of Mississippi Medical Center, USA

Submission: November 05, 2019; Published: November 12, 2019

*Corresponding author: Tobe S Momah, Department of Family Medicine, University of Mississippi Medical Center, USA

Background

Tabes Dorsalis has become a rare clinical presentation in cases of neuro syphilis since the advent of antibiotics. The recent surge in syphilis cases [1], however, has once again raised interest in the diagnosis and treatment of this rare clinical entity. In this case report, a case of *tabes dorsalis* in an 82 year African American female is presented. She, also, had right peroneal nerve mono neuropathy that challenged the clinical diagnosis of *tabes dorsalis* and complicated its management.

Keywords: Emergency room; Patient's laboratory; Arterial duplex; Neurology; Magnetic Resonance; Cerebro Spinal; Serology returned; Physical therapy; *Tabes dorsalis*

Abbreviations: ER: Emergency Room; CT: Computerized Tomography; MRI: Magnetic Resonance Imaging; CSF: Cerebro Spinal Fluid; RPR: Rapid Plasma Reagin; EMG: Electromyography; PT: Physical Therapy

Case Report

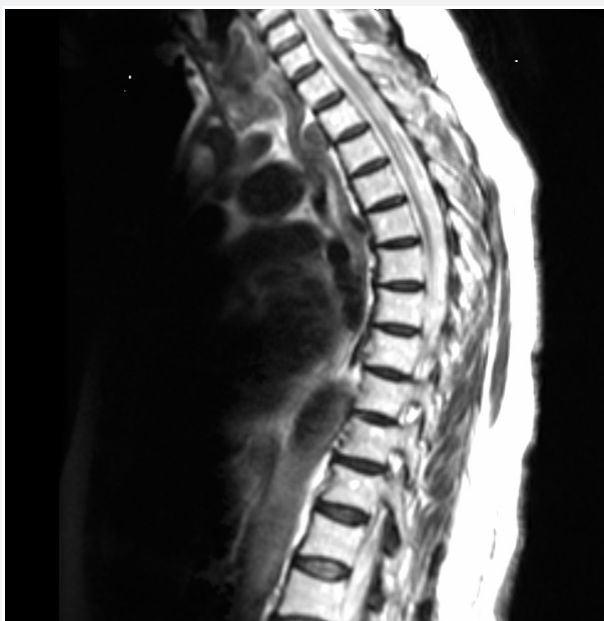

Figure 1: MRI of the thoracic spine indicated prominent Cerebro Spinal Fluid (CSF) density from T1 to T4 with no evidence of cord mass or tumor and CT of the right leg showed mild edema.

82 year old African American female presented to the Emergency room (ER) with complaints of right lower extremity weakness and swelling for two weeks. She states the episode started suddenly as she left her physician's office after treatment for an infection in the bladder. She denies any trauma or fall, and states that there were no accompanying signs or symptoms like short

ness of breath, chest pain or loss of consciousness. Patient's laboratory values were significant for low copper (743mcg/l) and thrombocytopenia (64,000k/UL).

Patient was assessed in ER and determined to have impaired sensation in right lower extremity with inability to move the right leg in any direction. She was evaluated with a venous duplex, arterial duplex, Computerized Tomography (CT) and Magnetic Resonance Imaging (MRI) of the right leg which were unremarkable. MRI of the lumbar spine indicated a moderate spinal canal narrowing at L4/5 and S1 due to posterior disc bulge and osteo arthropathy. MRI of the thoracic spine indicated prominent Cerebro Spinal Fluid (CSF) density from T1 to T4 with no evidence of cord mass or tumor (figure 1) and CT of the right leg showed mild edema.

A neurology consult was placed and a lumbar puncture was done by interventional radiology. The results were unremarkable, but serum Rapid Plasma Reagin (RPR) serology returned on day two with a titer of 1:16. A decision was made by Infectious disease and Neurology, in collaboration with the primary care team, to start Intravenous Penicillin G three million units every four hours for fourteen days. An electromyography (EMG) of the right leg, done after commencement of treatment, demonstrated right peroneal mono neuropathy. In the course of her treatment, after collaboration with physical therapy (PT), patient demonstrated improvement in the use of her right lower extremity and was able to bear more weight on it as a result. She was discharged with home PT to follow up with Primary Care Physician (Table 1).

Table 1: EMG Summary Table.

EMG Summary Table									
Muscle	Spontaneous				MUAP			Recruitment	
	IA	Fib	PSW	Fasc	Amp	Dur.	Poly	Pattern	Other
R.Tibialis anterior	N	None	None	None	2+	2+	1+	Reduced	-
R. Gastrocnemius (Medical head)	N	None	None	None	N	N	N	N	-
R. Extensor hallucis longus	Increased	1+	1+	None					
R. Vastus lateralis	N	None	None	None	N	N	N	N	-
R. Biceps femoris (short head)	N	None	None	None	N	N	N	N	-

Discussion

According to the CDC, preliminary data from 2016 indicated an increase in syphilis infections at all stages, including Neurosyphilis [2]. This latter stage of syphilis encompasses *tabes dorsalis*, which is a form of neurosyphilis that is characterized by degeneration of the nerves in the dorsal columns of the spinal cord with clinical signs and symptoms consistent with late neurologic manifestations of syphilis including general paresis, ataxic wide-based gait, paresthesia, loss of sensation and position sense, deep pain, dementia, and joint degeneration [3].

The disease is diagnosed majorly by clinical symptoms and signs, and usually associated with a positive serum RPR. In 30-40% of *tabes dorsalis* cases, however, the CSF is Venereal Disease Research Laboratory (VDRL) negative [4] (as seen in our case), thus making such cases difficult to diagnose. The diagnosis of *tabes dorsalis* must be therefore considered whenever a patient presents with any abnormal neurological finding but without a clear etiology.

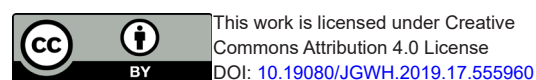
The MRI findings on the thoracic spine of the patient reported here are novel, because these findings are rarely reported in the literature. The first report of MRI changes in a *tabes dorsalis* patient showed cord atrophy and intra-medullary hyper intensity T2-weighted images [5] which are similar to the findings of

prominent CSF density (between T1 and T4) seen in our patient. These findings, coupled with the EMG positivity of a right peroneal nerve mono neuropathy, mark our case as unique.

With the recent resurgence of syphilis cases in the United States,1 making a diagnosis of *tabes dorsalis* may no longer be a back burner differential for clinicians. In cases such as ours, with unexplained extremity paresis, a high index of suspicion is warranted. The presence of this or other signs and symptoms of *tabes dorsalis*, in a patient with positive serological tests for treponemal and non-treponemal labs, makes further work-up for *tabes dorsalis* necessary and its treatment inevitable.

References

1. Call to action (2017) Let's work together to stem the tide of rising syphilis in the United States. Centers for Disease Control and Prevention. Sexually Transmitted Diseases Treatment Guidelines, pp. 1-12.
2. Syphilis (*Treponema pallidum*) 2018 Case Definition (2018) Centers for Disease Control and Prevention Office of Public Health Scientific Services (OPHSS) Center for Surveillance, Epidemiology, and Laboratory Services (CELS), USA.
3. Olry R, Haines DE (2018) Tabes Dorsalis: "Not, at all, "elementary my dear Watson. J Hist Neurosci 27(2): 198-203.
4. Heneao-Martinez A, Johnson SC (2014) Diagnostic tests for syphilis. Neurol Clin Pract 4(2): 114-122.
5. Pandey S (2011) Magnetic resonance imaging of the spinal cord in a man with tabes dorsalis. J Spinal cord Med 34(6): 609-611.



This work is licensed under Creative Commons Attribution 4.0 License
DOI: 10.19080/JGWH.2019.17.555960

Your next submission with Juniper Publishers will reach you the below assets

- Quality Editorial service
- Swift Peer Review
- Reprints availability
- E-prints Service
- Manuscript Podcast for convenient understanding
- Global attainment for your research
- Manuscript accessibility in different formats (Pdf, E-pub, Full Ttext, Audio)
- Unceasing customer service

Track the below URL for one-step submission
<https://juniperpublishers.com/online-submission.php>