



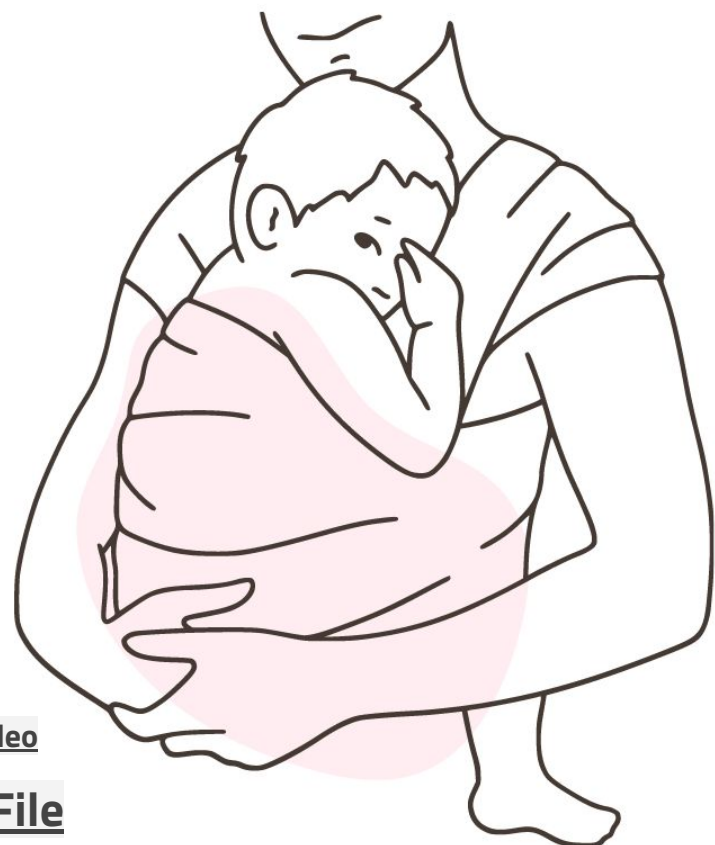Reviewed By
RAAOUM M. JABOR



Abnormal Presentation

Objectives:

- Define fetal malpresentation.
- List the predisposing factors for malpresentations.
- Identify the types of fetal malpresentation and the recommended delivery options for each



- Slides
- **Important**
- **Golden notes**
- Extra
- **Doctor's notes**
- **Previous Doctor's notes**
- **Reference**

[Kaplan Video](#)

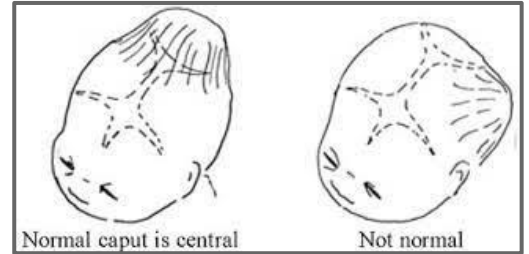
[Editing File](#)

Anatomic Characteristics of Fetal Head

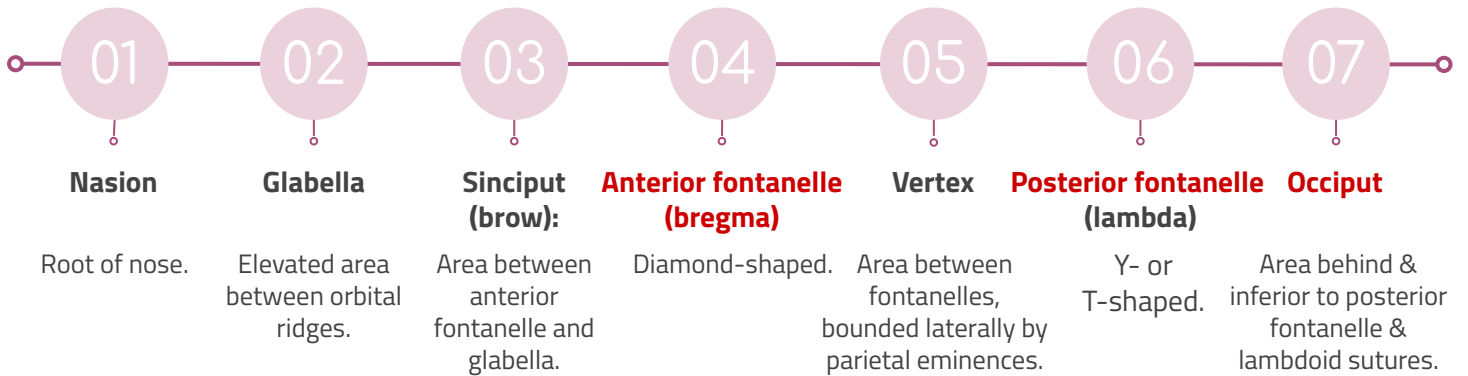


Fetal Head: Can't be compressed, unlike the other parts of the fetus.

- Successful vaginal delivery requires accommodation (molding + rotation) of descending fetal head to maternal pelvis.
- **Head:** the largest and least compressible part of the fetus → the most important part, in both cephalic and breech presentation (obstetric viewpoint).
- **Fetal skull consists of:** base + vault (cranium).
- **Cranial bones at birth:** thin - weakly ossified - easily compressible - interconnected only by membranes → overlap under pressure + **molding** (change shape to conform to maternal pelvis).

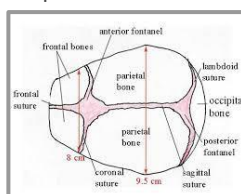
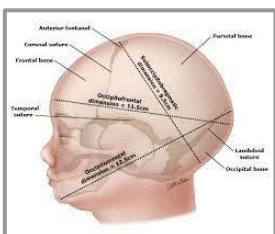


Landmarks of fetal skull, from front to back:



Diameters of fetal skull:

- **Suboccipitobregmatic:**
 - The presenting anteroposterior diameter when head is well flexed.
 - **Position/presentation:** occipitotransverse - occipitoanterior.
 - **Extension:** undersurface of occipital bone at the junction with the neck → center of anterior fontanelle.
 - **Length:** 9.5 cm.
- **Submentobregmatic:**
 - The presenting anteroposterior diameter in face presentations.
 - **Position/presentation:** face presentations.
 - **Extension:** junction of the neck & lower jaw → center of anterior fontanelle.
 - **Length:** 9.5 cm.
- **Occipitofrontal:**
 - The presenting anteroposterior diameter when head is deflexed.
 - **Position/presentation:** occipitoposterior presentation.
 - **Extension:** external occipital protuberance → glabella.
 - **Length:** 11 cm.
- **Supraoccipitomenal:**
 - The longest anteroposterior diameter of head.
 - The presenting anteroposterior diameter in a brow presentation.
 - **Position/presentation:** brow presentation.
 - **Extension:** vertex → chin.
 - **Length:** 13.5 cm.
- **Biparietal:**
 - The largest transverse diameter.
 - Transverse diameter of fetal skull.
 - **Extension:** between the parietal bones.
 - **Length:** 9.5 cm.
- **Bitemporal:**
 - The shortest transverse diameter.
 - Transverse diameter of fetal skull.
 - **Extension:** between the temporal bones.
 - **Length:** 8 cm.
- **Average circumference of term fetal head in occipitofrontal plane:** 34.5 cm



Fetal Description

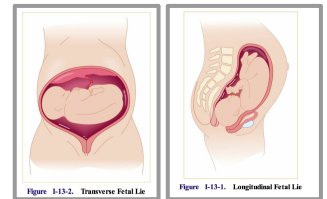
Fetal Description:

Fetal Presentation

- **Fetal presentation:** which part of the fetus occupies/*overlies* the pelvis or **maternal pelvic inlet**, felt during vaginal exam just above symphysis pubis with the right hand.
- **Classifications:**
 - **Cephalic presentation:** head (most common).
 - **Breech presentation:** buttocks or feet.
 - **Frank breech:** flexed hips + extended knees (*buttocks presenting*).
 - **Complete breech:** flexed thighs + flexed legs (*cannonball position*).
 - **Single footling breech:** one side flexed hip + other side extended knee (*one foot presenting*).
 - **Double footling breech:** thighs extended + legs extended (*feet presenting*).
 - **Shoulder presentation:** shoulder presentations + transverse or oblique lie.
 - **Compound presentation:** > 1 anatomical presenting part (*cephalic or breech presentation + extremity presentation*).

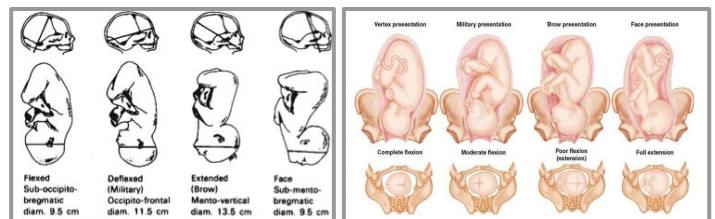
Fetal Lie

- **Fetal lie:** the relation of fetus **longitudinal axis** to mother longitudinal axis.
- **Classifications:**
 - **Longitudinal:** fetus and mother are in same vertical axis (**most common**).
 - **Oblique:** fetus at 45° angle to the mother.
 - **Transverse:** fetus at right angle to the mother (90°) → do c-section surgery.



Fetal Attitude

- **Fetal Attitude:** the relationship of the **different parts of baby** to each other.
- **Fetal Attitude:** the degree of extension - flexion of fetal head with cephalic presentation.
- **Usual/default attitude:** flexion.
- **Classification:**
 - **Vertex:** head is maximally flexed.
 - **Military:** head is partially flexed.
 - **Brow:** head is partially extended.
 - **Face:** head is maximally extended.
 - Mentum anterior face presentation.
 - Mentum posterior face presentation.



Fetal Position

- **Fetal position:** the relationship of a definite fetal part to the maternal bony pelvis.
- **Expression:** state whether the orientation part (occipital bone - sacrum - mentum) is anterior or posterior, left or right.
- **Vertex presentation landmark:** occipital bone.
- **Face presentation landmark:** mentum.
- **Brow presentation landmark:** frontal bone → c-section surgery indication.
- **Breech presentation landmark:** sacrum.
- **Most common position at delivery:** occiput anterior.

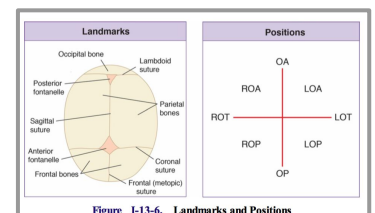


Figure 1-13-6. Landmarks and Positions

Malpresentation

> Malpresentation:

- **Fetus malpresentations in utero:** breech, face, and brow presentations.
- **Most common malpresentations:** breech presentation.
- **Incidence of face presentation:** 1 in 500 deliveries.
- **Incidence of brow presentation:** 1 in 1400 deliveries.
- **Rare malpresentations:** compound presentation - shoulder presentation.
 - Usually associated with **premature** births → **normal to have malpresentation** because of their normal size.

1. Breech Presentation

> Introduction:

- **Breech presentation:** when the fetal buttocks or lower extremities present into the maternal pelvis.
- Sitting baby.
- Pre-term, the fetus can be in breech position but once term is reached they normally rotate.
 - **Before 28 weeks:** 25% of fetuses are presenting as a breech.
 - **34 weeks:** most fetuses have assumed the vertex presentation position.
- Fetus grows → occupies more of the uterus → assume a vertex presentation to accommodate best to the uterus confines and shape.
- The **most common** abnormal fetal presentation and the most important.
- **Incidence:** 4% of all deliveries at term (>37 weeks).

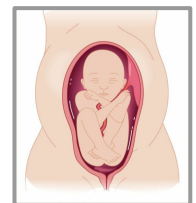> Classification: OSCE

01

**Complete Breech
(25%)**

Squat position:

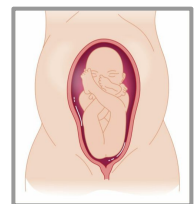
- Flexed both thighs.
- Flexed one or both knees.



02

**Frank Breech
(65%)**

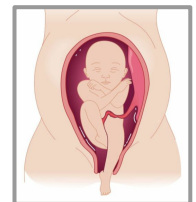- Flexed both thighs.
- Extended both knees.



03

**Footling / Incomplete
Breech (10%)**

- Extended one or both thighs.
- One or both knees or feet lying below buttocks (*foot is out*).



1. Breech Presentation

> Causes:

- **Major factor:** prematurity / **preterm** labor.
- **Low birthweight incidence (<2500 g):** 20 - 30% of all singleton breeches.
- **Structural anomalies incidence:** > 6% (2 - 3x that of a vertex).

Fetal

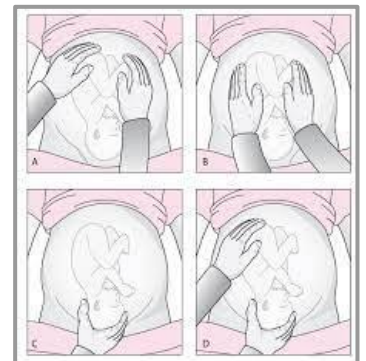- Hydrocephalus.
- Polyhydramnios → **moving a lot.**
- Oligohydramnios → **restricted movement.**
- **Placenta previa:** **low lying placenta.**
- Short umbilical cord
- Pelvic tumor → obstruct birth canal.

Maternal

- **Uterine anomalies:** bicornuate uterus.
 - **Bicornuate uterus:** a uterine malformation due to impairment in mullerian ducts fusion → **space abnormalities.**
- Fibroid uterus → **may occupy lower segment** → **restricting movement.**
- Multiple gestation.
- Contracted pelvis (small pelvis).

> Diagnosis:

- Often by **Leopold examination.**
 - Firm fetal head is palpated in the fundal region + softer, smaller breech occupies the lower uterine segment above symphysis pubis.
- **Frank breech:** fetal buttocks, anus, sacrum, and ischial tuberosities are palpated on vaginal examination.
- **Complete breech:** feet, ankles, and often buttocks are palpable through dilated cervix.
- **Incomplete breech:** one or both fetal feet palpated in vaginal examination, US required for definitive diagnosis.



> ★ Management: ★

Exclude Fetal and Uterine Anomalies:

- Look at the mother's pelvis + baby.
- Breech presentation suspected after 34 weeks → prenatal records + prior ultrasonic examinations reviewed for: uterine myomata - müllerian anomaly - fetal structural abnormality.
 - Suspicious results → do ultrasonic examination.

1. Breech Presentation

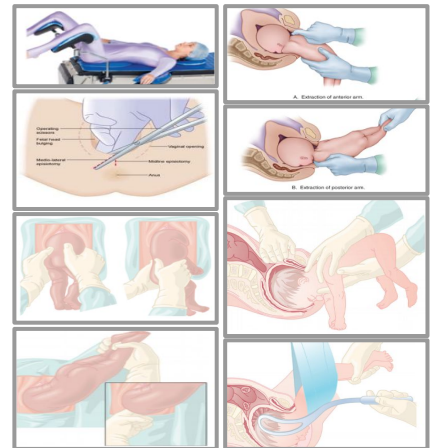
★ Management: ★

Vaginal Breech Delivery:

- **Randomized trials:** vaginal breech delivery was associated with ↑ perinatal mortality compared to planned cesarean.
 - **Before:** vaginal deliveries were performed in selected centers in patients who met strict criteria.
- **Current standard of care:** deliver **all breeches by cesarean** to avoid potential morbidities (umbilical cord prolapse - head entrapment - birth asphyxia - birth trauma).
- Breech presentation can present in a setting in which cesarean delivery is impossible / unsafe → assisted vaginal delivery of breech is an important practitioner skill.

Methodology:

1. Patient in lithotomy position → adequate exposure.
2. Fully dilated cervix (10 cm).
3. Buttocks protrudes through vulva → perform episiotomy.
4. Legs are delivered easily unless it is extended → flexed gently.
5. **Delivery of umbilicus:** small loop of cord is pulled down to feel pulsations.
6. Delivery of both arms first the anterior then the posterior.
7. Delivery of head: **don't rush it.**
8. Keep baby hanging to promote head flexion (*Burn Marshal manoeuvre*).
9. Jaw flexion + shoulder traction → to promote flexion (extended head won't pass).
10. Obstetrical forceps for the after coming head.

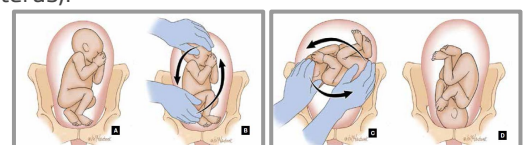


Criteria:

<p>Fetus must be in a frank or complete breech presentation. Gestational age should be at least 36 weeks. Estimated fetal weight should be between 2500 and 3800 g. Fetal head must be flexed. Maternal pelvis must be adequately large, as assessed by x-ray pelvimetry* or tested by prior delivery of a reasonably large baby.</p>	<p>There must be no other maternal or fetal indication for cesarean delivery. Anesthesiologist must be in attendance. Obstetrician must be experienced. Assistant must be scrubbed and prepared to guide the fetal head into the pelvis.</p>
<p>*Inlet: anteroposterior (AP) diameter ≥11.0 cm; transverse diameter ≥10.0 cm. Midpelvis: AP ≥11.5 cm, transverse diameter ≥10.0 cm.</p>	

External Cephalic Version (ECV):

- **External Cephalic Version:** a procedure in which obstetrician manually converts breech fetus to vertex presentation via external uterine manipulation under ultrasonic guidance.
- Considered **at term before labor onset.**
- Tendency for premature fetus to revert spontaneously to a breech presentation → not carried out before **36 - 37 weeks' gestation.**
- Small risk of placental abruption or cord compression → an equipped hospital for **emergency cesarean.**
- Patient should have an **intravenous access + nothing by mouth for 8 hours** before version attempt in case emergency delivery is necessary.
- **Immediate success rate:** 35 - 76%.
- ECV ↓ cesarean delivery rate, but didn't affect perinatal mortality rate.
- Only 2% of successful term versions revert to breech.
- **Potential/absolute contraindications:**
 - Any **absolute contraindication to labor** & vaginal birth regardless of fetal presentation (placenta previa - previous classical cesarean birth).
- **Not a contraindication, but limited evidence (that it is safe in this population):**
 - Prior **low transverse cesarean birth** → may rupture.
- **Other contraindications:** → ↓ likelihood of successful version and/or ↑ procedure fetal harm risk.
 - Severe oligohydramnios.
 - Nonreassuring fetal monitoring test results.
 - Hyperextended fetal head.
 - Significant fetal or uterine anomaly (hydrocephalus - septate uterus).
 - Placental abruption.
 - Ruptured membranes.
 - Active labor with fetal descent.
 - Multiple gestation.

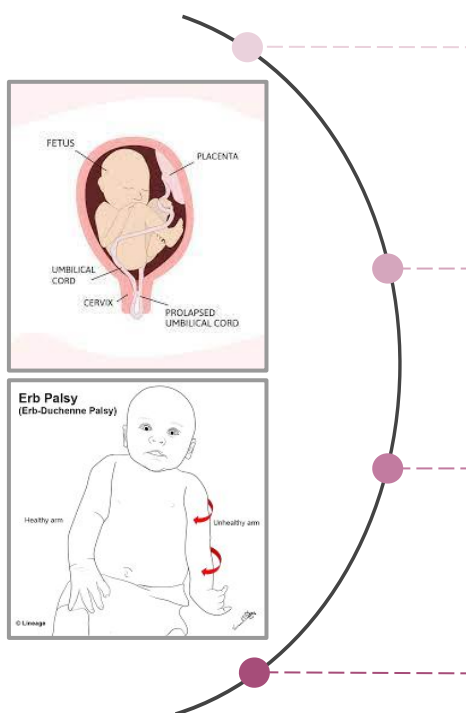
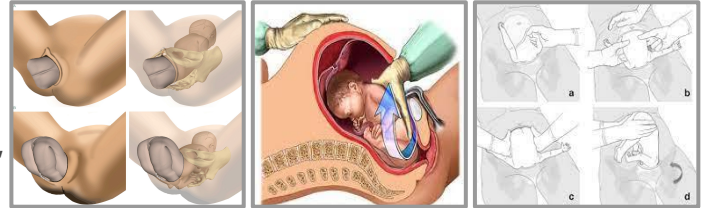


1. Breech Presentation

★ Management: ★

Cesarean Delivery:

- **During breech vaginal delivery:** successively larger parts of fetus deliver, with the largest part (head) delivering last.
 - **Very premature infant:** abdomen size < head size → lower extremities, abdomen, & trunk may deliver through an incompletely dilated cervix + fetal head trapped → fetal asphyxia + birth trauma.
- Head-abdominal size disparity → **premature** breech fetuses are preferentially delivered by **cesarean delivery**.
- Cesarean delivery is **currently preferred for both preterm and term breech infants**, although significant trauma can still occur if care is not taken with delivery of the arms and head.
- **Complications and Outcome:**



- **Even with optimal management, perinatal mortality:**
 - **Breech fetuses:** 25 per 1000 live births.
 - **Non Breech fetuses:** 12 - 16 per 1000 live births.
- **Perinatal mortality when prematurity & multiple gestations are excluded:**
 - **Breech fetuses:** significantly higher than for vertex fetuses.
- **Factors that contribute to ↑ perinatal morbidity & mortality:**
 - Lethal congenital anomalies. → Birth trauma.
 - Prematurity. → Asphyxia.
- Umbilical cord prolapse during labor or after coming head entrapment → asphyxia.
- Forceful traction is exerted on fetus → birth trauma.
 - **Can involve:** brachial plexus (*erb palsy*) - pharynx - liver.

2. Face Presentation

Introduction:

- **Face presentation:** when fetal **head is hyperextended** (complete extension) such that the fetal face, between the chin and orbits, is the presenting part.
- **During normal vertex delivery:** markedly flexed head + leading part is fetal occiput → pelvis entry.
- **Incidence:** 1 in 500 deliveries (**rare**).

Causes:

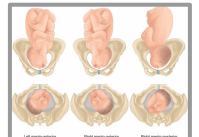
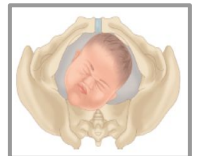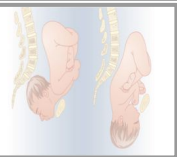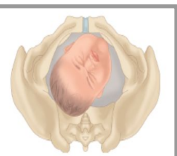- **Cause:** somewhat enigmatic/vague.
- **Mostly:** no etiologic factor is evident.
- **Causes of markedly extended head:**
 - Extreme prematurity.
 - High maternal parity.
 - Congenital anomalies (such as fetal goiter).

Diagnosis:

- Usually made with vaginal examination during labor.
 - **Findings:** soft tissues of fetal mouth & nose are adjacent to malar bones and orbital ridges.
- **Confirmed by:** sonography.
- Diagnosed in labor by palpating nose, mouth, and eyes on vaginal examination, **not by ultrasound**.
- **Anencephalic fetuses:** uniformly present face first → anencephaly must be ruled out if face presentation is suspected.

Classification:

- Labor proceeds → face descends to midplane → internal rotation of mentum transverse to vertical axis.
 - Final mentum transverse rotation occur after a significant period of maternal pushing → patience is necessary.
 - ≈ 50% of mentoposterior & mentotransverse presentations spontaneously rotate to a mentoanterior position.
- Position of presenting face is classified according to fetal chin (mentum) location.
 - Mentum **rotated anteriorly** under symphysis pubis → mentum anterior (60%).
 - Mentum **rotated posteriorly** → mentum posterior (25%).
 - Mentum persisted **transverse** → mentum transverse (15%).



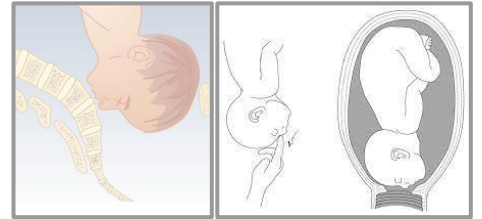
Management:

- Mechanism of face presentation labor is similar to vertex presentation in that the longest diameter (mentum to brow) enters pelvis transverse.
 - Spontaneous vaginal delivery or low forceps delivery occurs → perinatal morbidity & mortality for face presentations are similar to vertex presentations.
- **Mode of delivery:**
 - Mentum **anterior (mento-anterior)** → **head is delivered by flexion** (*baby's chin face mother's abdomen*) → **vaginal delivery** expected.
 - Forceps (not vacuum) can be applied to assist if prerequisites are met.
 - Mentum **posterior (mento-posterior)** → fetal head unable to extend farther to complete expulsive process → **vaginal delivery is not possible** → **cesarean delivery**.
 - Mentum **transverse** → **cesarean delivery**.

3. Brow Presentation

Introduction:

- **Brow Presentation:** when presenting part of the fetus is between the facial orbits and anterior fontanelle (*not fully extension like the face presentation*).
- **Presenting diameter:** supraoccipital diameter (much longer than presenting diameters of face or vertex presentations).
- **Presenting diameter: mento-vertical** (13.5 cm).
- Arises as a result of fetal head extension such that it is midway between flexion (*vertex presentation*) and hyperextension (*face presentation*).
- **Incidence:** 1 in 1400 deliveries (*very rare*).
- **Diagnosis: palpating anterior fontanelle**, supraorbital ridges & nose on vaginal examination.



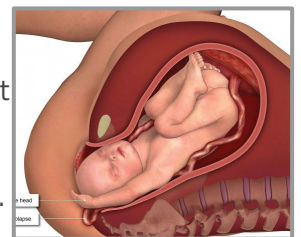
Management:

- Brow presentation is an unstable one → intrapartum management is expectant.
- 50 - 75% will convert to either a face presentation, through extension, or a vertex presentation, through flexion → subsequently deliver vaginally.
- Persistent brow presentation → large presenting diameter → impossible vaginal delivery (unless very small fetus or very large maternal pelvis) → **cesarean delivery**.
- **Delivery by: cesarean section** على طول!
- ↑ incidence of both prolonged labor (30 - 50%) + dysfunctional labor (30%).
- Perinatal morbidity & mortality are similar to vertex presentations.
- **Contraindicated!** midpelvic delivery and methods to convert the brow presentation to a vertex presentation (as with face presentations).

4. Compound Presentation

Introduction:

- **Compound presentation:** when a fetal extremity (*usually hand*) prolapses alongside the presenting part (*head*) and both parts enter the maternal pelvis at the same time.
- **Cause:** occurs more frequently with premature gestations.
- **Incidence of hand or arm prolapsing alongside fetal head:** 1 in 700 deliveries.



Management:

- **Management:** expectant.
- Usually the prolapsed part of fetus does not interfere with labor.
- If arm prolapses → wait to see if it moves out of the way as the head descends.
 - Arm doesn't move out of the way → arm may be gently pushed upward while head is simultaneously pushed downward by fundal pressure.
 - Complete extremity prolapses → fetus converts to shoulder presentation → cesarean delivery.

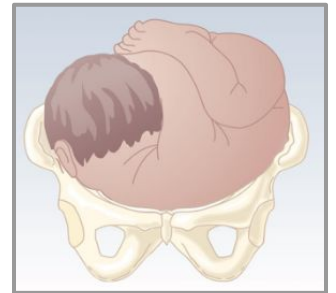
5. Shoulder Presentation

> Introduction:

- **Shoulder Presentation:** oblique or transverse lie in labor, where you can feel the baby's shoulder (*transverse is more common*).

> Causes:

- Women with high parity (uterus muscle have stretched from previous pregnancies).
- Placenta previa.
- Uterine anomalies.
- Pelvic tumor.



> Management:

- Diagnosed in early labor + intact membrane + no other pathology → **external cephalic version** can be tried (*in case of initiation of contraction*).
- Rupture of membranes → exclude cord prolapse (*because it may get out first*).
- Delivery of shoulder presentation labor with rupture membrane is by **caesarian section**.

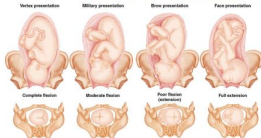439 Summary

Abnormal presentation (Fetal Malpresentation)

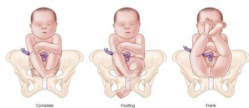General fetal description:

Fetal presentation: part of the fetus that overlies the maternal pelvic inlet

- **Cephalic presentation:** head present first (**most common presentation**)
 - Fetal attitude: degree of extension/flexion of the fetal head
 - Vertex: maximally flexed, **most common** (landmark: occipital bone)
 - Forehead/Military: partially flexed
 - Brow: partially extended (landmark: **frontal bone**)
 - Face: maximally extended (landmark: **mentum/fetal chin**)



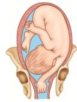- **Breech presentation:** feet or buttocks present first
 - **Complete:** hip and knee flexed (cannonball position)
 - **Footling:** hip of one leg is flexed and the knee of the other is extended
 - **Frank:** flexed hips and extended knees (buttocks presenting)



- **Shoulder presentation:** shoulder present first

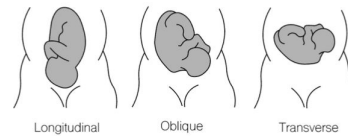


- **Compound presentation:** one or more of the limbs along with the head or the breech, both entering the pelvis at the same time



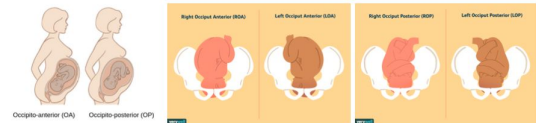Fetal lie: relation of longitudinal axis of the fetus to longitudinal axis of the mother.

- Longitudinal: fetus and mother are in same vertical axis
- Oblique: fetus at 45° angle to the mother
- **Transverse:** fetus at right angle to the mother (90°)



Fetal position: orientation of **fetal occiput** (back of baby's head) in relations to **maternal pelvis**

- Occiput anterior position:
 - Left occiput anterior (LOA): Fetal back faces the maternal left, anterior fontanelle faces the maternal right (**most common position**)
 - Right occiput anterior (ROA): Fetal back faces the maternal right, anterior fontanelle faces the maternal left
- Occiput posterior position: fetal occiput points towards the maternal sacral promontory



Malpresentation

Breech presentation: part of the fetus that overlies

- **Most common abnormal fetal presentation**
- Types: (see pics in previous page)
 - Complete: thighs and legs flexed
 - Footling: hip of one leg is flexed and the knee of the other is extended
 - Frank: flexed hips and extended knees (buttocks presenting)
- Causes:
 - **Preterm labor** (**most common/important cause**)
 - Maternal: uterine anomalies, fibroid, small pelvis
 - Fetal: **hydrocephalus**, polyhydramnios, oligohydramnios (restricted movement), **placenta previa**, **short umbilical cord**

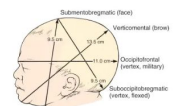
- **Management/mode of delivery:**

- **Cesarean section:** (the standard of care now in most practices)
- **Internal cephalic version:**
 - Fetus is rotated from a breech presentation or oblique/transverse lie to the cephalic presentation **by internal manipulation**.
 - Mainly used for delivery of a second twin who is breech, following a normal vaginal delivery of the first twin.
- **External cephalic version ECV:** A procedure in which the fetus is rotated from a breech presentation, or **oblique/transverse lie** to the cephalic presentation by **external manipulation**.
 - **Considered in breech presentation at term before the onset of labor.**
 - **Manual rotation is done ≥ 37 weeks**
 - **Before 37 weeks with breech presentation = wait for spontaneous version. Because of the tendency for premature fetus to revert spontaneously to a breech presentation**
 - Should be done in the theater with everything ready for C/S
 - If blood group of mother is RH negative, should receive anti-D immunoglobulin
 - **Contraindications:**
 - **Contracted/small pelvis**
 - Scar uterus, due to the risk of rupture
 - Primary gravida (difficult to perform) & multiple pregnancy
 - **Hypertensive patient**
 - **Placenta previa**
 - **Rh isoimmunization**
 - Fetal anatomical abnormalities, non-reassuring fetal status, oligohydramnios, antepartum hemorrhage, patient in active labor
 - **Complications:**
 - **Membrane rupture**
 - **Cord prolapse**
 - **Uterine rupture**
 - **Placental abruption**
 - **Asphyxia**
- **Vaginal breech delivery (video)**
 - **Complications:**
 - Cord prolapse
 - Lower limb fracture
 - Abdominal organ injuries

- Brachial plexus nerve injuries
- Difficulties in delivering the head and intracranial bleeding

Face (cephalic) presentation:

- Presenting diameter of the face is the **submentobregmatic**, which measures **9.5 cm**
- Positions:
 - Mentoanterior: chin/mentum facing anterior to symphysis pubis
 - Mentoposterior: chin/mentum facing posterior to symphysis pubis
- Causes:
 - Majority are unknown
 - Frequently: excessive tone of the extensor muscles of fetal neck
 - Rarely: tumor of the neck, thyroid, thymus gland and cord around the neck
- **Diagnosis:** in labor by palpating the nose, mouth, **chin**, and the eyes on vaginal examination



Mode of delivery:

- Mentoanterior: vaginal delivery **possible**
 - Mode of delivery: if the mentum rotates anteriorly under the symphysis pubis, vaginal delivery should be expected. **Forceps not vacuum, can be applied to assist if prerequisites are met**
- Mento posterior: vaginal delivery **impossible**
 - Mode of delivery: **must go for cesarean section**

Brow (cephalic) presentation:

- Presenting diameter is **mento-vertical 13.5cm**
- **Diagnosis:** in labor by palpating the anterior fontanelle, supraorbital ridges and nose on vaginal examination, **mouth and chin cannot be palpated**.
- **Mode of delivery:** **cesarean section**

Shoulder presentation:

- Oblique or transverse lie in labor
- Causes:
 - Multiple pregnancies; because the muscles of the uterus have stretched
 - Maternal: uterine anomalies, pelvic tumor
 - Fetal: placenta previa
- **Diagnosis:**
 - If diagnosed in early labor with intact membrane and no other pathology external cephalic version can be tried in case of initiation of contraction

439 Summary

- In case of rupture of the membranes exclude cord prolapse because it may get out first.
- **Mode of delivery:** if presented with membrane rupture → cesarean section

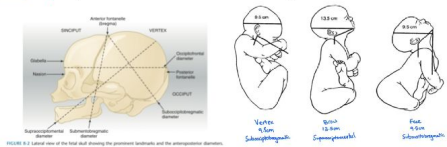


FIGURE 8-2 Lateral view of the fetal skull showing the greatest landmarks and the oblique diameters.

Quiz 439

Q4: which of the following is the most common type of abnormal presentation: :

- A. Shoulder presentation
- B. Face presentation
- C. Breech presentation
- D. Brow presentation

Q5: Regarding face presentation:

- A. This occurs in 1:250 labours.
- B. Mento-anterior presentation can be delivered vaginally
- C. Occurs due to complete flexion of the head
- D. Mento-posterior presentation can be delivered vaginally

Explanations:-

Q2: The majority of breech presentations resolve before 37 weeks' gestation, as the fetus is mobile with larger volumes of amniotic fluid. Since the patient is at 34 weeks' gestation, not in labor, and has no fetal complications, there is still a chance of spontaneous conversion to the cephalic position. Therefore, no intervention is required at this time and observation is sufficient. If a breech presentation does not resolve by 37 weeks' gestation, the patient has several options: external cephalic version (ECV) before spontaneous labor with a trial of vaginal birth (either normal vaginal delivery or breech delivery), followed by conversion to cesarean delivery if unsuccessful.

Q3: At 38 weeks' gestation, there is a low probability of spontaneous version to a cephalic presentation. Because breech delivery increases the risk of fetal asphyxia and delivery-related injury, this patient should be offered external cephalic version to try to rotate the fetus to a cephalic presentation before spontaneous labor.

Quiz

Question 1:

- The commonest cause of breech presentation is:
- A. Prematurity
 - B. Hydrocephalus
 - C. Placenta praevia
 - D. Polyhydramnios

Question 2:

- A 35-year-old woman, G4P3, at 34 weeks' gestation comes to the physician for a prenatal visit. She feels well. She does not note any contractions or fluid from her vagina. Her third child was delivered spontaneously at 35 weeks' gestation; pregnancy and delivery of her other two children were uncomplicated. Vital signs are normal. The abdomen is nontender and no contractions are felt. Pelvic examination shows a uterus consistent in size with 34 weeks' gestation. Ultrasonography shows the fetus in a breech presentation. The fetal heart rate is 148/min. Which of the following is the most appropriate next step in management?
- A. External Cephalic version
 - B. Assisted vaginal delivery
 - C. Observe
 - D. Cesarean delivery

Question 3:

- A 24-year-old primigravid woman at 38 weeks' gestation comes to the physician for a prenatal visit. At the last two prenatal visits, transabdominal ultrasound showed the fetus in breech presentation. no contractions are felt. The fetal rate tracing shows a baseline heart rate of 152/min and 2 accelerations over 10 minutes. Repeat ultrasound today shows a persistent breech presentation. The patient states that she would like to attempt a vaginal delivery. Which of the following is the most appropriate next step in management?
- A. Recommend cesarean delivery
 - B. Repeat ultrasound in one week
 - C. Offer external cephalic version
 - D. Offer internal podalic version

Question 4:

- Which of the following is the most common type of abnormal presentation?
- A. Shoulder presentation
 - B. Face presentation
 - C. Breech presentation
 - D. Brow presentation

Question 5:

- Which of the following is true regarding face presentation?
- A. This occurs in 1:250 labours.
 - B. Mento-anterior presentation can be delivered vaginally
 - C. Occurs due to complete flexion of the head
 - D. Mento-posterior presentation can be delivered vaginally

8	7	6	5	4
5	4	3	2	1

Reference

Fetal Malpresentation

Malpresentations of the fetus in utero include breech, face, and brow presentations, with breech the most common and face and brow occurring in about 1 in 500 and 1 in 1400 deliveries, respectively. Compound and shoulder presentations are rare, and usually associated with premature births.

BREECH PRESENTATION

Breech presentation occurs when the fetal buttocks or lower extremities present into the maternal pelvis. The incidence of breech presentation is 4% of all deliveries. Before 28 weeks, approximately 25% of fetuses are presenting as a breech. As the fetus grows and occupies more of the uterus, it tends to assume a vertex presentation to accommodate best to the confines and shape of the uterus. By 34 weeks' gestation, most fetuses have assumed the vertex presentation position.

Etiology

The major factor predisposing to breech presentation is prematurity. Approximately 20-30% of all singleton breeches are of low birth weight (<2500 g). However, fetal structural anomalies (e.g., hydrocephalus) may restrict the ability of the fetus to present as a vertex. In breech presentations, the incidence of structural anomalies is greater than 6%, or two to three times that of a vertex. Other etiologic factors include uterine anomalies (e.g., bicornuate uterus), multiple gestation, placenta previa, hydramnios, contracted maternal pelvis, and pelvic tumors that obstruct the birth canal.

Classification

There are three types of breech presentation: **frank, complete, and incomplete or footling** (Figure 13-5). **Frank breech** occurs when both fetal thighs are flexed and both lower extremities are extended at the knees. A **complete breech** has both thighs flexed and one or both knees flexed (sitting in a "squat" position). An **incomplete (or footling) breech** has one or both thighs extended and one or both knees or feet lying below the buttocks. At term, 65% of breech fetuses are frank, 25% are complete, and 10% are incomplete.

Diagnosis

The diagnosis of breech presentation can often be made by the **Leopold examination** (see Chapter 8), in which the firm fetal head is palpated in the fundal region and the softer, smaller breech occupies the lower uterine segment above the symphysis pubis. In a frank breech in labor, the fetal buttocks, anus, sacrum, and ischial tuberosities can be palpated on vaginal

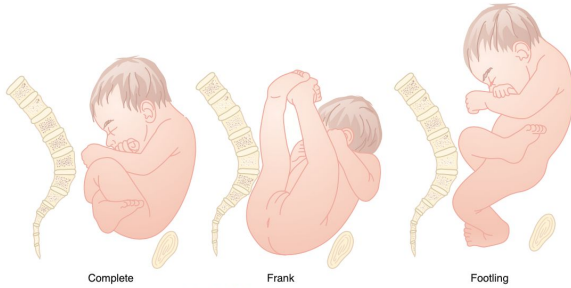


FIGURE 13-5 Types of breech presentation.

examination. With a complete breech, the feet, ankles, and often the buttocks are palpable through the dilated cervix. Vaginal examination of an incomplete breech reveals one or both fetal feet, but ultrasound may be required for definitive diagnosis.

Pregnancy Management

EXCLUDE FETAL AND UTERINE ANOMALIES. If breech presentation is suspected after 34 weeks, the prenatal records and any prior ultrasonic examinations should be reviewed for the presence of uterine myomata, a müllerian anomaly, or fetal structural abnormality. If suspicious, a thorough ultrasonic examination should be performed.

EXTERNAL CEPHALIC VERSION. External cephalic version (ECV) is a procedure in which the obstetrician manually converts the breech fetus to a vertex presentation via external uterine manipulation under ultrasonic guidance. **ECV may be considered in a breech presentation at term before the onset of labor.** Version is not carried out before 36 to 37 weeks' gestation because of the tendency for the premature fetus to revert spontaneously to a breech presentation. The procedure must be carried out in a hospital that is equipped to perform an emergency cesarean delivery because of the small risk of placental abruption or cord compression. The patient should have an intravenous access, and should have nothing by mouth for 8 hours before the version attempt in case emergency delivery is necessary. **Evidence of uteroplacental insufficiency, placenta previa, nonreassuring fetal monitoring, hypertension, intrauterine growth restriction, oligohydramnios, or a history of previous uterine surgery are contraindications to external cephalic version.** The immediate success rate of external version is 35-76%. Though ECV has been shown to decrease the rate of cesarean delivery, perinatal mortality rate has not been affected by this procedure. Only 2% of successful term versions revert to breech.

Labor Management

VAGINAL DELIVERY. Until the publication of randomized trials demonstrating that vaginal breech delivery was associated with increased perinatal mortality compared with planned cesarean, vaginal breech deliveries were performed in selected centers in patients who met strict criteria. These criteria are summarized in Box 13-4. **The standard of care now in most practices is to deliver all breeches by cesarean** to avoid the potential morbidities of umbilical cord prolapse, head entrapment, birth asphyxia, and birth trauma.

ASSISTED BREECH DELIVERY. Because the breech presentation can present in a setting in which cesarean delivery is impossible or unsafe, vaginal delivery of the breech continues to be an important practitioner skill.

BOX 13-4

CRITERIA FOR VAGINAL DELIVERY OF A BREECH PRESENTATION

Fetus must be in a frank or complete breech presentation.
Gestational age should be at least 36 weeks.
Estimated fetal weight should be between 2500 and 3800 g.
Fetal head must be flexed.
Maternal pelvis must be adequately large, as assessed by x-ray pelvimetry* or tested by prior delivery of a reasonably large baby.
There must be no other maternal or fetal indication for cesarean delivery.
Anesthesiologist must be in attendance.
Obstetrician must be experienced.
Assistant must be scrubbed and prepared to guide the fetal head into the pelvis.

*Inlet: anteroposterior (AP) diameter ≥ 11.0 cm; transverse diameter ≥ 10.0 cm. Midpelvis: AP ≥ 11.5 cm, transverse diameter ≥ 10.0 cm.

Once the fetus has delivered spontaneously to the umbilicus (Figure 13-6, A), gentle downward traction is exerted until the scapulae appear at the introitus (see Figure 13-6, B). After delivery of the scapulae, the shoulders are delivered by sweeping each arm in turn across the fetal chest until only the fetal head remains undelivered (see Figure 13-6, C). Once the shoulders have been delivered, the head is delivered by manual flexion of the fetal head with one hand flexing the head at the base of the skull while the operator's other hand is applied to the fetal maxilla for downward flexion (see Figure 13-6, D). Some obstetricians use Piper forceps routinely because this method has been shown to result in delivery of the head with the least amount of trauma to the fetus (see Figure 13-6, E).

Cesarean Delivery

During the process of breech vaginal delivery, successively larger parts of the fetus deliver, with the largest part, the fetal head, delivering last. In the very premature infant, the abdomen is much smaller than the head, so the lower extremities, abdomen, and trunk may deliver through an incompletely dilated cervix, leaving the fetal head trapped. This can result in fetal asphyxia and birth trauma. **Premature breech fetuses are thus preferentially delivered by cesarean delivery because of the head-abdominal size disparity.** Cesarean delivery is currently preferred for both preterm and term breech infants, although significant trauma can still occur if care is not taken with delivery of the arms and head.

Complications and Outcome

Even with optimal management, the perinatal mortality of breech fetuses is approximately 25 per 1000 live births versus 12 to 16 per 1000 for nonbreech

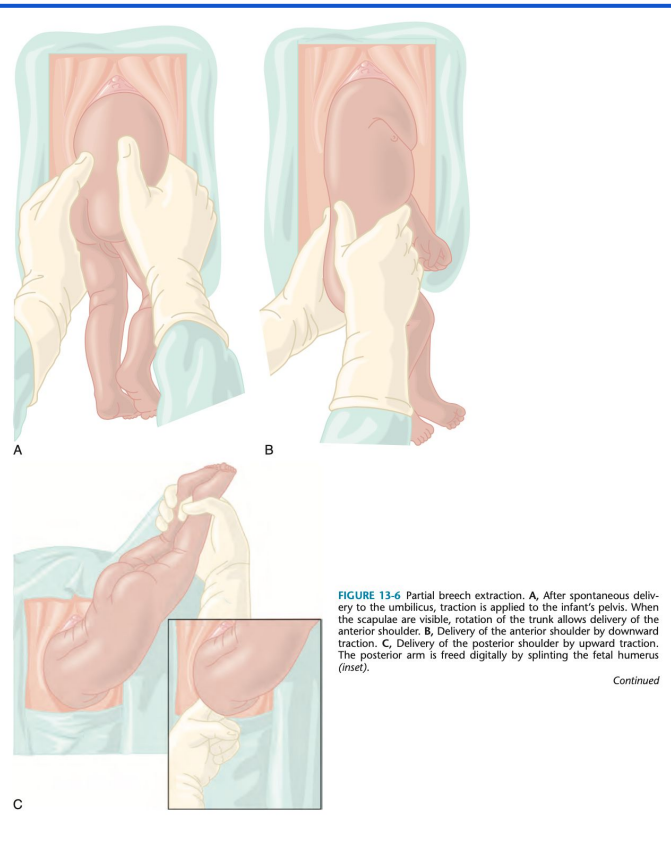


FIGURE 13-6 Partial breech extraction. A, After spontaneous delivery to the umbilicus, traction is applied to the infant's pelvis. When the scapulae are visible, rotation of the trunk allows delivery of the anterior shoulder. B, Delivery of the anterior shoulder by downward traction. C, Delivery of the posterior shoulder by upward traction. The posterior arm is freed digitally by splinting the fetal humerus (inset).

Continued

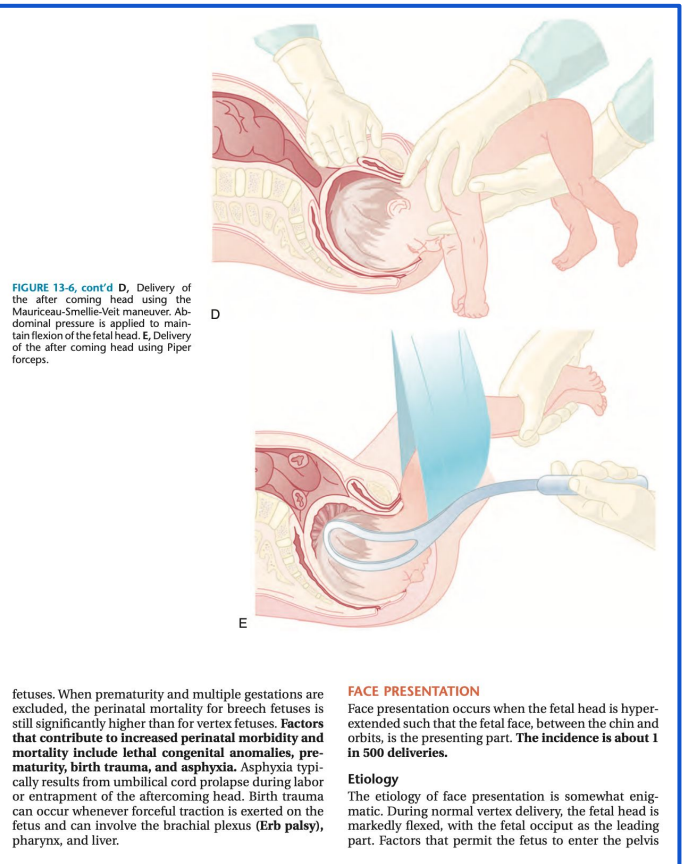


FIGURE 13-6, cont'd D, Delivery of the after coming head using the Mauriceau-Smellie-Veit maneuver. Abdominal pressure is applied to maintain flexion of the fetal head. E, Delivery of the after coming head using Piper forceps.

fetuses. When prematurity and multiple gestations are excluded, the perinatal mortality for breech fetuses is still significantly higher than for vertex fetuses. **Factors that contribute to increased perinatal morbidity and mortality include lethal congenital anomalies, prematurity, birth trauma, and asphyxia.** Asphyxia typically results from umbilical cord prolapse during labor or entrapment of the aftercoming head. Birth trauma can occur whenever forceful traction is exerted on the fetus and can involve the brachial plexus (**Erb palsy**), pharynx, and liver.

FACE PRESENTATION

Face presentation occurs when the fetal head is hyperextended such that the fetal face, between the chin and orbits, is the presenting part. **The incidence is about 1 in 500 deliveries.**

Etiology

The etiology of face presentation is somewhat enigmatic. During normal vertex delivery, the fetal head is markedly flexed, with the fetal occiput as the leading part. Factors that permit the fetus to enter the pelvis

Reference

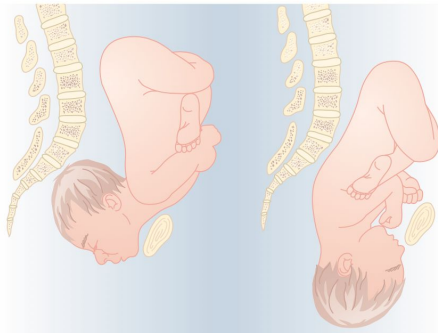


FIGURE 13-7 Spontaneous delivery of a mentum anterior face presentation. Note the flexion of the head under the symphysis pubis. The chin appears first, followed by the nose, brow, vertex, and occiput.

with a markedly extended head include extreme prematurity, high maternal parity, and congenital anomalies such as fetal goiter. In the majority of cases, no etiologic factor is evident.

Diagnosis

The diagnosis of face presentation is usually made at the time of vaginal examination during labor, when the soft tissues of the fetal mouth and nose are noted adjacent to the malar bones and orbital ridges. Face presentation is then confirmed by sonography. Because anencephalic fetuses uniformly present face first, **anencephaly should be ruled out when face presentation is suspected.**

Mechanism of Labor

The position of the presenting face is classified according to the location of the fetal chin (mentum). **Approximately 60% of face presentations are mentum anterior at the time of diagnosis,** whereas 15% are mentum transverse and 25% mentum posterior. The mechanism of labor with a face presentation is similar to the vertex presentation in that the longest diameter (mentum to brow) enters the pelvis transversely. As labor proceeds and the face descends to the midplane, internal rotation occurs into the vertical axis. If the mentum rotates anteriorly under the symphysis pubis, vaginal delivery should be expected. Forceps, but not vacuum, can be applied to assist if prerequisites are met. However, **if the mentum rotates posteriorly, the**

fetal head will be unable to extend farther to complete the expulsive process. Thus, mentum posterior cases and those with persistent mentum transverse must be delivered by cesarean delivery. Because final rotation from mentum transverse may occur only after a significant period of maternal pushing, patience is necessary. Approximately half of the mentoposterior and mentotransverse presentations spontaneously rotate to a mentoanterior position. When spontaneous vaginal delivery (Figure 13-7) or low forceps delivery occurs (Figure 13-8), perinatal morbidity and mortality for face presentations are similar to those for vertex presentations.

Other Presentations

Brow presentation occurs when the presenting part of the fetus is between the facial orbits and anterior fontanelle (Figure 13-9). This type of presentation arises as the result of extension of the fetal head such that it is midway between flexion (vertex presentation) and hyperextension (face presentation). **The incidence is about 1 in 1400 deliveries. With a brow presentation, the presenting diameter is the supraoccipital diameter,** which is much longer than the presenting diameter for a face or a vertex presentation.

The intrapartum management is expectant, because the brow presentation is an unstable one. Fifty to 75 percent will convert to either a face presentation, through extension, or a vertex presentation, through

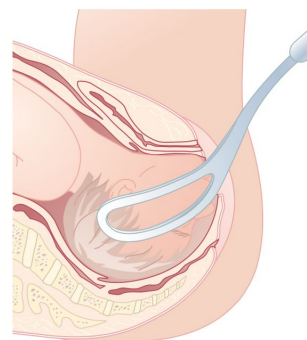


FIGURE 13-8 Simpson forceps applied to a mentum anterior face presentation.

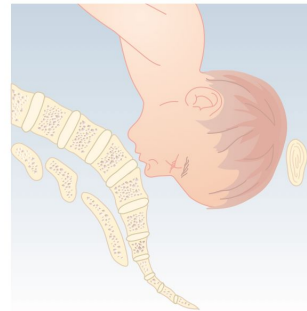


FIGURE 13-9 Brow presentation. Note the large presenting diameter (occipitofrontal).

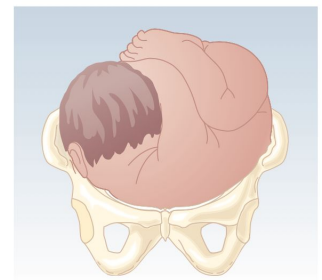


FIGURE 13-10 Shoulder presentation. Note the transverse lie of the fetus with the back down, which cannot be delivered vaginally.

flexion, and will subsequently deliver vaginally. **With a persistent brow presentation, the large presenting diameter makes vaginal delivery impossible, unless the fetus is very small or the maternal pelvis is very large, and delivery must be accomplished by cesarean delivery.** There is an increased incidence of both prolonged labor (30-50%) and dysfunctional labor (30%). As with face presentations, midpelvic delivery and methods to convert the brow presentation to a vertex presentation are contraindicated. **Perinatal morbidity and mortality are similar to those for vertex presentations.**

A **compound presentation** occurs when a fetal extremity (usually the hand) prolapses alongside the presenting part (the head) and both parts enter the maternal pelvis at the same time. This presentation occurs more frequently with premature gestations. The incidence of a hand or arm prolapsing alongside the presenting fetal head is 1 in 700 deliveries and management is expectant. Usually the prolapsed part of the fetus does not interfere with labor. If the arm prolapses, it is best to wait to see if it moves out of the way as the head descends. If it does not, the arm may be gently pushed upward while the head is simultaneously pushed downward by fundal pressure. If the complete extremity prolapses and the fetus then converts to a **shoulder presentation** (Figure 13-10), birth must be accomplished by cesarean delivery.



Med 441 Team:

Leader:

Sarah Alhamlan

Members:

Nada Alsaif

Good Luck!



Med 438 Team:

Leaders:

Ateen Almutairi - Lama ALzamil

Members:

Fatemah Alsaleh - Ghada Alsadhan
Ateen Almutairi - Razan Alrabah



Med 439 Team:

Leader:

Bushra Alotaibi

Members:

Alia Zawawi - Raghad Asiri