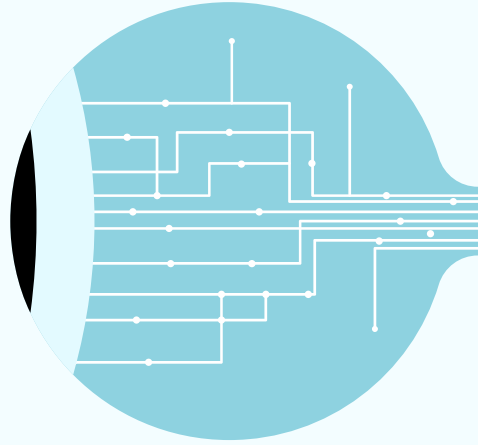


Lecture 9



v1.00

Editing File



Chronic Visual Loss

Presented by: Dr. Faisal Almobarak

Objectives of the course:

- To know common conditions that present with chronic visual loss (causes, clinical manifestation and management):
 - Chronic glaucoma (causes, types, management), Senile cataract, Diabetic macular edema, macular degeneration and Hereditary retinal diseases.
- How to use ophthalmic instruments and results of investigations to differentiate between different causes.
- To know what are treatment options for different conditions.
- To know when to refer a case to a specialist.
- **Causes, Medication, types are important for the exam**

Color index:

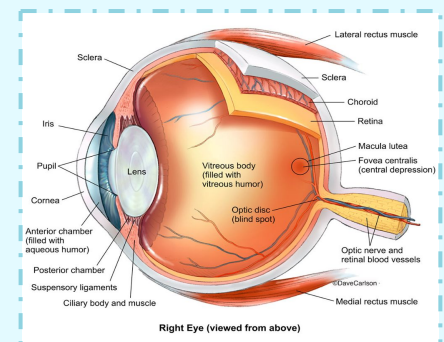
Lecture Outline

There are two ways to list the disorders of chronic visual loss, either by:

- Anatomical order
- Rarity of the disease

Causes of chronic visual loss by anatomical order:

1. Refractive
2. Cornea
3. Lens
4. Vitreous
5. Retina
6. Optic Nerve
7. Neurologic



Causes of chronic visual loss from most to least common:

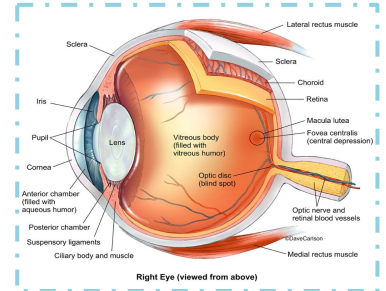
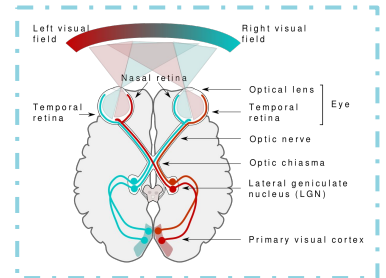
- ◇ Cataract **commonest** cause
- ◇ **Chronic** Glaucoma
- ◇ Diabetic retinopathy
- ◇ Macular degeneration **age related**
- ◇ Retinitis pigmentosa.

In this lectures, we organized the disorders from the most common to the least

Introduction To Chronic Visual Loss

❖ Anatomy of the eye & the visual pathway

- ◇ **Phototransduction:** By photoreceptors (rods and cones).
- ◇ **Image processing:** By horizontal, bipolar, amacrine and RGCs.
- ◇ **Output to optic nerve:** Via RGCs and nerve fiber layer.



What is Chronic visual loss?

It's a **gradual** progressive event (**painless visual loss**).

There is **no pain** no redness, no discharge (quite eye).

Duration: > 2 weeks.

❖ Vision: So how can we assess the vision?


- ◇ Quantity: VA (Visual acuity). See the image: good quantity but bad quality.
- ◇ Quality: VF (Visual Field), clarity of vision, color vision.
- ◇ Could be visual acuity 20/20 (quantity) but quality of vision is very bad or have color Blindness يشوف لكن يقطع يوميًا اشارات = quality not good
- ◇ Example :patient has glaucoma and visual field constricted, he can't see the sides يصدم العالم كل ما ساق (tunnel vision)

Blurry Eye Test



❖ Approach:

- ◇ Measure intraocular pressure with a tonometer
- ◇ Evaluate the nerve head, classifying it as normal, or abnormal
- ◇ Evaluate the clarity of the lens
- ◇ Evaluate the function and appearance of the macula.



How Glaucoma Affects Your Vision



Normal Vision



Moderate Glaucoma



Severe Glaucoma

-In general : Cut point of legal blind 20/200 =he can't drive

Causes of Chronic Visual Loss

1 Cataract (Lens) The most common cause

Definition

Opacity of the lens: Lens is transparent, and it contains proteins which are well-organized. When there is disorganization of lens protein = from soluble to insoluble, there will be clouding of the lens (cataract).



Helpful Video

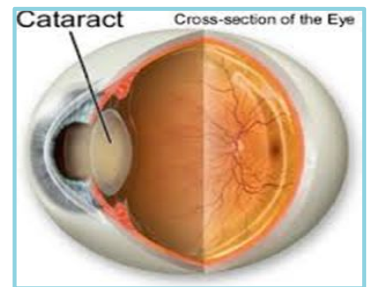
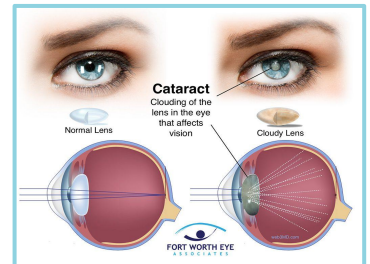
❖ Pathophysiology:

- Disorganization of lens proteins → **opacification**.

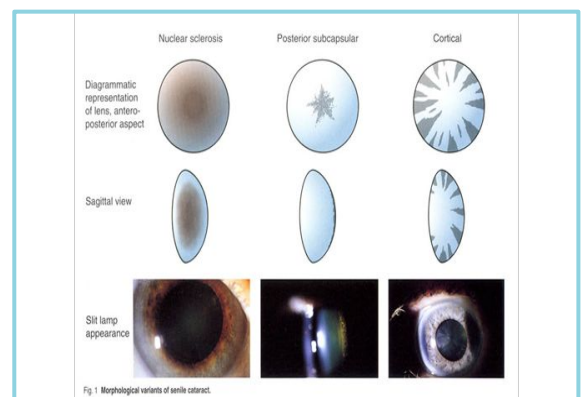
❖ Causes: MCQ

- Age related (Most Common Cause, MCQ)
 - Subcapsular (anterior or posterior). (mainly posterior)
 - Nuclear
 - Cortical.
- Metabolic:
 - DM
 - Galactosemia
 - Galactokinase deficiency
 - Fabry's disease
 - Lowes syndrome
 - Hypocalcemic syndrome
- Systemic diseases
 - Myotonic dystrophy
- Traumatic.
- Congenital. inherited or due to infection
- Drugs: **Cataractogenic drugs**, Chlorpromazine, Miotics, Myleran, Amiodarone, gold
 - topical or systemic steroid (The problem not only develop posterior subcapsular cataract they will develop Glaucoma as well)**. Pt. With SLE at high risk
- Inflammation. **Chronic uveitis**
- Ocular. **Retinitis pigmentosa**
- Patient with very high myopia

From most common to the least common



- Complicated cataract. EXTRA 437
 - Uveitis, Retinal dystrophy, retinitis pigmentosa, High myopia and Acute glaucoma.
- Intrauterine causes: Rubella, toxo and CMV.
- Syndromes: down syndrome, werner syndrome, rothman syndrome.
- Hereditary: 1/3
- Ocular: Patient with retinitis pigmentosa.



Causes of Chronic Visual Loss

Clinically:

- **Gradual** onset of painless visual loss.
- Visual acuity changes:
 - Worsening of **existing myopia**
 - In cataract the lens will enlarge & the anterior-posterior diameter increases, so light rays will be focused more anterior to the retina.
 - **Correction of hyperopia.**
 - In hyperopia, the light rays fall behind the retina; thus, some cataract patients, especially old ones who need near vision, will be happier with nuclear sclerosis, WHY? The diameter increases, light rays fall more anterior into the retina(will correct itself). So old patients who do not drive at night, will be happier & should be informed that they will need glasses for near vision after surgery
- -تباين- Loss of contrast sensitivity in low light. المريض ما يقدر يفرق بين درجات الالوان, فيحتاج ضوء اقوى عشان يفرق.
- -تشتت- Glare in bright light (scatter of light).
 - Classically happens with posterior subcapsular cataract (it opacification in the middle part of the lens so will scattered the light by this opacification) during night drive. Even if the patient has a visual acuity of 20\20; this affects visual quality.
 - The posterior subcapsular cataract will not allow equal penetration of light through the pupil. The light that passes through areas of condensation of posterior subcapsular cataract will have different intensity than the light that passes freely.

Treatment: MCQ

- Congenital (children and adults): lens aspiration ± IOL (Intraocular lens)
 - If take the cataract will lose 20 remember! So we need artificial lens.
 - Acquired(elderly) :
 - **ECCE + PCIOL** (posterior chamber intraocular lens) "very severe cataract".
 - Open anterior capsule & empty the lens from the opacified proteins; After that, you do ECCE or phacoemulsification then you put an artificial lens.
 - The problem with artificial lens: it does not allow accommodation. But new lenses allow patients to look far, intermediate and near without correction, it is called multi or trifocal IOL.
 - **Phaco (Phacoemulsification) + PCIOL** (Phaco is modified ECCE: small opening and putting a foldable lens). For moderately rigid lens
 - Simply you have an opacified lens proteins you need to exchange the lens with an artificial clear lens).
 - Under local anesthesia to block 3rd, 4th, 6th CN:
 - Retrobulbar anesthesia through inferior orbital rim.
- X **ICCE** (Intracapsular cataract extraction) removed lens and cataract and capsule, rare now.
- X **ECCE** (Extracapsular cataract extraction) removed center of lens that contains cataract, leave capsule. Bigger incision , more suture , more corneal damage, more infection risk
- X **ECCE IOL** (Extracapsular cataract extraction) + (intraocular lens) keeping the capsule in the eye acts as a bag for the artificial lens
- X **PHACO IOL** (Phacoemulsification) + (intraocular lens) small incision (2-3 mm), break cataract through ultrasound and place a foldable artificial lens. **this is now the preferred method.**

Causes of Chronic Visual Loss

❖ Cataract Clinical Classification (important):

- ◇ Maturity
- ◇ Morphological
- ◇ Age of onset

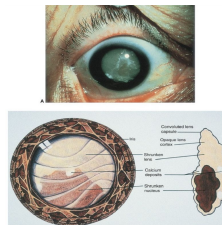
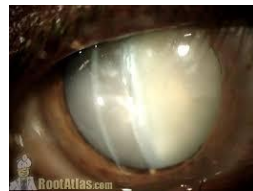According to The Maturity

Immature

- You can see the posterior pole (retinal details).

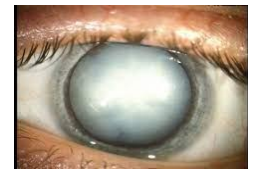Mature(Under the capsule)

- The whole lens is **completely white**.
- You cannot see the posterior pole "retina".
- The anterior chamber is shallow (narrow) → risk of glaucoma, so do a prophylaxis which is iridotomy.



Hyper-Mature

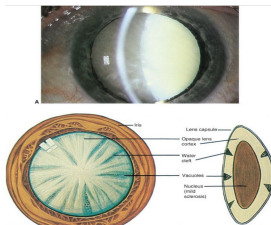
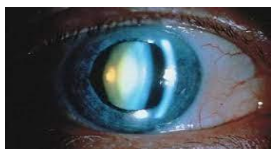- The lens proteins leak through the intact capsule, Lens is composed of nucleus, cortex & capsule. When the cortical proteins start to leak through an intact capsule, the nucleus will sink down within the capsule & the capsule will wrinkle. Urgent case.



Morphologic (According to the Anatomic location)

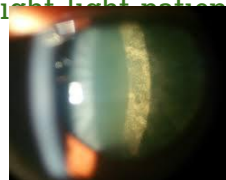Nuclear

- The lens nucleus itself becomes opacified.



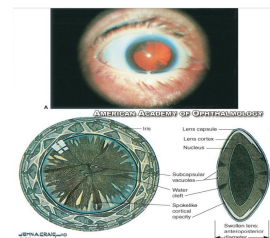
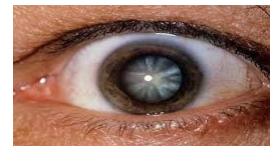Subcapsular

- Nucleus is not significantly affected either anterior or posterior subcapsular cataract
- It precipitates (the opacity) in the **posterior** subcapsular area.
- **Steroids** mostly cause this type of cataract and **age** Cataract
- In bright light patients will not see.



Cortical

- Nucleus and capsule are intact but cortex is opacified.



According to the Age of onset

Congenital (439)VERY IMP, MCQ

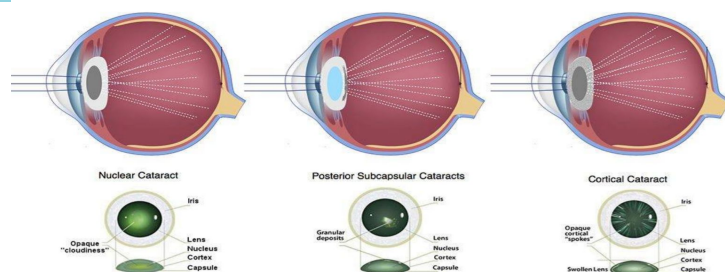
Infantile

Pre senile & Senile

Senile = after 45 Y.P

- Hereditary 1/3
- Metabolic
- **Syndromes:**
Down syndrome, trisomy 13 & 18
- **Intrauterine infection:**
Rubella, Toxoplasmosis, CMV

Types of Cataracts



Causes of Chronic Visual Loss

2 Glaucoma



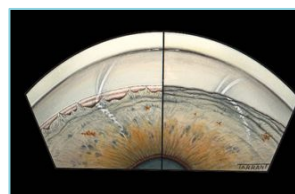
❖ The significance: الماء الأزرق - السويرق

- ◇ A major cause of blindness, most common cause of blindness in **African Americans** MCQ!
- ◇ **Progressive optic neuropathies**, that have in common characteristic morphological changes at the optic nerve head and retinal fiber layer because of the increase in the IOP cause the damaging (compression of the nerve) in the absence of other ocular disease or congenital anomalies. **Progressive retinal ganglion cell death** and **visual field loss** are associated with these changes.
- ◇ **Second leading cause of blindness (cataract is the first)** MCQ!
- ◇ **(you should be aware that glaucoma can happen with normal IOP which is called Normal Tension glaucoma) MCQ!!!**
- ◇ Often Asymptomatic; in early stage. Majority of patients lack pain, ocular inflammation.
 - If glaucoma is detected early and treated medically or surgically, **blindness can be prevented.**
 - **Damage is irreversible** MCQ!


Most common causes of secondary glaucoma: DM (neovascular glaucoma), uveitis (unilateral or bilateral).

❖ Classification of glaucoma:

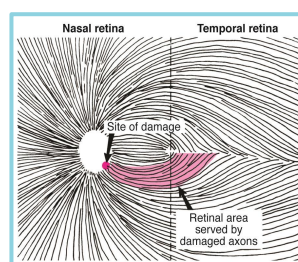
- ◇ According to the etiology:
 - **Primary:** no detectable reason, often **bilateral**
 - **Secondary:** predisposing factor, often **unilateral**
 - **congenital**
- ◇ According to the appearance of the angle:
 - **Open Angle Glaucoma.**
 - **Acute Closed angle Glaucoma.**
 - **combined**



Closed



Open



Glaucoma horizontal damage

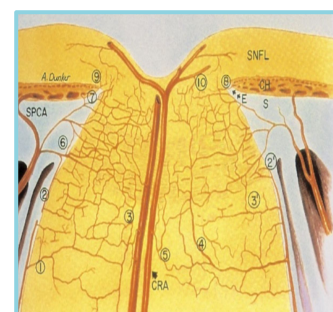
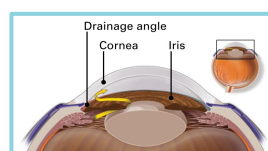
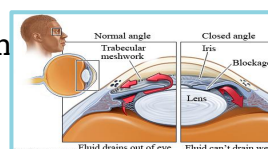
❖ Risk factors:

- ◇ **African Americans.** MCQ!
- ◇ IOP (most imp).
- ◇ Age.
- ◇ Family history. (most imp)
- ◇ DM/HTN.
- ◇ Medication "Steroids". Secondary
- ◇ Myopia.
- ◇ **inflammation**

- In glaucoma, the loss will start with peripheral vision, Wh

Because the increase in the IOP will start to compress the peripheral part of the retina which leads to damage the outer nerve axons first as it's will run at the peripheral part of the optic nerve so the middle axons will be pushed against the peripheral axons which will lead to being compressed against the lamella (dense connective tissue) so the peripheral axons will be damaged then the middle axons.

- The retinal ganglion is divided into superior and inferior retina embryologically, so the axon deviated to the superior and inferior retina so if the damage is at one side that side will defect.



Causes of Chronic Visual Loss

❖ Symptoms:

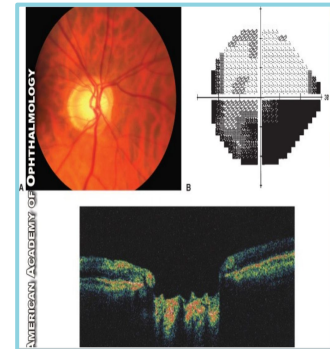
- ◇ Initially asymptomatic.
- ◇ Glaucoma starts with **peripheral (navigational) vision involvement (NO central vision involvement)**. irreversible chronic visual loss
 - Much peripheral vision can be lost before the patient notices visual impairment.
 - Patients present late to the clinic when they have progressive loss of vision & their visual field is markedly affected.
- ◇ Usually detected on routine examination.

Peripheral vision involvement



❖ Signs: **IMP!**

- ◇ peripheral horizontal visual field defect (vertical visual field loss is more associated with neurological causes of blindness).
- ◇ Optic disc cupping (تقعر) - more details in slide 11
- ◇ Focal damage to the optic nerve.
- ◇ Optic disc hemorrhage
 - When you shine a light to one eye the pupil for both eyes will contract at the same degree normally, but for example, if there is optic nerve damage in the right eye by 50% so the normal eye will constrict more than the left eye إذا عندك 100 رجال إذا عندك 100 رجال يعلمون العين اليسار ان فيه اضاءة واليمين 50 رجال فيصير ال response in the left will be better so it's constricted. This is when we don't alternate the light BUT if we shine the light on the left eye (normal) both eyes constrict with a variant degree, then directing the light to the right eye (the defected one) it's will dilate why? because the nerve damage on the right eye won't receive the same amount of light as the left eye do (relative afferent pupillary defect) but in a normal situation will be no variant as both eyes record the same amount of signals.
- ◇ Most of the world calls Glaucoma "blue water", however in some areas it can be called "black water" مرض سويرق لأنه يسرق النظر بهدوء بدون اعراض مثل السودان or even Swerek Disease



- **Gonioscopy: open or close** if close will do LPI= YAG laser peripheral iridotomy

● **Glaucoma triad:**

- **High IOP**
- **Characteristic optic nerve head damage** to know is it advance glaucoma ? =large cupping?
- **Visual field loss** peripheral horizontal, **Secondary to nerve fiber layer loss.** If central vision = tunnel vision

- **IOP is the single factor to be controlled (normal is 10-21 mmHg).**

- **Mean= 15.9mmHg ± 2 SD, IOP > 21.7 is abnormal.**

- In end-stage glaucoma, patients lose their peripheral visual field resulting in what's called tunnel vision. Patients will tilt their heads toward you when you speak to them.

❖ Factors affecting IOP:

- ◇ Age, sex, race, hereditary, diurnal and seasonal variation, blood pressure, obesity, drugs, posture, exercise, neural, hormonal, refractive error, eye movement, eyelid closure, inflammation, and surgery.

Causes of Chronic Visual Loss

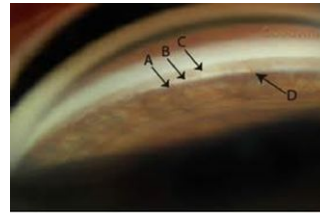
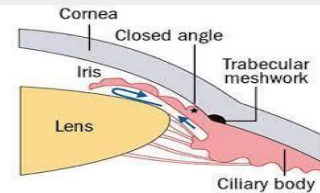
❖ Classification of glaucoma:

According to The Angle

Open = Iris Not covering TM

- In open angle you can see the angle structure
- Open angle: trabecular meshwork not occluded by peripheral iris.
- The problem with the pores in the Trabecular Meshwork(will narrow).
- Trabecular sclerosis happens causing aqueous accumulation (increase IOP) this will compress the axons against lamina cribrosa > will start losing axons > leading to cupping
Why axon dye? Because high IOP

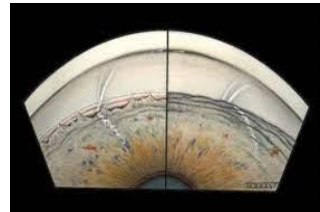
Laser Rx: **SLT**= selective laser trabeculoplasty → burns TM → capability of drainage of aqueous increased.



Closed = Iris covering TM

- You will not be able to see the angle structures.
- Aqueous pushing iris toward the cornea lead to close the angle.
- Unless you press the lens the structures will
 - **Mcq's or SAQ:** in peripheral anterior synechiae there will be adhesion between iris and angle.

Laser Rx: **LPI= YAG laser peripheral iridotomy** → laser opening behind the iris → aqueous goes behind the iris → pressure will decrease.



Treatment

Treatment is aimed at reducing intraocular pressure by 3 modalities available

1. Antiglaucoma medications to decrease the secretion of the Aqueous humor or increase the draining.
2. Laser treatment. SLT(Selective Laser Trabeculoplasty), PI
3. If no improvement do surgery, Surgical treatment either:
 - a. Cataract
 - b. incisional: trabeculoplasty, iridotomy, Canaloplasty and Ahmed implant.
 - c. Non incisional.

Me: *Decides to spend whole day studying*

Me After 5 mins of studying:



Did u get the message? :)

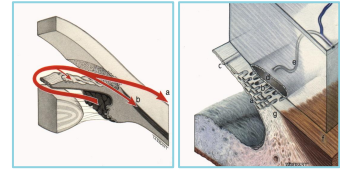


Causes of Chronic Visual Loss

❖ Aqueous humor:

◇ Active secretion:

- Na/K ATPase.
- Cl secretion.
- Carbonic anhydrase (available within the ciliary body and corneal endothelium)
 - The endothelium pumps fluid away from the cornea to keep the stroma dry.
 - The principal physiological function of the corneal endothelium is to allow leakage of solutes and nutrients from the aqueous humor to the more superficial layers of the cornea while at the same time pumping water in the opposite direction, from the stroma to the aqueous.
 - Accumulation of fluid within the stroma will result in a cloudy cornea instead of the normally transparent cornea.
 - For example, a patient underwent penetrating keratoplasty and developed glaucoma. Give the patient medication to stop the action of the carbonic anhydrase pump to reduce the aqueous production. At the same time, the medication will stop the function of the carbonic anhydrase pump within, and fluid will accumulate in the stroma (resulting in a cloudy cornea). In such a case, carbonic anhydrase pump inhibitors are not my 1st option.



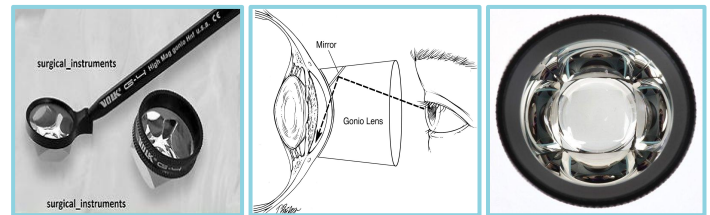
◇ Passive secretion:

- Ultrafiltration.
- Diffusion.

❖ Diagnosis:

◇ Gonioscopy or Zeiss gonioscopy lens:


- Are we dealing with open or closed, acute or chronic?
- You should do a **gonioscopy** and check the angle as we can not see the angle by the slit lamp.
- **It is used to view the iridocorneal angle in the case of glaucoma.**
- **Instrument: gonioscope/goniolens. It is used to view the iridocorneal angle in case of glaucoma.**



◇ Normal angle structures (important):

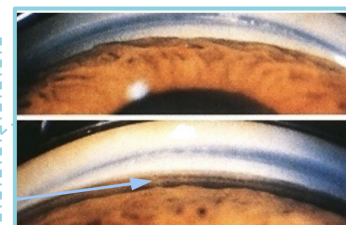
◇ Schwalbe's line (SL).

- Trabecular meshwork (TM).
 - Non pigmented.
 - Pigmented.
- Sclera spur (SS) is the attachment of the sclera and the cornea.
- Ciliary body. (If you didn't see them it's close-angle.)



Left: When you put the gonioscopy lens in center, you can see the angle in all quadrants at the same time.
Right: "Indentation gonioscopy", when you indent by these lens you may open a narrow angle. So it can differentiate between open angle, closed angle and narrow or positional angle

Above: no angel structure seen.
 Below: when you press by the lens, it shows you that the angle is open.



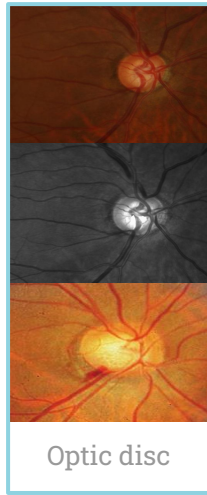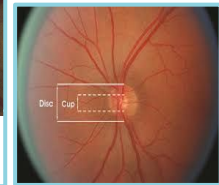
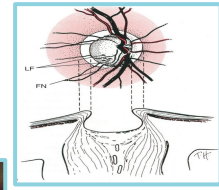
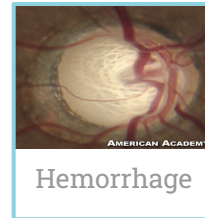
Causes of Chronic Visual Loss

Optic Nerve Head (ONH) complex evaluation:

- In clinic do detailed optic nerve exam because you might have:
 - Glaucomatous optic nerve head damage.
 - Anomalous disc.
 - Disc pallor because of CNS or DM.

■ What to evaluate:

- **Disc margin and disc diameter.**
- **Cup/disc ratio: (important)**
 - ◆ How to estimate it? Take the vertical ratio; if more than 0.3 we should worry.
 - ◆ **Normal value is 0.3, bigger cup = more nerve tissue loss.**



In glaucoma :

If cup increase (المقصود بالكب الفراغ اللي بالدسك) > axon decrease (losing vision) = IOP not control. so you should worry from this:)

■ Neuroretinal rim (forget about it):

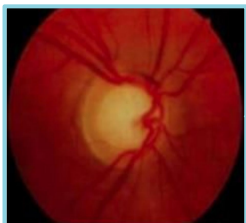■ area of axon

- The cup is almost circular. There are almost 1 million axons passing within the optic canal to go to the brain. These axons will form the optic disc. There is an empty space in the middle because 1 million axons cannot completely fill the canal. The space is called cup. When there is an enlargement of the cup, it means you are losing some axons because of glaucoma.
- How to assess the cup?
 1. Disc margin.
 2. Neuro-retinal rim. وتناسب نسبة.
- How much is the ratio of the cup to the disc margin vertically.
 - ◆ Disc size

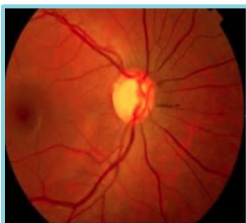
■ PPA (Peripapillary atrophy).

■ Nerve fiber layer (NFL) defect.

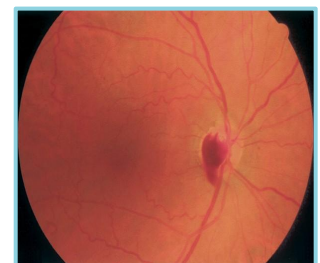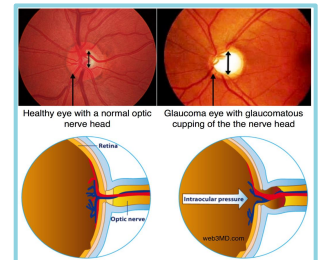
■ Optic disc hemorrhage



- **Diagnosis:**
 - Disc cupping
- **Investigation to confirm the diagnosis:**
 - Visual field examination.
- **2 types of visual field defect:**
 - Nasal step.
 - Arcuate scotoma.
 - Peripheral visual field defect.



- **Diagnosis:**
 - Disc cupping
- **Next step:**
 - Goldmann applanation tonometry.



● Open angle glaucoma: Intrinsic defect in outflow tract ^{Extra 437:}

- "In case of open angle glaucoma the angle is anatomically open, but physiologically impaired, why? Because the layer of trabecular meshwork isn't functioning as required, so when the aqueous humor goes from the anterior chamber and circulate between the iris and the lens, it won't go through the trabecular meshwork"

● To diagnose an open angle glaucoma: (Diagnosis by exclusion)

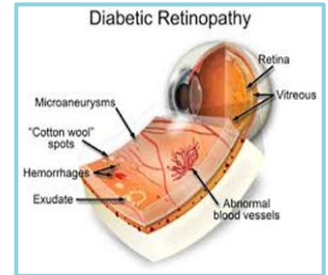
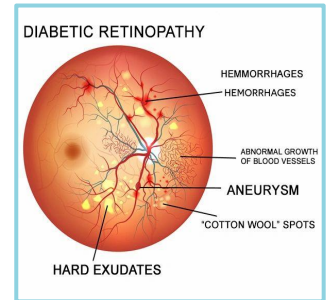
- Measure IOP (you should have high pressure by Goldmann applanation Tonometry)
- Look for optic disc (optic disc cupping)
- Visual field (defect respecting the horizontal midline)
- Gonioscopy (the angle is widely open)

Causes of Chronic Visual Loss

3 Diabetic retinopathy (Important)

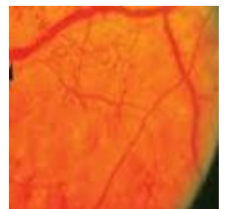
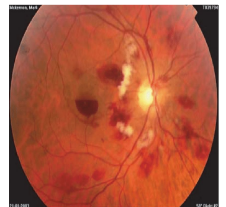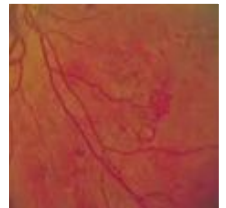
❖ Pathophysiology:

- ◇ **Microangiopathy** which involves precapillary arterioles, capillaries and postcapillary venules.
- ◇ **Two Mechanisms:**
 - **Microvascular occlusion.**
 - **Microvascular leakage.**



Microvascular occlusion

- **Thick capillary basement membrane**
 - It means lumen is smaller.
 - Abnormal blood vessels (fan-shape)
- **Capillary endothelial cell damage with changes in RBCs → Retinal ischemia → AV shunt and neovascularization of the retina and around the optic disc.**
 - So the cause of neovascularization of the retina which is seen in proliferative type is related to microvascular occlusion.
- **Change in red blood cell**
 - and increased viscosity in diabetic patients.



Abnormal blood vessels

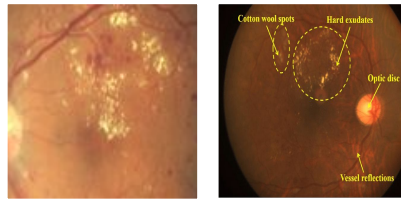
- All of these will lead to narrow the lumen of capillary > decreased blood supply > retinal ischemia > neovascularization and AV shunt formation (by VEGF).
- As we said new vessels will be fragile and weak > they can bleed then fibrosis.
- The retinal surface is dry (there should be no fluid within the retina).
- 1:45 P.M : Doctor said joke about ENT but I'm not sure about whether it will come in the SAQ or not 😊

Causes of Chronic Visual Loss

Microvascular leakage

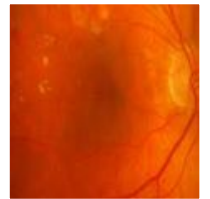
- **Loss of pericytes between endothelial cells**
 - Then there will be gap → plasma leakage of fluid and lipid into retina (retina should be dry) → exudates and edema

- Exudate of lipid in Retina.
- Ill-defined exudate, no pattern.
- More superficial.



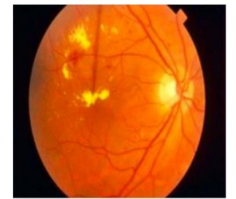● Retinal Edema

بلازما زي الاسفنج = تكب عليه موي ينتفخ



A. Risk factors:

- Duration of the disease** is the most important factor, then high blood sugar, pregnancy, nephropathy, poor metabolic control, smoking, **HTN**, obesity and hyperlipidemia, anemia.



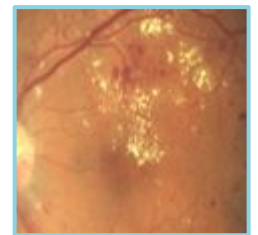
Diagnosis: non-proliferative diabetic retinopathy.
Treatment: Laser photocoagulation.

B. Types:

- Proliferative with or without macular edema
- Non-proliferative with or without macular edema.

C. Clinical classifications

- Remember! The hallmark feature of non-proliferative diabetic retinopathy is micro aneurysms; while in proliferative diabetic retinopathy, it is neovascularization.**

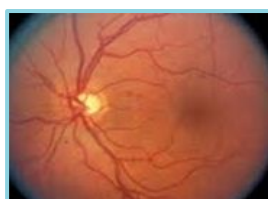


Clinically significant macular edema (CSME)

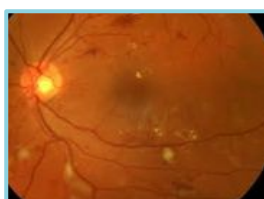
1. Non proliferative diabetic retinopathy (NPDR):

risk of vitreous bleeding & fibrosis that lead to tractional retinal detachment

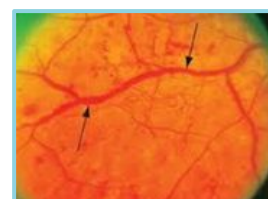
- Mild** (micro-aneurysms, the only patients developed).
- Moderate** (exudates, hemorrhages as well as micro-aneurysms).
 - Hemorrhage in 1-3 quadrants is considered moderate.
 - Venous bleeding in 1 quadrant is considered moderate.
 - Hemorrhage in 3 quadrants along with venous bleeding in 1 quadrant is still considered moderate.



Mild



Moderate



Causes of Chronic Visual Loss

- c. **Severe** the likelihood of developing PDR is >50% in 1y (hemorrhages in 4 quadrantes, venous bleeding or slugging (means diameter of the vein is increasing) in 2 quadrants, intraretinal malformation of blood vessels in 1 quadrate).

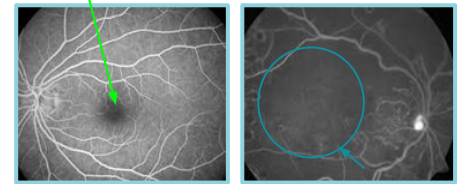
- Memorize it like this: "HIV" H: hemorrhages, I: intra-retinal vascular malformation, V: venous bleeding.
- The intra-retinal vascular malformation is deep within the retina (deep to the arcade).
- Intra-retinal vascular malformation is also known as intra-vascular micro-vascular abnormalities (IRMA).

● **Symptoms:**

- Asymptomatic
- Decreased visual acuity: clinically significant macular edema & macular ischemia.
- Most of the time asymptomatic but the vision can decrease if the patient have macular edema or macular ischemia (remember when we talk about diabetic retinopathy, when we said in microvascular: that occlusion>ischemia and Leakage>edema **both lead to decrease vision**)

- **treatment** : pan-retinal photocoagulation (PRP) to prevent developing PDR

Fovea or FAZ (foveal avascular zone)



normal

-Small blood vessels occlusion (not appear)
-And sometime will see the leakage (not in this photo)

Fundus fluorescein angiography:

Delineation of the vascularity of retina.

Right: Normal.

Left: Ischemic retina (dye will not pass through the ischemic area).

2. Proliferative diabetic retinopathy (PDR):

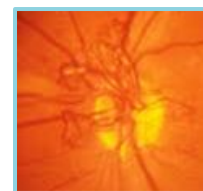
- a. **Early** (neovascularization, fan-like and disorganized).
- b. **Advanced** (when it progresses & bleeds, it will form fibrosis which is attached to the retina. When it contracts it will pull on the retina causing tractional retinal detachment).
 - Advanced proliferative diabetic retinopathy = there should be tractional retinal detachment.
 - The neovascularization forms on the retinal surface (superficial).

● **Symptoms:**

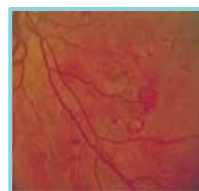
- Symptomatic. Most of the time but may come asymptotic
- It can also cause macular edema & macular ischemia.

● **Neovascularization:** (because ischemia)

- A. NVD: neovascularization of the disc. (above disc)
- B. NVE: neovascularization elsewhere. (away from disc)



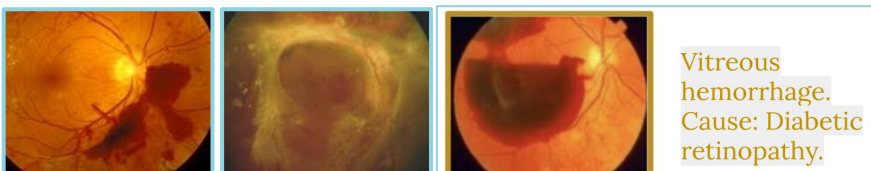
NVD



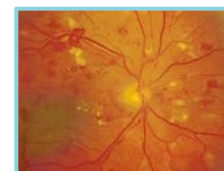NVE

- **Fragile** (intra-retinal or vitreous hemorrhage).
- Associated with fibrous proliferation which can cause at a later stage **tractional retinal detachment (TRD)**

- **treatment** : pan-retinal photocoagulation (PRP)



Vitreous hemorrhage.
Cause: Diabetic retinopathy.



Early

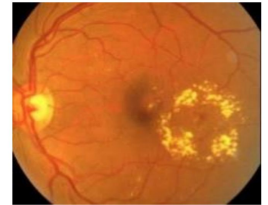

Advanced

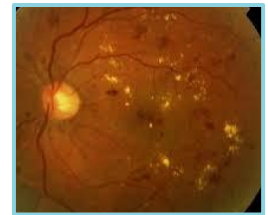
Causes of Chronic Visual Loss

❖ Diabetic Macular Edema:

- ◇ Retinal edema threatening or involving the macula.
- ◇ Evaluate: location of retinal thickening relative to the fovea and the presence and location of exudates.
- ◇ In clinically significant macular edema:
 - We have 2 classes because the management is different.
 - a. Focal macular edema:
 - Single leaking blood vessel:
 - ◆ Circinate ring, exudate in a circular fashion.
 - ◆ Treated with focal laser.
 - b. Diffuse macular edema:
 - Running in a circular way
 - ◆ Haphazardly diffuse exudates and thickening → diffuse macular edema.
 - ◆ Treated with grid laser or injection.
- ◇ Treatment:
 - Focal Laser > For PDR → pan retinal photocoagulation (treat the whole retina except the macula).
 - Intravitreal steroid injection.
 - Intravitreal anti-VEGF injection. (Avastin, Lucentis, Eylea).
 - Pars plana vitrectomy: For patients having chronic vitreous hemorrhage or tractional retinal detachment

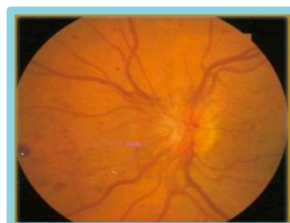
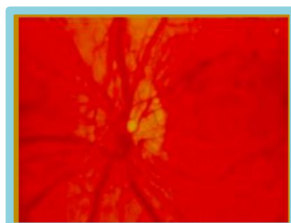


Circinate ring in focal macular edema.



❖ Management of diabetic retinopathy:

- ◇ NPDR > Observation (no treatment expect control the blood sugar).
- ◇ PDR > Pan retinal photocoagulation (PRP). The laser changes the ischemic retina to anoxic retina and this will decrease the vascular endothelial growth factor responsible for the formation of new vessels > stops the neovascularization.
- ◇ Macular edema > Focal or Grid laser, injections of anti-VEGF can decrease the edema



Diagnosis: proliferative diabetic retinopathy (neovascularization at the optic disc).

Management: Pan-retinal photocoagulation.

Causes of Chronic Visual Loss

4 Age Related Macular degeneration (AMD) *VERY IMPORTANT

Introduction:

- ◇ Impaired **central** vision, while, **peripheral** vision **preserved** (opposite to glaucoma).
 - That is why patients with macular degeneration will complain faster than patients with glaucoma.
- ◇ A leading cause of irreversible **central** visual loss (20/200 or worse).
- ◇ Legal blindness (**20/200 or worse**).
 - It is known as **age-related macular degeneration** because it comes with age. why in the macula? because it is highly used as all the light are spot in the macula and it's highly vascularized at the **center** to cool down the heats of the macula that why the damage at the center
 - Lipid deposition under the photoreceptors -> toxic reactions. Inflammatory element.

Symptoms: You need t be aware it

- ◇ Metamorphopsia: vision distorted (كأني أشوف الي قدامي مكسر).
- ◇ Micropsia: reduction of the size of objects.
- ◇ Macropsia: enlargement of the size of objects.
- ◇ **Central** scotoma :localized visual field loss.

Risk factors: important:

- ◇ **Uncontrollable risk factors**
 - **Age (above 60).**
 - Race (Caucasian).
 - Gender (females).
 - Genetics (family history).
- ◇ **Controllable anything increases the oxidative processes**
 - Smoking, high BP, high cholesterol, poor nutrition, UV light, Unprotected exposure to sunlight, excessive sugar intake, obesity, sedentary lifestyle. diet, vascular disease

Pathogenesis:

- ◇ **Macular involvement.**
- ◇ Outer retinal layer "photoreceptors".
- ◇ Retinal pigment epithelium (RPE).
- ◇ **Drusens**(made up of lipids and proteins): diposting and accumulating under the **retinal pigment epithelium and bruch's membrane** (suppose RPE to take it and pump out out) > photoreceptor will displace >**Metamorphosis.**

مثل أسنان المشط لو ضغطت عليه = جهه بتتفرق وجهه بتتجمع

-So photoreceptor will condensing in one area, the other areas

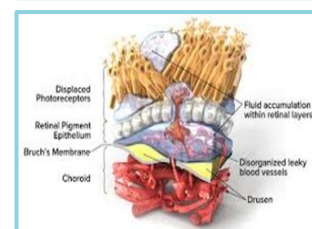
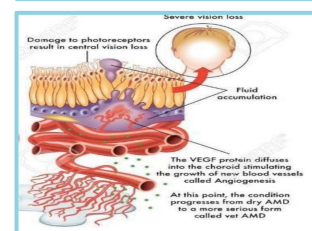
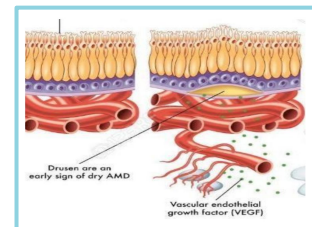
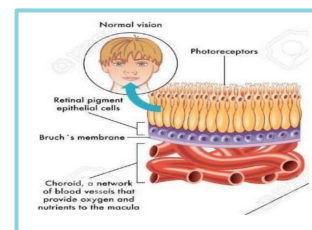

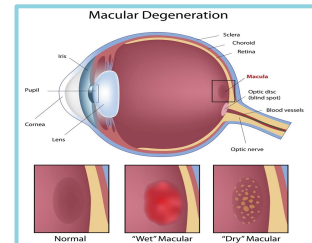
The light rays falling but have few photoreceptor.

-Micropsia + Micropsia = **Metamorphosis = distorted vision**

- ◇ Bruch's membrane.
- ◇ Choriocapillaris.

Types:

- ◇ Dry: slow progressive atrophy of retinal pigment epithelium (RPE) and photoreceptors.
- ◇ Wet: RPE detachment and choroidal neovascularization.



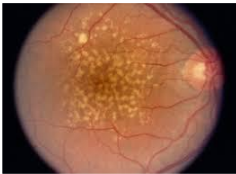Causes of Chronic Visual Loss

Types

Atrophic = dry

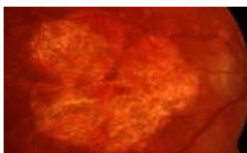
- 90% **common**, **Slow** progressive atrophy of RPE and photoreceptors.
- Often asymptomatic.
- Gradual over years.
- Signs:
 - **Drusen**. **Yellowish deposit with fine edge**
 - Geographic atrophy. **Yellow lesions**
 - Photoreceptor degeneration.
 - **Central** scotoma when light adapting.

- Drusens are soft, mostly circular & deep.
- Its color is dark similar to that of the normal retina.



Dry type ; atrophic and lipofuscin accumulation.

- The accumulation of drusens (lipids) for so many years will create a barrier that prevents oxygenation to reach the retina (photoreceptors) causing **atrophy of the photoreceptors & RPE** resulting in geographic atrophy. Patient then can't see.



- WE can't treat the patient because photoreceptors already are destroyed.

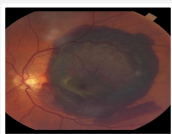
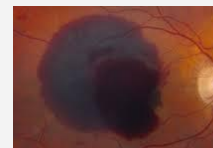Exudative = wet

- 10%, RPE detachment and choroidal neova. **Blood vessels leak fluid**
- **Rapidly** progressive (weeks) **due to hemorrhage**. It can be an acute or chronic cause of visual loss.
- Signs: **Metamorphopsia + Central scotoma (classic)**
 - Choroidal (subretinal) neovascularization.
 - Preretinal hemorrhage (shiny blood).
 - Elevation of retina because of accumulation of blood
 - Subretinal fibrosis. = photoreceptor +RPE gone = loss vision
 - Metamorphopsia (a classical complain of patients with macular degeneration).
 - Central scotoma (because of blood and scarring within the macular area).

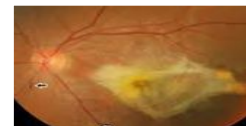

- Subretinal hemorrhage
 - If choroidal (subretinal) neovascularization bleeds, it will appear dark grey hemorrhage. That means it is under RPE (RPE is always dark in color).
 - If it is bright, that means it is above RPE.

Multilayer haemorrhage
Grayish and brighter in photo
Cause by **Choroidal neovascular membrane**



- Subretinal fibrosis
 - Remember we said the neovascularization almost always comes with fibrosis.
 - Once the patient has sub-retinal fibrosis, nothing can be done; thus, it needs urgent management.




- We can give the patient some medications to stop these blood vessels to invade the retina like **Anti-VEGF** agents or **lasers**.
- the disadvantage of the laser is **scarring**.

Causes of Chronic Visual Loss

Diagnostic Tests

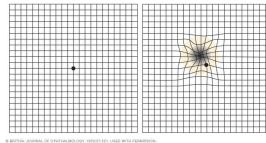
Visual acuity

- Because central vision will be affected first.
- Most of the patient will complain of disturbance in vision (20/20)'= beginning macular degeneration



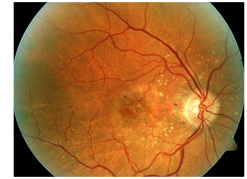
Amsler grid

- If the patient sees wavy lines, it means there is disorganization of photoreceptors secondary to accumulation of drusens. The black spot (blind spot) is caused by accumulated drusens, localized ischemia, localized loss of photoreceptors, hemorrhage & fibrosis.



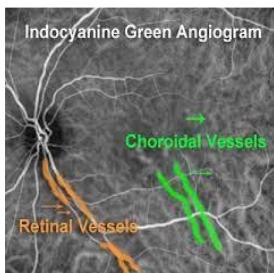
Ophthalmoscope

- Here you can see drusens, geographic atrophy, fluid, fibrosis or hemorrhage . Depends on the pt's stage.



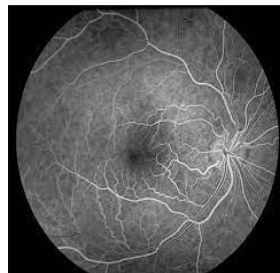
ICG (Indocyanine Green)

- It will show you the choroidal neovascular membrane.



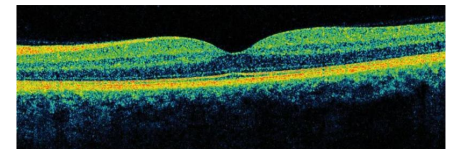
Fluorescein angiography

This 3 diagnostic tests Not explain by the doctor :)



OCT (Optical Coher Tomography)

- To show subretinal hemorrhages and fibrosis, which is dense homogenous membrane under the retina.



❖ Treatment:

- If dry:
 - Lifestyle: stop smoking, reduce UV exposure, Zinc & antioxidants. Vit.A
 - Low-vision aid (magnifiers) to improve the peripheral vision that still intact
 - Monitoring with Amsler chart to follow up the progression (important).
- If wet:
 - Observation (sometime the only thing is to observe. Example : Subretinal fibrosis)
 - Laser photocoagulation to stimulate photo for neovascular membrane especially for the wet type.
 - Anti-VEGF agents e.g: avastin, Lucentis & eylea Wet type (stop the retina from signaling VEGF & as a result will stop formation of abnormal blood vessels).
 - Verteporfin photodynamic therapy (PDT): Injection of photosensitizer into systemic circulation followed immediately by laser targeting new vessels in macular area. NOT used nowadays : you don't need to know it

Causes of Chronic Visual Loss

Drusens

Drusens (yellowish discoloration):

- lipid products from photoreceptor outer segments, found under retina.
- Drusens are hyaline nodules (or colloid bodies) deposited in Bruch's membrane, which separates the inner choroidal vessels from the RBE.
- Drusens may be small and discrete or larger, with irregular shapes and indistinct edges.
- Patients with drusens alone tend to have normal or near normal visual acuity, with minimal metamorphopsia
- With age certain people will develop lipid material deposition under the photoreceptors this will cause some sort of toxic reaction to the photoreceptors.
- Normally, the lipid deposits will be drained and absorbed by the choroid. If there is accumulation of lipid deposits, what will happen to the oxygenation from the choroid reaching the retina? decreased ischemia > atrophy. So the patient won't be able to see.

Neovascularization

With ischemia new vessels from choroid grow into the subretinal space forming subretinal neovascular membrane or preching the Bruch's membrane

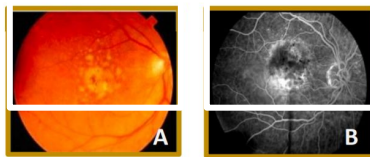
any new blood vessels in abnormal place are **ABNORMAL (fragile and weak)**

IMPP MCQ: Multilayer retinal hemorrhage is caused by choroidal neovascularization membrane !!!!!!!!!!!!!!!

Hemorrhage

The new vessels are very fragile can bleed easily

- New vessels is bad Either it continues to vitreous causing **vitreous hemorrhages** or it will bleed under the RPE causing sub **RPE hemorrhages** or it will bleed under the internal limiting membrane and causes **subhyaloid hemorrhage**.
- **Hemorrhage into subretinal space or even through the retina into the vitreous (significant loss of vision).**



Diagnosis: age-related macular degeneration.

2 risk factors: age & smoking.

Name of investigation in pic B: Fundus fluorescein angiography.

Causes of Chronic Visual Loss

5 Retinitis pigmentosa العشى الليلي

Definition

A group of genetic disorders affecting the retinal ability to respond to light.

- Most are legally blind (central visual field of less than 20 degrees = tunnel vision like glaucoma) by 40s. Legal blindness is 20/200 vision & worse



Helpful Video

Intro:

- **X-linked recessive:**
 - Males: more often and more severe
 - Females: carry the genes and experience vision loss less frequently.
- **Target photoreceptors** and associated with pigmentary changes in the RPE, which may be primary or secondary to the photoreceptor loss. **(not imp)**
- The retina has 2 types of cells that gather light: rods and cones. The rods are around the outer ring of the retina and are active in dim light. Most forms of RP affect the rods first. So night and peripheral vision will be affected. Cones are mostly in the center of the retina, they help in seeing color and fine details. When RP affects them, there'll be slow central vision loss and inability to see colors

Symptoms:

- **Slow loss of vision:**
 - **Nyctalopia:** loss of night vision, sometimes with progression > tunnel vision.
 - **Tunnel vision** "loss of peripheral vision". **At advance stage**
 - Blindness. **Unfortunately most are legally blind by 40 (for total retinitis pigmentosa -sectoral retinitis pigmentosa will not have this issue-)**
 - Photosensitivity.
 - Low or blurry vision at night especially while driving.
 - Very slow dark-light adaptation.

Signs:

- Visual acuity varies from: 20/20 to no light perception (NLP) at all.
- +-APD (afferent pupillary defect).
- **PSCC** (posterior sub-capsular cataract).
- **RPE hyperpigmentation** (bone spicules) it is the dark part of the eye, alternate with atrophic regions. **RPE always give dark color in retina**
- Attenuation of the arterioles "thinning".
- Waxy pallor of the optic nerve head.
- Cystoid macular edema (CME) in severe cases of RP.
Once it progress it can be sectoral or total. Once it becomes total surround the macula > tunnel vision

Treatment:

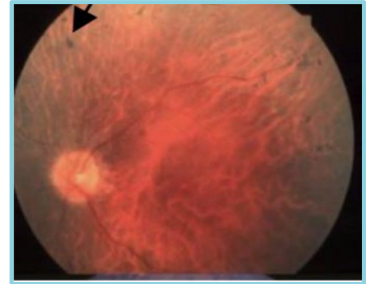
- Unfortunately, nothing can be done to prevent the progression of the disease, but associated ocular problems can be treated:
 - CAI: CME (carbonic anhydrase inhibitor for CME).
 - Vitamins.
 - Cataract: surgery.
 - Low vision aids.
 - Gene therapy **مئة ألف دولار = ذكرني بعرض ابو صلاح**



Causes of Chronic Visual Loss

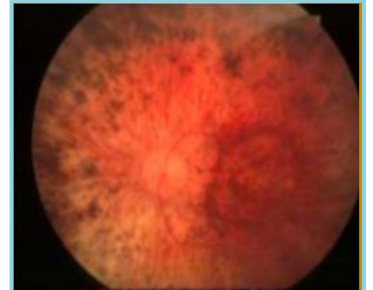
Early Stage

- Black spots in peripheral “bone spicules, why? RPE clumping” (black arrow).



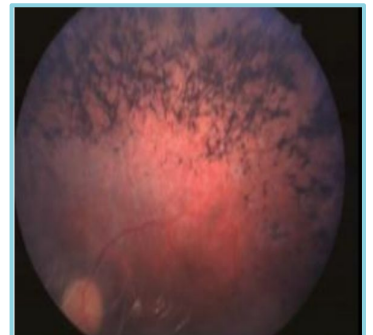
2nd Stage

- Bone spicules Increased more and more.
- Start to loss photoreceptors.
- Waxy disc appearance.
- Attenuation of arteriole.
- **Diagnosis: RPE hyperpigmentation (bone spicules) & waxy disc appearance.**
- **Test: VF, color testing.**
- **Treatment: carbonic anhydrase inhibitors.**
- **Retinal changes secondary to photoreceptors loss.**



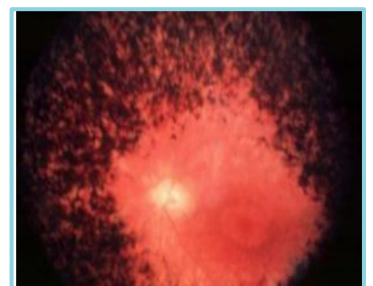
3rd Stage

- More loss of photoreceptor
- More clumping of RPE



4th Stage (Severe)

- Severe photoreceptors loss
- Tunnel vision
- Severe RPE loss and clumping
- Bone spicules
- Waxy pallor
- Circumferential involvement of retina. It will spare the macula.
- Cystoid macular edema.



Causes of Chronic Visual Loss

Workout:

- Visual field test (it shows constricted visual field & in advanced stage tunnel vision)
- Color testing (mild blue-yellow axis color defects).
- Dark adaptation study (reduced contrast sensitivity relative to VA).
- Genetic subtyping to confirm the presence of the particular gene-defects.
- Optical Coherence Tomography (OCT), to look for (CME), to confirm damage of photoreceptors and to show the extent of their loss. .
- FFA fluorescein angiography.
- ERG electroretinography IMP is an eye test that detects function of the retina including photoreceptors, to confirm the dysfunction or loss of functionality of photoreceptors.
- EOG electrooculography to measure eye movement.

Systemic associations:

- **Systemic associations: rule out systemic association MCQ!!!!**
- **Hearing loss & RP:**
 - **Usher syndrome (Important)** a condition characterized by partial or total hearing loss and RPE (common). **MCQ!!!!**
 - Alport syndrome is a genetic condition characterized by RP, kidney disease, and hearing loss.
 - Refsum disease is an autosomal recessive neurological disease that results in the over- accumulation of phytanic acid in cells and tissues.
- **Kearns-Sayre Syndrome (Important)**
 - **External ophthalmoplegia (thus restricted ocular motility).** **MCQ!!!!**
 - **Lid ptosis (unilateral or bilateral).**
 - **Heart block. REFER TO CARDIOLOGIST!!!!**
 - **Pigmentary retinopathy.**
- Abetalipoproteinemia is a disorder that interferes with the normal absorption of fat and fat- soluble vitamins)↓vitamin A →RP
- Mucopolysaccharidoses.
- Bardet-Biedl syndrome genetic disorder characterized principally by obesity, RP, pigmentosa, hypogonadism, and kidney failure in some cases.
- Neuronal ceroid lipofuscinosis lysosomal storage disorders characterized by dementia, RP, and epilepsy.

Causes of Chronic Visual Loss

6 Refractive

*Mostly in young patients like you:)

- **Causes:**
 - Myopia, hyperopia or astigmatism. Doctor explained them but it explained in refractive errors lec + amblyopia lec
 - **Amblyopia (lazy eye)**
Refractive error in children one of the **most common** causes of developing amblyopia because of the uncorrected refractive error.
So chronic vision loss in children might end up having amblyopia
usually the patients has NO eye pathology upon examination
- **Signs:**
 - Normal exam
 - Sometimes patients with astigmatism have corneal scar on examination.
 - Refraction needed to show errors either auto refractor or manual refractor
 - Everything will be normal except for visual acuity.
- **Treatment:**
 - Glasses, Contact Lenses, Refractive surgery
 - There are different types of refractive surgery:
 - **Lasik** and **epilasik**: we are maintaining the epithelium & applying it again.
 - **PRK**: there is scraping of the epithelium by focusing the laser emission on the corneal stroma.
 - NB: lenticular causes need cataract surgery.
It develop if anterior posterior diameter increase > focus inpower increase > the light will be in front of retina (myopia)
- **Occurrence:** Mostly in young adults.

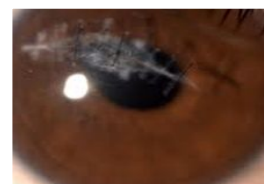
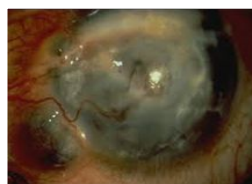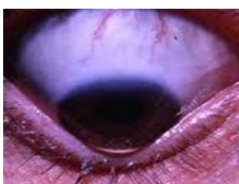7 Cornea Transparent

Causes:

- Scar
 - Truma common in children and workers will cause rupture globe when suture 1- it will heal by scar (opacity in cornea) 2- astigmatism by scar infection contact lens
- Hereditary
 - Corneal dystrophies above your level
 - **Keratoconus** القرنية المخروطية

Signs:

- Corneal scar.
- Bulging cornea.
- Stromal opacities.
- Patients might have some conjunctival injection with chronicity
- ± chronic eye irritation



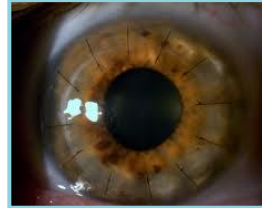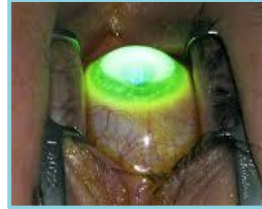MCQ : 1- most common cause of Microbial keratitis in young patient is **contact lens** and The most common organism in contact lens wearer is **pseudomonas**

- 2- Keratoconus with corneal ulcer > will cause **irregular astigmatism**
- 3- you can diagnose the patient by asking the patient to look down and will see s **Munson's sign**
- **Munson's sign** is a V-shaped indentation observed in the lower eyelid when the patient's gaze is directed downwards Develop In advance keratoconus.

Causes of Chronic Visual Loss

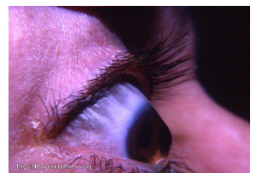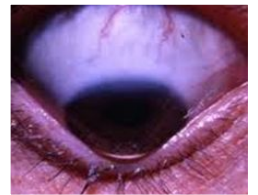Treatment:

- Refraction
- Contact lens (soft or hard (for Keratoconus) better for irregular cornea because it will maintain its shape)
- Corneal cross linking.
- Keratoplasty زراعة القرنية (Last option)
 - A cornea is taken from a donor & is implanted in a recipient eye,
 - There are 3 types:
 - Penetrating keratoplasty: implanting all layers of cornea.
 - Lamellar Keratoplasty: transplanting only the stromal and bowman layers.
 - Indications:
 - Keratoconus without scarring or with anterior stromal scarring.



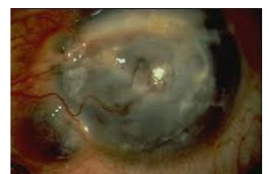Keratoconus:

- What is the sign? **Munson's sign (MCQ)** is a V-shaped indentation observed in the lower eyelid when the patient's gaze is directed downwards Develop In advance keratoconus
- It is impossible for someone with keratoconus to have hyperopia
- When the lid margin bulges down when someone looks down, this is a sign called Munson's sign that occurs with advanced Keratoconus.
- Advanced keratoconus:
 - Irregular myopic astigmatism.
 - Munson's sign.
 - Apical scarring.



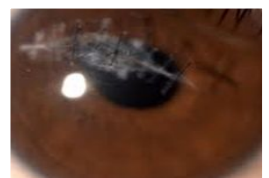
Chronic inflammatory process → chronic vascularization → scarring = Stromal opacities

- Usually the cornea is Avascular tissue so once you have vascularity reaching the cornea you will have leakage of inflammatory mediators → scarring and lipid deposit



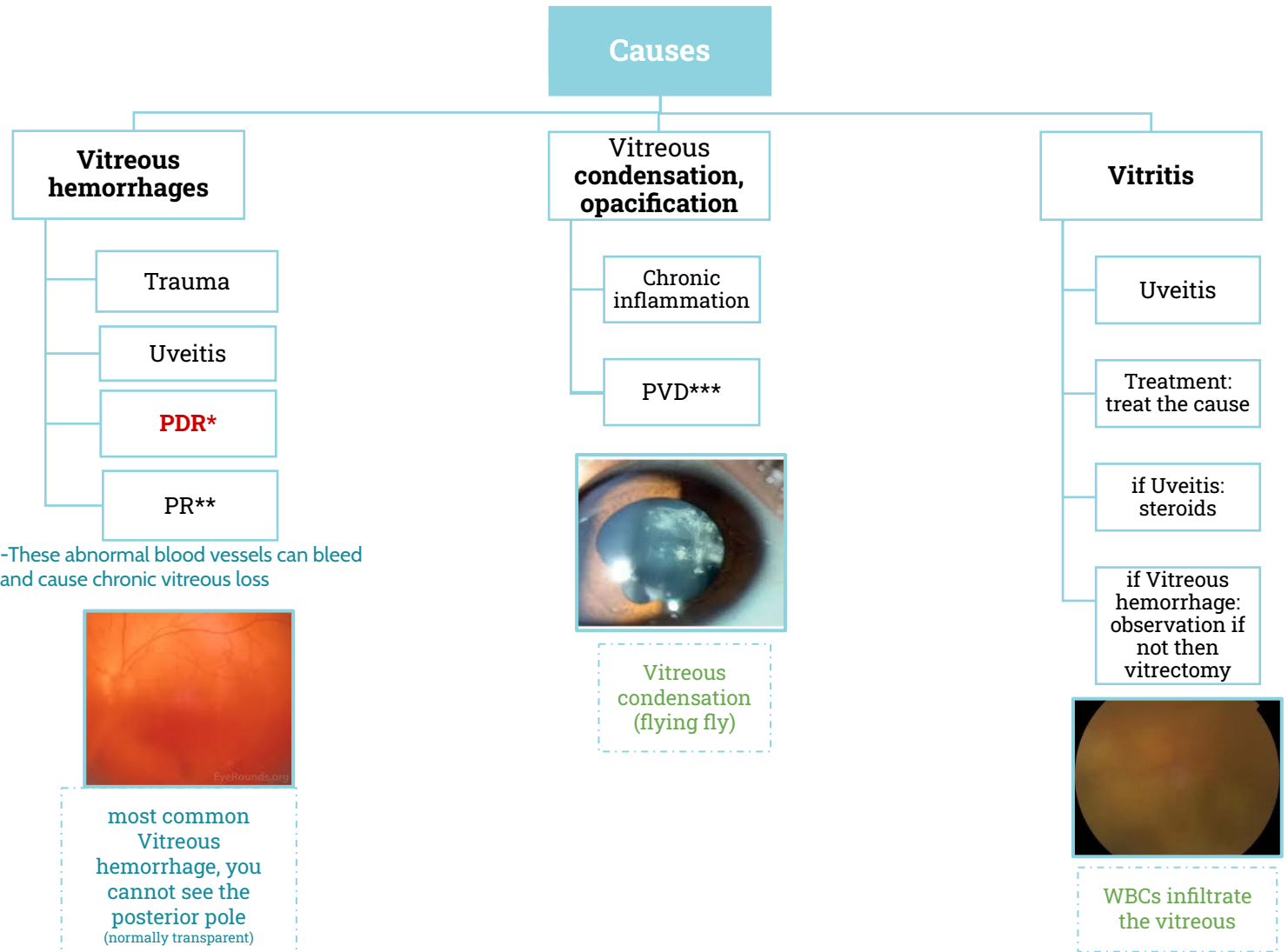
Corneal scar

- Penetrating globe injury → underwent primary repair → suturing the wound → ended up by corneal scar.
- The scarring isn't the issue here you need to maintain the integrity of globe.
- **MCQ: Sometimes the scar is central, within the pupillary area, so corneal haze will obscure the entry of light rays within the pupil, resulting in astigmatism and a barrier toward full light entry through the pupil.**
- **Also, infection. MCQ: If you are a contact lens wearer, you might have a corneal ulcer (microbial keratitis) M. The most common organism in contact lens wearer is pseudomonas. It causes a very rapid corneal perforation**



Causes of Chronic Visual Loss

8 Vitreous



Treatment:

- by treating the underlying cause
- Example : vitreous hemorrhage you will wait if not clear will do vitrectomy

* PDR (Proliferative diabetic Retinopathy) DM is the most common cause
 ** PR (Proliferative retinopathies in general) like Sickle cell retinopathy
 ***PVD (Posterior vitreous detachment)

EXTRA

Dr. Essam Note 437 Imp for the exam

- **What other symptoms will appear to a patient with chronic visual loss?**
 - Increase in severity
 - Loss of visual acuity or field
 - Involves both eyes -> loss of daily function
 - HE WILL NOT HAVE :
 - NO PAIN (ACUTE)
 - NO RED EYE (ACUTE)

- **How do we see a candle or a car?**
 - Light rays reflected off of the candle in divergence fashion and it will pass freely the cornea -> lens-> focused in the macula.
 - Divergence: light will fan out or spread (in nature, light is always divergence)
 - Convergence : is the physical joining together of light rays. Light rays tend to come together at a point (called point of convergence) from different directions. ex. magnifier

- **What provides the eye with refraction?**
 - Cornea 40 diopters
 - Lens 20 diopters (More important than cornea. Due to accommodation, it can provide up to 40 diopters)

- **What is the average dioptric power of the eye?**
 - 60 diopters

- **Name conditions that can disturb the ocular medium (increases opacity)?**
 - Cataract

- **What are the indications of cataract surgery?**
 1. The patient needs. For example, an engineer or an IT whose work got affected by his condition.
 2. Visual loss.
 3. Therapeutic indications, which means we remove the lens to treat other diseases. Like age-related macular degeneration or diabetic retinopathy. For example, in diabetic retinopathy we might not be able to see the retina bc of the lens so we remove them to treat the retina.
 4. When the lens complicate (Cataract causing Phacomorphic or Phacolytic Glaucoma)

- **How can the cataract cause glaucoma?**
 - When the lens increase in size, it pushes the iris and make pupillary block and angle closure, it's called (Phacomorphic Glaucoma).
 - In leaking mature or hypermature cataract, the protein leaks from the lens into the anterior chamber, it causes anaphylactic reaction, so the macrophages will block the trabecular meshwork >reduce the drainage > leading to secondary open angle glaucoma, (Phacolytic Glaucoma).

EXTRA

Dr. Essam Note 437 Imp for the exam

- **What is the most important risk factor for Diabetic retinopathy?**
 - Duration of diabetes, (Controlling the diabetes has its effect on the development but not as the duration).
- **What are the types of diabetic retinopathy? And what is the treatment?**
 - Proliferative with or without macular edema.
 - Treatment: Pan-retinal Photocoagulation (PRP).
 - Non-proliferative with or without macular edema.
 - Treatment: observation/no treatment.
 - Treatment of macular edema: Focal & Grid laser, anti
 - VEGF injections (Avastin, Lucentis, Eylea).
- **How does the PRP work?**
 - The laser changes the ischemic retina to anoxic retina and this will decrease the vascular endothelial growth factor responsible for the formation of new vessels > stops the neovascularization.

Lecture Quiz

Q1- A 45-year-old male with a history of renal transplant on steroid therapy complaining of gradual painless diminution of vision both eyes, on examination there is lens opacity.

What is the most likely type of cataract?

- A. Cortical cataract.
- B. Nuclear cataract.
- C. Posterior subcapsular cataract
- D. Dot cataract

Q2- A girl who came to the ER with redness and swelling after wearing her sister's lenses. The culture came as gram negative rods, what's the organism?

- A. E.coli
- B. Pseudomonas aeruginosa
- C. Chlamydia trachomatis
- D. Yersinia

Q3 - A 20-year-old male is complaining of a gradual decrease in visual acuity for the last 5 years. On examination: red reflex was present, ophthalmoscopy showed diffuse peripheral retinal pigmentary changes, attenuated vessels, and pale discs. What is the earliest manifestation of this disease?

- A. Central visual loss
- B. Metamorphopsia
- C. Loss of color vision
- D. Nyctalopia

Q4- A 45-year-old patient has type 1 diabetes for 25 years, his H_{A1C} is 7. Lipid profile is normal. Which of the following increases the risk of having retinopathy?

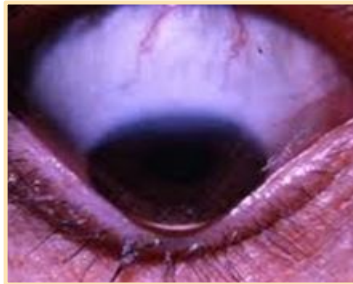- A. Hyperlipidemia
- B. High glucose level
- C. Duration of diabetes
- D. Blood pressure level

Q5- Which of the following is not true about exudative "wet" age-related macular degeneration

- A- Lipofuscin deposits
- B. Subretinal fibrosis
- C. Central scotoma
- D. neovascularization

Short Answer Questions

Case 1



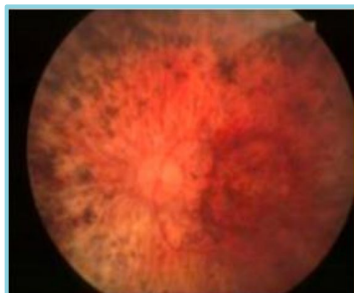
A: What is the sign shown in this picture?

B: What is the diagnosis?

C: Mention 2 other findings indicate advanced disease?

Case 2

A 33 year old male complaining of gradual visual loss in peripheral field, difficulty in night vision, eye examination shown below:



A: Mention 2 abnormal findings?

B: What is the diagnosis?

C: What is the treatment?

Answers:

Case 1

A: Munson's sign

B: Keratoconus

C: 1. Apical scarring 2. Irregular myopic astigmatism

Case 2

A: 1. Bone spicules 2. Waxy disc appearance

B: Retinitis pigmentosa

C: Carbonic anhydrase inhibitors

This work was originally done by 438 and 439 Ophthalmology Team

Edited by 441 Ophthalmology Team

Team leaders:

Abdullah Aldayel

Ibrahim Aljurayyan

Sultan Alosaimi

Members:

Bassam Ahmed

Note Takers:

Abdulrahman Badghaish

Faisal Alsaawi

