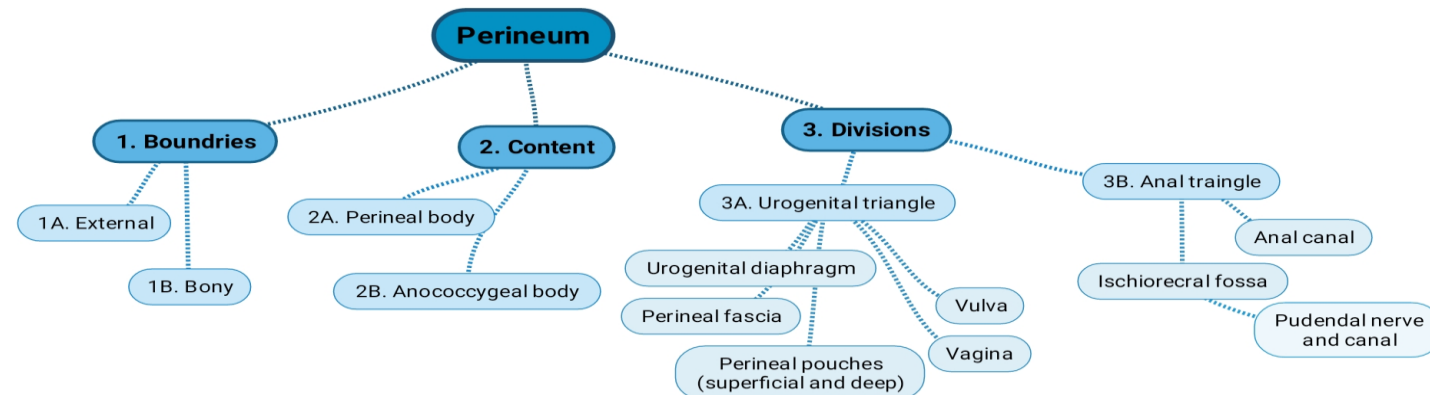


Objectives

At the end of the lecture, the student should be able to describe the:

- ✓ Boundaries of the perineum.
- ✓ Division of perineum into two triangles.
- ✓ Boundaries & Contents of anal & urogenital triangles.
- ✓ Lower part of Anal canal.
- ✓ Boundaries & contents of Ischioirectal fossa.
- ✓ Innervation, Blood supply and lymphatic drainage of perineum.

Lecture
Outline →



Introduction:

- The trunk is divided into 4 main cavities: thoracic, abdominal, pelvic, and perineal. (see image 1)
- The pelvis has an inlet and an outlet. (see image 2) The lowest part of the pelvic outlet is the perineum.
- The perineum is separated from the pelvic cavity superiorly by the pelvic floor.
- The pelvic floor or pelvic diaphragm is composed of muscle fibers of the levator ani, the coccygeus muscle, and associated connective tissue. (see image 3) We will talk about them more in the next lecture.

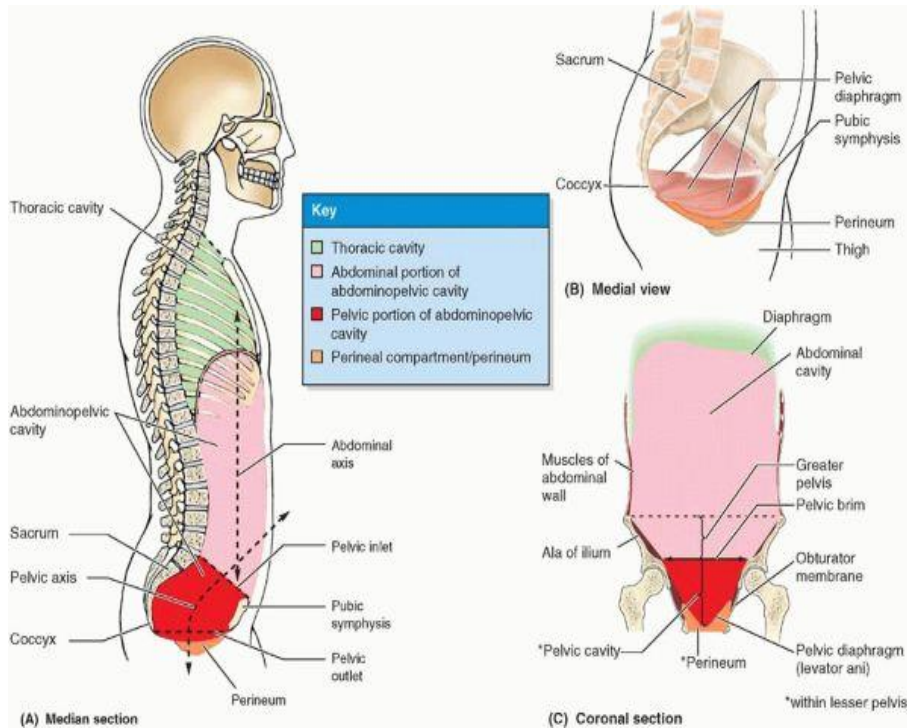


Image (1)

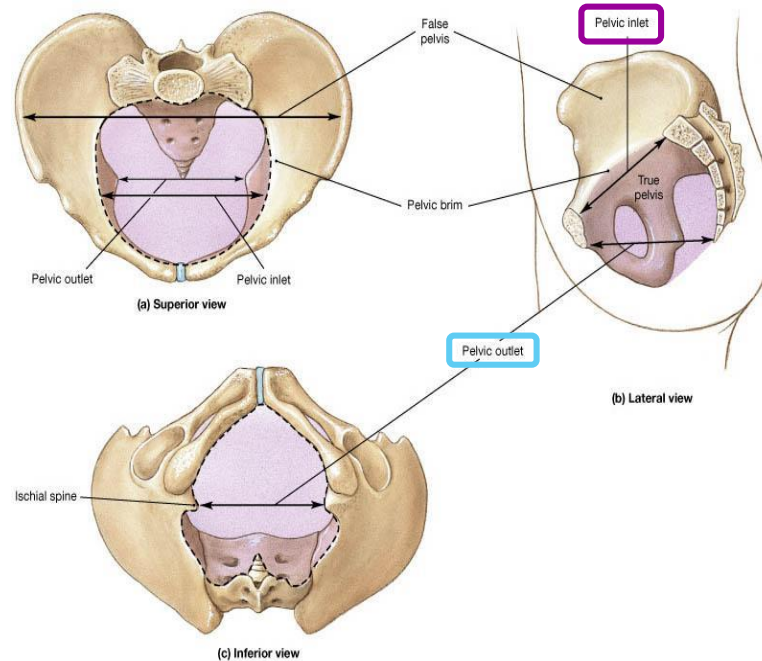


Image (2)

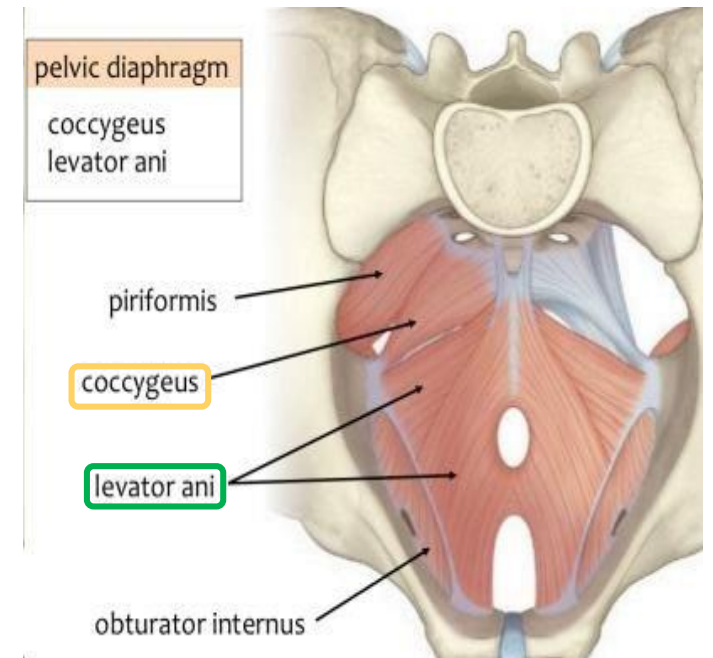


Image (3)

Note: this image is seen from ABOVE

Perineum

(In this lecture the **boundaries** and **relations** are important)

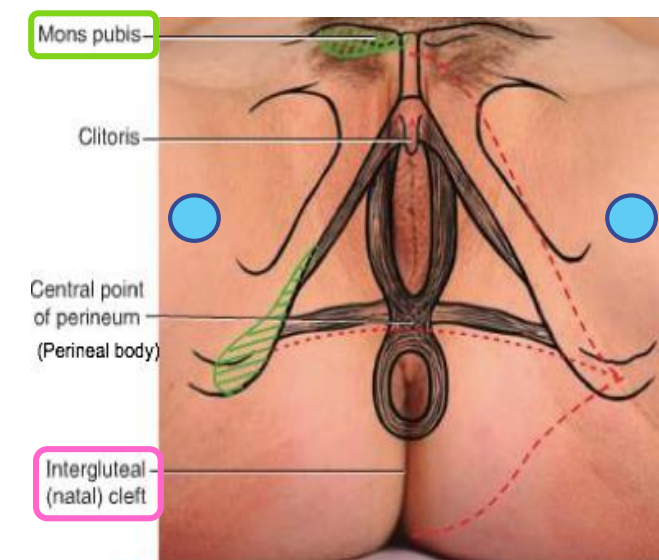
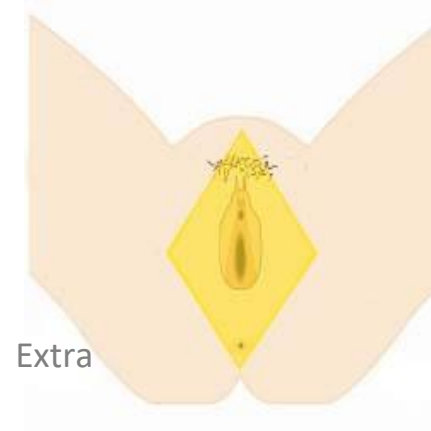
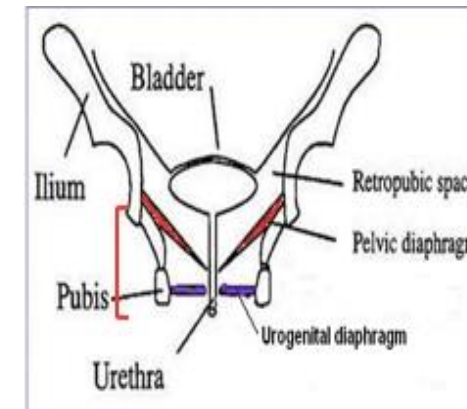
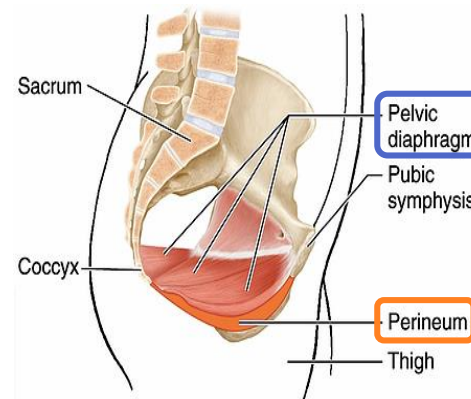
- Perineum is the region of the body below the pelvic diaphragm (The outlet of the pelvis)
- It is a diamond shaped area between the thighs.

Boundaries: (these are the external or surface boundaries)

Anteriorly	Laterally	Posteriorly
Mons pubis	Medial surfaces of the thighs	Intergluteal folds or cleft

Contents:

1. Lower ends of urethra, vagina & anal canal
 2. External genitalia
 3. Perineal body & Anococcygeal body
- (we will now talk about these in the next slides)



■ Palpable bony structure
 - - - - Outline of perineal region
- - - - Line dividing perineal region into urogenital triangle (anterior to line) and anal triangle

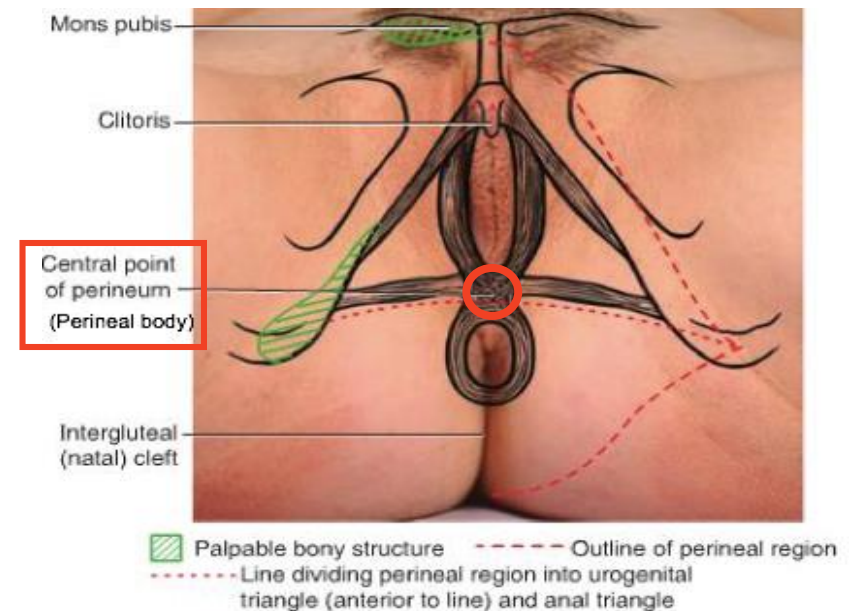
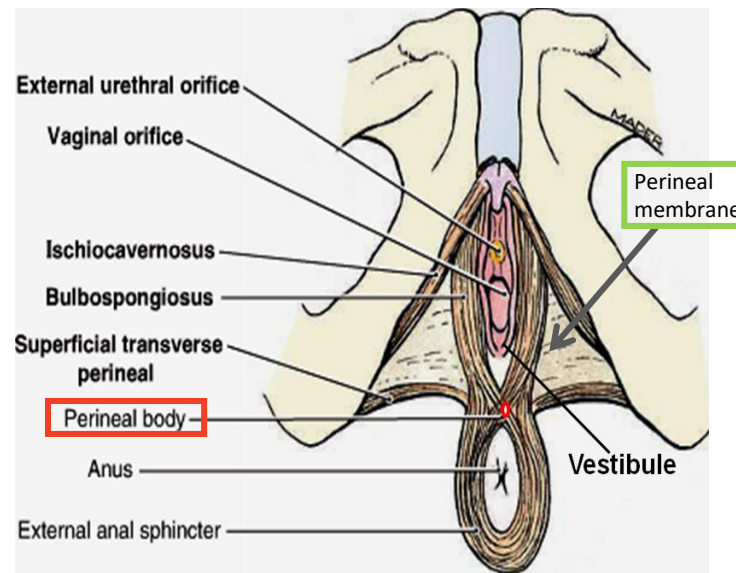
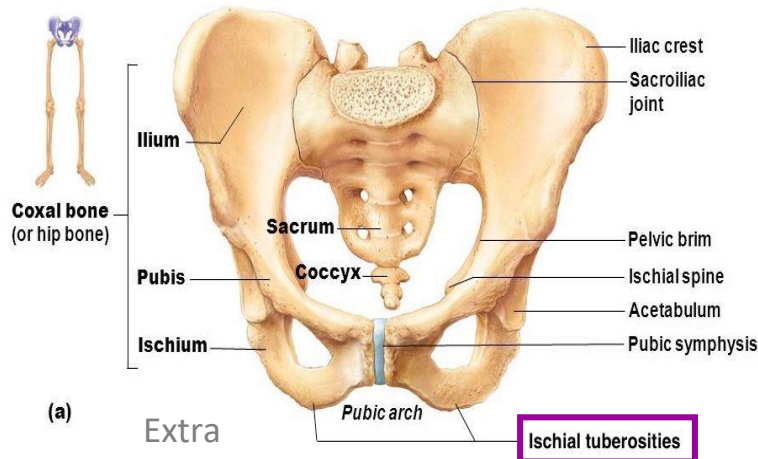
Perineum

Perineal body

- Perineal body is an irregular fibromuscular mass of variable size and consistency, located at midpoint of the line between the ischial tuberosities.
- Lies in the **subcutaneous** tissue, posterior to vaginal vestibule and anterior to the anal canal & anus
- Forms the central point of the perineum & blends anteriorly with the perineal membrane

Function:

1. Gives **attachment** to perineal muscles
2. Plays an important role in visceral support especially in female

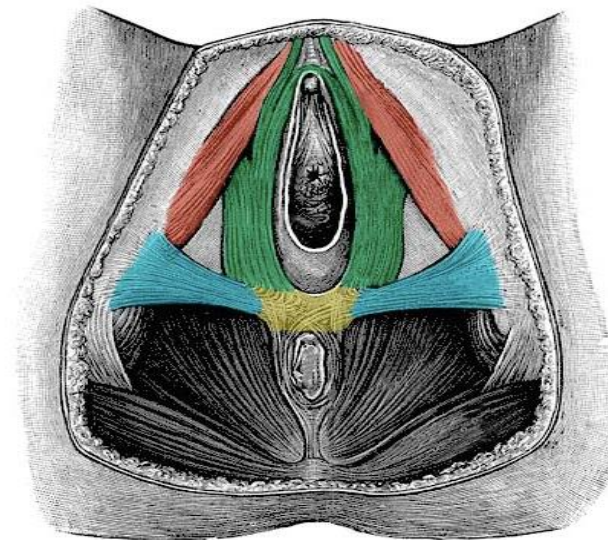
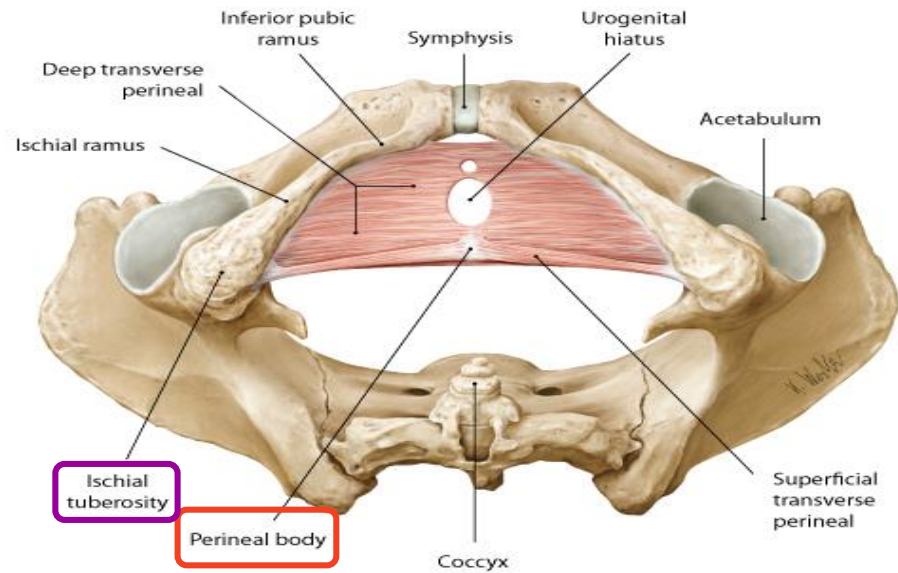
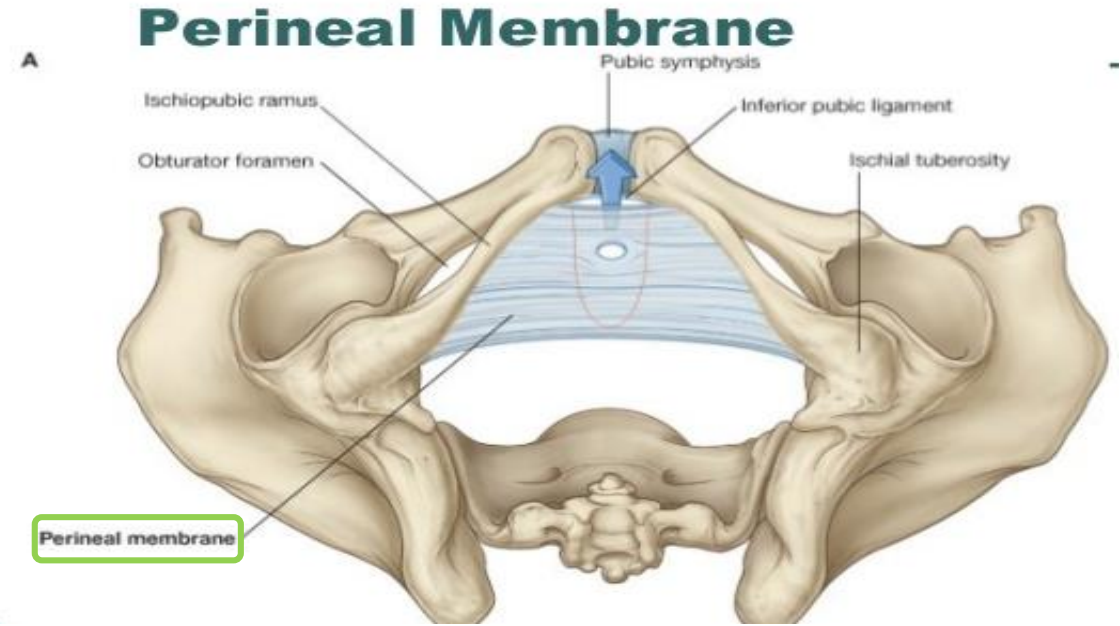
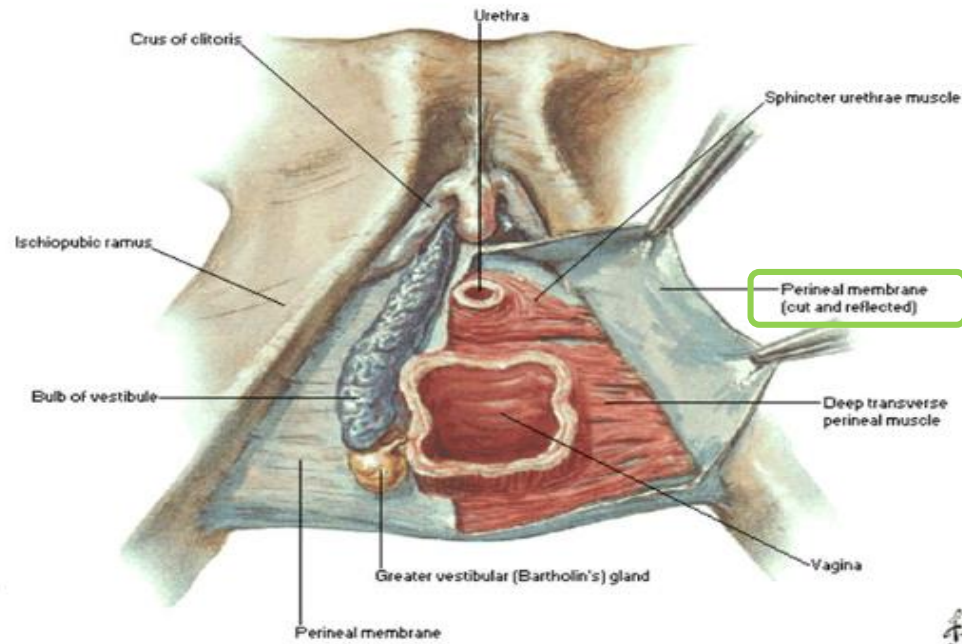


Extra explanation:

The **perineal body** is an irregular fibromuscular mass. It is located at the junction of the urogenital and anal triangles – the central point of the perineum. This structure contains skeletal muscle, smooth muscle and collagenous and elastic fibres.

Anatomically, the perineal body lies just deep to the skin. It acts as a point of **attachment** for muscle fibres from the pelvic floor and the perineum itself

These pictures are extra.

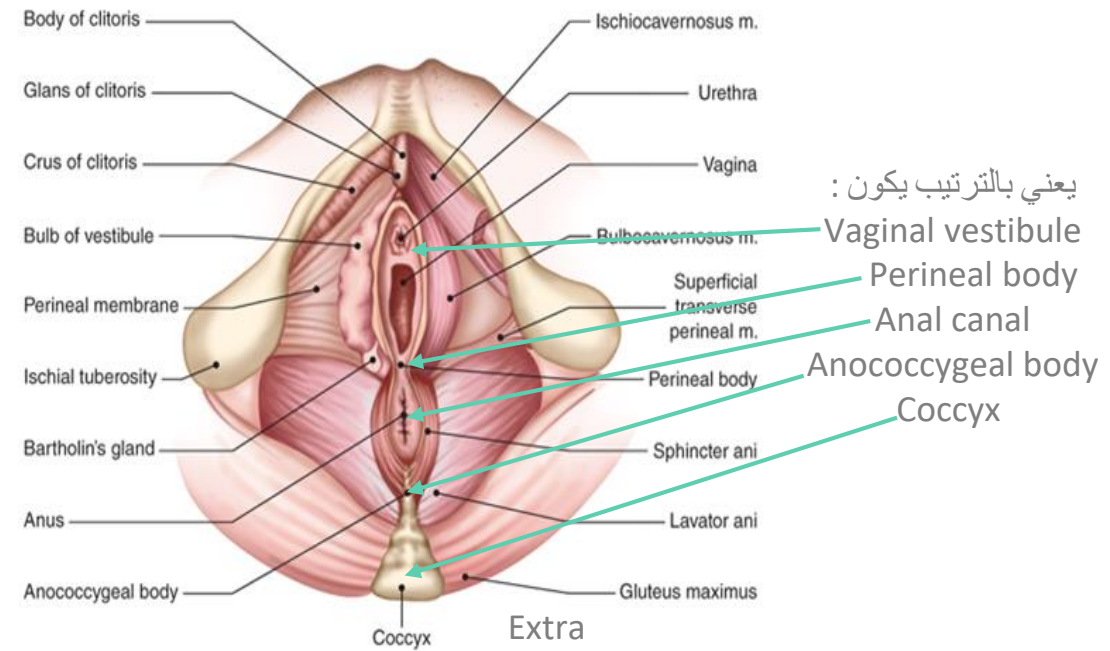
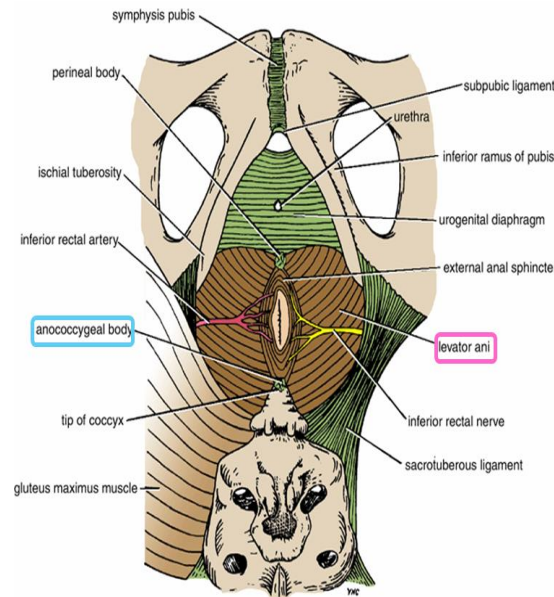
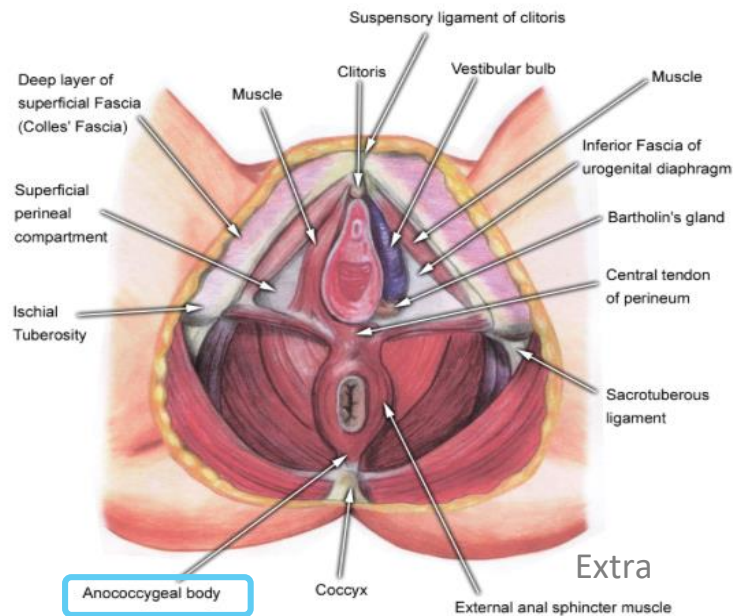


- Perineal body
- Ischiocavernosus
- Bulbocavernosus
- Transverse perineal

Perineum

Anococcygeal Body

- The anococcygeal body is a complex **musculotendinous** structure (more tendinous).
- Situated between the anterior aspect of the **coccyx** and the posterior wall of the **anorectal canal**
- Receives insertion of fibers of levator ani muscle (gives attachment of levator ani muscles).

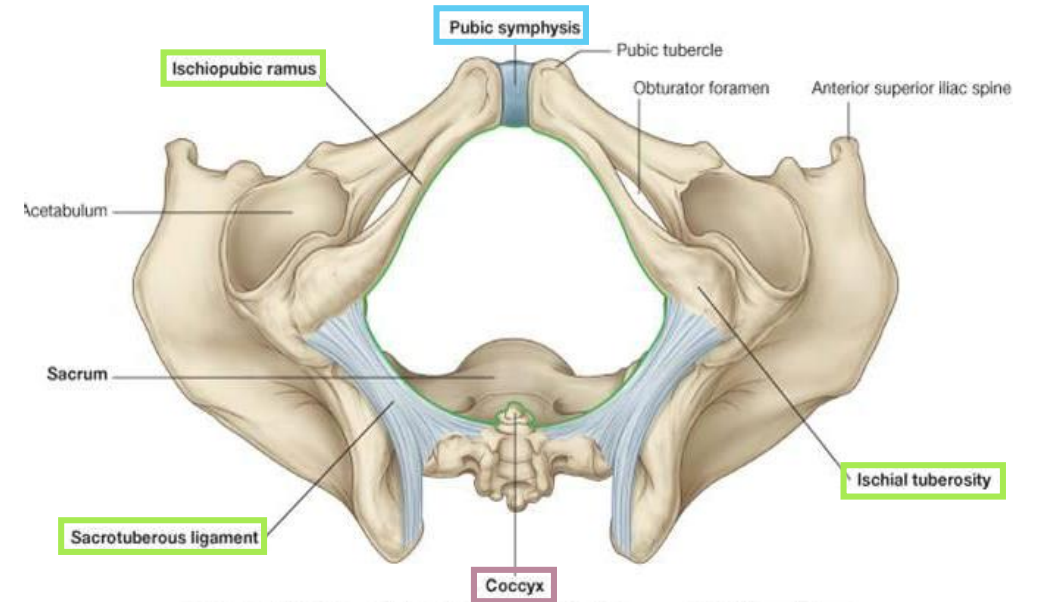


Perineum Divisions

Boundaries:

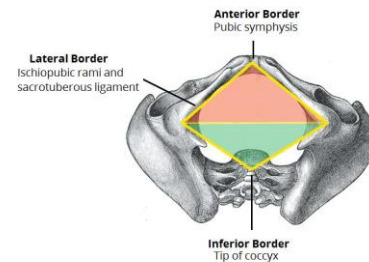
- Its **bony** boundaries are:

Anteriorly	Laterally	Posteriorly
Symphysis pubis	Ischiopubic rami, ischial tuberosities & sacrotuberous ligaments*	Coccyx

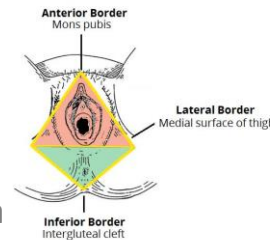


Note the perineum has bony boundaries and surface or external boundaries: →

Anatomical Borders:



Surface Borders:



Extra

* ligament between sacrum and ischial tuberosity

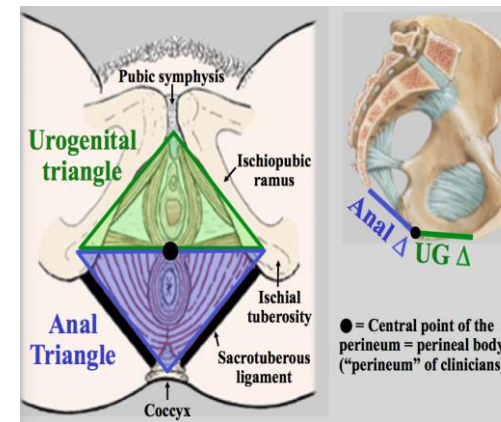
** this is the same line that passes through the perineal body

Division:

- By an imaginary line** passing through two ischial tuberosities, it is divided into:

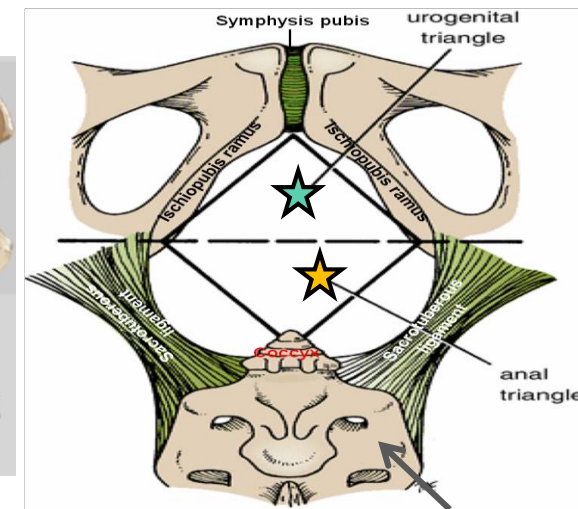
- I. Urogenital triangle anteriorly.
- II. Anal triangle posteriorly.

In the next slides we will talk about the **urogenital** triangle in detail.



● = Central point of the perineum = perineal body ("perineum" of clinicians)

Extra



Sacrum

1. Urogenital Triangle

Boundaries:

Anteriorly	Laterally	Posteriorly
Symphysis pubis	Ischiopubic rami & ischial tuberosities	Transverse line passing through the 2 ischial tuberosities

Contents:

1. Lower part of urethra & vagina.
2. External genitalia (vulva).
3. Urogenital diaphragm

The urogenital triangle : is associated with the structures of the urogenital system – the external genitalia (genital part) and urethra (urinary part).

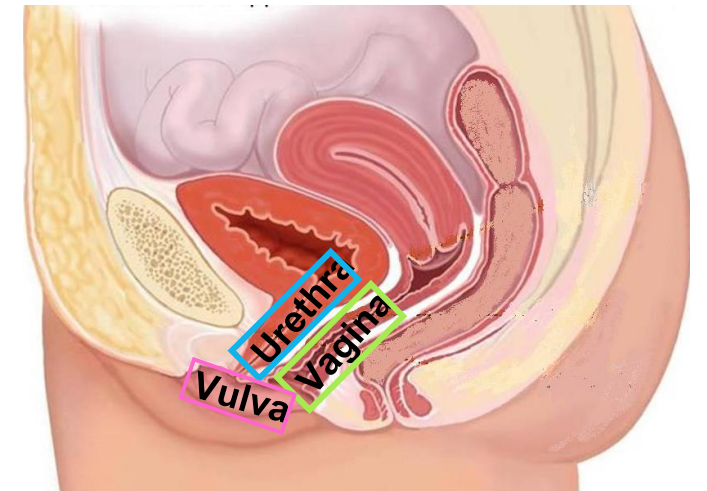
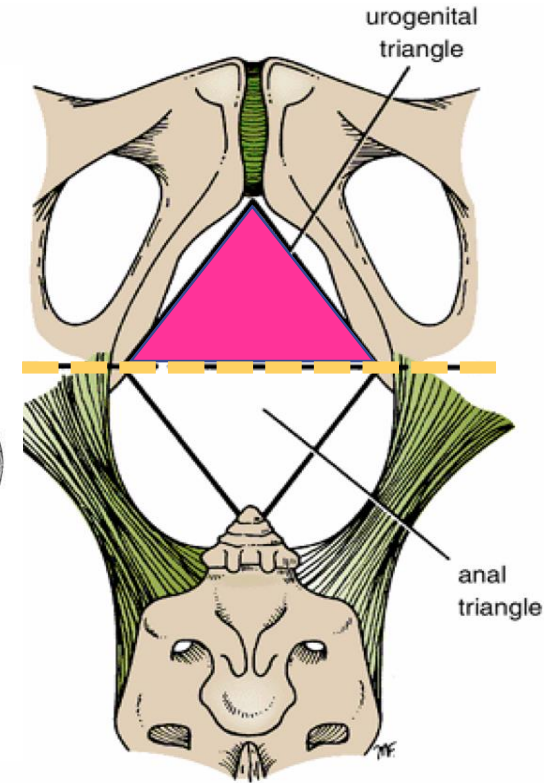
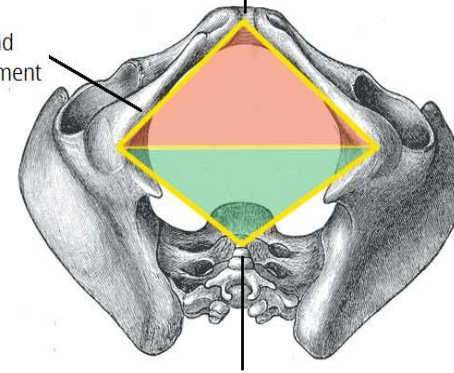
Anatomical Borders:

Lateral Border
Ischiopubic rami and sacrotuberous ligament

Extra

Anterior Border
Pubic symphysis

Inferior Border
Tip of coccyx



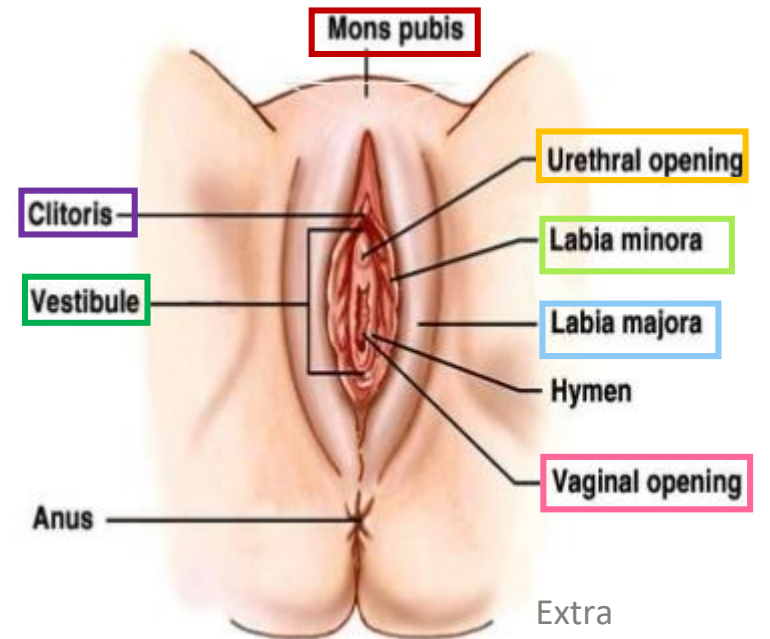
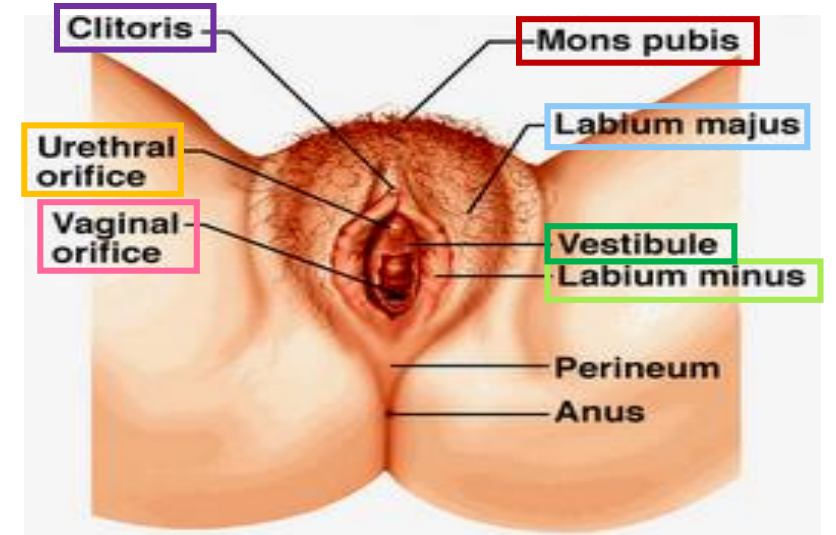
I. Urogenital Triangle

Female External Genitalia (Vulva)



The external genital organs of the female are collectively known as the **vulva** (also called the pudendum). The vulva is comprised of many different structures:

1. **Mons pubis**: a collection of fat overlying the pubes
2. **Labia majora** (*labia means lips or flaps*).
3. **Labia minora**.
4. **Clitoris** (*the two labia minora meet at a point anteriorly and make the clitoris*).
5. **Vestibule of vagina**: The interval *or area* between the two labia minora *and has 2 openings*:
6. Vagina & urethra open into the vestibule through **urethral orifice** *anteriorly* and **vaginal orifice** *posteriorly*.



Extra Explanation

There are many layers in the urogenital triangle
The first component is the **urogenital diaphragm** which is composed of:

1. Superior layer of fascia of urogenital diaphragm
2. Deep transvers muscle + sphincter urethrae
3. Inferior layer of fascia of urogenital diaphragm: this layer is also called **perineal membrane**.

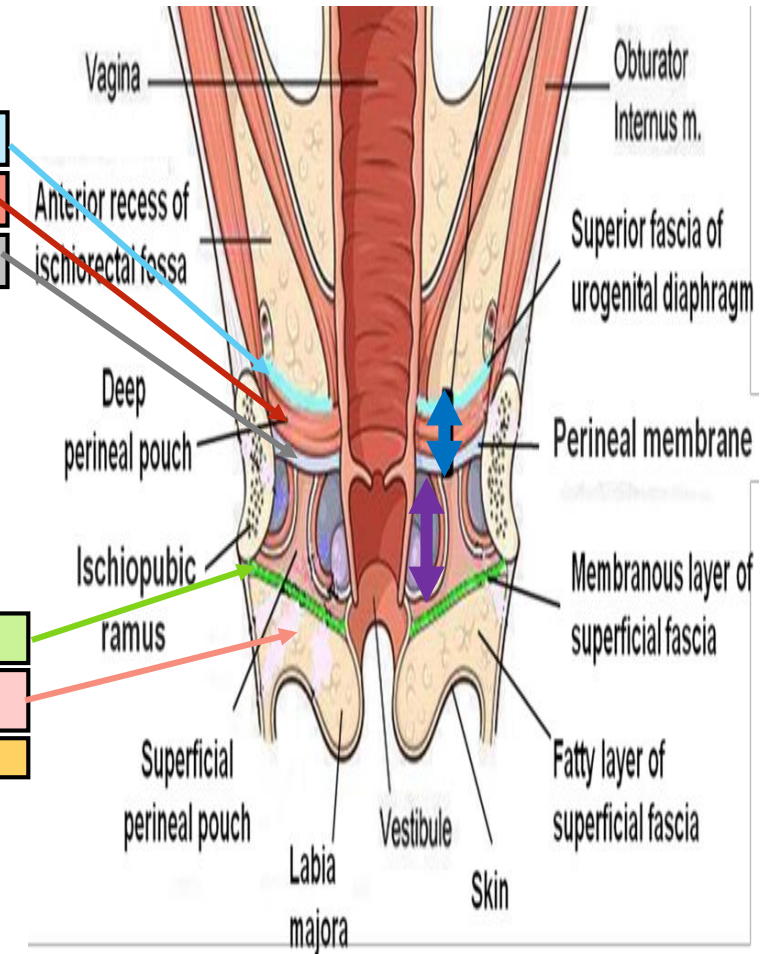
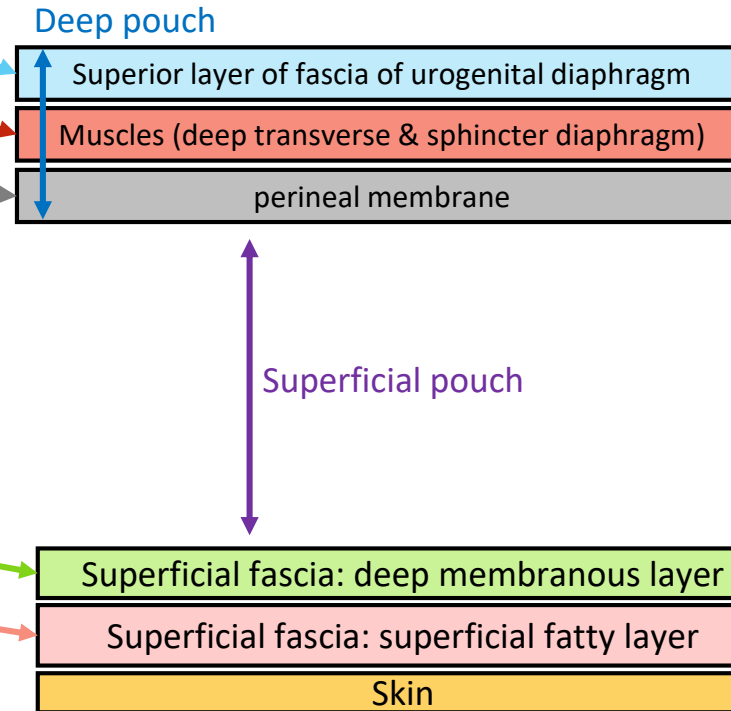
The urogenital triangle extends downwards until the **skin**. Below the skin we have the **perineal fascia** which is divided into:

1. Superficial perineal fascia: further divided into deep membranous layer and superficial fatty layer
2. Deep perineal fascia

NOTE: Remember that the superficial layer is the one closer to the skin.

Next we have the pouches which are above and below the perineal membrane:

The **deep pouch** is basically the same as the urogenital diaphragm (above perineal membrane).
The **superficial pouch** extends below the perineal membrane to the deep membranous layer.



I. Urogenital Triangle

Urogenital Diaphragm

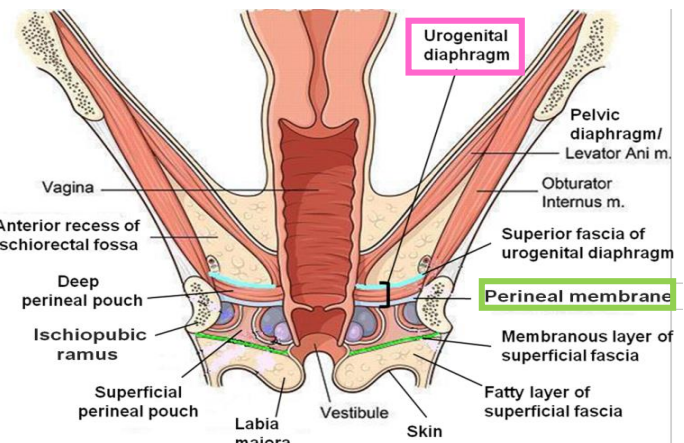
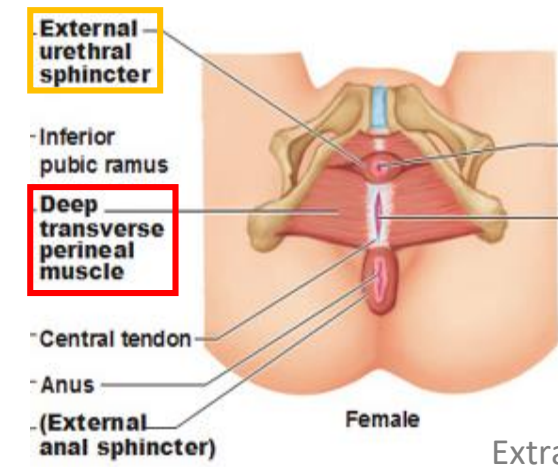
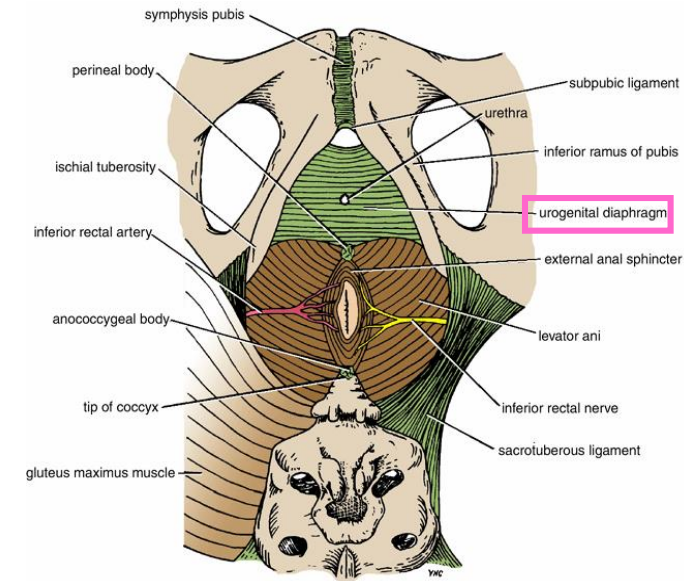
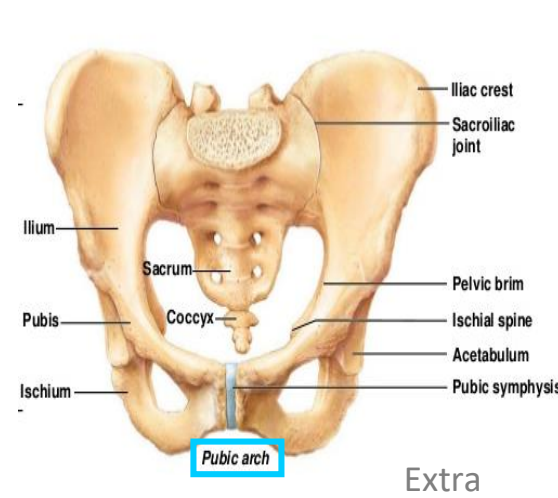
- A triangular **musculofascial diaphragm** located in the anterior part of the perineum (in the urogenital triangle).

- Fills in the gap between the **pubic arch**.

- **Composed of:** musculo-fascial so it has muscles and fascia

- | | | |
|--------|---|--|
| muscle | { | (1) <u>Sphincter urethrae</u> and |
| | | (2) the <u>deep transverse perineal muscles</u> enclosed within |
| fascia | { | (3) the superior and (4) inferior layers of fascia of the urogenital diaphragm (The inferior layer of the fascia is formed by the <u>perineal membrane</u>) |

The fascia cover the muscle from above and below



Note: we have 2 fascia: perineal fascia (superficial and deep) and fascia of urogenital diaphragm (superior and inferior)

I. Urogenital Triangle

Perineal Fascia

Perineal Fascia

Fascia of Urogenital Triangle (Perineal Fascia) is continuous anteriorly with the fascia of abdomen and consists of 2 layers: **superficial** and **deep** layers

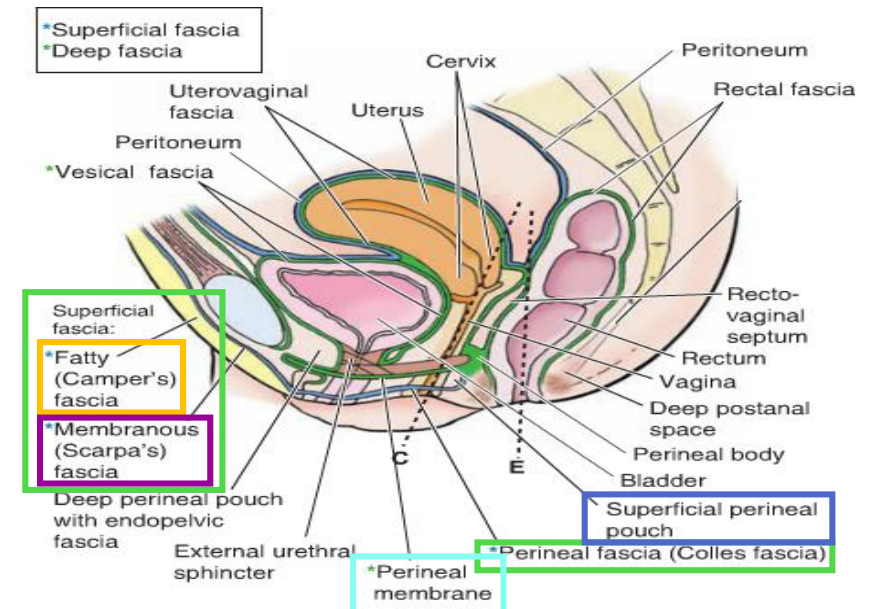
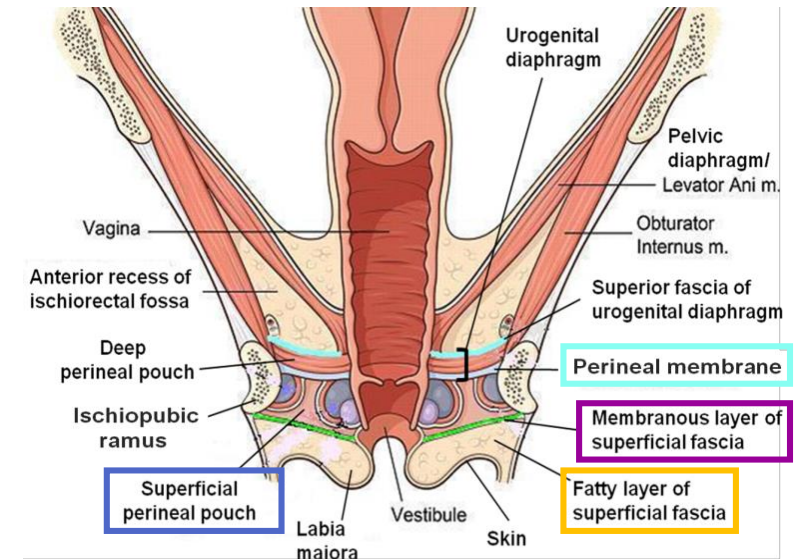
Superficial perineal fascia

Consists of:

- Superficial fatty layer** (Camper's fascia) makes up the substance of mons pubis & labia majora and extends into the anal region.
- Deep membranous layer** (Colle's fascia):
 - Does not extend to anal region.
 - Becomes fused with the posterior margin of the perineal membrane

Deep perineal fascia

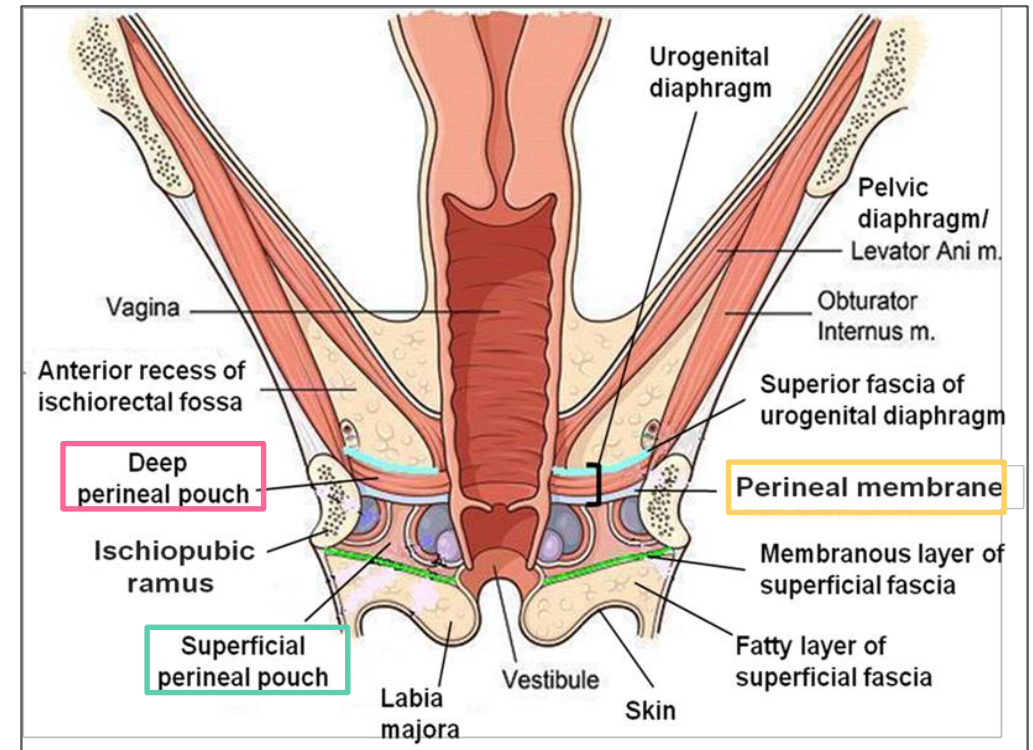
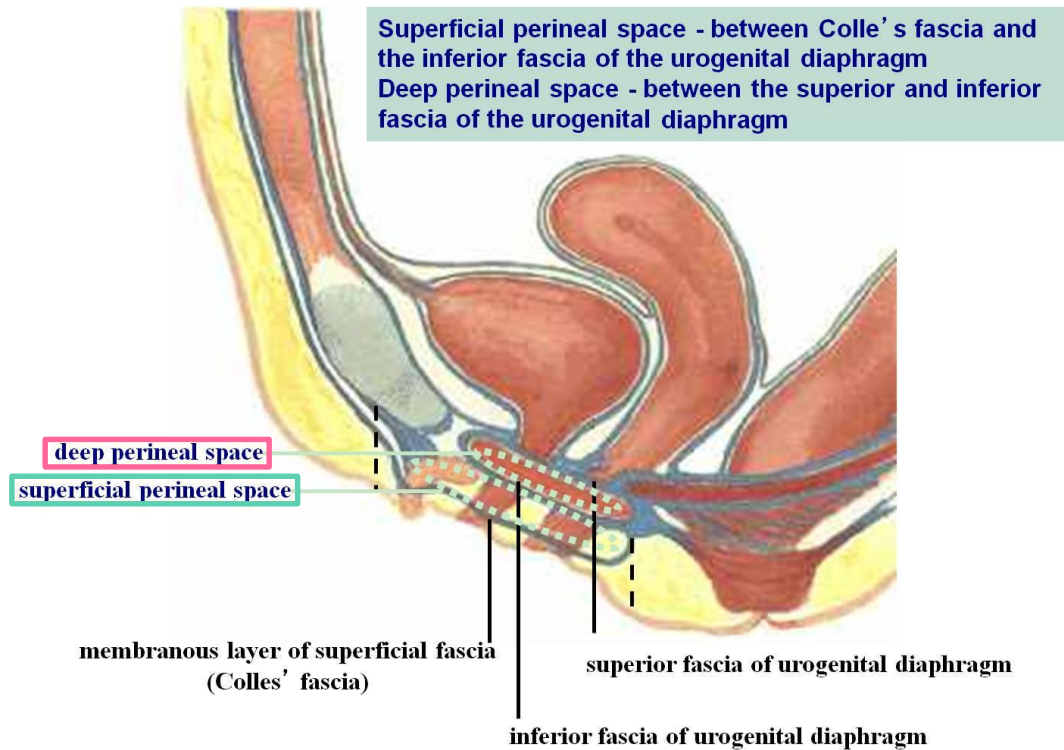
invests the muscles in the superficial perineal pouch (the muscles will be mentioned later)



I. Urogenital Triangle

Perineal Pouches

Structurally, the urogenital triangle is complex, with a number of fascial layers and pouches. Unlike the anal triangle, the urogenital triangle has an additional layer of strong deep fascia; the **perineal membrane**. This membrane has pouches on its superior and inferior surfaces: the **superficial** and **deep** pouches.



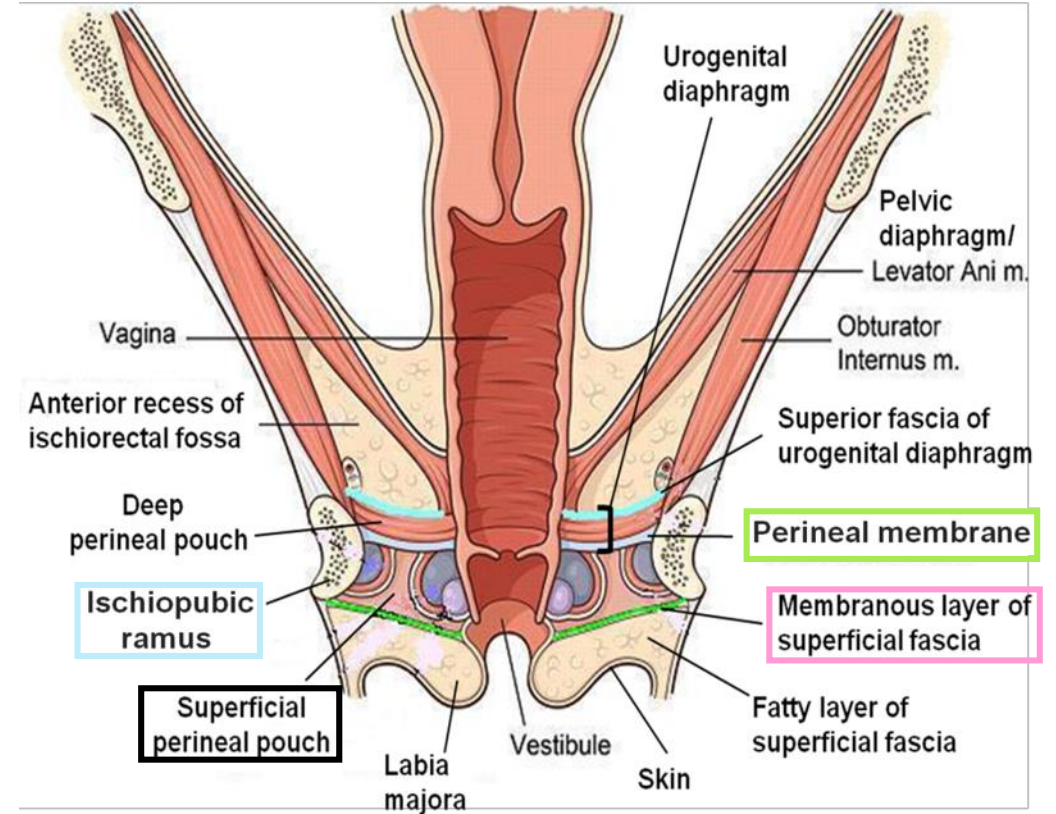
Perineal Pouches

Superficial Perineal Pouch

- It is the **potential space between the deep membranous layer of superficial fascia and the perineal membrane** (inferior fascia of urogenital diaphragm).

- Boundaries:

Superiorly	Laterally	Inferiorly
Perineal membrane	Ischiopubic rami	Membranous layer of superficial fascia (colles fascia)



Perineal Pouches The contents are important.

Contents of Superficial Perineal Pouch

1. Bulbs of vestibule: on each side of vaginal orifice.

2. Crura of clitoris (crura: plural of “crus”)

3. Superficial perineal muscles:

(see slide 6 for a picture of the muscles)

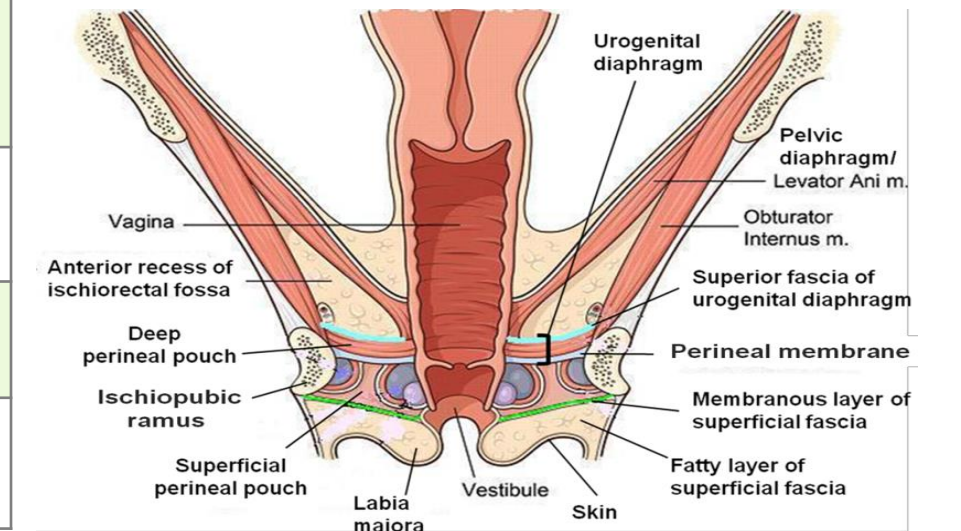
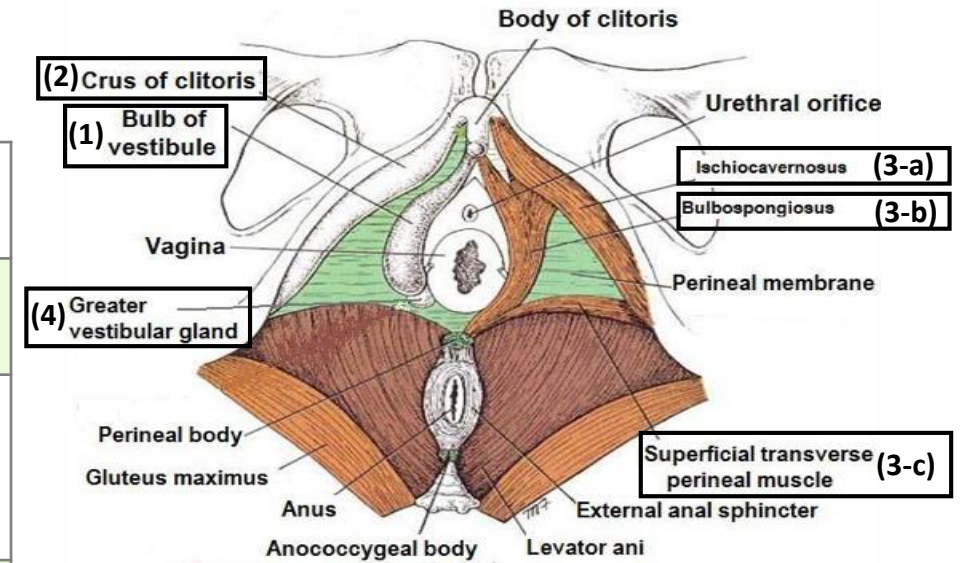
a) Ischiocavernosus muscle:
covers crus of clitoris on each side.

b) Bulbospongiosus muscle:
surrounds orifice of vagina and covers vestibular bulb.

c) Superficial transverse perineal muscles

4. Greater vestibular glands: on each side of vaginal orifice.

5. Perineal branch of pudendal nerve: supplying muscles & skin.



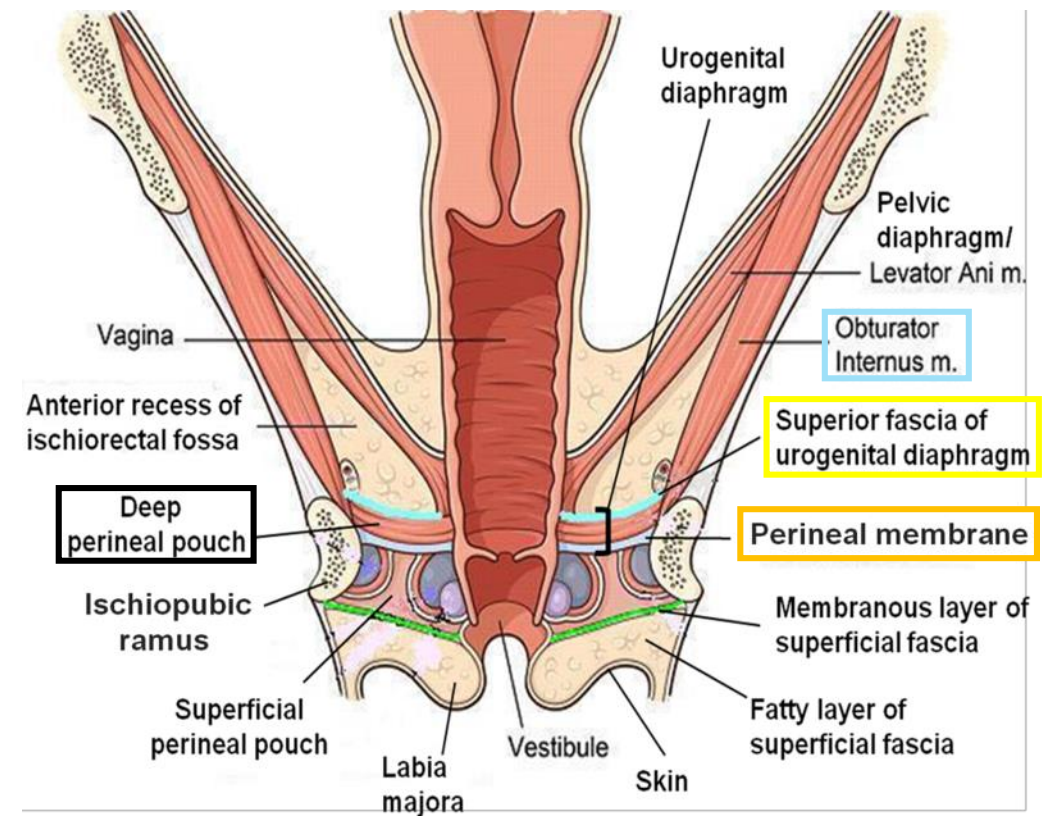
Perineal Pouches

Deep Perineal Pouch

- It is a **completely closed space deep to the perineal membrane.**
- It is the same as the urogenital diaphragm.

○ Boundaries:

Superiorly	Laterally	Inferiorly
Superior fascia of the urogenital diaphragm	Inferior portion of obturator internus fascia	Inferior fascia of the urogenital diaphragm (perineal membrane)



Perineal Pouches

Contents of Deep Perineal Pouch

1. Part of urethra

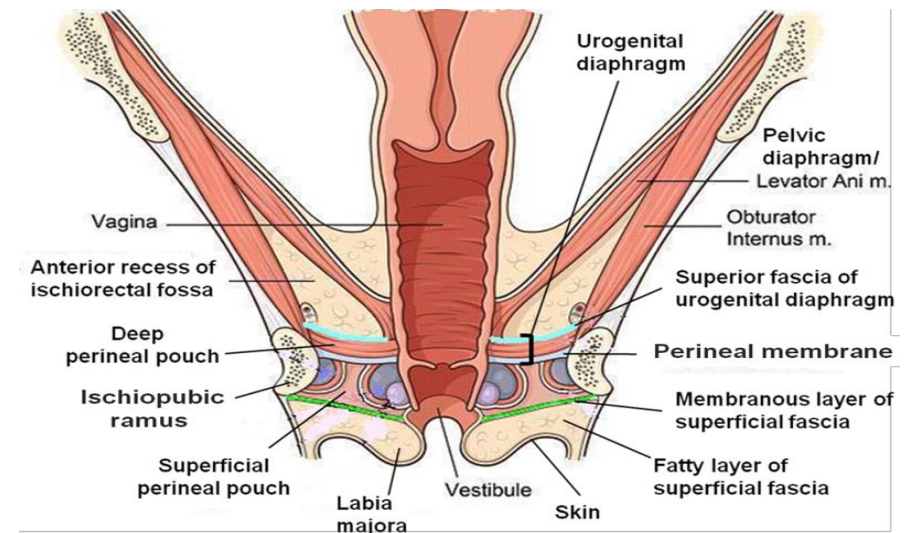
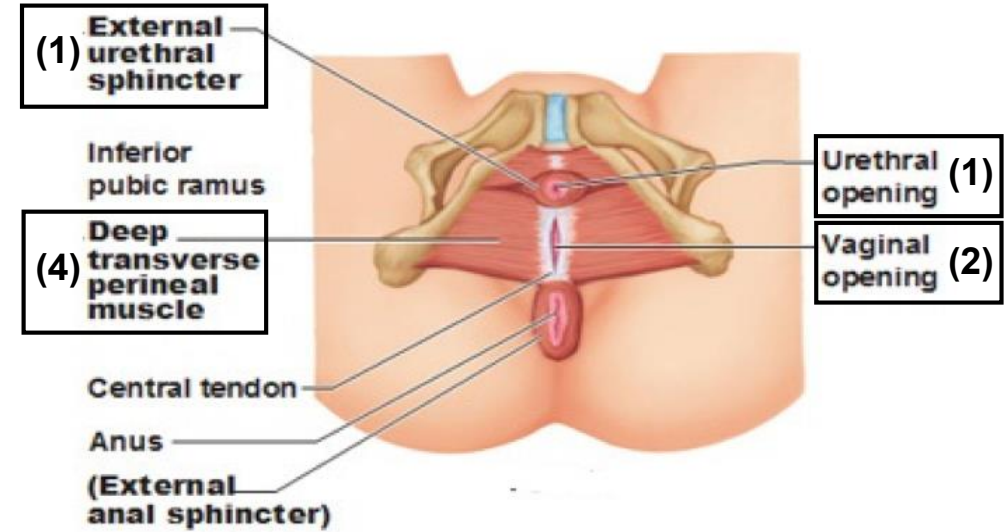
2. Part of vagina

3. Sphincter urethrae and Sphincter vaginae muscles; which is pierced by urethra & vagina.

4. Deep transverse perineal muscles

5. Internal pudendal vessels

6. Dorsal nerve of clitoris



Vagina

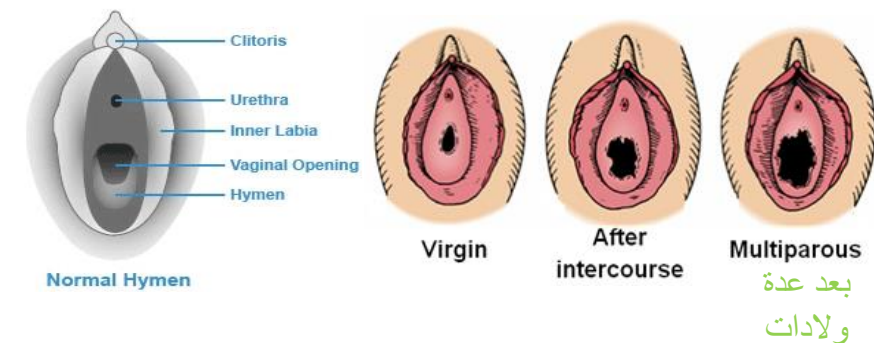
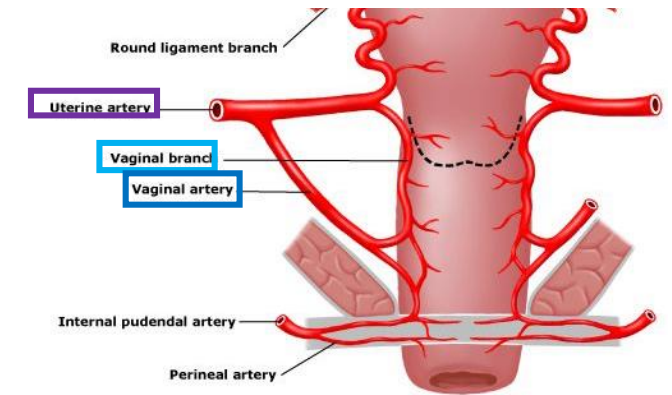
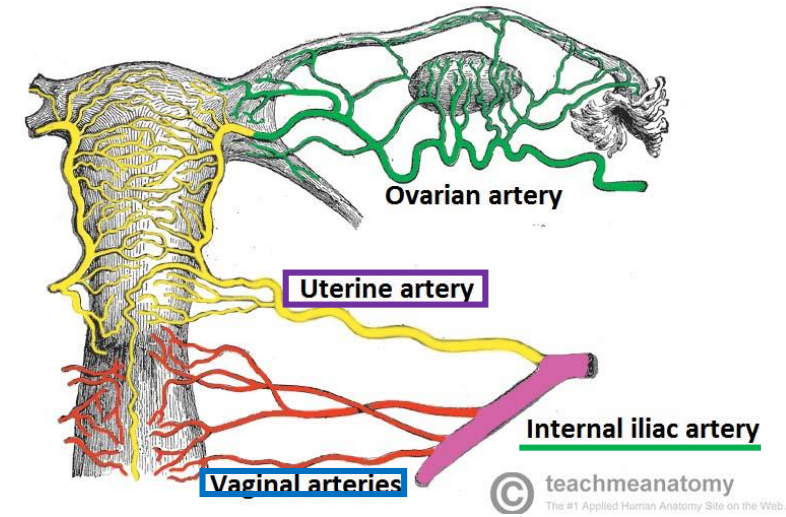
- The vagina is a muscular canal that leads from the **uterus** to the **external orifice** of the genital canal
- It measures about 3 in. (8 cm) long.
- It serves as the excretory duct for the menstrual flow & forms part of the birth canal.
- The **vaginal orifice** in a virgin possesses a thin mucosal fold, called the **hymen** (غشاء العذرية), which is normally perforated at its center to allow the menstrual blood to flow out.

Arteries:

1. Vaginal artery, a branch of the internal iliac artery
2. Vaginal branch of the uterine artery

Veins:

1. drain into the **internal iliac** veins.



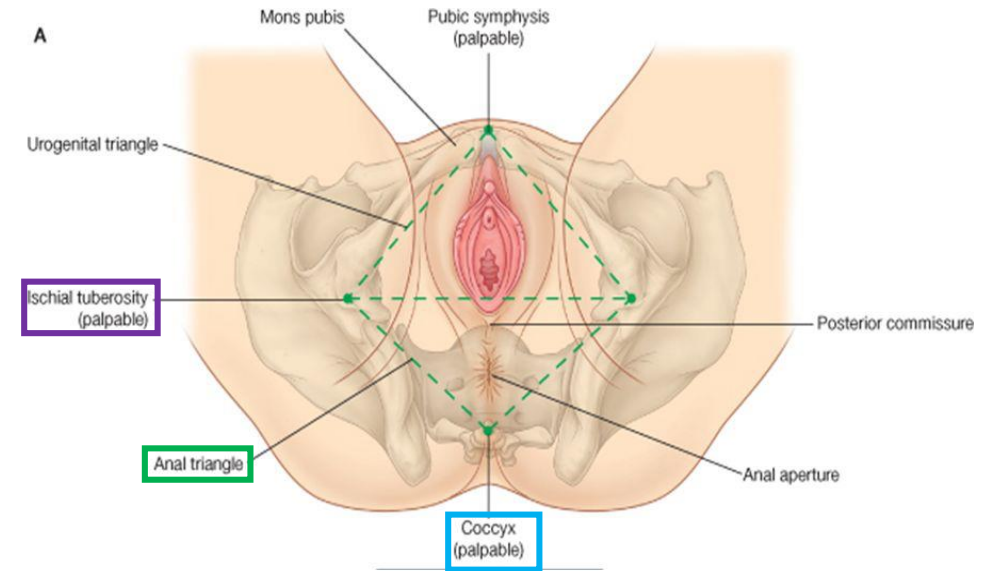
II. Anal Triangle

Boundaries:

Anteriorly	Laterally	Posteriorly
Transverse line passing through the 2 ischial tuberosities	ischial tuberosity & sacrotuberous ligament.	Coccyx

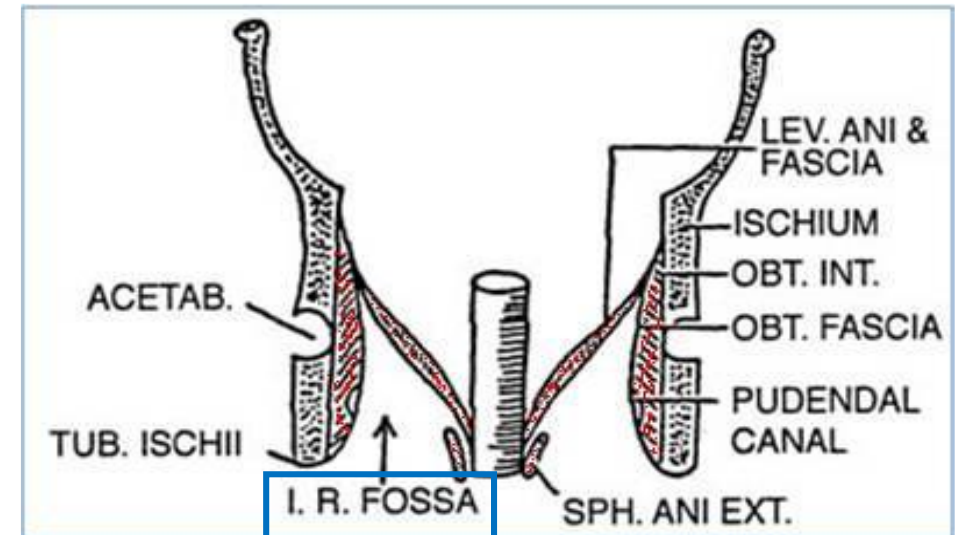
Contents:

1. Lower part of Anal canal
2. Ano-coccygeal body
3. Ischiorectal fossa on each side (will be discussed later)



14-03-2011

4



II. Anal Triangle Anal Canal

- It is about **1.5 in.** long, descending from the rectal ampulla to the anus.

Relations (In female):

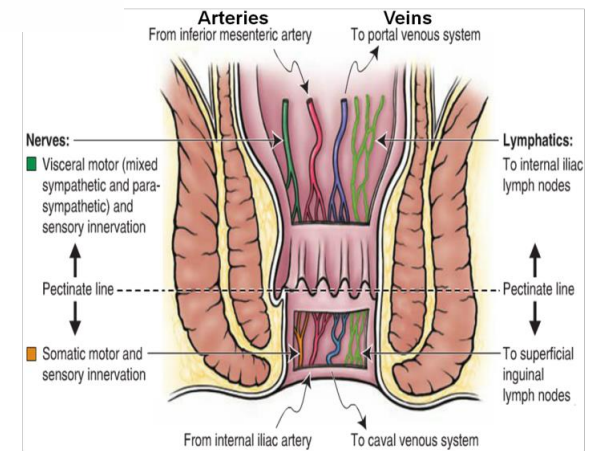
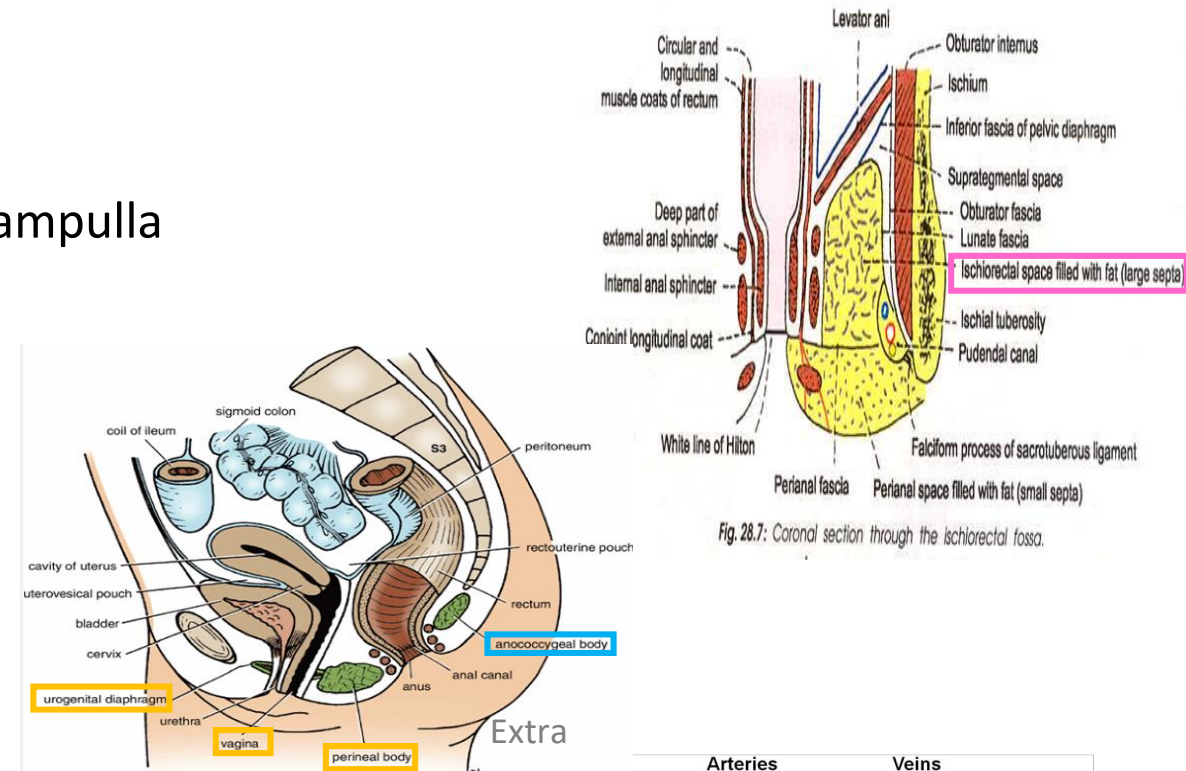
Anteriorly	Posteriorly	Laterally
Perineal body, urogenital diaphragm, lower part of vagina	Anococcygeal body	Ischiorectal fossae

Division: Divided by **pectinate line** into:

1. Upper half: derived from **hindgut*** (**endoderm**)
2. Lower half: derived from the **proctodeum** (**ectoderm**)

The two parts have **different** blood supply, nerve supply and lymphatic drainage.

*remember from GIT block: the artery of the hindgut is the inferior mesenteric artery



Transitions occurring at **pectinate line**.

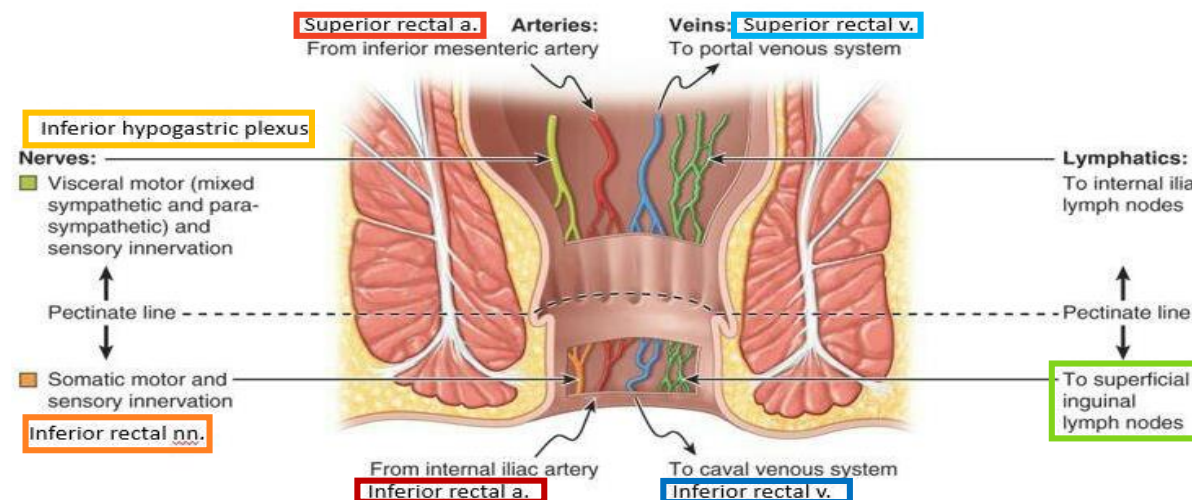
Anal canal	Arterial supply	Venous drainage	Lymphatic drainage	Nerves
Upper half (<u>endoderm</u>)	<u>Superior rectal artery</u> (continuation of the inferior mesenteric artery)	<u>Superior rectal vein</u> drained into the inferior mesenteric vein (portal circulation).	Para-rectal nodes drained into inferior mesenteric lymph nodes	(sensitive to stretch) Visceral^ <u>sensory & motor</u> (Inferior Hypogastric Plexus) (sympathetic & parasympathetic).
Lower half (<u>ectoderm</u>)	<u>Inferior rectal artery</u> (branch of internal pudendal artery)	<u>Inferior rectal vein</u> drained into the internal pudendal vein (Systemic circulation*) site of portal-systemic anastomosis**.	<u>Superficial inguinal lymph nodes</u>	(sensitive to pain) Somatic^ <u>motor & sensory</u> nerves (Inferior rectal N. branch of pudendal N.) supplies: <i>external sphincter muscle</i> of the anus and the <i>skin</i> of the anal region.

The name of the nerves are only mentioned on the girls slides.

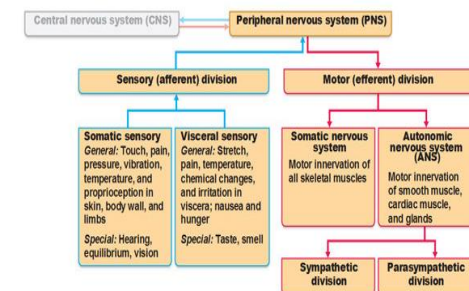
***Clinical importance:**

in children we give medication in the form of suppository (تحميلة) We insert it in the lower half of the anal canal but we shouldn't push it in too deeply because then it will go to the portal instead of the systemic circulation.

**In cases of portal hypertension this will lead to hemorrhoids (بواسير)



^to review the difference between visceral and somatic look at this picture:



II. Anal Triangle Ischiorectal Fossa

- A fascial lined **wedge-shaped** space on each side of the anal canal.

Boundaries:

Base	Medial Wall	Lateral Wall
Skin of the perineum.	Levator ani & anal canal.	Obturator internus, covered with fascia.

Contents:

1. Dense fat.
2. **Pudendal nerve** & **internal pudendal vessels** within the **pudendal canal**.
3. **Inferior rectal** nerve & vessels crossing the fossa to reach anal canal.

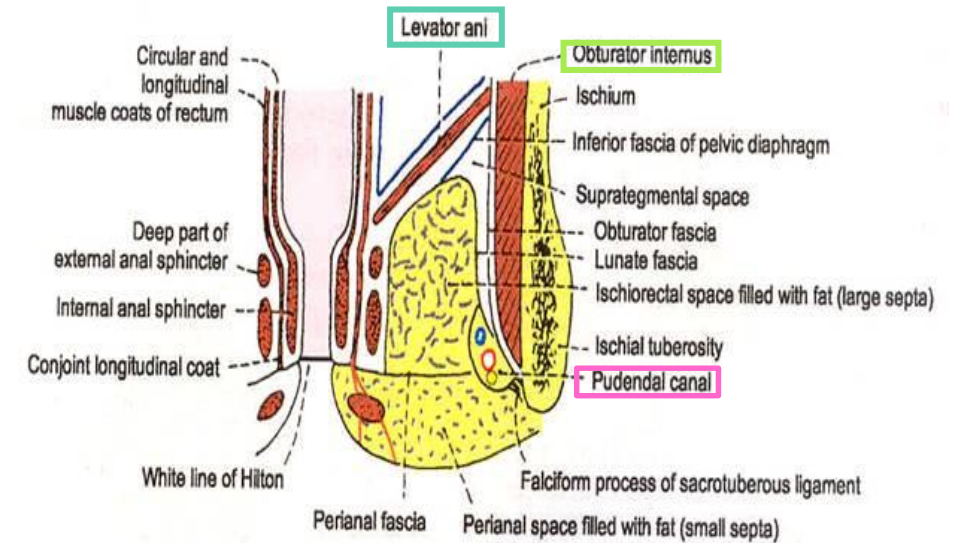
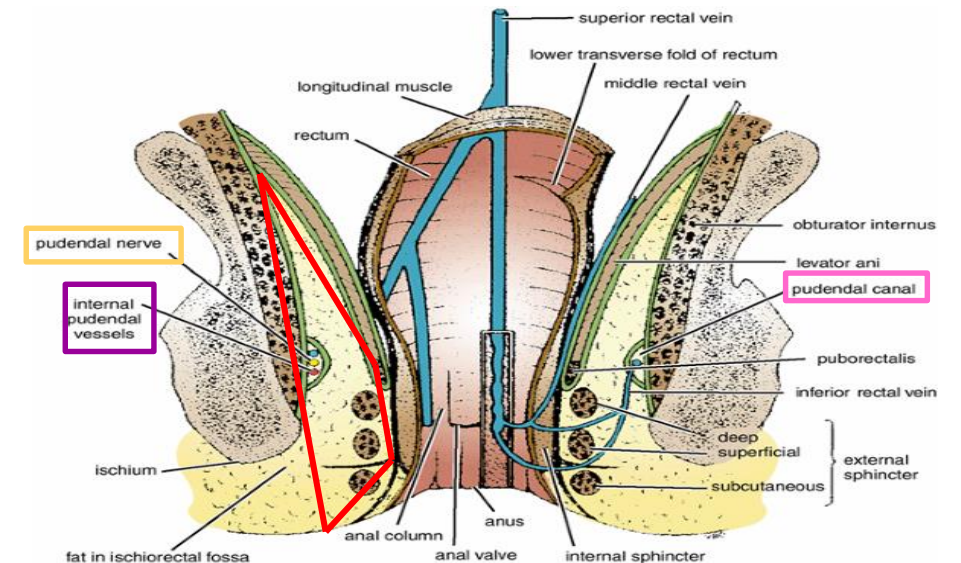


Fig. 28.7: Coronal section through the ischiorectal fossa.



II. Anal Triangle Pudendal Canal

- The pudendal canal is a fascial canal formed by obturator fascia, located on the lateral wall of the ischiorectal fossa.

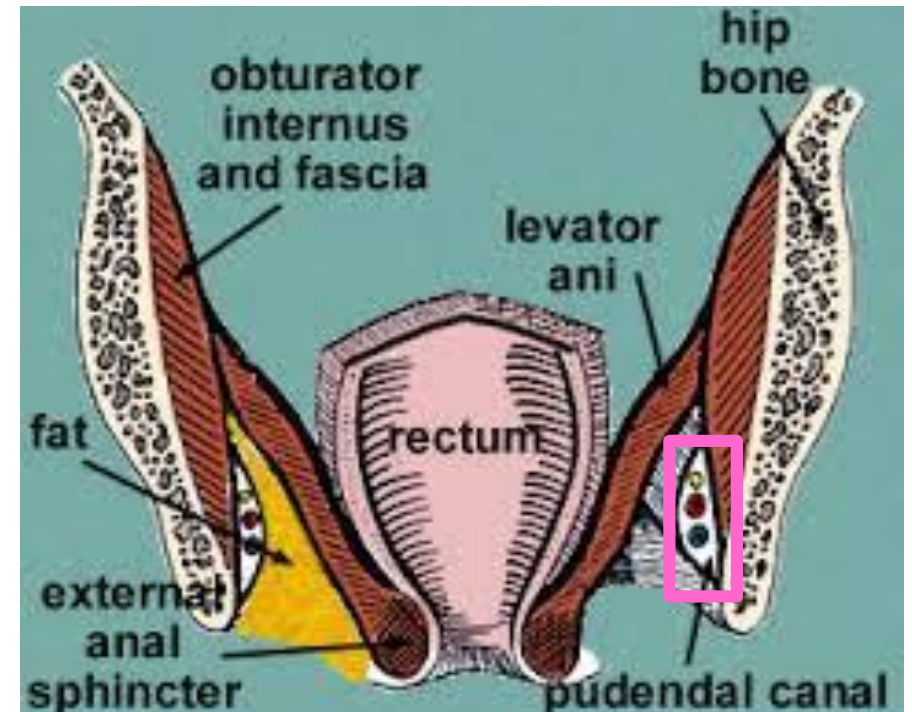
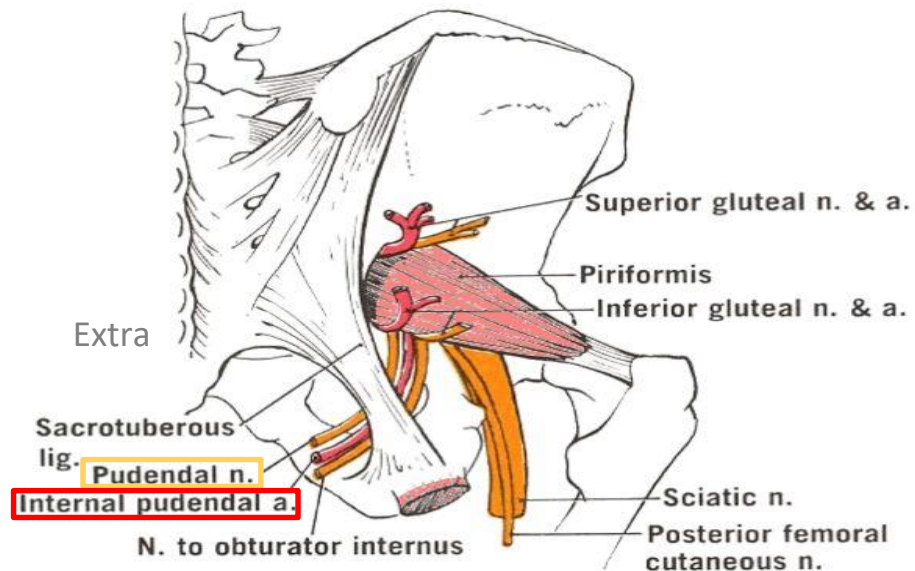
Contents:

1. Pudendal nerve.
2. Internal pudendal vessels (artery and vein).

Mnemonic:
VAN

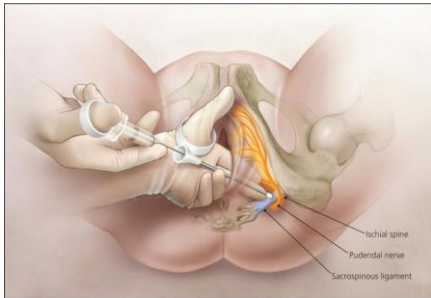
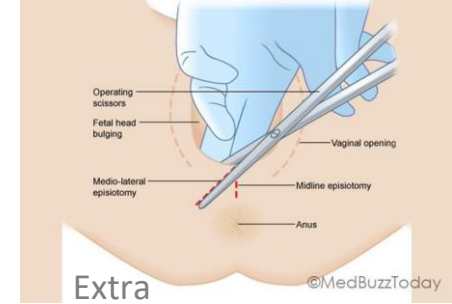


Vein
Artery
Nerve



II. Anal Triangle Pudendal Nerve Block **Important!**

- Pudendal nerve block is used in providing **analgesia** for the second stage of labour (الولادة) to provide anesthesia of the perineum in order to create or repair an **episiotomy** (An episiotomy is a surgically planned **incision** on the perineum and the **posterior vaginal wall** during second stage of **labor** to prevent perineal tear).
- Method: can be done by transvaginally or through perineal approach.



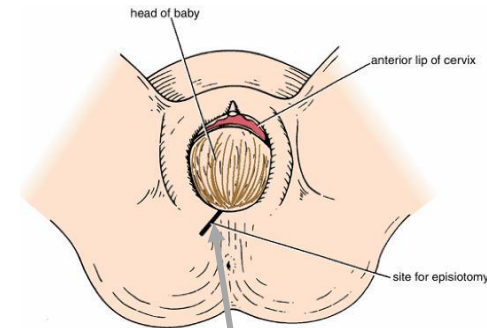
Transvaginal method:

- The needle is passed **through the vaginal mucous** membrane toward the ischial spine.
- After the needle is passed through the **sacrospinous ligament**, the anesthetic solution is injected around the pudendal nerve

الفرق بين الاثنين انه الاول يكون من جوى لازم الدكتور يدخل من المهبل . بينما الطريقة الثانية تكون من برا الدكتور يحس العظم بعدين يدخل الإبرة على طول.

Perineal method:

- The ischial tuberosity is palpated **subcutaneously** through the buttock. (needs experience)
- The needle is inserted on the **medial side of the ischial tuberosity** to a depth of about 1 in. (2.5 cm) from the free surface of the tuberosity.
- The anesthetic is injected around the pudendal nerve.



The cut is made in an oblique line so we don't cut the perineal body

Perineum: region of the body below the pelvic diaphragm

•Contents: 1\Lower ends of urethra, vagina & anal canal- 2\ External genitalia- 3\ Perineal body & Anococcygeal body

Perineal body is an irregular fibromuscular mass, located at the midpoint of the line between the ischial tuberosities

Function:

1-Gives attachment to perineal muscles.

2-Plays an important role in visceral support especially in female.

The anococcygeal body is a complex musculotendinous structure, located between the anterior aspect of the coccyx and the posterior wall of the anorectal canal.

•Receives insertion of fibers of levator ani muscle

Boundaries of perineum:

Anteriorly Mons pubis \ **Laterally** Medial surfaces of the thighs \ **Posteriorly** Intergluteal folds.

Division of perineum:

Urogenital triangle anteriorly:

• **Boundaries:**

Anteriorly : Symphysis pubis.

Posteriorly : Transverse line passing through the 2 ischial tuberosities.

Laterally : Ischiopubic rami & ischial tuberosities.

• **Content:**

-Lower part of **urethra** & **vagina**.

-**External genitalia** (vulva).

Anal triangle posteriorly:

• **Boundaries:**

Anteriorly: Transverse line passing through the 2 ischial tuberosities.

Posteriorly : coccyx.

Laterally : ischial tuberosity & sacrotuberous ligament.

• **Contents:**

- Lower part of Anal canal.

- Ano-coccygeal body.

- Ischiorectal fossa on each side.

Ischiorectal fossa:

Boundaries:

-**Base**: Skin of the perineum.

-**Medial wall**: Levator ani & anal canal.

-**Lateral wall**: Obturator internus, covered with fascia.

Contents:

- Dense fat.

- **Pudendal nerve & internal pudendal vessels** within the **pudendal canal**.

- **Inferior rectal nerve & vessels** crossing the fossa to reach anal canal.

<i>Urogenital Diaphragm</i>	<i>Female External Genitalia (Vulva)</i>	<i>Perineal Fascia</i>	<i>Perineal Pouches</i>	<i>Vagina</i>	<i>Anal Canal</i>	<i>Pudendal Canal:</i>
<ul style="list-style-type: none"> A triangular musculofascial diaphragm <u>located in</u> the urogenital triangle. Fills in the gap between the pubic arch. <p>Composed of:</p> <ol style="list-style-type: none"> Sphincter urethrae deep transverse perineal muscles. Superior layer of urogenital fascia Inferior layer of urogenital fascia (perineal membrane) 	<ol style="list-style-type: none"> Mons pubis. Labia majora. Labia minora. Clitoris. Vestibule of vagina. urethral orifice & vaginal orifice. 	<p>continuous anteriorly with the fascia of abdomen.</p> <p>consists of:</p> <p><u>Superficial perineal fascia:</u> -Superficial <u>fatty</u> layer (Camper’s fascia). - Deep <u>membranous</u> layer (Colle’s fascia).</p> <p><u>Deep perineal fascia:</u> <u>invests</u> the <u>muscles</u> in the superficial perineal pouch.</p>	<p>Superficial: It is the space between the <i>deep membranous layer of superficial fascia</i> and the <i>perineal membrane</i>.</p> <p>Deep: It is a completely closed space <i>deep to the perineal membrane</i></p>	<p>-muscular canal that leads from the uterus to the external orifice of the genital canal.</p> <p>- 3 in. (8 cm) long.</p> <p>-It is the excretory duct for the menstrual flow & forms part of the birth canal.</p> <p>Arteries:</p> <p>-Vaginal artery, a branch of the internal iliac artery</p> <p>-Vaginal branch of the uterine artery</p> <p>Veins: internal iliac veins</p>	<p>- 1.5 in. long, descending from the rectal ampulla to the anus.</p> <p>Relations (In female):</p> <p>Anteriorly: Perineal body, urogenital diaphragm, and lower part of vagina</p> <p>Posteriorly: Anococcygeal body.</p> <p>Laterally: Ischiorectal fossae.</p> <p>Division:</p> <p><u>Upper half:</u> derived from hindgut (endoderm)</p> <p><u>Lower half:</u> derived from the proctodeum (ectoderm)</p> <p>*The two parts have <u>different</u> blood supply, nerve supply and lymphatic drainage.</p>	<p>-A fascial canal formed by obturator fascia, located on the lateral wall of the ischiorectal fossa</p> <p>Contents:</p> <ol style="list-style-type: none"> Pudendal nerve. Internal pudendal vessels.

MCQs

Q1: All the following are contents of urogenital triangle except :

- A) Urethra
- B) Vagina
- C) Valva
- D) Anus

Q2: Which one of the following structures forms the center point of perineum?

- A) Perineal body
- B) Ischial tuberosities
- C) Anococcygeal body
- D) Coccyx

Q3: Which one of the following structures lie anterior to Urogenital Triangle?

- A) Ischiopubic rami
- B) Ischial tuberosities.
- C) External genitalia
- D) Symphysis pubis

Q4: Which of the following is a content of superficial perineal pouch ?

- A) Dorsal nerve of clitoris
- B) Pudendal artery
- C) Pudendal vein
- D) Perineal branch of pudendal nerve

Q5: Which of the following is a lateral boundary to deep perineal pouch?

- A) Inferior portion of obturator internus fascia
- B) Superior portion of obturator internus fascia
- C) Ischiopubic rami
- D) Superior fascia of the urogenital diaphragm

Q6: Vaginal branch originates from which of the following arteries?

- A) Internal iliac artery
- B) Ovarian artery
- C) Uterine artery
- D) Inferior mesenteric artery

Q7: Which of the following vein drain the inferior rectal vein?

- A) Uterine vein
- B) Internal pudendal vein
- C) Superior mesenteric vein
- D) Inferior mesenteric vein

Q8: The fascia canal of pudendal canal formed by which of the following?

- A) Deep perineal fascia
- B) Superficial perineal fascia
- C) Obturator fascia
- D) Superior fascia of urogenital diaphragm

Answers: 1. D, 2. A, 3. D, 4. D, 5. A, 6. C, 7. B, 8. C

SAQ

Q1: Regarding the relation of the anal canal in female ?

- 1-Anteriorly: perineal body, urogenital diaphragm, lower part of vagina
- 2- Posteriorly: anococcygeal body
- 3- Laterally: ischiorectal fossae

Q2: What's the divisions of the anal canal and from where it's derived ?

- Upper half: Derived from hindgut (endoderm)
- Lower half: Derived from proctodeum (ectoderm)

Q3: What are the contents of the superficial pouch?

1. Bulbs of vestibule.
2. Crura of clitoris
3. Superficial perineal muscles:
 - a) Ischiocavernosus muscle.
 - b) Bulbospongiosus muscle.
 - c) Superficial transverse perineal muscles
4. Greater vestibular glands.
5. Perineal branch of pudendal nerve.

Q4: What are the bony boundaries of the perineum?

- 1-Anteriorly: Symphysis pubis
- 2- Posteriorly: Coccyx
- 3- Laterally: Ischiopubic rami, ischial tuberosities & sacrotuberous ligaments

Q5: What are the contents of the urogenital triangle?

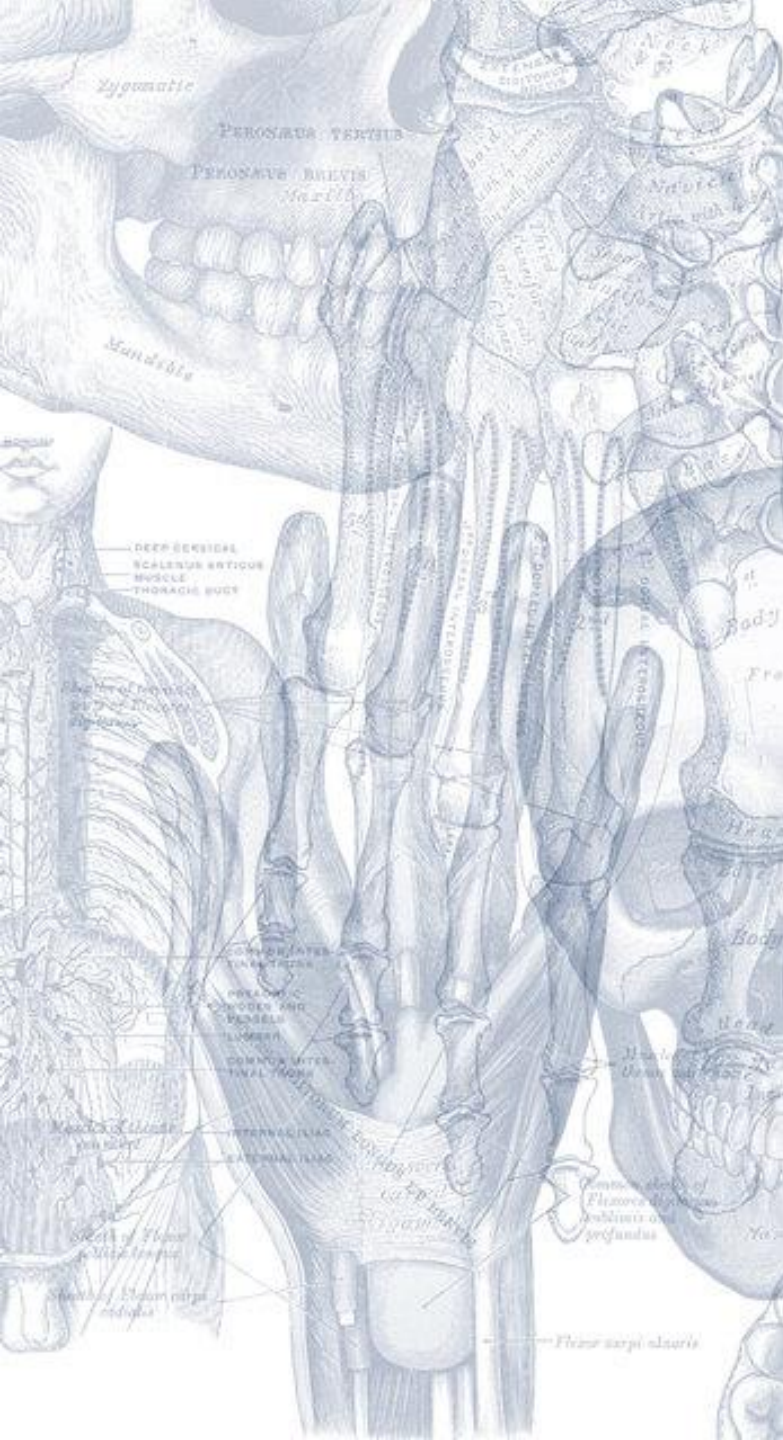1. Lower part of urethra & vagina.
2. External genitalia (vulva).

Q6: What are the contents of the anal triangle?

1. Lower part of Anal canal
2. Ano-coccygeal body
3. Ischiorectal fossa on each side

Q6: What are the contents of the pudendal canal?

1. Pudendal nerve.
2. Internal pudendal vessels



Leaders:

Nawaf ALKhudairy
Jawaher Abanumy

Members:

Alanoud Abuhaimed
Anwar Alajmi
Ghaida Alsaeed
Lama Alfawzan
Lama ALTamimi
Rawan AlWadee
Safa Al-Osaimi
Shatha Alghaihb
Wejdan alzaid



Feedback



anatomyteam436@gmail.com



[@anatomy436](https://twitter.com/anatomy436)

References:

- 1- Girls' & Boys' Slides
- 2- Greys Anatomy for Students
- 3- TeachMeAnatomy.com