

Tonsil with Tangier disease

Brenda L. Nelson, DDS
Lester D.R. Thompson, MD

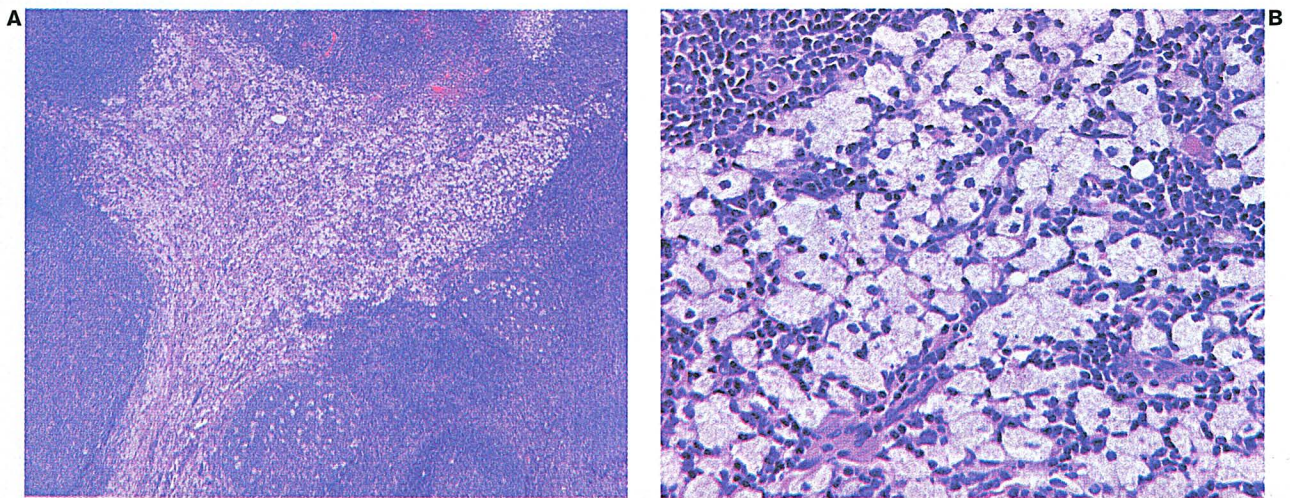


Figure. A: Low-power view of a tonsil specimen shows a parafollicular accumulation of pale-staining, foamy histiocytes. B: High-power view of a hematoxylin-stained slide shows clusters of plump histiocytes filled with lipid droplets. The esters are "clear."

Tangier disease is a rare autosomal-recessive inherited disorder that is caused by a defect in chromosome 9q31. It is characterized by a severe deficiency or absence of high-density lipoproteins in plasma. A defect in cellular cholesterol removal results in the massive, abnormal accumulation of cholesterol esters in macrophages in many tissues. Although this accumulation is most conspicuous in the tonsils, progressive accretion of these esters also occurs in nerves (neuropathy) and vessels (atherosclerosis). The pathognomonic finding is a low plasma cholesterol concentration accompanied by normal or elevated triglyceride levels and large, lobulated, hyperplastic, bright orange-yellow tonsils and adenoid tissue. Affected families have been identified on Tangier Island, Va., in Chesapeake Bay as well as in Missouri, Kentucky, and Europe.

Microscopically, the affected tissues demonstrate a prominent accumulation of foamy histiocytes (xanthoma

cells) that contain lipid droplets (cholesterol esters) and occasionally crystalline material (figure). Lipid droplets are not present in lysosomes. The foamy histiocytes aggregate in clusters, often in the parafollicular area of the lymph nodes or tonsils. It is important to perform special studies to exclude an infectious etiology.

The diagnosis is considered important because, although there is no specific therapy, heart disease affects these patients at a very early age.

Suggested reading

Assmann G, von Eckardstein A, Brewer HB, Jr. Familial high density lipoprotein deficiency: Tangier disease. In: Scriver CR, Beaudet AL, Sly WS, Valle D, eds. *The Metabolic and Molecular Bases of Inherited Disease*. 7th ed. New York: McGraw-Hill, 1995:2053-66.

Ferrans VJ, Fredrickson DS. The pathology of Tangier disease. A light and electron microscopic study. *Am J Pathol* 1975;78:101-58.