

# *Pseudomonas* Skin Infection

## Clinical Features, Epidemiology, and Management

Douglas C. Wu,<sup>1</sup> Wilson W. Chan,<sup>2</sup> Andrei I. Metelitsa,<sup>1</sup> Loretta Fiorillo<sup>1</sup> and Andrew N. Lin<sup>1</sup>

1 Division of Dermatology, University of Alberta, Edmonton, Alberta, Canada

2 Department of Laboratory Medicine, Medical Microbiology, University of Alberta, Edmonton, Alberta, Canada

### Contents

Abstract . . . . .	158
1. Introduction . . . . .	158
1.1 Microbiology . . . . .	158
1.2 Pathogenesis . . . . .	158
1.3 Epidemiology: The Rise of <i>Pseudomonas aeruginosa</i> . . . . .	158
2. Cutaneous Manifestations of <i>P. aeruginosa</i> Infection. . . . .	159
2.1 Primary <i>P. aeruginosa</i> Infections of the Skin. . . . .	159
2.1.1 Green Nail Syndrome. . . . .	159
2.1.2 Interdigital Infections . . . . .	159
2.1.3 Folliculitis . . . . .	159
2.1.4 Infections of the Ear . . . . .	160
2.2 <i>P. aeruginosa</i> Bacteremia . . . . .	160
2.2.1 Subcutaneous Nodules as a Sign of <i>P. aeruginosa</i> Bacteremia . . . . .	161
2.2.2 Ecthyma Gangrenosum . . . . .	161
2.2.3 Severe Skin and Soft Tissue Infection (SSTI): Gangrenous Cellulitis and Necrotizing Fasciitis. . . . .	161
2.2.4 Burn Wounds . . . . .	162
2.2.5 AIDS . . . . .	162
2.3 Other Cutaneous Manifestations . . . . .	162
3. Antimicrobial Therapy: General Principles . . . . .	163
3.1 The Development of Antibacterial Resistance . . . . .	163
3.2 Anti-Pseudomonal Agents . . . . .	163
3.3 Monotherapy versus Combination Therapy . . . . .	164
4. Antimicrobial Therapy: Specific Syndromes . . . . .	164
4.1 Primary <i>P. aeruginosa</i> Infections of the Skin. . . . .	164
4.1.1 Green Nail Syndrome. . . . .	164
4.1.2 Interdigital Infections . . . . .	165
4.1.3 Folliculitis . . . . .	165
4.1.4 <i>Pseudomonas</i> Otitis Externa . . . . .	165
4.1.5 Malignant Otitis Externa. . . . .	165
4.2 <i>P. aeruginosa</i> Systemic Infections . . . . .	165
4.2.1 Bacteremia . . . . .	165
4.2.2 Severe SSTI and Burns. . . . .	165
4.3 Future Directions . . . . .	165
5. Conclusion . . . . .	166

## Abstract

*Pseudomonas aeruginosa* is a Gram-negative bacillus that is most frequently associated with opportunistic infection, but which can also present in the otherwise healthy patient. The range of *P. aeruginosa* infections varies from localized infections of the skin to life-threatening systemic disease. Many *P. aeruginosa* infections are marked by characteristic cutaneous manifestations. The aim of this article is to provide a comprehensive synthesis of the current knowledge of cutaneous manifestations of *P. aeruginosa* infection with specific emphasis on clinical features and management.

The ability of *P. aeruginosa* to rapidly acquire antibacterial resistance is an increasingly well recognized phenomenon, and the correct application of antipseudomonal therapy is therefore of the utmost importance. A detailed discussion of currently available anti-pseudomonal agents is included, and the benefits of antimicrobial combination therapy versus monotherapy are explored. Rapid clinical recognition of *P. aeruginosa* infection aided by the identification of characteristic cutaneous manifestations can play a critical role in the successful management of potentially life-threatening disease.

## 1. Introduction

*Pseudomonas aeruginosa* is a bacterium that causes a wide variety of infections that have characteristic skin manifestations. They range from localized, benign infections of the skin to life-threatening systemic infections that feature skin lesions with characteristic morphology. In this article, we aim to provide a comprehensive synthesis of the current knowledge about the cutaneous manifestations of *P. aeruginosa* infection.

### 1.1 Microbiology

*P. aeruginosa* is a species of Gram-negative bacilli belonging to the family Pseudomonadaceae. Obligate aerobes, these organisms grow best in ambient air at 37°C, though they can grow at temperatures as high as 42°C.<sup>[1]</sup> In the laboratory setting, colonial morphology typically features a metallic sheen, blue-green pigment, and a unique grape-like, fruity odor. The pigment pyoverdine, which is greenish-yellow and fluoresces under Wood's light, is common to the fluorescent group of *Pseudomonas* species (notably *P. aeruginosa*, *P. fluorescens*, *P. putida*), but pyocyanin, which is non-fluorescent and greenish-blue, is unique to *P. aeruginosa* and imparts the characteristic color.<sup>[2]</sup> However, many morphologic variants exist, including mucoid and dwarf morphotypes, with mucoid strains being commonly isolated from airway cultures of cystic fibrosis patients. Biochemical features supportive of the identification include a positive oxidase test, an inability to ferment carbohydrates (alkaline over no change on a triple sugar iron slant), and the ability to grow on cetrimide agar. Growth at 42°C remains a defining characteristic of *P. aeruginosa* from the other fluorescent pseudomonads.<sup>[1]</sup>

### 1.2 Pathogenesis

*P. aeruginosa* has a plethora of features that contribute to its ability to cause disease. Sato and colleagues<sup>[3]</sup> showed that

strains of *P. aeruginosa* that are deficient in pili and flagella were incapable of establishing infection and spreading throughout the host. Furthermore, the expression of various proteases facilitates *P. aeruginosa* dissemination by allowing the microorganism to disrupt basement membrane integrity.<sup>[4]</sup> Other factors that contribute to virulence include phospholipase C activity,<sup>[5]</sup> surface expression of ferripyochelin-binding protein,<sup>[6]</sup> production of lipopolysaccharide,<sup>[7]</sup> and the elaboration of exoproducts secreted by the type III secretion system.<sup>[8]</sup> Finally, the mucoid phenotype visible on colonial growth is a result of the production of a polysaccharide known as alginate.<sup>[9]</sup> This biofilm facilitates bacterial adhesion and immune evasion, and is a particularly important virulence factor in the airway colonization and chronic lung infection of patients with cystic fibrosis.<sup>[10]</sup>

### 1.3 Epidemiology: The Rise of *Pseudomonas aeruginosa*

*P. aeruginosa* can thrive under nutritionally stringent conditions, as evidenced by its ability to grow even in distilled water, using only dissolved carbon dioxide and residual ions as substrates for growth.<sup>[11]</sup> This hardiness makes it an especially effective opportunistic pathogen, where host defenses have already been compromised.<sup>[12]</sup> In addition, it is hydrophilic and has a predilection for moist environments. Indeed, the association of *P. aeruginosa* infections with water-related reservoirs such as swimming pools,<sup>[13]</sup> hot tubs,<sup>[14]</sup> and contact lens solution<sup>[15]</sup> has been well documented. These two factors combine to facilitate the ubiquitous nature of the bacterium as it can be recovered from almost any environmental water source.

Despite its presence in the environment, *P. aeruginosa* is seldom a colonizer of healthy human hosts,<sup>[16]</sup> but colonization has been observed in individuals undergoing multiple courses of antibacterials, as well as in the respiratory tracts of mechanically ventilated patients.<sup>[1]</sup> Over the past 60 years, *P. aeruginosa* has

evolved from a rarely considered pathogen to one of the most common micro-organisms involved in hospital-acquired infections. Data from the EPIC (European Prevalence of Infection in Intensive Care) study identified it as the predominant Gram-negative species (28.7%) isolated from bronchopulmonary infection sites of patients hospitalized in 1417 intensive care units of 17 Western European countries.<sup>[17]</sup> Similarly, the 1999 SENTRY Antimicrobial Surveillance Program from Canada, the US, and Latin America demonstrated that it was the third most common pathogen (10.6%) found in 4267 bloodstream isolates.<sup>[18]</sup> *P. aeruginosa* is highly effective in contaminating hospital-based water reservoir systems, and carriage on the hands of healthcare workers can further facilitate transmission.<sup>[19]</sup>

## 2. Cutaneous Manifestations of *P. aeruginosa* Infection

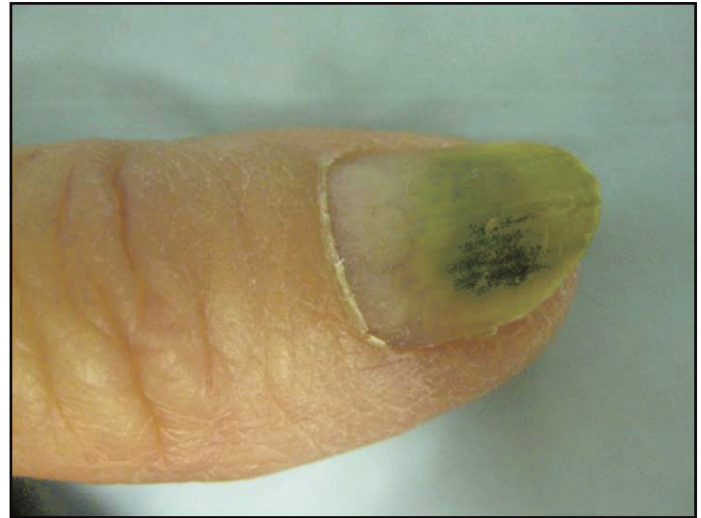
The cutaneous manifestations of *P. aeruginosa* infection range from superficial to deep, and can occur in both immunocompromised and healthy individuals. In the case of the immunocompromised host, however, more significant morbidity and mortality can result from untreated *P. aeruginosa* infection. A high index of suspicion and rapid clinical recognition are therefore essential to improve prognosis. Broadly speaking, cutaneous manifestations of *P. aeruginosa* infection can be classified as either primary infection due to cutaneous inoculation, or those that are secondary to *P. aeruginosa* bacteremia.

### 2.1 Primary *P. aeruginosa* Infections of the Skin

*P. aeruginosa* can give rise to a variety of mild skin infections with unique clinical presentations. These syndromes typically present in otherwise healthy individuals, and some resolve spontaneously without specific antibacterial therapy.

#### 2.1.1 Green Nail Syndrome

One of the oldest cutaneous manifestations associated with *P. aeruginosa* infection is the greenish discoloration of the nails that arises due to the pyocyanin pigment produced by the bacterium.<sup>[20]</sup> ‘Green nail syndrome’ or chloronychia has long been recognized as being caused primarily by *P. aeruginosa*, although it can rarely be caused by other bacteria and fungi.<sup>[21]</sup> The classic clinical presentation consists of the triad of green discoloration of the nail plate, proximal chronic paronychia, and disto-lateral onycholysis (figure 1).<sup>[22]</sup> Nail psoriasis may play a role in predisposing towards *P. aeruginosa* superinfection.<sup>[23]</sup>



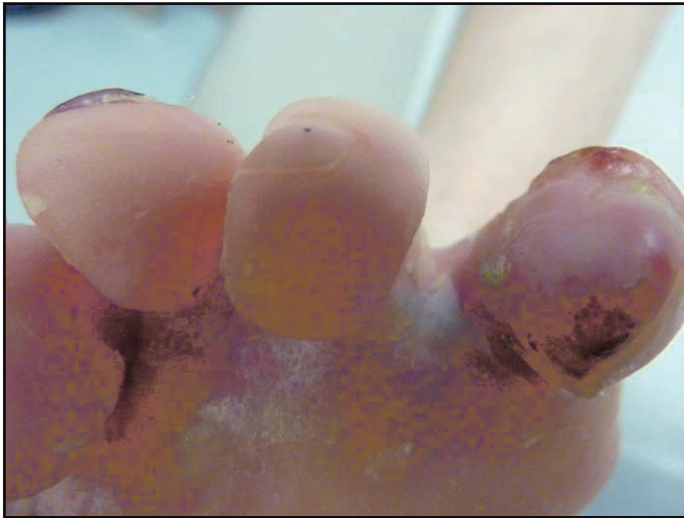
**Fig. 1.** Green discoloration of nails. Culture yielded growth of *Pseudomonas aeruginosa*.

#### 2.1.2 Interdigital Infections

Infection of toe webspaces is most commonly associated with yeast; however, persistent colonization by dermatophytes can increase susceptibility to further bacterial superinfection. Italian investigators who studied 123 patients with toe-web infections found that *P. aeruginosa* was the predominant causative bacterium.<sup>[24]</sup> Similarly, investigators in the United Arab Emirates found that *P. aeruginosa* accounted for 26.7% of cases of toe-web intertrigo. In this study, only *Candida* and *Aspergillus* were found to be more frequent causes.<sup>[25]</sup> Karaca et al.<sup>[26]</sup> highlighted the importance of recognizing *P. aeruginosa* and other pathogenic flora within toe-web infections. Clinical presentation typically consists of erythema, vesicopustules, erosions, maceration, and a hyperkeratotic rim (figure 2).<sup>[27]</sup> Cutaneous signs are often accompanied by patient reports of burning and pain.

#### 2.1.3 Folliculitis

One of the best known cutaneous entities ascribed to *P. aeruginosa* infection is ‘hot tub folliculitis,’ which is due to the recreational use of hot tubs, whirlpools, and swimming pools. Hot tub folliculitis typically presents in previously healthy individuals who are exposed to contaminated water.<sup>[28]</sup> It is characterized by the sudden onset of numerous, large, monomorphic, painful papules and pustules approximately 24 hours after prolonged immersion in contaminated water. The lesions are clustered on body areas in contact with the water surface, typically the upper trunk, axillary folds, hips, and buttocks (figure 3). Hot tub folliculitis is more common after immersion in a body of water with temperature over 38°C



**Fig. 2.** Toe-web infection with *Pseudomonas aeruginosa* in a patient with epidermolysis bullosa.

as *Pseudomonas* is heat tolerant. *P. aeruginosa* can be cultured from skin pustules.<sup>[29]</sup>

Additionally, long-term use of tetracycline in the treatment of acne vulgaris can result in folliculitis caused by Gram-negative bacteria, including *P. aeruginosa*.<sup>[30]</sup> These studies highlight the fact that *P. aeruginosa* folliculitis could arise from sources other than hot tubs and baths. It can also present opportunistically in patients with chronic wounds or burns, especially patients with epidermolysis bullosa.<sup>[31]</sup> *Pseudomonas* hot-foot syndrome is characterized by acute onset of painful plantar nodules in children, believed to be due to inoculation of *P. aeruginosa* on the soles through rubbing against the abrasive floor of a wading pool. In most patients, the eruption resolves spontaneously.<sup>[32]</sup> An outbreak with similar features involving the palms and soles of 33 children has been associated with the use of a hot tub.<sup>[33]</sup>

#### 2.1.4 Infections of the Ear

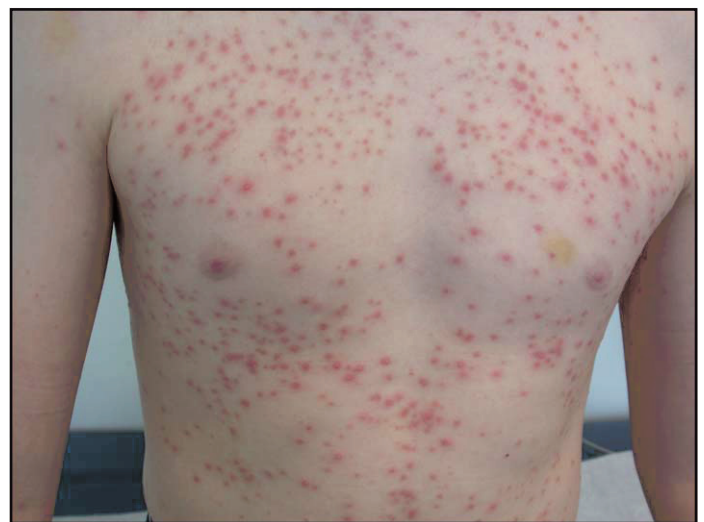*P. aeruginosa* infections of the ear can vary from benign to life threatening. On the one hand, studies of uncomplicated auricular perichondritis have suggested that *P. aeruginosa* is the most common micro-organism responsible.<sup>[34]</sup> Furthermore, Keene et al.<sup>[35]</sup> discovered that the micro-organism contributed to the incidence of superficial ear cartilage infections after commercial piercings – ironically, via contaminated cleaning agents. Acute diffuse otitis externa is a common problem in swimmers, with *P. aeruginosa* being the most common pathogen involved.<sup>[13]</sup>

On the other hand, pseudomonal ear infections can progress to the severe condition known as malignant otitis externa, an

invasive and potentially life-threatening condition that affects the external ear and skull base. In this setting, the patient is classically elderly, immunocompromised, and often has diabetes mellitus.<sup>[36]</sup> The patient presents with severe otalgia, purulent otorrhea, and evidence of granulation tissue in the external auditory canal.<sup>[37]</sup> If left untreated, the infection can worsen and lead to mastoiditis and cranial nerve palsy. Microbiologic studies have established that *P. aeruginosa* is by far the most common pathogen found in culture isolates.<sup>[38]</sup> Detection, treatment, and prevention are multidisciplinary efforts often involving the primary-care physician, dermatologist, and otolaryngologist. Due to the serious nature of malignant otitis externa, rapid recognition and medical and surgical treatment of *P. aeruginosa* external ear infections is imperative.

#### 2.2 *P. aeruginosa* Bacteremia

*P. aeruginosa* bacteremia is a life-threatening disorder that may feature cutaneous lesions with characteristic morphology. Investigators have suggested that *P. aeruginosa* bacteremia is associated with the greatest mortality of all Gram-negative bacteremias.<sup>[39]</sup> Early recognition of dermatologic findings may provide critical clues that prompt rapid initiation of appropriate therapy. Cutaneous manifestations of systemic *P. aeruginosa* infections include subcutaneous nodules, ecthyma gangrenosum, and gangrenous cellulitis. Patients with severe burn wounds are also highly susceptible to deadly pseudomonal infection. Finally, patients with AIDS who then become opportunistically infected with *P. aeruginosa* can display unique cutaneous manifestations.



**Fig. 3.** Folliculitis on the trunk, featuring erythematous papules. Culture yielded *Pseudomonas aeruginosa*.

### 2.2.1 Subcutaneous Nodules as a Sign of *P. aeruginosa* Bacteremia

In 1980, Schlossberg<sup>[40]</sup> noticed the presence of indurated, subcutaneous nodules during the treatment of two patients with confirmed *P. aeruginosa* septicemia. This report was followed by further isolated case reports over the next several years.<sup>[41,42]</sup> In the case of a pediatric patient with concurrent systemic lupus erythematosus and *P. aeruginosa* sepsis, subcutaneous nodules were accompanied by the development of hemorrhagic bullae. In this scenario, the bacterium could also be cultured from bullous fluid.<sup>[43]</sup> With the report from Raffi et al.<sup>[44]</sup> in 1988, subcutaneous nodules were becoming a well recognized – albeit rare – clinical sign of pseudomonal bacteremia.

These lesions typically consist of multiple, erythematous, non-fluctuant or minimally fluctuant, indurated, warm subcutaneous nodules that affect the face, neck, chest, abdomen, back, or extremities, and can be either painful or painless.<sup>[45,46]</sup> Histology shows acute vasculitis and suppurative panniculitis with the presence of Gram-negative rods.<sup>[41,45,47]</sup> *P. aeruginosa* can be cultured from skin biopsy specimens. Patients who develop subcutaneous nodules as a result of *P. aeruginosa* sepsis are generally very ill and have a variety of cancers and immunodeficient syndromes.<sup>[48,49]</sup> However, isolated cases of *P. aeruginosa* sepsis and the development of subcutaneous nodules in previously healthy individuals have been reported.<sup>[50,51]</sup> Furthermore, *P. aeruginosa*-related subcutaneous nodules in the absence of pseudomonal sepsis were reported in one case and thought to be the result of traumatic inoculation.<sup>[52]</sup>

Therefore, the development of characteristic subcutaneous nodules can be an important clinical clue to an underlying *P. aeruginosa* bacteremia and should be investigated appropriately with biopsy and culture. Additionally, patients who manifest with such cutaneous findings typically have some form of immune dysfunction and an investigation into these underlying conditions should be considered.

### 2.2.2 Ecthyma Gangrenosum

Ecthyma gangrenosum is a necrotic cutaneous lesion that is associated with *P. aeruginosa* bacteremia. It is most commonly found in immunocompromised individuals, although it can also develop in previously healthy individuals as a sign of underlying pseudomonal septicemia – sometimes with fatal consequences.<sup>[53-55]</sup> Ecthyma gangrenosum has also been described as a consequence of other infectious agents and even in the absence of bacteremia.<sup>[56-58]</sup> Two distinct pathogenetic mechanisms have been hypothesized to explain the development of ecthyma gangrenosum. In the classic scenario, an immunocompromised patient develops a *P. aeruginosa* septicemia and blood-borne seeding of the bacterium to the skin results in the

development of ecthyma gangrenosum lesions. This mechanism was evidenced in a study of ecthyma gangrenosum over a 12-year period at the Mayo Clinic. The investigators identified eight cases and found that each of these patients had underlying hematologic disease and were receiving chronic immunosuppression.<sup>[59]</sup> Further case studies confirmed the association of ecthyma gangrenosum with various immunocompromising medical conditions including aplastic anemia, AIDS, chronic lymphocytic leukemia, and myelofibrosis.<sup>[60-63]</sup> Rarely, traumatic inoculation of *P. aeruginosa* can lead to subsequent bacteremia and ecthyma gangrenosum even in individuals without underlying immune compromise.<sup>[64]</sup> Similarly, widespread breakdown of the skin's barrier function as a result of burn injury or toxic epidermal necrolysis has also been reported to predispose towards pseudomonal bacteremia and the development of ecthyma gangrenosum.<sup>[65,66]</sup> An alternative pathogenetic mechanism of ecthyma gangrenosum development involves the localized infection of skin by *P. aeruginosa* without concurrent bacteremia, usually seen in patients with hematologic malignancy or other immunocompromising medical conditions.<sup>[67,68]</sup>

The diagnosis of ecthyma gangrenosum begins with recognition of its classic cutaneous manifestation. It typically begins as a gunmetal gray, infarcted macule or papule with surrounding erythema, which then evolves into a necrotic, black, ulcerative eschar with an erythematous halo.<sup>[69]</sup> Frequently, the lesion presents in the anogenital or axillary region, but other sites can be involved, including the nasal ala and periocular region.<sup>[63,70]</sup> Histology shows necrosis of the epidermis and upper dermis, and often a mixed inflammatory cell infiltrate around the infarcted region. A necrotizing vasculitis with vascular thrombosis is seen in the margins. There are many Gram-negative bacteria between the collagen bundles, and sometimes in the media and adventitia of small blood vessels.<sup>[71]</sup> Cultures of lesion and blood can confirm the presence of *P. aeruginosa*, and sensitivity analysis is important to determine the choice of antimicrobial therapy. Careful monitoring and follow-up of these patients is important due to the potentially life-threatening nature of pseudomonal sepsis and the propensity of ecthyma gangrenosum to present in immunocompromised individuals. In patients who appear otherwise healthy, further work-up of potential underlying medical conditions should be considered.

### 2.2.3 Severe Skin and Soft Tissue Infection (SSTI): Gangrenous Cellulitis and Necrotizing Fasciitis

Widespread and aggressive *P. aeruginosa* infection of the skin and fascial layers can result in rapidly progressive destruction and inflammation, potentially leading to fulminant

skin failure and death. Although rare, this spectacular cutaneous manifestation of *P. aeruginosa* infection often initially presents insidiously with localized pain, swelling, and inflammation of the soft tissues with associated fever and malaise. This cellulitis, itself a potentially serious medical condition, can then progress to uncontrolled skin necrosis. Although relatively rare, a significant body of literature exists describing the incidence of severe cellulitis and necrotizing fasciitis as a result of *P. aeruginosa*. Indeed, in an epidemiologic study of adults hospitalized for infectious cellulitis, Carratala et al.<sup>[72]</sup> found that the presence of the micro-organism as a causative agent was one of the few factors directly associated with increased mortality. Typically, patients with *Pseudomonas*-associated cellulitis also have an underlying immunocompromising medical condition. In the setting of leukemia, profound and prolonged neutropenia is the factor most closely associated with the development of a *P. aeruginosa* infection.<sup>[73]</sup> Other conditions that have been associated with the development of *P. aeruginosa* cellulitis include drug-induced agranulocytosis, Waldenstrom macroglobulinemia, and Felty syndrome.<sup>[74,75]</sup> In a rare case report, Atzori et al.<sup>[76]</sup> treated an elderly patient with pseudomonal cellulitis complicating an underlying ophthalmic herpes zoster. Herpetic damage of anatomic barriers in combination with impaired defense mechanisms due to decompensated diabetes were thought to contribute to cellulitis susceptibility in this case. On the other hand, Habif<sup>[77]</sup> discovered the development of *P. aeruginosa* cellulitis as a result of toe-web superinfection in an otherwise healthy 42-year-old man.

Necrotizing fasciitis is a rare but serious infection of the subcutaneous tissue and fascia that requires prompt surgical and antimicrobial therapy. It often affects immunocompromised or elderly individuals.<sup>[78,79]</sup> It is most commonly caused by organisms such as streptococci, Enterobacteriaceae, or *Staphylococcus aureus*. *P. aeruginosa* is an uncommon cause, and a 2008 review reported 11 confirmed cases caused by *P. aeruginosa* in the English language literature.<sup>[79]</sup> Infrequently, *P. aeruginosa* infection can cause a specific variant of necrotizing fasciitis known as Fournier gangrene. This condition, named after Jean-Alfred Fournier, who presented a case in 1883 of perineal gangrene in an otherwise healthy young man, is a necrotizing infection involving the soft tissues of the male genitalia.<sup>[80]</sup> Patients typically present with scrotal discomfort and malaise, which then progresses to perineal pain, swelling, blistering, and necrosis.<sup>[81,82]</sup>

#### 2.2.4 Burn Wounds

Extensive physical damage to the skin's barrier function has severely deleterious effects on its ability to ward off bacterial infection. This is the case in the common clinical scenario of

burn patients, and the impact of *P. aeruginosa* infection in this population has been well studied. *P. aeruginosa* remains one of the most common serious bacterial infections to present in burn patient populations.<sup>[83-85]</sup> The incidence of multi-drug-resistant strains of *P. aeruginosa* has been steadily increasing, and has had particularly devastating effects on burn units.<sup>[86,87]</sup> Risk factors associated with the acquisition of *Pseudomonas* infections in hospitalized burn patients include length of hospitalization, previous use of broad-spectrum antibacterials such as carbapenems, known presence of *P. aeruginosa* on the unit, and total body surface area burned.<sup>[88,89]</sup>

#### 2.2.5 AIDS

*P. aeruginosa* super-infection of AIDS patients is a rare complication of end-stage disease, but can have significant impact on mortality.<sup>[90]</sup> In this setting, cutaneous manifestations have been reported to include subcutaneous nodules, ecthyma gangrenosum without bacteremia, and progressive folliculitis with cellulitis.<sup>[91]</sup> Typically, these cases are associated with chronic neutropenia, but this is not necessarily the case.<sup>[62]</sup>

### 2.3 Other Cutaneous Manifestations

Various other cutaneous manifestations of *P. aeruginosa* infection have been noted in the literature, although often in isolated case reports. For example, it has been associated with the development of cutaneous botryomycosis. Bacterial botryomycosis is a rare, chronic granulomatous disease most often caused by *S. aureus*, *Escherichia coli*, or *P. aeruginosa*.<sup>[92]</sup> Clinically, it can be indistinguishable from a mycetoma of deep fungal origin.<sup>[93]</sup> Bishop et al.<sup>[94]</sup> therefore relied further on results of bacterial culture and the demonstration of Gram-negative organisms within the granules of the lesions themselves, found both in the dermis and the subcutaneous fat. Histologically, the lesions consist of round-shaped granules with an amorphous center and lobulated periphery surrounded by dense leukocytic infiltrate.<sup>[95]</sup> Definitive treatment with antibacterial therapy leads to resolution of the lesion.

We found two reports of pseudomonal balanitis in the English language literature. Petrozzi and Erlich<sup>[96]</sup> noted the development of erosive balanitis secondary to *P. aeruginosa* infection, and attributed it to the use of a mixture of topical antibacterials, antifungals, and corticosteroid agents to treat a pre-existing balanitis. On the other hand, Manian and Alford<sup>[97]</sup> reported that the development of pseudomonal balanitis acted as a source of subsequent bacteremia in a neutropenic patient.

Henoch-Schönlein purpura (HSP) is a small vessel vasculitis characterized by the deposition of IgA immune complexes in



the skin and kidney. The typical cutaneous manifestation of HSP is palpable purpura. Although most commonly associated with streptococcal upper respiratory tract infections, Egan et al.<sup>[98]</sup> presented a single case report of relapsing HSP due to *P. aeruginosa* pyelonephritis. In light of their findings, the authors suggested that *P. aeruginosa* could be considered as a possible trigger of HSP.

The impact of pseudomonal infection on skin graft survival after plastic reconstructive surgery has also been studied. Here, the investigators found that 23.5% of skin grafts were lost due to infection. Of these infections, microbiologic cultures revealed *P. aeruginosa* in 58.1% of cases.<sup>[99]</sup>

### 3. Antimicrobial Therapy: General Principles

The treatment of *P. aeruginosa* infections is not a simple matter. In the setting of its ever-increasing prominence as a pathogen and its propensity for antimicrobial resistance, an increasing number of studies have emerged attempting to delineate the optimal antimicrobial principles involved in its treatment. Uncomplicated primary cutaneous *P. aeruginosa* infections such as toe-web intertrigo or hot tub folliculitis are commonly managed successfully with conservative, topical, or oral applications of an anti-pseudomonal agent. However, the management of potentially life-threatening *P. aeruginosa* bacteremia and the associated cutaneous findings that often arise in immunocompromised patients is far more complicated. In these cases, proper antimicrobial therapy takes into account a variety of factors such as severity of the infection, underlying risk factors and diseases, knowledge of the epidemiology and resistance phenotypes in individual settings, and the associated pharmacokinetic and pharmacodynamic parameters.

#### 3.1 The Development of Antibacterial Resistance

Multiple studies over the past decades have established the increasing emergence of antibacterial-resistant *P. aeruginosa* strains. Indeed, in a multinational study, Hanberger et al.<sup>[100]</sup> found that the highest incidence of resistance among bacteria was seen in *P. aeruginosa* and that up to 37% and 46% of bacterial isolates were resistant to ciprofloxacin and gentamicin, respectively. Intrinsically, *P. aeruginosa* is resistant to many  $\beta$ -lactams (including amoxicillin and ceftriaxone) by virtue of its AmpC  $\beta$ -lactamase, which may become derepressed, leading to increased levels of resistance.<sup>[1,11]</sup> It can also acquire a number of mutations and plasmids with which to circumvent targeted antimicrobial effects. These include an ever-increasing array of  $\beta$ -lactamases (including metallo- $\beta$ -lactamases, which

confer carbapenem resistance), upregulation of multi-drug efflux pumps, mutations that decrease the permeability of the outer membrane to certain antibacterials, and alteration to drug targets, which render them ineffective.<sup>[101,102]</sup>

There is strong evidence to suggest that anti-pseudomonal antibacterial overuse and misuse are associated with the development of resistant strains of *P. aeruginosa*.<sup>[103]</sup> Neuhauser et al.<sup>[104]</sup> reported that the overall susceptibility to ciprofloxacin decreased steadily from 86% in 1994 to 76% in 2000, a result that was significantly correlated to increased national use of fluoroquinolones. Similarly, 10-year epidemiologic data collected from an inpatient dermatology service showed an increase in fluoroquinolone-resistant leg ulcer-associated *P. aeruginosa* from 19% in 1992 to 56% in 2001.<sup>[105]</sup> It is important to note that certain antibacterials appear to be more prone to developing resistance, leading to treatment failures.<sup>[106]</sup> In three separate studies, imipenem was less effective than either ceftazidime or ciprofloxacin in controlling *P. aeruginosa* pneumonia due to the increased development of imipenem resistance.<sup>[107-109]</sup> In support of these findings, Carmeli et al.<sup>[110]</sup> found that imipenem possessed an adjusted hazards ratio for pseudomonal resistance development of 2.8 ( $p=0.02$ ), compared with 0.7 for ceftazidime, 0.8 for ciprofloxacin, and 1.7 for piperacillin. The emergence of resistant strains of *P. aeruginosa* during therapy has been estimated to increase mortality 3-fold; to increase the rate of secondary bacteremia 9-fold; to double the length of hospital stay, with increased risk of associated co-morbidities; and to increase total hospital charges by \$US11 981 (year of costing 2002).<sup>[111]</sup> Taken together, these data indicate that the development of antibacterial-resistant strains of *P. aeruginosa* has far-reaching medical, social, and economic consequences. Careful consideration should therefore be applied when selecting first-line antimicrobial therapy for *P. aeruginosa*.

#### 3.2 Anti-Pseudomonal Agents

Because of the bacterium's proclivity for resistance, a large proportion of commonly used antimicrobials lack adequate coverage to be considered effective, and as such only a small subset are anti-pseudomonal. Currently, the physician's armamentarium of anti-pseudomonals includes aminoglycosides, ciprofloxacin, colistin, and a limited number of the  $\beta$ -lactams (ticarcillin, ureidopenicillins, ceftazidime, cefepime, carbapenems, and aztreonam).<sup>[112]</sup> Of these, data from the 2005 SENTRY report indicate that cefepime has retained broad activity and spectrum against *P. aeruginosa*.<sup>[113]</sup> The specific anti-pseudomonal agents currently in use are summarized in table I.

**Table 1.** Currently available anti-pseudomonal agents

Class of antibacterial	Examples of agents	Mechanism of action
Aminoglycosides	Tobramycin Gentamicin Amikacin	Reversible binding to 30S ribosomal subunit, inhibition of protein synthesis, and causing missense and nonsense protein expression
$\beta$ -Lactams		Binding to cell wall synthesis enzymes (PBPs), inhibiting cell wall synthesis
carboxypenicillins	Ticarcillin	
ureidopenicillins	Piperacillin	
cephalosporins	Ceftazidime (third generation) Cefepime (fourth generation) Ceftobiprole (new generation)	
carbapenems	Imipenem Meropenem	
monobactams	Aztreonam	
Fluoroquinolones	Ciprofloxacin	Binds to topoisomerase II (and IV), causing supercoiled DNA to relax, inhibiting DNA replication
Polymyxins	Colistin	Binds to phospholipid cell membrane via an amphipathic detergent-like structure, causing membrane disruption and leakage of cytoplasmic contents

**PBPs** = penicillin-binding proteins.

### 3.3 Monotherapy versus Combination Therapy

Traditionally, *P. aeruginosa* is one of a few bacterial pathogens for which combination therapy is routinely considered. Two commonly cited reasons for this are the potential for synergistic efficacy and the potential to reduce the emergence of resistance. Early *in vitro* data suggested that various combinations of amikacin, ceftazidime, imipenem, and ciprofloxacin had a synergistic effect in treating *P. aeruginosa*.<sup>[114-116]</sup> These data received additional support when clinical studies of pseudomonal bacteremia demonstrated that survival of neutropenic hosts was better when gentamicin was combined with carbenicillin or ticarcillin.<sup>[117]</sup> Similarly, experimental data suggested that the use of multiple anti-pseudomonal agents had the potential to reduce the emergence of resistant strains.<sup>[118,119]</sup> However, recent clinical data have been more controversial. On the one hand, Safdar et al.<sup>[120]</sup> conducted a meta-analysis on the impact of combination antimicrobial therapy on mortality rates in Gram-negative bacteremia and found that there was a survival benefit in the setting of *P. aeruginosa* bacteremia (odds ratio 0.50; 95% CI 0.30, 0.79). However, four of the five studies included single aminoglycosides in the monotherapy arm – a treatment approach that has been questioned as inherently inadequate.<sup>[121]</sup> In a retrospective analysis, Chamot et al.<sup>[122]</sup> reported that empiric treatment of *P. aeruginosa* bacteremia with adequate combination therapy until determination of definitive sensitivities showed improved survival at 30 days compared

with monotherapy; but once the sensitivities became known, no survival benefit could be distinguished between definitive combination therapy and definitive monotherapy. Other observational studies have concluded that combination antibacterial therapy confers no mortality benefit compared with adequate monotherapy.<sup>[123-125]</sup> Unfortunately, these data suffer from lack of randomization and proper controls. The lack of large, randomized, double-blind, placebo-controlled clinical trials comparing the efficacy of adequate monotherapy with combination antimicrobial therapy in the treatment of *P. aeruginosa* bacteremia hampers clinical recommendations. Still, in the absence of definitive supportive data, there are many infectious disease practitioners who would recommend use of combination therapy for *P. aeruginosa*, especially in severe infections, as morbidity and mortality from these infections are significant, and resistance to antimicrobials continues to rise.<sup>[108,110]</sup> Regional resistance rates and profiles for *P. aeruginosa*, as with other pathogens, are critical in establishing locally relevant empiric antibacterial guidelines.

## 4. Antimicrobial Therapy: Specific Syndromes

### 4.1 Primary *P. aeruginosa* Infections of the Skin

#### 4.1.1 Green Nail Syndrome

Treatment of green nail syndrome includes cutting the detached nail plate, brushing the nail bed with 2% sodium



hypochlorite solution twice daily, and avoidance of chronic moisture.<sup>[22]</sup> This condition also responds to acetic acid soaks and topical application of tobramycin otic or ophthalmic drops under the nail plate and massaged on the cuticle.<sup>[23]</sup>

#### 4.1.2 Interdigital Infections

Due to the mixed nature of the flora cultured from toe-web infections, successful treatment often requires both antibacterials and antifungals. For example, Westmoreland et al.<sup>[126]</sup> achieved success with oral ciprofloxacin treatment and local application of Castellani (carbol-fuchsin) paint. In a randomized, double-blind, placebo-controlled trial, Gupta et al.<sup>[127]</sup> reported that 0.77% ciclopirox gel applied once or twice daily was effective in treating complex toe-web infections that involved dermatophytes, Gram-positive, and Gram-negative bacteria.

#### 4.1.3 Folliculitis

Folliculitis, including that due to *P. aeruginosa*, can often be successfully treated with conservative management due to the self-limiting nature of the disease. However, initiation of oral ciprofloxacin after culture and sensitivity testing has been reported, with good outcomes in severe cases.<sup>[32,33]</sup> In these cases, bathing in a diluted solution of acetic acid following application of gentamicin or tobramycin cream to the affected areas may also suffice. To prevent recurrence, it is important to drain the hot tub of the contaminated water and superchlorinate the tub and the drain or scrub with ammonium quaternium compounds to eradicate the bacterium. *P. aeruginosa* folliculitis may be an indicator of improper pool maintenance or chlorination, and notification of public health may be warranted depending on the nature of the exposure.

#### 4.1.4 Pseudomonas Otitis Externa

*Pseudomonas* otitis externa can be managed by debridement of the serum crust with hypertonic (3%) saline, disinfection with a mixture of alcohol and acetic acid, reduction of inflammation by local application of 50% Burow solution (aluminum subacetate and glacial acetic acid), followed by otic tobramycin, ofloxacin, or a combination ciprofloxacin/dexamethasone otic preparation.

#### 4.1.5 Malignant Otitis Externa

As discussed in section 2.1.4, malignant otitis externa is a serious condition that warrants involvement with a surgical otolaryngology service, as debridement of the ear canal may be necessary. The use of hyperbaric oxygen has also been reported in difficult cases,<sup>[128]</sup> but the mainstay of treatment remains a

prolonged course ( $\geq 6$  weeks) of antimicrobials. A  $\beta$ -lactam such as ceftazidime has been successfully used,<sup>[129]</sup> but the convenience of oral ciprofloxacin versus parenteral regimens is substantial. Oral ciprofloxacin (from 8 weeks to 6 months) has been used, although the increase in ciprofloxacin-resistant strains of *P. aeruginosa* has reduced the efficacy of this approach.<sup>[130]</sup> Shimizu et al.<sup>[37]</sup> has described an approach with aggressive treatment, involving local debridement and intravenous carbapenem therapy for 6 weeks, followed with Burow solution as ear drops.

### 4.2 *P. aeruginosa* Systemic Infections

#### 4.2.1 Bacteremia

*P. aeruginosa* bacteremia may be suspected in the appropriate clinical setting (e.g. febrile neutropenic patient), possibly aided by the characteristic cutaneous manifestations. Appropriate empiric therapy could involve the use of an anti-pseudomonal  $\beta$ -lactam, whether piperacillin, ceftazidime, cefepime, imipenem, or meropenem. If empiric combination therapy is desired, an agent from another class, commonly an aminoglycoside (e.g. tobramycin), may be added. Once susceptibility results are available, antimicrobial therapy may be tailored accordingly. However, treatment for a pseudomonal bacteremia is often complex, especially with multi-drug-resistant strains, and consultation with an infectious disease physician is appropriate.

#### 4.2.2 Severe SSTI and Burns

The principles for antimicrobial selection and administration in skin and soft tissue infections are similar to those described in section 4.2.1, with consideration of combination therapy in severe infections such as gangrenous cellulitis and necrotizing fasciitis. It is paramount that surgical management of these severe infections occurs, with debridement of necrotic tissue to decrease the microbial burden of *P. aeruginosa*. In burn wounds, source control is similarly critical, with excision of necrotic and nonviable tissue as well as infected eschar. Topical antimicrobials, such as silver compounds (silver nitrate, silver sulfadiazine) and mafenide acetate, have played a significant role in decreasing the incidence of invasive burn wound sepsis.<sup>[131]</sup> Systemic antimicrobials are indicated in invasive burn wound infections and sepsis, with combination therapy being preferable.<sup>[11]</sup>

### 4.3 Future Directions

Currently, *P. aeruginosa* strains resistant to all commercially available forms of antimicrobial therapy have already

emerged.<sup>[132]</sup> The voracious ability of the bacterium to acquire multi-drug resistance has galvanized the search for novel treatment agents. Unfortunately, the results of garenoxacin, tigecycline, and ertapenem in the treatment of pseudomonal infections have not been encouraging.<sup>[133-135]</sup> On the other hand, recent data on the efficacy of the new  $\beta$ -lactam molecule ceftobiprole suggest good *P. aeruginosa* coverage, although extensive clinical experience with this drug is still lacking.<sup>[136]</sup> Experimental work by Mangoni et al.<sup>[137]</sup> has explored the possibility of using naturally occurring antimicrobial peptides to bolster current therapeutic modalities, and this option may hold future promise. Other experimental approaches have involved immunotherapy directed against the unique virulence factors of the bacterium. For example, vaccination strategies against pseudomonal lipopolysaccharide have successfully completed phase I and II clinical trials and are currently undergoing phase III testing; and other targeted strategies against alginate, flagella, and pili have met with some experimental success (for a review see Kipnis et al.<sup>[138]</sup>).

In summary, antimicrobial therapy for *P. aeruginosa* infections is dependent on a variety of interacting factors. Currently, significant resources are being focused on defining optimal guidelines; but good clinical judgment in individual situations and knowledge of a region's *Pseudomonas* antimicrobial resistance profile remain of the utmost importance. A range of anti-pseudomonal agents is available to physicians, with continued development of novel drugs. Finally, experimental strategies to treat *P. aeruginosa* infections continue to show promise for future clinical application.

## 5. Conclusion

The cutaneous manifestations of *P. aeruginosa* infections are highly variable, ranging from mild, self-limiting syndromes to life-threatening disease. This plethora of clinical presentations results from the versatility of the micro-organism, and its ability to express a multitude of pathogenic factors. Due to its predilection for water-based reservoir systems, *P. aeruginosa* has a highly ubiquitous nature. Contamination of hospital wards wherein the sickest of patient populations are to be found is a particularly devastating problem. Taking care to prevent transmission is important, and even simple hand washing can have a beneficial effect.<sup>[139]</sup> Still, the mainstay of treatment involves antimicrobial therapy. The selection of a proper anti-pseudomonal therapeutic regimen is needed to control serious infections and to prevent the spread of resistant strains. In extreme cases where widespread structural integrity of the skin is disrupted secondary to *P. aeruginosa* infection, medical man-

agement alone is insufficient and urgent surgical consultation is required. Ultimately, early recognition of the various cutaneous manifestations of *P. aeruginosa* infection can give important clues to more severe underlying disease, aids in subsequent definitive diagnosis, and is critical in optimizing treatment options.

## Acknowledgments

No sources of funding were used to prepare this review. The authors have no conflicts of interest that are directly relevant to the content of this review.

## References

- Blondel-Hill E, Henry DA, Speert DP. *Pseudomonas*. In: Murray PR, editor. Manual of clinical microbiology. 9th ed. Washington, DC: ASM Press, 2007: 734-48
- Silvestre JF, Betloch MI. Cutaneous manifestations due to *Pseudomonas* infection. *Int J Dermatol* 1999; 38 (6): 419-31
- Sato H, Okinaga K, Saito H. Role of pili in the pathogenesis of *Pseudomonas aeruginosa* burn infection. *Microbiol Immunol* 1988; 32 (2): 131-9
- Bejarano PA, Langeveld JP, Hudson BG, et al. Degradation of basement membranes by *Pseudomonas aeruginosa* elastase. *Infect Immun* 1989; 57 (12): 3783-7
- Ostroff RM, Vasil ML. Identification of a new phospholipase C activity by analysis of an insertional mutation in the hemolytic phospholipase C structural gene of *Pseudomonas aeruginosa*. *J Bacteriol* 1987; 169 (10): 4597-601
- Sokol PA. Surface expression of ferripyochelin-binding protein is required for virulence of *Pseudomonas aeruginosa*. *Infect Immun* 1987; 55 (9): 2021-5
- Pier GB, Goldberg JB. *Pseudomonas aeruginosa* A-band and B-band lipopolysaccharides. *Infect Immun* 1995; 63 (12): 4964-5
- Nicas TI, Iglewski BH. Contribution of exoenzyme S to the virulence of *Pseudomonas aeruginosa*. *Antibiot Chemother* 1985; 36: 40-8
- Henry RL, Mellis CM, Petrovic L. Mucoid *Pseudomonas aeruginosa* is a marker of poor survival in cystic fibrosis. *Pediatr Pulmonol* 1992; 12 (3): 158-61
- Meluleni GJ, Grout M, Evans DJ, et al. Mucoid *Pseudomonas aeruginosa* growing in a biofilm in vitro are killed by opsonic antibodies to the mucoid exopolysaccharide capsule but not by antibodies produced during chronic lung infection in cystic fibrosis patients. *J Immunol* 1995; 155 (4): 2029-38
- Pollack M. *Pseudomonas aeruginosa*. In: Mandell GL, Bennett JE, Dolin R, editors. Principles and practice of infectious diseases. 5th ed. Philadelphia (PA): Churchill Livingstone, 2000: 1760-6
- Driscoll JA, Brody SL, Kollef MH. The epidemiology, pathogenesis and treatment of *Pseudomonas aeruginosa* infections. *Drugs* 2007; 67 (3): 351-68
- Wang MC, Liu CY, Shiao AS, et al. Ear problems in swimmers. *J Chin Med Assoc* 2005; 68 (8): 347-52
- Chandrasekar PH, Rolston KV, Kannagara DW, et al. Hot tub-associated dermatitis due to *Pseudomonas aeruginosa*: case report and review of the literature. *Arch Dermatol* 1984; 120 (10): 1337-40
- Willcox MD. *Pseudomonas aeruginosa* infection and inflammation during contact lens wear: a review. *Optom Vis Sci* 2007; 84 (4): 273-8
- Speert DP, Campbell ME, Davidson AG, et al. *Pseudomonas aeruginosa* colonization of the gastrointestinal tract in patients with cystic fibrosis. *J Infect Dis* 1993; 167 (1): 226-9
- Vincent JL, Bihari DJ, Suter PM, et al. The prevalence of nosocomial infection in intensive care units in Europe: results of the European Prevalence

- of Infection in Intensive Care (EPIC) Study. EPIC International Advisory Committee. *JAMA* 1995; 274 (8): 639-44
18. Diekema DJ, Pfaller MA, Jones RN, et al. Survey of bloodstream infections due to gram-negative bacilli: frequency of occurrence and antimicrobial susceptibility of isolates collected in the United States, Canada, and Latin America for the SENTRY Antimicrobial Surveillance Program, 1997. *Clin Infect Dis* 1999; 29 (3): 595-607
  19. Foca M, Jakob K, Whittier S, et al. Endemic *Pseudomonas aeruginosa* infection in a neonatal intensive care unit. *N Engl J Med* 2000; 343 (10): 695-700
  20. Moore M, Marcus MD. Green nails: the role of *Candida* (Syringosporea, Monilia) and *Pseudomonas aeruginosa*. *AMA Arch Derm Syphilol* 1951; 64 (4): 499-505
  21. Chernosky ME, Duker CD. Green nails: importance of *Pseudomonas aeruginosa* in onychia. *Arch Dermatol* 1963; 88: 548-53
  22. Maes M, Richert B, de la Brassinne M. Green nail syndrome or chloronychia. *Rev Med Liege* 2002; 57 (4): 233-5
  23. Sakata S, Howard A. *Pseudomonas chloronychia* in a patient with nail psoriasis [letter]. *Med J Aust* 2007; 186 (8): 424
  24. Aste N, Atzori L, Zucca M, et al. Gram-negative bacterial toe web infection: a survey of 123 cases from the district of Cagliari, Italy. *J Am Acad Dermatol* 2001; 45 (4): 537-41
  25. Lestringant GG, Saarinen KA, Frossard PM, et al. Etiology of toe-web disease in Al-Ain, United Arab Emirates: bacteriological and mycological studies. *East Mediterr Health J* 2001; 7 (1-2): 38-45
  26. Karaca S, Kulac M, Cetinkaya Z, et al. Etiology of foot intertrigo in the District of Afyonkarahisar, Turkey: a bacteriologic and mycologic study. *J Am Podiatr Med Assoc* 2008; 98 (1): 42-4
  27. Fangman W, Burton C. Hyperkeratotic rim of gram-negative toe web infections [letter]. *Arch Dermatol* 2005; 141 (5): 658
  28. Fowler Jr JF, Stege 3rd GC. Hot tub (*Pseudomonas*) folliculitis. *J Ky Med Assoc* 1990; 88 (2): 66-8
  29. Zichichi L, Asta G, Noto G. *Pseudomonas aeruginosa* folliculitis after shower/bath exposure. *Int J Dermatol* 2000; 39 (4): 270-3
  30. Boni R, Nehrhoff B. Treatment of gram-negative folliculitis in patients with acne. *Am J Clin Dermatol* 2003; 4 (4): 273-6
  31. Hollyoak V, Allison D, Summers J. *Pseudomonas aeruginosa* wound infection associated with a nursing home's whirlpool bath. *Commun Dis Rep CDR Rev* 1995; 5 (7): R100-2
  32. Fiorillo L, Zucker M, Sawyer D, et al. The pseudomonas hot-foot syndrome. *N Engl J Med* 2001; 345 (5): 335-8
  33. Yu Y, Cheng AS, Wang L, et al. Hot tub folliculitis or hot hand-foot syndrome caused by *Pseudomonas aeruginosa*. *J Am Acad Dermatol* 2007; 57 (4): 596-600
  34. Prasad HK, Sreedharan S, Prasad HS, et al. Perichondritis of the auricle and its management. *J Laryngol Otol* 2007; 121 (6): 530-4
  35. Keene WE, Markum AC, Samadpour M. Outbreak of *Pseudomonas aeruginosa* infections caused by commercial piercing of upper ear cartilage. *JAMA* 2004; 291 (8): 981-5
  36. Handzel O, Halperin D. Necrotizing (malignant) external otitis. *Am Fam Physician* 2003; 68 (2): 309-12
  37. Shimizu T, Ishinaga H, Seno S, et al. Malignant external otitis: treatment with prolonged usage of antibiotics and Burow's solution. *Auris Nasus Larynx* 2005; 32 (4): 403-6
  38. Roland PS, Stroman DW. Microbiology of acute otitis externa. *Laryngoscope* 2002; 112 (7 Pt 1): 1166-77
  39. Kreger BE, Craven DE, Carling PC, et al. Gram-negative bacteremia: III. Reassessment of etiology, epidemiology and ecology in 612 patients. *Am J Med* 1980; 68 (3): 332-43
  40. Schlossberg D. Multiple erythematous nodules as a manifestation of *Pseudomonas aeruginosa* septicemia. *Arch Dermatol* 1980; 116 (4): 446-7
  41. Llistosella E, Ravella A, Moreno A, et al. Panniculitis in *Pseudomonas aeruginosa* septicemia. *Acta Derm Venereol* 1984; 64 (5): 447-9
  42. Bagel J, Grossman ME. Subcutaneous nodules in *Pseudomonas sepsis*. *Am J Med* 1986; 80 (3): 528-9
  43. Fleming MG, Milburn PB, Prose NS. *Pseudomonas septicemia* with nodules and bullae. *Pediatr Dermatol* 1987; 4 (1): 18-20
  44. Raffi F, Regnier B, Pichon F, et al. *Pseudomonas aeruginosa sepsis* presenting as peripheral subcutaneous nodules: report of 2 cases. *Intensive Care Med* 1988; 14 (4): 434-6
  45. Campo RE, Ratzan KR, Melnick SJ. Subcutaneous nodules as a dermatologic manifestation of bacteremia due to *Pseudomonas aeruginosa*. *South Med J* 1994; 87 (2): 233-5
  46. Nieves DS, James WD. Painful red nodules of the legs: a manifestation of chronic infection with gram-negative organisms. *J Am Acad Dermatol* 1999; 41 (2 Pt 2): 319-21
  47. Teplitz C. Pathogenesis of *Pseudomonas vasculitis* and septic legions. *Arch Pathol* 1965; 80: 297-307
  48. Sangeorzan JA, Bradley SF, Kauffman CA. Cutaneous manifestations of *Pseudomonas* infection in the acquired immunodeficiency syndrome. *Arch Dermatol* 1990; 126 (6): 832-3
  49. Bourelly PE, Grossman ME. Subcutaneous nodule as a manifestation of *Pseudomonas sepsis* in an immunocompromised host. *Clin Infect Dis* 1998; 26 (1): 188-9
  50. Asumang A, Goldsmith AL, Dryden M. Subcutaneous nodules with pseudomonas septicemia in an immunocompetent patient. *Anaesth Intensive Care* 1999; 27 (2): 213-5
  51. Diaz-Valle D, Benitez del Castillo JM, Fernandex Acenero MJ, et al. Endogenous *Pseudomonas endophthalmitis* in an immunocompetent patient. *Eur J Ophthalmol* 2007; 17 (3): 461-3
  52. Aleman CT, Wallace ML, Blaylock WK, et al. Subcutaneous nodules caused by *Pseudomonas aeruginosa* without sepsis. *Cutis* 1999; 63 (3): 161-3
  53. Mull CC, Scarfone RJ, Conway D. Ecthyma gangrenosum as a manifestation of *Pseudomonas sepsis* in a previously healthy child. *Ann Emerg Med* 2000; 36 (4): 383-7
  54. Gencer S, Ozer S, Ege Gul A, et al. Ecthyma gangrenosum without bacteremia in a previously healthy man: a case report. *J Med Case Reports* 2008; 2 (1): 14
  55. Zomorodi A, Wald ER. Ecthyma gangrenosum: considerations in a previously healthy child. *Pediatr Infect Dis J* 2002; 21 (12): 1161-4
  56. Agarwal S, Sharma M, Mehndirata V. Solitary ecthyma gangrenosum (EG)-like lesion consequent to *Candida albicans* in a neonate. *Indian J Pediatr* 2007; 74 (6): 582-4
  57. Lobo I, Pinto A, Ferreira A, et al. Non-pseudomonal ecthyma gangrenosum present in diclofenac-induced agranulocytosis. *Eur J Dermatol* 2008; 18 (3): 350-1
  58. Reich HL, Williams Fadeyi D, Naik NS, et al. Nonpseudomonal ecthyma gangrenosum. *J Am Acad Dermatol* 2004; 50 (5 Suppl.): S114-7
  59. Greene SL, Su WP, Muller SA. Ecthyma gangrenosum: report of clinical, histopathologic, and bacteriologic aspects of eight cases. *J Am Acad Dermatol* 1984; 11 (5 Pt 1): 781-7
  60. Ramar K, Hauer D, Potti A, et al. Ecthyma gangrenosum and chronic lymphocytic leukaemia [letter]. *Lancet Infect Dis* 2003; 3 (2): 113
  61. Chun WH, Kim YK, Kim LS, et al. Ecthyma gangrenosum associated with aplastic anemia. *J Korean Med Sci* 1996; 11 (1): 64-7
  62. Kim EJ, Foad M, Travers R. Ecthyma gangrenosum in an AIDS patient with normal neutrophil count. *J Am Acad Dermatol* 1999; 41 (5 Pt 2): 840-1
  63. Solowski NL, Yao FB, Agarwal A, et al. Ecthyma gangrenosum: a rare cutaneous manifestation of a potentially fatal disease. *Ann Otol Rhinol Laryngol* 2004; 113 (6): 462-4

64. Athappan G, Unnikrishnan A, Chandraprakasam S. Ecthyma gangrenosum: presentation in a normal neonate [letter]. *Dermatol Online J* 2008; 14 (2): 17
65. Gresik CM, Brewster LP, Abood G, et al. Ecthyma gangrenosum following toxic epidermal necrolysis syndrome in a 3-year-old boy: a survivable series of events. *J Burn Care Res* 2008; 29 (3): 555-8
66. Downey DM, O'Bryan MC, Burdette SD, et al. Ecthyma gangrenosum in a patient with toxic epidermal necrolysis. *J Burn Care Res* 2007; 28 (1): 198-202
67. Song WK, Kim YC, Park HJ, et al. Ecthyma gangrenosum without bacteraemia in a leukaemic patient. *Clin Exp Dermatol* 2001; 26 (5): 395-7
68. Singh N, Devi M, Devi S. Ecthyma gangrenosum: a rare cutaneous manifestation caused by *Pseudomonas aeruginosa* without bacteremia in a leukemic patient. *Indian J Dermatol Venereol Leprol* 2005; 71 (2): 128-9
69. Weinberg AN, Swartz MN. Gram-negative coccal and bacillary infections. In: Freedberg IM, Goldsmith LA, Katz S, et al., editors. *Fitzpatrick's dermatology in general medicine*. 6th ed. New York: McGraw-Hill, 2003: 1731-43
70. Inamadar AC, Palit A, Athankiar SB, et al. Periocular ecthyma gangrenosum in a diabetic patient [letter]. *Br J Dermatol* 2003; 148 (4): 821
71. Weedon D. Bacterial and rickettsial infections. In: Weedon D, Strutton G, Rubin AI, editors. *Skin pathology*. Brisbane (QLD): Churchill Livingstone, 2002: 620
72. Carratala J, Roson B, Fernandez-Sabe N, et al. Factors associated with complications and mortality in adult patients hospitalized for infectious cellulitis. *Eur J Clin Microbiol Infect Dis* 2003; 22 (3): 151-7
73. van der Meer JW, Alleman M, Boekhout M. Infectious episodes in severely granulocytopenic patients. *Infection* 1979; 7 (4): 171-5
74. West SK, Joseph A, Foss AJ. *Pseudomonas aeruginosa* eyelid necrosis associated with Felty syndrome. *Ophthalm Plast Reconstr Surg* 2008; 24 (4): 313-4
75. Falagas ME, Pappas VD, Michalopoulos A. Gangrenous, hemorrhagic, bullous cellulitis associated with *Pseudomonas aeruginosa* in a patient with Waldenström's macroglobulinemia. *Infection* 2007; 35 (5): 370-3
76. Atzori L, Ferrelli C, Zucca M, et al. Facial cellulitis associated with *Pseudomonas aeruginosa* complicating ophthalmic herpes zoster [letter]. *Dermatol Online J* 2004; 10 (2): 20
77. Habib TP. Images in clinical medicine: pseudomonas cellulitis [letter]. *N Engl J Med* 2005; 353 (2): e2
78. Poitelea C, Wearne MJ. Periocular necrotizing fasciitis: a case report. *Orbit* 2005; 24 (3): 215-7
79. Akamine M, Miyagi K, Uchihara T, et al. Necrotizing fasciitis caused by *Pseudomonas aeruginosa*. *Intern Med* 2008; 47 (6): 553-6
80. Vaz I. Fournier gangrene. *Trop Doct* 2006; 36 (4): 203-4
81. Martinelli G, Alessandrino EP, Bernasconi P, et al. Fournier's gangrene: a clinical presentation of necrotizing fasciitis after bone marrow transplantation. *Bone Marrow Transplant* 1998; 22 (10): 1023-6
82. Cabrera H, Skoczodopole L, Marini M, et al. Necrotizing gangrene of the genitalia and perineum. *Int J Dermatol* 2002; 41 (12): 847-51
83. Schlager T, Sadler J, Weber D, et al. Hospital-acquired infections in pediatric burn patients. *South Med J* 1994; 87 (4): 481-4
84. Rastegar Lari A, Bahrami Honar H, Alaghebandan R. *Pseudomonas* infections in Tohid Burn Center, Iran. *Burns* 1998; 24 (7): 637-41
85. Santucci SG, Gobara S, Santos CR, et al. Infections in a burn intensive care unit: experience of seven years. *J Hosp Infect* 2003; 53 (1): 6-13
86. Hsueh PR, Teng LJ, Yang PC, et al. Persistence of a multidrug-resistant *Pseudomonas aeruginosa* clone in an intensive care burn unit. *J Clin Microbiol* 1998; 36 (5): 1347-51
87. Agnihotri N, Gupta V, Joshi RM. Aerobic bacterial isolates from burn wound infections and their antibiograms: a five-year study. *Burns* 2004; 30 (3): 241-3
88. Ozkurt Z, Ertek M, Erol S, et al. The risk factors for acquisition of imipenem-resistant *Pseudomonas aeruginosa* in the burn unit. *Burns* 2005; 31 (7): 870-3
89. Wibbenmeyer L, Danks R, Faucher L, et al. Prospective analysis of nosocomial infection rates, antibiotic use, and patterns of resistance in a burn population. *J Burn Care Res* 2006; 27 (2): 152-60
90. Meynard JL, Barbut F, Guiguet M, et al. *Pseudomonas aeruginosa* infection in human immunodeficiency virus infected patients. *J Infect* 1999; 38 (3): 176-81
91. Berger TG, Kaveh S, Becker D, et al. Cutaneous manifestations of *Pseudomonas* infections in AIDS. *J Am Acad Dermatol* 1995; 32 (2 Pt 1): 279-80
92. Meissner M, Spieth K, Wolter M, et al. Cutaneous botryomycosis: a rarely diagnosed bacterial infection of the skin. *Hautarzt* 2007; 58 (11): 966-8
93. Picou K, Batres E, Jarratt M. Botryomycosis: a bacterial cause of mycetoma. *Arch Dermatol* 1979; 115 (5): 609-10
94. Bishop GF, Greer KE, Horwitz DA. *Pseudomonas botryomycosis*. *Arch Dermatol* 1976; 112 (11): 1568-70
95. Conti-Diaz IA, Almeida EA, Rondan M, et al. Cutaneous botryomycosis: report of the two first Uruguayan cases. *Rev Inst Med Trop Sao Paulo* 1996; 38 (5): 375-8
96. Petrozzi JW, Erlich A. Pseudomonal balanitis. *Arch Dermatol* 1977; 113 (7): 952-3
97. Manian FA, Alford RH. Nosocomial infectious balanoposthitis in neutropenic patients. *South Med J* 1987; 80 (7): 909-11
98. Egan CA, O'Reilly MA, Meadows KP, et al. Relapsing Henoch-Schönlein purpura associated with *Pseudomonas aeruginosa* pyelonephritis. *J Am Acad Dermatol* 2000; 42 (2 Pt 2): 381-3
99. Unal S, Ersoz G, Demirkan F, et al. Analysis of skin-graft loss due to infection: infection-related graft loss. *Ann Plast Surg* 2005; 55 (1): 102-6
100. Hanberger H, Garcia-Rodriguez JA, Gobernado M, et al. Antibiotic susceptibility among aerobic gram-negative bacilli in intensive care units in 5 European countries: French and Portuguese ICU Study Groups. *JAMA* 1999; 281 (1): 67-71
101. Livermore DM. Multiple mechanisms of antimicrobial resistance in *Pseudomonas aeruginosa*: our worst nightmare? *Clin Infect Dis* 2002; 34 (5): 634-40
102. Bonomo RA, Szabo D. Mechanisms of multidrug resistance in *Acinetobacter* species and *Pseudomonas aeruginosa*. *Clin Infect Dis* 2006; 43 Suppl. 2: S49-56
103. Rello J, Ausina V, Ricart M, et al. Impact of previous antimicrobial therapy on the etiology and outcome of ventilator-associated pneumonia. *Chest* 1993; 104 (4): 1230-5
104. Neuhauser MM, Weinstein RA, Rydman R, et al. Antibiotic resistance among gram-negative bacilli in US intensive care units: implications for fluoroquinolone use. *JAMA* 2003; 289 (7): 885-8
105. Valencia IC, Kirsner RS, Kerdel FA. Microbiologic evaluation of skin wounds: alarming trend toward antibiotic resistance in an inpatient dermatology service during a 10-year period. *J Am Acad Dermatol* 2004; 50 (6): 845-9
106. Troillet N, Samore MH, Carmeli Y. Imipenem-resistant *Pseudomonas aeruginosa*: risk factors and antibiotic susceptibility patterns. *Clin Infect Dis* 1997; 25 (5): 1094-8
107. Rubinstein E, Lode H, Grassi C. Ceftazidime monotherapy vs. ceftriaxone/tobramycin for serious hospital-acquired gram-negative infections: Antibiotic Study Group. *Clin Infect Dis* 1995; 20 (5): 1217-28
108. Fink MP, Snyderman DR, Niederman MS, et al. Treatment of severe pneumonia in hospitalized patients: results of a multicenter, randomized, double-blind trial comparing intravenous ciprofloxacin with imipenem-cilastatin. The Severe Pneumonia Study Group. *Antimicrob Agents Chemother* 1994; 38 (3): 547-57
109. Norrby SR, Finch RG, Glauser M. Monotherapy in serious hospital-acquired infections: a clinical trial of ceftazidime versus imipenem/cilastatin. European Study Group. *J Antimicrob Chemother* 1993; 31 (6): 927-37
110. Carmeli Y, Troillet N, Eliopoulos GM, et al. Emergence of antibiotic-resistant *Pseudomonas aeruginosa*: comparison of risks associated with different antipseudomonal agents. *Antimicrob Agents Chemother* 1999; 43 (6): 1379-82

111. Giamarellou H. Prescribing guidelines for severe *Pseudomonas* infections. *J Antimicrob Chemother* 2002; 49 (2): 229-33
112. Giamarellou H, Antoniadou A. Antipseudomonal antibiotics. *Med Clin North Am* 2001; 85 (1): 19-42, v
113. Sader HS, Fritsche TR, Jones RN. Potency and spectrum trends for cefepime tested against 65746 clinical bacterial isolates collected in North American medical centers: results from the SENTRY Antimicrobial Surveillance Program (1998-2003). *Diagn Microbiol Infect Dis* 2005; 52 (3): 265-73
114. Giamarellos-Bourboulis EJ, Grecka P, Giamarellou H. In-vitro interactions of DX-8739, a new carbapenem, meropenem and imipenem with amikacin against multiresistant *Pseudomonas aeruginosa*. *J Antimicrob Chemother* 1996; 38 (2): 287-91
115. Giamarellou H, Petrikos G. Ciprofloxacin interactions with imipenem and amikacin against multiresistant *Pseudomonas aeruginosa*. *Antimicrob Agents Chemother* 1987; 31 (6): 959-61
116. Giamarellou H, Zissis NP, Tagari G, et al. In vitro synergistic activities of aminoglycosides and new beta-lactams against multiresistant *Pseudomonas aeruginosa*. *Antimicrob Agents Chemother* 1984; 25 (4): 534-6
117. Bodey GP, Jadeja L, Elting L. *Pseudomonas* bacteremia: retrospective analysis of 410 episodes. *Arch Intern Med* 1985; 145 (9): 1621-9
118. Michea-Hamzehpour M, Pechere JC, Marchou B, et al. Combination therapy: a way to limit emergence of resistance? *Am J Med* 1986; 80 (6B): 138-42
119. Michea-Hamzehpour M, Auckenthaler R, Regamey P, et al. Resistance occurring after fluoroquinolone therapy of experimental *Pseudomonas aeruginosa* peritonitis. *Antimicrob Agents Chemother* 1987; 31 (11): 1803-8
120. Safdar N, Handelsman J, Maki DG. Does combination antimicrobial therapy reduce mortality in Gram-negative bacteraemia? A meta-analysis. *Lancet Infect Dis* 2004; 4 (8): 519-27
121. Paul M, Leibovici L. Combination antibiotic therapy for *Pseudomonas aeruginosa* bacteraemia. *Lancet Infect Dis* 2005; 5 (4): 192-13; discussion 193-4
122. Chamot E, Boffi El Amari E, Rohner P, et al. Effectiveness of combination antimicrobial therapy for *Pseudomonas aeruginosa* bacteremia. *Antimicrob Agents Chemother* 2003; 47 (9): 2756-64
123. Chatziniolaou I, Abi-Said D, Bodey GP, et al. Recent experience with *Pseudomonas aeruginosa* bacteremia in patients with cancer: retrospective analysis of 245 episodes. *Arch Intern Med* 2000; 160 (4): 501-9
124. Leibovici L, Paul M, Poznanski O, et al. Monotherapy versus beta-lactam-aminoglycoside combination treatment for gram-negative bacteremia: a prospective, observational study. *Antimicrob Agents Chemother* 1997; 41 (5): 1127-33
125. Siegman-Igra Y, Ravona R, Primerman H, et al. *Pseudomonas aeruginosa* bacteremia: an analysis of 123 episodes, with particular emphasis on the effect of antibiotic therapy. *Int J Infect Dis* 1998; 2 (4): 211-5
126. Westmoreland TA, Ross EV, Yeager JK. *Pseudomonas* toe web infections. *Cutis* 1992; 49 (3): 185-6
127. Gupta AK, Skinner AR, Cooper EA. Evaluation of the efficacy of ciclopirox 0.77% gel in the treatment of tinea pedis interdigitalis (dermatophytosis complex) in a randomized, double-blind, placebo-controlled trial. *Int J Dermatol* 2005; 44 (7): 590-3
128. Carfrae MJ, Kesser BW. Malignant otitis externa. *Otolaryngol Clin North Am* 2008; 41 (3): 537-49
129. Johnson MP, Ramphal R. Malignant external otitis: report on therapy with ceftazidime and review of therapy and prognosis. *Rev Infect Dis* 1990; 12 (2): 173-80
130. Bernstein JM, Holland NJ, Porter GC, et al. Resistance of *Pseudomonas* to ciprofloxacin: implications for the treatment of malignant otitis externa. *J Laryngol Otol* 2007; 121 (2): 118-23
131. Pruitt Jr BA, McManus AT, Kim SH, et al. Burn wound infections: current status. *World J Surg* 1998; 22 (2): 135-45
132. Wang CY, Jerng JS, Chen KY, et al. Pandrug-resistant *Pseudomonas aeruginosa* among hospitalised patients: clinical features, risk-factors and outcomes. *Clin Microbiol Infect* 2006; 12 (1): 63-8
133. Reinert RR, Low DE, Rossi F, et al. Antimicrobial susceptibility among organisms from the Asia/Pacific Rim, Europe and Latin and North America collected as part of TEST and the in vitro activity of tigecycline. *J Antimicrob Chemother* 2007; 60 (5): 1018-29
134. Fritsche TR, Sader HS, Jones RN. Potency and spectrum of garenoxacin tested against an international collection of skin and soft tissue infection pathogens: report from the SENTRY antimicrobial surveillance program (1999-2004). *Diagn Microbiol Infect Dis* 2007; 58 (1): 19-26
135. Burkhardt O, Derendorf H, Welte T. Ertapenem: the new carbapenem 5 years after first FDA licensing for clinical practice. *Expert Opin Pharmacother* 2007; 8 (2): 237-56
136. Rossolini GM. Redesigning beta-lactams to combat resistance: summary and conclusions. *Clin Microbiol Infect* 2007; 13 Suppl. 2: 30-3
137. Mangoni ML, Maisetta G, Di Luca M, et al. Comparative analysis of the bactericidal activities of amphibian peptide analogues against multidrug-resistant nosocomial bacterial strains. *Antimicrob Agents Chemother* 2008; 52 (1): 85-91
138. Kipnis E, Sawa T, Wiener-Kronish J. Targeting mechanisms of *Pseudomonas aeruginosa* pathogenesis. *Med Mal Infect* 2006; 36 (2): 78-91
139. Larson EL, Cimiotti JP, Haas J, et al. Gram-negative bacilli associated with catheter-associated and non-catheter-associated bloodstream infections and hand carriage by healthcare workers in neonatal intensive care units. *Pediatr Crit Care Med* 2005; 6 (4): 457-61

---

Correspondence: Dr Andrew N. Lin, Division of Dermatology and Cutaneous Sciences, 2-104 Clinical Sciences Building, University of Alberta, Edmonton, AB, Canada T6G 2G3.  
E-mail: andrew.lin@ualberta.ca