



# Addressing Frequently Asked Questions and Dispelling Myths About Melanocytic Nevi in Children

James Anderson-Vildósola, MD, Ángela Hernández-Martín, MD\*

## KEYWORDS

- Congenital melanocytic nevus • Acquired melanocytic nevus • Melanoma • Sunscreen
- Sun protection • Children

## KEY POINTS

- The risk of malignancy of an isolated CMN is very low regardless of its size and location.
- The number of acquired congenital melanocytic nevus increases with age and is higher in children with lower phototypes and intense sun exposure.
- MN may clear in color and acquire volume with age, but this morphological change does not indicate malignant transformation.
- Information such as family history of melanoma or personal history of repeated sunburns can help identify which patients are at increased risk for melanoma.
- Sunscreens must be applied to the entire skin surface exposed to the sun and not only and specifically to melanocytic nevus.

## INTRODUCTION

Melanocytic nevi (MN) are congenital (CMN) or acquired (AMN) benign melanocytic neoplasms. CMN are present from birth, although depending on their size and color, they may not become clinically evident until the first months of life. The incidence of CMN is estimated between 0.2% and 2.1% of newborns.<sup>1,2</sup> Classically, they have been divided according to the size of their diameter into small (<1.5 cm), medium (1.5–20 cm), and large (>20 cm).<sup>3</sup> In 2004, the giant CMN category was added to designate nevi with a diameter exceeding 40 cm.<sup>4</sup> CMN can present as single or multiple lesions. In the latter, there may be a larger nevus accompanied by other smaller ones (satellite CMN) or multiple lesions of similar size (multiple CMN).

AMN develop throughout time, predominantly during the first two decades of life.<sup>5</sup> The most common AMN are small, pigmented lesions (1–5 mm), homogeneous in color, with well-defined

and regular borders. In some cases, color may be heterogeneous, but symmetry is present, and there are no additional clinical or dermoscopic concerning signs. Depending on their clinical and histologic appearance, specific subtypes are distinguished, among which are Spitz nevus and Reed nevus, typically presenting in children. Spitz nevus prevalence varies between 1.4 and 7 cases per 100,000 inhabitants, and it is characteristically a nonpigmented AMN with a reddish hue (**Fig. 1**).<sup>6</sup> From a histologic point of view, it is distinguished by the presence of theca of melanocytic cells of epithelioid or spindle morphology. The pigmented variant is called Reed nevus and is defined by dark-brown pigmentation and a dermoscopic starburst pattern (**Figs. 2 and 3**).<sup>7</sup> Another subtype of AMN is called atypical or dysplastic nevus, which, despite its benign biologic behavior, presents an alarming appearance because of its heterogeneous tone, size, and irregularity of its edges.<sup>8</sup> In

Department of Dermatology, Hospital Infantil Niño Jesús, Madrid, Spain

\* Corresponding author. Department of Dermatology, Hospital Infantil Niño Jesús, Avda. Menéndez Pelayo 65, Madrid 28009, Spain.

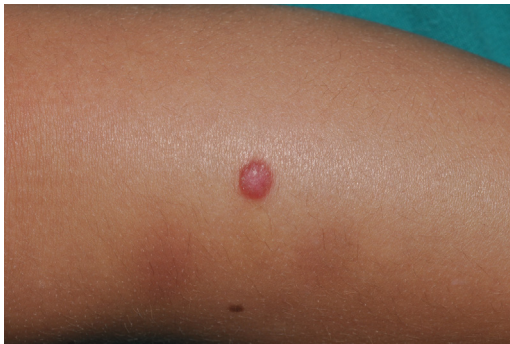E-mail address: ahernandez@aedv.es

Dermatol Clin 40 (2022) 51–59

<https://doi.org/10.1016/j.det.2021.09.005>

0733-8635/22/© 2021 Elsevier Inc. All rights reserved.

Descargado para Anonymous User (n/a) en Community of Madrid Ministry of Health de ClinicalKey.es por Elsevier en noviembre 28, 2021. Para uso personal exclusivamente. No se permiten otros usos sin autorización. Copyright ©2021. Elsevier Inc. Todos los derechos reservados.

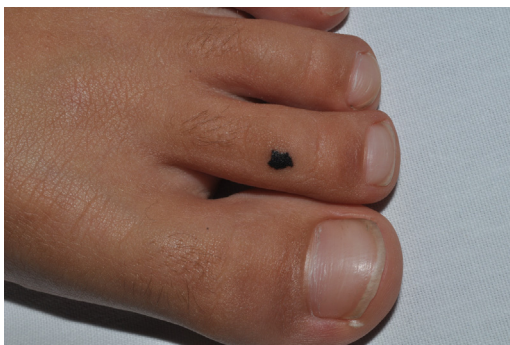

**Fig. 1.** Spitz nevus. Red dome-shaped papule on the lower limb of a 3-year-old boy.

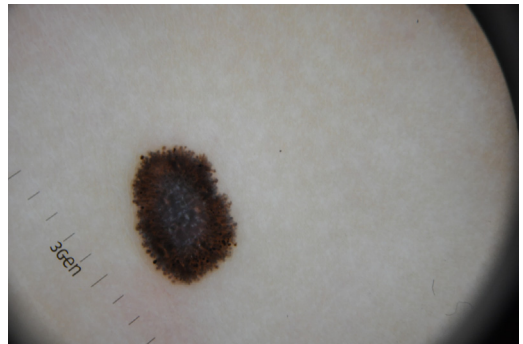general, dysplastic nevi are rare in childhood except in the context of dysplastic nevus syndrome, defined by the existence of a history of melanoma in one or more first- or second-degree relatives, the presence of 50 or more MN with the aforementioned “atypical” clinical appearance, and their distinctive histologic characteristics. Despite their low frequency, patients with atypical or dysplastic nevi compose a particular subgroup to consider because of their increased likelihood of developing melanoma.<sup>9</sup>

The reason for the appearance of MN is not precisely known. Molecular studies indicate that CMN appear as a result of somatic mutations in *NRAS* and *BRAF* genes,<sup>10,11</sup> whereas AMN would be mainly conditioned by mutations in *BRAF*.<sup>12–14</sup> Despite CMN having a similar mutational profile as melanoma,<sup>15–17</sup> only a tiny proportion of nevi ultimately give rise to melanoma. It is estimated that any single nevus’s annual transformation rate ranges from approximately 1 in 200,000 in individuals younger than 40 years of age to approximately 1 in 33,000 if they are older than 60 years.<sup>18</sup>

MN appear mainly in childhood and are a cause for concern in parents and caregivers, because of the aesthetic consequences and the risk of malignant transformation, and other uncertainties based



**Fig. 2.** Reed nevus. Hyperpigmented irregularly bordered lesion on dorsum of toe.



**Fig. 3.** Reed nevus. Dermoscopy of Reed nevus showing the classical starburst pattern.

more on beliefs than on proper scientific evidence. In this review, we answer the most frequently asked questions posed by parents and caregivers, basing our responses on scientific evidence.

### DO CONGENITAL MELANOCYTIC NEVI HAVE A HIGH RISK OF MALIGNANT TRANSFORMATION?

Although classically it has been considered that CMN had a high risk of malignant transformation, this view has largely changed over the years. In the 1970s and 1980s, it was considered that the risk of developing melanoma within a CMN was about 20%, but estimates were imprecise because of small study sizes and selection bias, which overestimated the risk.<sup>19–21</sup> However, subsequent series that included a more significant number of patients observed a markedly lower risk. A systematic review published in 2006 with data from 6571 patients<sup>19</sup> determined that the incidence varied widely depending on the sample size, ranging between 0.05% in the largest sample of 3922 cases,<sup>1</sup> and 10.7% in a sample of 56 cases.<sup>20</sup> According to this systematic review, the overall incidence of melanoma is much higher in large or giant CMN, whereas melanoma seems to be exceptional in small CMN.<sup>19</sup> More recently, a prospective study conducted in the United Kingdom with a cohort of 448 patients observed an overall incidence of 2.2%.<sup>22</sup> These authors found that the 10 patients in the study who developed melanoma had more than one CMN, whereas no patient with a single CMN, regardless of size and location, presented this outcome. However, 7 of the 10 patients who developed melanoma had a giant CMN as one of the lesions. Hence, if we exclusively consider this group of patients, melanoma incidence rises to 8%. Likewise, although there is extensive literature highlighting an elevated risk of malignant transformation of large lesions located on the central area of the

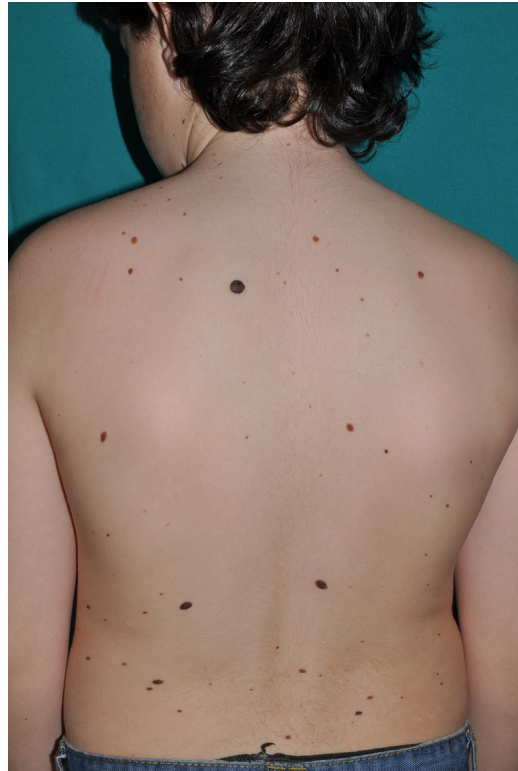back,<sup>19,23,24</sup> the authors found that the factor with the highest statistical power for predicting melanoma in the context of a CMN was not the size or location of the lesion, but rather the detection of a concomitant morphologic alteration in the central nervous system (CNS).<sup>22</sup> In turn, the latter is more likely in newborns with two or more CMN regardless of their size and location. Consequently, these authors recommend a screening MRI study of the CNS for all newborns with more than one CMN, especially if one of them is giant.<sup>22</sup>

The risk of malignancy of an isolated CMN is very low no matter the size or location. If the newborn has multiple CMN, and, in particular, if one of them is larger than the rest, close dermatologic and neurologic follow-up is recommended. Performing an MRI of the CNS within the first 6 months of life must be considered.

### WHY DOES MY CHILD HAVE MORE AND MORE MOLES?

Patients may acquire an increasing number of MN throughout childhood, and in some patients this increase is particularly striking (Fig. 4). The prevalence of AMN is related to various factors including age, sex, phototype, and intensity of sunlight exposure. Concerning age, few nevi are present in early childhood, but their number increases with time, especially from 12 years of age on, reaching a peak in the third decade of life.<sup>25,26</sup> The difference in prevalence by sex is controversial,<sup>27,28</sup> but it seems the number of AMN is higher in adolescent men than in women after menarche.<sup>29</sup> As for skin type, individuals with a lower phototype (red hair, blue eyes, easy sunburning) tend to have a higher number of MN than individuals of darker skin phototype.<sup>26,29</sup>

Regarding sun exposure, it seems that the intensity of sun exposure is proportional to the number of AMN,<sup>30,31</sup> whether it is intermittent or continuous.<sup>32</sup> The beneficial effect of sunscreens during childhood in reducing the appearance of MN is controversial. A meta-analysis of the literature published in 2013 found no evidence that the use of sunscreens in childhood prevented the appearance of MN,<sup>33</sup> but another more recent study observed this beneficial effect if the sun protection factor (SPF) is higher than 30.<sup>29</sup> On the contrary, the use of sunscreens with an SPF less than 30 is related to a tendency to develop a vaster number of nevi, probably caused by the combination of insufficient protection and a false sense of security.<sup>29</sup>



**Fig. 4.** Acquired melanocytic nevus. Twelve-year-old boy showing numerous acquired melanocytic nevi on the back. Note the different size, morphology, and color.

An increasing number of AMN can develop throughout childhood, especially in children with fair skin/lower phototypes and frequent or intense sun exposure.

### WHAT ARE THE WARNING SIGNS THAT A MOLE IS BECOMING MALIGNANT?

The incidence of melanoma in children is much lower than in adults, and exceedingly rare in children younger than 10 years of age, so melanoma is not usually included among the main differential diagnoses in younger children. Complicating matters more, the clinical warning signs are also different, making it challenging to identify. Thus, the classic warning signs included in the acronym “ABCDE” (asymmetry, border irregularity, color variation, diameter  $\geq 6$  mm, evolution) may be absent in up to 60% of preadolescents and 40% of adolescents. In addition, because 76% of melanoma in children are amelanotic (nonpigmented) and develop as red or pink lesions, “modified ABCD” criteria have been proposed: A for amelanotic (red or pink lesion, and therefore not necessarily dark); B for “bleeding, bump” (ulceration

and bulging are indicative clinical data); C for color uniformity (and not heterogeneous, as classically occurs in adult melanoma); and D for “de novo, any diameter” (without preceding lesion, of any size) (Table 1).<sup>34</sup> Another additional criterion for melanoma suspicion is the acronym EFR (elevated, firm, and growing), regarding the appearance of an elevated, firm, and growing lesion persisting for more than 1 month. The EFR rule helps exclude inflammatory lesions, such as insect bites or folliculitis, common in the pediatric population, that are usually stable and tend to resolve in less than 1 month. Unlike in adult melanoma, the lesion diameter (D of the ABCDE rule) is not a valid discrimination factor for pediatric melanoma, so the D of the modified ABCD rule for children includes lesions of any diameter.<sup>34</sup> Some series observed that about 50% of pediatric deaths caused by melanoma had lesions of 5 mm or less in diameter,<sup>34–36</sup> so the size of lesions in children does not serve to discriminate between benign and malignant neoplasms. Finally, interpreting evolution, or the E of the classic rule, is challenging in children because morphologic changes of MN throughout childhood are frequent and lack prognostic significance (Fig. 5).

Despite the extremely low incidence of melanoma in children, it must be kept in mind that specific subgroups of pediatric patients are at a higher risk, such as fair-skinned, blue-eyed, red-haired individuals; children with poor tanning ability and prone to sunburn; or those with a genetic predisposition (familial melanoma, xeroderma pigmentosum, or immunodeficiencies).<sup>37</sup>

The classical “ABCDE” criteria are not sensitive enough in children and must be accompanied by additional clinical data adapted to the pediatric age (modified ABCD criteria). Melanomas in children younger than 10 years of age usually manifest as elevated, firm, and growing red bumps, whereas clinical signs of malignant transformation in adolescents are more likely to adapt to classical ABCDE rules. Simple information, such as a family history of melanoma or personal history of repeated sunburns, can help identify which patients are at increased risk for melanoma.

### IS IT NECESSARY THAT A DERMATOLOGIST REVIEW ALL MELANOCYTIC NEVI IN CHILDREN (CONGENITAL AND ACQUIRED)?

Although it is difficult to calculate because of the high prevalence of MN in a healthy population, the estimated risk of MN becoming malignant is low, ranging from 0.0005% (or <1 in 200,000)

**Table 1**  
Conventional ABCDE melanoma detection criteria and additional ABCD criteria for children

Conventional Criteria	Additional Criteria for Children
<b>A</b> Asymmetry	<b>A</b> melanotic
<b>B</b> Border irregularity	<b>B</b> leeding, <b>B</b> ump
<b>C</b> Color variation	<b>C</b> olor uniformity
<b>D</b> Diameter $\geq 6$ mm	<b>D</b> e novo, any Diameter
<b>E</b> Evolution	<b>E</b> FG <sup>a</sup> rule

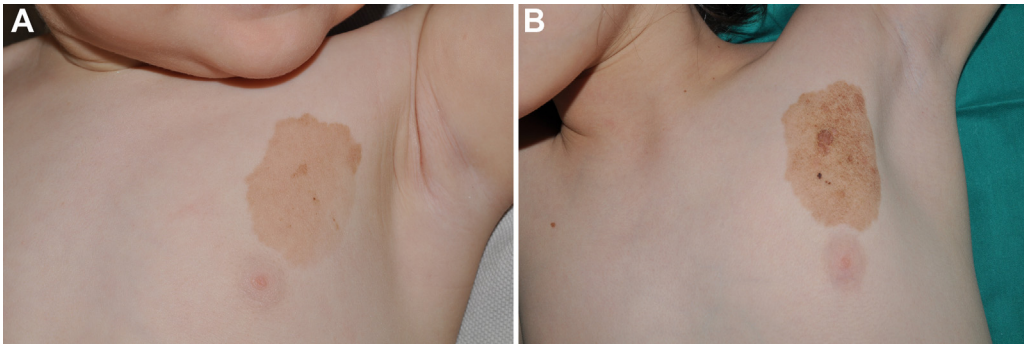
<sup>a</sup> Elevated, firm, and growing.

before the age of 40 years, to 0.003% (1 in 33,000).<sup>18</sup> In addition, melanoma arises as a de novo lesion in 70% of cases,<sup>38,39</sup> so it does not seem necessary to refer all patients with benign-looking MN to specialized care.

Despite this, and although the risk of melanoma within MN in the general pediatric population is low, we should not exclude beforehand such diagnostic possibility. Therefore, the previously mentioned groups at high risk of developing melanoma (ie, family history of melanoma, repeated sunburns, or immunodeficiency), any clinically suspicious lesion (according to ABCDE rules in different ages), or even one with an apparently benign morphology but that raises personal concerns about its biologic behavior, should be referred to a dermatologist.

Likewise, MN with potential relevant aesthetic impact may need a referral for a multidisciplinary approach. In particular, the deterioration in patients' quality of life because of facial skin lesions has been well studied.<sup>40,41</sup> Keep in mind that a significant portion of CMN undergo marked lightning throughout childhood,<sup>42</sup> and a “wait and see” approach may be reasonable. Nor should it be forgotten that surgical interventions, especially when the benefit is not entirely clear, can entail considerable emotional stress for the patient and parents and caregivers, and pose a risk associated with repeated surgical interventions under general anesthesia.<sup>43,44</sup> However, it is essential to assess each case individually, paying attention to the patients' and their parents' and caregivers' expectations, because hopes frequently do not correspond with reality, and the scar may not be as satisfactory as expected or may even be unaesthetic.<sup>45</sup> Along with other authors,<sup>46</sup> we recommend addressing surgically those facial nevi in which a potential disfiguring surgical sequelae is less than the original lesion.





**Fig. 5.** Congenital melanocytic nevus. Changing appearance with time of a congenital melanocytic nevus of small-to-medium size on the trunk when the patient was 9 months old (A) and 10 years old (B).

Children with benign-looking MN do not require routine referral to the dermatologist unless the patient is at risk of developing melanoma for any reason; has atypical-appearing, rapidly evolving, or symptomatic nevi; or has a nevus requiring a multidisciplinary approach because of its aesthetic impact.

of acral melanomas are different from those of acral nevi, ruling out a potential association.<sup>51,52</sup>

There is no current evidence to support the belief that acral MN have a more aggressive biologic behavior than MN in other locations, so their diagnosis, management, and monitoring should be similar to that of lesions in other locations.

### ARE MELANOCYTIC NEVI ON THE PALMS AND SOLES MORE DANGEROUS THAN THOSE IN OTHER LOCATIONS?

There is a widely held belief that MN in palms and soles have a higher risk of malignant transformation than those in other parts of the body, but current evidence does not support this. Acral melanomas are the least common type in the United States, representing 2% to 3% of all melanomas.<sup>47</sup> Acral melanomas are the most prevalent group in Japan, where they account for 47% of all melanomas.<sup>48</sup> Although in the White population the risk of suffering a melanoma is directly proportional to the total number of AMN, the number of AMN present in Japanese individuals' soles does not seem to be a risk factor for suffering acral melanoma.<sup>49</sup> Hence, in a study of 104 Japanese patients with acral melanoma, not only did less than 11% of patients have a previous MN at that location, but the number of acral MN was not higher in people with acral melanoma than the rest of the population.<sup>50</sup> Another study compared the topographic distribution of acral MN with melanomas at this location, finding a different distribution of the locations of MN and acral melanomas.<sup>48</sup> Acral melanomas in the Japanese population appear *de novo*, without preceding MN, in almost 90% of cases and arise in a different location from where acral MN usually appear.<sup>48</sup> In addition, the mutational profile of palmar and plantar MN is similar to MN located elsewhere on the body,<sup>48,50</sup> whereas the mutations

### HOW OFTEN SHOULD MELANOCYTIC NEVI BE CHECKED?

Patients with increased risk of melanoma should be reviewed periodically, along with clinical and dermoscopic follow-up of doubtful lesions, but it is uncertain what approach to take for children with CMN and AMN in the absence of warning signs. Many experts recommend an annual check-up of MN, whereas others suggest that patients request a follow-up visit only if they observe morphologic changes or discomfort in any of the lesions. Nevertheless, there is no scientific evidence to support the former, nor does self-examination seem reliable enough.<sup>53</sup> Traditionally, the classic ABCDE rule has been emphasized to teach how to detect worrisome MN,<sup>54</sup> but these warning signs may have limited utility in the pediatric age.<sup>34</sup> In our practice, we do not routinely review CMN or AMN when their clinical and dermoscopic characteristics are banal, but we recommend a follow-up visit in the event of any morphologic change or new-onset symptoms.

There is no well-defined universal strategy with sufficient evidence to make recommendations on the specific need to review MN with benign characteristics in children with no risk factors for melanoma or on the ideal timing of such reviews.

### IS IT BETTER TO BE “SAFE THAN SORRY”? (IS IT ADVISABLE TO REMOVE AS MANY NEVI AS POSSIBLE AS SOON AS POSSIBLE?)

There is strong evidence that the number of AMN is a significant risk factor for the development of melanoma,<sup>27,28</sup> but the effectiveness of surgical excision as a preventive measure is more than doubtful. It is logical to think that the greater the number of melanocytes, the greater the risk of malignant transformation of these cells, and therefore, the prophylactic surgical removal of MN would, in theory, have a potential therapeutic value. However, the question is whether this attitude is cost-effective, something that has not been proved useful in young individuals so far.<sup>55</sup>

The risk of malignancy in solitary CMN is low, regardless of their size and location. Moreover, a substantial number of patients develop melanoma outside of CMN,<sup>19</sup> so theoretically, complete removal of the lesion would not eliminate the risk. Besides, there are cases where melanoma appeared where a CMN had previously been partially or entirely removed.<sup>56</sup> Consequently, the excision of CMN does not eliminate the risk of melanoma.<sup>19</sup> Regarding the theoretic possibility of malignancy of AMN, calculating the percentage of malignancy is complex because of the latter's high prevalence; however, only 30% of melanomas appear on previous AMN.<sup>38,39</sup> Accordingly, most of them would be de novo lesions, and prophylactic removal of AMN would not be beneficial.

There is no scientific evidence to support prophylactic removal of either AMN or CMN, and therefore, surgery would only be advocated if there are clinical findings to advise it.

### ARE NEVI THAT BULGE WORRISOME?

Often, patients come to our office expressing their desire to remove exophytic lesions on the body, mostly on their trunk or scalp. The motivations are diverse, but in general, aesthetic criteria prevail and, secondarily, the discomfort caused by rubbing against clothing or during hairstyling. Descriptions of the natural progression of AMN pointing to their natural evolution toward elevation date back to the nineteenth century.<sup>57</sup> This slow elevation from a nearly flat to raised lesion occurs because of the migration of melanocytes to deeper regions of the dermis, “lifting” the overlying tissue and producing a color lightning, which can become pink without evidence of pigmentation (Fig. 6).<sup>57–59</sup> Importantly, in most cases, this slow progression is not worrisome. Unless the lesion

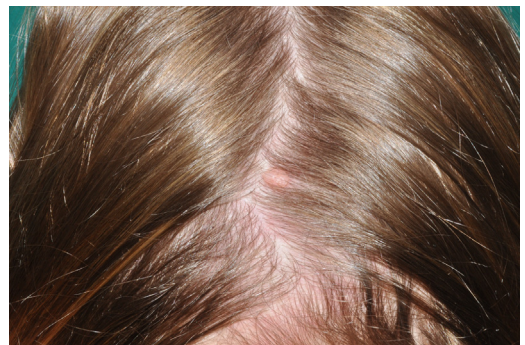is symptomatic or subject to repeated trauma by brushes or clothing, otherwise banal-appearing lesions that are raised do not require removal.

MN are changing lesions in changing individuals, and not all morphologic changes reflect malignant transformation. MN may clear in color and acquire volume with age, but this morphologic change does not indicate malignant transformation.

### HOW CAN I PREVENT MALIGNANT TRANSFORMATION OF MOLES?

Intense sun exposure is a well-known risk factor for developing skin cancer. In particular, melanoma development is strongly related to repeated sunburns during childhood and adolescence, and therefore, implementing the appropriate strategies for sun protection is essential. However, a study performed in 2013 demonstrated that only 10% of students between 14 and 17 years of age applied sunscreen with an SPF greater than or equal to 15 while performing outdoor activities.<sup>60</sup> Younger children are prone to use sunscreens properly because their parents and caregivers take on the responsibility to apply them regularly. However, the adherence to sun protection diminishes noticeably with age. For example, a study performed in the United States observed that 69% of adolescents aged between 11 and 18 years had experienced sunburn the previous summer.<sup>61</sup>

Physicians and school policies play a crucial role in educational interventions to promote sun-protective behaviors, but, most interestingly, only 44% of adolescents and their parents reported receiving advice on photoprotection from their physicians, whereas only 22% of physicians acknowledged giving recommendations on the subject to their patients.<sup>62</sup> A recent survey among pediatricians showed that sun protection ranked low among preventive topics



**Fig. 6.** Raised acquired pink melanocytic nevus on the scalp in a 14-year-old girl. The lesion was excised because of repeated traumatization of the lesion during hair styling.

and that only a minority of them offered to counsel about sun protection and indoor tanning.<sup>63</sup>

These data show that educational interventions in sun protection behaviors have ample room for improvement.<sup>64</sup>

Although the risk of malignant transformation of an individual MN is low, appropriate sun protection from an early age is important in minimizing this risk. Caregivers and parents play a pivotal role, and improvement of educational interventions carried out by physicians and health care providers is needed.

### WHICH IS THE BEST SUNSCREEN?

The importance of proper use of topical sunscreens in childhood to prevent the cumulative effect of solar radiation (UVA and UVB) on the skin is well known to parents and caregivers and raises a recurring question about the ideal product. Sunscreens contain chemical (organic) or physical (inorganic) compounds that block ultraviolet radiation. In general, physical or inorganic sunscreens are preferred in children to minimize the risks of sensitization and toxicity.<sup>65</sup> The SPF, broad-spectrum activity against UVA and UVB, the amount of sunscreen applied, and the regularity of application are essential factors determining the usefulness of a sunscreen's protective effects.

The SPF only measures UVB protection (not UVA) and is not a measure of time but a measure of the fraction of sunburn-producing UV rays that reach the skin. For example, "SPF 20" means that one-twentieth of the burning radiation will reach the skin.<sup>66</sup> The American Academy of Dermatology recommends using SPF sunscreens equal to or greater than 30 regardless of skin type.<sup>67</sup> It is important to use sunscreen with broad-spectrum activity. The amount of protective cream is another element that determines its effectiveness, which is proportional to the amount applied. A study carried out with primary school children aged 5 to 12 years who applied the sunscreen themselves found that they used less than half of the recommended 2 g/cm<sup>2</sup>.<sup>68</sup> Finally, regular reapplication of the sun protection cream, especially after bathing and physical exercise, optimizes its sustained effect throughout the photo-exposure period. The American Academy of Dermatology recommends reapplying sunscreen approximately every 2 hours, or after swimming or sweating, according to the directions on the bottle.<sup>67</sup> Sun protection strategies in addition to the correct use of sunscreens include photoprotective clothing and sunglasses, and avoiding intense sunlight at peak hours of UV radiation.

The best sunscreen is the one that you apply in enough quantity and frequency (again and again). Ensure your sunscreen offers broad-spectrum protection (blocks UVA and UVB radiation) and has a minimum SPF of 30.

### CLINICS CARE POINTS

- The risk of malignancy of a solitary congenital melanocytic nevus is low, regardless of its size and location.
- The number of acquired melanocytic nevi increases throughout childhood, especially in children with lower phototypes and those who are more exposed to the sun, particularly if repeated sunburns.
- Surgical management of melanocytic nevi does not prevent melanoma and must be discussed individually.
- Melanoma is extremely rare in children younger than 10 years of age and may be challenging to recognize. The classic "ABCDE" alarm criteria for early detection of melanoma are not sensitive enough in children and must be accompanied by additional clinical information and pediatric-related criteria.
- Sunscreens must be applied to the entire skin surface exposed to the sun and not only and specifically to melanocytic nevi. Clothing, hats, and sunglasses offer additional protection.
- Physicians and school policies play a key role in educational interventions to promote sun-protective behaviors to prevent skin cancer.

### DISCLOSURE

Dr J. Anderson-Vildósola has no conflict of interest to declare. Dr A. Hernández-Martín has conducted clinical trials for Mayne Pharma and Celgene; and has received honoraria for academic lectures from Viatrix, Leti Pharma, Pierre Fabre, and Beiersdorf Laboratories.

### REFERENCES

1. Berg P, Lindelöf B. Congenital melanocytic naevi and cutaneous melanoma. *Melanoma Res* 2003;13:441–5.
2. Rivers JK, Frederiksen PC, Dibdin C. A prevalence survey of dermatoses in the Australian neonate. *J Am Acad Dermatol* 1990;23:77–81.
3. Kopf AW, Bart RS, Hennessey P. Congenital nevocytic nevi and malignant melanomas. *J Am Acad Dermatol* 1979;1:123–30.

4. Krengel S, Scope A, Dusza SW, et al. New recommendations for the categorization of cutaneous features of congenital melanocytic nevi. *J Am Acad Dermatol* 2013;68:441–51.
5. Crane LA, Mokrohisky ST, Dellavalle RP, et al. Melanocytic nevus development in Colorado children born in 1998: a longitudinal study. *Arch Dermatol* 2009;145:148–56.
6. Dika E, Ravaioli GM, Fanti PA, et al. Spitz nevi and other spitzoid neoplasms in children: overview of incidence data and diagnostic criteria. *Pediatr Dermatol* 2017;34:25–32.
7. Requena L, Yus ES. Pigmented spindle cell naevus. *Br J Dermatol* 1990;123:757–63.
8. Rosendahl CO, Grant-Kels JM, Que SKT. Dysplastic nevus: fact and fiction. *J Am Acad Dermatol* 2015;73:507–12.
9. Goldsmith LA, Askin FB, Chang AE, et al. Diagnosis and treatment of early melanoma: NIH consensus development panel on early melanoma. *JAMA* 1992;268:1314–9.
10. Charbel C, Fontaine RH, Malouf GG, et al. NRAS mutation is the sole recurrent somatic mutation in large congenital melanocytic nevi. *J Invest Dermatol* 2014;134:1067–74.
11. Kinsler VA, Thomas AC, Ishida M, et al. Multiple congenital melanocytic nevi and neurocutaneous melanosis are caused by postzygotic mutations in codon 61 of NRAS. *J Invest Dermatol* 2013;133:2229–36.
12. Poynter JN, Elder JT, Fullen DR, et al. BRAF and NRAS mutations in melanoma and melanocytic nevi. *Melanoma Res* 2006;16:267–73.
13. Wu J, Rosenbaum E, Begum S, et al. Distribution of BRAF T1799A(V600E) mutations across various types of benign nevi: implications for melanocytic tumorigenesis. *Am J Dermatopathol* 2007;29:534–7.
14. Ichii-Nakato N, Takata M, Takayanagi S, et al. High frequency of BRAFV600E mutation in acquired nevi and small congenital nevi, but low frequency of mutation in medium-sized congenital nevi. *J Invest Dermatol* 2006;126:2111–8.
15. Ball NJ, Yohn JJ, Morelli JG, et al. RAS mutations in human melanoma: a marker of malignant progression. *J Invest Dermatol* 1994;102:285–90.
16. van 't Veer LJ, Burgering BM, Versteeg R, et al. N-ras mutations in human cutaneous melanoma from sun-exposed body sites. *Mol Cell Biol* 1989;9:3114–6.
17. Davies H, Bignell GR, Cox C, et al. Mutations of the BRAF gene in human cancer. *Nature* 2002;417:949–54.
18. Tsoo H, Bevona C, Goggins W, et al. The transformation rate of moles (melanocytic nevi) into cutaneous melanoma: a population-based estimate. *Arch Dermatol* 2003;139:282–8.
19. Krengel S, Hauschild A, Schafer T. Melanoma risk in congenital melanocytic naevi: a systematic review. *Br J Dermatol* 2006;155:1–8.
20. Greely PW, Middleton AG, Curtin JW. Incidence of malignancy in giant pigmented nevi. *Plast Reconstr Surg* 1977;36:26–37.
21. Quaba AA, Wallace AF. The incidence of malignant melanoma (0 to 15 years of age) arising in 'large' congenital nevocellular nevi. *Plast Reconstr Surg* 1986;78:174–81.
22. Kinsler VA, O'Hare P, Bulstrode N, et al. Melanoma in congenital melanocytic naevi. *Br J Dermatol* 2017;176:1131–43.
23. Kinsler VA, Chong WK, Aylett SE, et al. Complications of congenital melanocytic naevi in children: analysis of 16 years' experience and clinical practice. *Br J Dermatol* 2008;159:907–14.
24. Ka VSK, Dusza SW, Halpern AC, et al. The association between large congenital melanocytic naevi and cutaneous melanoma: preliminary findings from an Internet-based registry of 379 patients. *Melanoma Res* 2005;15:61–7.
25. Siskind V, Darlington S, Green L, et al. Evolution of melanocytic nevi on the faces and necks of adolescents: a 4 y longitudinal study. *J Invest Dermatol* 2002;118:500–4.
26. Luther H, Altmeyer P, Garbe C, et al. Increase of melanocytic nevus counts in children during 5 years of follow-up and analysis of associated factors. *Arch Dermatol* 1996;132:1473–8.
27. Bataille V, Bishop J, Sasieni P, et al. Risk of cutaneous melanoma in relation to the numbers, types and sites of naevi: a case-control study. *Br J Cancer* 1996;73:1605–11.
28. Grulich AE, Bataille V, Swerdlow AJ, et al. Naevi and pigmentary characteristics as risk factors for melanoma in a high-risk population: a case-control study in New South Wales, Australia. *Int J Cancer* 1996;67(4):485–91.
29. De Giorgi V, Gori A, Greco A, et al. Sun-protection behavior, pubertal development and menarche: factors influencing the melanocytic nevi development: the results of an observational study of 1,512 children. *J Invest Dermatol* 2018;138:2144–51.
30. Baron AE, Asdigian NL, Gonzalez V, et al. Interactions between ultraviolet light and MC1R and OCA2 variants are determinants of childhood nevus and freckle phenotypes. *Cancer Epidemiol Biomarkers Prev* 2014;23:2829–39.
31. Dulon M, Weichenthal M, Blettner M, et al. Sun exposure and number of nevi in 5- to 6-year-old European children. *J Clin Epidemiol* 2002;55:1075–81.
32. Asdigian NL, Barón AE, Morelli JG, et al. Trajectories of nevus development from age 3 to 16 years in the Colorado kids sun care program cohort. *JAMA Dermatol* 2018;154:1272.
33. de Maleissye M-F, Beauchet A, Saiag P, et al. Sunscreen use and melanocytic nevi in children: a systematic review: sunscreen and nevi in children. *Pediatr Dermatol* 2013;30:51–9.
34. Cordoro KM, Gupta D, Frieden IJ, et al. Pediatric melanoma: results of a large cohort study and proposal for modified ABCD detection criteria for children. *J Am Acad Dermatol* 2013;68:913–25.
35. Downard CD, Rapkin LB, Gow KW. Melanoma in children and adolescents. *Surg Oncol* 2007;16(3):215–20.



36. Melnik M, Urdaneta L, Al-Jurf A, et al. Malignant melanoma in childhood and adolescence. *Am Surg* 1986;52:142-7.
37. Childhood melanoma treatment (PDQ®): health professional version. In: PDQ cancer information summaries. Bethesda, MD: National Cancer Institute (US); 2002.
38. Lin WM, Luo S, Muzikansky A, et al. Outcome of patients with de novo versus nevus-associated melanoma. *J Am Acad Dermatol* 2015;72:54-8.
39. Bevona C. Cutaneous melanomas associated with nevi. *Arch Dermatol* 2003;139:1620.
40. Masnari O, Neuhaus K, Aegerter T, et al. Predictors of Health-related Quality of Life and Psychological Adjustment in Children and Adolescents With Congenital Melanocytic Nevi: Analysis of Parent Reports. *J Pediatr Psychol*. 2019;44(6):714-725.
41. Brown MM, Chamlin SL, Smidt AC. Quality of life in pediatric dermatology. *Dermatol Clin* 2013;31:211-21.
42. Margileth AM. Spontaneous regression of large congenital melanocytic nevi, with a halo rim in 17 children with large scalp and trunk nevi during 45 years: a review of the literature. *Clin Pediatr (Phila)* 2019;58:313-9.
43. Loepke AW, Soriano SG. An assessment of the effects of general anesthetics on developing brain structure and neurocognitive function. *Anesth Analg* 2008;106:1681-707.
44. Ben-Ari A, Margalit D, Nachshoni L, et al. Traumatic stress among children after surgical intervention for congenital melanocytic nevi: a pilot study. *Dermatol Surg* 2019. <https://doi.org/10.1097/DSS.0000000000002276>.
45. Ruiz-Maldonado R, Tamayo L, Laterza AM, et al. Giant pigmented nevi: clinical, histopathologic, and therapeutic considerations. *J Pediatr* 1992;120:906-11.
46. Kinsler V, Bulstrode N. The role of surgery in the management of congenital melanocytic naevi in children: a perspective from Great Ormond Street Hospital. *J Plast Reconstr Aesthet Surg* 2009;62(5):595-601.
47. Bradford PT, Goldstein AM, McMaster ML, et al. Acral lentiginous melanoma: incidence and survival patterns in the United States, 1986-2005. *Arch Dermatol* 2009;145:8.
48. Ghanavati S, Costello CM, Buras MR, et al. Density and distribution of acral melanocytic nevi and acral melanomas on the plantar surface of the foot. *J Am Acad Dermatol* 2019;80:790-2.e2.
49. Rokuhara S, Saida T, Oguchi M, et al. Number of acquired melanocytic nevi in patients with melanoma and control subjects in Japan: nevus count is a significant risk factor for nonacral melanoma but not for acral melanoma. *J Am Acad Dermatol* 2004;50:695-700.
50. Kogushi-Nishi H, Kawasaki J, Kageshita T, et al. The prevalence of melanocytic nevi on the soles in the Japanese population. *J Am Acad Dermatol* 2009;60:767-71.
51. Curtin JA, Patel HN, Cho K-H, et al. Distinct sets of genetic alterations in melanoma. *N Engl J Med* 2005;353(20):2135-47.
52. Sakaizawa K, Ashida A, Uchiyama A, et al. Clinical characteristics associated with BRAF, NRAS and KIT mutations in Japanese melanoma patients. *J Dermatol Sci* 2015;80:33-7.
53. US Preventive Services Task Force, Bibbins-Domingo K, Grossman DC, et al. Screening for skin cancer: US preventive services task force recommendation statement. *JAMA* 2016;316:429.
54. Weinstock M, Risica P, Martin R, et al. Melanoma early detection with thorough skin self-examination: the "check it out" randomized trial. *Am J Prev Med* 2007;32:517-24.
55. Waldmann A, Nolte S, Geller AC, et al. Frequency of excisions and yields of malignant skin tumors in a population-based screening intervention of 360,288 whole-body examinations. *Arch Dermatol* 2012;148:903-10.
56. Bett BJ. Large or multiple congenital melanocytic nevi: occurrence of neurocutaneous melanocytosis in 1008 persons. *J Am Acad Dermatol* 2006;54:767-77.
57. Stegmaier OC. Natural regression of the melanocytic nevus. *J Invest Dermatol* 1959;32:413-21.
58. Unna PG. The histopathology of the diseases of the skin. Translated from the German, with the assistance of the author, by Norman Walker. New York: Macmillan Publishing Co; 1896.
59. Stegmaier OC, Montgomery H. Histopathologic studies of pigmented nevi in children. *J Invest Dermatol* 1953;20:51-64.
60. Dietrich AJ. Sun protection counseling for children: primary care practice patterns and effect of an intervention on clinicians. *Arch Fam Med* 2000;9:155-9.
61. Cokkinides V, Weinstock M, Glanz K, et al. Trends in sunburns, sun protection practices, and attitudes toward sun exposure protection and tanning among US adolescents, 1998-2004. *Pediatrics* 2006;118:853-64.
62. Balk SJ. Counseling parents and children on sun protection: a national survey of pediatricians. *Pediatrics* 2004;114:1056-64.
63. Balk SJ, Gottschlich EA, Holman DM, et al. Counseling on sun protection and indoor tanning. *Pediatrics* 2017;140:e20171680.
64. Guy GPJ, Holman DM, Watson M. The important role of schools in the prevention of skin cancer. *JAMA Dermatol* 2016;152:1083-4.
65. Paller AS, Hawk JLM, Honig P, et al. New insights about infant and toddler skin: implications for sun protection. *Pediatrics* 2011;128:92-102.
66. Cripps DJ, Hegedus S. Protection factor of sunscreens to monochromatic radiation. *Arch Dermatol* 1974;109:202-4.
67. American Academy of Dermatology Association. SUNSCREEN FAQs [WWW document]. Available at: [www.aad.org/media/stats-sunscreen](http://www.aad.org/media/stats-sunscreen). Accessed January 10, 2021.
68. Diaz A, Neale RE, Kimlin MG, et al. The children and sunscreen study: a crossover trial investigating children's sunscreen application thickness and the influence of age and dispenser type. *Arch Dermatol* 2012;148:606-12.