

Research Article

Double Needle Technique-A Novel Approach of Anaesthesia for Thoracolumbar Spine Fractures

Richa Chandra¹; Carmine Pullano²; Gaurav Misra^{3*};
Pallav Agrawal⁴; Alok Singh⁵

¹Rohilkhand Medical College, Bareilly, UP, India

²Consultant Anaesthesiologist, Casa di cura privata Villa, Pia Roma, Italy

³Associate Professor, Sri Ram Murti Smarak Institute of Medical Sciences, Bareilly, UP, India

⁴Consultant Neurosurgeon, GD Hospital, Bareilly, UP, India

⁵Consultant Orthopedician, GD Hospital, Bareilly, UP, India

*Corresponding author: Gaurav Misra

3Associate Professor; Sri Ram Murti Smarak Institute of Medical Sciences, Bareilly, UP, India.

Email: dr.gauravmisra@gmail.com

Received: July 28, 2023

Accepted: September 09, 2023

Published: September 16, 2023

Introduction

Spinal fractures are the major cause of morbidity and mortality in injuries associated with road traffic accidents, fall from height and sports misadventure.

These fractures are associated with neurological deficits, paraplegia, cardiopulmonary complications and psychological problems. Mostly these fractures occur at thoracolumbar junction, mid-thoracic or lower lumbar spine. Thoracolumbar junction being the commonest as this is the transition zone between the rigid thoracic cavity and mobile lumbar spine.

In 75% cases zone between T12 and L1 is involved followed by T10 and L2 due to free floating ribs causing increased mobility than upper thoracic segments, one third of these patients have associated hemothorax, pneumothorax, diaphragmatic rupture or bleeding from major vessel involvement [1,2].

Spinal decompression surgery along with pedicle screw fixation at multiple levels is the treatment of choice for fracture

Abstract

Background: spinal fractures are associated with significant morbidity and mortality. Spinal decompression along with pedicle screw fixation is the standard line of treatment. General anaesthesia is considered as gold standard for these procedures but regional anaesthesia has its own set of advantages. We introduced dual needle technique for spinal anaesthesia to overcome the effect of regression of block with added advantage of low volume of local anaesthetics providing stable hemodynamics.

Material and Methods: The present study was conducted at a tertiary care centre from April 2020 to November 2022 after approval from Ethical and Research committee. We enrolled 39 patients aged 20 to 70 years with ASA physical status I-III who were scheduled for pedicle screw fixation due to traumatic spine fractures ranging from T 8 to upper lumbar vertebrae. Under aseptic precautions after local infiltration with 2ml 2% xylocaine adrenaline solution at both sites, initial subarachnoid block was performed at T5-T6 Level with 27 G Quincke Babcock needle and second block at L3 -L4 level with similar needle.

Results: One or two episodes of hypotension was observed in five (12.8%) patients, whereas a single episode of bradycardia in two (5.0%) patients which responded well to medications. Parasthesia during needle insertion was observed in two (5%) patients. There were no post-operative complications like PDPH or position related injuries. **Conclusion:** This double needle technique is a feasible and practical technique which can be applied in patients with spinal fractures, with promise of hemodynamic stability and minimal position related injuries.

stabilization, neurological recovery and to minimize long term complications [3].

General anesthesia is the gold standard for these surgeries but it has its own set of complications like altered ventilatory requirements in already compromised cardiopulmonary status patients, prone position, ocular complications, possibility of brachial plexus injury etc. Conventional lumbar spinal anesthesia has also been successfully advocated as an alternative to general anesthesia.

Novel use of regional anesthesia was discovered and tested during the COVID-19 pandemic when the airway manipulation was more at risk for anesthesiologist to fear of virus spread. Mohammed Fawzy M. Khattab et al conducted awake spine surgery during the COVID era resulting in short hospitalization, increased patient satisfaction and optimally controlled pain thus making this technique superior to general anesthesia [4].

The concept of segmental spinal anesthesia involves the blockade of specific dermatomes essential for surgery with very low drug dosage of local anesthetic agents, this made it different from conventional lumbar spinal anesthesia.

The concept made the innovation of Dural puncture possible at higher levels above L2. There is always sensory regression associated with conventional spinal anesthesia so we devised a novel technique of subarachnoid blocks at two levels simultaneously to overcome the problem of sensory regression and low volume of local anesthetics for better hemodynamic stability. In this technique one needle was kept at lumbar level to cover lower thoracic and sacral levels and other needle at mid thoracic level to cover the lower cervical routes up to thoracic levels using small quantity of drugs thus avoiding major hemodynamic alterations, respiratory complications which are common in conventional lumbar technique due to large volume of drug.

Material and Methods

This study was conducted from April 2020 to November 2022 at a tertiary care center after approval by the ethical and research committee. We enrolled 39 patients aged 20 to 70 years with ASA physical status I-III, scheduled for pedicle screw fixation due to traumatic spine fractures ranging from T8 to upper lumbar vertebrae. Written informed consent was obtained from all the patients included in study. We excluded patients under ASA Class IV and V. Patients with contraindications for regional anesthesia e.g. local infection, coagulopathy, known allergy to drugs involved in study, abnormalities of spine like Kyphosis, scoliosis, fractures resulting from infective pathology of spine were also excluded from study.

Patients were counseled on their first visit regarding the need and plan of surgery, proposed anesthesia plan in detail, its merits and side effects. They were also reassured that any pain, discomfort or anxiety would be dealt appropriately, and if need arises general anesthesia will be given, while giving utmost care about their comfort.

All patients were preoperatively evaluated and investigated by clinical examination and laboratory parameter as required by their clinical condition. On arrival to pre-operative room 20G/18 G IV canula was secured in upper limb and an IV drip was started. Standard monitors e.g. ECG, NIBP, SpO₂ were attached before proceeding for the anaesthesia procedure. Positioning for the regional anaesthesia was assisted by both surgeon and anesthesiologist. Lateral position was made as a wood log rolling maneuver, avoiding any possibility of twisting, flexing or curling of spine [5].

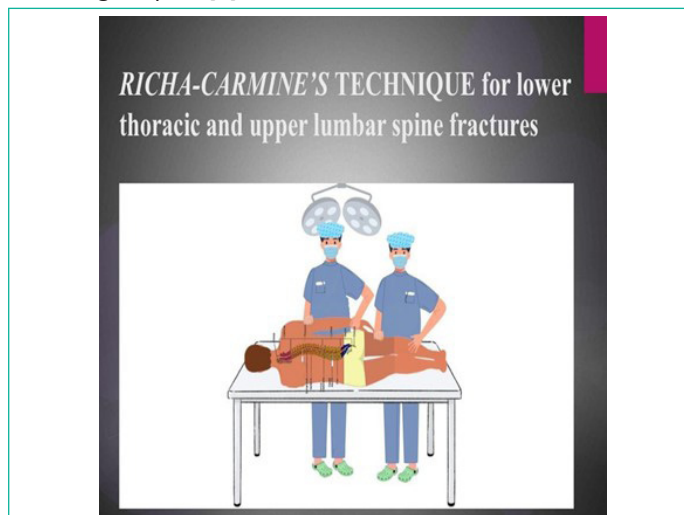


Table 1: Patients with comorbid conditions.

Comorbidity	Number of Patients (%)
Hypertension	9(23.0%)
Diabetes	11(28.2%)
COPD/ Asthma	8(20.5%)
Hemothorax-ICD insitu	6(15.3%)

Table 2: Intra operative adverse effects.

Adverse Effects	Number of Patients (%)
Hypotension	5(12.8%)
Bradycardia	2(5.0%)
Nausea	0(0%)
Vomiting	0(0%)
Respiratory discomfort	2(5%)
Paresthesia	2(5%)
Upper arms weakness	0(0%)

Positioning of patients during log rolling maneuver was assisted by surgeon and his team and required two to three persons depending on built of the patient. We used established landmarks to ascertain exact level for the block as follows - C7 spine, lower level of scapula at T7, 12th rib corresponding to L1 vertebrae. Under aseptic precautions after local infiltration with 2ml 2% xylocaine adrenaline solution at both sites, initial subarachnoid block was performed at T5-T6 Level with 27 G Quincke's Babcock needle and second block at L3-L4 level with similar needle (Richa-Carmine's technique).

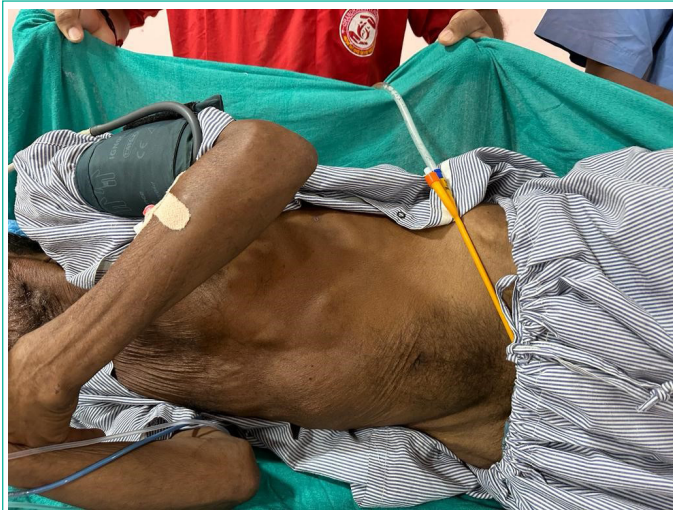We used midline approach in all the patients with a 45° tilt of the needle at thoracic level while insertion. During thoracic puncture after piercing Ligamentum Flavum, we proceeded slowly and carefully, after every 0.5mm advancement of needle CSF flow was checked. Once free flow of CSF was achieved 1.0 ml isobaric Levobupivacaine with 5mcg Dexmedetomidine at T5-T6 level was injected and 1.5 ml hyperbaric bupivacaine with 5 mcg Dexmedetomidine was injected at L3-L4 site. The patients were made supine immediately after the block and Oxygen supplementation was started with mask @4-6 LPM. Final prone position for surgery was accomplished after 5-6 minutes of the block.

Vital signs (HR, RR, SpO₂) were recorded every minute throughout the surgery. NIBP was recorded initially every 3 minutes for first 15 minutes and then every 5 minutes till the completion of surgery. Sensory level was assessed using the pin prick method. Extension of block was from lower cervical roots C5, C6 to sacral roots. Level was considered adequate for the surgery. ESSAM score was used to assess motor block in upper limb; hand grip (T1/ C8), wrist flexion (C8/C7), elbow flexion (C6/C5). Four grades (0-3) were assigned according to the number of absent movement [6]. Motor block in lower limbs were assessed by Bromage score; 0-free movement of legs and feet, 1-just able to flex knees with free movement of feet 2-unable to flex knees with free movement of feet 3-unable to move knees and feet [7].

Any episode of hypotension and bradycardia were noted and dealt appropriately. Hypotension was defined as systolic BP <90 mm Hg, and treated with single bolus doses of Injection Phenylephrine 0.1 mg IV. Bradycardia was defined as heart rate <50/minute and treated with Injection Atropine 0.6 mg IV. Sedation was provided with Injection Midazolam 1mg IV and Injection Fentanyl 1-1.5mcg/kg IV. All patients received IV fluids as per 4-2-1 rule. Intra operative nausea and vomiting was treated with injection Ondansetron 4mg IV. In the post anesthesia care unit hemodynamic parameters were continuously monitored

Table 3: Post-operative complications.

Complication	Number of Patients (%)
PDPH	0(0%)
Positioning related injury	0(0%)
Infection	0(0%)

**Figure 1:** Log Rolling Technique for patient.

and any adverse effects e.g. nausea, vomiting, urinary retention, nasal congestion were noted.

Results

We enrolled 39 patients in our study after their consent was obtained. Among them 21 patients were male (53.8%) and 18 patients (46.1%) were female. The comorbidities in patients were also taken into account. Majority of patients had hypertension or diabetes; few patients also had history of COPD and asthma. Few patients also had two concurrent existing comorbidities. There were also patients who had hemothorax preoperatively and a ICD was in situ.

Paresthesia during needle insertion was observed in two (5%) patients, therefore needle was repositioned and there was no reported neurological sequel in follow up period. All the patients were positioned in a similar fashion and any adverse effect was duly noted and dealt appropriately. One or two episodes of hypotension was observed in five (12.8%) patients, whereas a single episode of bradycardia in two (5.0%) patients which responded well to medications. Two patients (5%) also complained of mild respiratory discomfort but got relieved with reassurance. Other adverse effects like nausea, vomiting and upper arm weakness was not observed in any of the study participants. All the patients were observed during the post-operative recovery phase and there were no reported complications of PDPH, infection or positioning related injury during that phase.

Discussion

Although in the past subarachnoid block was considered superior to general anesthesia in terms of blood loss, position related problems, no airway manipulation and minimal systemic administration of drugs. In recent times the thoracic approach has emerged as a feasible and safe alternative with its own set of advantages.

Pedicle Screw Fixation Possible under Spinal Anesthesia:

Noah L Lessing et al compared conventional lumbar spinal anesthesia with general anesthesia in elderly patients undergoing elective lumbar spine fusion through posterior approach and found SAB superior to general anesthesia [8].

Rung et al used isobaric Bupivacaine 0.5% for lumbar discectomies to avoid any effect due to position change and minimal hemodynamic changes than hyperbaric drug [9].

Jellish et al compared general and spinal anesthesia for lumbar double level laminectomies and discectomies. He concluded spinal anesthesia to be superior in terms of less blood loss due to vasodilatation and spontaneous respiratory movements leading to reduced pulmonary complications. Patients who received spinal anesthesia stayed conscious and aided in making prone position leading to negligible chances of brachial plexus injury, eye injuries or pressure sore to the face [10]. He used hyperbaric Bupivacaine 11 mg in L4-L5 interspace to achieve a T6-T10 dermatomal level.

Goddard M et al described spontaneous respiration during spinal anesthesia causes lower intrathoracic pressure compared with general anesthesia utilizing positive pressure ventilation. Lower intrathoracic pressure leads to less engorgement of epidural veins leading to reduced blood loss and a clear surgical field making a surgeon's job easier [11].

Why Use Two Needles: The history of using two punctures for spinal anaesthesia dates back to 1934, when segmental anaesthesia was obtained using two needles, one by subarachnoid puncture lumbar and one by puncture in the cisterna magna [12]. All the aforementioned studies are done for the fixation of lumbar vertebrae by pedicle screws, but none of them included lower thoracic and upper lumbar fractures, which are the most common sites being affected by fractures. We conducted cases of these fractures with two needles simultaneously at two different sites over the spine, thus encompassing over large dermatomal area. Imbelloni et al divided intrathecal blocks in 3 zones 1st low zone-for lower limbs surgeries (limited above by the 1st nerve segment of lumbar regions), 2nd middle zone (limited above the 10th thoracic segment for lower abdomen surgeries), 3rd zone was a high zone limited above by the thoracic segment for upper abdomen and lower thoracic region.

In our study surgeries were conducted in the middle zone, so we attempted blocks at high and low zone to get effective dermatomal coverage on middle zone [13]. Regression of subarachnoid block is a theoretical and practical phenomenon which starts from the higher level and proceed to the lower as the time progresses, in a conventional lumbar spinal anaesthesia procedure. Here considering the problem of regression, a two level of subarachnoid blocks were performed simultaneously, upper puncture covered from dermatomal level T1 to T12, and lower puncture covered the lumbar and sacral regions.

As both punctures and drug instillation was done in a same time, so the chances of regression tend to occur equally from both sides. Fixation of thoracic and lumbar spine fractures is performed in prone position, so tolerance of bolsters in an awake patient is difficult, the above approach of block addressed that problem head on and all patients tolerated the surgery well. This method also has minimal side effects of prone positions like brachial plexus injury, eye injuries and others as the patients were awake and positioned their head and arms by themselves, comfortably as per the position suitable to them. These methods also have added advantages of spontaneous respiratory movements, reduced blood loss and negligible pulmonary complications as compared to general anesthesia.

Spinal Block at Thoracic Level

T .Jonnesco first time proposed the role of general spinal

block for head, neck and thorax by giving subarachnoid block at the level of T1 -T2 interspace to get analgesia for upper limbs, head and neck. He also used mid thoracic and lower thoracic blocks for thoracic and abdominal surgeries [14]. In 2005 Van Zundert et al conducted laproscopic cholecystectomy successfully in a patient with severe respiratory disease by giving subarachnoid block at thoracic level [15]. Magnetic resonance imaging studies by Imbelloni et al concluded that posterior dura-spinal cord distance is significantly greater in the mid thoracic region than at upper and lower thoracic levels (T6 9.5 ± 1.8 mm, T12 Levels 3.7 ± 1.2 mm, $p < 0.001$, T1 4.7 ± 1.7 mm, $p < 0.001$) [16]. Studies clearly depict greatest distance of 7.75 mm between meninges and duramater, at the level of 5th thoracic vertebrae. This distance becomes more steep by the use of needle in angulated fashion, making punctures more safe.

Ahmed Abdelaal et al performed a feasibility trial of thoracic segmental spinal anesthesia at T5 level in 25 patients posted for breast surgery. All the procedures were uneventful with minimal hemodynamic alterations, while conducting successful surgeries [17].

Paola Vincenzi et al conducted 4 cases for breast and axillary surgery under segmental spinal anesthesia at T6-T 8 level and found it as a safe alternative to general anesthesia [18].

We attempted spinal puncture at T5-T6 level, which was deemed controversial in past before, but multiple studies by different authors have established the safety of this procedure. Johannes J Le Roux et al defined the role of thoracic spinal anesthesia in 21st century and found total of fifteen original articles over thoracic or segmental spinal anesthesia. He included studies related to performance of subarachnoid block from T4-T5 to T10-T11 [19].

Radhashyam et al gave subarachnoid block at T10 level in 30 patients for upper and lower abdominal surgeries without any adverse neurological sequelae and minimal hemodynamic alterations [20].

Imbelloni et al emphasized the need of deposition of local anesthetics as close as to the site of innervation of surgery by comparing low dose thoracic segmental spinal anesthesia with large dose conventional lumbar anesthesia in laproscopic cholecystectomies and found minimal haemodynamic disturbances and early discharge of patients from hospital in thoracic spinal anesthesia group. Therefore, in segmental spinal anesthesia there is less need of local anesthetics as compared to conventional lumbar spinal anesthesia, where a large volume of drug is given to achieve a wider and distant field [21].

Which Type of Needle Should be Used

It was also emphasized in the literature that pencil point needle has at least 1mm of blind point beyond the orifice and thus more length of needle needs to be introduced into the dura to attain free flow of CSF, resulting in decreased safety margin compared to cut point needle. There are recommendations in literature to use cut point needle for thoracic punctures and we followed the same protocol [22].

Anticipated Problems

Primary anticipated complications like neurological injuries, ventilatory impairment due to high level of spinal blocks, major hemodynamic alterations due to thoracic level of blocks, chances of PDPH due to dura puncture at two different sites, probability of CNS infections due to dual punctures. In our study

group we did not encountered any of the above complications and majority of the procedures were uneventful.

Above mentioned publications clearly depicted the available space between dura mater and spinal cord is adequate at mid thoracic level for subarachnoid punctures without any risk of neurological damage.

Thoracic spinal nerves are having thin diameter and amount of CSF is less compared to lumbar area, so dose of local anesthetics required for effective block is very low. Although we achieved coverage of wide dermatomal block by using very small doses of local anesthetics at both places with of Isobaric Levobupivacaine, which helped us to achieve greater hemodynamic stability.

Imbelloni et al also suggested that anticipated problem of ventilatory impairment has very negligible incidence as diaphragm is the most important muscle for inspiration, which has innervation from cervical routes and expiration by itself is a passive process. To conclude thoracic block will only affect muscles of anterior abdominal wall which are] responsible for forced expiration and coughing [23,24].

We did not encountered any incidence of PDPH in our study group of patients as similar to other literature on thoracic spinal anaesthesia, nevertheless it can be due to prolonged bed ridden status of patients in post operative period. There was no evidence of any CNS infections in any of the patients, irrespective of reported incidence of iatrogenic dura laceration of 7.5% in literature, but all of the patients were prescribed antibiotics which cross blood brain barrier [25].

S. Parthasarthy et al used continuous spinal catheter with the use of 18 G Tuohy needle in 30 patients and found PDPH in 3% patients only, without any other complications. We preferred 27 G Quincke needles with very small caliber leading to negligible chances of infection and PDPH, as compared to Tuohy needle [26].

Limitations

The major limitation of this study is small study population and practical utility of this technique can be assessed if large subset of patient population can be examined for its advantages and drawbacks. This technique can be applied widely in patients with multiple co- morbidities and other injuries to assess its feasibility and safety.

Conclusion

This double needle technique is a feasible and practical technique which can be applied in patients with spinal fractures, with promise of hemodynamic stability and minimal position related injuries. It can be beneficial in patients who have co- existing thoracic injuries, co- morbidities and other conditions deeming them high risk for general anaesthesia and may prolong hospital stay and increased medical expenditure.

Author Statements

Disclosures

Human subjects: Consent was obtained or waived by all participants in this study. GD Hospital issued approval GDS/2020/016. Animal subjects: All authors have confirmed that this study did not involve animal subjects or tissue. Conflicts of interest: In compliance with the ICMJE uniform disclosure form, all authors declare the following: Payment/services

info: All authors have declared that no financial support was received from any organization for the submitted work. Financial relationships: All authors have declared that they have no financial relationships at present or within the previous three years with any organizations that might have an interest in the submitted work. Other relationships: All authors have declared that there are no other relationships or activities that could appear to have influenced the submitted work.

References

1. Knightly JJ, Sonntag VKH. Thoracolumbar fractures. In: menzes A, Sonntage V, editors. Principle,of spinal surgery. New York: McGraw-Hill. 1996; 919-49.
2. Wood KB, Li W, Lebl DR, Ploumis A. Management of thoracolumbar spine fractures. *Spine J.* 2014; 14: 145-64.
3. Hekmat Al Dahhan M. Traumatic dorsolumbar spine fractures and its management. *QMJ.* 7.
4. Khatatb MFM, Sykes DAW, Abd-El-Barr MM, Waguia R, Montaser A, Ghamry SE, et al. Spine surgery under awake spinal anesthesia: an Egyptian experience during the COVID-19 pandemic. *Neurosurg Focus.* 2021; 51: E6.
5. PULLEN RL. Logrolling a patient. *Nursing.* Feb 2004; 34: 22.
6. Abd Elrazek E, Scott NB, Vohra A. An epidural scoring scale for arm movements (ESSAM) in patients receiving high thoracic epidural analgesia for coronary artery bypass grafting. *Anaesthesia.* 1999; 54: 1104-9.
7. Craig D, Carli F. Bromage motor blockade score - a score that has lasted more than a lifetime. *Can J Anaesth.* 2018; 65: 837-8.
8. Lessing NL, Edwards CC 2nd, Dean CL, Waxter OH, Lin C, Curto RA et al. 4th. Spinal anesthesia for geriatric lumbar spine surgery: A comparative case series. *Int J Spine Surg.* 2020; 14: 713-21.
9. Rung GW, Williams DDO, Gelb DE, Grubb MMD. Isobaric spinal anesthesia for lumbar disk surgery. *Anesth Analg.* May 1997; 84: 1165-6.
10. Jellish WS, Thalji Z, Stevenson K, Shea J. A prospective randomized study comparing short- and intermediate-term perioperative outcome variables after spinal or general anesthesia for lumbar disk and laminectomy surgery. *Anesth Analg.* 1996; 83: 559-64.
11. Goddard M, Smith PD, Howard AC. Spinal anaesthesia for spinal surgery. *Anaesthesia.* 2006; 61: 723-4.
12. Fay T, Gotten N. Controlled spinal anesthesia: its value in establishing appropriate levels for chordotomy. *Arch NeurPsych.* 1933; 30: 1276-81.
13. Imbelloni LE. Segmental spinal anesthesia: A systematic review. *J Anesth Clin Res.* 2020; 11: 953.
14. Jonnesco T. Remarks ON GENERAL SPINAL analgesia. *Br Med J.* 1909; 2: 1396-401.
15. van Zundert AA, Stultiens G, Jakimowicz JJ, van den Borne BE, van der Ham WG, Wildsmith JA. Segmental spinal anaesthesia for cholecystectomy in a patient with severe lung disease. *Br J Anaesth.* 2006; 96: 464-6.
16. Lee RA, van Zundert AA, Breedveld P, Wondergem JH, Peek D, Wieringa PA. The anatomy of the thoracic spinal canal investigated with magnetic resonance imaging (MRI). *Acta Anaesthesiol Belg.* 2007; 58: 163-7.
17. The novel use of spinal anesthesia at mid thoracic level: a feasibility study, Ahmed Adbdelaal, Ahmed Mahmoud, Hazem Abdelwahab Hussein, Karim Girgis, Ahmed Mustafa Kamal. *Egyptian Cardiothoracic Anesthesia Society.* 2014; 1687-9090.
18. Opioid free segmental thoracic spinal anesthesia with intrathecal sedation for breast and axillary surgery: Report of four cases, Paola Vincenzi, Massimo Stronati, Salvatora Luorio, Diletta Gudenzi, Gianfranco Boccoli, Roberto Starnari, Local and regional anesthesia. 2022: 15: 23-29.
19. le Roux JJ, Wakabayashi K, Jooma Z. Defining the role of thoracic spinal anaesthesia in the 21st century: a narrative review. *Br J Anaesth.* 2023; 130: e56-65.
20. Spinal at T, Paria R, Surroy S, Majumdar M, Paria B, Sengupta S, Das G et al. *IOSR JDMS.* 2014; 13: 28-32.
21. Imbelloni LE, Sakmoto JW, Viana EP, de Araujo AA. Segmental spinal anesthesia: A systematic review. *J Anesth Clin Res.* 2020.
22. Eduardo Imbelloni LE. What is the best needle for spinal thoracic anesthesia: pencil point needle or cut point needle? Letter to editor. *Acta Scie Medic.* 2020; 4: 33-4.
23. Driscoll P. Gray's Anatomy, 39th Edition. *Emergency Medicine Journal.* 39th ed. 2006; 23: 492. doi: 10.1136/emj.2005.027847.
24. Ahmed A. Thoracic spinal anesthesia to do or not to do. 2018.
25. Bande PP, Garnaik S, Kulkarni RV, Wajekar S, Kothmire T. Incidental dural tear in lumbar spine surgery: A prospective study. *Int J Ortho Res.* 2021; 4: 81-4.
26. Parthasarathy S, Ravishankar M. Continuous spinal anesthesia with epidural catheters: an experience in the periphery. *Anesth Essays Res.* 2011; 5: 187-9.