



DEPARTMENT OF PATHOLOGY

Case of the Week

Cytopathology: *Mycobacterium avium* complex infection with non-necrotizing granulomatous inflammation involving a lymph node

Prepared by: Andrea Hernandez, DO (resident), Dianne Grunes, MD (fellow), Barbara Bengston, CT, and Melissa Yee-Chang, DO (attending)

February 16, 2016

History

The patient is a 35 year old HIV-positive male who presents to the emergency department with altered mental status. He complained of low grade fever, productive cough and subjective weight loss. Oral candidiasis and painful cervical lymphadenopathy were noted on physical exam. His CD4 count was 40 cells/ μ L, indicating progression to AIDS. Chest X-ray demonstrated consolidation in the lower lobe of the left lung. An ultrasound guided aspiration biopsy of the cervical lymph node is performed.

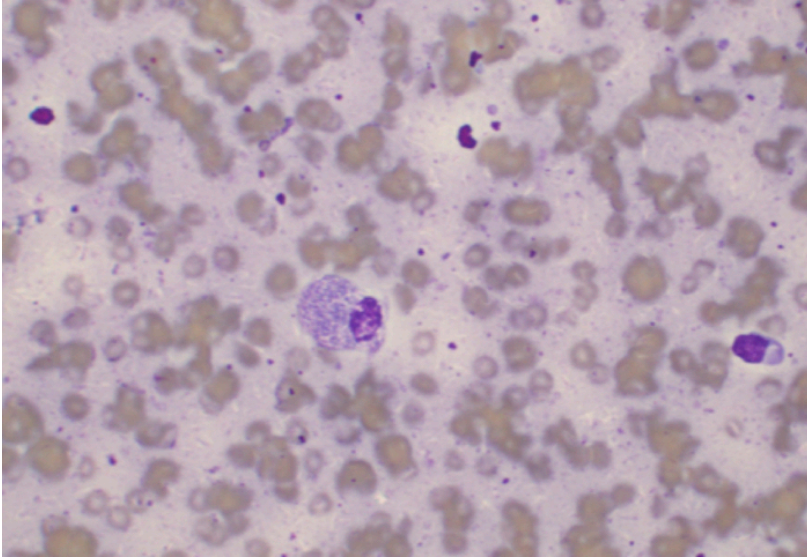


Figure. 1: (Diff-Quik stain, 400x magnification)

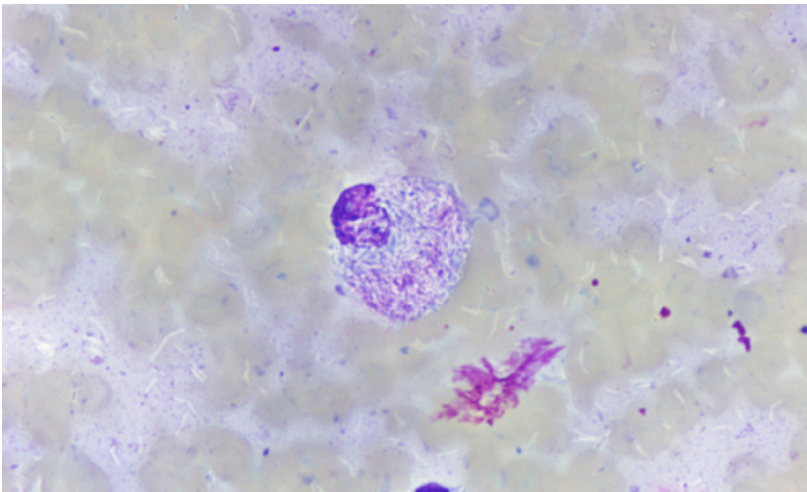


Figure. 2: (Diff-Quik stain, 1000x magnification)

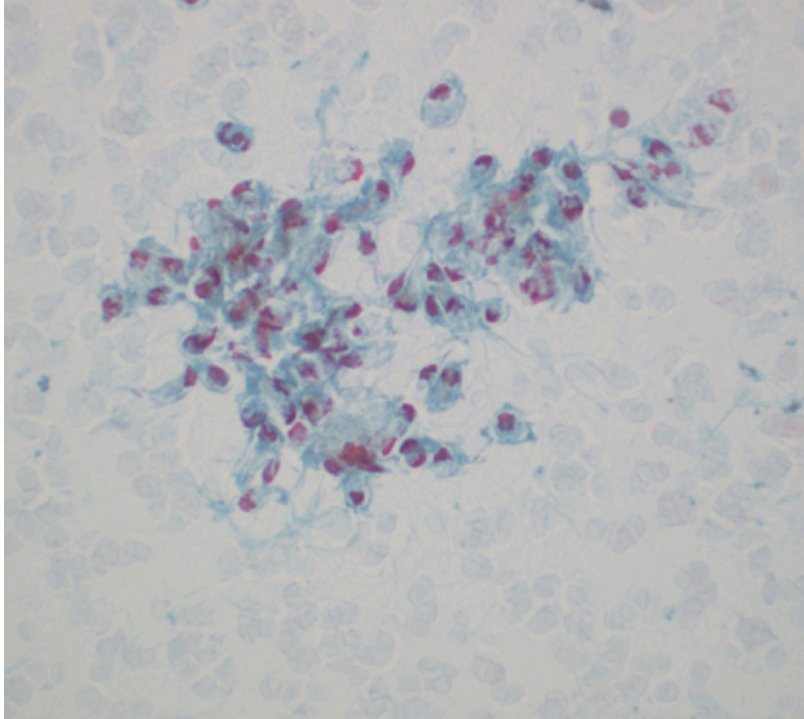


Figure 3: (PAP stain, 40x magnification)

Figure 1 - 3

Figure 1: Fine needle aspirate from the lymph node showing a histiocyte containing numerous outlines of intracellular bacilli within the cytoplasm.

Figure 2: A histiocyte with abundant intracellular unstained bacilli which appear as slightly curved, colorless rods, displaying the “negative image” of the mycobacteria. Due to the striated appearance of the cellular cytoplasm, these histiocytes may be referred to as “pseudo-Gaucher cells”. Extracellular, negative-image mycobacteria are also seen within the background.

Figure 3: Loose aggregate of epithelioid histiocytes forming a vague non-necrotizing granuloma, however, the mycobacteria are not readily identified as on the Diff Quik- stained smear.

Diagnosis

Mycobacterium avium complex infection with non-necrotizing granulomatous inflammation involving a lymph node

Discussion

Mycobacterium avium complex (MAC) infections are caused by one of two mycobacterial species: *M. avium* or *M. intracellulare*. These atypical mycobacteria have emerged as major

pathogens in disseminated non-tuberculous infection and are a common cause of opportunistic infections in immunocompromised individuals, particularly the HIV population. Among HIV-infected individuals, the risk of MAC increases as the CD4 cell number declines <50 cells/ μ L¹.

Atypical mycobacteria are ubiquitous in the environment, frequently isolated from soil and fresh and salt water². Human disease is believed to be acquired from inhalation or ingestion of the organisms allowing entry via the respiratory and gastrointestinal tract further disseminating through the lymphatics. In contrast to tuberculous mycobacterial infection, person-to-person or common source transmission of MAC does not appear to be common.

The most common presenting symptoms of disseminated MAC are non-specific and include: fever, night sweats, abdominal pain, diarrhea, dyspnea, and weight loss. Localized disease is seen almost exclusively in immunocompetent adults and children. The symptoms of localized disease include: fever, leukocytosis and focal lymphadenitis³.

These organisms are acid-fast, rod-shaped bacilli, like other mycobacterium, however their culture characteristics differ and many are resistant to common medications used to treat tuberculosis. The diagnosis of MAC is made by isolation of the organism in culture, usually from blood or lymph node.

Fine-needle aspiration biopsy (FNAB) is a minimally invasive procedure that can be utilized in the diagnosis of mycobacterial infection. The aspirate smear slides show histiocytes containing abundant intracellular bacilli within the cytoplasm. The Diff-Quik stain outlines the morphology of abundant bacilli which appear as slightly curved, colorless rods, forming “negative images” of the mycobacteria^{4,5}. This “negative image” occurs as a result of hydrophobic interactions of the water-based stain with the lipid within the bacterial cell wall^{4,5}. The diagnosis was confirmed with positive AFB stain performed on the cell block and mycobacterial speciation was confirmed by DNA hybridization performed on a sputum sample. Although not pathognomonic, these cytologic features when reviewed in conjunction with the clinical history and radiologic findings should raise the diagnostic consideration of mycobacterium avium complex infection.

References

1. Horsburgh CR Jr, Schoenfelder JR, Gordin FM, et al. Geographic and seasonal variation in Mycobacterium avium bacteremia among North American patients with AIDS. *Am J Med Sci* 1997; 313:341.
2. Reed C, von Reyn CF, Chamblee S, et al. Environmental risk factors for infection with Mycobacterium avium complex. *Am J Epidemiol* 2006; 164:32.
3. Panel on Opportunistic Infections in HIV-Infected Adults and Adolescents. Guidelines for the prevention and treatment of opportunistic infections in HIV-infected adults and adolescents: Recommendations from the Centers for Disease Control and Prevention, the National Institutes of Health, and the HIV Medicine Association of the Infectious Diseases Society of America. https://aidsinfo.nih.gov/contentfiles/lvguidelines/Adult_OI.pdf (Accessed on February 15, 2016).

4. Sidawy, MK, Ali, SZ. Fine Needle Aspiration Cytology: A Volume in Foundations in Diagnostic Pathology. Churchill Livingstone; 1st edition (February 7, 2007); 163-165.

5. Ioachim, HL, Medeiros, LJ. Ioachim's Lymph Node Pathology. Lippincott Williams & Wilkins; 4th edition (September 1, 2008); 137-142.