

***ANATOMY OF FEMALE
PELVIS AND FETAL SKULL***

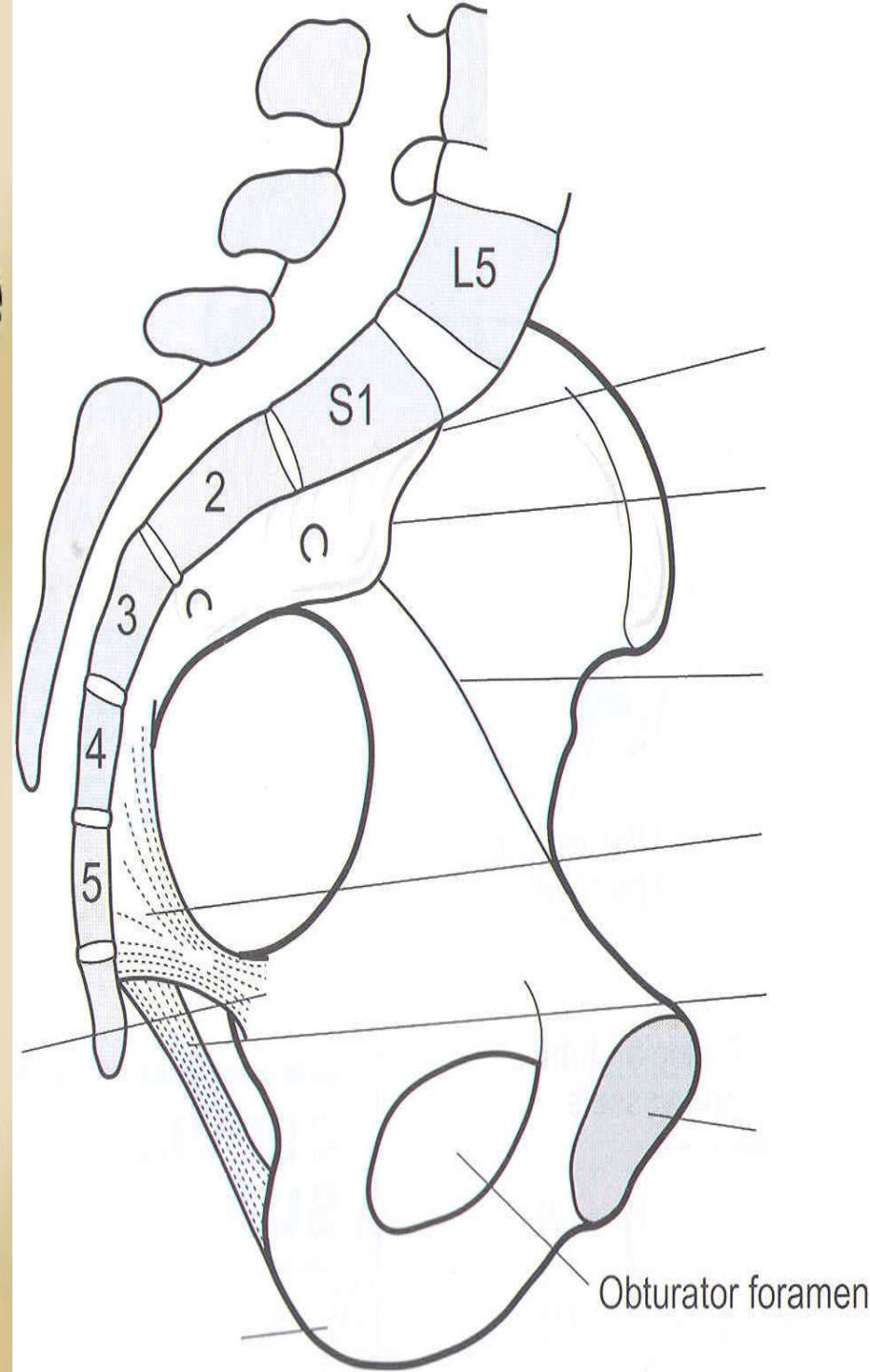
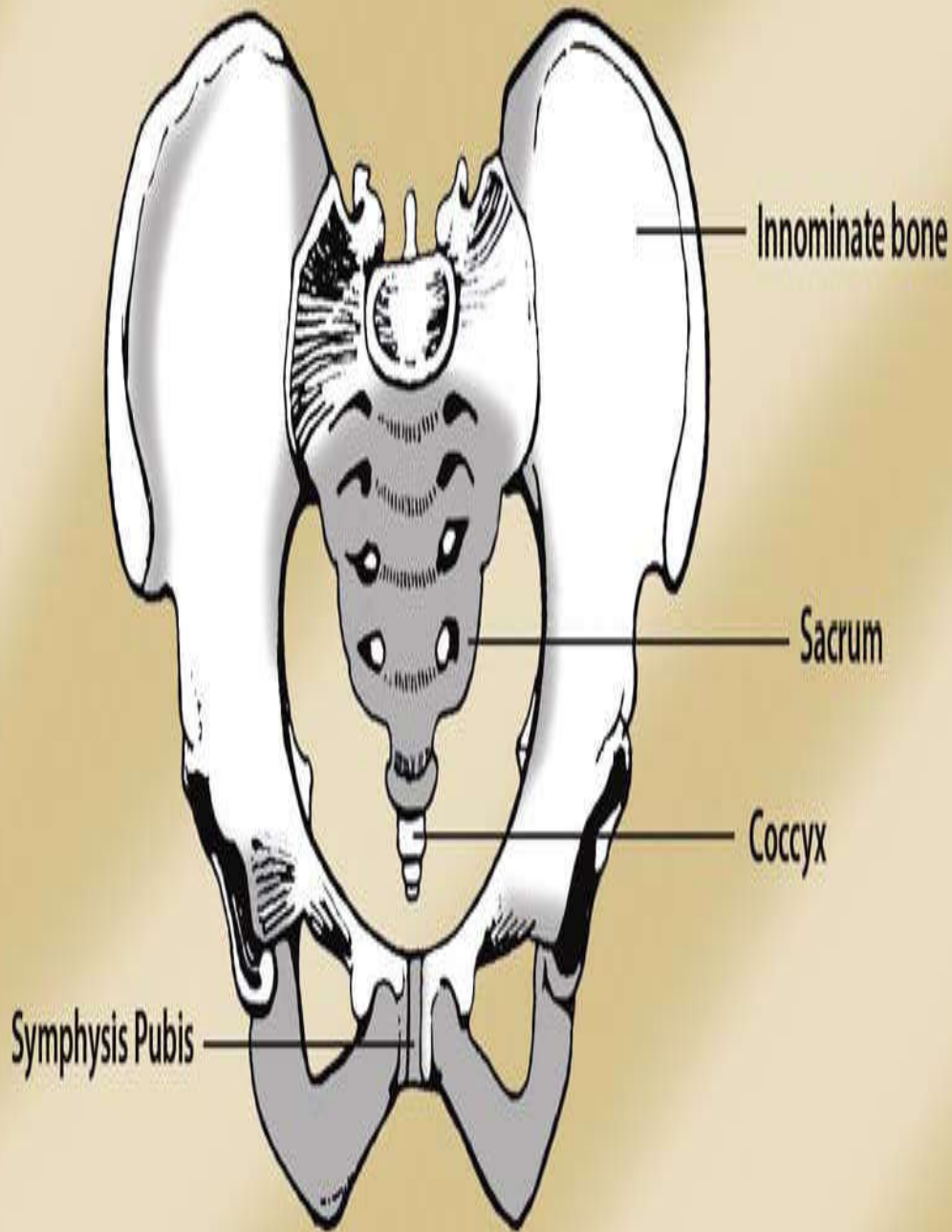
By

Prof. YASSER A.

HELMY

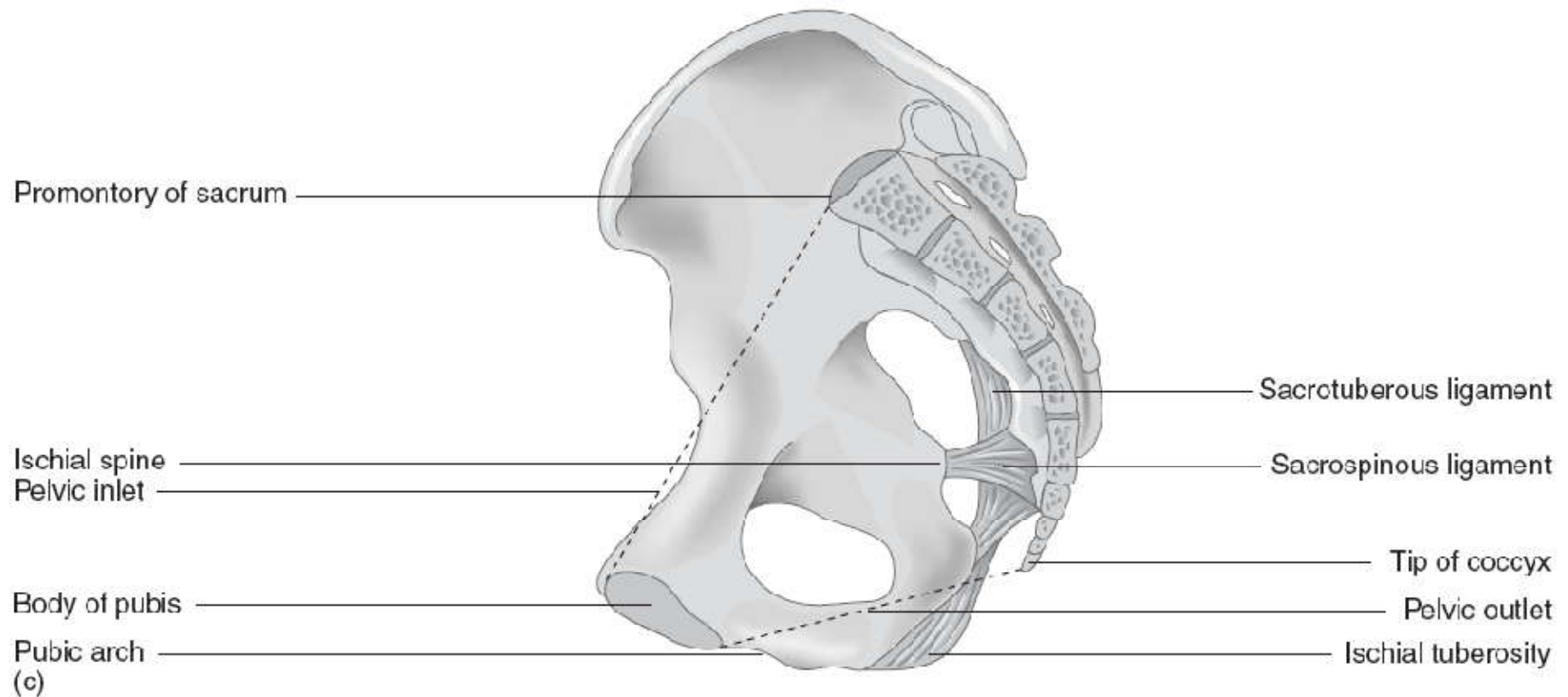
Prof. of Obst & Gynecol.

The 'true pelvis' refers to the bony canal that the fetus needs to pass through during the normal mechanism of childbirth. It comprises a brim, cavity and an outlet.



THE PELVIC PLANES:

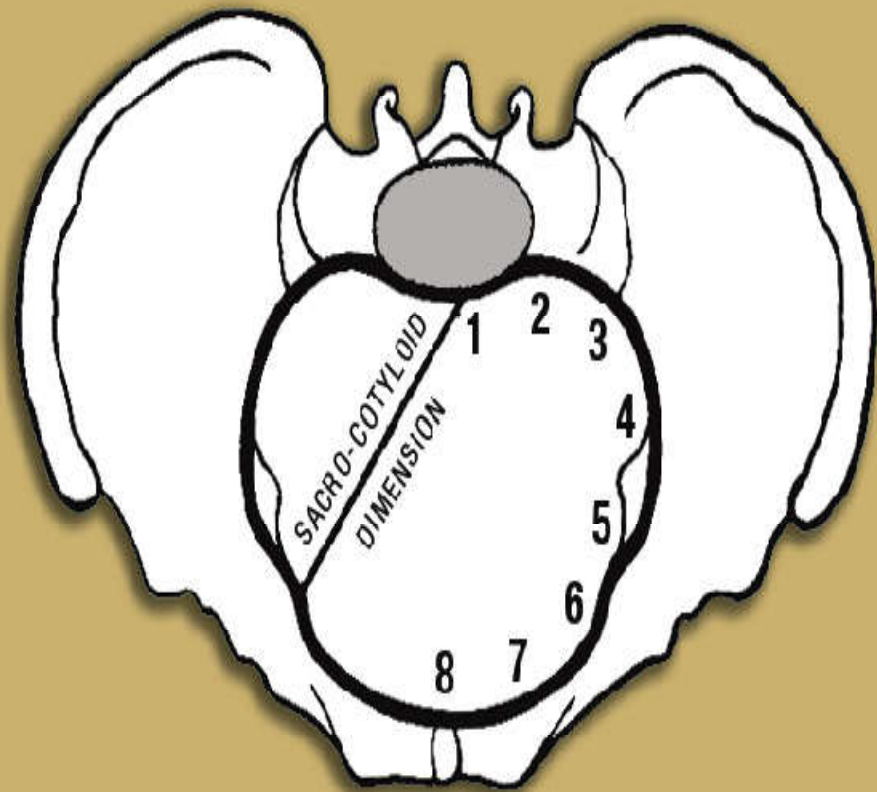
The pelvic planes refer to hypothetical flat surfaces on the pelvis, which are located at the *brim, cavity and pelvic outlet*. Taking the pelvic brim as our landmark, the plane of the brim is an angle of 55° to the horizontal, while the plane at the outlet is 15° . This is due to the difference in the length of the walls of the pelvis anteriorly and posteriorly.



The pelvic brim (inlet):

The pelvic brim separates the 'false' pelvis above, from the 'true' pelvis below. The brim is rounded in shape. Its boundaries are:

- Sacral promontory (1)
- Sacral ala (2)
- Sacroiliac joint (3)
- Iliopectineal line (4)
- Iliopectineal eminence (5)
- Superior ramus of the pubic bone (6)
- Upper inner border of the body of the pubic bone (7)
- Upper inner border of the symphysis pubis (8)

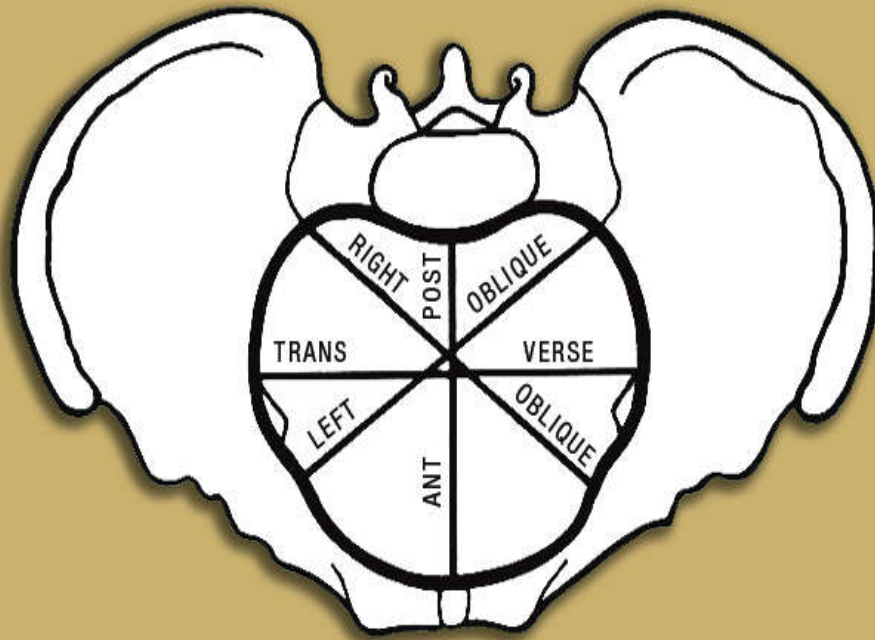


Pelvic landmarks

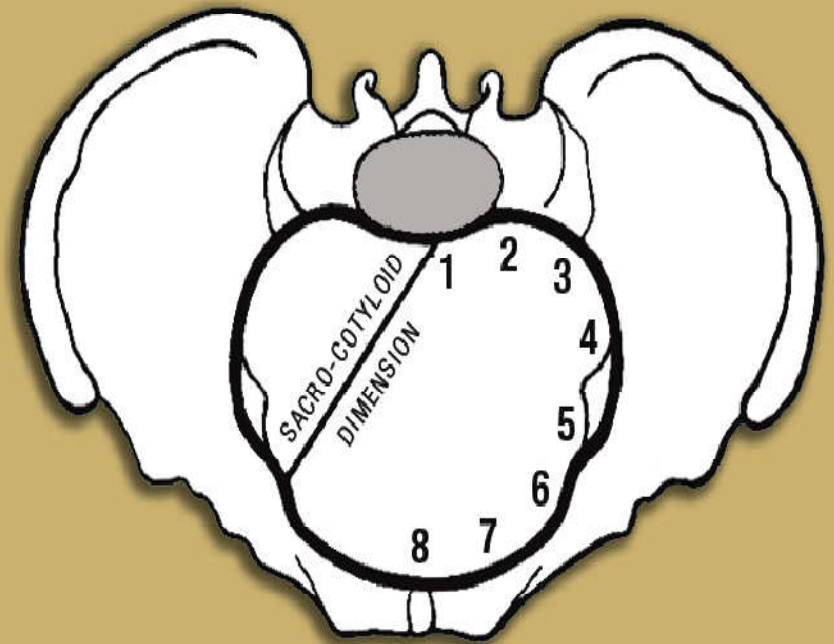
THE PELVIC BRIM (INLET):

There are 4 diameters at the pelvic brim

- Anterior-posterior diameter
- Oblique diameter (left and right) 12 cm
- Transverse diameter 13 cm
- Sacro-cotyloid 9-9.5 cm



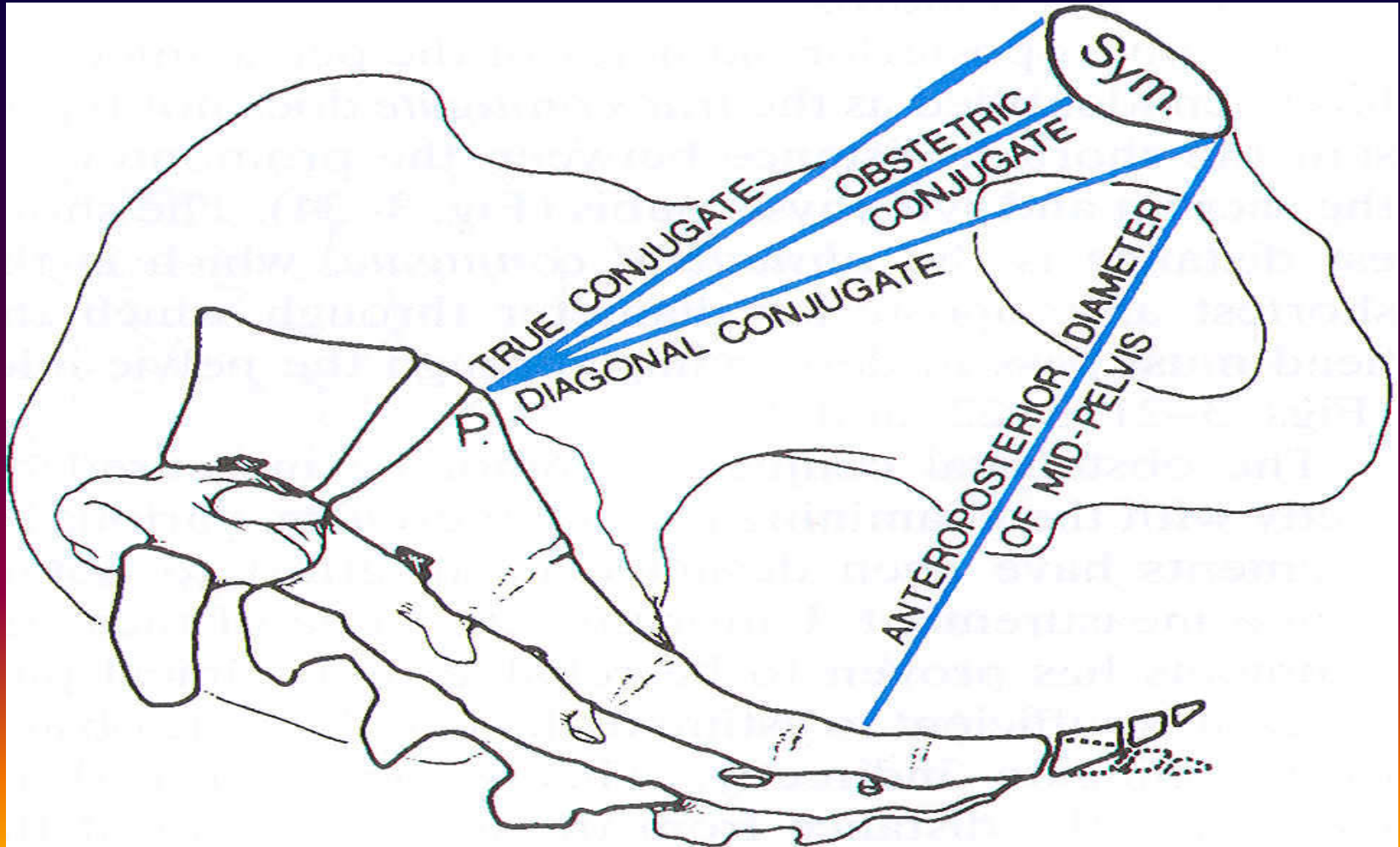
Diameters of the pelvic brim



Pelvic landmarks

THE PELVIC BRIM (INLET):

- Anterior-posterior diameter
- The anatomical (true) conjugate 11 cm
- The obstetric conjugate 10.5 cm
- The diagonal conjugate 12.5 cm



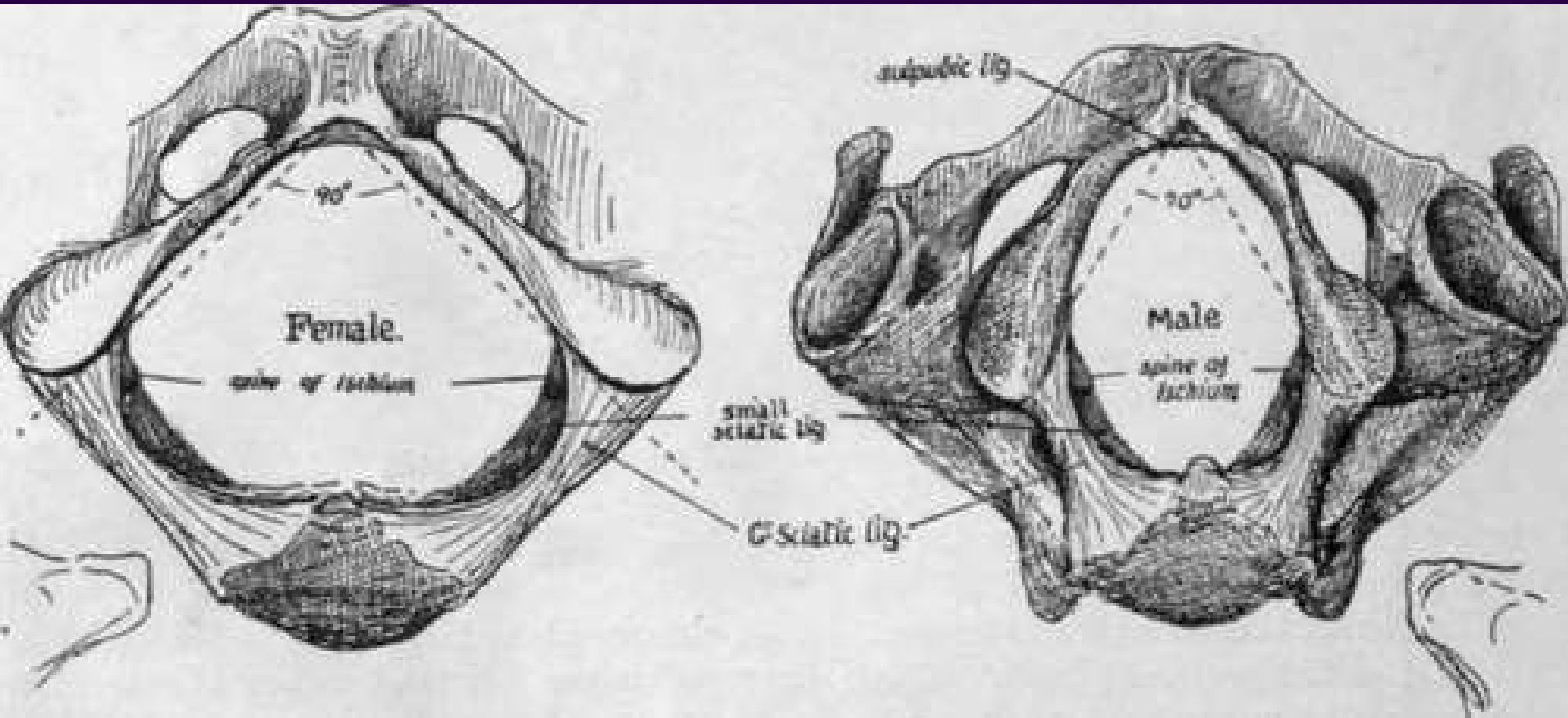
THE PELVIC CAVITY:

This extends from the pelvic brim above to the pelvic outlet below. The plane of mid cavity lies at the level of a line between the middle of the posterior surface of the symphysis pubis and the junction between the 2nd and 3rd sacral vertebrae. It is rounded in shape with its all diameters = 12.5 cm. internal rotation occurs when the biparietal diameter of the fetal head in this plane.

THE PELVIC OUTLET:

It is diamond-shaped; its boundaries are partially comprised of ligaments. The landmarks of the pelvic outlet are:

- Lower border of the symphysis pubis
- Pubic arch
- Ischial spines and ischial tuberosities
- Sacrotuberous and sacrospinous ligaments
- Lower aspect of the sacrum and the coccyx



THE PELVIC OUTLET:

It has the following diameters:

--*Anatomical anteroposterior*: between the lower border of the symphysis pubis and the tip of the coccyx 11 cm

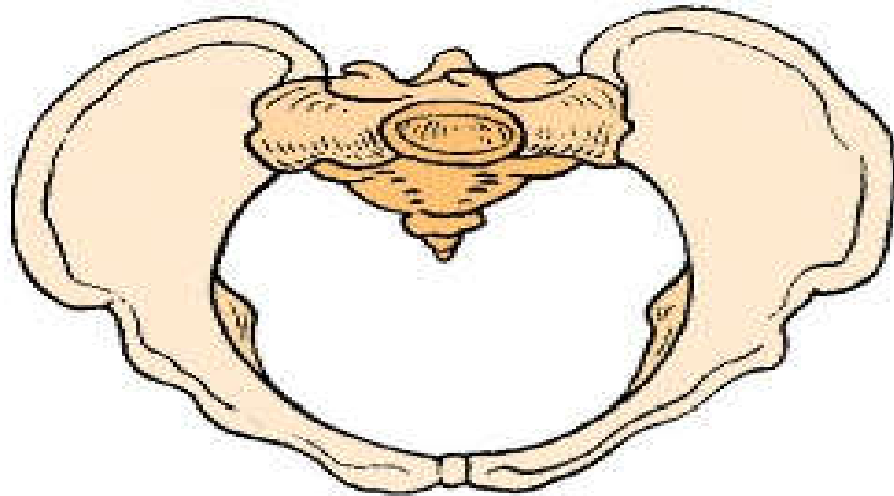
--*Obstetric anteroposterior*: between the lower border of the symphysis pubis and the tip of the sacrum 13 cm

--*Bituberous diameter*: between the inner aspects of the ischeal tuberosities 11 cm

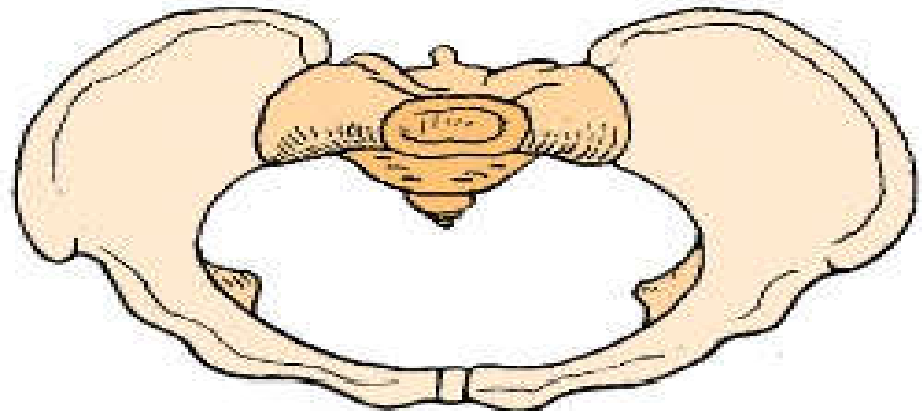
--*Bispinous diameter*: between the tips of ischeal spines 10.5 cm

TYPES OF FEMALE PELVIS:

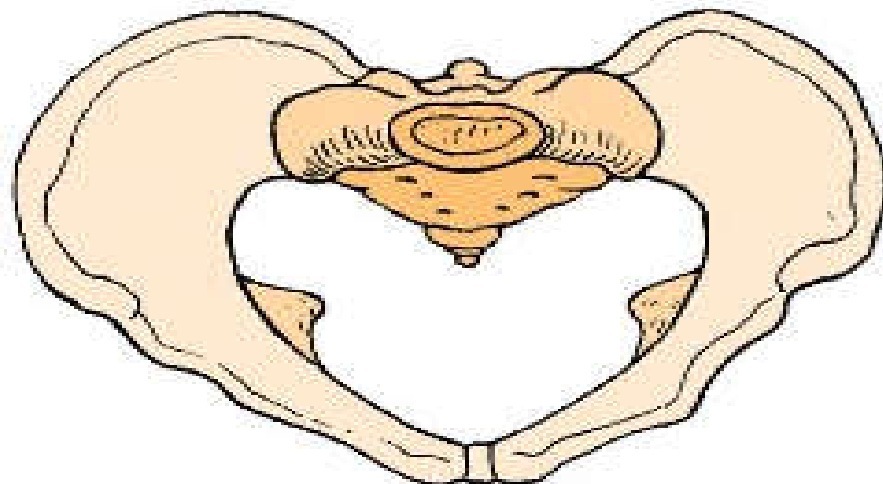
There are 4 basic types of female pelvises and these are classified according to the shape of the brim or inlet.



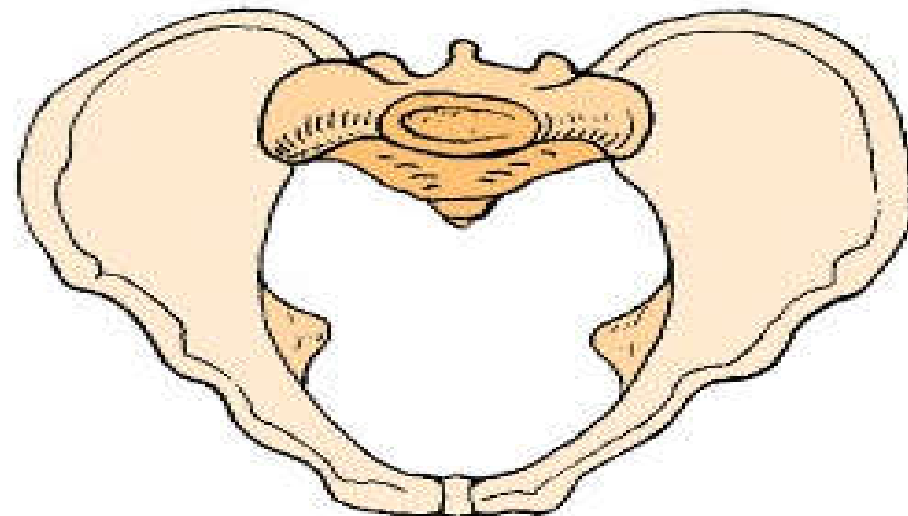
Gynecoid



Platypelloid

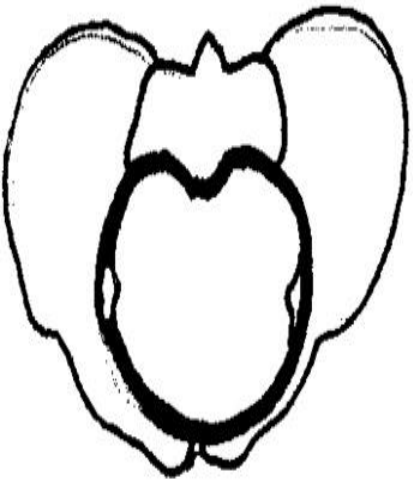


Android

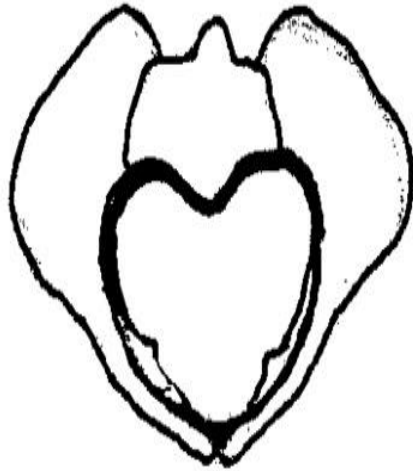


Anthropoid

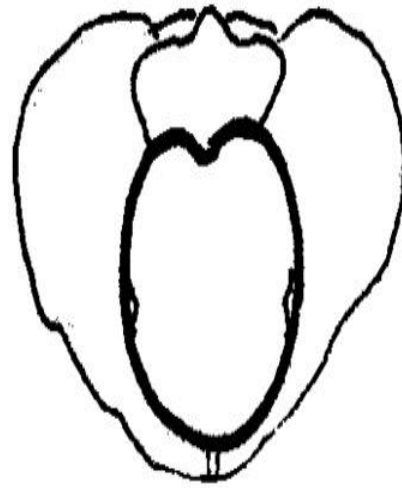
Four Pelvic Types



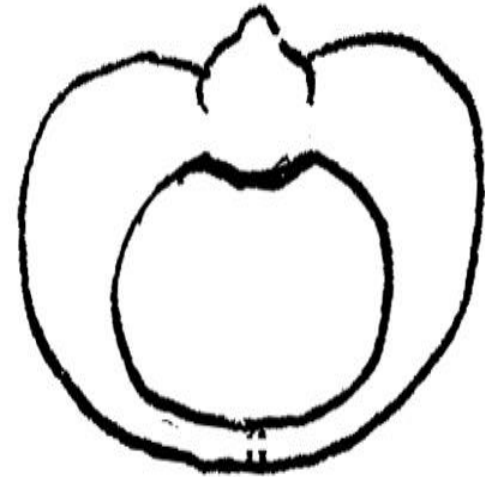
Gynecoid




Android



Anthropoid



Platypelloid



TYPES OF FEMALE PELVIS:

The Gynecoid pelvis (50%)

It has an almost round brim and will permit the passage of an average-sized baby with the least amount of trauma to the mother and baby in normal circumstances. The pelvic cavity (the inside of the pelvis) is usually shallow, with straight side walls and with the ischial spines not so prominent as to cause a problem as the baby moves through.

The Anthropoid pelvis (25%)

It has an oval brim and a slightly narrow pelvic cavity. The outlet is large, although some of the other diameters may be reduced. If the baby engages in the pelvis in an anterior position, labor would be expected to be straightforward in most cases.

TYPES OF FEMALE PELVIS:

The Android pelvis (20%)

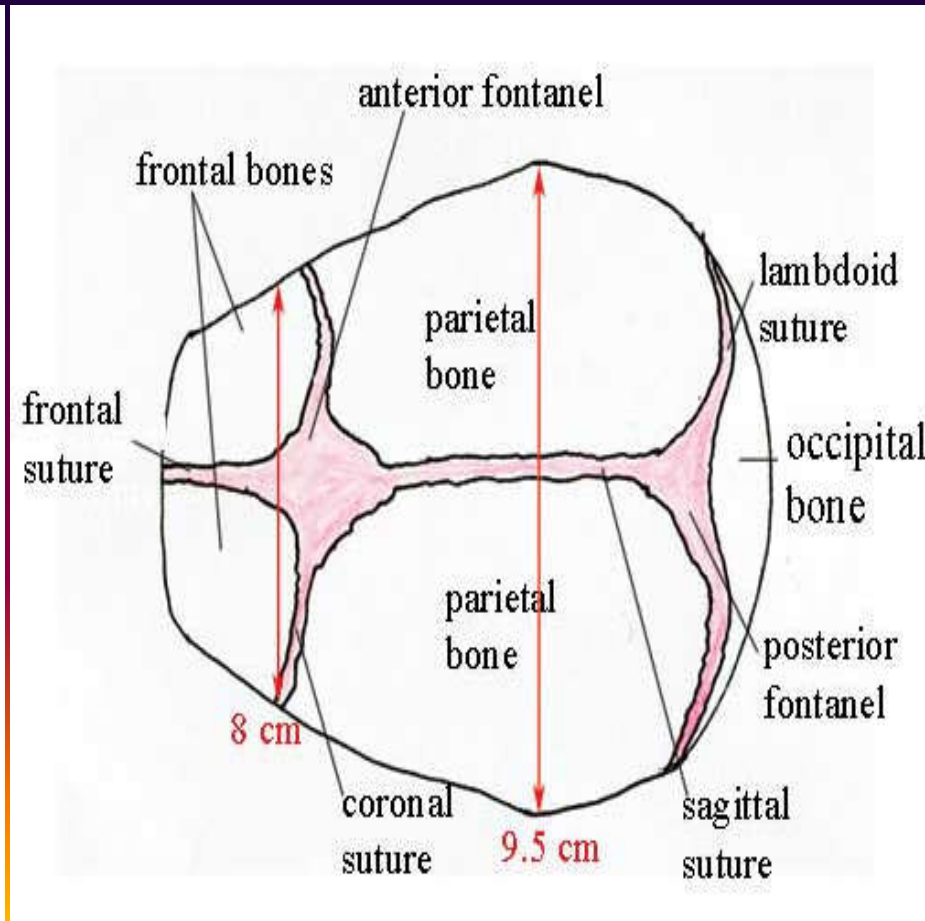
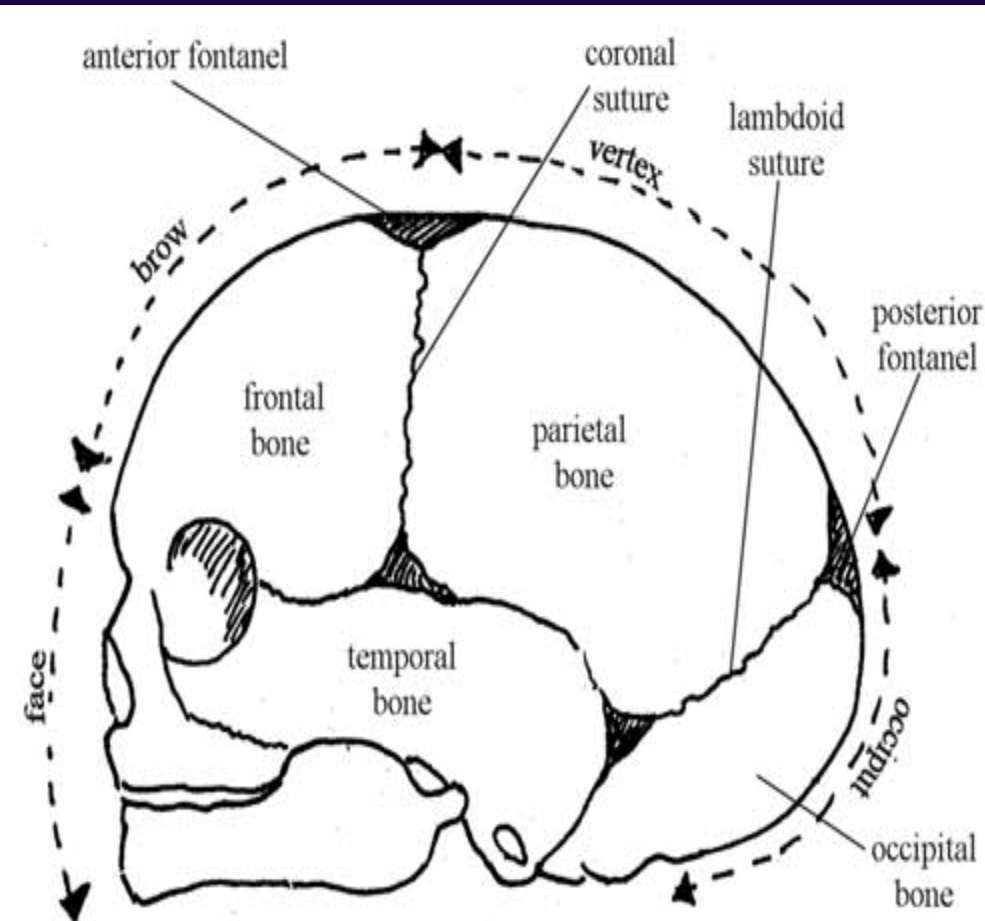
It has a heart-shaped brim and is quite narrow in front. This type of pelvis is likely to occur in tall women with narrow hips and is also found in African women. The pelvic cavity and outlet is often narrow, straight and long. The ischial spines are prominent.

The Platypelloid pelvis (5%)

It has a kidney-shaped brim and the pelvic cavity is usually shallow and may be narrow in the antero-posterior (front to back) diameter. The outlet is usually roomy. During labor the baby may have difficulty entering the pelvis, but once in, there should be no further difficulty.

THE FETAL SKULL:

The fetal skull is the most difficult part of the baby to pass through the mother's pelvis, because of the hard bony nature of the skull. Understanding the anatomy of the fetal skull and its diameter will help to recognize how a labor is progressing, and whether a normal vaginal delivery is likely or not.



THE FETAL SKULL DIAMETERS:

➔ Suboccipito bregmatic 9.5 cm

from middle of the bregma to undersurface of the occipital bone, it is the engagement diameter of the well flexed head in occipito anterior position

➔ Suboccipito frontal 10 cm

from anterior end of the bregma to undersurface of the occipital bone, it is the engagement diameter of the incompletely flexed head in occipito anterior position

➔ Occipitofrontal 11.5 cm

from the root of the nose to the occipital protuberance, it is the engagement diameter of the deflexed head in the occipito posterior position

THE FETAL SKULL DIAMETERS:

➔ Mentoverical 13.5 cm

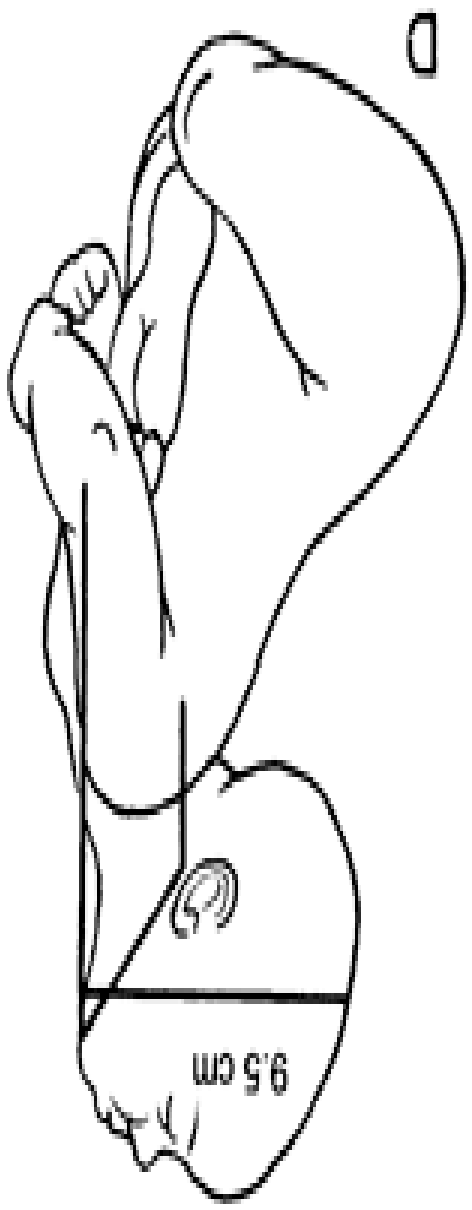
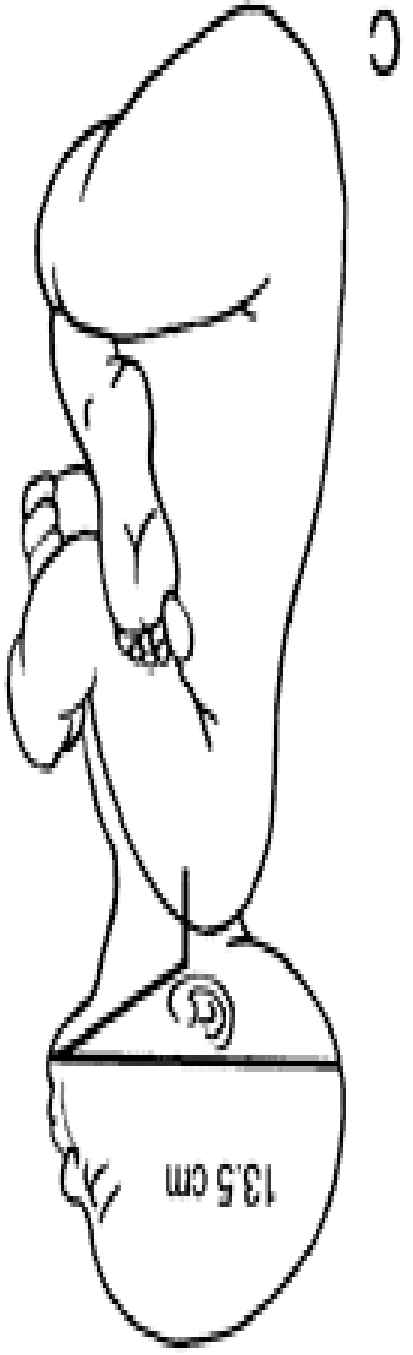
from the tip of the chin to the vertical point, it is the engagement diameter in brow presentation, it is more than the largest diameter in the pelvic brim so the head can not enter the pelvis in brow presentation

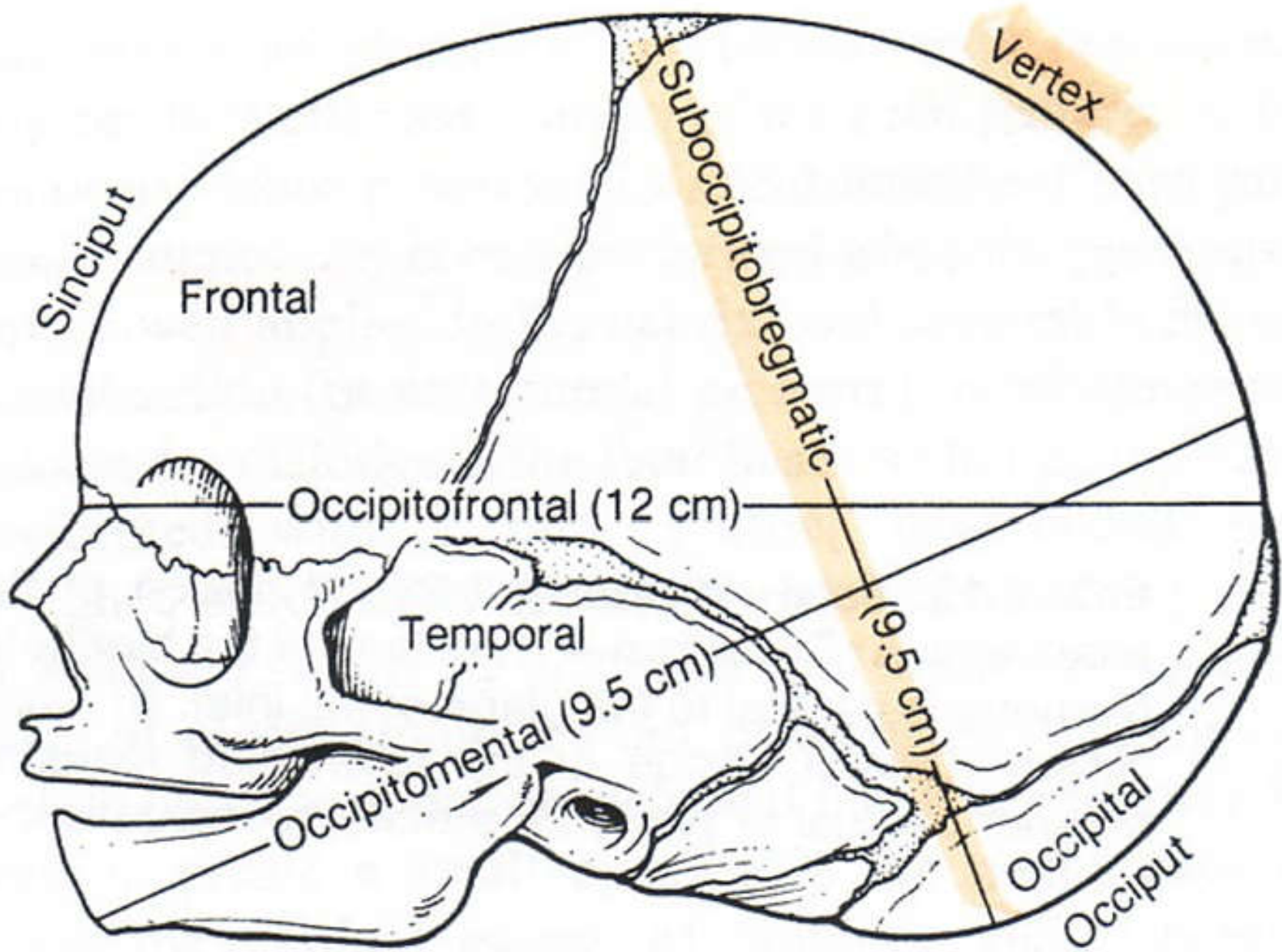
➔ Submentobregmatic 9.5 cm

from the junction of the chin and neck to middle of bregma. It is the engagement diameter in face presentation when the head is completely extended

➔ Biparietal diameter 9.5 cm

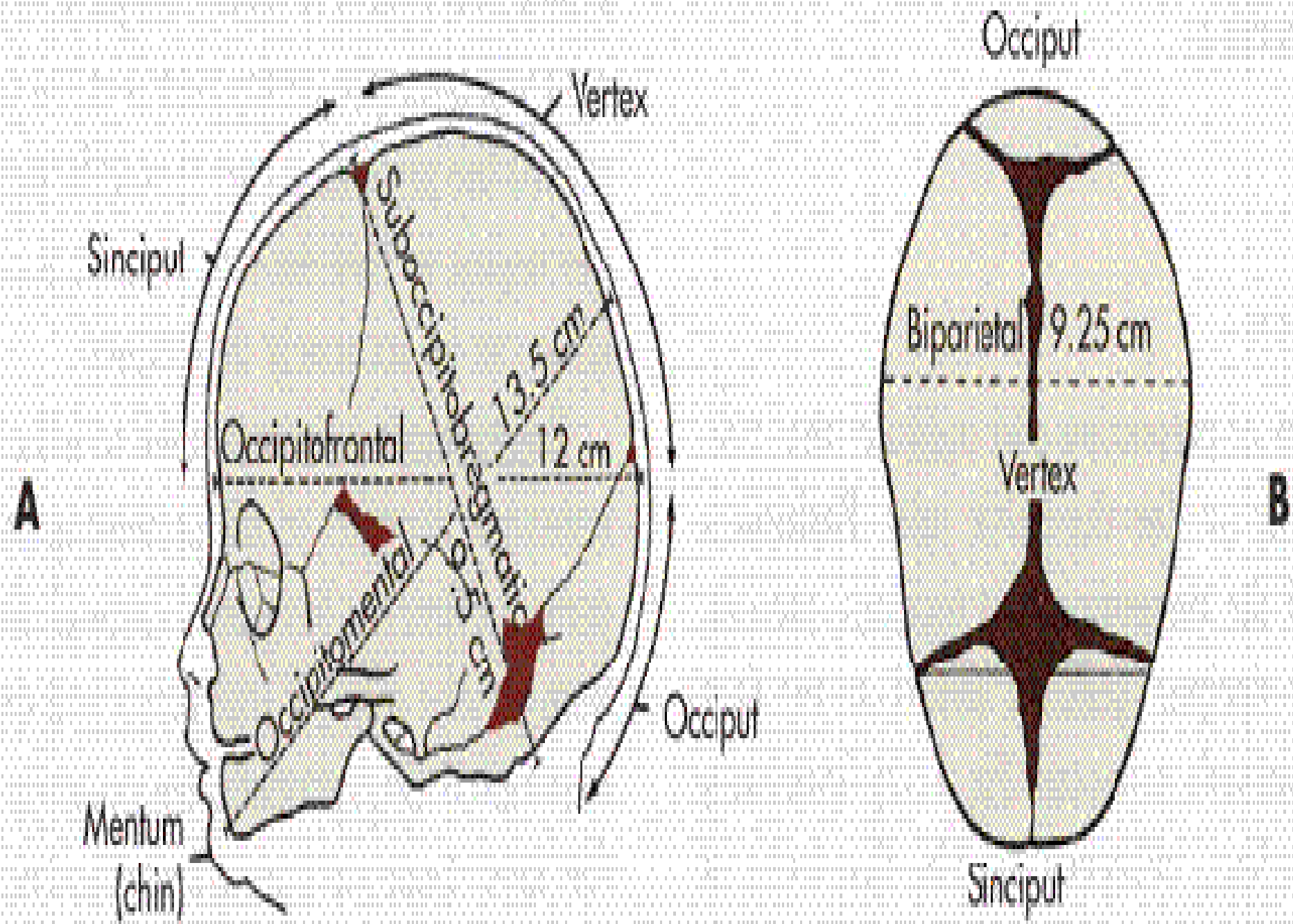
between parietal eminences, it is the greatest transverse diameter





A

Occiput



TERMS AND DEFINITIONS

Presenting part: That part of the fetus that lies over the inlet and first enters the pelvis

Engagement: the entrance of the fetal presenting part into the pelvic inlet and the beginning of the descent through the pelvic canal

THANK

YOU