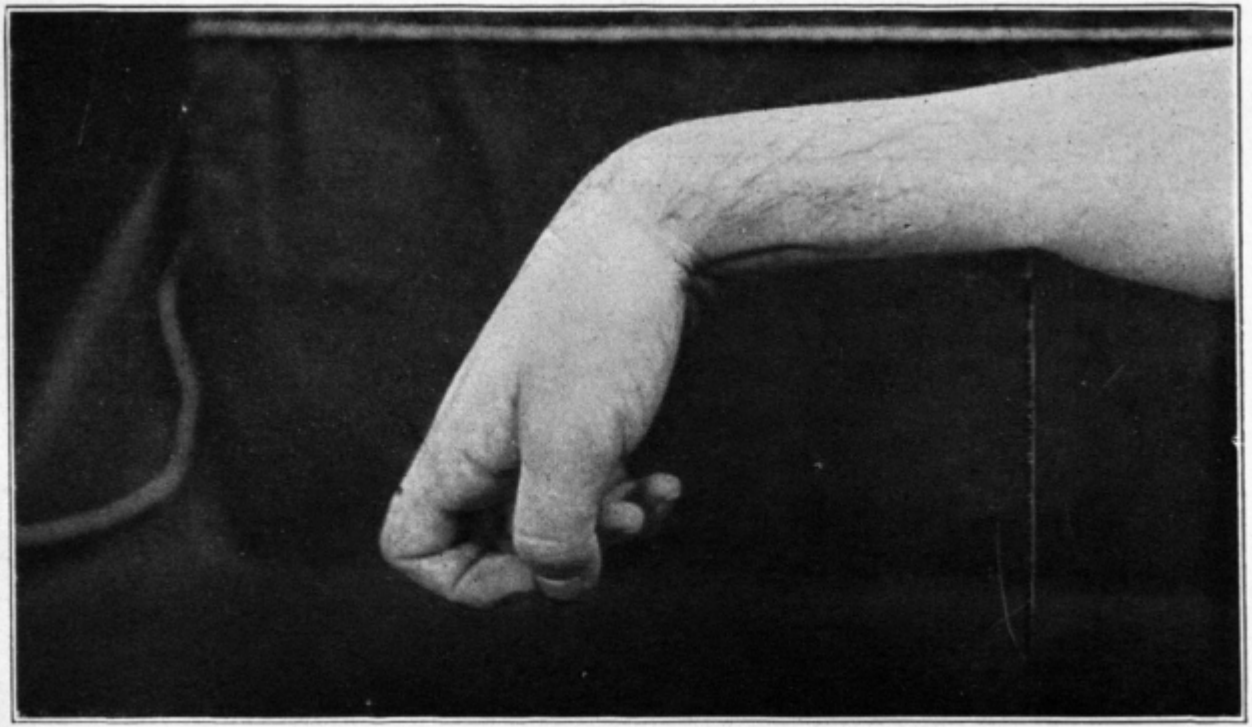

FIG. 91.—Attempted flexion of fingers in musculospiral palsy