

# Philodryas olfersii: state of the art

## Abstract

*Philodryas* sp. in particular, *P. olfersii* is an attractive snake emanated by its green color, with a brown stripe along the back, and an inoffensive appearance. Accidents are rare due to the posterior position of the inoculating teeth (opisthoglyphous), but they are not free-effects either local as systemic. Although most studies with this poison date back less than 3 decades, which started with the Duvernoy's gland secretion and came to transcriptomic analysis, besides the fractioning of the venom to isolate substances responsible for toxic effects, all efforts are converging to the understanding of its pathological mechanisms. We immersed in a scientific platform looking for *Philodryas olfersii* aiming to establish its "state of the art". In this work, we hope to sensitize the medical community about the severity of envenomation by *P. olfersii* can cause, mainly to children, and also the population about the risks of manipulation of this sympathetic snake. Besides, we reinforce that any therapeutic strategy aiming to mitigate the clinical evolution of envenoming is highly desirable.

**Keywords:** green-snake, edematogenic, hemorrhagic, neurotoxic, myotoxic, *Philodryas olfersii*

Volume 15 Issue 1 - 2022

Anna Paula Farias-De-França,<sup>1</sup> Jaqueline de Cássia Prouença Assunção,<sup>2</sup> Yoko Oshima-Franco<sup>2</sup>

<sup>1</sup>Department of Pharmacy, University of Sorocaba (UNISO), Brazil

<sup>2</sup>Post-Graduate Program in Pharmaceutical Sciences, University of Sorocaba (UNISO), Brazil

**Correspondence:** Oshima-Franco Y, Post-Graduate Program in Pharmaceutical Sciences, University of Sorocaba, UNISO, Rodovia Raposo Tavares, km 92.5, Zip code 18023-000, Sorocaba, SP, Brazil, Tel +55 15 2101-7197, Email yoko.franco@prof.uniso.br

Received: January 28, 2022 | Published: February 08, 2022

## Introduction

The ophidism is a global concern due to the number of people which affect (~5.4 million people are bitten each year), generally, in localities where the assistance is inaccessible or, when accessible, the treatment is belatedly instituted. Besides, the snake venoms vary in composition and effects (paralysis, bleeding disorders leading to a fatal hemorrhage, irreversible kidney failure, and tissue damage), and many times the snake is unknown to the victim, which can difficult the specific antivenom administration. Due to around 137,000 deaths/year, WHO formally included snakebite envenoming as a highest priority neglected tropical disease in June 2017.<sup>1</sup>

In Brazil, there are four venomous snakes popularly known as "jararaca" (*Bothrops* genus), "cascavel" (rattlesnake, *Crotalus* genus), "coral verdadeira" (coral snake, *Micrurus* genus), and "surucucu" (*Lachesis* genus). The non-venomous snakes, which are the most Brazilian snakes, belong to the following families: Aniliidae ("falsa coral"); Boidae ("jibóias" and "sucuris"); Colubridae ("cobra-verde", "cobra-cipó"); Leptotyphlopidae ("cobracega"); and Typhlopidae ("fura-terra").<sup>2</sup>

However, colubrid snakes from *Philodryas* genus (Wagler, 1830) are opisthoglyphous (rear-fanged) snakes (Boulenger, 1896) and can give a venomous bite in which the systemic envenomation is rare justifying the classification as "slight" only with local repercussion (local pain, edema, erythema, and ecchymosis),<sup>3-5</sup> which can be treated using anti-inflammatory and analgesic agents, as well as antimicrobials to avoid infections, if necessary.<sup>2</sup> These opisthoglyphous snakes are found not only in Brazil but in the South American continent, as shown in Figure 1, with 23 recognized species.<sup>6</sup>

In this study, the main findings of *Philodryas olfersii* were documented aiming to establish the state of the art knowledge about this venom, since this snake is responsible for the most bites caused by the Dipsadidae subfamily.<sup>7</sup>

The *Philodryas olfersii* snake (Figure 1) also known as a green snake or liana snake, is green in color and has a longitudinal band of the brown color from the back of the head to the tail, has a medium size, and reaches up to 1.5m in total length, with its tail 23 to 36% your body size. It has daytime activity and feeds on small mammals,

birds, frogs, and lizards that it obtains with poisoning and constriction<sup>8</sup> (Figures 1 & 2).<sup>8</sup>

Kingdom	Animalia – Animal, animaux, animals
Subkingdom	Bilateria
Infra kingdom	Deuterostomia
Phylum	Chordata – cordés, cordado, chordates
Subphylum	Vertebrata – vertebrado, vertebrés, vertebrates
Infra phylum	Gnathostomata
Superclass	Tetrapoda
Class	Reptilia Laurenti, 1768 – reptels, reptiles, Reptiles
Order	Squamata Oppel, 1811 – Amphisbaenians, Lizards, Snakes, amphisbènes, lézards, serpents
Suborder	Serpentes Linnaeus, 1768 – Snakes, cobra, serpents, serpents
Infraorder	Allopholidia Nopcea, 1923
Family	Colubridae Oppel, 1811 – Colubrids, Typical Snakes
Subfamily	Dipsadinae
Tribe	Philodryadini Cope, 1886
Genus	Philodryas Wagler, 1830 – Green Snakes
<b>Direct Children:</b>	
Species	<i>Philodryas aestiva</i> (A. M. C. Duméril, Bibron and A. H. A. Duméril, 1854) – Brazilian Green Racer
Species	<i>Philodryas assasii</i> (Jan, 1863) – Burrowing Night Snake
Species	<i>Philodryas amaru</i> Zaher, Arredondo, Valencia, Arbelaez, Rodrigues and Altamirano-Benavides, 2014
Species	<i>Philodryas argentea</i> (Daudin, 1803) – Striped Sharpnose Snake
Species	<i>Philodryas amabilis</i> (Amaral, 1932) – Amalido's Green Racer
Species	<i>Philodryas baroni</i> Berg, 1895 – Baron's Green Racer
Species	<i>Philodryas boliviana</i> Boulenger, 1896 – Bolivian Racer
Species	<i>Philodryas chamusca</i> (Wiegmann, 1835) – Chikan Green Racer
Species	<i>Philodryas cordata</i> Donnelly and Myers, 1981
Species	<i>Philodryas erlandi</i> Lönnberg, 1902 – Miranda Green Racer
Species	<i>Philodryas georgoboulengeri</i> Skoczim, Zaher, Murphy, Scrocchi, Benavides, Zhang and Bonatto, 2012 – Southern Sharpnose Snake
Species	<i>Philodryas jacksoni</i> Werner, 1900
Species	<i>Philodryas itatiaia</i> (Amaral, 1923)
Species	<i>Philodryas maticossetalis</i> Kostlowsky, 1898 – Miranda Green Racer
Species	<i>Philodryas natleri</i> Steindachner, 1870 – Paraguay Green Racer
Species	<i>Philodryas olfersii</i> (Lichtenstein, 1823) – Lichtenstein's Green Racer
Species	<i>Philodryas patagoniensis</i> (Girard, 1858) – Patagonia Green Racer
Species	<i>Philodryas osannobolidae</i> Günther, 1872 – Günther's Green Racer
Species	<i>Philodryas silvanae</i> Boulenger, 1900
Species	<i>Philodryas tachymenoides</i> (Schmidt and Walker, 1943) – Schmidt's Green Racer
Species	<i>Philodryas trilineata</i> (Burmester, 1881)
Species	<i>Philodryas varia</i> (Jan, 1853) – Jan's Green Racer
Species	<i>Philodryas viridissima</i> (Linnaeus, 1758) – Common Green Racer

Figure 1 Taxonomic hierarchy - Information presented on the ITIS website. ITIS, Integrated Taxonomic Information System.




Figure 2 *Philodryas olfersii* snake found in Sorocaba city (23°30'08"S, 47°20'06"W), São Paulo state, Brazil.

It has a horizontal visual band with greater density in the central region and less in the dorsal region, such a characteristic is important to understand its hunting behavior, locomotion, and its position in the ecological niche of tree snakes,<sup>9</sup> also have a chromosome number diploid  $2n=36$  plus 3 metacentrics, 4 submetacentric and 10 acrocentrics, similar to that described in other species of the subfamily Dipsadidae and of the *Philodryas* genus.<sup>10</sup>

Its anatomy of the teeth leads to a low incidence of accidents, as it is an opisthoglyphous, that is, it has the poison inoculating tooth located at the bottom of the mouth, in the posterior portion of the upper jaw, making it difficult to inoculate the poison.<sup>4</sup>

### Snake bites occurrence

Silveria and Nishioka<sup>11</sup> analyzed 91 cases of bites without envenoming and/or caused by non-venomous snakes, in a retrospective survey between 1984 to 1990 attended by Hospital de Clínicas of the Universidade Federal de Uberlândia, Minas Gerais state, Brazil, and found one patient bitten by *P. olfersii* developed severe local pain, swelling, and redness at the site of the bite, with normal clotting time. Whereas 132 cases of accidents caused by *P. olfersii* were evaluated by Ribeiro et al.<sup>12</sup> a fatal case happened with a child of 10-months bitten three times in the arm by a *P. olfersii* specimen in the Rio Grande do Sul state, in 1993, after described by Salomão and Di Bernardo,<sup>13</sup> imputing risks to accidents caused by this snake, arising the need to study the systemic effects of this poison.

Araujo and Santos<sup>14</sup> reported two cases of human envenoming by colubrid snakes, being one caused by *P. olfersii* and the other by *P. patagoniensis*, both envenomings were much alike. The treatment of both did not include the bothropic antivenom, and the envenoming caused by *P. olfersii* were of the major intensity with edema and the enlargement of lymph nodes, the wounds showed suppuration and there was the presence of ecchymosis wounds.

According to the patients admitted in Butantan Institute, SP, Brazil, between 1982 and 1990, 43 patients were diagnosed with bites by *P. olfersii*. Among them, 32 were male (74.4%) and 11 female (25.6%) and occurred mainly on hot days, during the day, 65% of them from November to February. The most common clinical features were local pain (37.2%), swelling (34.9%), erythema (18.6%), and ecchymosis (9.3%).<sup>3</sup>

Correia et al.<sup>4</sup> reported a case of a 17-year-old male patient attended in the Restauração Hospital from Curado IV (Pernambuco state, Brazil), approximately 18 hours after being bitten on his right hand. He reported local pain and edema. The physical examination revealed the presence of erythema, significant edema, and ecchymosis in the entire arm with no systemic abnormalities. Although not considered poisonous, *P. olfersii* and the snakes of the subfamily Dipsadidae (formerly Colubridae) as of medical and scientific importance<sup>15</sup> which encourages more studies to improve diagnosis and treatment of these poisonings.

### Treatment

Due to similarities between *Bothrops* and *Philodryas* accidents, and due to the latter is considered non-venomous, there is no specific anti-*Philodryas* venom, becoming the treatment generally addressed to bothropic antivenom. Some authors consider this administration unnecessary<sup>11</sup> whereas others are favorable<sup>16,17</sup> since *Bothrops* antivenom has a neutralizing activity of hemorrhagic venom components. Although the administration remains controversial, a routine support treatment is performed such as intravenous hydration, analgesic, anti-inflammatory, and corticoids (30' before serum

administration) are performed<sup>4</sup> besides the monitoring by laboratory analyses (electrolytes and diuresis). Considering that historically this poison was little studied alternatives to treat *Philodryas* accidents will certainly arise, as already described with medicinal plants as *Cordia salicifolia* and *Lafoensia pacari*.<sup>18</sup>

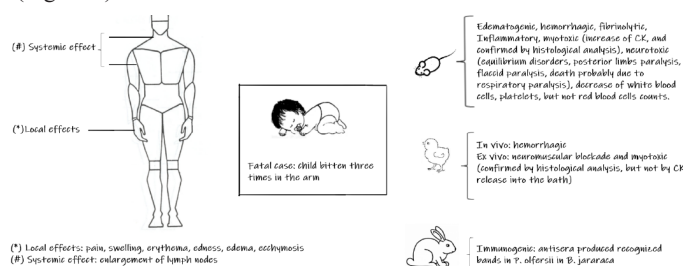
### Experimental studies made with the *Philodryas olfersii* venom – Timeline

Table 1 shows a timeline of main experimental studies, which allowed reaching the state of the art about this intriguing venom (Table 1).

#### *Philodryas olfersii*: the state of the art

The knowledge of envenomation induced by *P. olfersii* described in the literature is summarized in Figure 3, showing the state of the art either in humans as in animals.

Some *P. olfersii* venom profiles can be used as differential among other venoms of medical interest such as the absence of activity on phospholipase A<sub>2</sub>, fibrinogenase, platelet aggregant, nucleotidase, and DNase enzymes.<sup>16,19</sup> In *ex vivo* mice neuromuscular preparations submitted to Duvernoy's gland secretion, the CK released into the bath was similar to the control condition, even with the presence of myotoxin in the gland composition.<sup>20</sup> The transcriptomic study revealed the presence of major toxin classes from the Viperidae family, including serine proteases, metalloproteases, C-type lectins, Crisps, and a C-type natriuretic peptide (CNP)<sup>24</sup> also corroborated by a zymographic study which showed a high alkaline phosphatase activity comparable to venoms of Viperidae snakes found in Brazil.<sup>25</sup> (Figure 3).



**Figure 3** *Philodryas olfersii*: state of the art. The knowledge on *P. olfersii* (human accidents and experimental results).

### Conclusion

The treatment of snakebite envenomation, a neglected tropical disease, is the serum therapy, in which availability in certain countries is deficient or even absent. What to say about a snake not yet recognized as venomous, which occurrence of accidents does not justify the antiserum production by public authorities and private pharmaceutical industries? Moreover, we hope to sensitize the medical community about the severity of envenomation by *P. olfersii* can cause, mainly to children, and also the population about the risks of manipulation of this sympathetic snake. Besides, we reinforce that any therapeutic strategy aiming to mitigate the clinical evolution of envenoming is highly desirable.

### Acknowledgments

JCPA was partially supported by Programa de Pós-Graduação em Ciências Farmacêuticas of the Universidade de Sorocaba (Uniso, Sorocaba, SP, Brazil); APFF was supported by Fundação de Amparo à Pesquisa do Estado de São Paulo (FAPESP 2019/05891-7).

## Conflicts of interest

The authors declare that they have no conflict of interest.

## Author contributions

YOF, APFF, and JCPA: concept the design of the original research, acquisition, analysis of data, final interpretation of data and wrote the manuscript. All authors critically revised the content.

## Funding

None.

## References

- https://www.who.int/news-room/detail/23-05-2019-who-launches-globalstrategy-for-prevention-and-control-of-snakebite-envenoming
- http://189.28.128.100/dab/docs/publicacoes/cadernos\_ab/abcd24.pdf
- Ribeiro LA, Puerto G, Jorge MT. Bites by the colubrid snake *Philodryas olfersii*: a clinical and epidemiological study of 43 cases. *Toxicon*. 1999;37(6):943–948.
- Correia JM, Santana Neto PL, Sabino Pinho MS, et al. Poisoning due to *Philodryas olfersii* (Lichtenstein, 1823) attended at Restauração Hospital in Recife, State of Pernambuco, Brazil: case report. *Rev Soc Bras Med Trop*. 2010;43(3):336–338.
- Oliveira JS, Sant’Anna LB, Oliveira Junior MC, et al. Local and hematological alterations induced by *Philodryas olfersii* snake venom in mice. *Toxicon*. 2017;132:9–17.
- https://www.itis.gov/servlet/SingleRpt/SingleRpt?search\_topic=TSN&search\_value=700309#null.
- Collaço R de C, Cogo JC, Rodrigues-Simioni L, et al. 2012. Protection by *Mikania laevigata* (guaco) extract against the toxicity of *Philodryas olfersii* snake venom. *Toxicon*. 2012;60 (4):614–622.
- Hartmann PA. Hábito alimentar e utilização do ambiente em duas espécies simpátricas de *Philodryas* (Serpentes, Colubridae), no sul do Brasil. Master Dissertation. Brazil, São Paulo: Instituto de Biociências; 2001.
- Hauzman E, Bonci DMO, Grotzner SR, et al. 2014. Comparative study of photoreceptor and retinal ganglion cell topography and spatial resolving power in Dipsadidae snakes. *Brain, Behav Evol*. 2014;84 (3):197–213.
- Nery NDA, Alves MAO, Aquino HD, et al. 2015. Karyotype of *Philodryas nattereri* and *Philodryas olfersii* with a comparative analysis of the Dipsadidae Family. *Genet Mol Res*. 2015;14 (2):6297–6302.
- Silveria PV, Nishioka SA. Non-venomous snake bite and snake bite without envenoming in a Brazilian teaching hospital. Analysis of 91 cases. *Rev Inst Med Trop*. 1992;34 (6):499–503.
- Ribeiro LA, Puerto G, Jorge MT. Acidentes por serpentes do gênero *Philodryas*: avaliação de 132 casos. *Rev Soc Bras Med Trop*. 1994;27 (1):87.
- Salomão EL, Di-Bernardo M. *Philodryas olfersii*: uma cobra comum que mata, caso registrado na área da 8ª Delegacia Regional de Saúde. Sociedade Brasileira de Zoologia. 1995.
- Araújo ME, Santos AC. Cases of human envenoming caused by *Philodryas olfersii* and *Philodryas patagoniensis* (Serpentes: Colubridae). *Rev Soc Bras Med Trop*. 1997;30 (6):517–519.
- Vasconcelos-Filho FSL, Rocha-e-Silva RC, Horn Vasconcelos R, et al. Natural history and biological aspects of Dipsadidae snakes: *P. olfersii*, *Ppatagoniensis* and *P. nattereri*. *Rev Bras Hig Sanid Anim*. 2015;9 (3):386–399.
- Assakura MT, Salomão MG, Puerto G, et al. Hemorrhagic, fibrinolytic and edema-forming activities of the venom of the colubrid snake *Philodryas olfersii* (green snake). *Toxicon*. 1992;30 (4):427–438.
- Teixeira Rocha MM, Paixão-Cavalcante D, Tambourgi DV, et al. Duvernoy’s gland secretion of *Philodryas olfersii* and *Philodryas patagoniensis* (Colubridae): neutralization of local and systemic effects by commercial bothropic antivenom (*Bothrops* genus). *Toxicon*. 2006;47(1):95–103.
- Schezaro-Ramos R, Collaço RC, Cogo JC, et al. 2020. *Cordia salicifolia* and *Lafoensia pacari* plant extracts against the local effects of *Bothrops jararacussu* and *Philodryas olfersii* snakes venoms. *J Venom Res*. 2020;10:32–37.
- Assakura MT, Reichl AP, Mandelbaum FR. Isolation and characterization of five fibrin(ogen)olytic enzymes from the venom of *Philodryas olfersii* (green snake). *Toxicon*. 1994;32 (7):819–831.
- Prado-Franceschi J, S Hyslop S, Cogo JC, et al. 1996. The effects of Duvernoy’s gland secretion from the xenodontine colubrid *Philodryas olfersii* on striated muscle and the neuromuscular junction: partial characterization of a neuromuscular fraction. *Toxicon*. 1996;34 (4): 459–466.
- Prado-Franceschi J. Characterization of a myotoxin from the Duvernoy’s gland secretion of the xenodontine colubrid *Philodryas olfersii* (green snake): effects on striated muscle and the neuromuscular junction. *Toxicon*. 1998;36(10):1407–1421.
- de Pérez OA, de Vila LL, Peichoto ME, et al. Edematogenic and myotoxic activities of the Duvernoy’s gland secretion of *Philodryas olfersii* from the north-east region of Argentina. *Biocell*. 2003;27(3):363–370.
- Rodríguez-Acosta A, Lemoine K, Navarrete L, et al. Experimental ophitoxemia produced by the opisthoglyphous lora snake (*Philodryas olfersii*) venom. *Rev Soc Bras Med Trop*. 2006;39 (2):193–197.
- Ching AT, T Rocha MM, Paes Leme AF, et al. Some aspects of the venom proteome of the Colubridae snake *Philodryas olfersii* revealed from a Duvernoy’s (venom) gland transcriptome. *FEBS Lett*. 2006;580(18):4417–4422.
- Sales PB, Santoro ML. Nucleotidase and DNase activities in Brazilian snake venoms. *Comp Biochem Physiol C Toxicol Pharmacol*. 2008;174 (1):85–95.
- Peichoto ME. A comparative study of the effects of venoms from five rear-fanged snake species on the growth of *Leishmania major*: identification of a protein with inhibitory activity against the parasite. *Toxicon*. 2011;58(1):28–34.
- Peichoto ME, Tavares FL, Santoro ML, et al. Venom proteomes of South and North American opisthoglyphous (Colubridae and Dipsadidae) snake species: a preliminary approach to understanding their biological roles. *Comp Biochem Physiol Part D Genomics Proteomics*. 2012;7(4):361–369.