

Review Article

Colibacillosis in poultry: A review

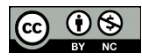
Yuvraj Panth

Department of Veterinary Medicine and Public Health, Agriculture and Forestry University,
Rampur, Chitwan, Nepal

Correspondence: vetdoc.yuvraj@gmail.com, ORCID: <https://orcid.org/0000-0002-7423-0859>

Received: June 23; Accepted: September 23; Published: October 25, 2019

© Copyright: Panth, Y. (2019).



This work is licensed under a [Creative Commons Attribution-NonCommercial 4.0 International License](https://creativecommons.org/licenses/by-nc/4.0/).

ABSTRACT

Avian colibacillosis is caused by a group of pathogens designated avian pathogenic *Escherichia coli* (APEC). Despite being known for over a century, avian colibacillosis remains one of the major endemic diseases afflicting the poultry industry worldwide. Autologous bacterins provide limited serotype-specific protection, yet multiple serogroups are associated with disease, especially O1, O2 and O78 among many others. This article provides the vital information on the epidemiology, diagnosis, control and treatment strategy for avian colibacillosis. A better understanding of the information addressed in this review article will assist the poultry researchers and the poultry industry in continuing to make progress in reducing and eliminating avian colibacillosis from the poultry flocks.

Keywords: Colibacillosis, economics, poultry

Correct citation: Panth, Y. (2019). Colibacillosis in poultry: A Review. *Journal of Agriculture and Natural Resources*, 2(1), 301-311. DOI: <https://doi.org/10.3126/janr.v2i1.26094>

INTRODUCTION

Any localized or systemic infection characterized by colisepticemia, hemorrhagic septicemia, coligranuloma (Hjarre's disease), swollen head syndrome, venereal colibacillosis, coliform cellulitis, peritonitis, salpingitis, orchitis, osteomyelitis/synovitis, panophthalmitis, omphalitis/yolk sac infection and enteritis, is referred to as colibacillosis. It is characterized in its acute form by septicemia resulting in death, and in its subacute form by pericarditis, perihepatitis, air sacculitis and other lesions. The presence of exudations in the peritoneal (abdominal) cavity including serum, fibrin and inflammatory cells (pus), are the characteristics. Fibrin is the product of the inflammatory response in chicken that is seen covering the surfaces of multiple organs, including the oviduct, the ovary, the intestine, the alveoli, the heart, the lungs and the liver (Linden, 2015). However, we should not only diagnose based on the lesions to infer an infection with *Escherichia coli* without adding the descriptor “coli” or “coliform”, because other opportunistic bacteria can behave similarly to *E. coli* in secondary infections (Barnes *et al.*, 2008).

It has been observed that avian colibacillosis is a major infectious disease worldwide in birds of all ages, which imparts a significant economic impact on poultry production. Losses are economical, as a result of mortality and decreased productivity of affected birds, mainly around the peak egg production period and throughout the late lay period (Linden, 2015). Avian Pathogenic *Escherichia coli* (APEC) infections are due to stress caused by infections with mycoplasma, infectious bursal disease (IBD) virus, infectious bronchitis (IB) virus, New Castle disease (ND) virus, and environmental influences such as temperature, humidity, ammonia and dust on farms. In addition, *E. coli* can penetrate through the shell when the egg is contaminated by feces, and can spread to chickens during hatching, resulting in high early chick mortality, as well as infection of the yolk sac (Kabir, 2010).

E. coli bacteria are a normal inhabitant of the digestive tract of birds and most strains do not cause diseases. When they occur, findings are colisepticemia (blood infection) and yolk sac infection in young chicks; and peritonitis and egg coligranuloma in adults (Vegad, 2015). Often, colibacillosis occurs simultaneously with other diseases, which makes diagnosis and management difficult (Linden, 2015). Rodents, water, flies, insects, food composition, etc. are potential risk factors for APEC (Vandekerchove *et al.*, 2004). The intensification of poultry production and the aggressive expansion of the poultry production systems result in an increase in the incidence of colibacillosis through increased exposure of birds to pathogens and stress (Guabiraba & Schouler, 2015).

Colibacillosis' prophylaxis is based on strict control of breeding conditions, with priority in biosafety practices and vaccination. Vaccines available in the market are more or less effective, mainly because APEC strains are very diverse and are not widely applied to date. The treatment of colibacillosis is based on antibiotherapy, however, increasing occurrence of multidrug-resistant *E. coli* isolates, has challenged.

Etiology

The disease is caused by certain strains of avian pathogenic *Escherichia coli* (APEC), of which strain O is more common. *Escherichia coli* is a gram-negative, non-acid fast, non-staining,

non-spore-forming bacillus, usually $3 \times 0.6 \mu\text{m}$ in size, which is included in the Enterobacteriaceae family (Nolan *et al.*, 2013).

E. coli is usually motile, often fimbriated, with peritrichous flagella. Somatic (O), flagellar (H) and sometimes capsular (K) antigens are used to differentiate *E. coli* serotypes. The pathogenic strains of the bacteria have virulence factors that allow them to colonize mucosal surfaces and subsequently produce diseases. Age, immune status, the nature of the diet and the strong exposure to pathogenic strains are the factors that predispose animals to develop clinical diseases after colonization by the pathogen. (Quinn *et al.*, 2011). *E. coli* O157: H7, an important zoonotic pathogen, has been isolated from chickens and turkeys; and pigeons can transport shigatoxin-producing *E. coli* (STEC), which can affect people (Nolan *et al.*, 2015).

Epidemiology

The organism is present throughout the world and is a normal inhabitant of the gastrointestinal tract of animals and birds at a concentration of 10^6 per grams, while the dust in the poultry house can contain up to 10^5 - 10^6 / gm (Vegad, 2015). Garbage and feces are sources of contamination for both healthy birds and eggs. Transmission is possible through ovaries to newborn chicks. Food, rodent droppings, contaminated well water are the sources of pathogenic *E. coli*. While, isolates of pathogens for poultry commonly belong to certain serogroups, particularly serogroups O78, O1 and O2, but O15 and O55 may also be found to some extent (Chart *et al.*, 2000). According to Amin *et al.*, (2017), the most frequent serogroup of *E. coli* observed was O76 (15.59%), followed by 14.45% O8, 12.17% O1, 7.22% O26, 6.44% O2, 4.94% O114, 4.18% O11, 3.80 % O2 and 3.04% every O45 and O84. Avian colibacillosis was found to be widely prevalent in all chicken age groups (9.52 to 36.73%) with an especially high prevalence rate in adult layer birds (36.73%) in Gazipur, Bangladesh (Rahman *et al.*, 2004). However, the prevalence was found to be higher in broilers than in layers in the large Mymensingh district of Bangladesh (Matin *et al.*, 2017) and in the state of Kassala, East Sudan (Omer *et al.*, 2010). The onset of colibacillosis was 32.52% during March 23, 2014 to May 14, 2014 in Gazipur, Bangladesh (Hossain *et al.*, 2015).

A total of 16.32% were colibacillosis alone among 3799 cases, while mixed infection with mycotoxicity, chronic respiratory disease, infectious bursal disease and coccidiosis were 4.13%, 14.71%, 1.07% and 1.23% respectively, during the year 2014/15 at the Central Veterinary Laboratory, Kathmandu (CVL report, 2014/15). It was found that the prevalence of colibacillosis in poultry was dominant, with 25.69% of the cases presented at the Veterinary Teaching Hospital of Agriculture and Forestry University in Chitwan, Nepal, during fiscal year 2014/2015 and 2015/2016 (Gautam *et al.*, 2017). A total of 44 outbreaks of colibacillosis occurred in 2015, of which 112823 chickens were affected and 7803 died, while 155 outbreaks of colibacillosis occurred between January and June 2016, of which 77202 chickens were affected and 3183 died (VEC report, 2015; VEC report 2016). 14.16% of cases during August 2016 to January 2017 (Shrestha & Shrestha, 2019) and 9.29% during mid-December 2014 to mid-June 2015 (Sharma & Tripathi, 2015) present at the National Laboratory of Avian Disease Research (NADIL), Chitwan, were colibacillosis positive. 31% of liver samples were positive for *E. coli* in poultry in a study conducted at the Surkhet Regional Veterinary Laboratory during September 2016 to January 2017 (Sapkota & Pandey, 2019).

Clinical signs and Lesions

In general, broilers approximately 5 weeks of age are affected (Seneviratna, 1969). Birds of any age can be affected if resistance is reduced by predisposing factors. Chicks less than 10 days old are particularly susceptible if their resistance has been reduced (Seneviratna, 1969).

The severity of the infection may be mild or persistent, and clinical signs may be absent in these cases. Birds with colisepticemia can become lethargic and stop eating and drinking. Severity of the disease may be indicated by the degree of reduced water consumption (Nolan *et al.*, 2015). Chronically affected birds show signs of stunted growth and unthriftiness.

E. coli infections in poultry occur in two forms: systemic and localized.

Localized forms of colibacillosis

Omphalitis / yolk sac infection

The poor hygiene of the hatchery and the contamination of the eggshell contribute to the inflammation of the navel (omphalitis) of the newborn chicks and to the concurrent infection of the adjacent yolk sac (yolk sacculitis). The yolk sac infection is the most common cause of chick mortality during the first week after hatching, *i.e.*, early chick mortality.

- Affected birds show depression, swollen abdomen and tendency to cluster (huddling)
- Affected birds are often dehydrated, stunted, and may have a vent pasting and an enlarged gall bladder
- Unabsorbed yolk sac
- Distended and smelly yolk sac with abnormality in color and consistency
- The tissue around the navel is often moist and red (inflamed); so the disease is often called "mushy" chick or poult disease
- Peritonitis and hemorrhage on the surface of the intestine

Swollen head syndrome

An acute to subacute form of cellulitis that affects the subcutaneous tissues of the periorbital area, giving a swollen appearance to the chicken's face, is swollen head syndrome. Swelling of the head is caused by inflammatory exudate under the skin that accumulates in response to bacteria, usually *E. coli*, after viral infections of the upper respiratory tract, such as avian metapneumovirus, infectious bronchitis virus, etc. (Nolan *et al.*, 2013) and is worse in flocks exposed to high levels of ammonia in the air (Nolan *et al.*, 2015). Mainly broilers and their parents are affected, characterized by the swollen appearance of the face, respiratory symptoms (coughing and sneezing), tracheitis, opisthotonus, green diarrhea with a foul odour (Vegad, 2015).



Figure 1: Swollen Head Syndrome;
Source: Nolan *et al.*, 2015

Coliform Cellulitis (Inflammatory Process)

Cellulitis is the inflammation of the loose connective tissue located under the skin. Serosanguinous to caseous exudate plaques in subcutaneous tissues are commonly located on the abdomen or between the thigh and midline. The clinical signs are usually absent. Lesions are

observed in the processing after deburring or during autopsy. The fast, heavy and aggressive fattening lines, more often, are likely to have scratches on the skin, which predisposes to coliform infection and then cellulitis (Nolan *et al.*, 2015).

Males are more often affected than females (Al-Ankari *et al.*, 2001; Blanco *et al.*, 1997) that could be due to its association with weight and aggressiveness. Other risk factors include poor feathering, high flock density, litter quality, as they make birds prone to scratches.

Diarrheal disease (enteritis)

Primary enteritis is a common manifestation of *E. coli* infections in mammals, including humans, however, it is considered rare in poultry. Diarrhea is the result of enterotoxigenic (ETEC), enterohemorrhagic (EHEC), enteropathogenic (EPEC) or enteroinvasive *E. coli* (EIEC) infections; with each type having certain virulence factors that determine the characteristics of enteric disease (Nolan *et al.*, 2013). Strains that cause enteritis are able to bind and erase the intestinal epithelium. The birds are dehydrated and show diarrhea. The intestine and the blind of the affected birds are pale and distended with fluid and mucus spots. Characteristic “pits and pedestals” that adhere to blurred lesions covered with adhered *E. coli* are observed in the intestines (Nolan *et al.*, 2015).

Venereal colibacillosis (acute vaginitis)

Venereal colibacillosis is more common in turkey breeding hens. Vaginitis is acute and most often causes mortality. Cloacal and intestinal prolapse, peritonitis often accompanies vaginitis. The mucosa of the affected hens is thickened, ulcerated and covered with a caseonecrotic membrane. Egg production is reduced with a larger number of small eggs.

Salpingitis and peritonitis

Oviduct inflammation (salpingitis) due to *E. coli* infection results in reduced egg production with the death of laying hens and breeders. Mortality is sporadic and infections can spread to the peritoneum causing peritonitis. Oviducts are presented with a firm mass or masses of caseous exudate. Cloaca, infected air sacs, vent pecking and prolapse are responsible for infection (Vegad, 2015; Linden, 2015). When *E. coli* spreads from the oviduct to the abdomen, salpingoperitonitis occurs. In immature birds, the oviduct is infected by extension of the air sacculitis that affects the left abdominal air sac (Nolan *et al.*, 2013). Affected birds show signs of sporadic loss of laying, damaged vents, urate leaks, distended abdomen and death.

Coliform orchitis / epididymitis / epididymo-orchitis

The testicles and epididymis of the affected roosters are swollen, firm, irregularly shaped and may have adhesions to adjacent tissues; the necrosis is extensive. The lesions are typically unilateral.

Egg peritonitis

Almost always, egg peritonitis is caused by *E. coli*. Egg peritonitis is the inflammation of the peritoneum caused by the presence of a broken egg in the abdominal cavity. It is a common cause of sporadic death in laying or breeding hens, but in some flocks it can become the main cause of death before or after reaching maximum production and giving the appearance of a

contagious disease (Rosales, 2019). Dead birds show scattered pieces of yolk, thick yolk, cheese-like material or milky fluid in the abdominal cavity (Vegad, 2015). A complete or partially formed egg may be impacted in the oviduct.

Systemic forms of colibacillosis

Colisepticemia

Colisepticemia is defined by the presence of virulent *E. coli* in the bloodstream of birds. The duration, degree and outcome of the disease plus the pattern and severity of the lesions are determined by virulence and the number of organisms, balanced with the effectiveness of the host's defenses. The most common form of colibacillosis is characterized by an initial respiratory infection (air sacculitis), often followed by a generalized infection (perihepatitis, pericarditis and septicemia) (Mellata *et al.*, 2003). Colisepticemia progresses through the following stages: acute septicemia, subacute polyserositis and chronic granulomatous inflammation (Nolan *et al.*, 2013).

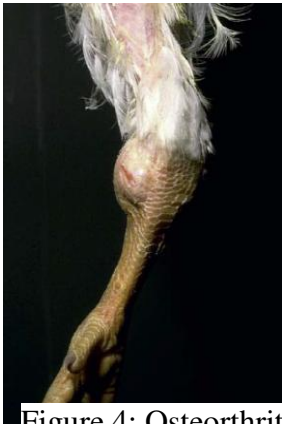

Figure 4: Osteoarthritis;
Source: Nolan et al.,
2015

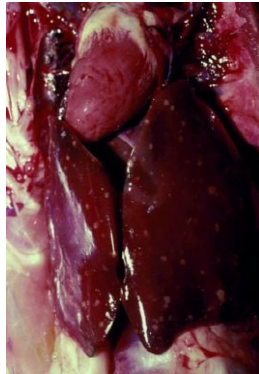


Figure 3: Multiple
focal lesions in
liver; Source:
Nolan et al., 2015

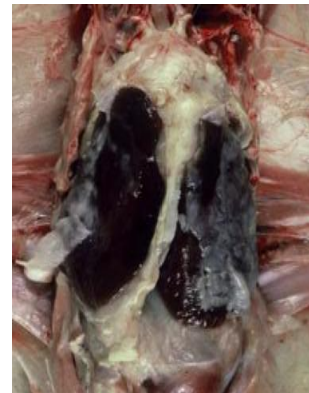

Figure 2: Perihepatitis;
Source: Nolan et al.,
2015

Pericarditis, characteristic of colisepticemia, is frequently observed and may be associated with myocarditis. The pericardium becomes cloudy and edematous. Initially, fluid and soft masses of pale exudate accumulate within the pericardial sac, followed by fibrinous exudate. With the progression of the disease, the exudate increases, becomes more cellular and undergoes marriage. (Nolan *et al.*, 2013). Then, the inflamed adherent pericardial sac undergoes organization (fibrosis), resulting in constrictive pericarditis and heart failure. Fibrous perihepatitis and splenomegaly with necrotic tissues in the liver and spleen may be evident.

There is air sacculitis of varying severity and, therefore, respiratory signs such as rales, sneezing and cough are observed. Osteomyelitis, arthritis, tenosynovitis and spondylitis can be sequelae of colisepticemia.

On PM examination, the infected air sacs thicken, are opaque and may contain caseous exudate. Affected birds are normal in appearance and are often found dead with a complete culture, sometimes in acute colisepticemia.

In layers and breeders, most outbreaks are associated with the onset of egg production, but less frequently they occur at a more advanced age. A rapid onset of deep depression, lameness and diarrhea was observed (Zanella *et al.*, 2000). At necropsy, polyserositis (perihepatitis, pericarditis) and peritonitis associated with free yolk in the peritoneal cavity, oophoritis and salpingitis were present in most birds (Nolan *et al.*, 2013).

The chicks are affected within 24-48 hours after hatching. A total of 10-20% mortality is observed with elevation for 2-3 weeks. Initial lesions in chicks consist of congested lungs and splenomegaly. When the bacterium is located in the central nervous system, meningitis and encephalitis are evident in young chicks. Affected birds have neurological signs of rowing and/or neck twisting. Unilateral panophthalmitis is occasionally observed and is characterized by severe inflammation and damage to the internal eye tissue.

Hemorrhagic Septicemia

This form occurs in turkeys and is characterized by widespread circulatory alterations, discoloration of subserosal fat, bloody fluid on serous surfaces, pulmonary edema and hemorrhage, and enlargement of the liver, spleen and kidneys. Generalized necrosis of the liver and multifocal necrosis of the spleen are evident on the cut surfaces. (Nolan *et al.*, 2013).

Coligranuloma

Coligranuloma (Hjarre's disease) is a sporadic form of colibacillosis that affects chickens, turkeys and quails. Multiple granulomas occur in the liver, proventriculus, ventricle, small intestine, cecum and mesentery.

Diagnosis

The diagnosis is based on the isolation and identification of the *E. coli* organism of the typical colibacillosis lesions. Fibrinous pericarditis is highly suggestive of the disease (Seneviratna, 1969). A presumptive diagnosis of *E. coli* infection can be made if the majority of the colonies are characteristically dark with a metallic glow on eosin-methylene blue (EMB) agar, bright pink, with a precipitate around the colonies on MacConkey agar, or yellow in tergitol-7 agar. Differentiation between APEC and commensal *E. coli* isolates can be made by using molecular diagnoses such as PCR (Nolan *et al.*, 2013).

Acute septic diseases caused by Pasteurellae (*Pasteurella*, *Ornithobacterium*, *Riemerella*), Salmonellae, Streptococci and other organisms, should be taken in consideration to differentiate the disease. *Chlamydophila*, pasteurellae or streptococci (*Streptococcus*, *Enterococcus*) can cause pericarditis or peritonitis, and other bacteria, mycoplasmas and *Chlamydophila* can cause airsacculitis. (Nolan *et al.*, 2013).

Prevention and control

Management

The prevention of colibacillosis is largely a matter of good sanitation and hygiene. Predisposing factors and sources of infection should be ruled out and resolved accordingly. Fumigation of litter with methyl bromide and formaldehyde is effective in destroying *E. coli* (Seneviratna, 1969). Fecal contamination of eggs can be reduced by collecting eggs frequently,

keeping nest material clean, without using eggs from the floor, discarding broken eggs and spraying or disinfecting eggs within 2 hours after laying. The water test for coliform count and treatment with disinfectants is essential. Hot granulation processes destroy *E. coli* (Ekperigin *et al.*, 1990), but care must be taken not to contaminate the finished food again. Colibacillosis has been controlled by the chlorination of drinking water and the use of closed irrigation systems (nipple) (Dhillon & Jack, 1996). Maintaining good air and litter quality is essential to reduce the risk of a flock developing colibacillosis (Davis & Morishita, 2005). Proper ventilation minimizes damage to the respiratory tract by ammonia and, therefore, reduces exposure to bacterial and aerial endotoxins.

Nutritional management should be manipulated, such as food additives that support a healthy immune system and improve survival capacity, adequate protein ratios, increased selenium, increased levels of vitamins A and E and probiotics to promote competitive exclusion (Linden, 2015). Appropriate care should be taken to restrict immunosuppression from stress or other diseases.

Vaccination

Table 1: *E. coli* vaccine types and characteristics (Linden, 2015)

Type of vaccine	Description	Results
<i>Autogenous (killed)</i>	<ul style="list-style-type: none"> Provides protection against homologous <i>E. coli</i> strains No cross protection Breast injection 	<ul style="list-style-type: none"> Reduced morbidity and mortality due to <i>E. coli</i> infection
<i>Commercial live</i>	<ul style="list-style-type: none"> Poulvac <i>E. coli</i> 078 (by Zoetis) Cross protection against serotypes O1, O2 and O18 Spray 	<ul style="list-style-type: none"> Reduced morbidity and mortality due to <i>E. coli</i> infection Enhanced bird productivity

Treatment

Treatment strategies should include actions to control predisposing infections or environmental factors and the early use of antibacterials indicated by susceptibility testing. Different antimicrobial drugs have been used to treat and control colibacillosis. The fortuitous use of antimicrobials has produced a threat of resistance to antimicrobials and, therefore, the availability of effective antimicrobials has decreased. In addition, the development of new drugs is also lacking.

Neomycin (38.00%) was mainly used for the treatment of colibacillosis, with an efficacy of 92.10%, with resistance of *E. coli* to neomycin, oxytetracycline, amoxicillin, enrofloxacin and ciprofloxacin, 38.88%, 50.55%, 60.68%, 50.00% and 30.55% respectively, during March 23, 2014 to May 14, 2014 in Gazipur, Bangladesh (Hossain *et al.*, 2015). Gentamicin (100%) was highly sensitive for the treatment of colibacillosis (Hossain *et al.*, 2015).

For an effective treatment, an antibiotic sensitivity test is desired to determine the susceptibility of the bacterial isolate to an antimicrobial therapy. The sensitivity of *E. coli* to gentamicin, neomycin, levofloxacin, tetracycline, enrofloxacin, cephalixin, azithromycin,

bacitracin, chloramphenicol, doxycycline, amoxicillin and ampicillin was 100%, 100%, 100%, 89%, 84%, 81% , 80%, 80%, 80%, 71%, 50% and 20% respectively (CVL report 2014/15).

Alternatives to antimicrobials such as prebiotics, probiotics, enzymes, digestive acidifiers, vitamins, immune enhancers and anti-inflammatory drugs have been suggested; however, the use of these has not been done so excitingly. *Lactobacillus*, *Bacillus* species have been used as probiotics to inhibit colonization of *E. coli* in the digestive tract.

Conclusion

Colibacillosis is primarily a disease that occurs when birds are stressed or infected with other diseases such as CRD, IBD, etc., that suppress the immune system. *E. coli*, a normal commensal of the gastrointestinal tract, finds possibilities of multiplication and alters the health of the birds when the birds are predisposed to stress. Care must be taken to prevent the disease by maintaining strict biosecurity measures.

Author Contributions

YP wrote whole article.

Conflicts of Interest

The author declares that there is no conflict of interest.

REFERENCES

- Abalaka, S.E., Sani, N. A., Idoko, I. S., Tenuche, O. Z., Oyelowo, F. O., Ejeh, S. A., & Enem, S. I. (2017). Pathological changes associated with an outbreak of colibacillosis in a commercial broiler flock. *Sokoto Journal of Veterinary Sciences*, 15(3), 95-102. <http://dx.doi.org/10.4314/sokjvs.v15i3.14>
- Abdul-Rahman Al-Ankari , J. M. Bradbury , C. J. Naylor , K. J. Worthington , C. Payne-Johnson & R. C. Jones. (2001). Avian pneumovirus infection in broiler chicks inoculated with *Escherichiacoli* at different time intervals. *Avian Pathology*, 30(3), 257-267, DOI: 10.1080/03079450120054686
- Amin, U., Kamil, S. A., Shah, S. A., Tanveer, A. D., Mir, M. S., Kashoo, Z. A., & Wani, B. M. (2017). Serotyping and prevalence of avian pathogenic *Escherichia coli* infection in broilers in Kashmir. *The Pharma Innovation Journal*, 6(10), 336-338.
- Barnes, H. J., Nolan, L. K., & Vaillancourt, J. P. (2008). Colibacillosis. *Diseases of Poultry*, 12th Ed. Blackwell Publishing
- Blanco, J. E., Blanco, M., Mora, A., & Blanco, J. (1997). Prevalence of bacterial resistance to quinolones and other antimicrobials among avian *Escherichia coli* strains isolated from septicemic and healthy chickens in Spain. *Journal of Clinical Microbiology*. 35, 2184–2185.
- Chart, H., Smith, H. R., La Ragione, R. M., & Woodward, M. J. (2000). An investigation into the pathogenic properties of *Escherichia coli* strains BLR, BL21, DH5 α , and EQ1. *Journal of Applied Microbiology*, 89, 1048-1058.

- CVL Report. (2014/15). Annual Technical Report. Central Veterinary Laboratory Tripureshwar, Kathmandu, Nepal
- Davis, M. & Morishita, T. Y. (2005). Relative ammonia concentrations, dust concentrations, and presence of *Salmonella* species and *Escherichia coli* inside and outside commercial layer facilities. *Avian Diseases*, 49, 30-35.
- Dhillon, A. S., & Jack, O. K. (1996). Two outbreaks of colibacillosis in commercial caged layers. *Avian Diseases*, 40, 742–746. DOI: 10.2307/1592290
- Ekperigin, H. E., McCapes, R. H., Redus, R., Ritchie, W. L., Cameron, W. J., Nagaraja, K. V., & Noll, S. (1990). Microcidal effects of a new pelleting process. *Poultry Science*, 69, 1595–1598.
- Gautam, G., Devkota, B., & Thapaliya, S. (2017). Recent Case Flow Pattern in Veterinary Teaching Hospital of Agriculture and Forestry University, Chitwan, Nepal. *Journal of Agriculture and Forestry University*, 1, 119-128.
- Guabiraba, R. & Schouler, C. (2015). Avian colibacillosis: still many black holes, *FEMS Microbiology Letters*, 362(15) doi: 10.1093/femsle/fnv118
- Hossain, M. A., Amin, M. R., Khan, M. D. I., Mollah, M. L., & Amin, M. A. (2015). Occurrences, treatment and antibiotic resistant pattern of colibacillosis and salmonellosis in broiler. *Journal of Bioscience and Agriculture*, 4(2), 67-73.
- Kabir, S. M. L. (2010). Avian Colibacillosis and Salmonellosis: A Closer Look at Epidemiology, Pathogenesis, Diagnosis, Control and Public Health Concerns. *International Journal of Environmental Research and Public Health*, 7, 89-114. doi:10.3390/ijerph7010089
- Linden, J. (2015). Colibacillosis in Layers: an Overview. *The Poultry Site*. Retrieved from <http://www.thepoultrysite.com/articles/3378/colibacillosis-in-layers-an-overview/> on 22nd January, 2019.
- Matin, M. A., Islam, M. A., & Khatun, M. M. (2017). Prevalence of colibacillosis in chickens in greater Mymensingh district of Bangladesh, *Veterinary World*, 10(1), 29-33.
- Mellata, M., Dho-Moulin, M., Dozois, C. M., Curtis, R., Lehous, B., & Fairbrother, J. M. (2003). Role of avian pathogenic *Escherichia coli* virulence factors in bacterial interaction with chicken heterophils and macrophages. *Infection and Immunity*, 71(1), 494-503. doi: 10.1128/IAI.71.1.494-503.2003
- Nolan, L. K, Barnes, H. J., Vaillancourt, J. P., Abdul-Aziz, T., & Logue, C. M. (2013). Colibacillosis. In: *Diseases of Poultry*, Swayne, D. E., Glisson, J. R., McDougald, L. R., Nolan, L. K., Suarez, D. L., Nair, V. L (Eds.). Wiley-Blackwell, 13th Edition, 751-805.
- Nolan, L. K, Barnes, H. J., Vaillancourt, J. P., Abdul-Aziz, T. & Logue, C. M. (2015). Colibacillosis. In: *Manual of Poultry Diseases*, edited by Brugere-Picoux, J., Vaillancourt, J. P., Shivaprasad, H. L., Venne, D., & Bouzouais, M. AFAS, 301-315.
- Omer, M. M., Abusalab, S. M., Gumaa, M. M., Mulla, S. A., Omer, E. A., Jeddah, I. E., Al-Hassan, A. M., Hussein, M. A., & Ahmed, A. M. (2010). Outbreak of Colibacillosis among broiler and layer flocks in intensive and semi intensive poultry farms in Kassala State, Eastern Sudan. *Asian Journal of Poultry Science*, 4(4), 173-181
- Quinn, P.J., Markey, B.K., Leonard, F. C., FitzPatrick, E.S., Fanning, S., & Hartigan, P. J. (2011). *Veterinary Microbiology and Microbial Disease* (2nd edition). Wiley-Blackwell, 492-505.

- Rahman, M. A., Samad, M. A., Rahman, M. B., & Kabir, S. M. L. (2004). Bacterio-pathological studies on salmonellosis, colibacillosis and pasteurellosis in natural and experimental infections in chickens. *Bangladesh Journal of Veterinary Medicine*, 2, 1-8.
- Rosales, A. G. (2019). Egg Peritonitis in Poultry (Egg yolk peritonitis). Retrieved from <https://www.merckvetmanual.com/poultry/disorders-of-the-reproductive-system/egg-peritonitis-in-poultry> on 22nd January, 2019.
- Sapkota, M. M. & Pandey, K. R. (2019). Prevalence and Associated Risk Factor of *Escherichia Coli* from the cases of Poultry at Regional Veterinary Laboratory (RVL) Surkhet, Nepal. Retrieved from <https://www.farm.com.np/research/prevalence-and-associated-risk-factor-of-escherichia-coli-of-poultry-nepal/> on 18th August, 2019
- Seneviratna, P. (1969). *Diseases of Poultry (Including Cage Birds)* (2nd edition). Bristol: John Wright and Sons Ltd., 68-70.
- Sharma, A., & Tripathi, P. (2015). Seasonal Prevalence of Poultry Diseases and their interaction with IBD and Mycotoxicosis in Chitwan, Nepal. *The Research Gate*. doi: 10.13140/RG.2.2.27054.41283
- Shrestha, S., & Shrestha, B. K. (2019). Case-flow analysis of National Avian Disease Investigation Laboratory (NADIL), Chitwan during August 2016 to January 2017. Retrieved from <https://www.farm.com.np/research/poultry-disease-in-nepal/> on 21st January, 2019.
- Vandekerchove, D., Herdt, P. D., Laevens, H. & Pasmans, F. (2004). Risk factors associated with colibacillosis outbreaks in caged layer flocks. *Avian Pathology*, 33(3), 337-342, DOI: 10.1080/0307945042000220679
- Vegad, J. L. (2015). *Poultry Diseases* (2nd Edition). CBS Publishers.
- VEC Report. (2015). *Annual Epidemiological Bulletin*, 11(3). Veterinary Epidemiology Center, Tripureshwor, Kathmandu, Nepal.
- VEC Report. (2016). *Annual Epidemiological Bulletin*, 12(1). Veterinary Epidemiology Center, Tripureshwor, Kathmandu, Nepal.
- Zanella, A., Alborali, G. L., Bardotti, M., Candotti, P., Guadagnini, P. F., Martino, P. A., & Stonfer, M. (2000). Severe *Escherichia coli* O111 septicaemia and polyserositis in hens at the start of lay. *Avian Pathology*, 29(4), 311-317. DOI: 10.1080/03079450050118430