

## CASE REPORT

# Hamman's Syndrome: A Rare Benign Syndrome

Aida Abdul Rahim<sup>1,2</sup>, Mohd Taufiq Yahaya<sup>1,2</sup>, Siti Nor Farhana Mohd Shafie<sup>1,2</sup>, Laila Mastura Ahmad Apandi<sup>1</sup>

<sup>1</sup> Department of Radiology, Serdang Hospital, 43400 Serdang, Selangor, Malaysia

<sup>2</sup> Department of Imaging, Faculty of Medicine and Health Sciences, Universiti Putra Malaysia, 43400 Serdang, Selangor, Malaysia

### ABSTRACT

Hamman's syndrome by definition is spontaneous pneumomediastinum with the exclusion of thoracic trauma or iatrogenic cause. It is rare and is more common in adolescence male. Amongst the risk factors are underlying lung condition such as asthma and interstitial lung disease, drug inhalation and parturient woman. Patient usually presents with sudden onset of shortness of breath and chest pain with subcutaneous emphysema on examination. The diagnosis is confirmed with chest radiograph. The prognosis of Hamman's syndrome is excellent. Most cases are self-limiting and resolve spontaneously. However, Hamman's syndrome is a poorly recognised disease due to its rarity. Therefore, the patient may be subjected to misdiagnosis and treatment. This is a case report of Hamman's syndrome misdiagnosed and treated as pneumothorax. The objective of this case report is to highlight the importance of differentiating this benign syndrome with life threatening differentials which may have similar clinical presentation. Thus, avoiding unnecessary costly investigation, treatment and invasive procedures.

**Keywords:** Hamman's syndrome, Emergency Department, Spontaneous pneumomediastinum

### Corresponding Author:

Laila Mastura Ahmad Apandi (MRad, MBBS),  
Email: lailamastura@upm.edu.my  
Tel: +60173686795

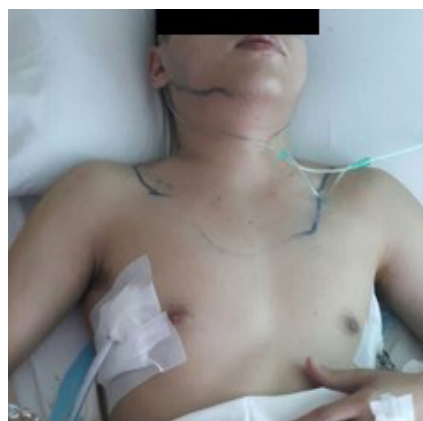### INTRODUCTION

Spontaneous pneumomediastinum, was first coined by Louis Hamman in 1939. Since then, the condition is called Hamman's syndrome, currently also known as Macklin's syndrome. It is a rare entity, most often encountered in young adults; more commonly in peripartum and postpartum patients. This is a case report of Hamman's syndrome, highlighting the importance of differentiating this benign syndrome with life threatening condition thus avoiding unnecessary costly investigation, treatment and invasive procedures.

### CASE REPORT

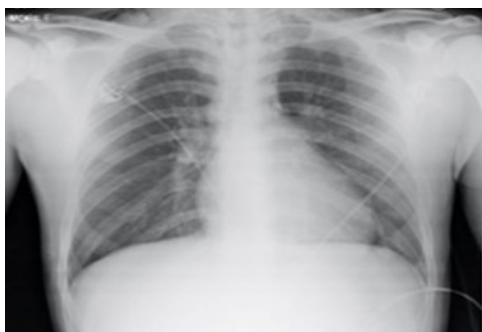
A young gentleman presented to the casualty with sudden onset chest pain and neck swelling. There was mild shortness of breath. Patient did not have any symptoms respiratory tract infection or trauma prior to presentation. There was no associated hoarseness of voice, fever, vomiting, chills or rigors. He had previous history of childhood asthma but was never hospitalised. On examination, there was no audible wheeze upon auscultation. There was significant swelling of the neck with subcutaneous crepitations or subcutaneous emphysema palpated, from the chest area extending

to the neck region (Figure 1). There was no stridor or distended vessels seen.



**Figure 1: Picture of the patient with significant swelling of the neck**

Respiratory rate was normal. His oxygen saturation was maintained at 98% on room air and temperature documented was 37°C. Patient was also put on nasal oxygen. ECG done showed normal findings. The blood examination done showed no increase in inflammatory parameters and his creatinine kinase was within normal limit. Initial chest radiograph (CXR) was taken. The pneumomediastinum was misinterpreted as bilateral pneumothorax by the medical officer of the Emergency Department. Bilateral chest tube was inserted (Figure 2) after discussion between the medical officer and the emergency physician.



**Figure 2: CXR showing lucency outlining the mediastinal contour**

On the next day of admission, the case was discussed with the radiologist as there was no bubbling in the underwater seal bottle of the chest tubes bilaterally. The radiologist reviewed the CXR done on admission. The diagnosis of pneumomediastinum was made with no evidence of pneumothorax. CT Thorax was subsequently done to evaluate the chest tubes placement and to find the cause of the pneumomediastinum.

The CT thorax done showed extensive chest area subcutaneous emphysema extending to the neck region, as well as pneumomediastinum (Figure 3). There was no pneumothorax as per previous CXR finding. There was no evidence of airway injury or fractures.

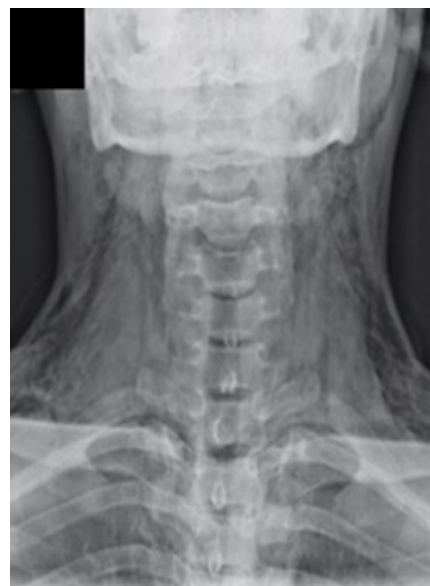Laryngeal scope was not performed upon discussion with the ENT team as there was no supportive biochemical data or history to suggest airway injury.

The extensive subcutaneous emphysema and neck swelling improved gradually within seven days of stays. There was no intravenous antibiotic given. The chest tube was removed after CT Thorax images are reviewed. Patient was stable throughout admission and was finally discharged on day 8 of admission.

## DISCUSSION

Spontaneous pneumomediastinum (Hamman's syndrome) is a rare condition of having free air within the mediastinum without any obvious precipitating cause. The syndrome is self-limiting, transient condition which improves with time and treated conservatively. The pneumomediastinum is resultant from alveolar rupture which leads to air dissecting along the peribronchovascular interstitial sheaths, interlobular septa, visceral pleura and into the mediastinum (1). This pathophysiology mechanism is also known as the Macklin effect. It is also associated with high intra-alveolar pressure, often associated with underlying lung condition such as asthma and interstitial lung disease (1, 2).

Among precipitating factors of Hamman's syndrome were alcohol excess, vomiting, coughing and illicit drug use (2) Some may be idiopathic. This syndrome is also



**Figure 3: Neck radiograph in AP view showing significant subcutaneous emphysema**

more common in peripartum and post partum period (1, 2).

At the encounter of air lucencies devoid of lung markings on a chest radiograph, a novice doctor might mistakenly jump into conclusion that the patient is having pneumothorax, especially when the clinical presentation of typical acute chest pain with dyspnea and subcutaneous emphysema are similar in both conditions. Furthermore, recognizing pneumomediastinum from a small medial pneumothorax from chest radiography may be a diagnostic challenge (6). Misinterpretations are commonly realized upon CT Thorax study, which might be done a few days after the initial admission (3). Awareness of this syndrome can potentially avoid pain, pneumothorax and potential skin or lung infection from unnecessary chest tube insertion.

This condition also needs to be differentiated from Boerhaave's syndrome, which is another cause of a non-traumatic mediastinum emergencies. It is a more sinister form of pneumomediastinum, as the aetiology is due to transmural ruptured of the esophagus, usually at distal third of the esophagus. It is commonly precipitated by frequent vomiting, commonly predisposed among alcoholics (3). These factors can be elicited from a thorough history taking. It carries a high mortality rate as it is usually missed or delayed with sequelae of dehydration, mediastinitis, sepsis and shock.

Other differentials of non-traumatic mediastinal emergencies to be considered are acute mediastinitis, spontaneous mediastinal hematoma, tension pneumomediastinum or pneumopericardium as well as esophageal emergencies such as acquired esophagorespiratory fistulas and intramural hematoma of the esophagus. These conditions can be differentiated with CT Thorax.

Chest radiograph is frequently done as an initial screening tool for patients with chest pain. In chest radiographs, the signs to look for in pneumomediastinum are linear lucency or stripe lucency surrounding the mediastinum, presence of the thymus, 'continuous diaphragm' sign and 'double bronchial wall' sign. The continuous diaphragm, as the name infer, result from the presence of air over the diaphragmatic surface. Meanwhile, the double bronchial wall sign is a demonstrable air or lucency on both side of the bronchial wall. On lateral chest radiograph, subtle lucency can be elicited anterior to the pericardium.

Although sometimes these lucencies can be quite subtle to a novice eye, recognizing it is diagnostic of a pneumomediastinum. Pneumothorax, on the other hand, are seen as linear peripheral lucency with absent of lung markings. The appearance of pneumothoraces can varies depending on the patient's position during the radiograph is obtained. For instances, unilateral lung lucency and deep sulcus sign (mostly in paediatric population) are also signs of pneumothorax when the radiograph is taken in supine position. The heart border appears more remarkable and the costophrenic sulcus will be unusually deepened as air prefer to accumulates anteriorly to the lung.

The best position is to obtained radiographs in PA erect position and during expiratory phase, which may not always be fulfilled and is limited by patients' condition. Nevertheless, in most cases, clinicians or surgeon would further investigate with a contrast enhanced CT thorax, which should be a one-stop shop modality for patients with Hamman's syndrome.

Computed tomography is the modality of choice as it is readily available, cheap and can obtained fast acquisition. It has a high sensitivity and specificity due to its ability to reconstruct multiplanar projection and multislice thin cut acquisition. Multiple setting can be obtained with post-processing options making it excellent to look at bone, lung, and any soft tissue pathologies. In multiphase study, evaluation of the thoracic aorta caliber and presence of any dissection, can be done.

Free air pockets within the mediastinum, increased attenuation of mediastinal fat, localized fluid collections, enlarged lymph nodes, pleural effusions, and empyema are among common features of acute mediastinitis (5). It's a common cause of chest pain, however most cases of acute mediastinitis resulting from complications of cardiovascular or cardiothoracic surgical procedures, which can also associated with sternal dehiscence (5). To exclude or detect esophageal pathophysiologic cause of a suspected mediastinal emergencies, a contrast-enhanced esophagography are sometimes done in some centres. This may demonstrate extravasation of contrast material into the mediastinum, although its false negative

result can be quite high (5) Non-traumatic spontaneous rupture of the esophagus such as in Boerhaave's syndrome, are more detectable on contrasted CT by demonstration of focal esophageal wall thickening, periesophageal fluid collections and free mediastinal air pocket (5).

## CONCLUSION

It is important to recognize and differentiate pneumomediastinum from pneumothorax, especially in adolescent with no precipitating trauma. Clinical history is always crucial to avoid mismanagement. However, correct chest radiograph interpretation and CT Thorax are imperative to avoid misdiagnosis. This patient had unnecessary chest tube insertion and prolonged hospitalization due to lack of awareness of this syndrome. Hamman's syndrome also needs to be differentiated from Boerhaave's syndrome as the later present pivotal early detection for early intervention.

## ACKNOWLEDGEMENT

This work is supported by Putra Grant-Putra Young Initiative (GP-IPM/2018/9641200) fromUniversiti Putra Malaysia, Malaysia

## REFERENCES

1. Wintermark M, Schnyder P. The Macklin effect: a frequent etiology for pneumomediastinum in severe blunt chest trauma. *Chest*. 2001;120 (2): 543-7.
2. Kelly S. Spontaneous pneumomediastinum (Hamman's syndrome). Volume 8, Issue 2, April 2010, Pages 63-66 <https://doi.org/10.1016/j.surge.2009.10.007>
3. Ho AS, Ahmed A, Huang JS, Menias CO, Bhalla S. Multidetectorcomputedtomographyofspontaneous versus secondary pneumomediastinum in 89 patients: can multidetector computed tomography be used to reliably distinguish between the 2 entities? *J Thorac Imaging*. 2012;27(2):85-92 PMID:21436744. <http://dx.doi.org/10.1097/RTI.0b013e3182103876>
4. Alves GRT et al. Spontaneous pneumomediastinum (Hamman's syndrome). *J. bras. pneumol.* vol.38 no.3 SroPaulo May/June 2012<http://dx.doi.org/10.1590/S1806-37132012000300018>
5. Katabathina VS, Restrepo CS, Martinez-Jimenez S et-al. Nonvascular, nontraumatic mediastinal emergencies in adults: a comprehensive review of imaging findings. *Radiographics*. 2011;31 (4): 1141-60. <http://dx.doi.org/10.1148/rg.314105177>
6. Zylak CM, Standen JR, Barnes GR et-al. Pneumomediastinum revisited. *Radiographics*. 2000: 20 (4): <https://doi.org/10.1148/radiographics.20.4.g00j1131043>