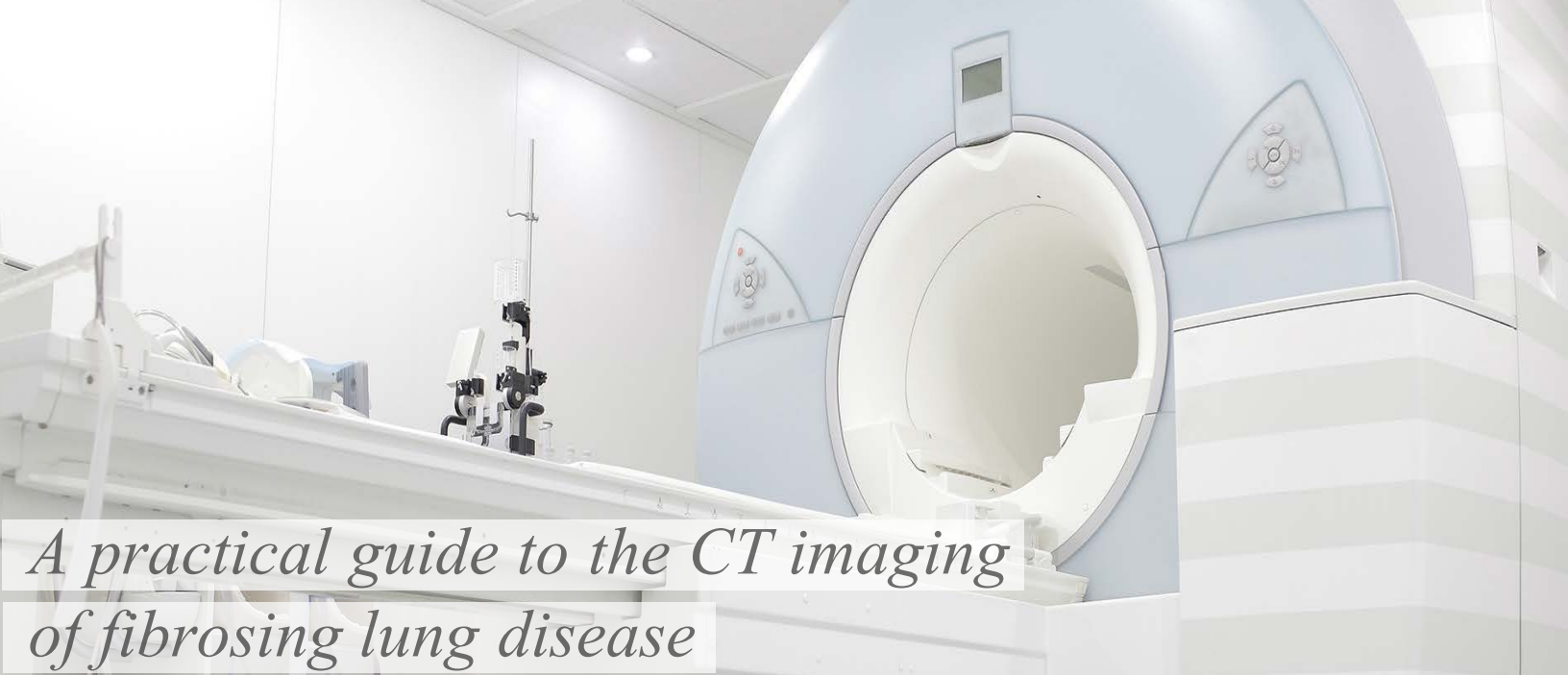



A practical guide to the CT imaging of fibrosing lung disease

All HRCT images are a courtesy of Dr Simon Walsh

Algorithm

The interpretation of HRCT of diffuse lung diseases has traditionally relied on '*pattern recognition*'. In the context of fibrosing lung disease, this approach can be refined and simplified. It is possible to apply a simple and easily remembered stepwise approach that covers most of the diagnostic questions encountered in clinical practice. The journey starts with the basic question of 'abnormal or not?', and then proceeds through a few steps to arrive at a consideration of the HRCT features that point to the most likely fibrosing lung disease.

HRCT TECHNIQUE

Concept:

Acquisition of the highest spatial resolution images possible using '*as low as reasonably achievable*' (ALARA) radiation

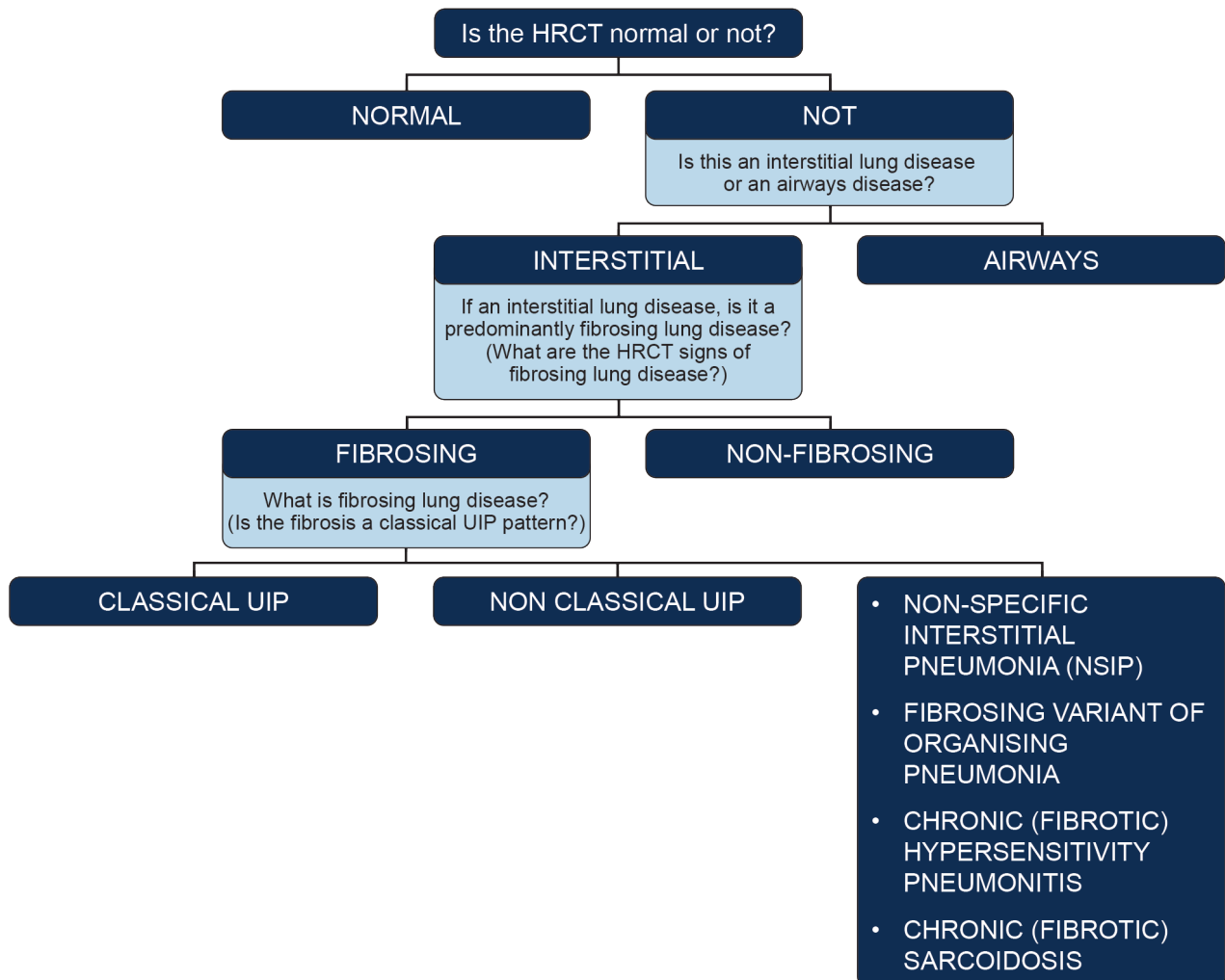
Basic requirements:

- Whole lung volumetric CT acquisition for adults
- Patient scanned supine while breath holding at end inspiration
- Thin section reconstructions (<2 mm thickness)
- High spatial frequency reconstructions (very sharp)
- Window settings: centre -500 to -800 HU; width 1300 to 1800 HU

Refinements and additions:

- Prone CT (from carina down) – to clarify the significance of dependent opacification; not needed if ILD is known or clearly present on chest radiograph
- Expiratory CT – to aid the identification of air trapping caused by small airways obstruction; not routinely needed, but can be helpful in cases of suspected hypersensitivity pneumonitis
- Multiplanar reconstructions of volumetric CT data (coronal reformats in particular) show disease distribution to advantage and may help to differentiate traction bronchiectasis from honeycombing
- Consider very low-dose radiation (e.g. 30 mAs) for follow-up HRCTs, especially for younger patients
- Intravenous contrast is not indicated, indeed contrast administration makes evaluation of the density of the lung parenchyma difficult (an important point when assessing a patient with a suspected acute exacerbation of IPF)

Diagnostic algorithm for fibrosing lung disease



Recognising lung disease

.... KNOW WHEN TO CALL FOR HELP

Practitioners with an interest in diffuse lung disease should ultimately be conversant with the HRCT characteristics of the following fibrosing diseases:

- Usual interstitial pneumonia (UIP) – classical and non-classical patterns
- Non-specific interstitial pneumonia (NSIP)
- Fibrosing variant of organising pneumonia
- Chronic (fibrotic) hypersensitivity pneumonitis
- Chronic (fibrotic) sarcoidosis

If you are confronted with an HRCT, which does not fit with any of these conditions, it is time to summon assistance either from multidisciplinary discussion or from an experienced thoracic radiologist.

Is the HRCT normal or not?

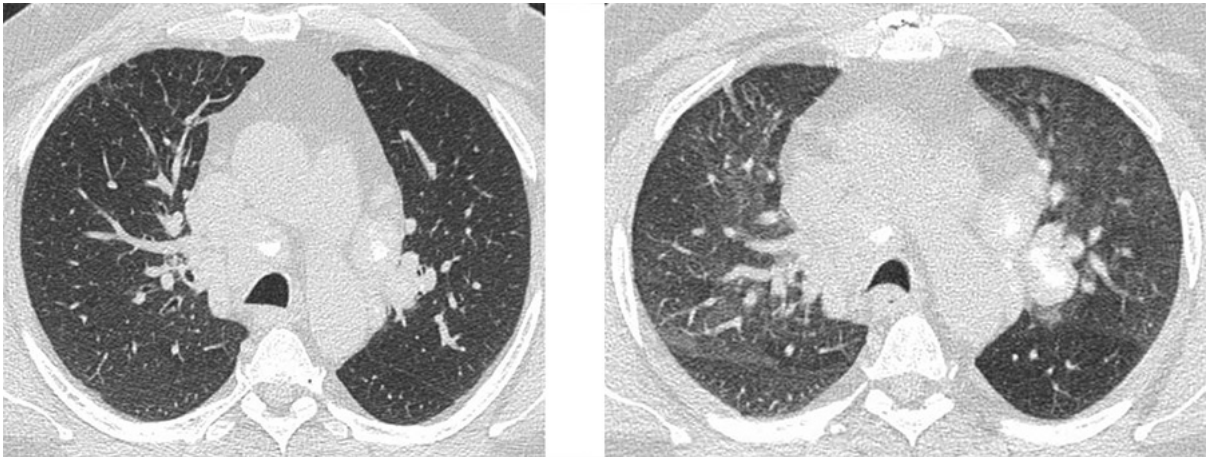
Likely points of difficulty (1/4)

Artifactual causes of **generalised increase in density** of the lung parenchyma (lighter grey than expected).

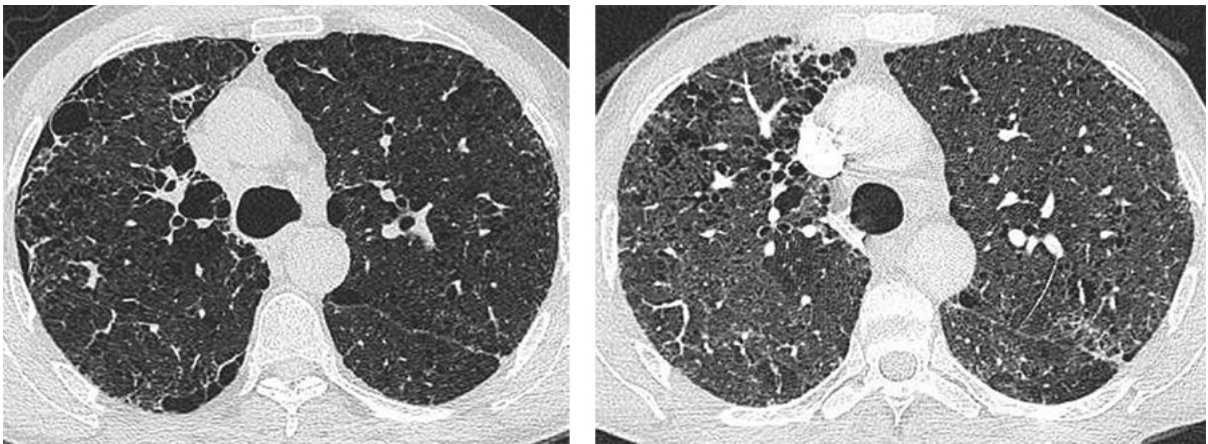
Possible causes:

- Lungs not at full inflation
- Non-standard window settings
- Images from an unfamiliar CT scanner
- Intravenous contrast administration (e.g. CT pulmonary angiogram)

Paired CT images



Paired inspiratory (left) and expiratory (right) HRCT



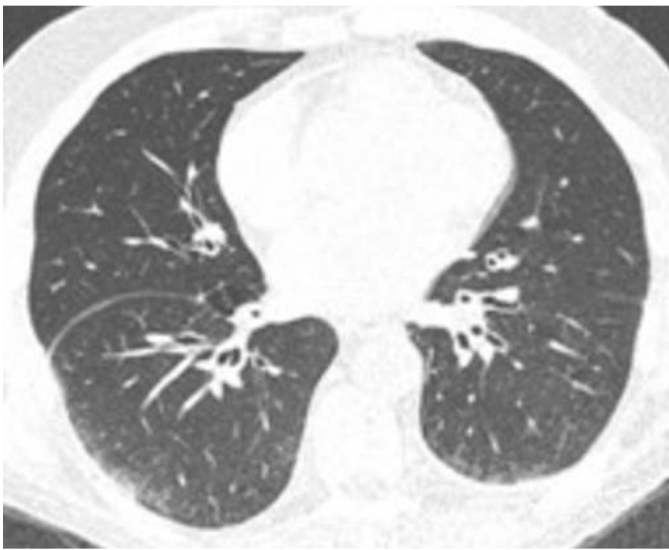
Paired HRCT without contrast (left) and with contrast (right)

Likely points of difficulty (2/4)

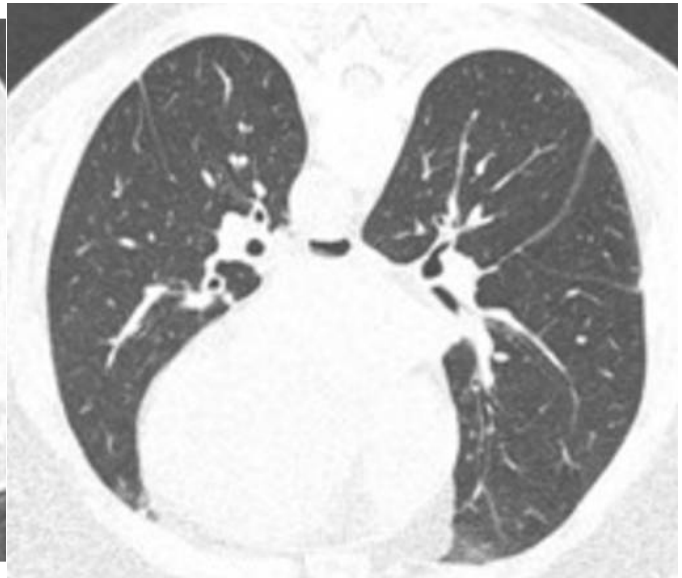
Appearances of the **subpleural (peripheral) lung**.

Differentiation between early interstitial lung disease in the posterobasal segments of the lower lobes and physiologic **gravity-dependent opacification** requires HRCT in the prone position for certain clarification – in healthy individuals the *opacification* disappears on turning to the prone position, whereas if this density represents disease, it is present on both the prone and supine images. In the absence of prone sections to make this distinction, the total gas diffusing capacity (DLco) may help to elucidate whether clinically significant interstitial lung disease is present or not.

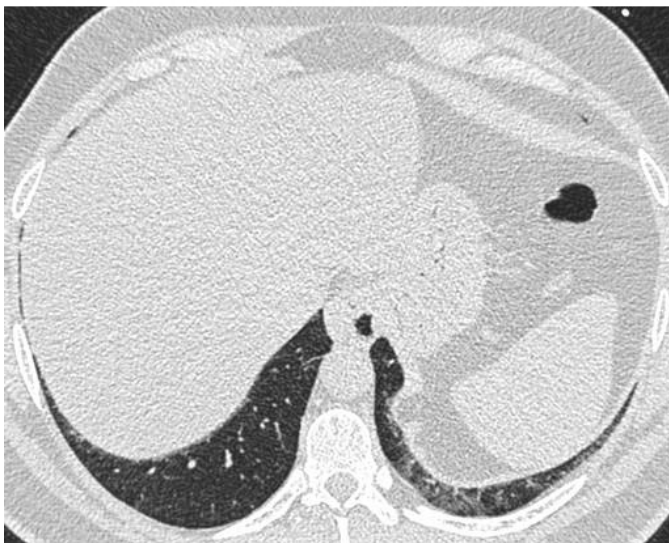Paired CT images



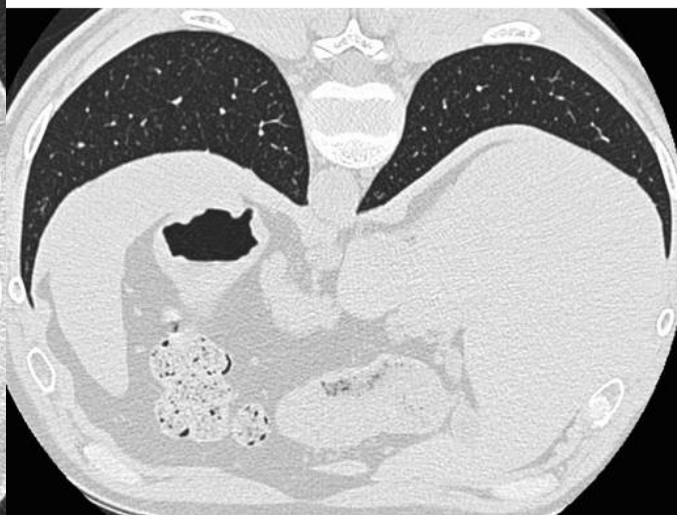The limited subpleural opacification in the posterobasal segments in the supine position



is no longer visible in the prone position



Fixed opacification in the supine

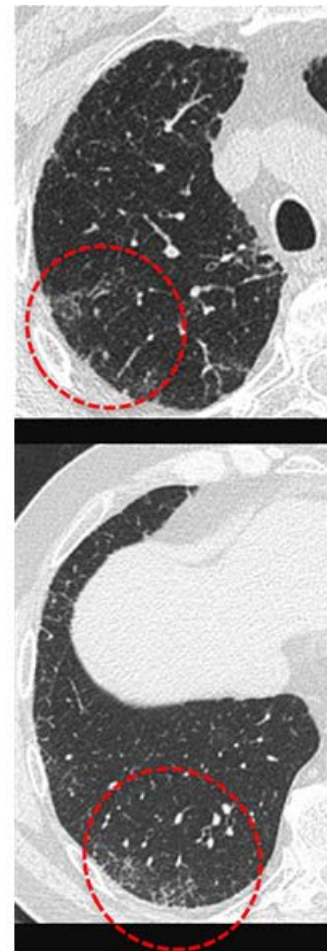
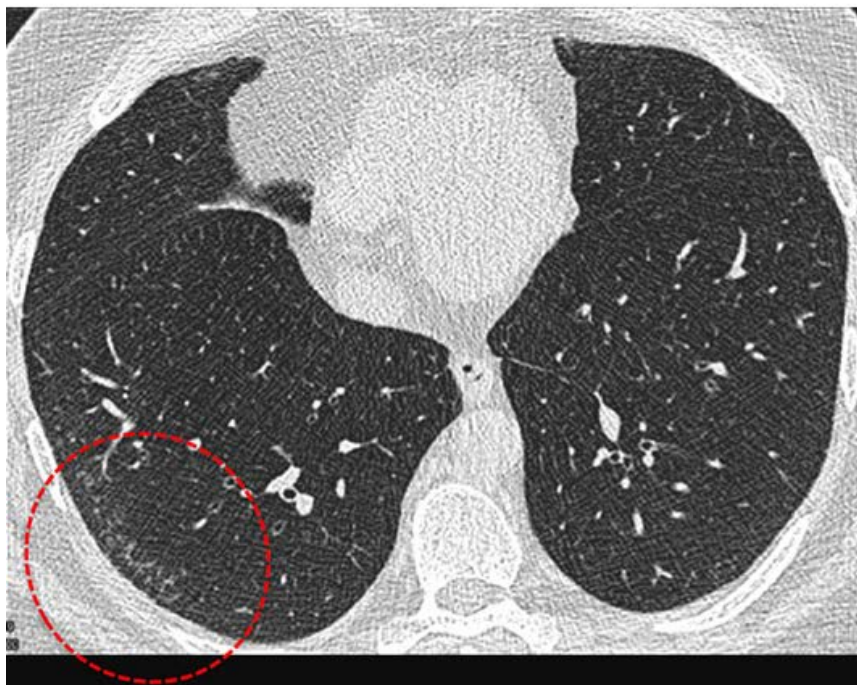


and prone images indicating limited interstitial lung disease

Limited interstitial lung abnormalities. In adult studies, interstitial lung abnormalities (ILAs) are present on CT in 7% of the general population.¹⁻⁴ Early work on limited interstitial lung abnormalities (ILAs) suggested that these may be a normal part of ageing lung.¹ However more recent studies in large populations have reported associations between ILAs and smoking,¹ reduced lung capacity, exercise capacity, gas exchange² and genetic abnormalities including MUC5B promoter polymorphism.³ Progression of ILAs on CT may be associated with increased risk of death.⁵ These associations have led investigators to question if ILAs represent an early stage of idiopathic pulmonary fibrosis (IPF). Since the prevalence of ILAs is far greater than that of IPF, only a small proportion of ILAs are likely to represent clinically significant disease. This requires further study.

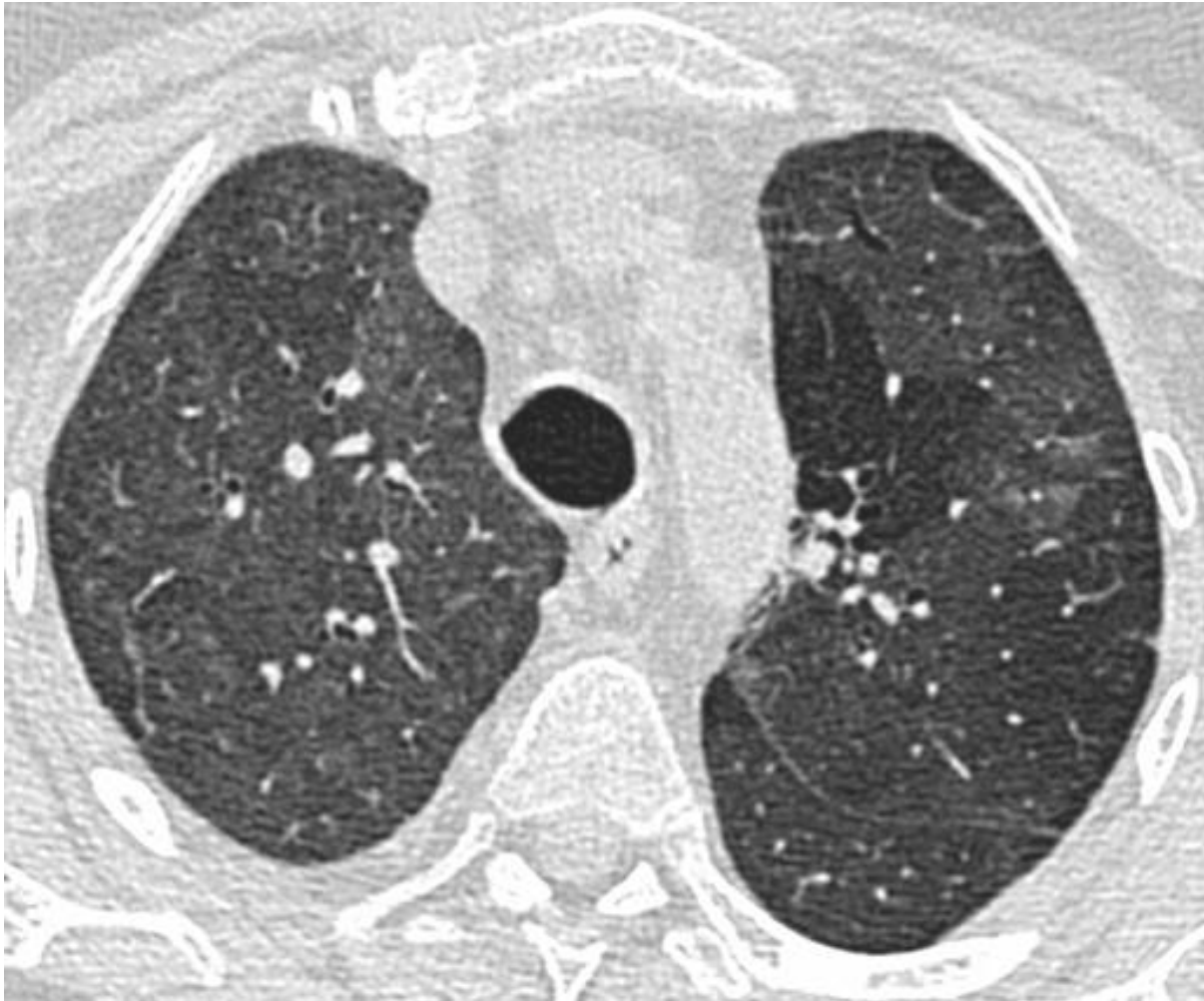1. Lederer et al. Am J Respir Crit Care Med 2009;180:407-414
2. Putman et al. JAMA 2016;315:672-681
3. Hunninghake et al. N Engl J Med 2013;368:2192-2200
4. Copley et al. Radiology 2009;251:566-573
5. Araki et al. Am J Respir Crit Care Med 2016;194:1514-1522

Limited interstitial lung abnormalities



Likely points of difficulty (3/4)

Inhomogeneity of the density of the lung parenchyma (*mosaicism*). Some degree of 'patchiness' of the lung density, usually due to minor small airways dysfunction or obliteration, is common in apparently healthy individuals. Up to about 25% of the cross-sectional area of the lung may be of decreased attenuation (blackier) and still be considered as being within the normal range. In the absence of accompanying signs, mosaicism is not a feature of fibrosing lung disease.



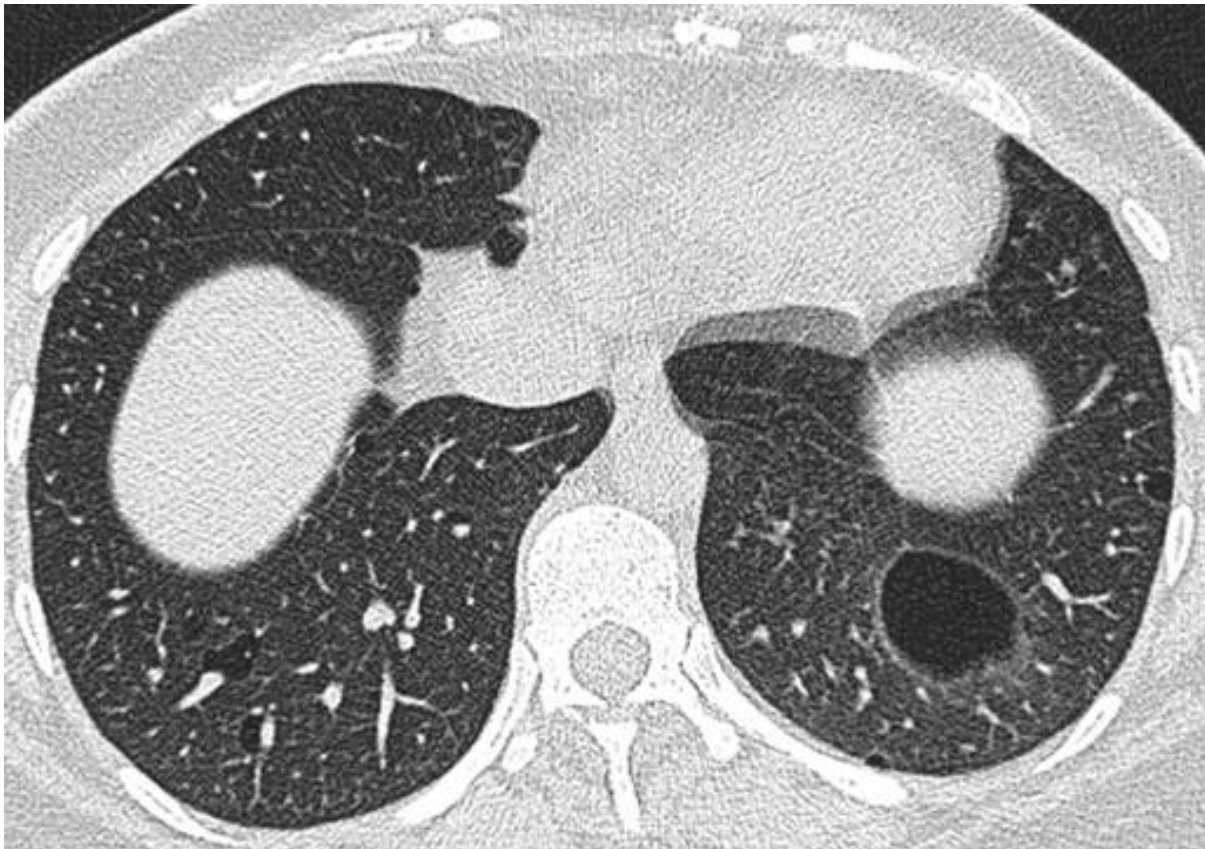Subtle density differences (mosaicism) in a healthy individual with normal lung function

Likely points of difficulty (4/4)

Cysts. A cause or explanation should be sought for cystic air spaces in younger individuals (<60 years old), e.g. a manifestation of centrilobular emphysema. In the elderly a few thin-walled cystic air spaces are quite common and do not denote disease.



[Further Reading](#)
Will open in new
browser window



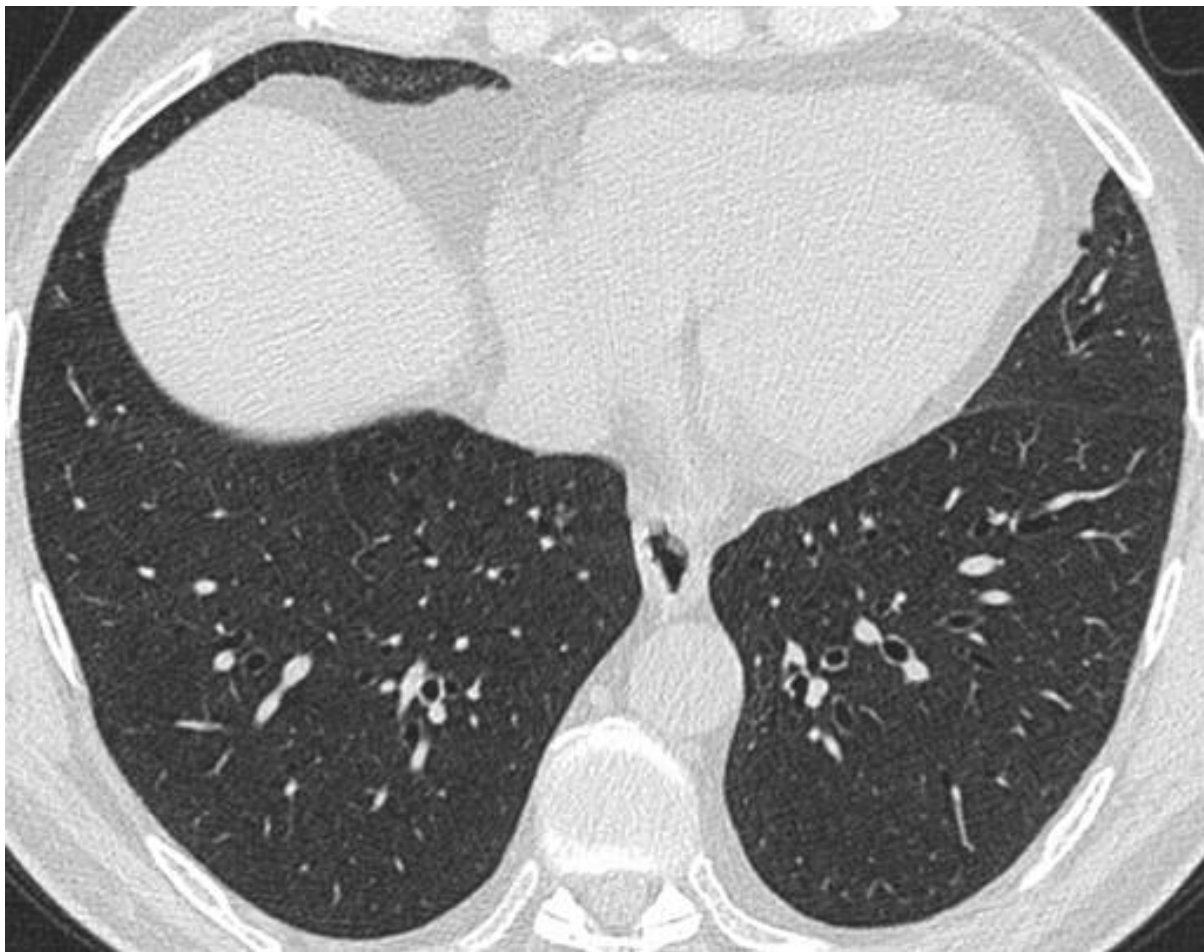
Cystic air spaces in a 76-year-old healthy man

Is it interstitial or airways?

Considerations

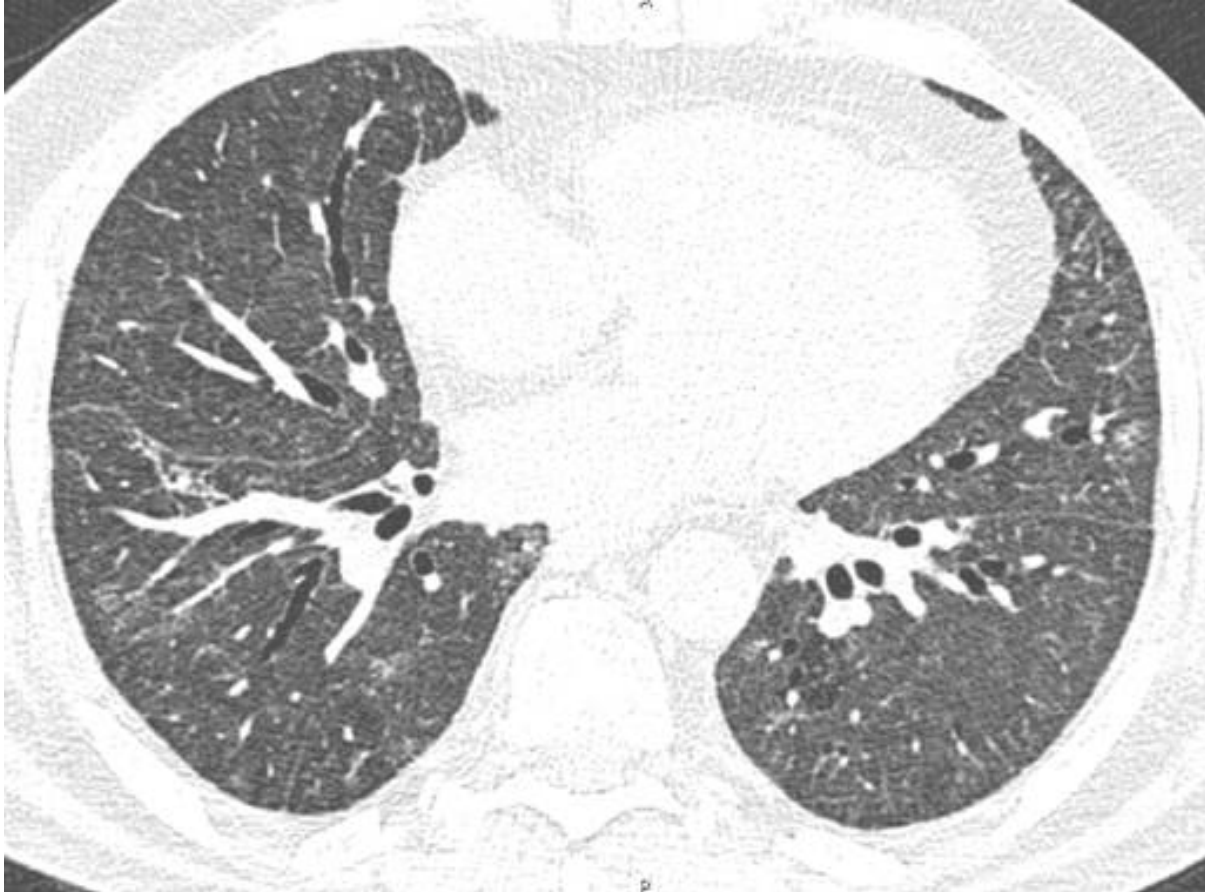Airways abnormal?

Incidental changes (minor wall thickening and/or bronchial dilatation) are seen in cigarette smokers (chronic bronchitis) as a sequel to childhood viral lower respiratory infection, in the elderly in whom bronchi are often mildly dilated and thick-walled.



Mild dilatation of the segmental and subsegmental bronchi in an elderly patient.

If the background lung is abnormal, either ground glass or reticular pattern, then it is likely that any bronchial dilatation is due to interstitial fibrosis (the phenomenon of [traction bronchiectasis](#))



Diffuse ground glass opacification with conspicuous traction bronchiectasis in the right middle lobe caused by fine retractile fibrosis.

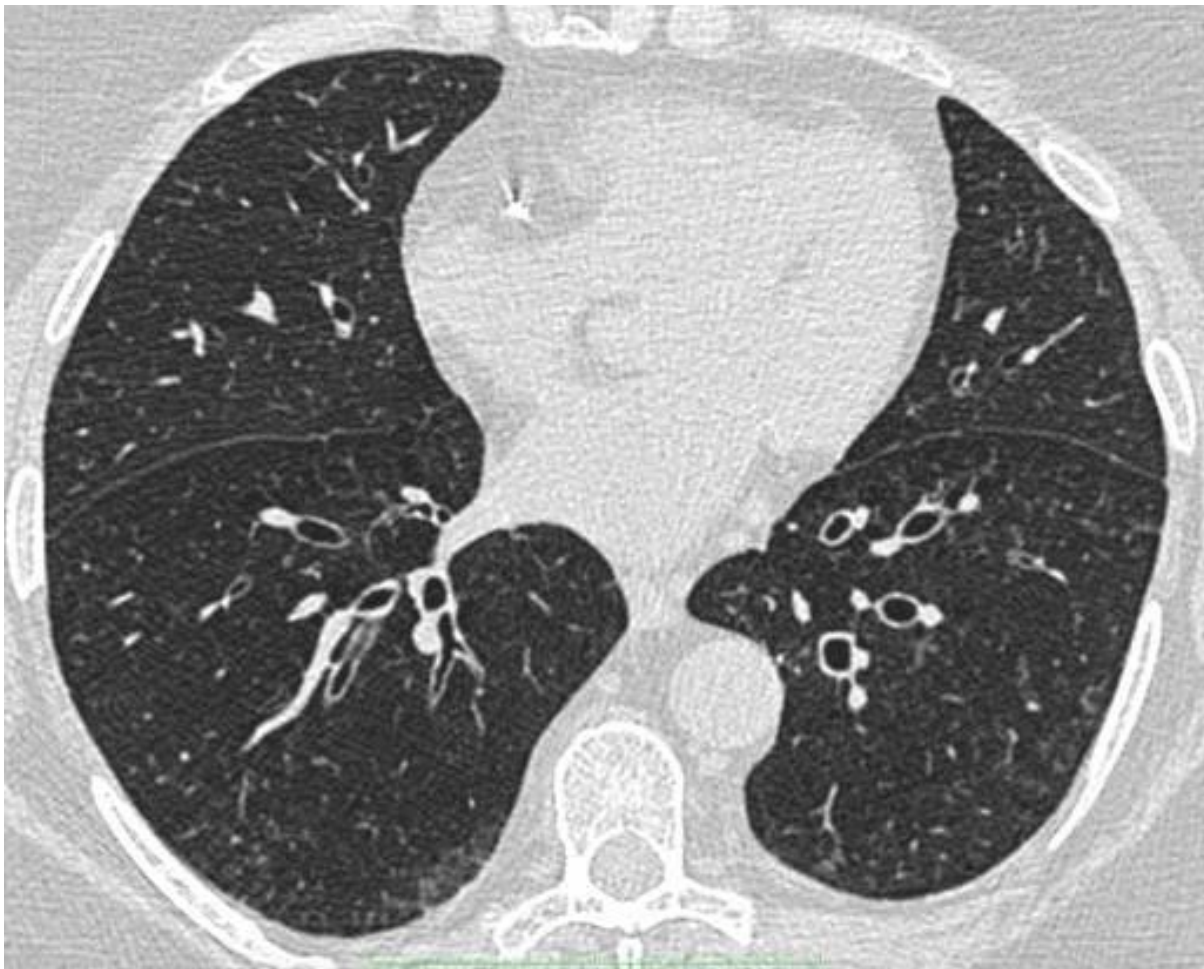Interstitial lung disease present?

Basic patterns indicating interstitial lung disease include: reticulation (including honeycombing), ground glass opacity (often with a fine granular texture): linear opacities and consolidation – although the latter reflects airspace disease, in this context it is almost invariably accompanied by interstitial abnormalities. Conversely, several diseases considered 'interstitial' have accompanying foci of consolidation.

Likely points of difficulty

In some (very few) situations both airways and interstitial abnormalities coexist, such as:

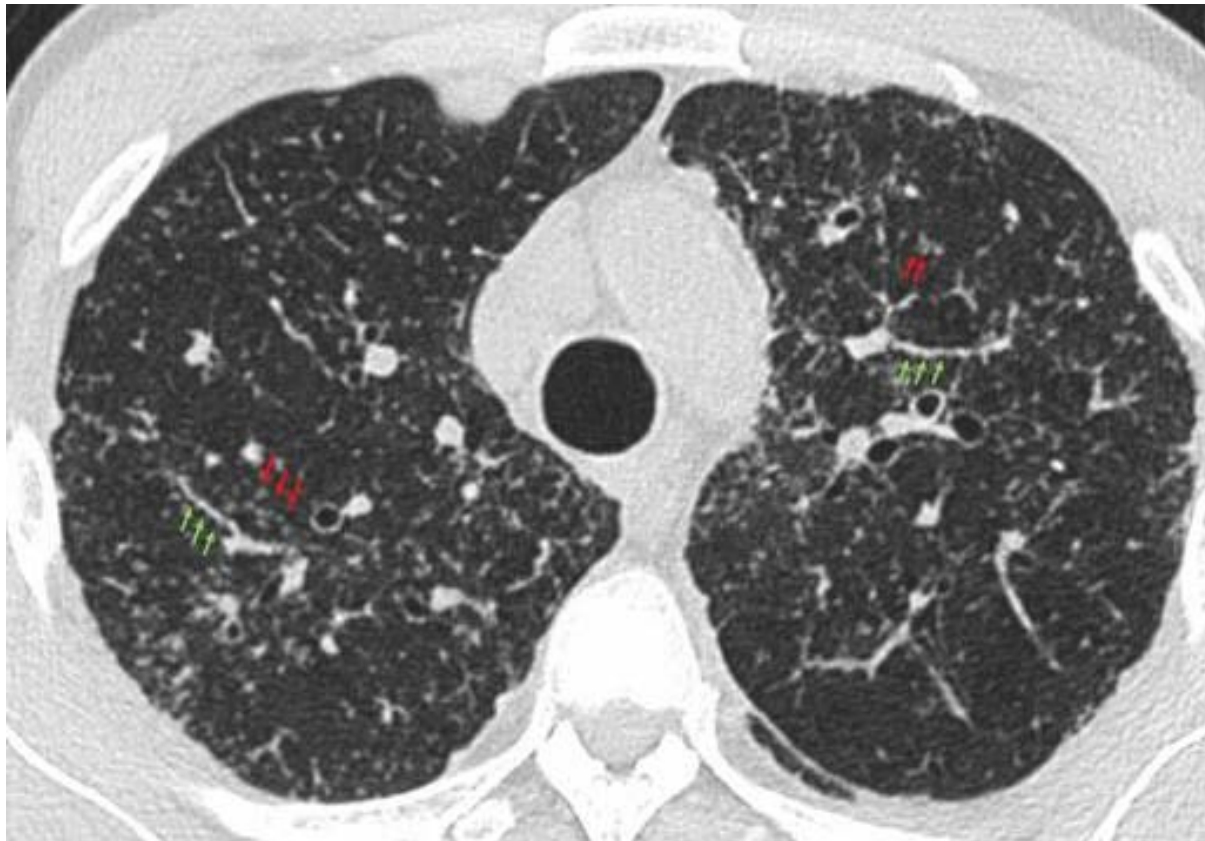
- i. connective tissue diseases (particularly rheumatoid arthritis and mixed connective tissue disease)
- ii. hypersensitivity pneumonitis (small airways involvement)
- iii. the spectrum of combined variable immunodeficiency disease/granulomatous interstitial lung disease (sarcoidosis-like) spectrum.



Connective tissue disease

Free-standing bronchiectasis in a patient with rheumatoid arthritis. There is also a subtle subpleural interstitial abnormality representing very limited cellular NSIP.

Micronodular and/or tree-in-bud pattern spectrum. Occasionally a 'small' nodular pattern may be difficult to categorise as reflecting small airways versus an interstitial disease. For example, the bronchocentric nodular pattern of sarcoidosis and the tree-in-bud pattern of exudative bronchiolitis. In the latter, the larger airways are almost invariably abnormal (with bronchial wall thickening and some degree of bronchial dilatation)



Tree-in-bud pattern

A rare example of exudative bronchiolitis manifesting as a tree-in-bud pattern (red arrows) in a patient with pulmonary sarcoidosis. Fissural nodularity due to pleural granulomas are present (green arrows). Tree-in-bud is not seen in patients with sarcoidosis and therefore, when present, should alert the radiologist to the presence of exudative bronchiolitis.

If ILD, is it predominantly fibrosing?

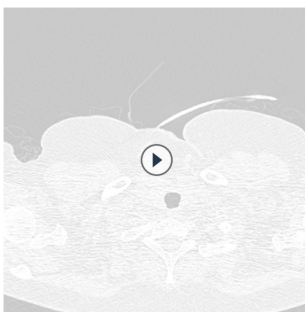
This is a crucial step. Firstly, because the differential diagnosis of fibrosing lung disease is very short: in practice no more than 5 entities (many textbooks list >10 conditions but this is misleading). Secondly, fibrosing lung disease accounts for >80% of cases of diffuse lung disease encountered in most practices, and these entities have very different clinical significance.

Considerations

The individual [HRCT signs of fibrosing lung disease](#) are not entirely reliable but in combination are reasonably specific. Serial change (chest radiography and HRCT), if available, will often increase the certainty that the basic abnormality is a fibrosing lung disease.

Likely points of difficulty

If disease is very limited (e.g. minor subpleural changes), the HRCT signs of established fibrosis may not be present.



Early cellular/fibrotic NSIP

Subtle subpleural ground glass opacification in a patient with early and limited cellular NSIP. There are no features of fibrosis.

In cases of extensive centrilobular and paraseptal emphysema, it may be difficult to decide whether there is some admixed interstitial fibrosis and, thus, whether or not the dominant pattern is a fibrosing lung disease.



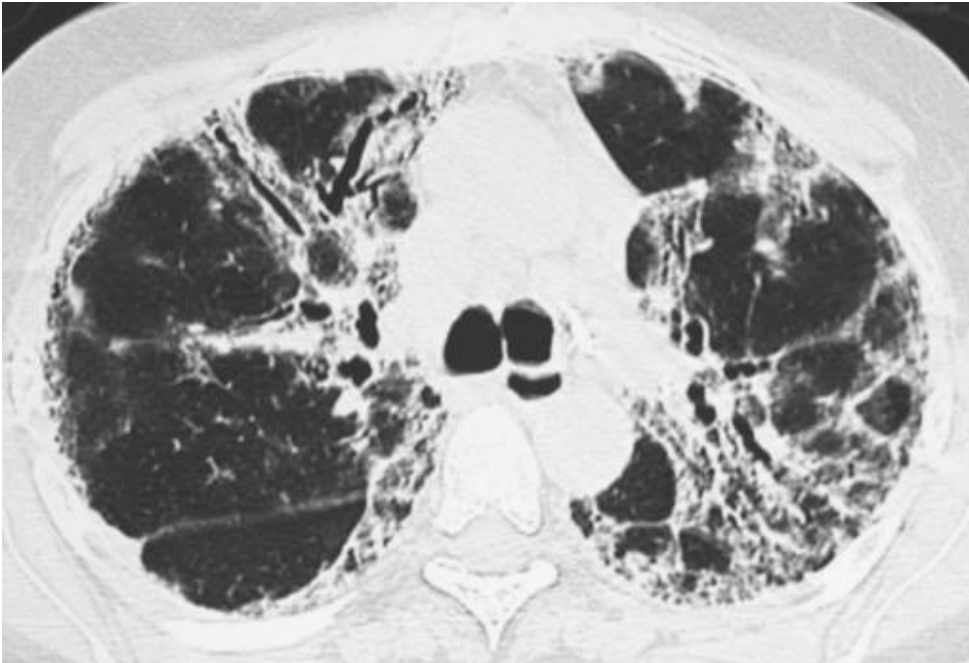
Extensive centrilobular emphysema

Extensive centrilobular emphysema with some paraseptal emphysema.

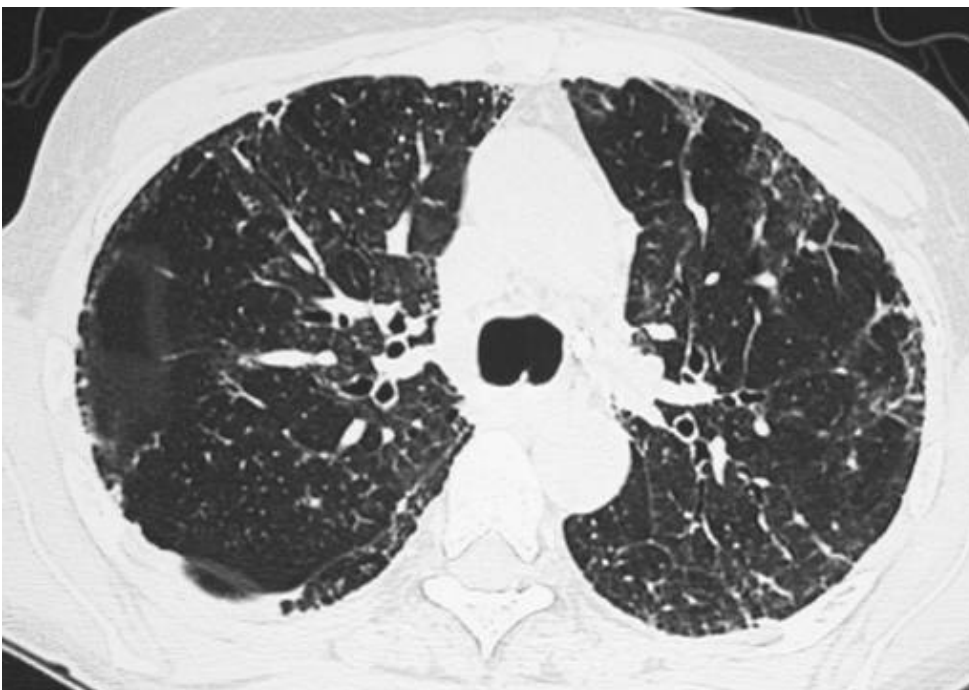
In some cases of diffuse alveolar damage/organising pneumonia HRCT signs may closely resemble those of established fibrosing lung disease (e.g. nitrofurantoin-induced organising pneumonia).

Organising pneumonia

1/2 Distorted and dilated airways within abnormal lung looking like traction bronchiectasis



2/2 After withdrawal of nitrofurantoin and a period of steroid treatment, these appearances have largely resolved.



The HRCT signs of fibrosing lung disease

Established fibrosis in the lungs has several different HRCT manifestations ranging from delicate ground glass opacification to dense consolidation. The specificity of some of these signs for a fibrotic process can be low (e.g. a reticular pattern does not necessarily denote pulmonary fibrosis). In attempting to establish whether a chronic diffuse lung disease is present the following three signs are key:

- Honeycomb pattern
- Traction bronchiectasis
- Volume loss

These three signs do not have equal weight (lobar volume loss, by itself, is entirely non-specific). However, when all three signs can be identified the presence of a predominantly fibrosing lung disease is near certain.



[Fleischner Glossary](#)

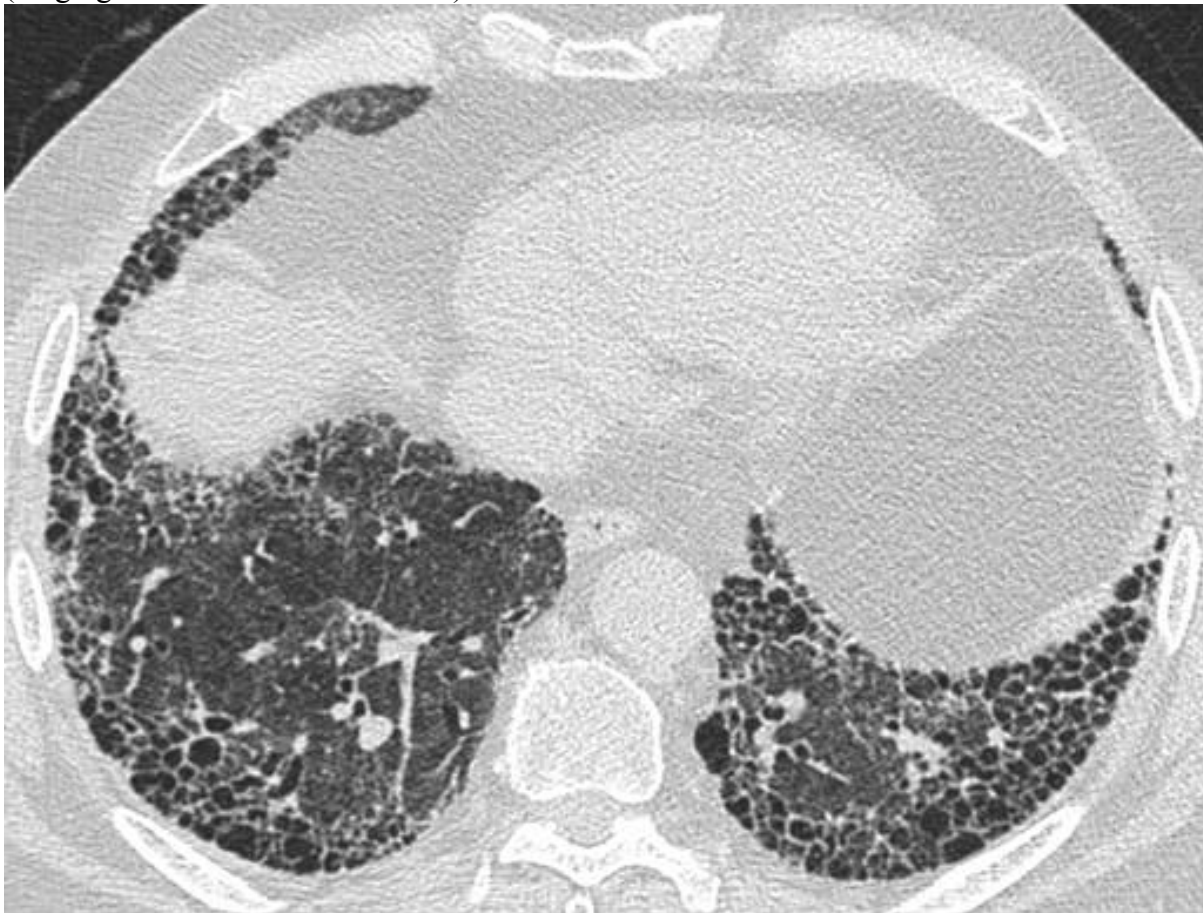Will open in new
browser window

Reliability of individual HRCT signs of fibrotic lung disease

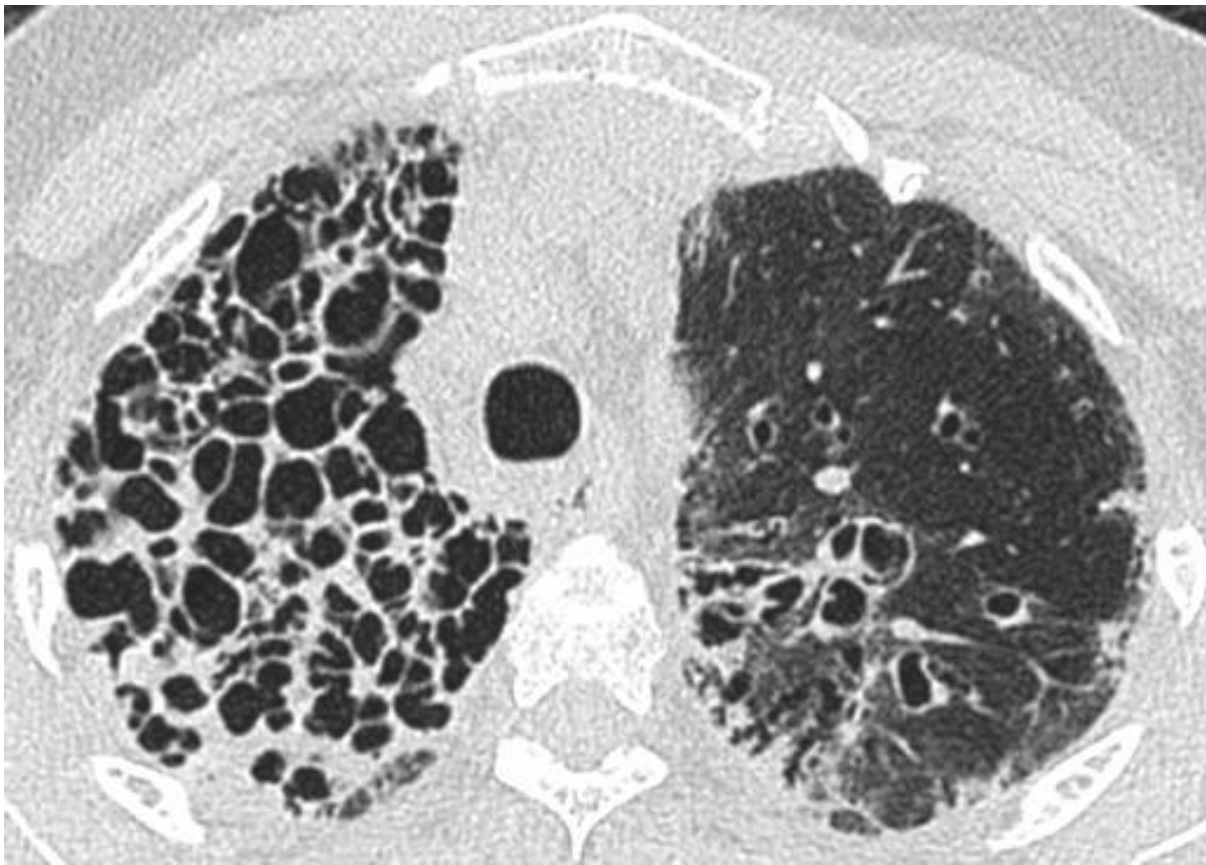
| | |
|-------------------------|---------|
| Honeycomb pattern | ★ ★ ★ ★ |
| Traction bronchiectasis | ★ ★ ★ ★ |
| Volume loss | ★ ★ ★ ★ |
| All three signs present | ★ ★ ★ ★ |

Honeycombing

Honeycombing is a cardinal sign of pulmonary fibrosis, and its accurate identification is important (largely because it is the key feature of classical usual interstitial pneumonia) but sometimes difficult. Definitions vary but can be summarised as clustered cystic airspaces, with conspicuous walls, and of roughly uniform size (ranging from 0.3–2.5 cm diameter).



1/1 Small honeycomb cysts



2/2 Large honeycomb cysts

Areas of single and multiple layers of cysts often coexist. It is important to remember that below a certain size (~2 mm diameter) honeycomb cysts will not be recognisable as such on HRCT because of the partial volume effect – this means that air density (black) within these tiny cysts, which is a key distinguishing feature between honeycombing and a more generic reticular pattern, cannot be identified. It should also be appreciated that microscopic honeycombing, a sign sought by pathologists in lung biopsies, may be present within fibrotic lung but invisible on HRCT because it is below the resolution of the technique.

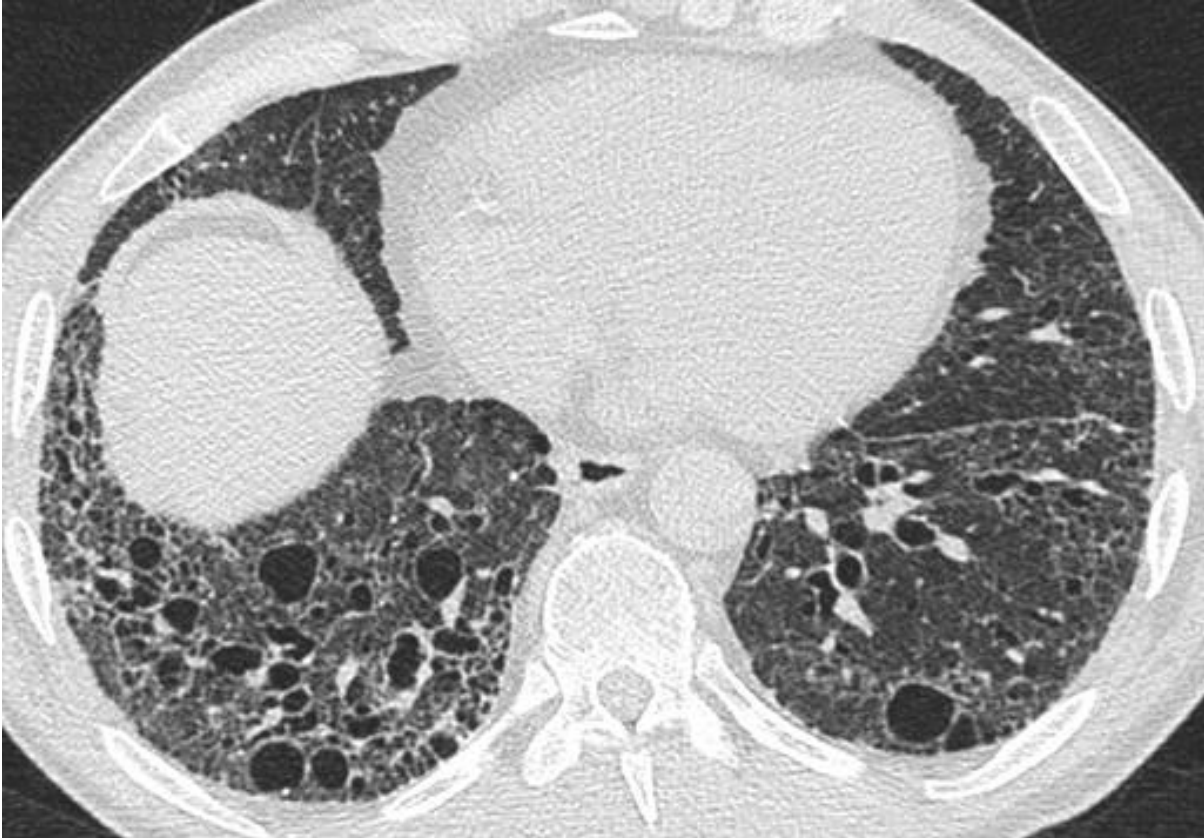There are a few important mimics of a honeycomb pattern, and inter-observer disagreement for this sign is quite high. The following situations are responsible for most instances of false positive identification of honeycombing:



[Further Reading](#)

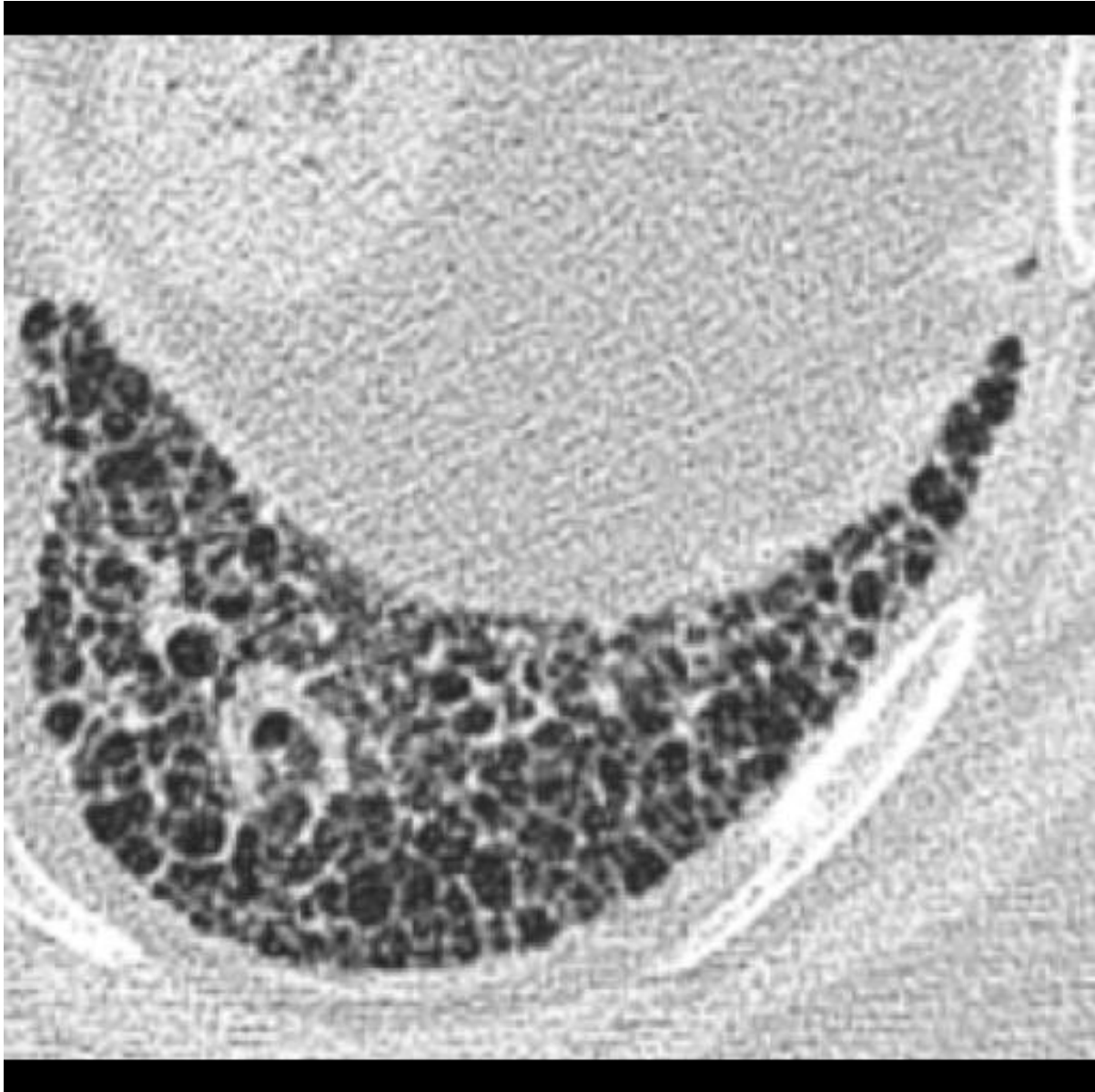
Will open in new browser window

Centrilobular/paraseptal emphysema superimposed on fine interstitial fibrosis (usually NSIP) - look for evidence of free-standing emphysema in the upper lobes, particularly the presence of paraseptal emphysema along the mediastinal surfaces at the lung apices

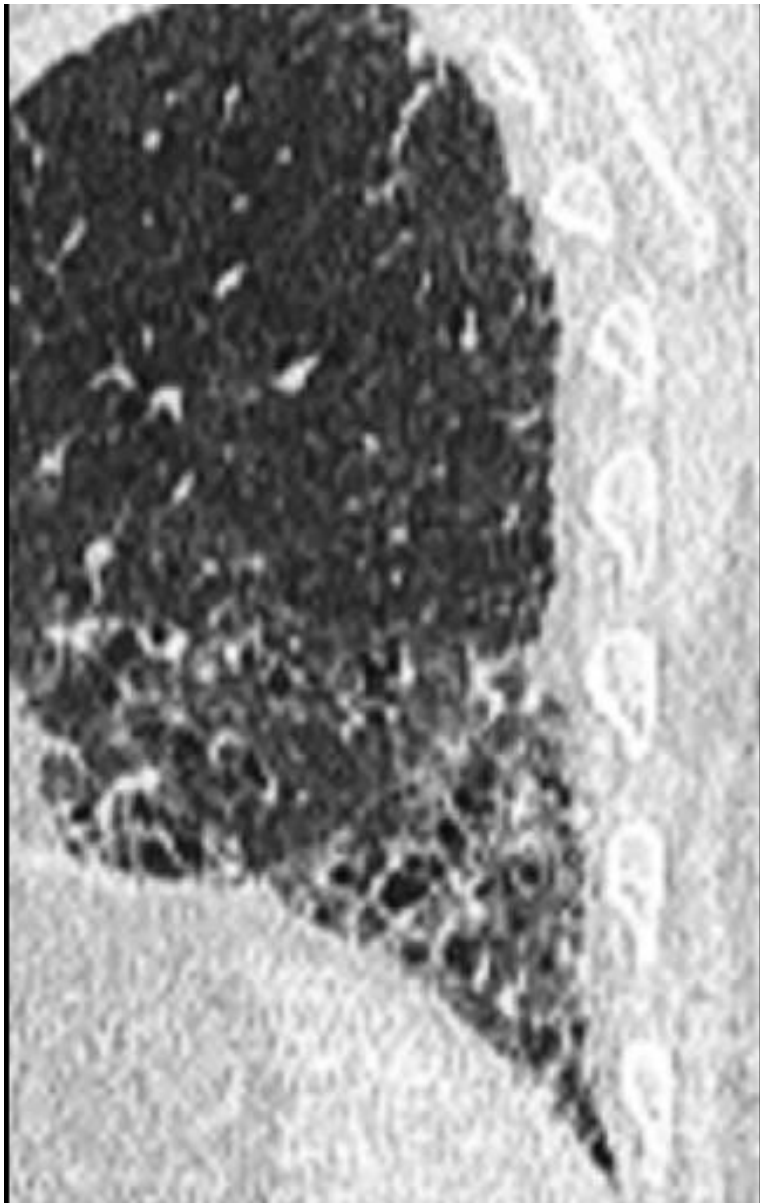


Centrilobular/paraseptal emphysema superimposed on fine interstitial fibrosis – this is not a honeycomb pattern

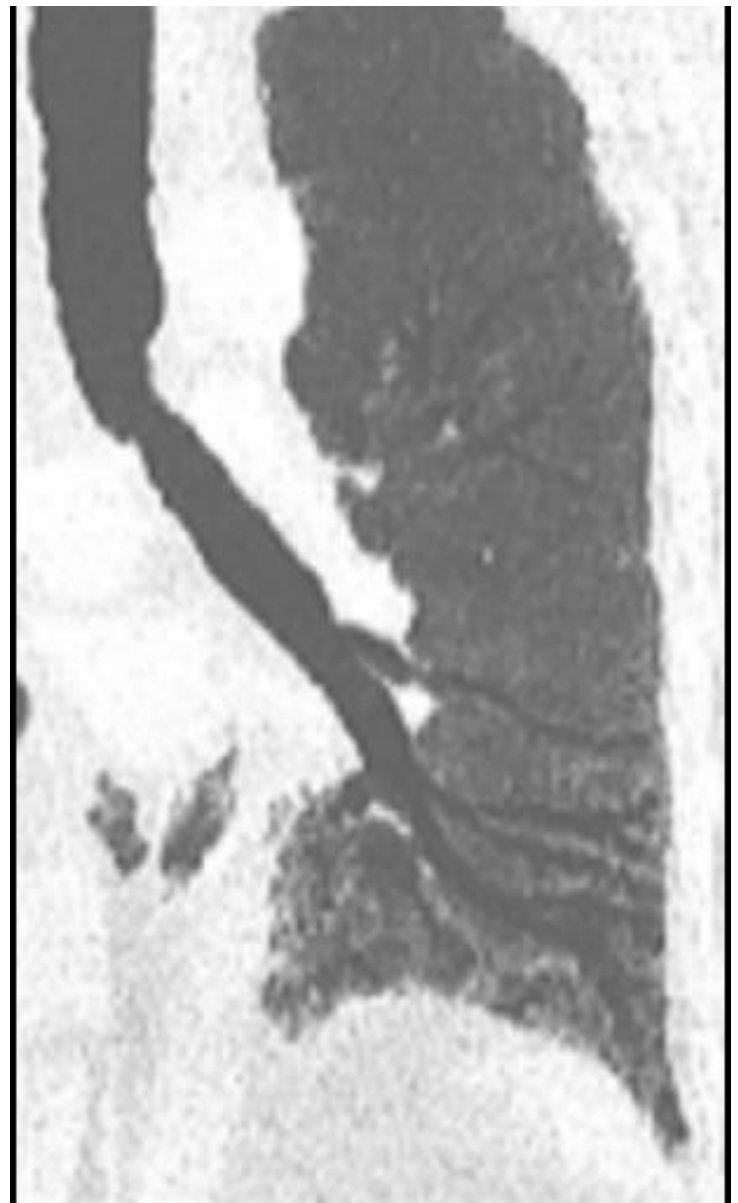
Traction bronchiolectasis – look to see if you can make the 'honeycomb cysts' join up (in the lower lobes more easily done on coronal images which would denote traction bronchiectasis rather than honeycombing).



a) Cropped axial image demonstrating multilayered small cysts resulting in a pattern of honeycombing

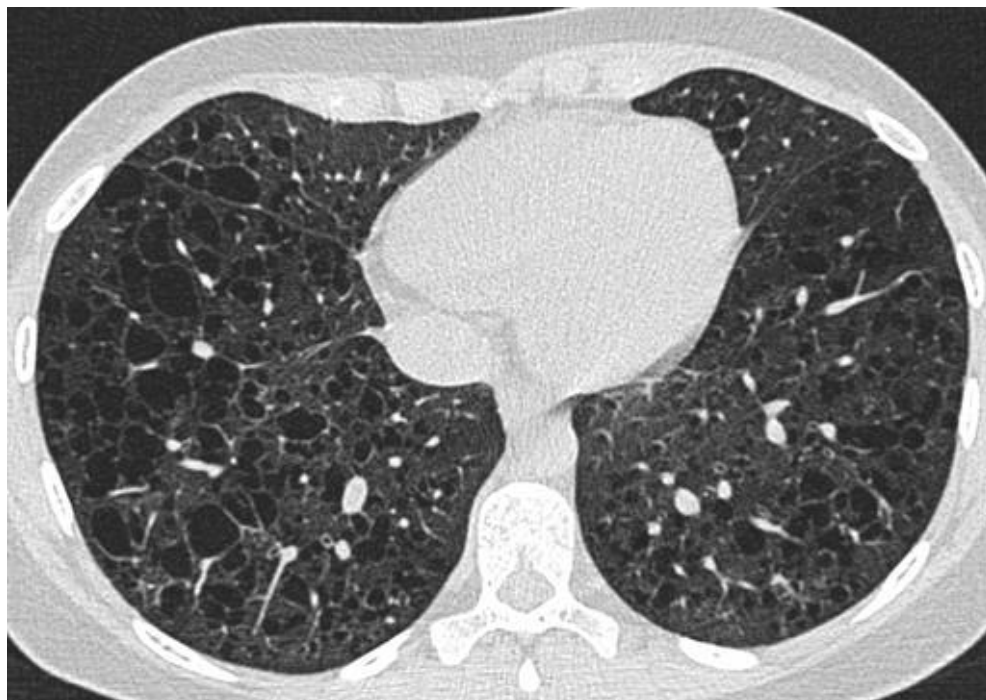

b) Coronal reformat of (a) again demonstrated multilayered subpleural cysts suggestive of honeycombing



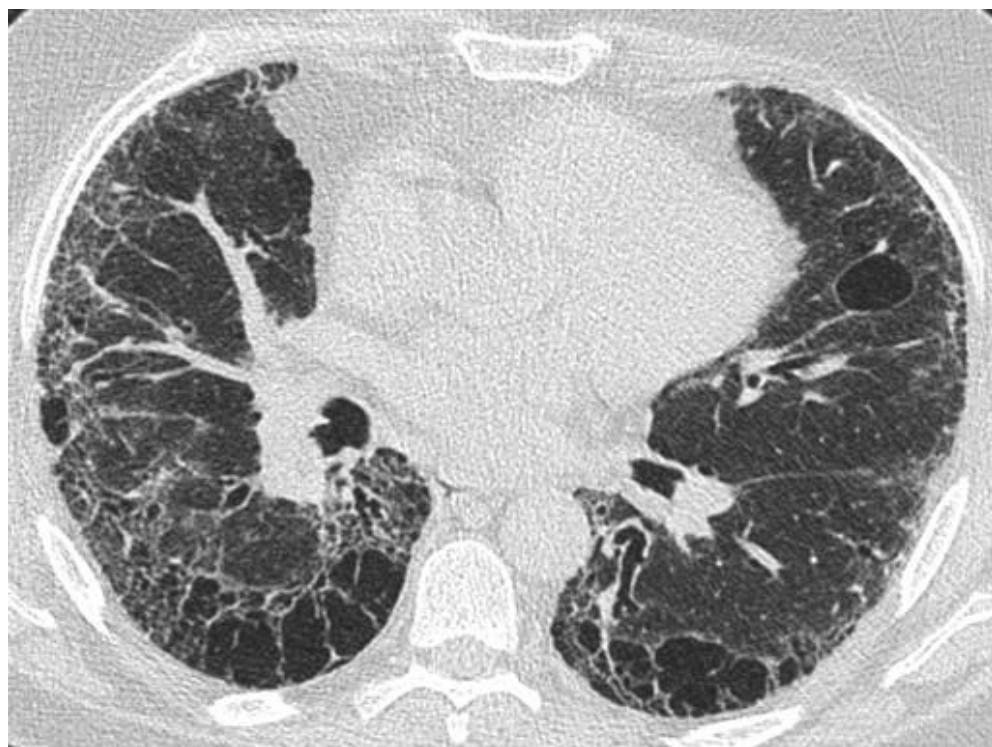MinIP reconstruction demonstrating multiple areas of traction bronchiectasis contributing to the apparent honeycomb pattern in (a) and (b)

Other cystic conditions – not usually confused with the honeycombing of UIP (because of marked distribution differences).



An example of Langerhans cell histiocytosis – this pattern of cystic lung disease was much more pronounced in the upper lobes.

Subpleural honeycombing admixed with paraseptal emphysema can modify typical honeycombing appearances resulting in subpleural parenchymal destruction.

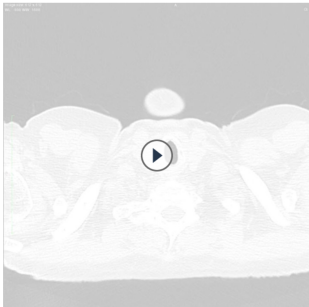


Traction bronchiectasis

An almost invariable accompaniment to interstitial fibrosis, which may not be conspicuous if:

- there is severe honeycombing or mixed fibrosis/emphysema), or
- the interstitial fibrosis is of very limited extent.

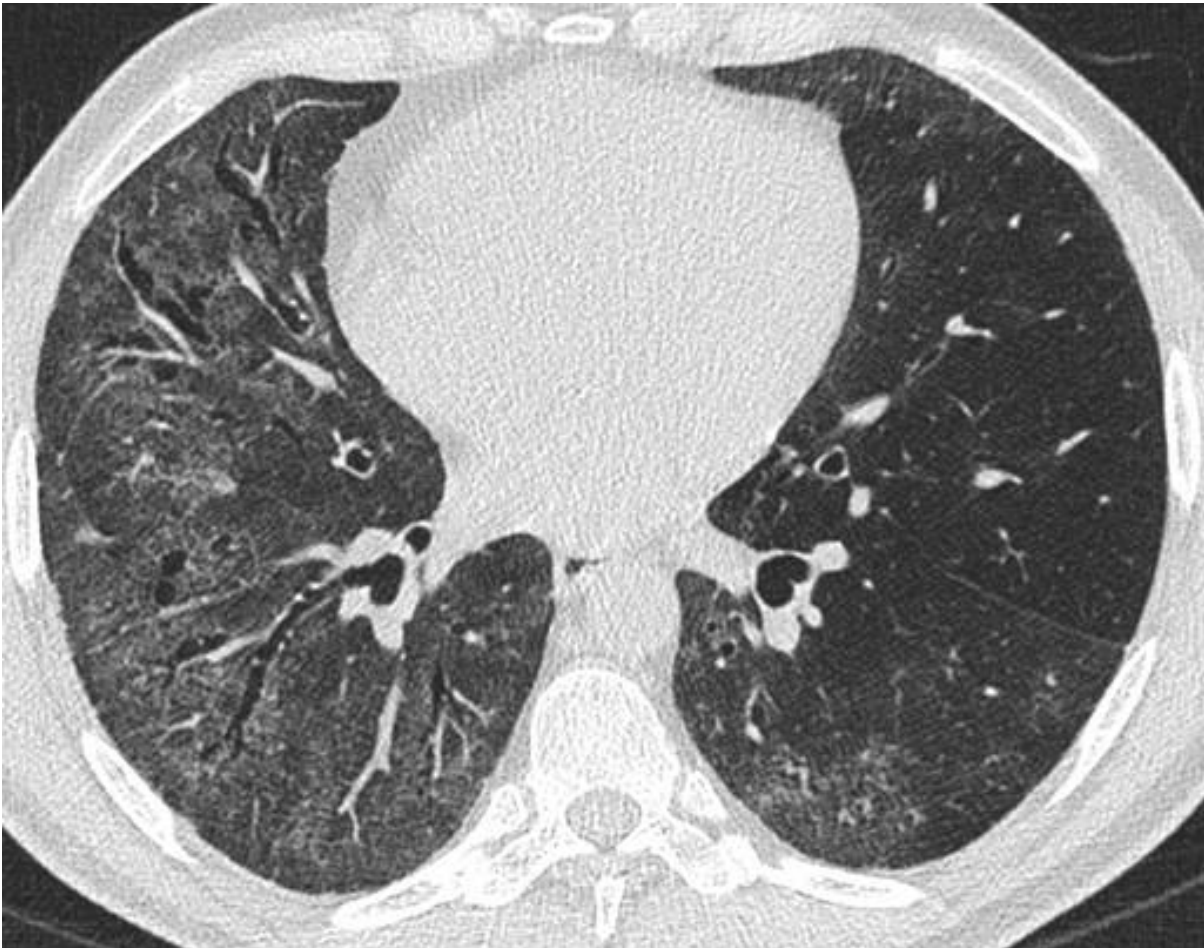
The irregular ('wrinkly') dilatation of the bronchi and bronchioles is caused by the surrounding retractile fibrosis (which itself is manifested as either reticulation or ground glass opacity – the background lung is always abnormal).



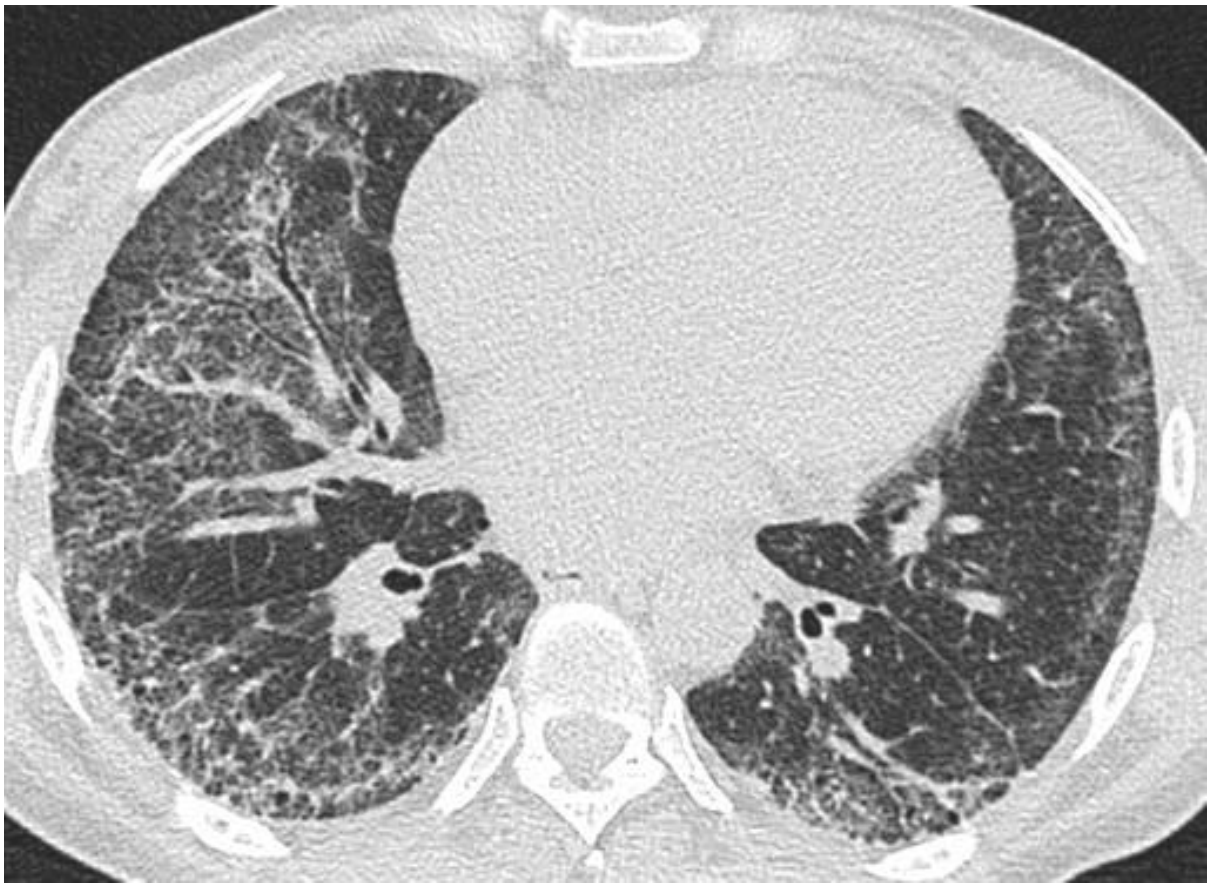Traction bronchiectasis

Making the distinction between traction bronchiectasis and honeycombing can be challenging. In this case, many of the subpleural cysts are connected to airways indicating the presence of traction bronchiectasis.

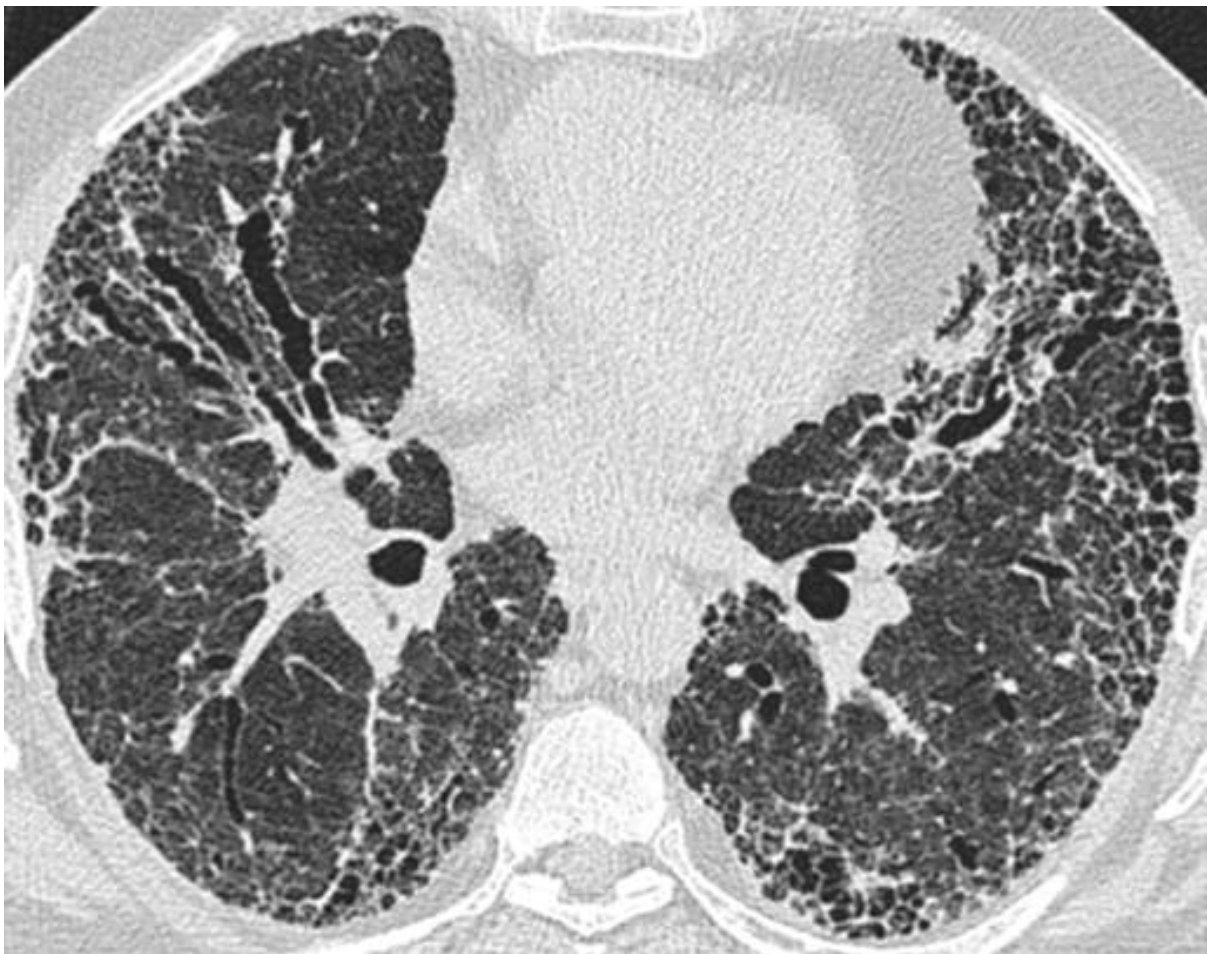The severity of this phenomenon ranges from subtle to very obvious (and like honeycombing it has prognostic, as well as diagnostic, significance).



1/3 Moderately severe traction bronchiectasis manifesting as non-tapering airways extending into the lung periphery caused by fine retractile ground glass fibrosis.



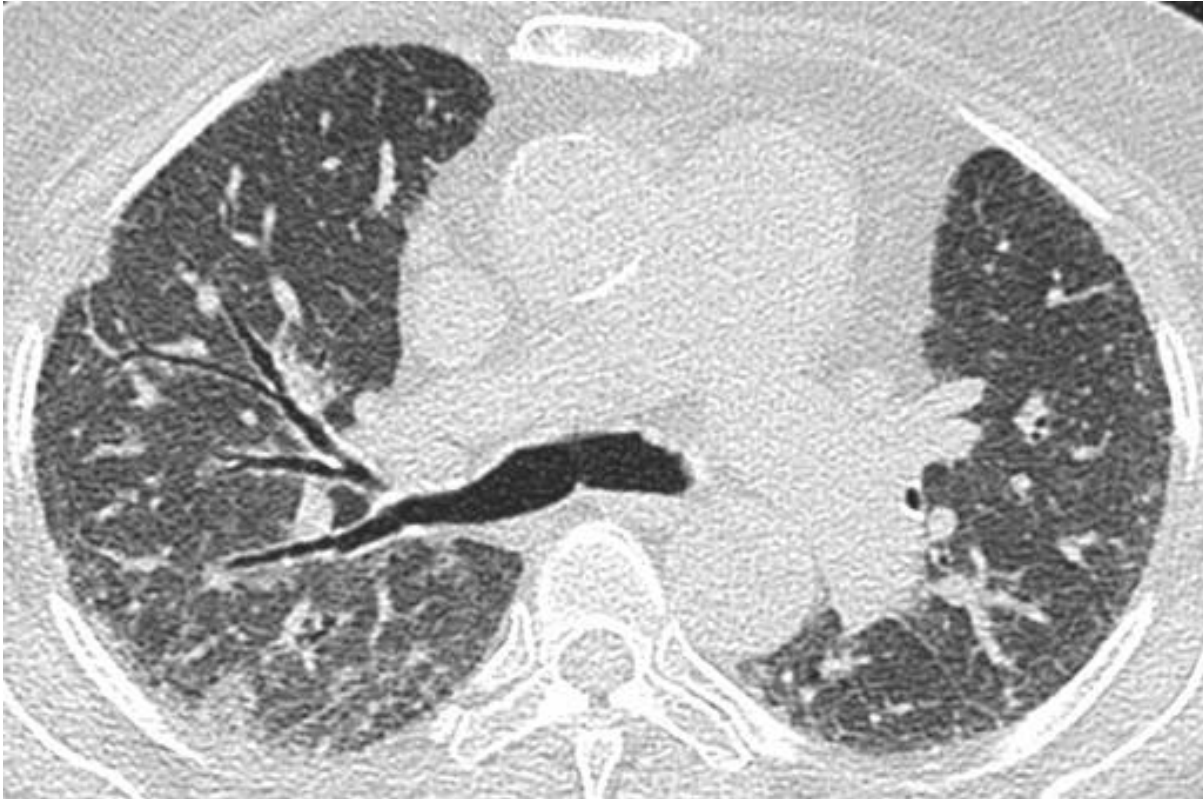2/3 Mild traction bronchiectasis within ground glass and reticular opacities.



3/3 Severe traction bronchiectasis within the right middle lobe and lingular segment.

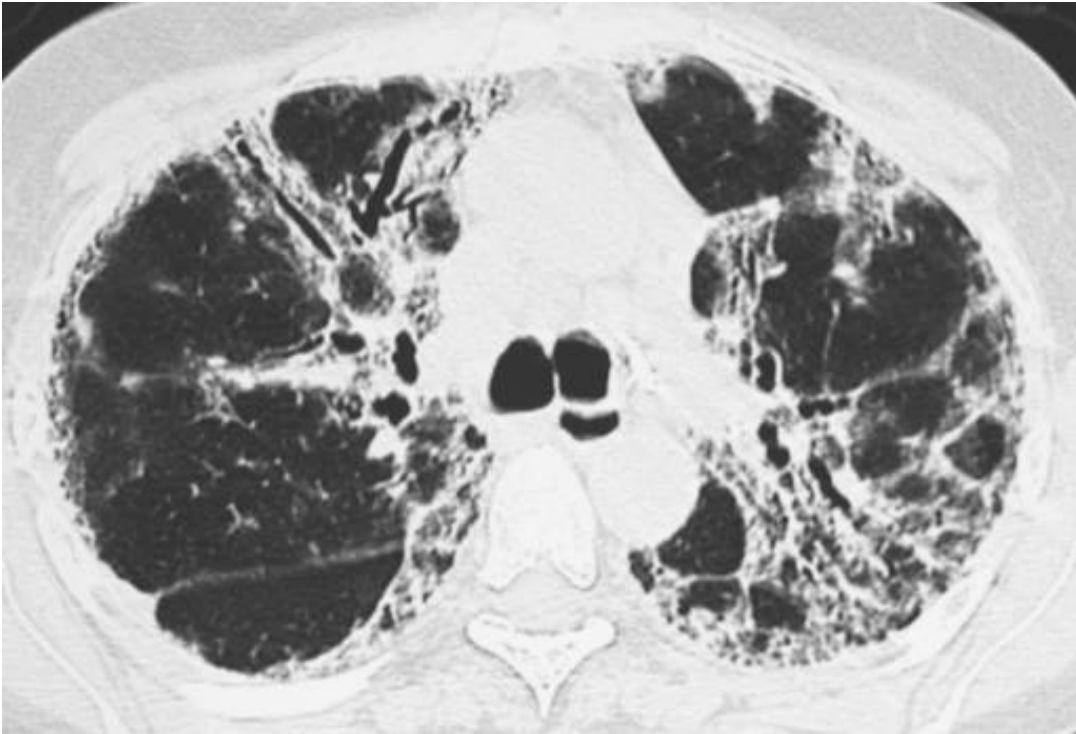
There is also significant observer variation for traction bronchiectasis, and the usual difficulties are:

- a) distinguishing traction bronchiectasis from honeycombing
- b) over-calling traction bronchiectasis when there is widespread ground glass opacification – in this situation air-filled (back) bronchi are very conspicuous (but are not actually dilated).

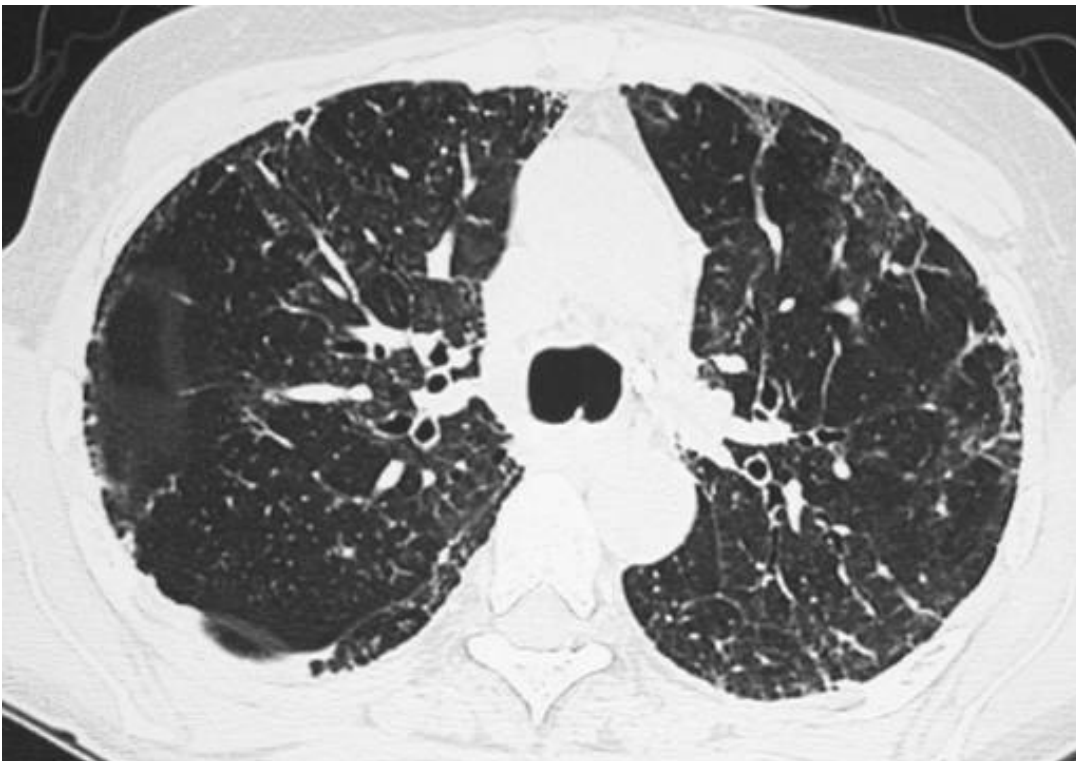

Ground glass opacification making the airways conspicuous but not definitively dilated.

c) in acute and subacute inflammatory diseases (notably organising pneumonia) bronchi may become reversibly dilated



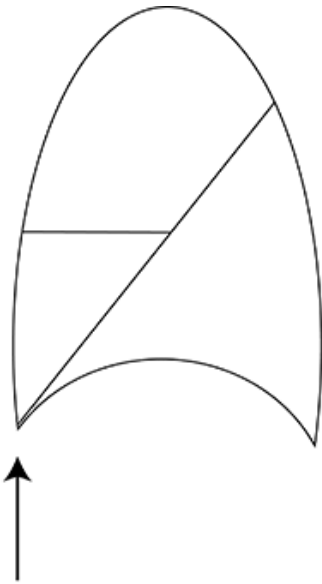
1/2 Distorted and dilated airways within abnormal lung looking like traction bronchiectasis



2/2 After withdrawal of nitrofurantoin and a period of steroid treatment these appearances have largely resolved.

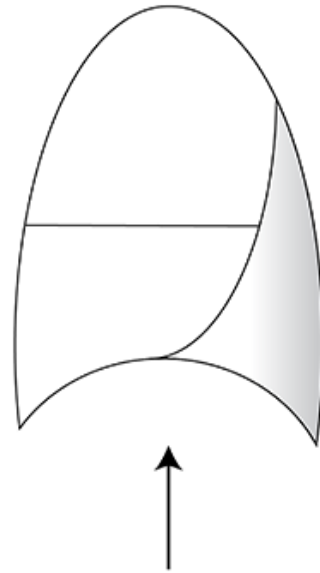
Volume loss

In the context of fibrosing lung disease, most of which are lower zone predominant, the detection of volume loss depends on identifying the abnormal position of the lower oblique fissures. In the normal state the oblique fissures reach the anterior surface of the diaphragm.



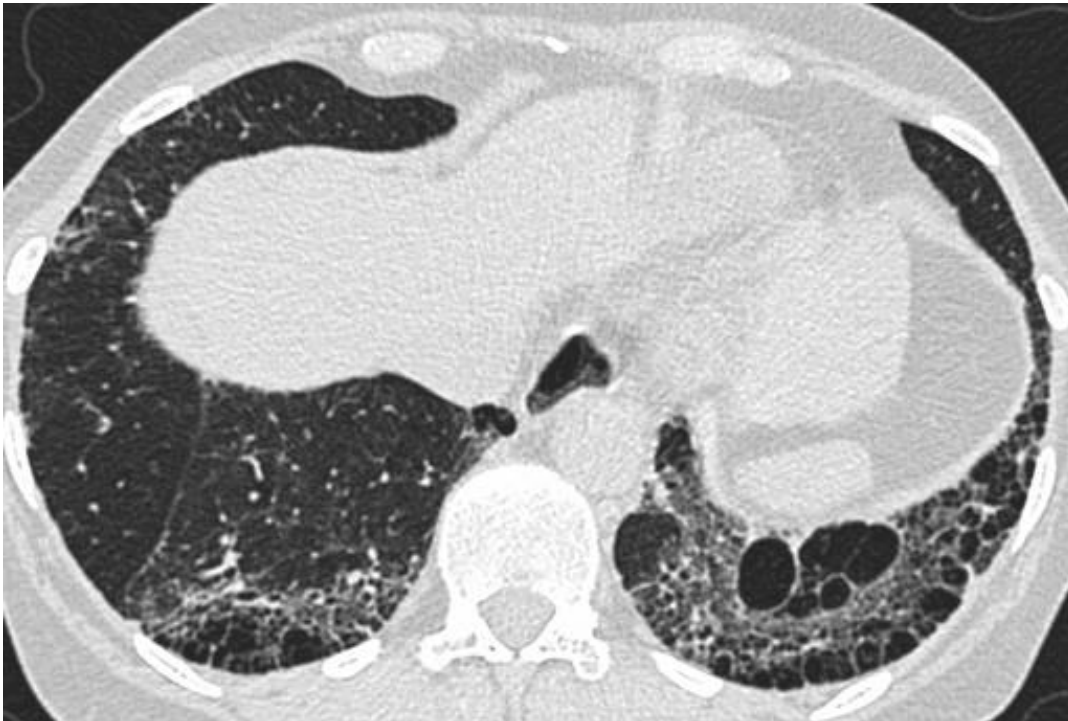
Normal position of the oblique fissure (arrow, anterior on diaphragm)

Lateral chest radiograph



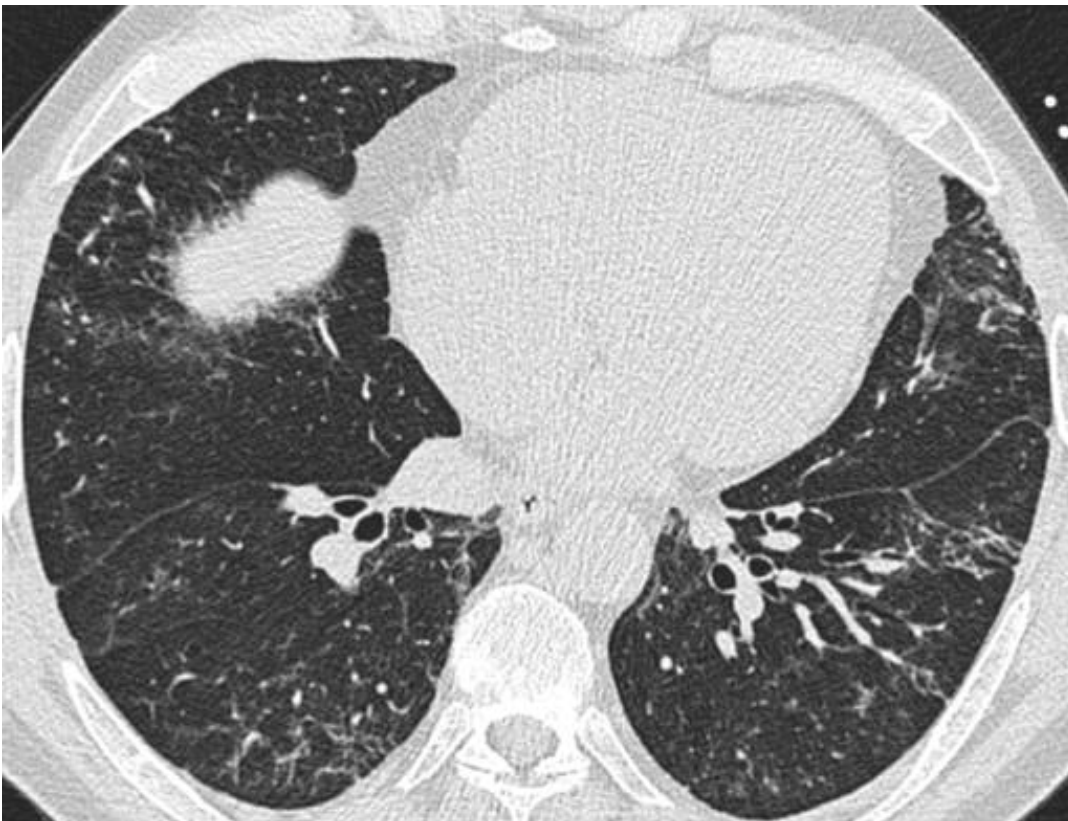Volume loss associated with fibrosis causes posterior retraction of the oblique fissure (arrow)

As the interstitial fibrosis causes progressive contraction of the lower lobes, so the oblique fissures are drawn posteriorly and thus make contact with the diaphragm more posteriorly.



Volume loss in lower lobes with posterior displacement of the oblique fissures.

Volume loss is a useful corroborative sign of fibrosing lung disease when honeycombing is absent and traction bronchiectasis is equivocal.



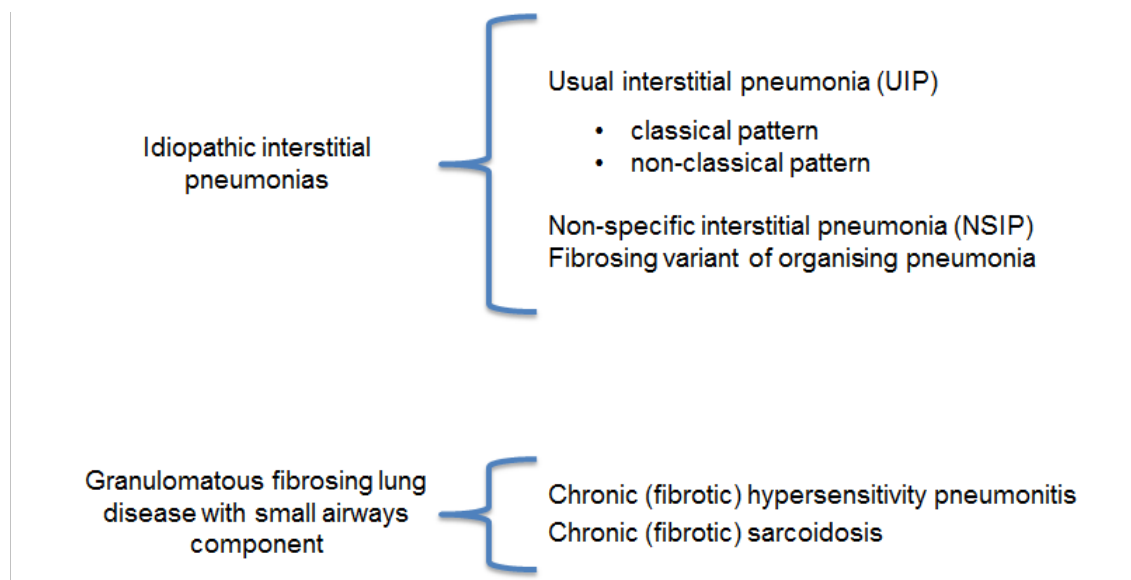
Volume loss in lower lobes with posterior displacement of the oblique fissures.

Which fibrosing lung disease?

Having arrived at the conclusion that the HRCT appearances are those of a diffuse fibrosing lung disease, the next and last stage is to refine the short differential diagnosis of five conditions:

- Usual interstitial pneumonia (UIP)
 - classical
 - non-classical patterns
- Non-specific interstitial pneumonia (NSIP)
- Fibrosing variant of organising pneumonia
- Chronic (fibrotic) hypersensitivity pneumonitis
- Chronic (fibrotic) sarcoidosis

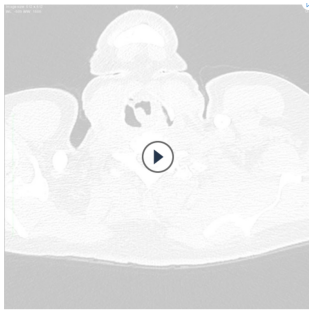
Conceptually, it may be useful to group these conditions into two categories:



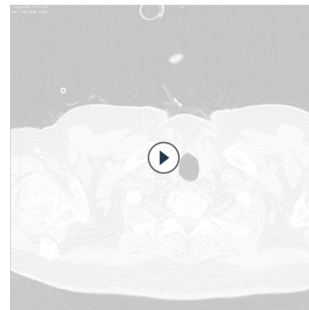
First step: Is the fibrosis a classical UIP pattern?

Does the HRCT show fibrosis that is:

- Subpleural
- Predominantly lower zone (basal)
- Honeycomb pattern



Classical UIP

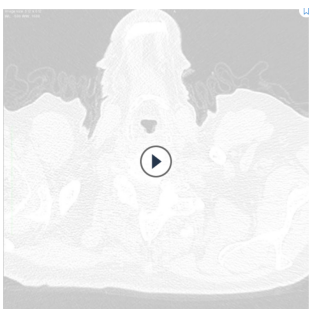


Only if these three conditions are unequivocally met can a confident HRCT diagnosis of UIP be made; crucially, honeycombing (not merely a reticular pattern) needs to be present to allow the term “definite UIP” to be used.

Second step: If not classical UIP, then what?

There is increasing evidence that the older the patient, the more likely that a fibrosing lung disease will be UIP. Clinical experience suggests that this is true, i.e. elderly patients with fibrosing lung disease without honeycombing are likely, in the absence of features that point to an alternative diagnosis, to have IPF/UIP.¹⁻³

1. Fell et al. Am J Respir Crit Care Med 2010;181:832-837
2. Salisbury et al. Respir Med 2016;118:88-89
3. Brownell et al. Thorax 2017;72:424-429



Non-classical UIP

Categories of “certainty” around a HRCT diagnosis of a UIP pattern are contained in a (controversial) table from the 2011 ATS/ERS statement

ATS/ERS/JRS/ALAT STATEMENT IDIOPATHIC PULMONARY FIBROSIS: EVIDENCE-BASED GUIDELINES FOR DIAGNOSIS AND MANAGEMENT

HIGH-RESOLUTION COMPUTED TOMOGRAPHY CRITERIA FOR UIP PATTERN

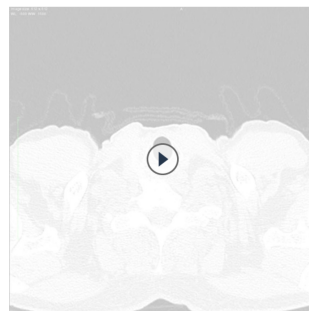
| UIP Pattern (all four features) | Possible UIP Pattern (all three features) | Inconsistent with UIP Pattern (any of the seven features) |
|---|---|---|
| <ul style="list-style-type: none"> • Subpleural, basal predominance • Reticular abnormality • Honeycombing with or without traction bronchiectasis • Absence of features listed as inconsistent with UIP pattern (see third column) | <ul style="list-style-type: none"> • Subpleural, basal predominance • Reticular abnormality • Absence of features listed as inconsistent with UIP pattern (see third column) | <ul style="list-style-type: none"> • Upper or mid-lung predominance • Peribronchovascular predominance • Extensive ground glass abnormality (extent > reticular abnormality) • Profuse micronodules (bilateral, predominantly upper lobes) • Discrete cysts (multiple, bilateral, away from areas of honeycombing) • Diffuse mosaic attenuation/air-trapping (bilateral, in three or more lobes) • Consolidation in bronchopulmonary segment(s)/lobe(s) |

UIP = usual interstitial pneumonia

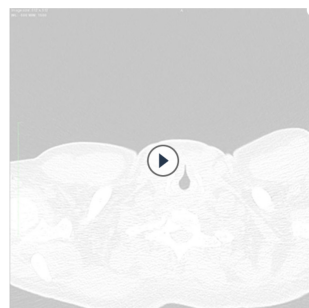
A general rule, derived from a single paper,¹ is that the older the patient the more likely that a fibrosing lung disease will be UIP; clinical experience suggests that this is usually true, i.e. elderly patients with fibrosing lung disease without honeycombing are likely, in the absence of any features that point to an alternative diagnosis, to have IPF/UIP.

1. Fell et al. Am J Respir Crit Care Med 2010;181:832-837

The full spectrum of “non-classical” HRCT manifestations of UIP are not well documented but are probably wider than generally appreciated - a brief cameo statement of non-classical UIP appearances might be “NSIP-like with no unexpected features”.



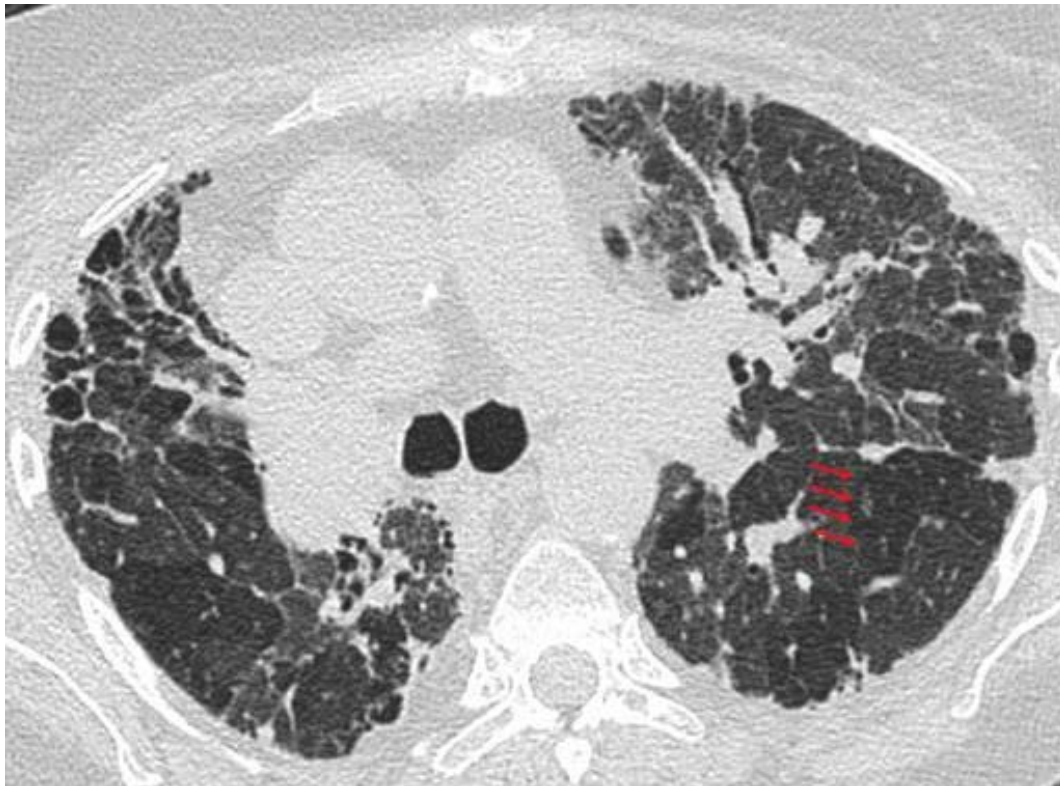UIP/IPF in a 74-year-old man



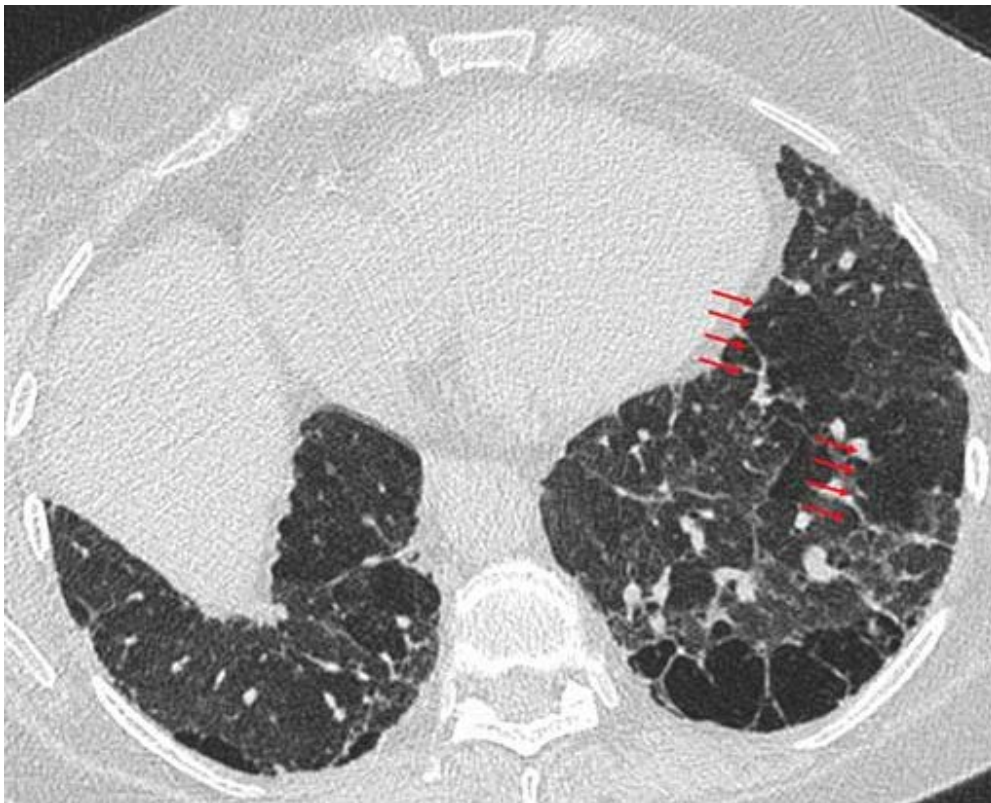
Non-classical UIP pattern

Features that should alert to the possibility that the fibrosing lung disease is **NOT** UIP/IPF are (in descending order of importance):

- i. Lobules of decreased attenuation** in areas of relatively spared (non-fibrotic) lung; usually not very profuse but >4 or 5. If present, these lobules are suggestive of chronic hypersensitivity pneumonitis (or, less frequently, sarcoidosis).
- ii. Non-basal distribution of the fibrosis.** If the fibrosis is clearly perihilar or concentrated in the upper lobes, UIP is unlikely (but note that UIP may be occasionally relatively uniformly distributed with no particular zonal distribution, particularly when it is advanced).

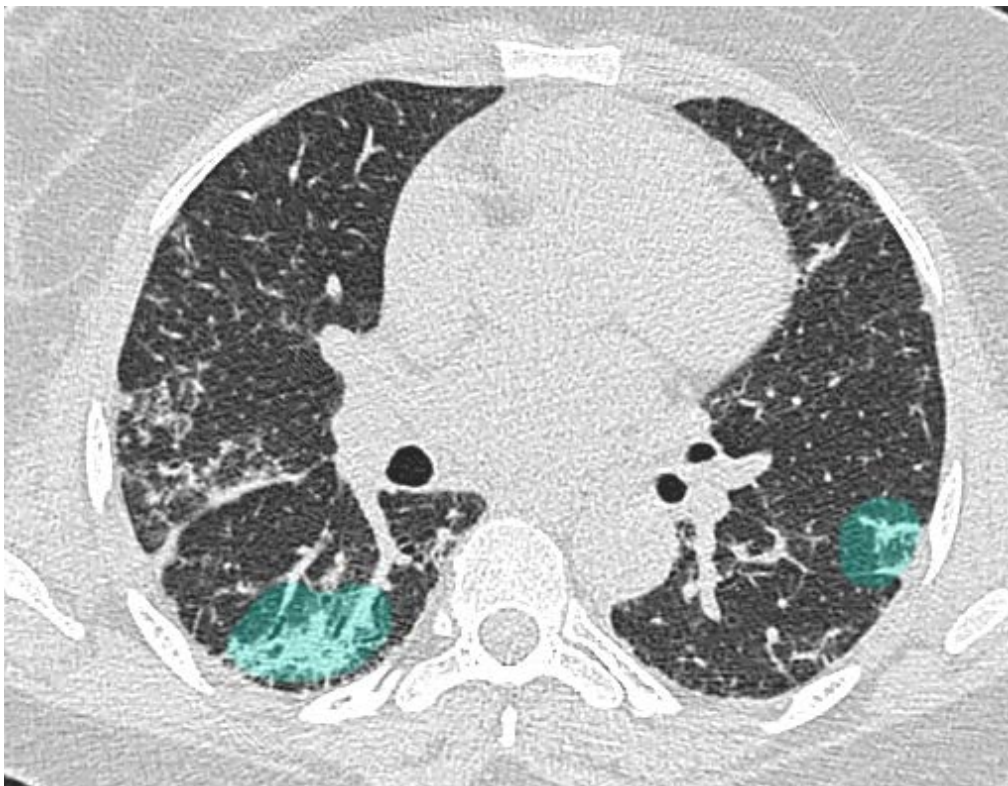


1/2 Lobules of decreased attenuation



2/2 Lobules of decreased attenuation

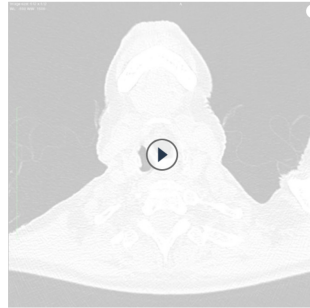
iii. Foci of consolidation are not a feature of pure UIP but very dense, usually peripheral, fibrosis may be manifest as small areas of consolidation. A more obvious consolidating component raises the possibility of a fibrosing organising pneumonia.



Foci of consolidation

iv. Nodules - of any size, density and distribution - are not a feature of UIP and an alternative explanation for their presence should be sought (e.g. the indistinct low attenuation centrilobular nodules of a subacute hypersensitivity pneumonitis -although these are only rarely encountered in patients with chronic fibrotic hypersensitivity pneumonitis).

Subpleural irregularity with limited peripheral consolidation in the upper lobes may reflect a component of pleuroparenchymal fibroelastosis which rarely accompanies a UIP pattern.



Pleuroparenchymal fibroelastosis

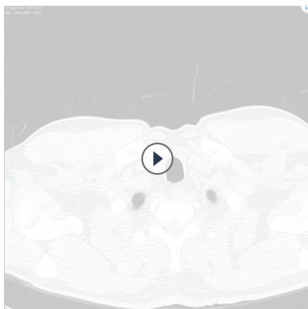
HRCT pointers to non-UIP fibrosing lung disease

Non-specific interstitial pneumonia (NSIP)

The early CT literature about NSIP is very confusing and suggests that the HRCT patterns of NSIP are variable and entirely non-specific, with reports indicating a wide variation in the presence of disparate signs as consolidation and honeycombing. Nevertheless, there is reasonably stereotypical appearance of 'pure' fibrotic NSIP, particularly when it is seen in the context of systemic sclerosis.

The HRCT appearances of fibrotic NSIP can be summarised as: *a fibrosing lung disease in which ground glass predominates and honeycombing is minimal or absent, it is usually lower zone in distribution and there may be subpleural sparing.*

As NSIP progresses, the delicate texture of the ground glass opacification may be replaced by a coarser reticular pattern and occasionally some honeycombing. Because of the distinct overlap in appearances between fibrotic NSIP and non-classical UIP, the age of the patient and whether, clinically, there is suggestion of an underlying connective tissue disease become crucial. The likelihood of a cryptic ('non-CTD-related') fibrotic NSIP in an elderly man is slight.

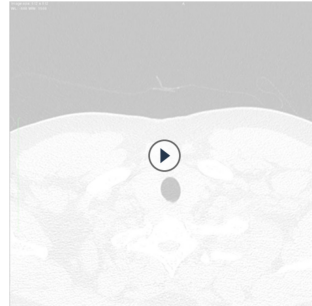


Non-specific interstitial pneumonia (NSIP)

Fibrosing variant of organising pneumonia (OP)

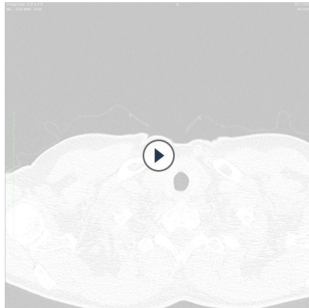
The key CT finding in making this diagnosis is foci of consolidation. Given that the evolution of organising pneumonia is becoming incorporated into alveolar walls as fibrosis, signs of OP may only be present or conspicuous on CTs in the earlier stages of the disease.

Foci of consolidation, ground glass opacity and a perilobular pattern, but little signs of fibrosis on this CT; a CT 2 years later showed features of established interstitial fibrosis
Organising pneumonia



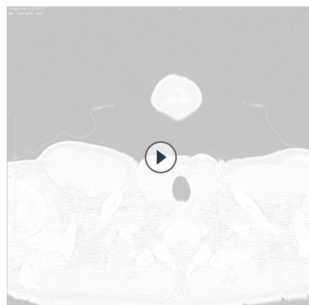
Organising pneumonia

Thus, if the possibility of fibrotic OP is entertained, every attempt should be made to examine earlier CTs if available. Nevertheless on a single CT, subtle stigmata of OP may be present many months and occasionally years after presentation. In addition to foci of consolidation – with or without air bronchograms – a limited perilobular pattern or bronchocentric densities may be identifiable (in addition to CT signs of fibrosis).



Foci of consolidation

Perilobular consolidation of organising pneumonia



Bronchocentric densities

Bronchocentric distribution of organising pneumonia

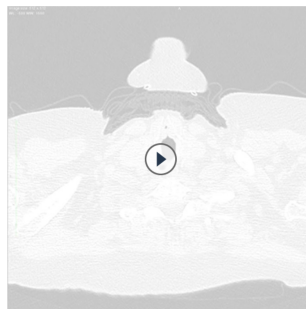
Chronic fibrotic hypersensitivity pneumonitis

The distribution of fibrosis and ancillary findings are key pointers to the diagnosis of chronic fibrotic hypersensitivity pneumonitis. In some cases, there is no zonal predominance, while in others, there is a predilection for either the upper or lower lobes. In cases of fibrosing lung disease, which affects all zones with no particular zonal distribution, chronic HP should always be considered.


In cases in which the fibrosis is predominantly basal the differential is between chronic HP and UIP, the distinction is often difficult (as it can be for pathologists).

In such cases, a search should be made for the following signs that points towards chronic HP:

1. Lobules of decreased attenuation reflecting the bronchiolitis that accompanies chronic HP (these need to be away from areas of fibrotic lung, i.e. within relatively normal lung because lobules of decreased attenuation are often scattered within established fibrosis, especially in UIP).

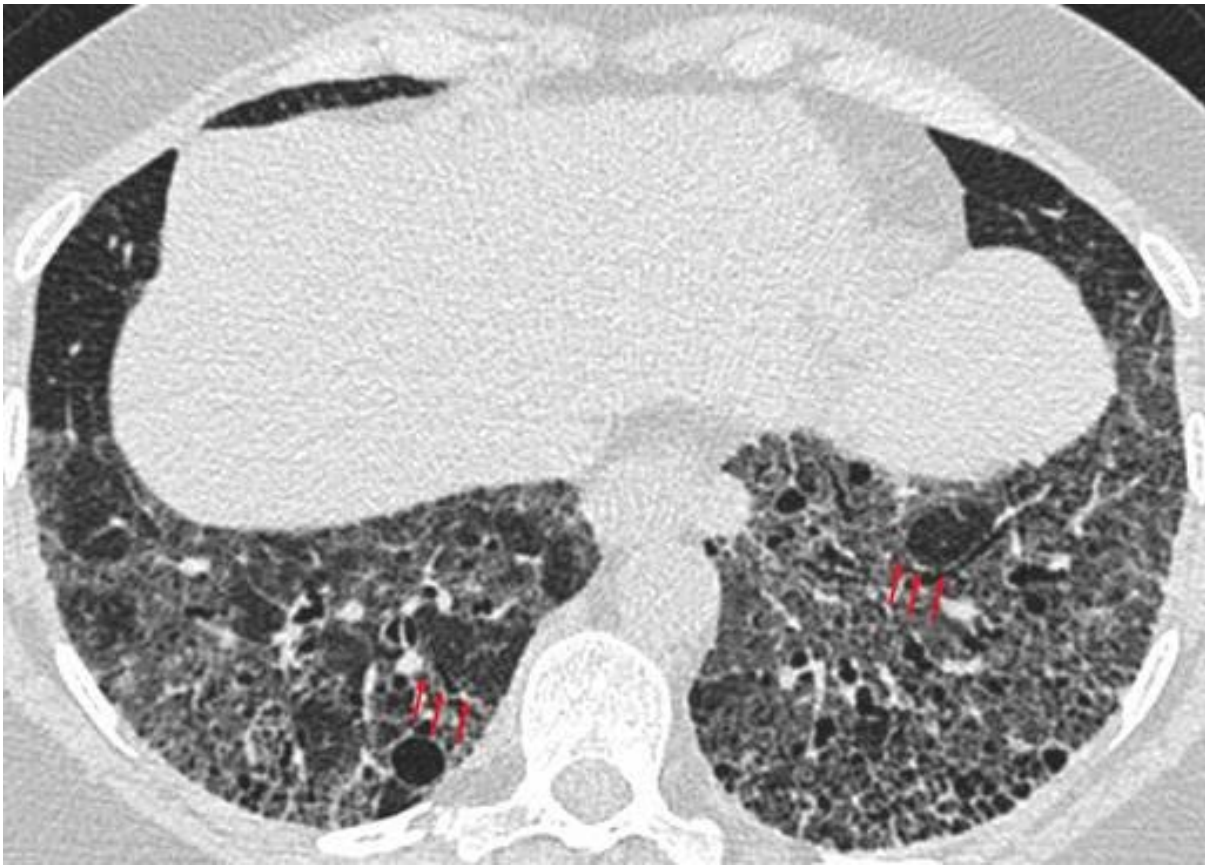


Chronic HP bronchiolitis example 1

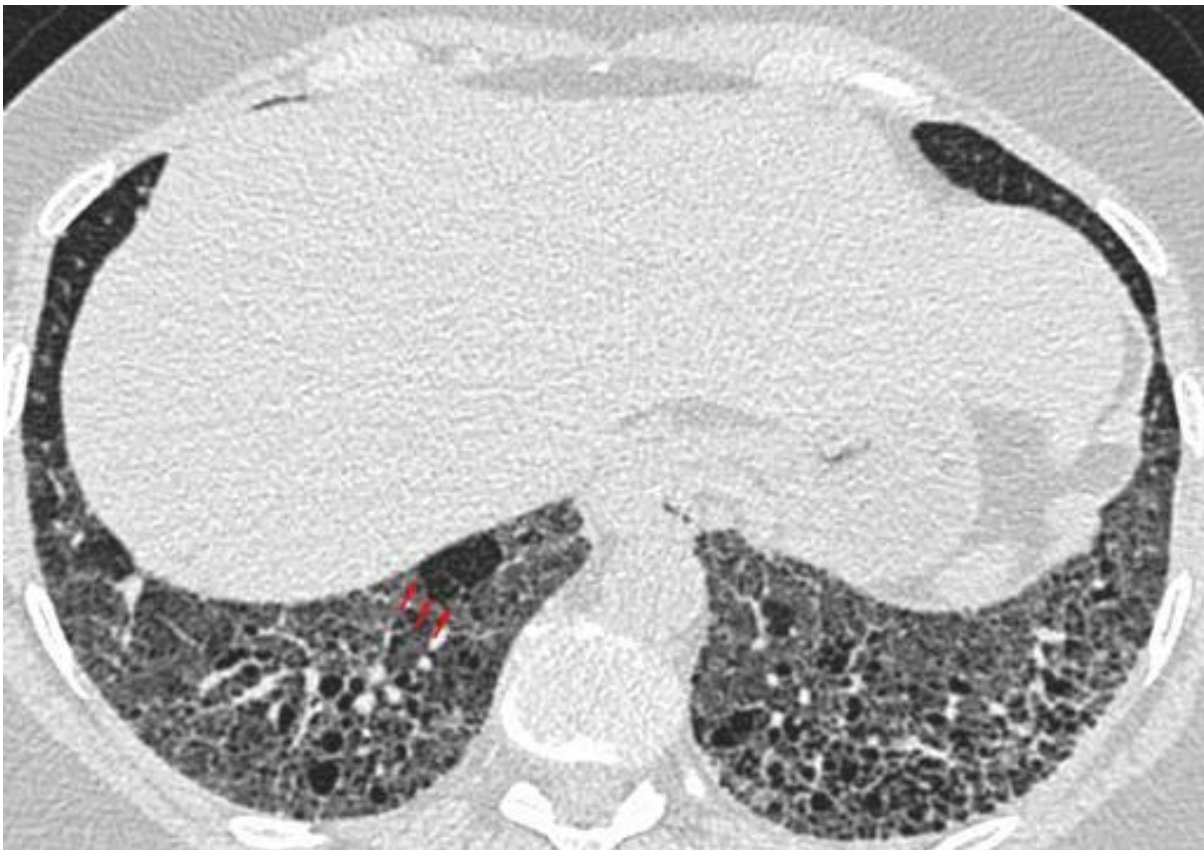


Chronic HP bronchiolitis example 2

Two different examples of UIP showing lobules of decreased attenuation within fibrotic lung.

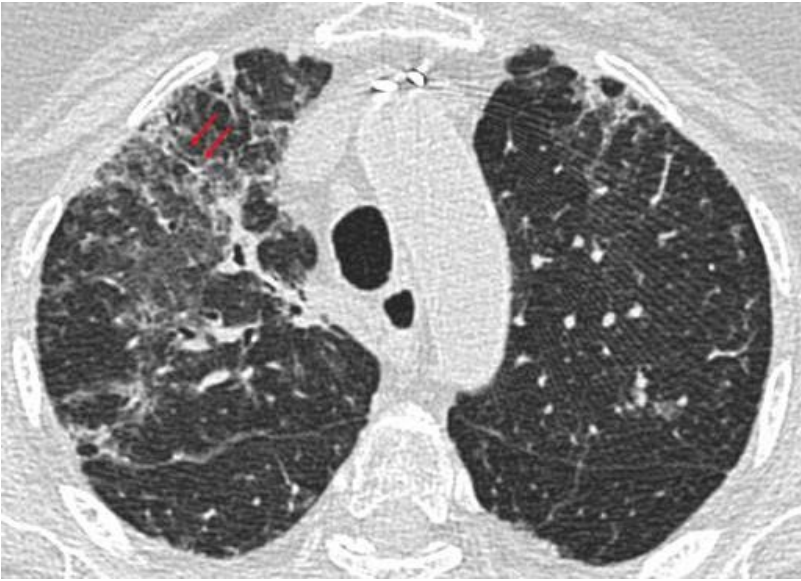


An example of UIP showing lobules of decreased attenuation within fibrotic lung.

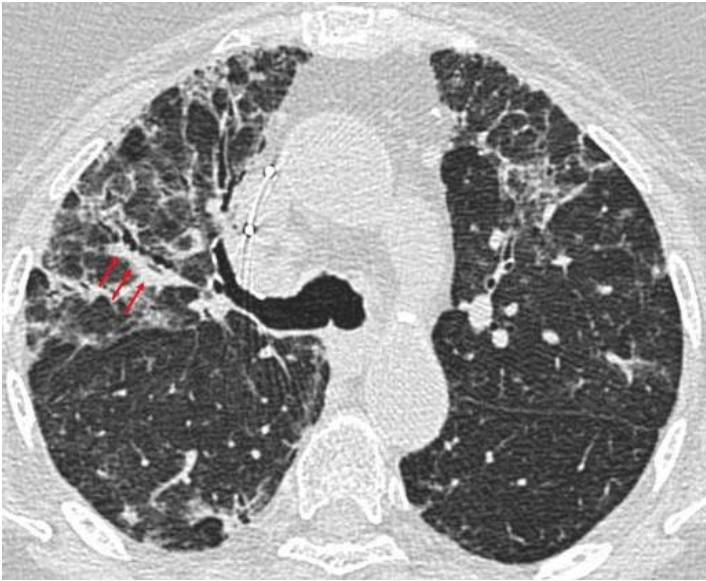


An example of UIP showing lobules of decreased attenuation within fibrotic lung.

2. Vague bronchocentricity of the fibrosis in the upper lobes – this may be a very subtle but telling sign; the fibrosis is not as obviously bronchocentric as it is in sarcoidosis.

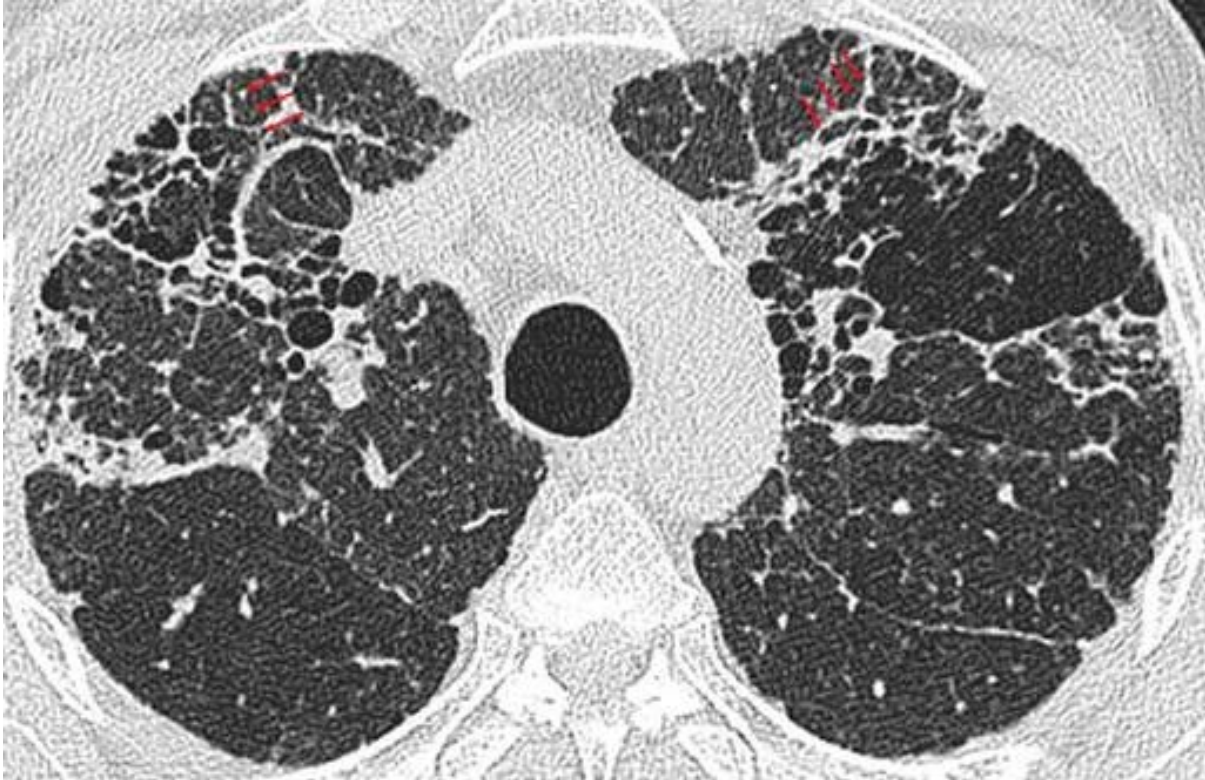

1/2 Bronchocentricity of fibrosis



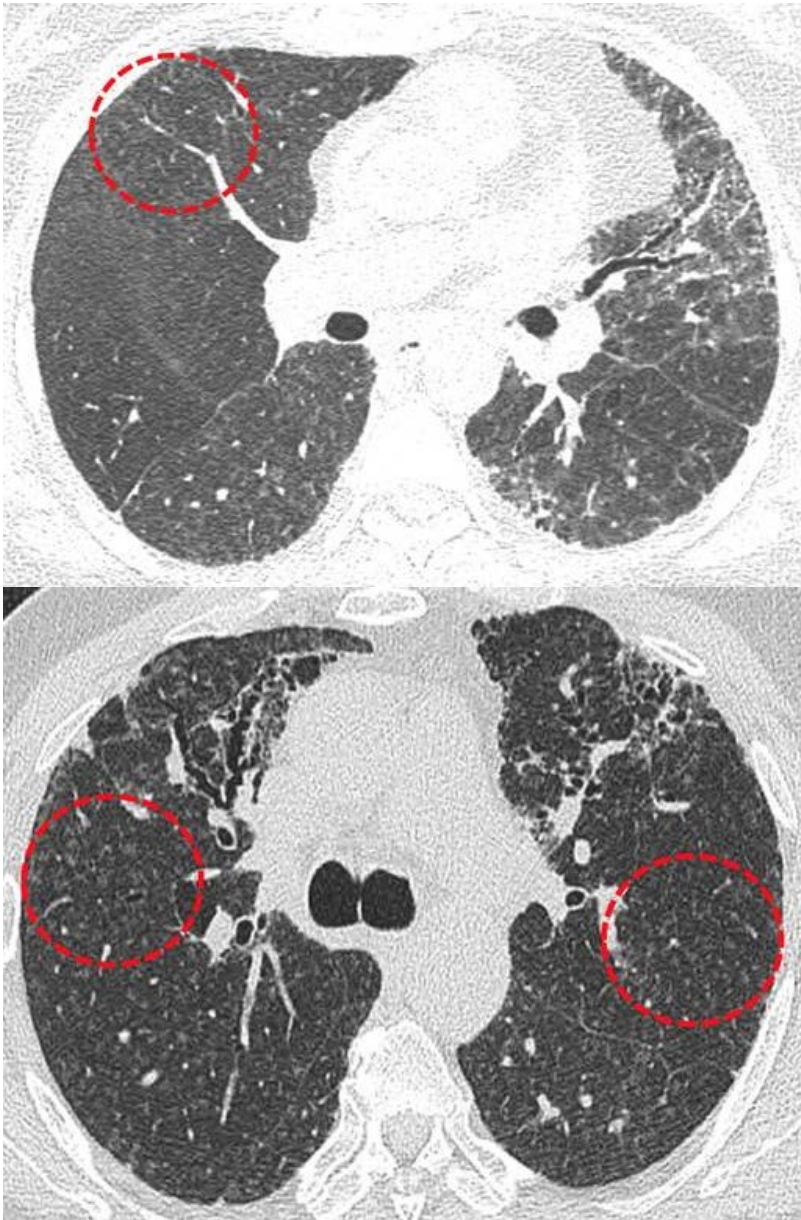
2/2 Bronchocentricity of fibrosis

3. Thickened interlobular septa – not profuse but more conspicuous than in other fibrotic interstitial pneumonias (i.e. UIP or NSIP).



Septal thickening most obvious anteriorly in the left upper lobe in a patient with chronic hypersensitivity pneumonitis

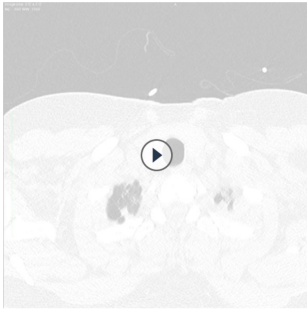
4. Signs of subacute hypersensitivity pneumonitis – in particular, small indistinct ground glass density centrilobular nodules and ground glass opacification. However, in the majority of cases of established fibrotic (chronic) HP, features of subacute HP are absent.



Rare examples of two patients with chronic hypersensitivity pneumonitis with soft ground glass nodules, indicating the presence of coexistent subacute hypersensitivity pneumonitis (red circles).

Fibrotic sarcoidosis

In most cases of fibrotic sarcoidosis there are enough findings (distribution and additional signs) to suggest the diagnosis. The classic upper zone distribution of fibrosis, which streams directly off the hila (often trending posteriorly), is well known and is diagnostic particularly when there are other findings, such as symmetrically disposed calcified hilar and mediastinal lymph nodes. In a very small proportion of patients, a predominantly basal distribution is encountered and such cases mimic UIP.

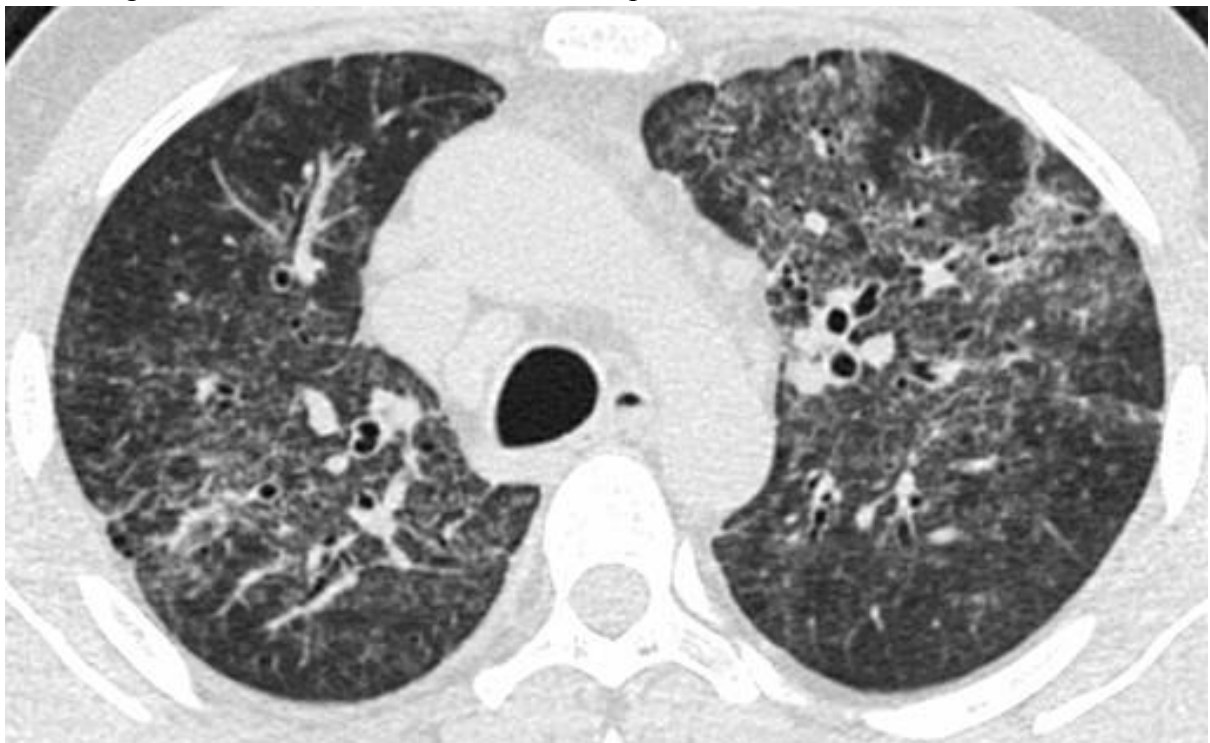

Fibrotic sarcoidosis

There are two broad manifestations of basal fibrotic sarcoidosis:

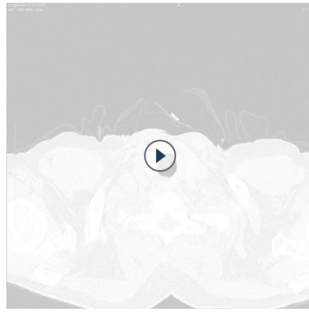
1) Reticular and ground glass pattern caused by nodular thickening of the interlobular and intralobular septae.

Fibrotic sarcoidosis. Reticular and ground glass pattern caused by nodular thickening of the interlobular and intralobular septae.



Fibrotic sarcoidosis reticular pattern

2) A more destructive pattern with honeycombing and fibrotic bullae - these cases more closely resemble UIP (and have a similar outcome to UIP).



Fibrotic sarcoidosis with UIP pattern

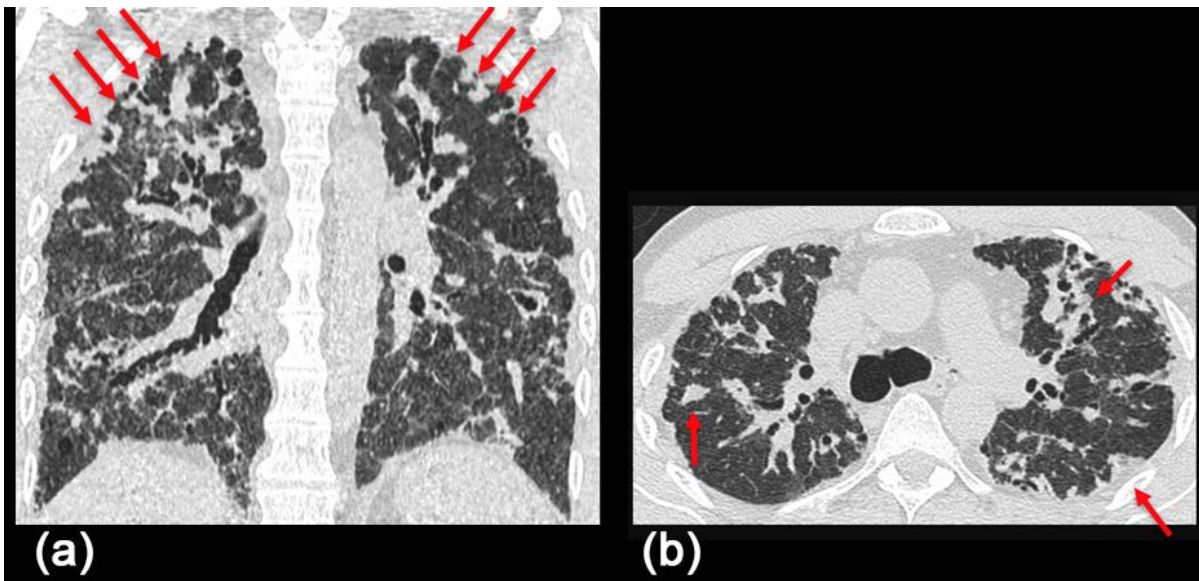
Pleuroparenchymal fibroelastosis

The 2013 [American Thoracic Society/European Respiratory Society update of the international multidisciplinary classification of the Idiopathic Interstitial Pneumonias](#) recognised idiopathic pleuroparenchymal fibroelastosis (PPFE).¹ This is a rare condition that consists of a form of fibrosis rich in elastic fibers involving the pleura and subpleural lung parenchyma, predominantly in the upper lobes.

It usually presents in the sixth decade of life and has no gender predilection. Associations include familial interstitial lung disease, lung transplantation, chemotherapeutic agents and recurrent infections. Pneumothorax is a common complication. The disease course is aggressive with 60% of patients progressing and death occurring in 40%.¹

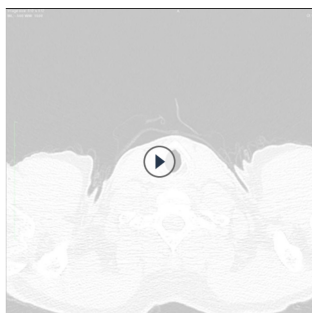
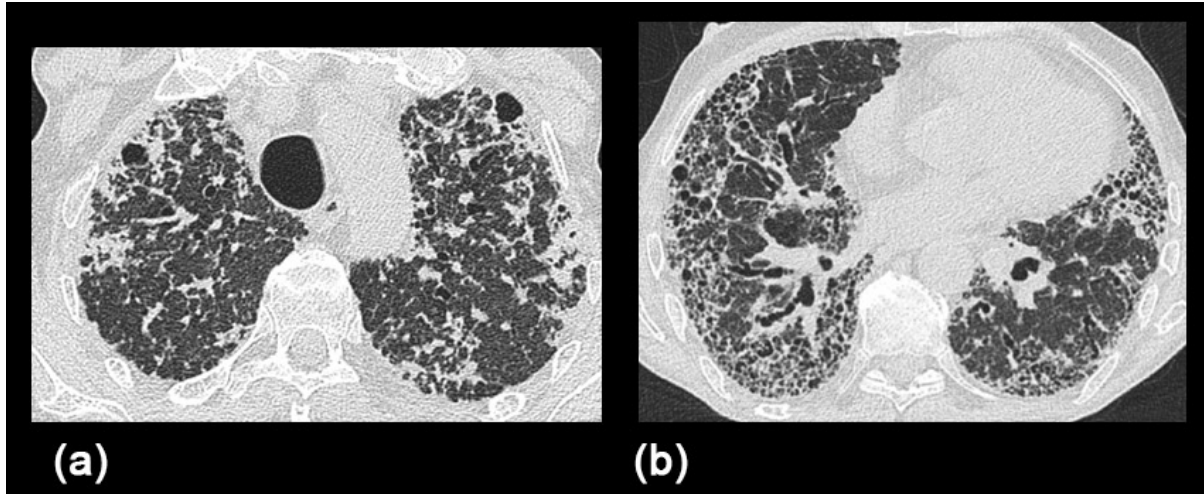
1. Travis et al. Am J Respir Crit Care Med 2013;188:733-748

Coronal reconstruction (a) and axial CT image (b) in a patient with idiopathic pleuroparenchymal fibroelastosis. CT appearances of idiopathic pleuroparenchymal fibroelastosis are distinctive, dense irregular subpleural consolidation and thickening in the upper zones, which represents elastotic fibrosis. These appearances are associated with upper lobe volume loss, architectural distortion and traction bronchiectasis.

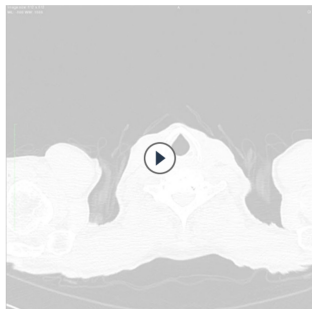


In the results of one study,¹ co-existent fibrotic lung disease was demonstrated in the mid or lower zones in 42% of cases. In this study, this coexistent fibrotic lung disease most resembled fibrotic NSIP although data (unpublished at the time of writing) suggests that histopathological evidence of usual interstitial pneumonia is present in almost one third of patients with PPFE. In this pair of axial images, PPFE features are seen in the upper lobes (a), while a UIP pattern of subpleural honeycombing is seen in the lower lobes (b).

1. Reddy et al 2012. ERJ;40:377-385



Pleuroparenchymal fibroelastosis



Pleuroparenchymal fibroelastosis complicated by pneumothorax

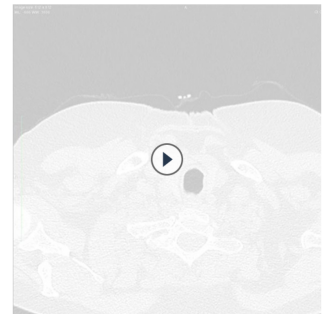
Case studies

No clinical information is presented for the case studies, because the purpose is to concentrate on analysis of the HRCT images. It is recommended that you scroll through the case BEFORE reading the accompanying description and interpretation.

Case Study 1

Description:

Predominantly subpleural and basal reticular pattern. Moderate traction bronchiectasis within the abnormal lung. Some volume loss in the lower lobes with oblique fissures drawn back to reach the mid-point of the diaphragmatic surfaces. A few cystic airspaces (possible limited honeycombing) confined to the medial part of the right costophrenic recess. No obvious centrilobular emphysema.



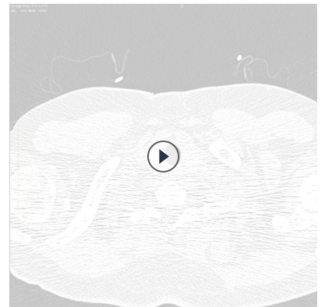
Interpretation:

Moderately advanced established fibrosis. Distribution and features, despite the lack of overt honeycombing, consistent with UIP (i.e. probable UIP). No CT features inconsistent with UIP. In an elderly patient (he was 74 years old), this is very likely to be UIP.

Case Study 2

Description:

Peripheral paraseptal emphysema and honeycombing in the upper lobes. Fine reticulation and ground glass opacification in the lower lobes. Mild traction bronchiectasis and volume loss in the lower lobes. An area of pseudo-honeycombing medially in the left upper lobe reflects combined fibrosis and emphysematous destruction.



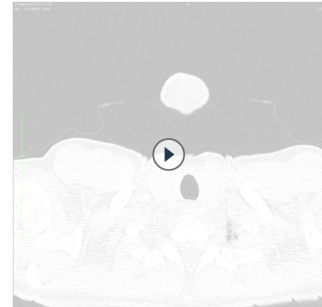
Interpretation:

Interstitial fibrosis with coexisting emphysema. HRCT morphology compatible with either fibrotic NSIP or non-classical UIP. The indolent course of the disease and finding of predominantly pigmented macrophages on broncholaveolar lavage in this cigarette smoker, led to an MDT diagnosis of smoking-related fibrotic NSIP.

Case Study 3

Description:

Patchy peripheral ground glass opacification in the upper lobes merging with subpleural consolidation in the lower lobes. Minor reticular elements with distortion and dilatation of airways and some volume loss in the lower lobes. Note the bronchocentric and perilobular characteristics of the consolidation in the lower lobes.



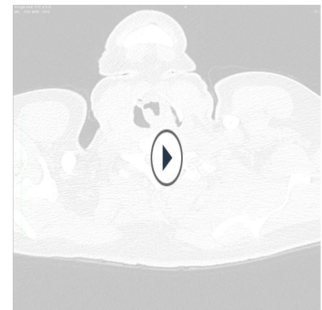
Interpretation:

The distribution of consolidation in the lower lobes is suggestive of organising pneumonia, while the ground glass with sparing of the immediate subpleural lung in the upper lobes is suggestive of fibrotic NSIP. The patient had a mixed connective tissue disease, and the radiologic diagnosis was fibrotic NSIP with overlapping features of organising pneumonia.

Case Study 4

Description:

Coarse subpleural reticular pattern consisting of relatively uniform size thick-walled cystic air spaces (honeycombing). There is no coexisting emphysema. This peripheral honeycombing is most pronounced at the lung bases.



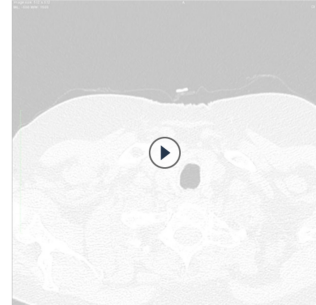
Interpretation:

Classical UIP pattern.

Case Study 5

Description:

A difficult case of fibrotic lung disease characterised by areas of reticulation and ground glass opacification, which in places is subpleural in the lower lobes, but with vague bronchocentric areas of fibrosis in the upper lobes). At the lung bases, there is evidence of very subtle mosaic attenuation.



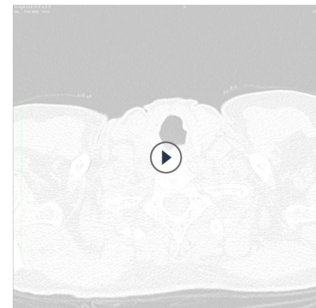
Interpretation:

The presence of mosaicism in the setting of a fibrosing lung disease raises the possibility of chronic hypersensitivity pneumonitis. The vague bronchocentric elements of the fibrosis in the upper lobes also is compatible with this diagnosis. This case required multidisciplinary discussion. A bronchoalveolar lavage was performed and showed 37% lymphocytes. The multidisciplinary diagnosis was chronic hypersensitivity pneumonitis.

Case Study 6

Description:

There are areas of angular subpleural consolidation with a definite upper lobe distribution. There is also some free-standing bronchiectasis in the upper lobes, and subpleural reticulation and traction bronchiectasis in the lower lobes.



Interpretation:

Imaging features are consistent with pleuroparenchymal fibroelastosis in the upper lobes with a coexistent fibrotic lung disease meeting 'possible UIP' criteria in the lower lobes.

About Dr Simon Walsh



Simon Walsh is a Consultant Thoracic Radiologist working at King's College Hospital Foundation Trust specialising in the imaging of diffuse lung diseases. He also works as a freelance software developer and applies these skills to his research interests in medicine. His specific research interests include staging of idiopathic pulmonary fibrosis, the role of multidisciplinary evaluation in the setting of diffuse lung disease, computer-aided image analysis, machine learning and computer vision. He regularly lectures on the imaging of diffuse lung diseases, both nationally and internationally and is widely published on this subject, including articles in several high impact respiratory journals, such as *Lancet Respiratory Medicine*, *European Respiratory Journal* and *Thorax*. He is also a member of the current ATS/ERS/JRS/ALAT IPF guideline committee.