

Talib jawad

Connective tissue

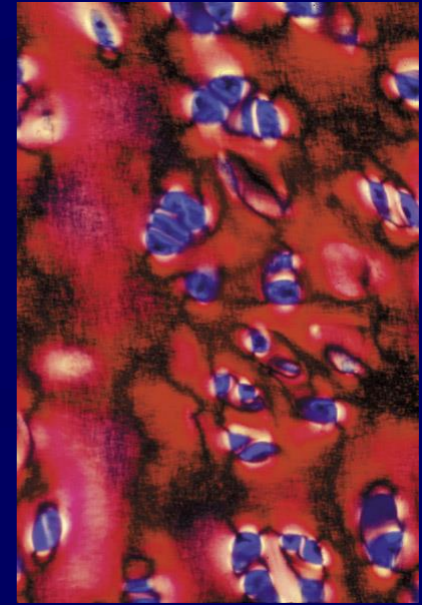
CARTILAGE and BONE

**True necessities
for life as we
know it.**

CARTILAGE

A. Important for:

- support of soft tissues
- formation and growth of long bones
- durability of articular joints



B. Consists of an extracellular matrix (ground substance) containing,

- chondroblasts and chondrocytes (cartilage cells)
- collagen and in some cases elastin fibers
- glycosaminoglycans
- proteoglycans*, proteoglycan aggregates
- water

***Collagen provides tensile strength and durability, however, proteoglycans are also important, e.g. if you inject papain (an enzyme that digests the protein cores of proteoglycans) into the ears of a rabbit, after a few hours the ears will lose their stiffness and droop.**

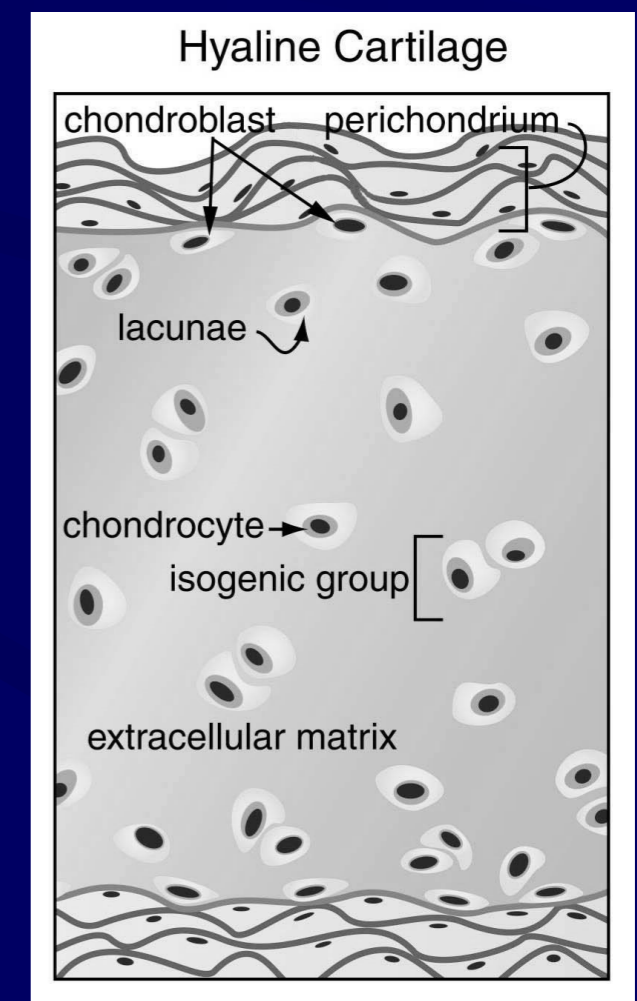
C. The qualities of the different types of cartilage depend on,

1. Differences in the type of collagen and concentration of collagen and elastin fibers in the extracellular matrix
2. The types of proteoglycan molecules that these fibers are associated with.

D. Hyaline and elastic cartilage are surrounded by a connective tissue capsule called the perichondrium that is composed of fibroblasts and associated fibers and ground substance.

E. The cartilage itself is devoid of blood vessels.

1. Nutrition of cells within the cartilage matrix is dependent on the diffusion of nutrients from blood capillaries in perichondrium and/or adjacent tissues.



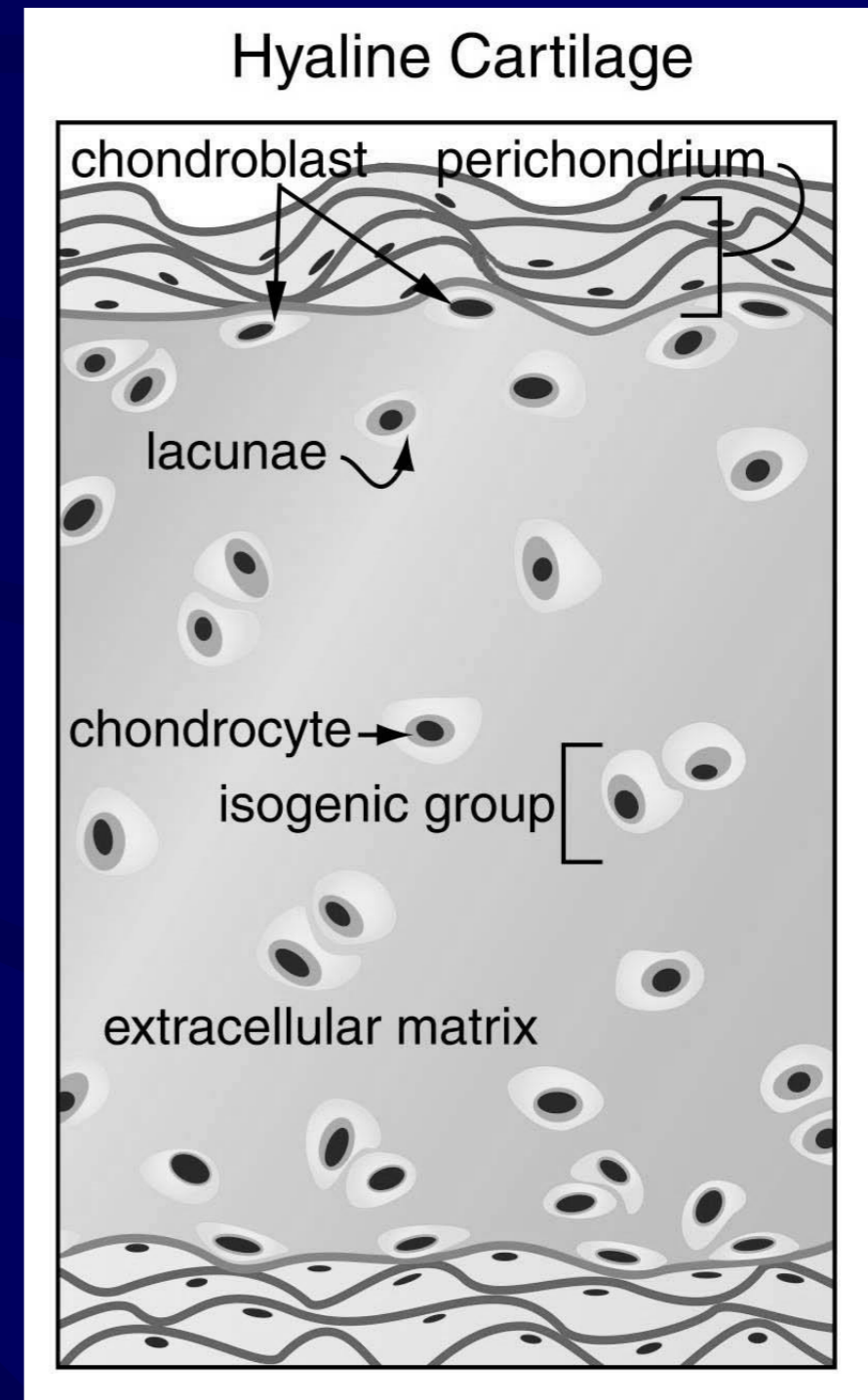
Three types of cartilage

The extracellular matrix of these 3 types differs in terms of concentration of collagen and elastin fibers.

1. Hyaline cartilage

a. Dominant protein component of extracellular matrix is collagen (type 2).

b. Translucent to bluish-white in life

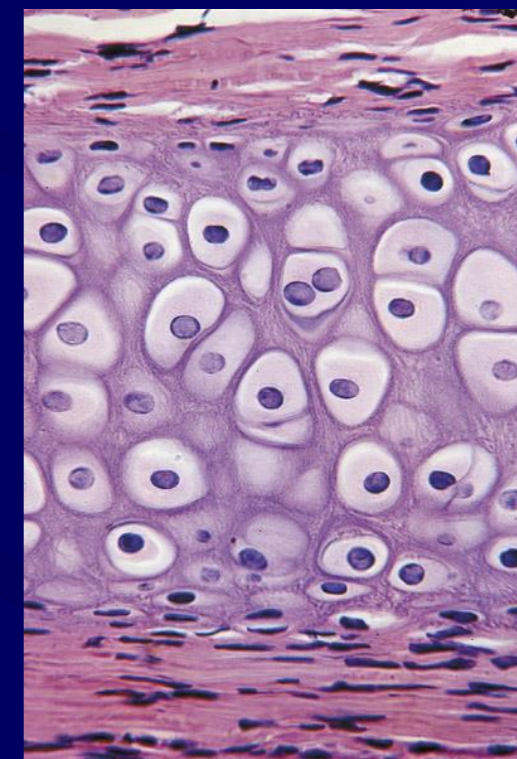
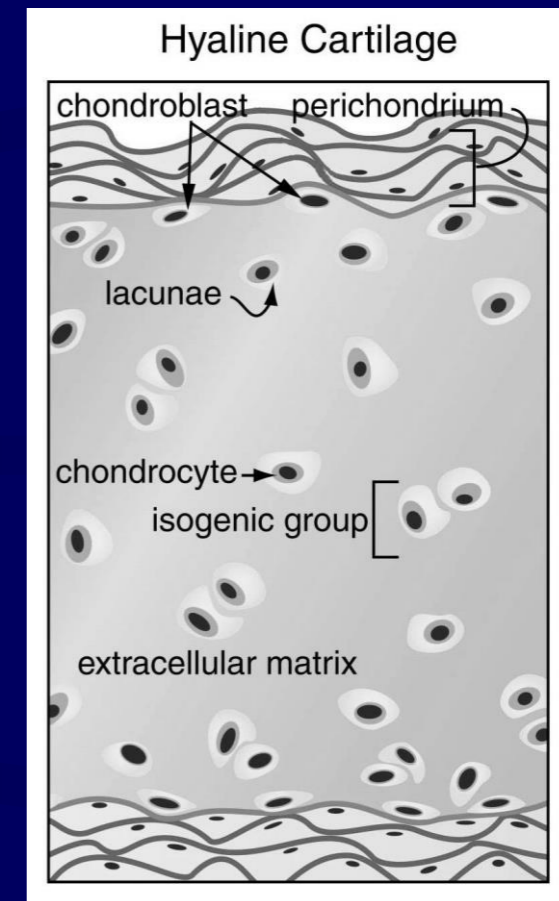


Hyaline cartilage

c. Important in embryonic formation and later growth of long bones - forms epiphyseal plates of long bones

d. In adult, mainly found lining

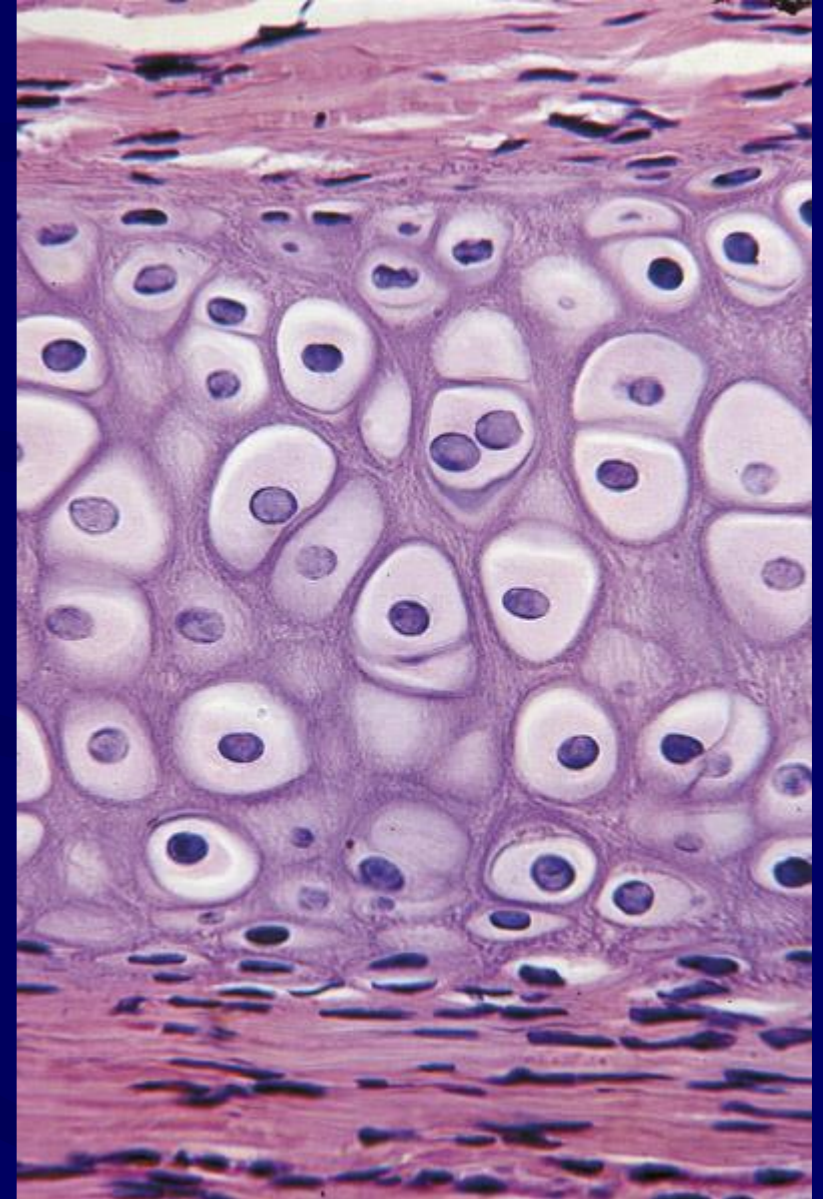- outer wall of respiratory passages (e.g. trachea)
- ventral ends of ribs, and
- on surfaces of bone joints where it is called **articular cartilage**.



Hyaline cartilage - structure/cell types/characteristics

1. Perichondrium

- vascularized connective tissue sheath surrounding cartilage (except in case of articular cartilage).
- rich in collagen.
- main cell type - fibroblasts
- Inner layer contains cells that are thought by some to be fibroblasts and by others to be undifferentiated mesenchyme cells. In any event, the cells can differentiate to form chondroblasts.

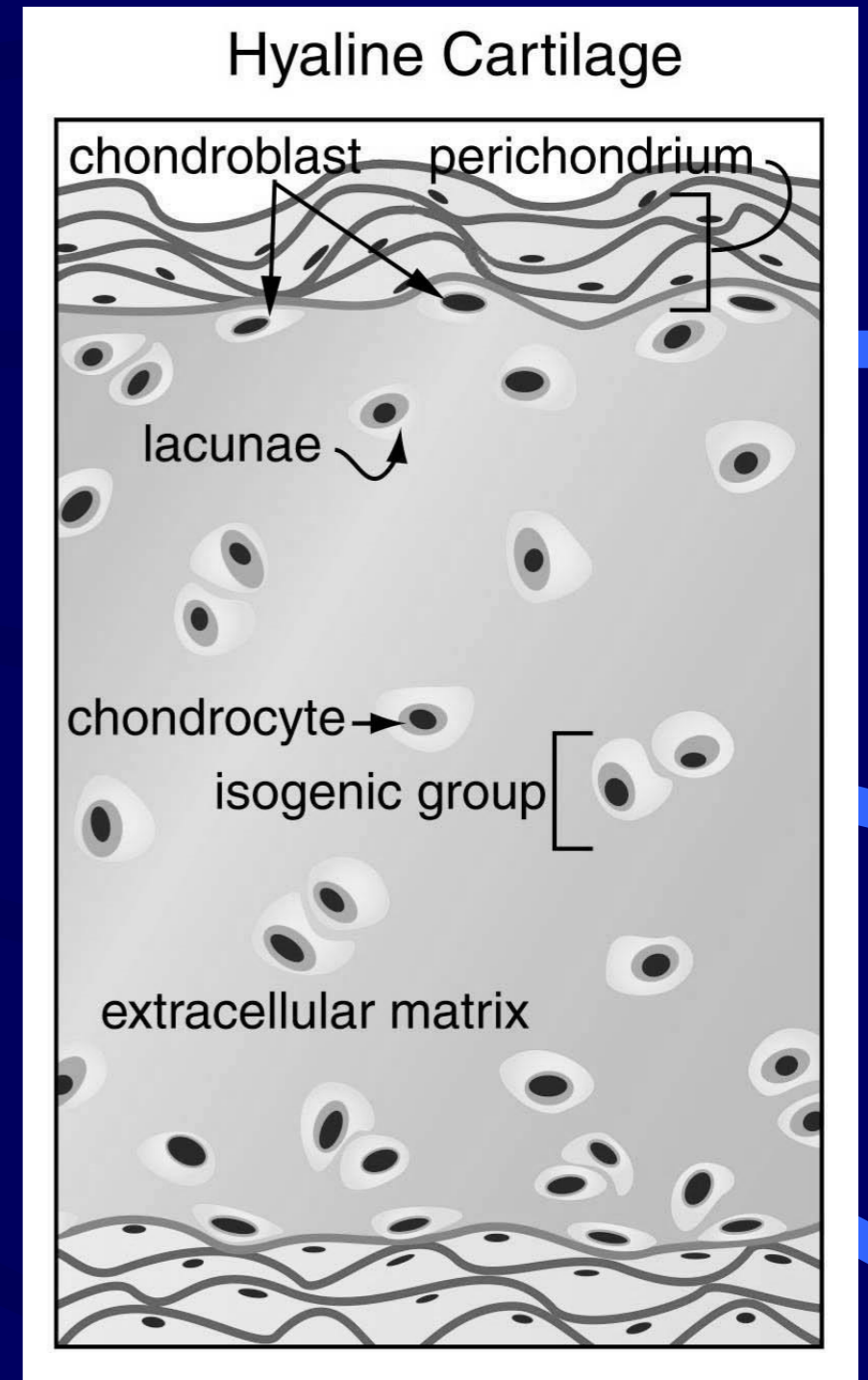


Hyaline cartilage

2. Chondroblasts - immature cartilage cells. Secrete extracellular matrix, but are not yet imprisoned in a lacuna.

3. Chondrocytes

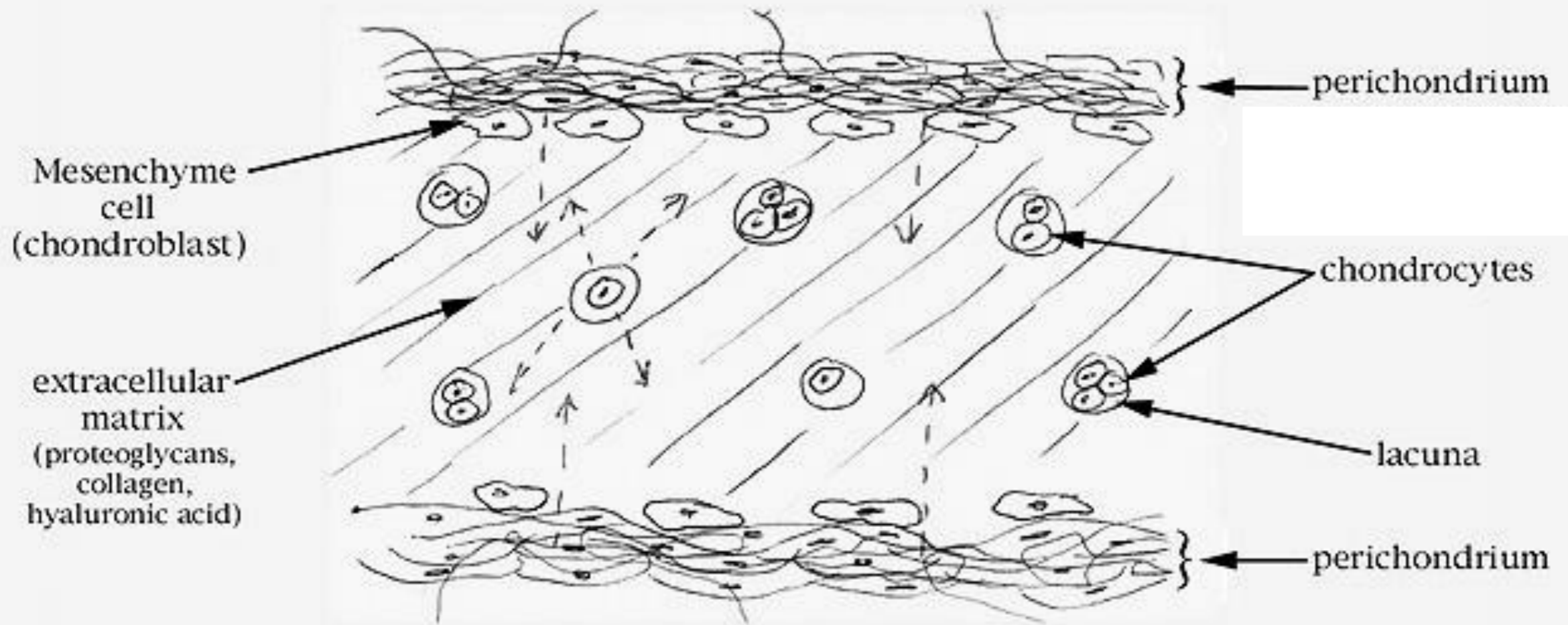
- Mature cartilage cells that are embedded in the extracellular matrix.
- Reside in small spaces within the matrix that are called **lacunae**.
- Sometimes form groups of 2 or 3 - **isogenic group**
- Chondrocytes have an **eliptic** shape.
- Organelle systems in cytoplasm are typical of cells that secrete.



Copyright 2000 R. Nims & S.C. Kempf

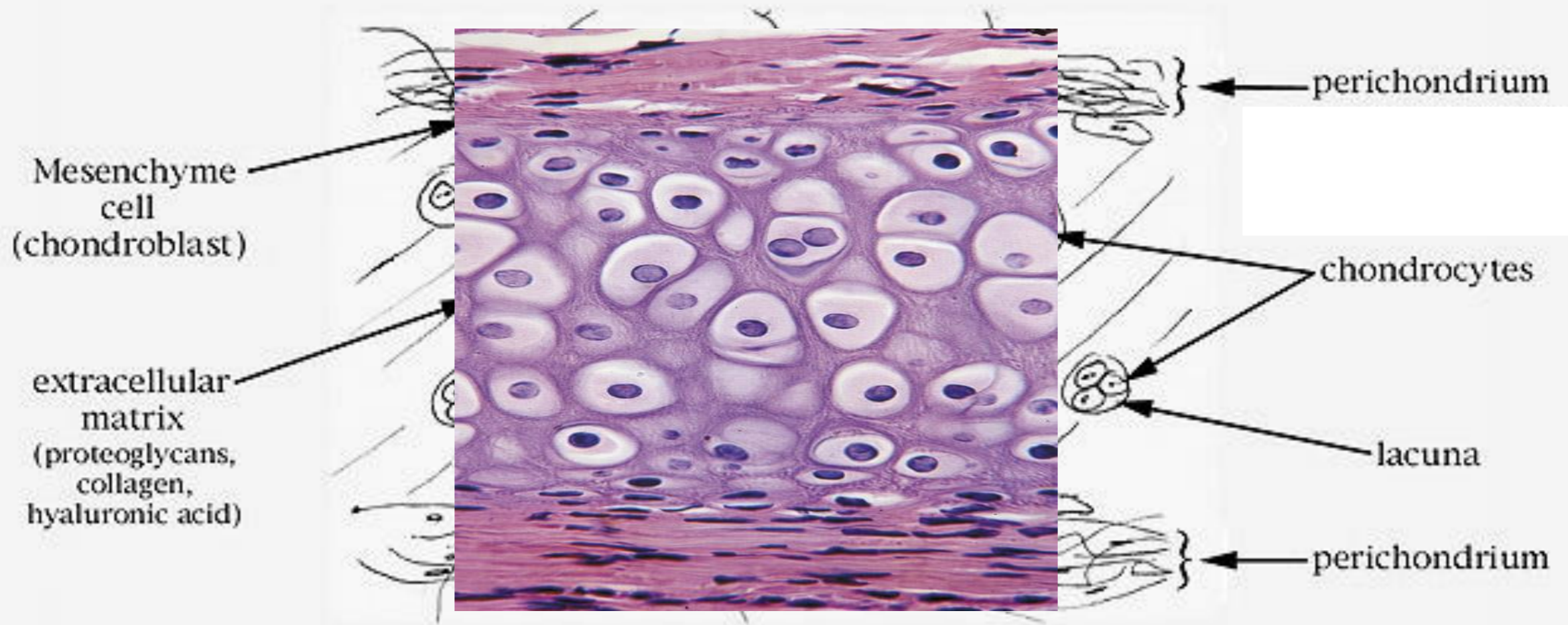
4. Can undergo calcification (arthritis) and can act as the template for bone formation and growth.

Components of Cartilage



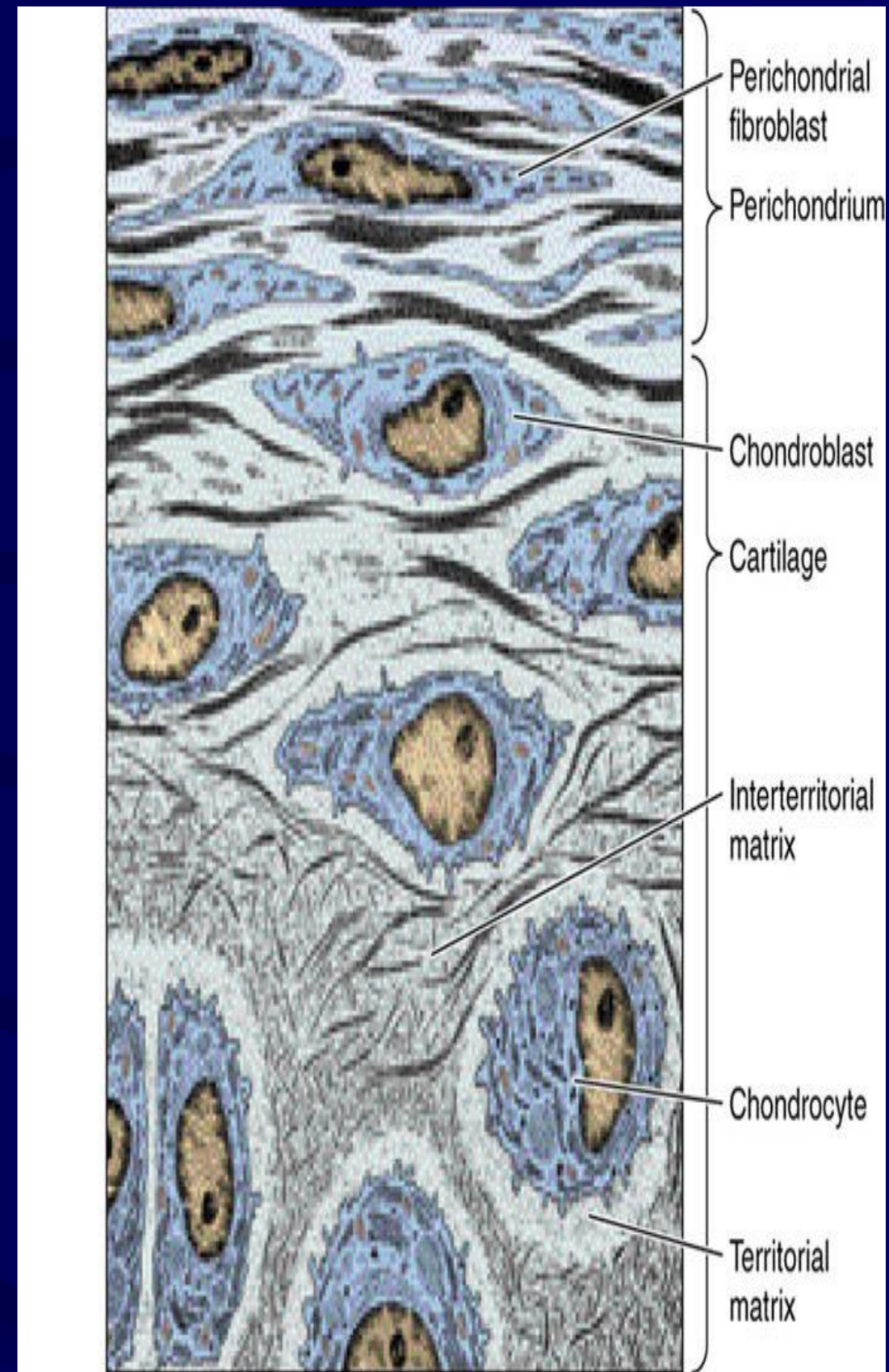
- ← - - - - diffusion of nutrients through extracellular matrix to chondrocytes
- ← - - - - diffusion of chondrocyte excretory products through extracellular matrix to circulatory system
- capillaries

Components of Cartilage



- ← - - - diffusion of nutrients through extracellular matrix to chondrocytes
- ← - - - diffusion of chondrocyte excretory products through extracellular matrix to circulatory system
- capillaries

Diagram of the area of transition between the perichondrium and the hyaline cartilage. As perichondrial cells differentiate into chondrocytes, they become round, with an irregular surface. Cartilage (interterritorial) matrix contains numerous fine collagen fibrils except around the periphery of the chondrocytes, where the matrix consists primarily of glycosaminoglycans; this peripheral region is called the territorial, or capsular, matrix.



Three types of cartilage

2. Elastic cartilage

a. High concentration of **elastin** fibers in extracellular matrix.

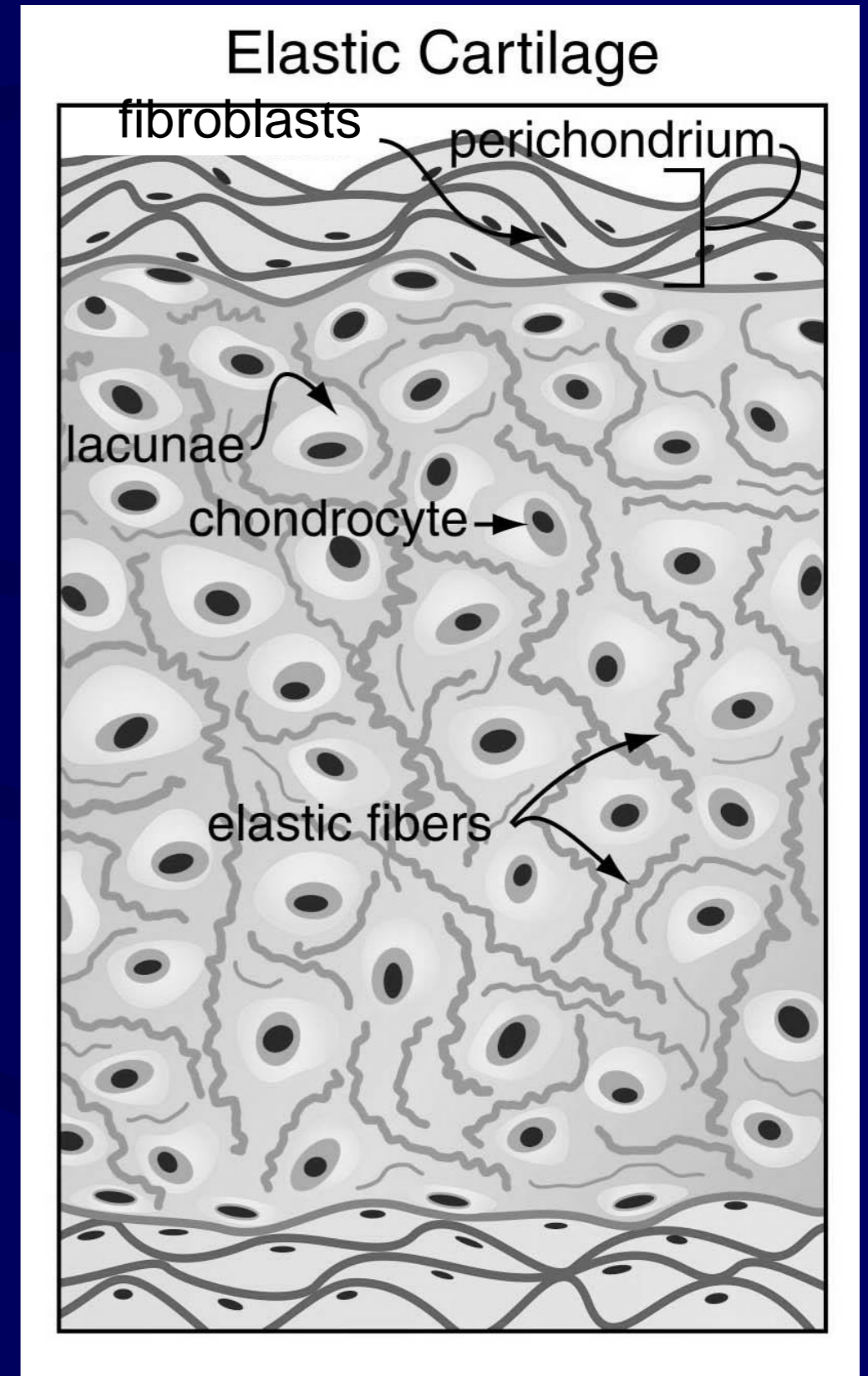
(e.g. external ears-pinna)

b. Ground substance - yellow in color (due to elastin content)

c. Chondrocytes are more closely packed, **no isogenic groups**.

d. Chondrocytes exhibit less accumulation of glycogen and lipids than in hyaline cartilage.

e. Does not calcify

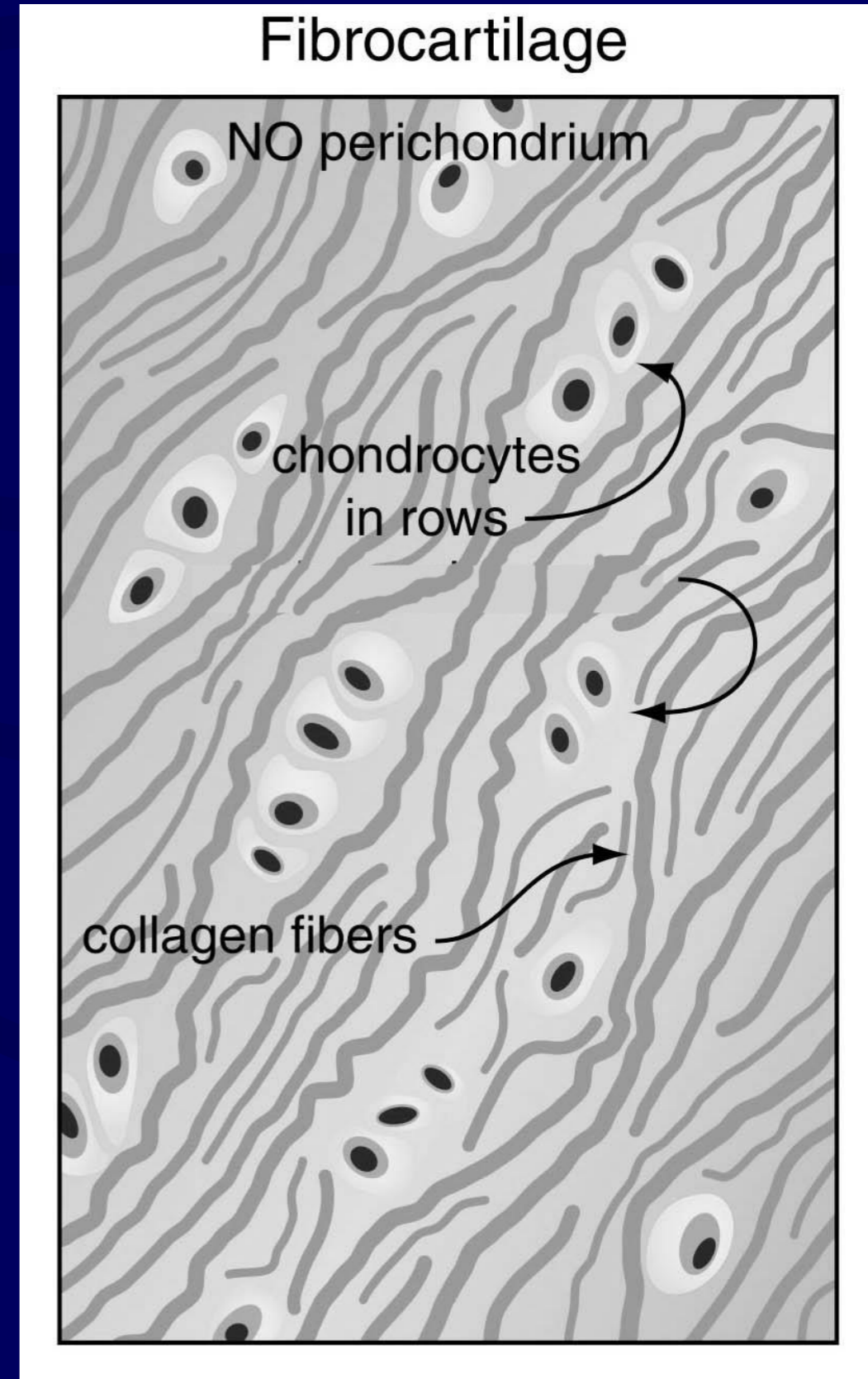


Copyright 2000 R. Nims & S.C. Kempf

Three types of cartilage

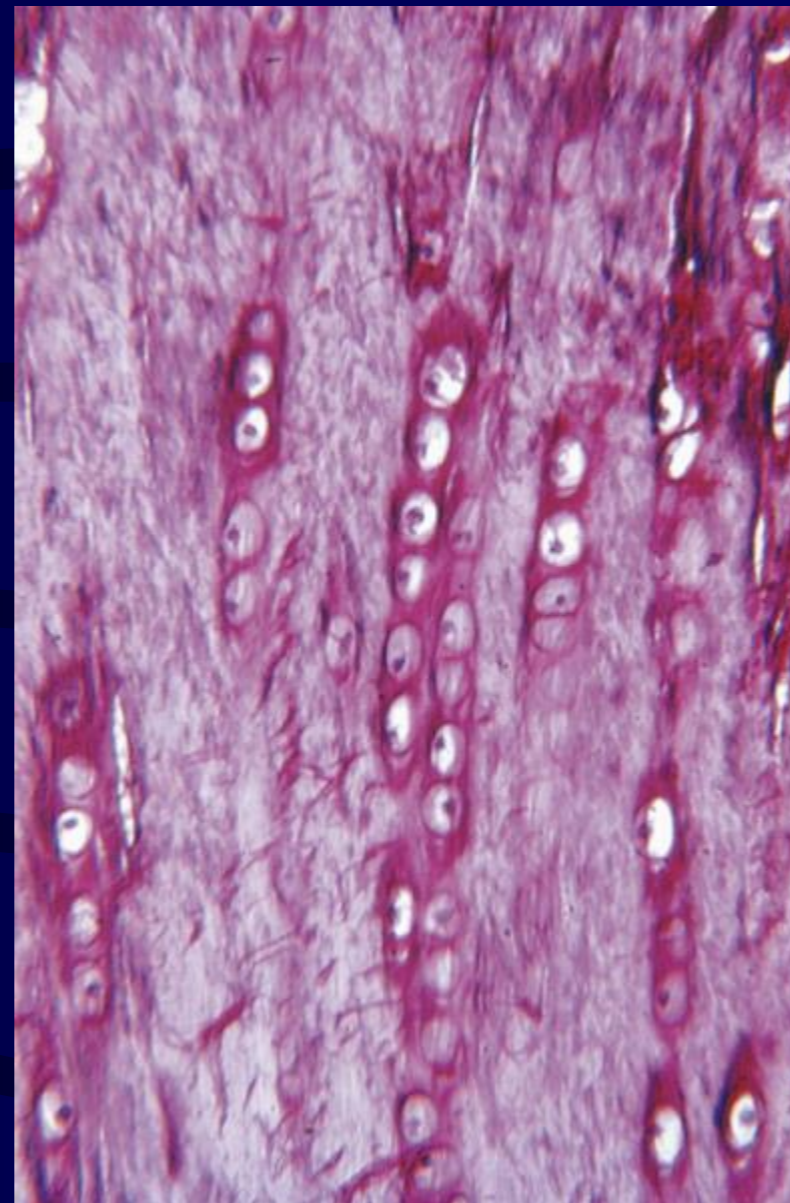
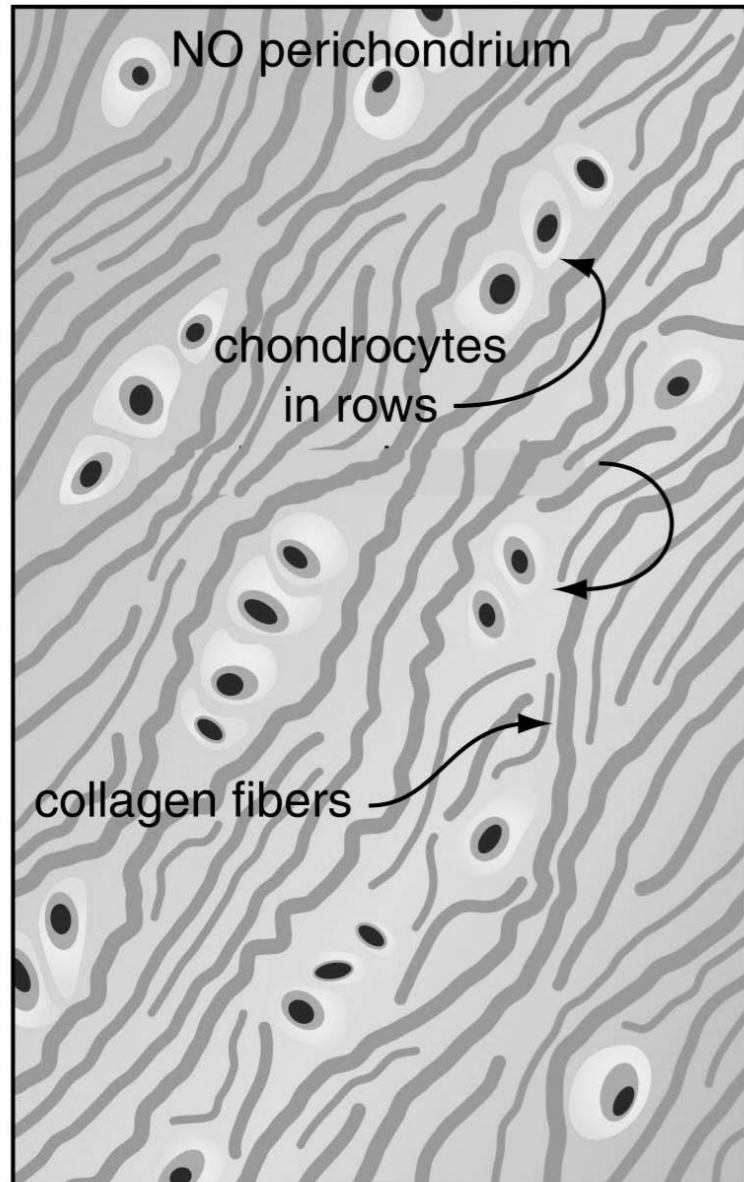
3. Fibrous cartilage (fibrocartilage)

- a. An irregular, dense, fibrous tissue with thinly dispersed, encapsulated chondrocytes.
- b. Contains many very large bundles of collagen fibers (type 1).
- c. Resists compression and shear forces. Has durability and high tensile strength.
- d. Found at connection of tendons to bone and in intervertebral discs and some joints
- e. No perichondrium



Intervertebral disk

Fibrocartilage



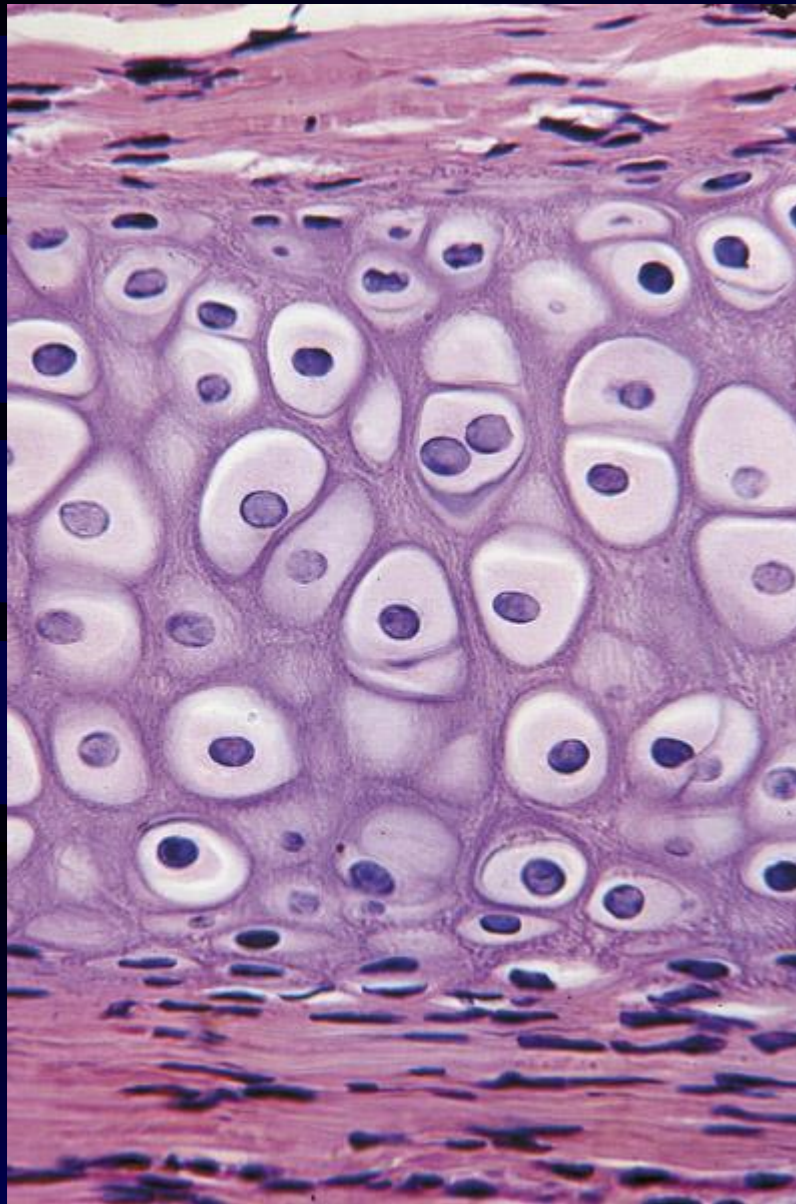
Central disk - less organized
spongy, shock absorber

Peripheral disk - more organized,
fibrous

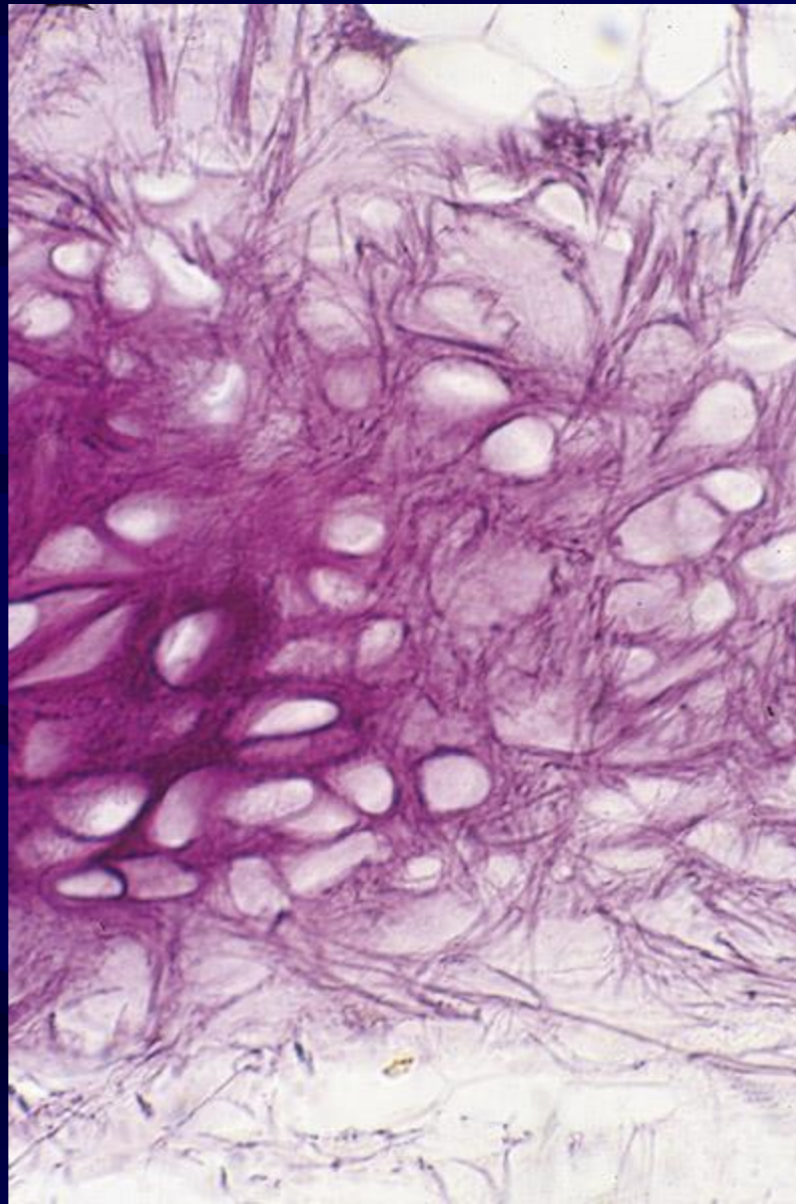
**Note regular organization of
fibers.**

**Note extended linear rows of
chondrocytes**

hyaline



elastic



fibrous

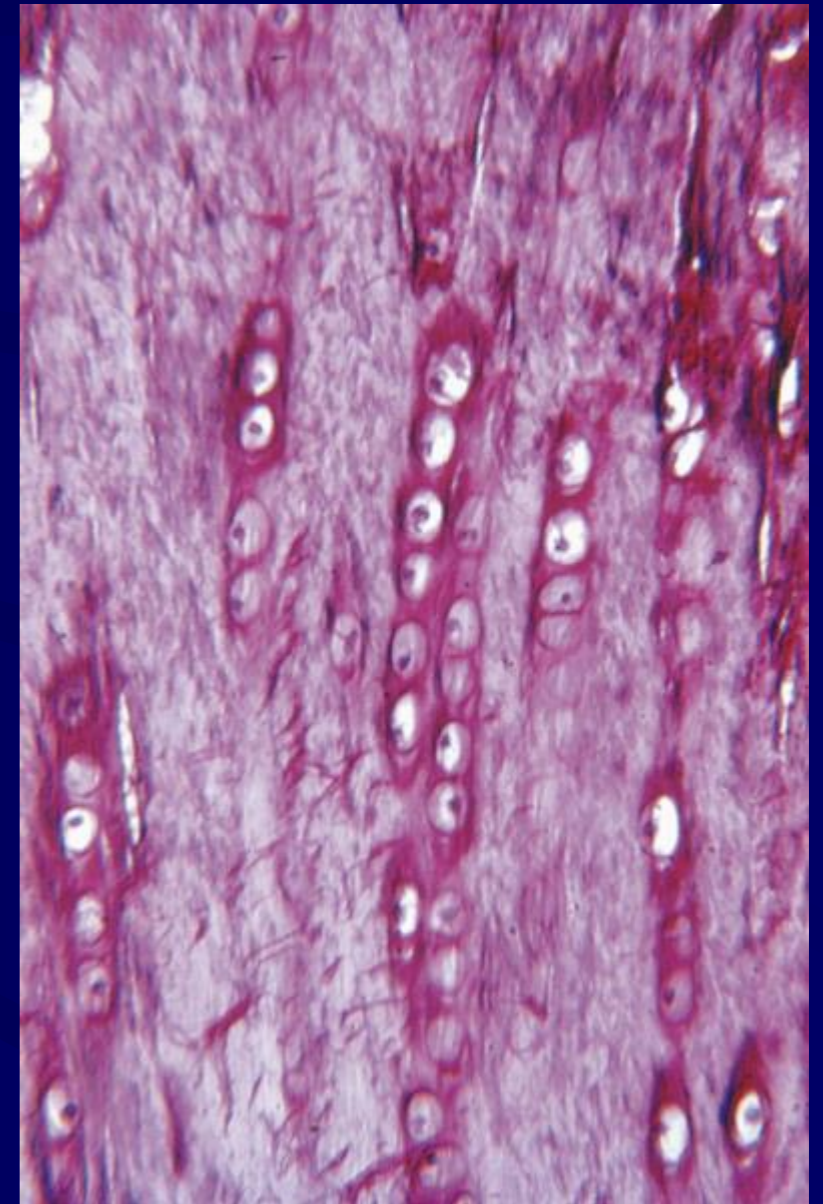
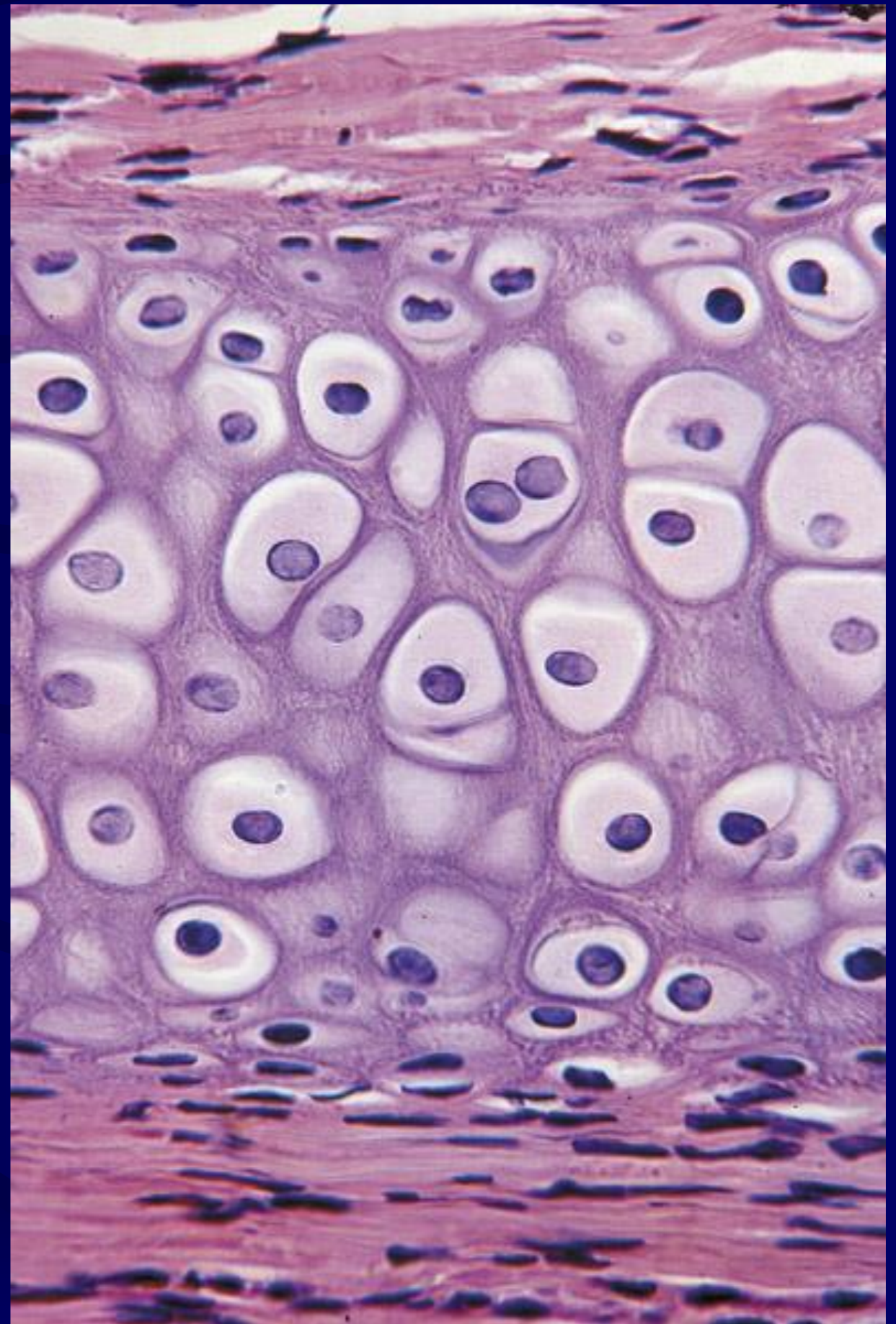
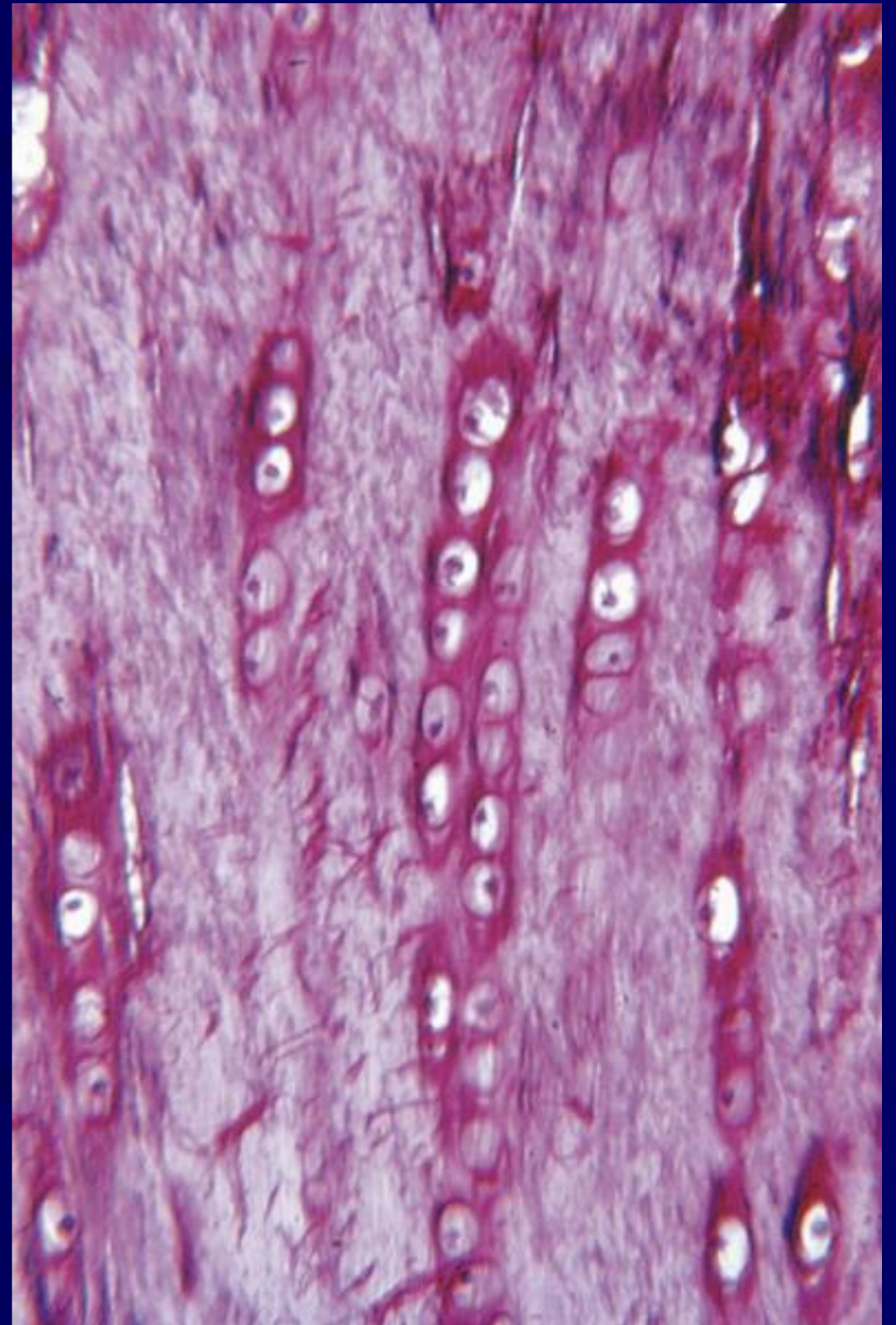


Figure 7—2.

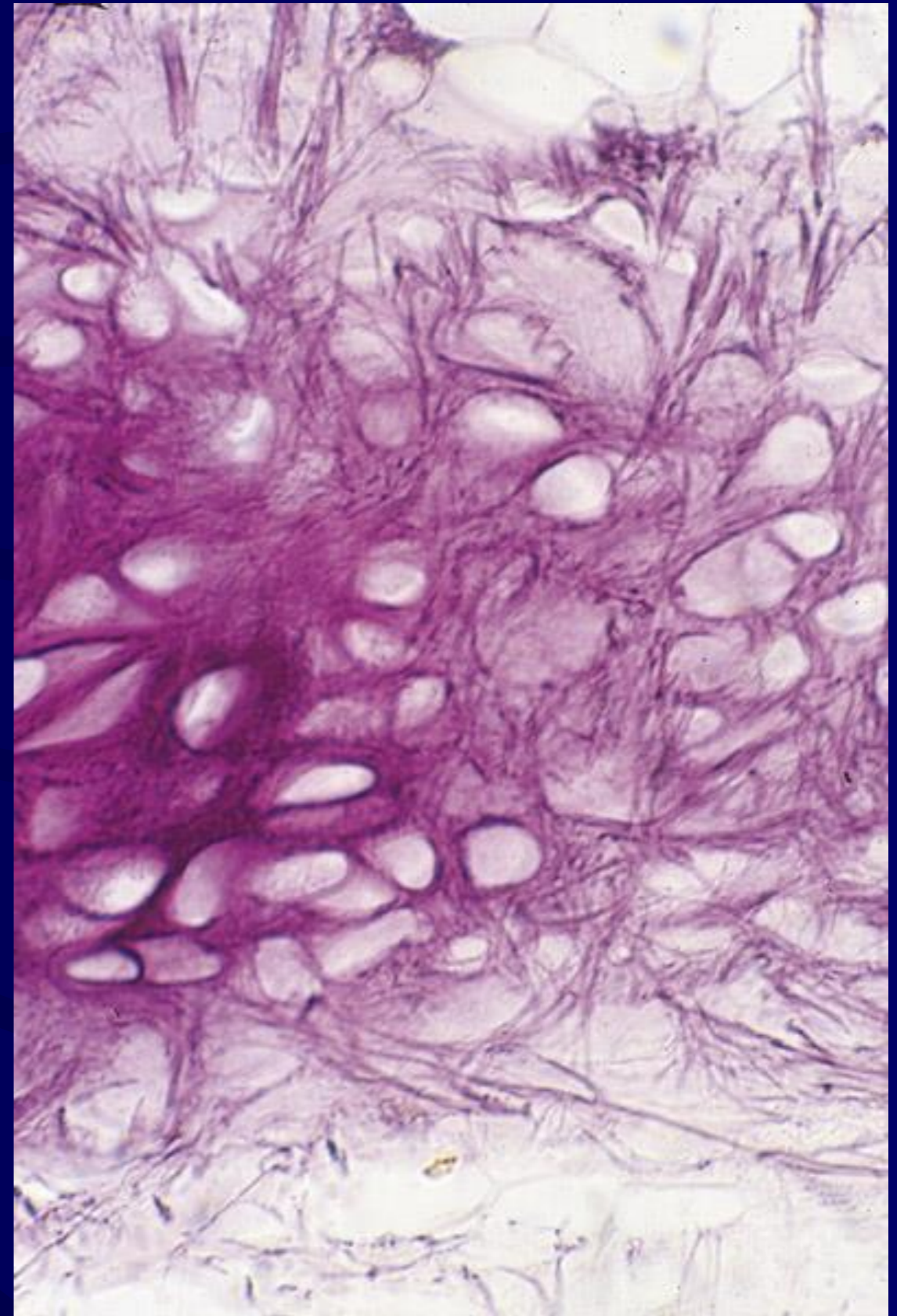
Photomicrograph of hyaline cartilage. Chondrocytes are located in matrix lacunae, and most belong to isogenous groups. The upper and lower parts of the figure show the perichondrium stained pink. Note the gradual differentiation of cells from the perichondrium into chondrocytes. H&E stain. Low magnification.



Photomicrograph of fibrocartilage. Note the rows of chondrocytes separated by collagen fibers. Fibrocartilage is frequently found in the insertion of tendons on the epiphyseal hyaline cartilage. Picrosirius-hematoxylin stain.



Elastic cartilage,
stained for elastic
fibers. Cells are not
stained. This flexible
cartilage is present,
the auricle of the ear
and in the epiglottis.
Resorcin stain.
Medium
magnification.



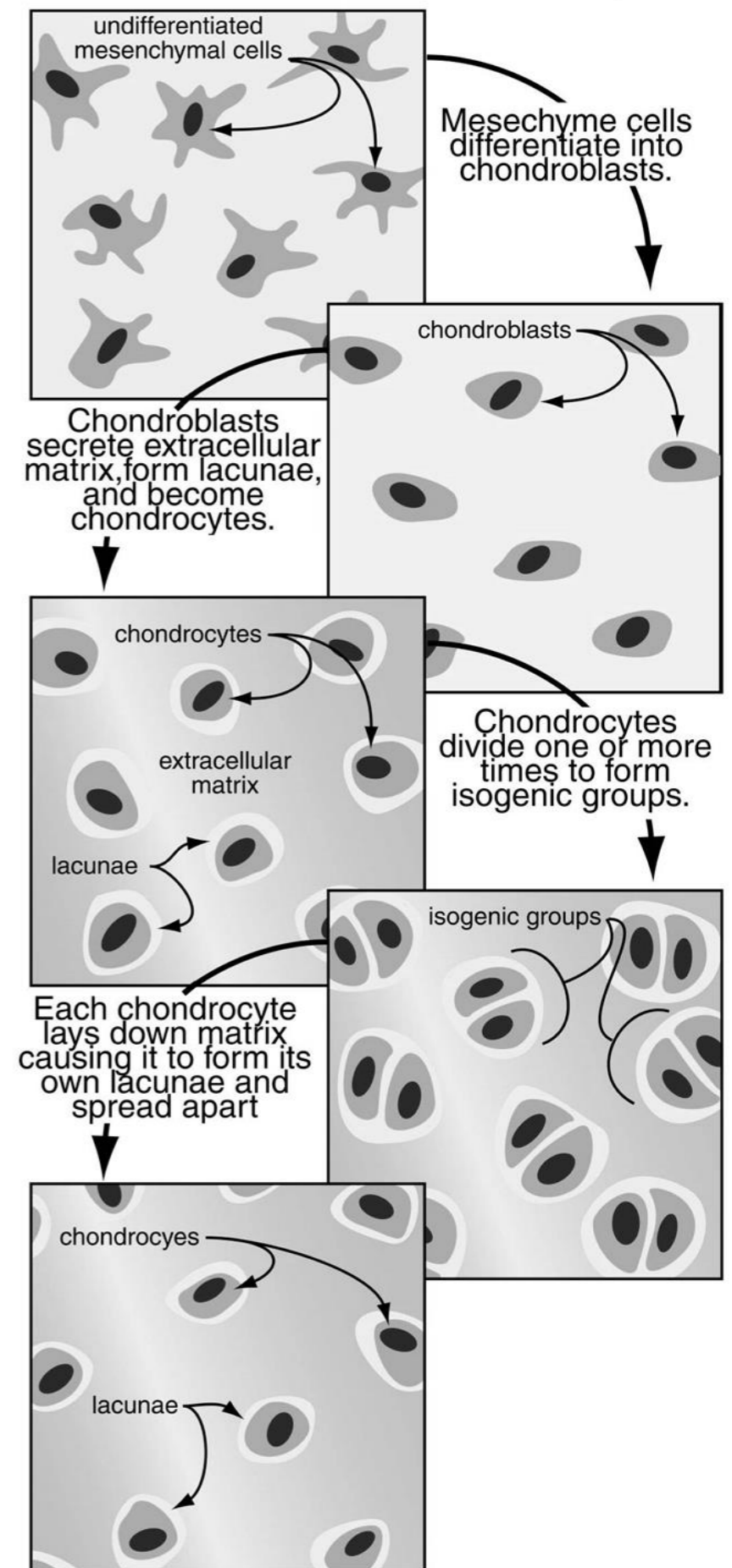
**In both interstitial and
appositional cartilage
growth,**

HISTOGENESIS OF CARTILAGE

1. Interstitial growth during embryogenesis

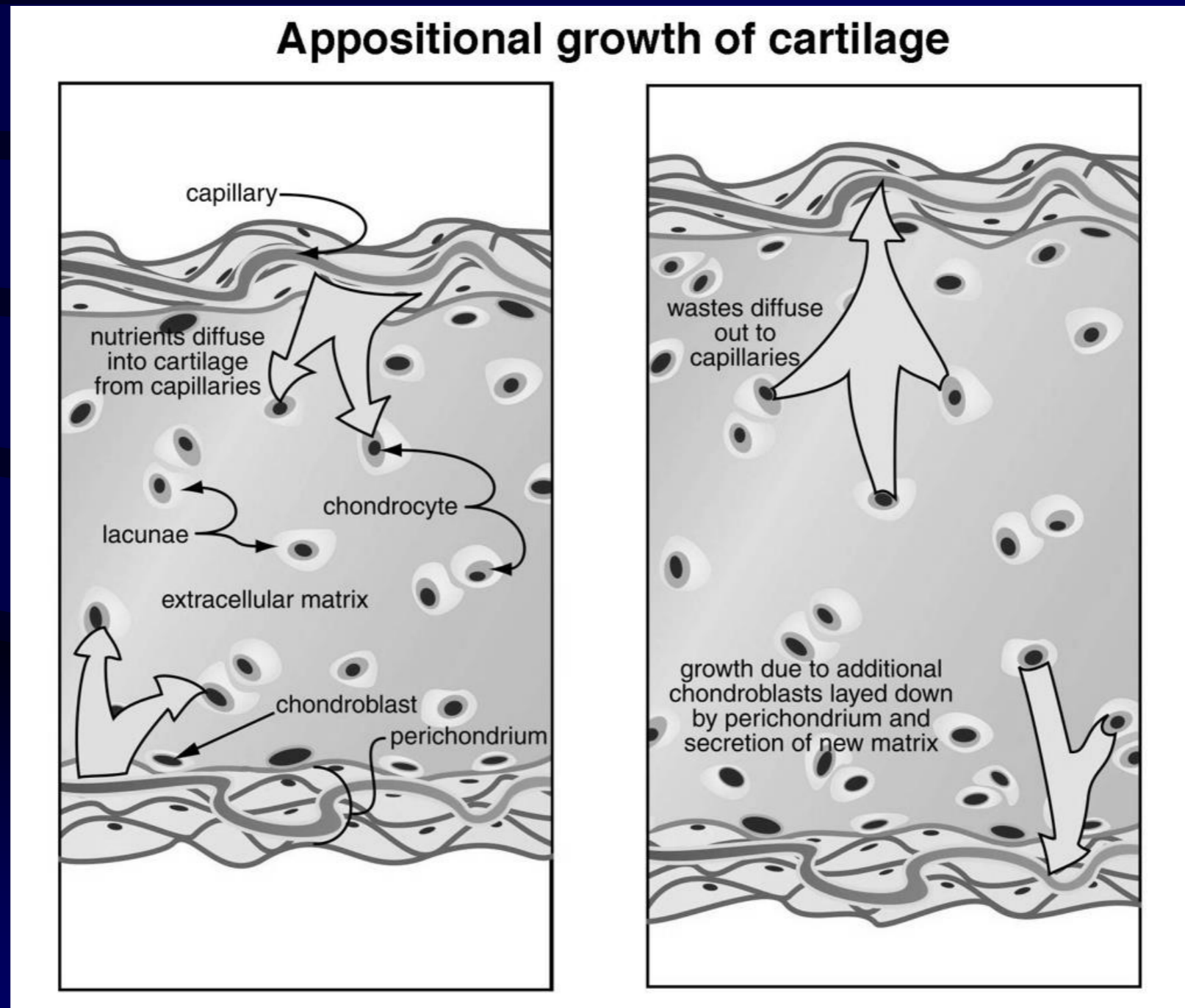
- **Mesenchymal** cells will aggregate and differentiate into closely knit clusters of **chondroblasts**.
- These cells will begin to secrete collagen and mucopolysaccharide matrix.
- The matrix secretion will cause the chondroblasts to be pushed apart.
- As this occurs, the cartilage cells will undergo divisions and continue to secrete matrix.
- In the case of hyaline cartilage, this will result in some small clusters of chondrocytes within the developing matrix - **isogenic groups**.
- Eventually the ground substance becomes more rigid and the cartilage cells (now **chondrocytes**) become trapped in lacunae and can no longer be pushed apart by secretion.
- This sort of growth of cartilage is termed **interstitial growth** due to the secretion of matrix into the interstitial regions between cells or groups of cells.

Interstitial Growth of Cartilage



2. Appositional growth of cartilage during embryogenesis and subsequent juvenile development.

- A layer of chondroblasts can lay down matrix at the outer edge of a mass of growing cartilage.



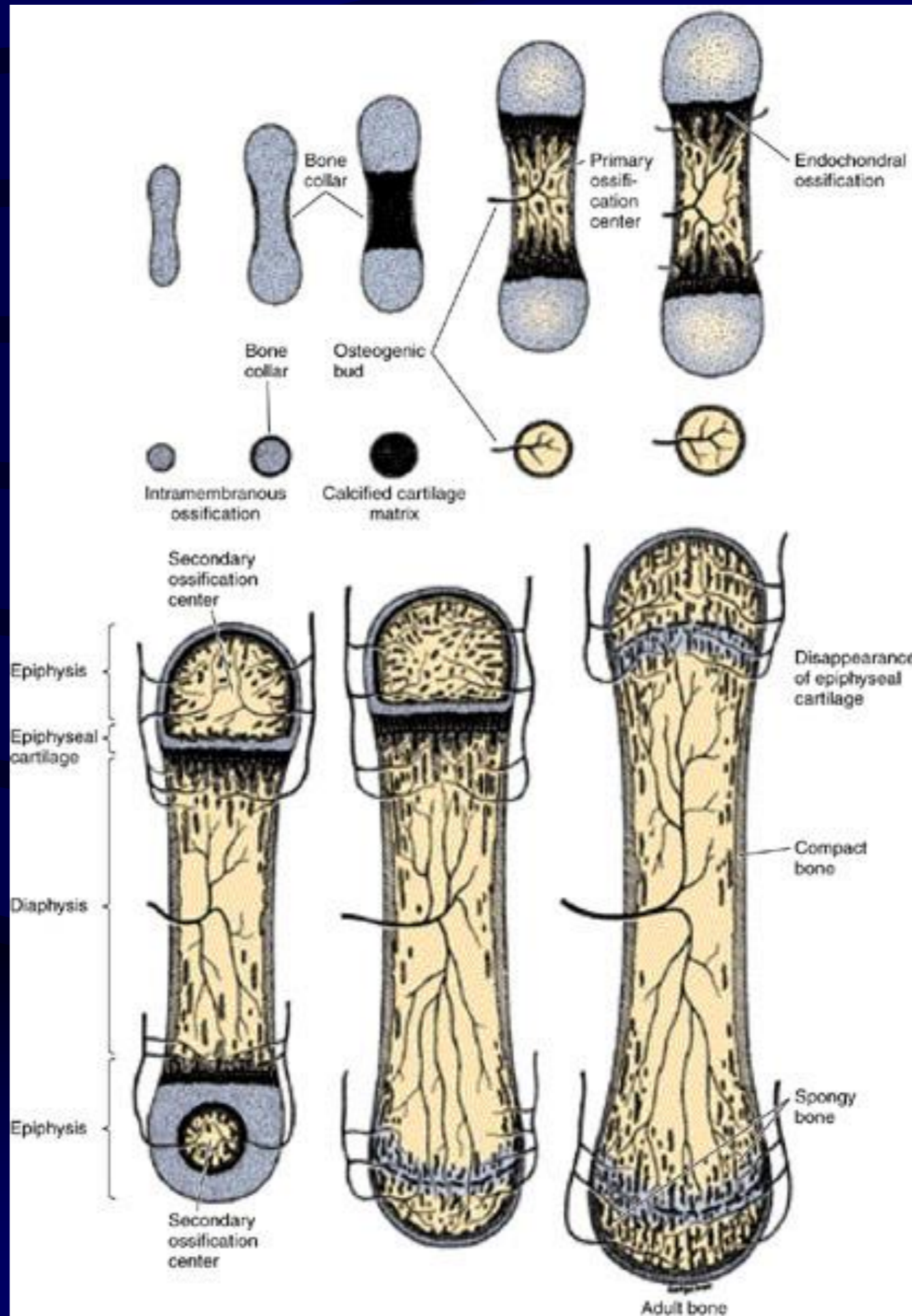
3. In both interstitial and appositional cartilage growth,

A: As the cartilage continues to grow, the central regions become more rigid due to secretory products

and the cells in this region take on the characteristics of mature chondrocytes.

B: The outer edge of the cartilage mass becomes invested with additional mesenchymal cells (most differentiate into fibroblasts) to form a specialized connective tissue covering for the cartilage known as perichondrium. Does not occur on articular or fibrous cartilage

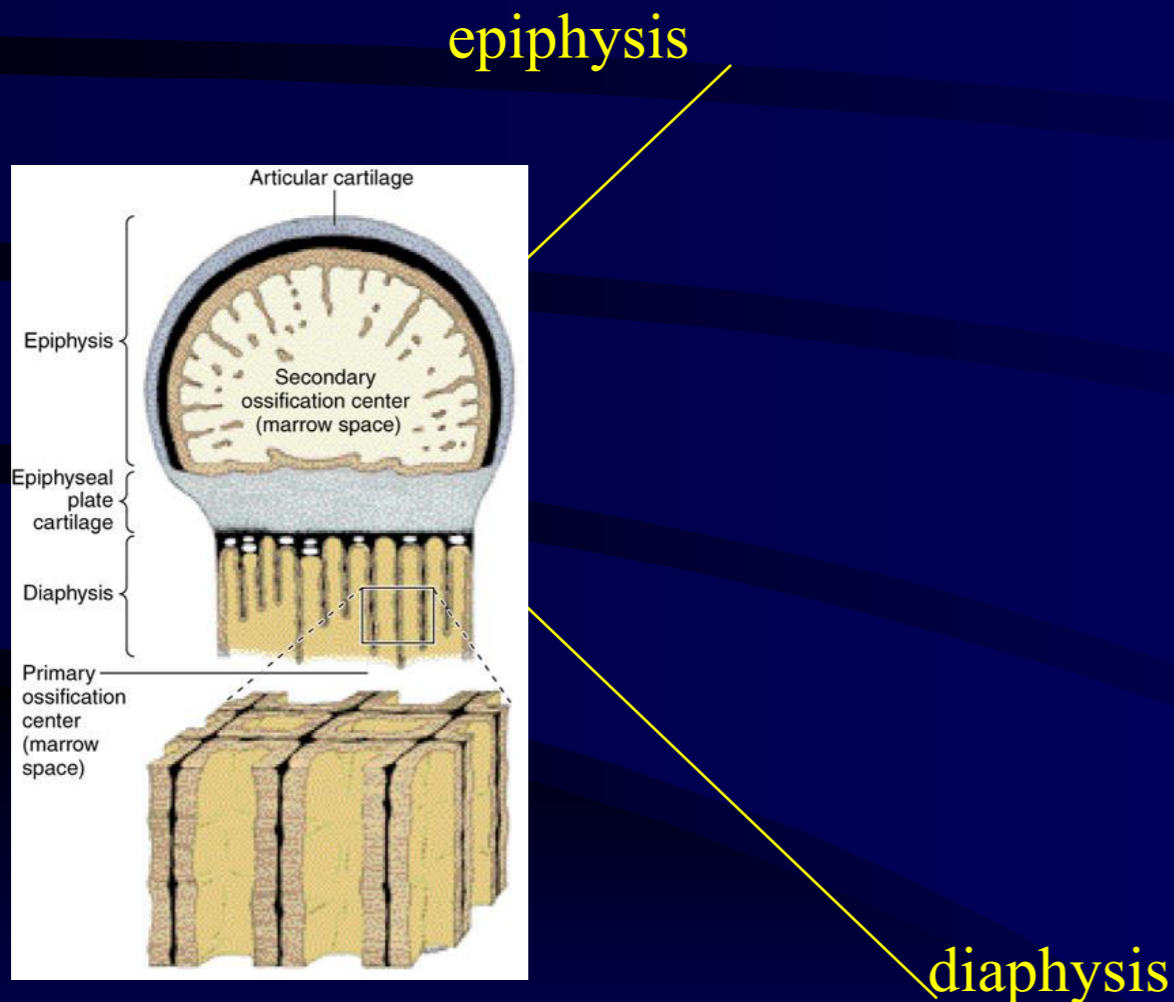
C: Appositional growth can continue after the perichondrium is formed. This is accomplished by chondroblasts (and perhaps fibroblasts) associated with the perichondrium secreting additional ground substance.



BONE

Bone is one of the hardest substances in the body. You might look at it and think it is a dead, mineralized material; however, it's important to realize that bone is a living tissue composed of cells and their associated extracellular matrix. **IT IS A CONNECTIVE TISSUE!**

The structure of bone



Bone terminology:

Endochondral bone

Membranous bone

Compact bone

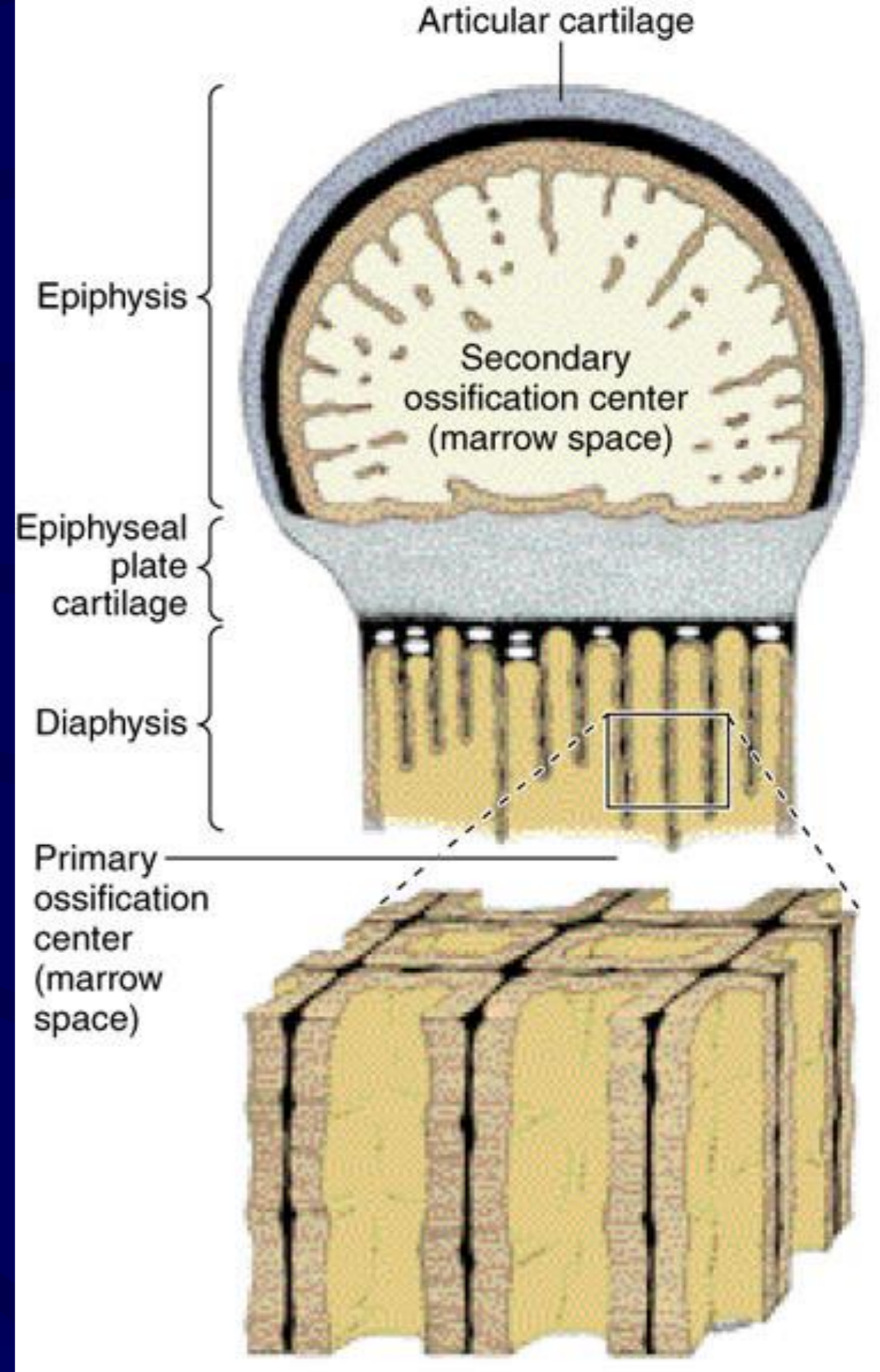
Spongy bone

Cancellous bone

Lamellar bone

Trabecular bone

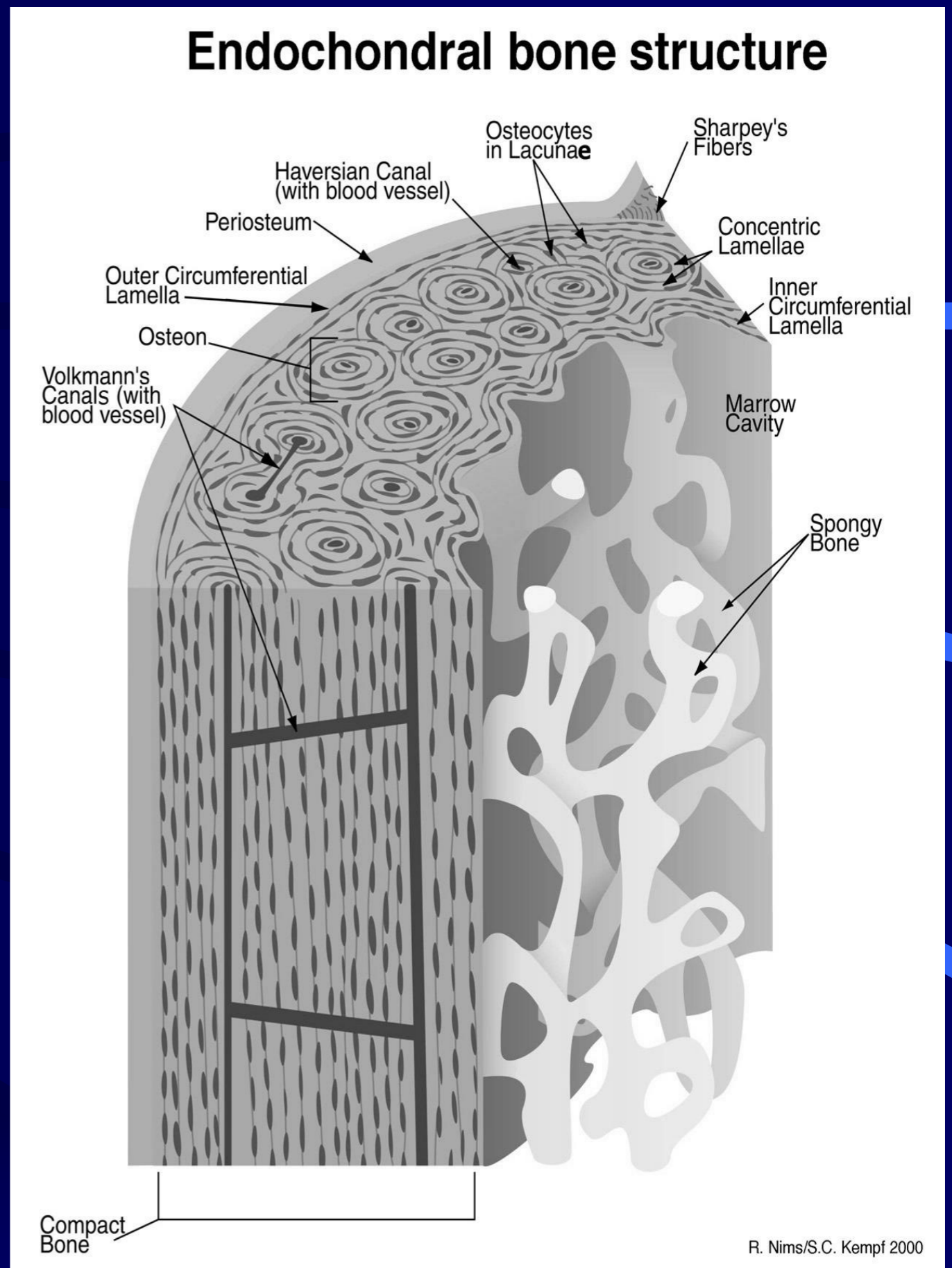
Schematic drawings showing the 3-dimensional shape of bone in the epiphyseal plate area. Hyaline cartilage is stippled; calcified cartilage is black, and bone tissue is shown as yellow hatched areas. The upper drawing shows the region represented 3-dimensionally in the lower drawing.



The structure of bone

1. Periosteum

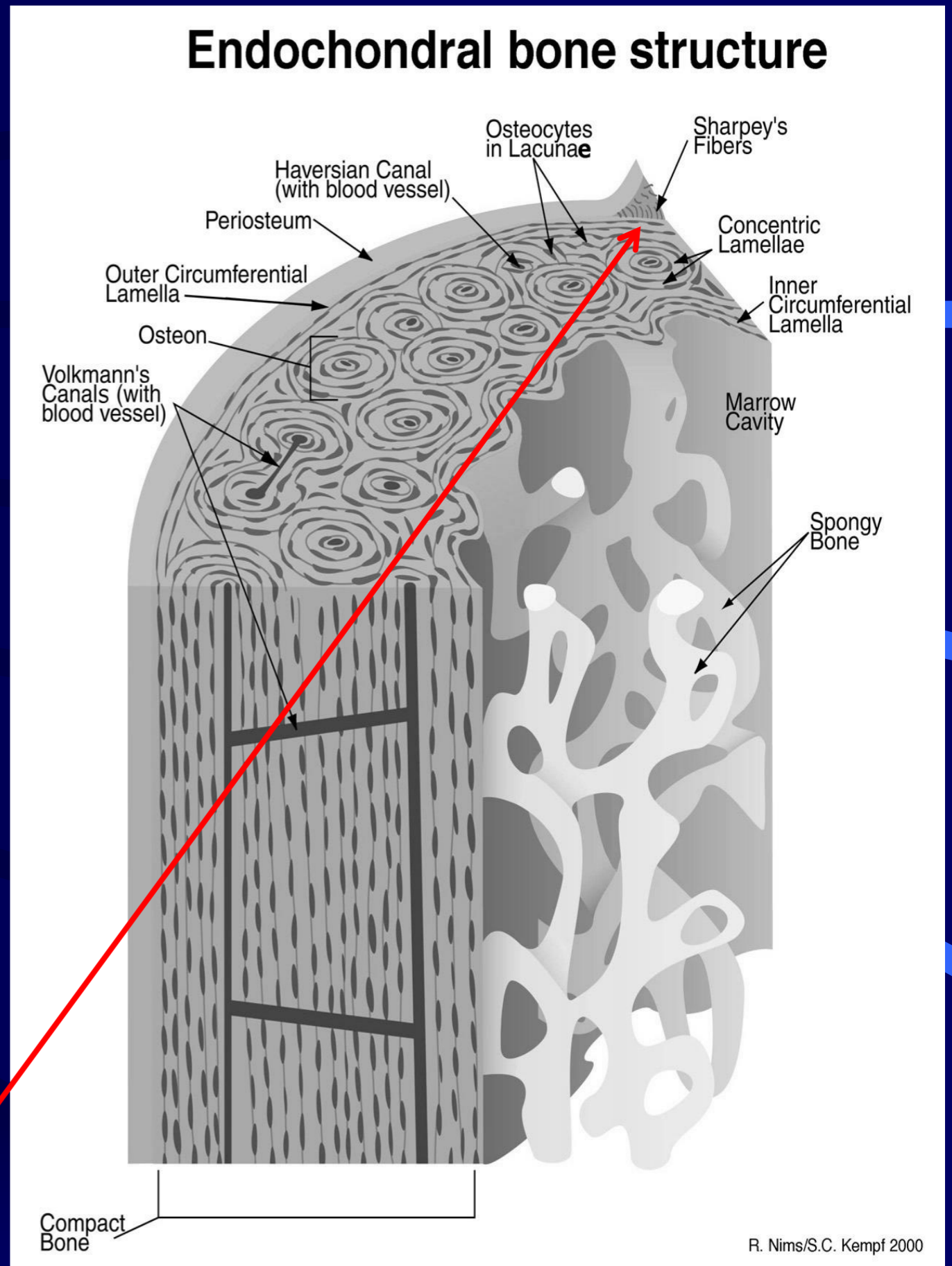
- **Outer layer of connective tissue that covers the bone, contains fibroblasts and a high concentration of collagen fibers.**



The structure of bone

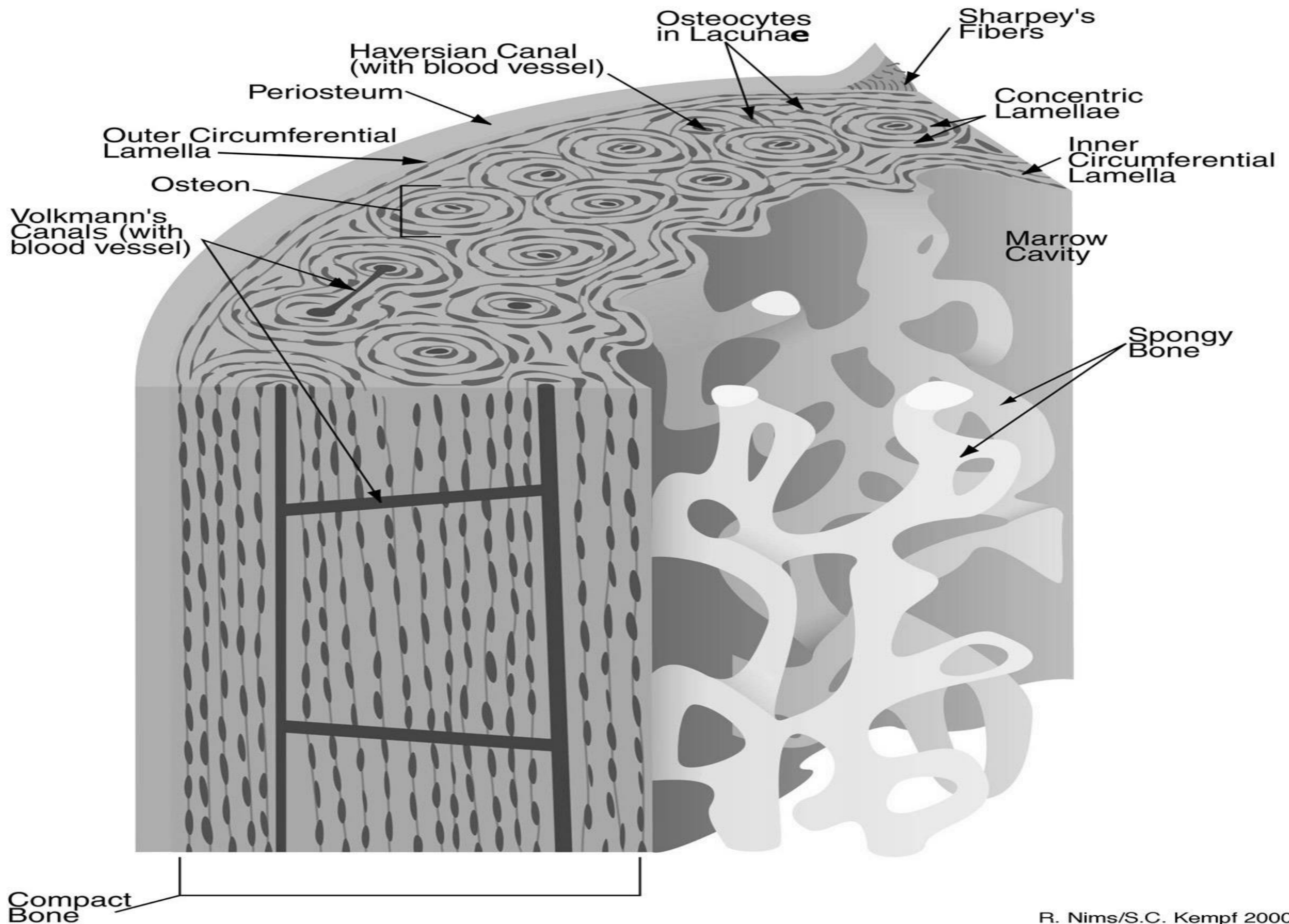
1. Periosteum

- **Two distinct layers.**
- **External layer very fibrous**
- **The internal layer is more cellular and vascularized**
- **Fibers penetrate the calcified bone matrix and bind periosteum to bone**
- **Sharpey's fibers**



- **The inner layer provides cells for bone histogenesis during development and in the healing of fractures.**

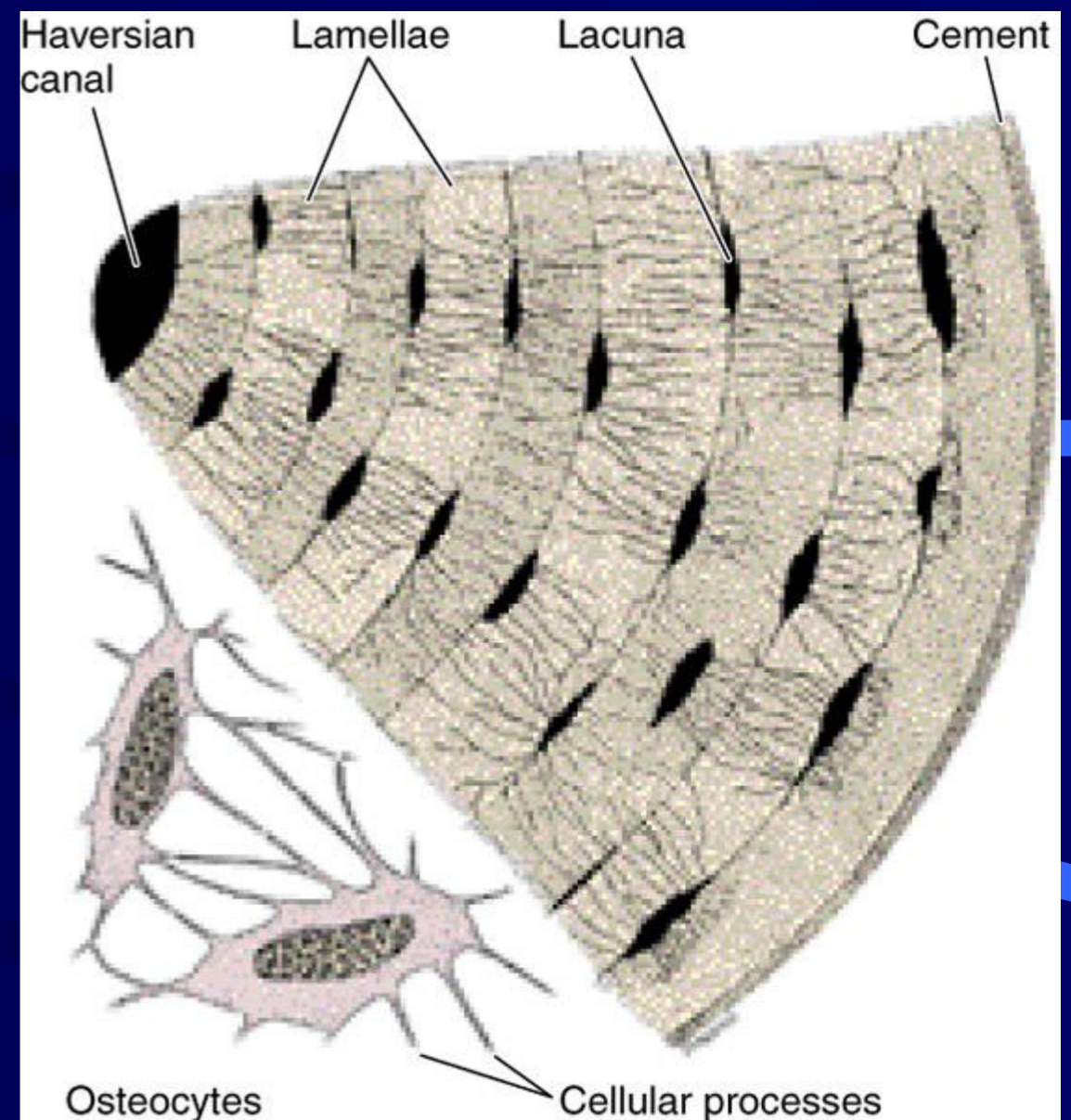
Endochondral bone structure



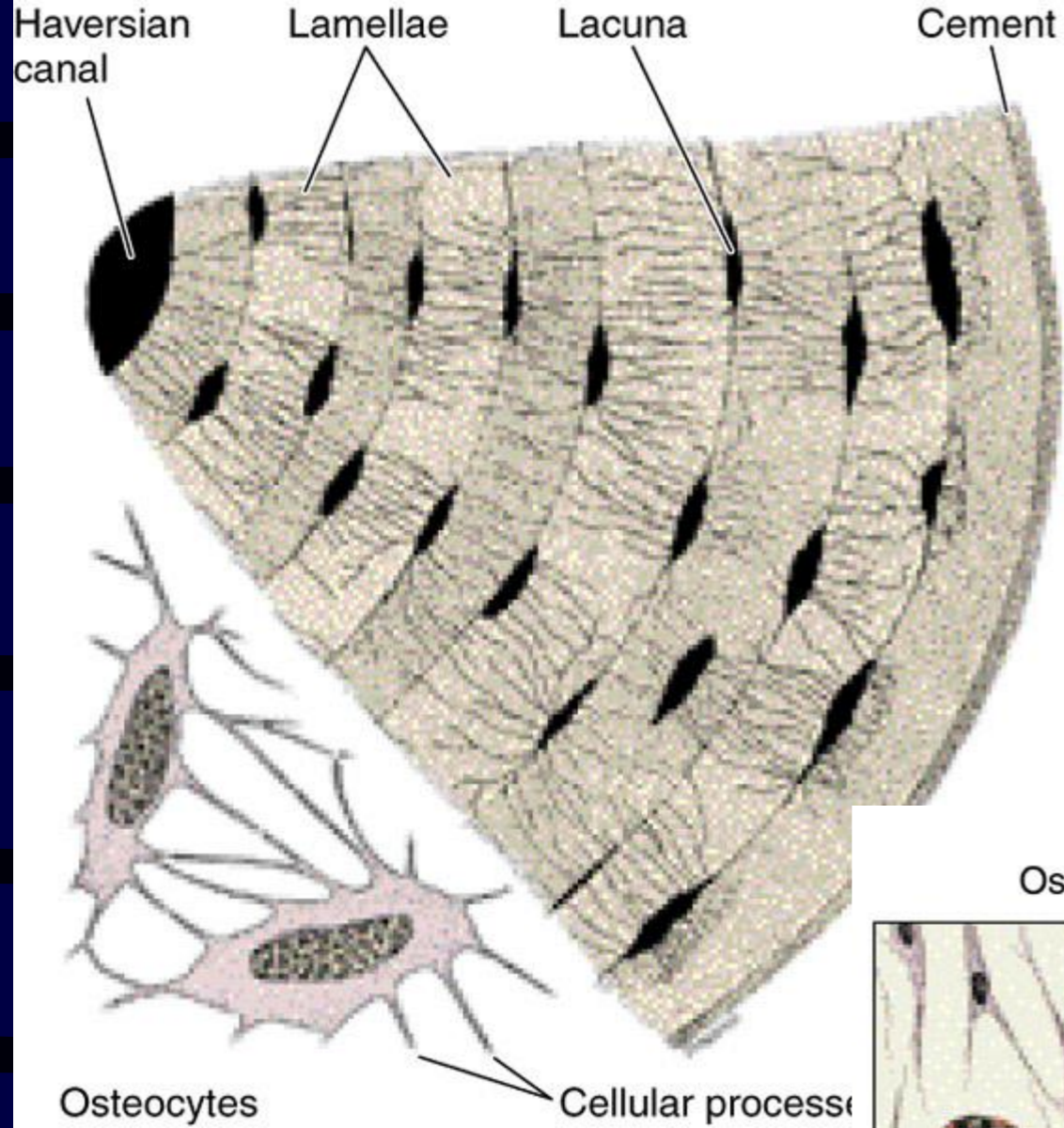
2 osteocytes and part of a haversian system. Collagen fibers of contiguous lamellae are sectioned at different angles.

Note the numerous canaliculi that permit communication between lacunae and with the haversian canals.

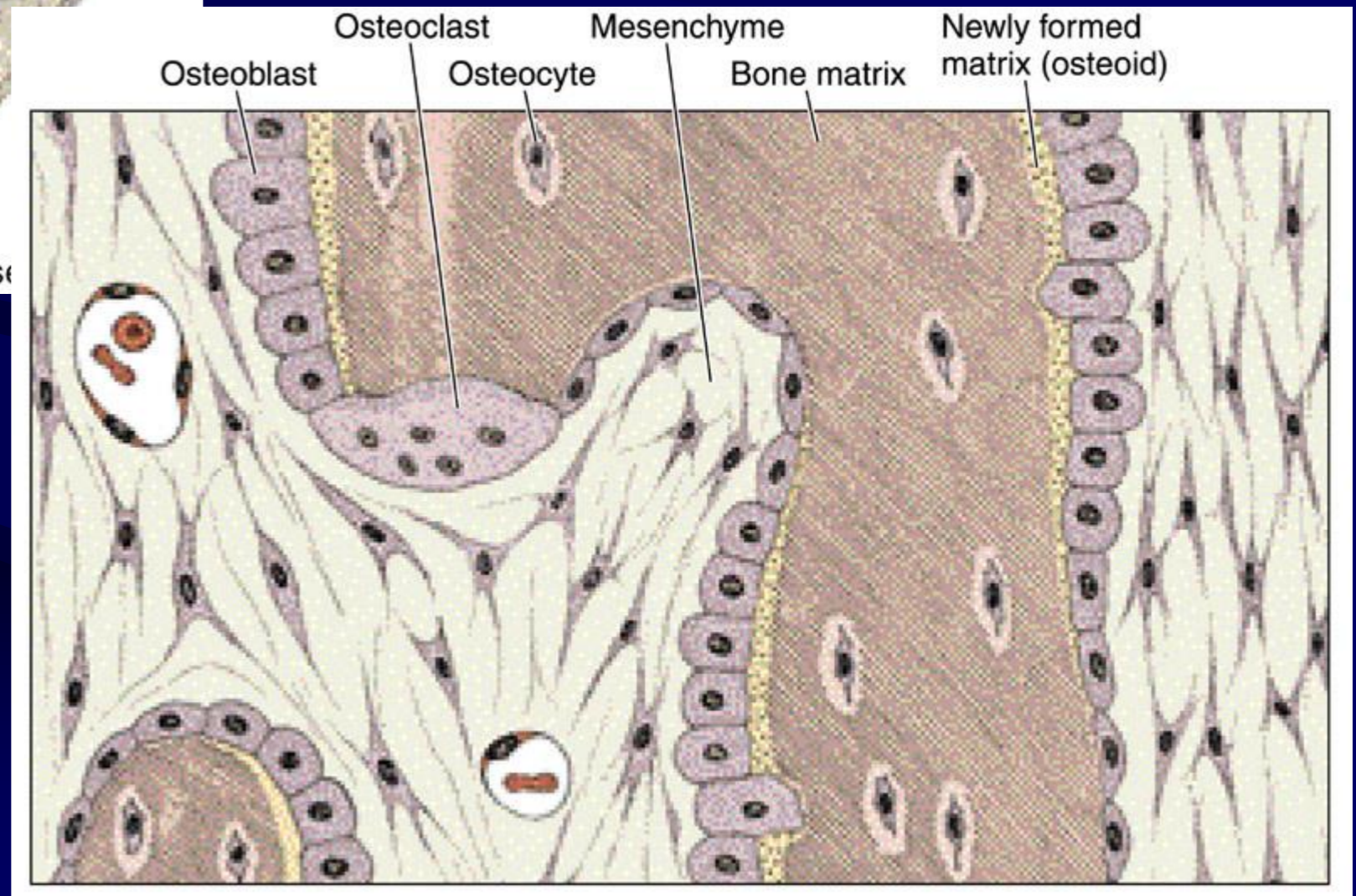
each lamella consists of multiple parallel arrays of collagen fibers. In adjacent lamellae, the collagen fibers are oriented in different directions.



The presence of large numbers of lamellae with differing fiber orientations provides the bone with great strength, despite its light weight



Junction of periodontal ligament and alveolar bone. **OC**, osteocytes; **SF**, Sharpey's fibers



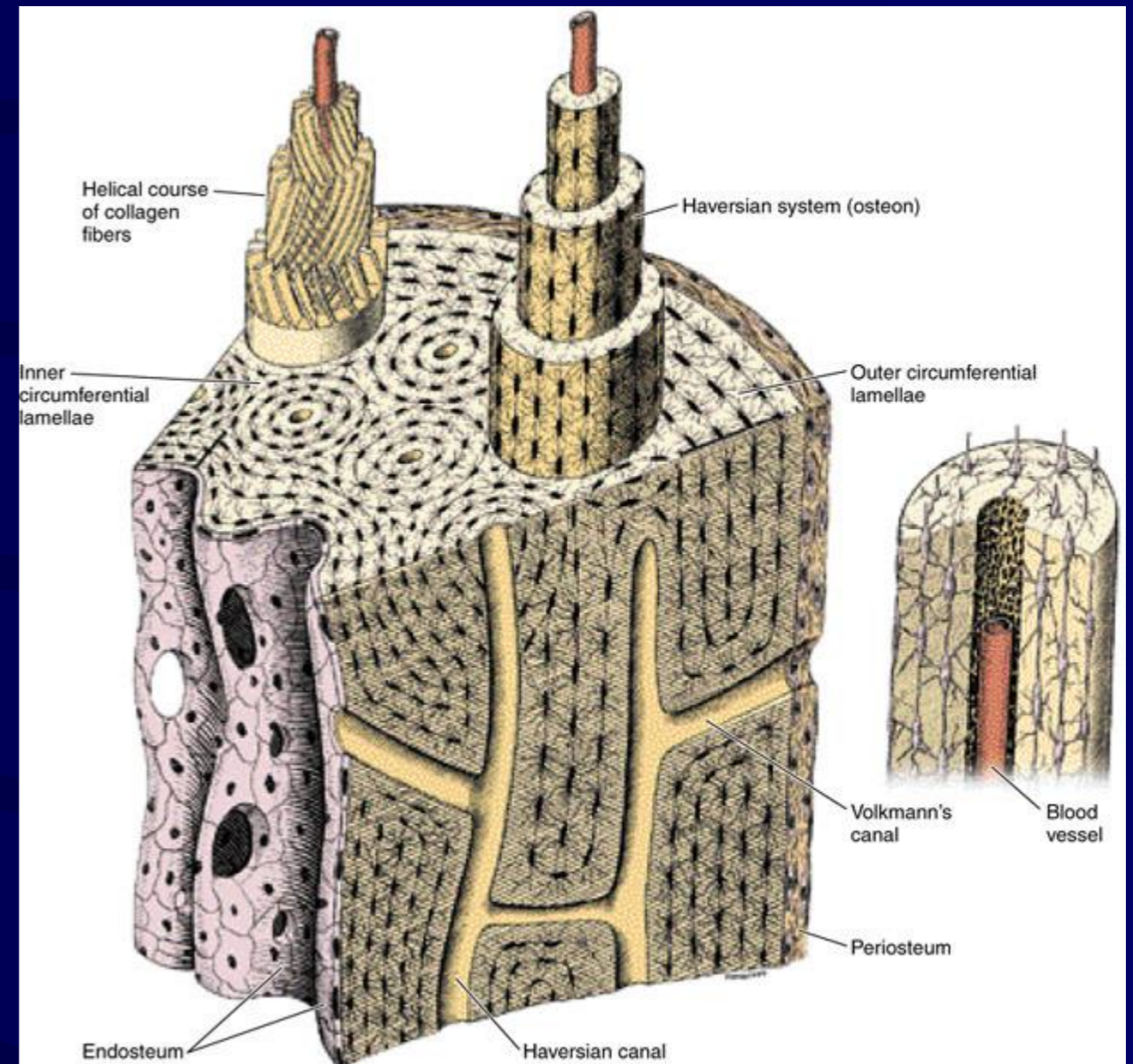
The structure of bone

2. Endosteum

- Lines the internal surfaces of bones - one cell thick

- Similar in general function to the periosteum, but much thinner

- Does not exhibit two distinct layers

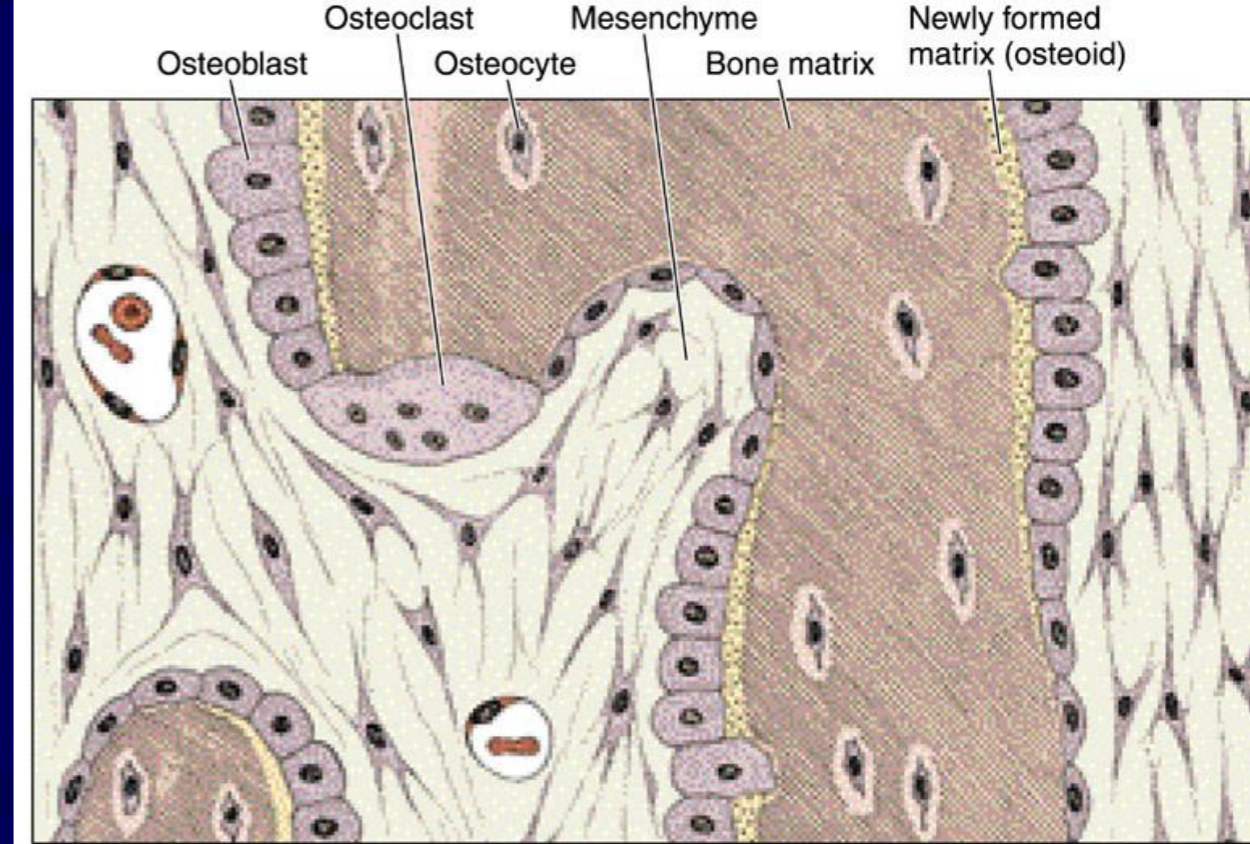


3. Important roles of the periosteum and endosteum are nutrition of bone cells and provision of **osteoblasts** for bone histogenesis and repair.

Bone Cell Types

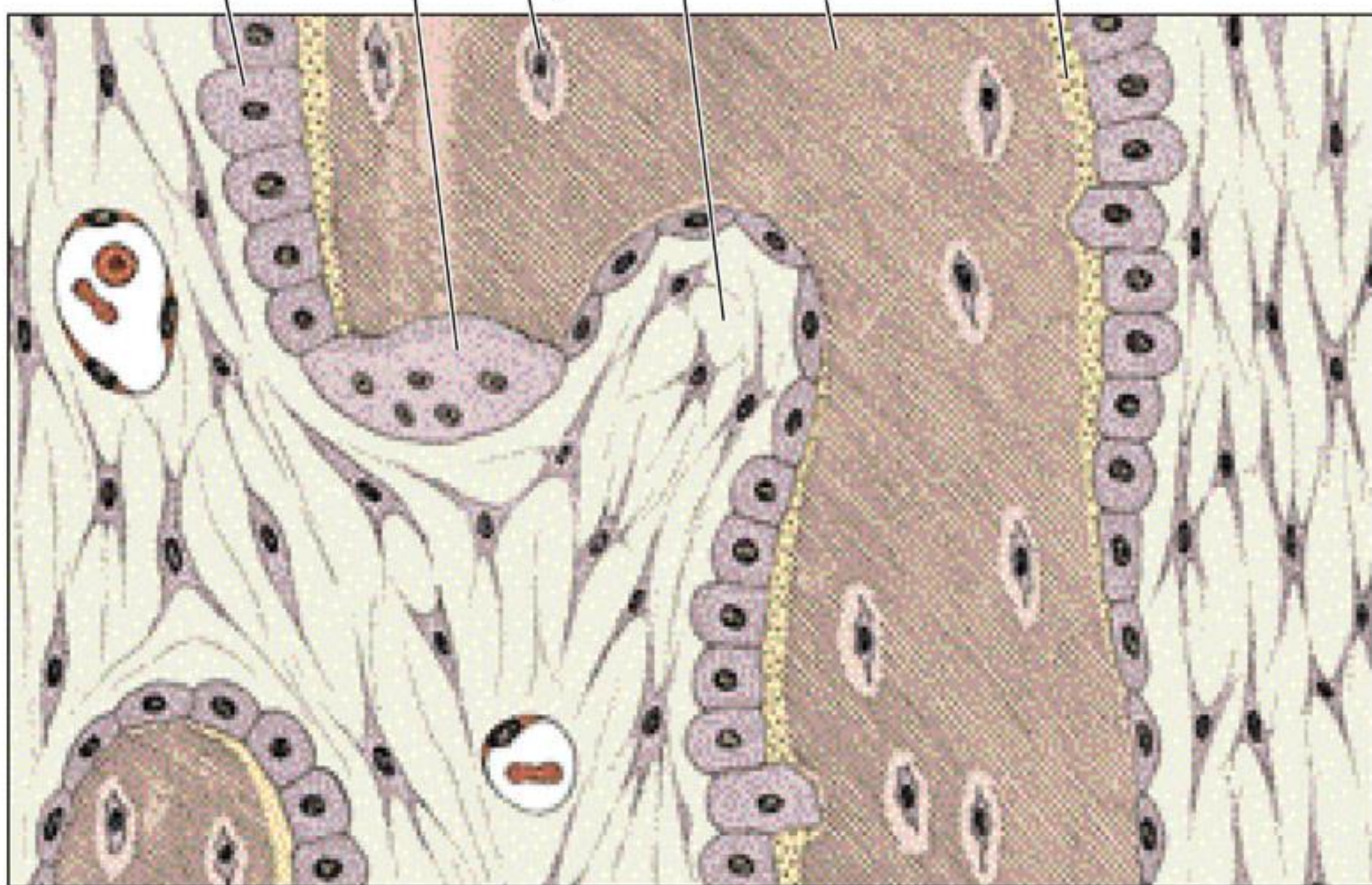
1. Osteoblasts

- Immature bone cells that synthesize and secrete the **osteoid matrix** that will calcify as the bones extracellular matrix.
- Matrix is composed of **glycoproteins** and **collagen**.
- Are located on the surfaces of forming bone and are **not yet embedded in the calcified extracellular (osteoid) matrix**.
- Ultrastructure shows organelle systems typical of protein secreting cells.



- Have cytoplasmic processes that bring them into contact with neighboring osteoblasts, as well as nearby **osteocytes**.

Osteoblast Osteoclast Mesenchyme Bone matrix Newly formed matrix (osteoid)

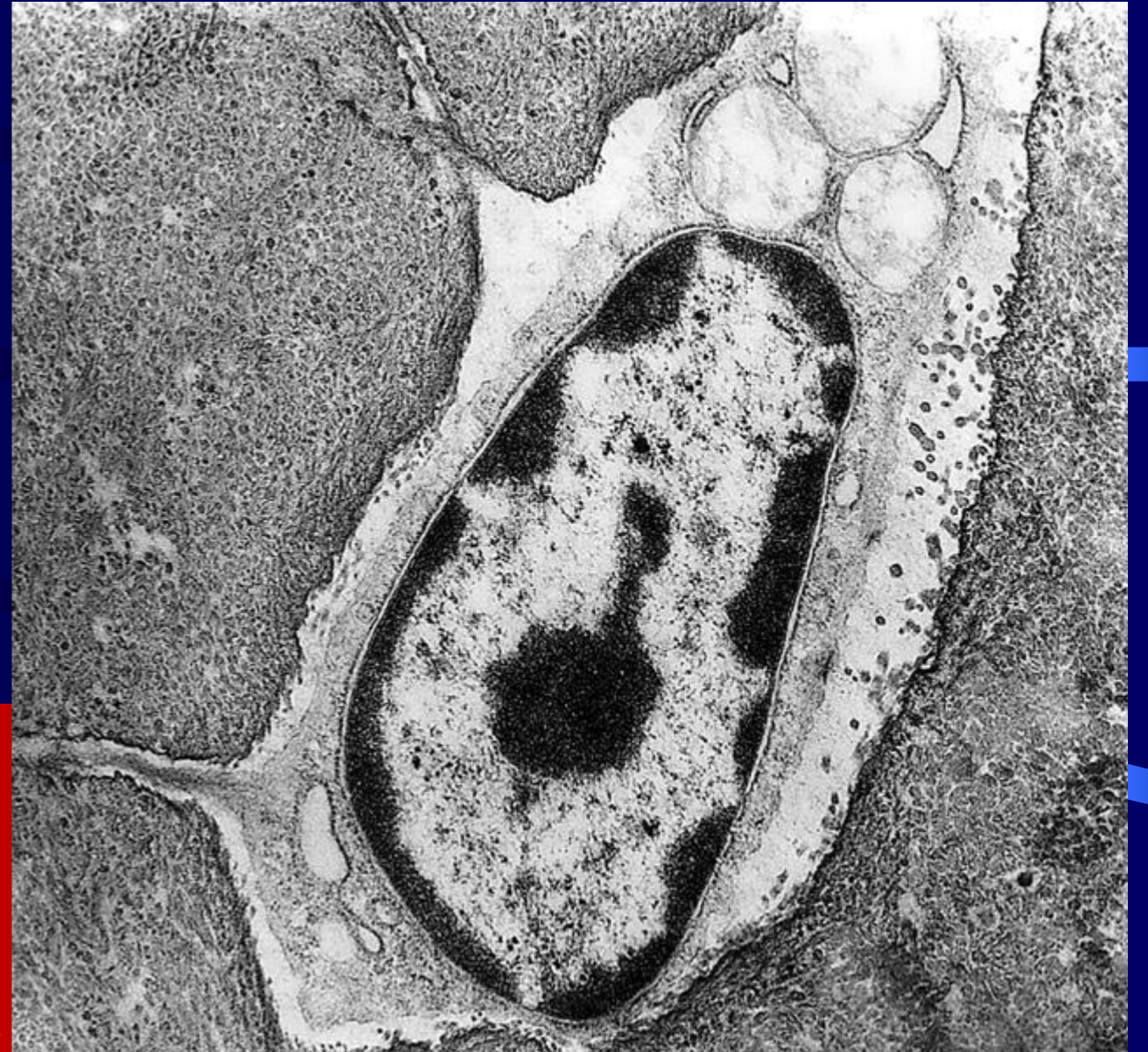

2. Osteocytes

- Mature bone cells - osteoblasts that have become embedded in calcified bone matrix.
- They reside in **lacunae** within the matrix
- Are in contact with neighboring osteocytes via cytoplasmic processes that extend through small tunnels called **canaliculi**.
- **Contacting cytoplasmic processes are characterized by gap junctions. This allows communication between osteocytes and is important in the transfer of nutrients to these cells since they generally are far removed from blood capillaries.**

Osteon = Haversian system (HS)

Haversian canal (in center of osteon/HS)



- **The cells are flattened and their internal organelles exhibit the characteristics of cells that have reduced synthetic activity.**

3. Osteoclasts

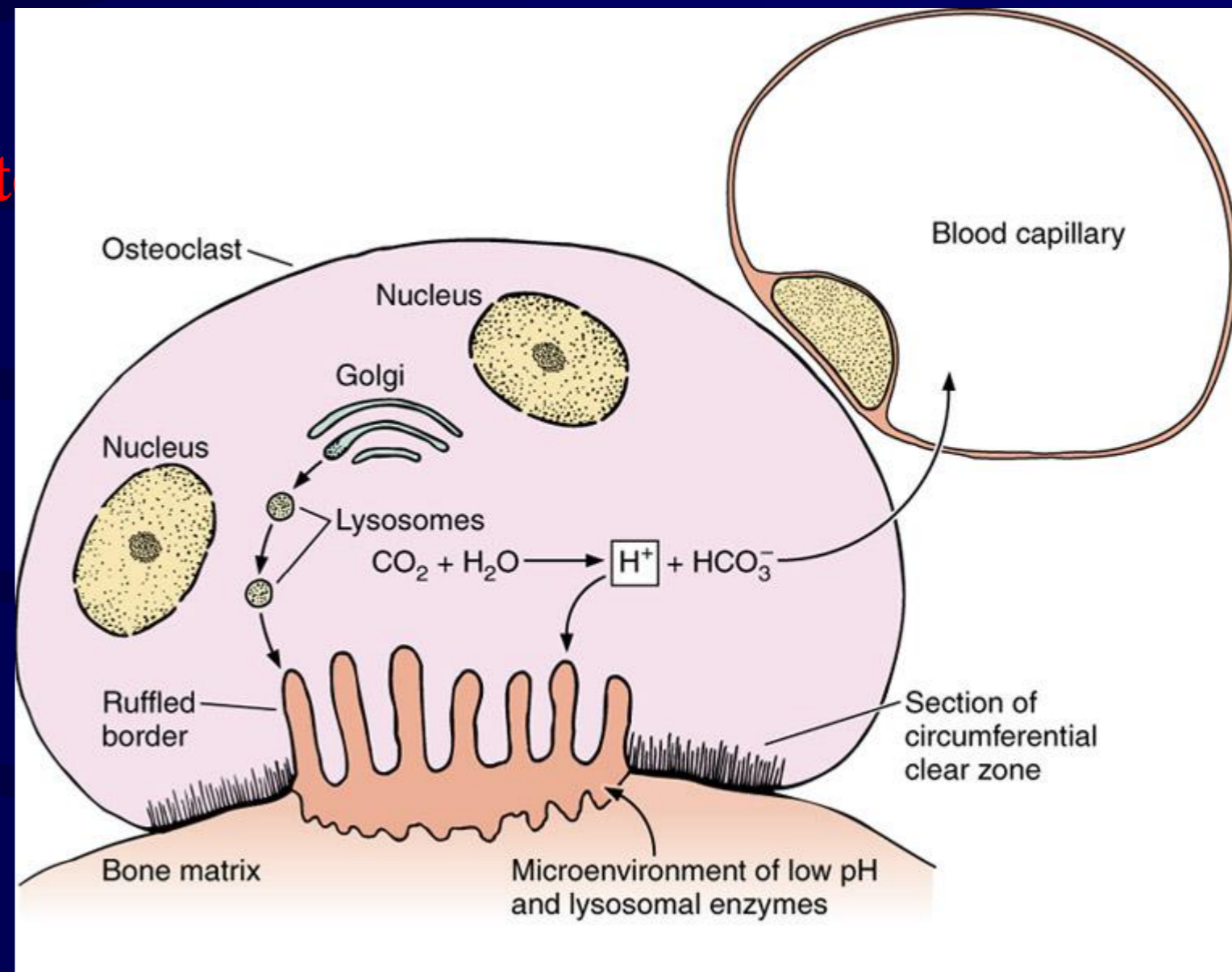
- These are large multinucleated cells

- Act to reabsorb bone

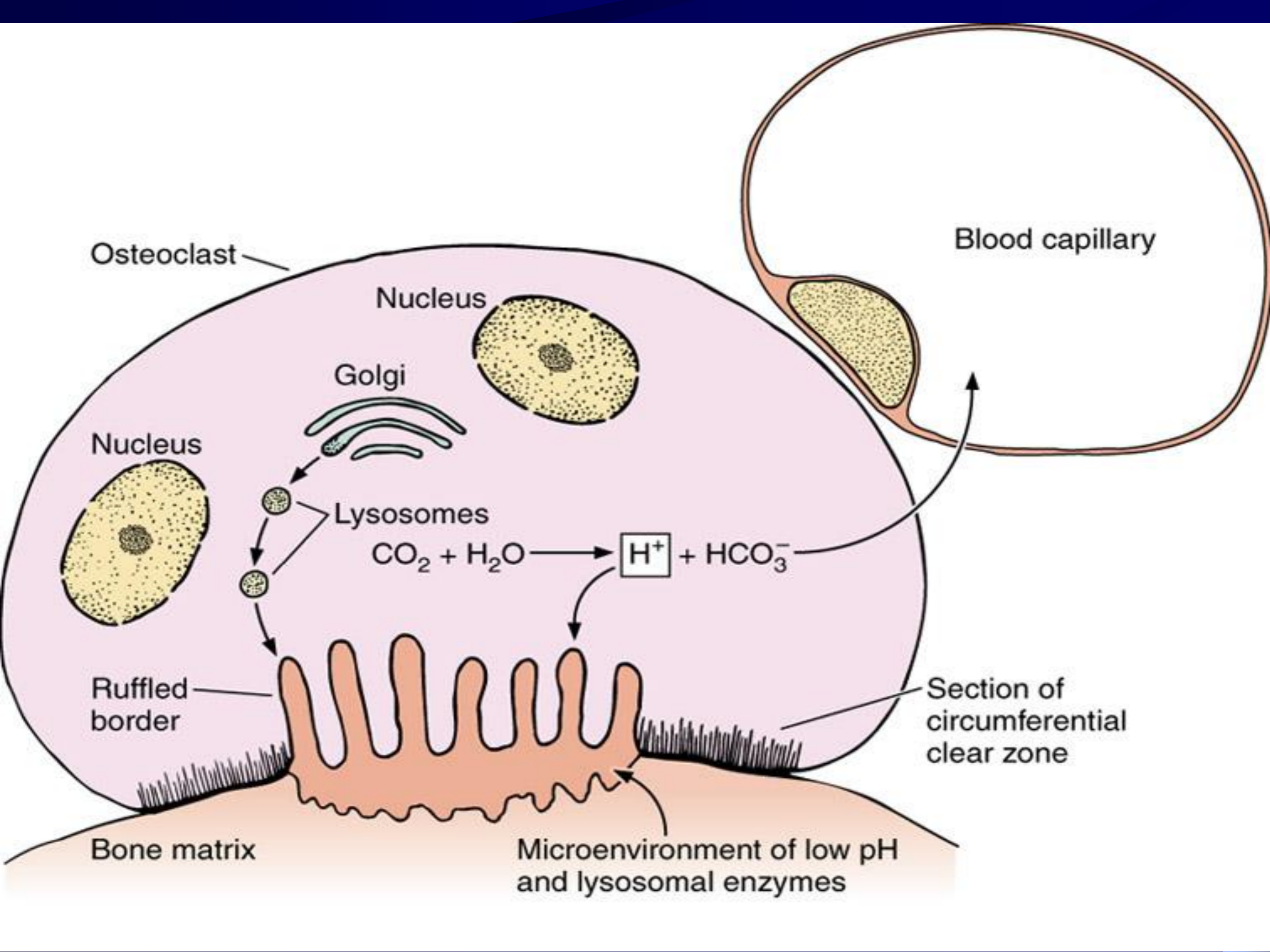
during specific stages in bone formation and healing, and during the continual reworking of internal bone architecture that occurs throughout life.

- Important in maintaining calcium balance in the body - respond to

calcitonin (secreted by parafollicular cells of thyroid/ultimobranchial bodies - lowers Ca^{++} concentration in blood),



and **parathyroid hormone** (secreted by parathyroid glands - raises Ca^{++} concentration in blood).



HISTOGENESIS OF SKELETAL STRUCTURE

Two modes of bone formation

1. Intramembranous - direct formation of bone structure with **no cartilage template** (e.g. flat bones of skull)

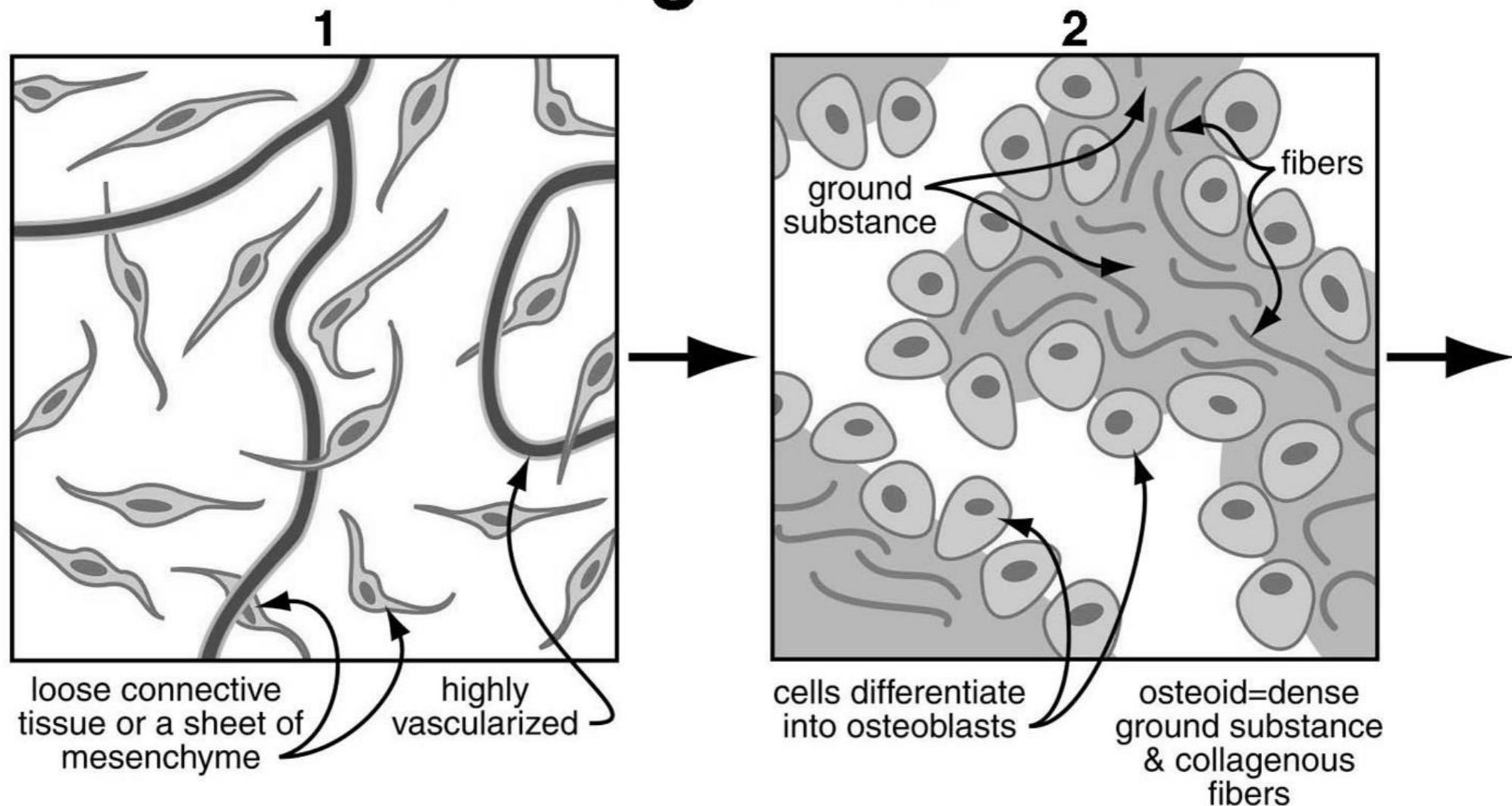
2. Endochondral - formed from **cartilage template** that is subsequently replaced by bone (e.g. vertebral column, long bones of limbs).

INTRAMEMBRANOUS BONE HISTOGENESIS

1. Mesenchymal cells aggregate and begin to secrete matrix that is characterized by bundles of collagen fibers.

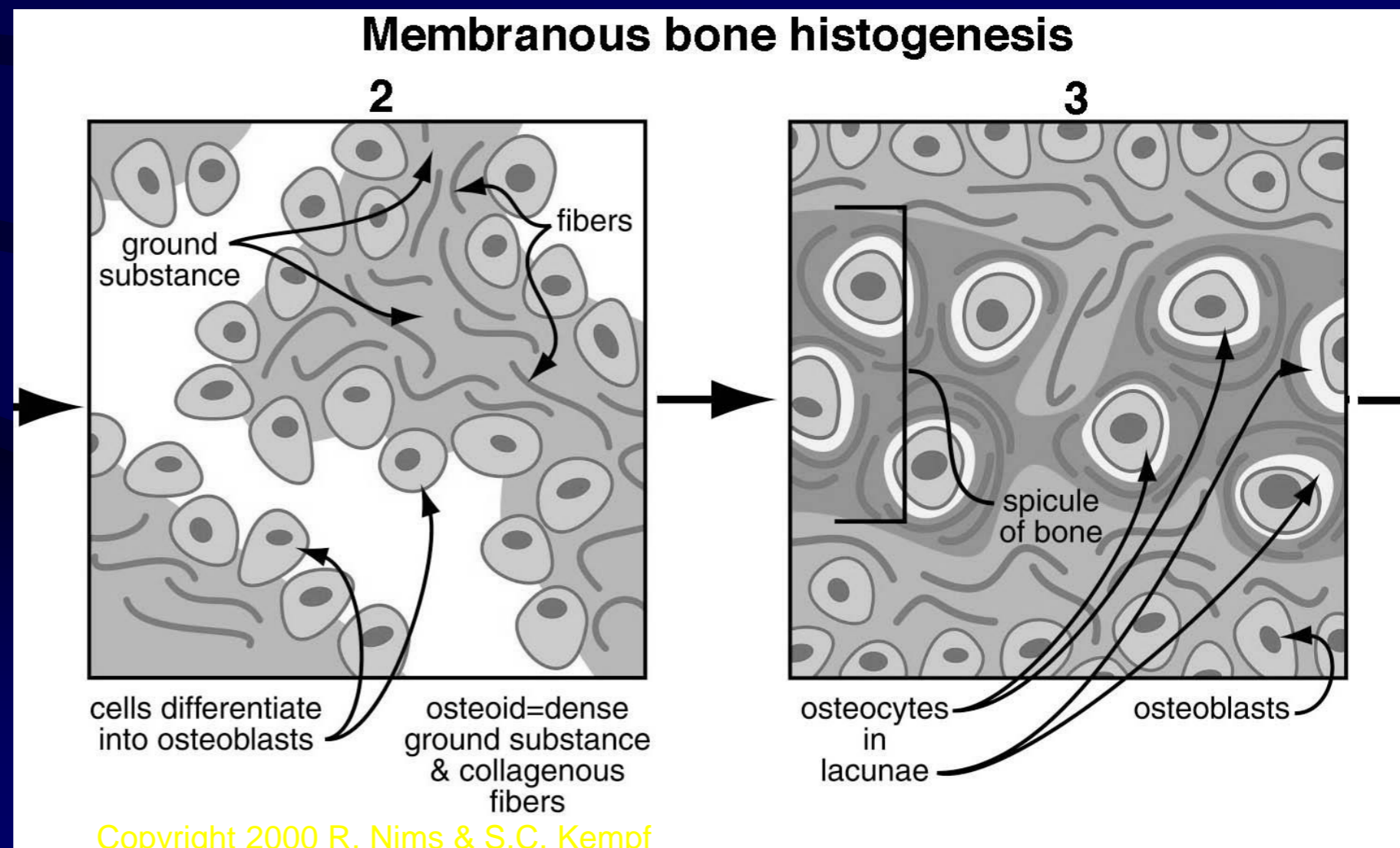
2. The mesenchymal cells lose their characteristic appearance and round up becoming true osteoblasts. The osteoblasts become oriented in an epithelial-like layer along the forming bone matrix.

Membranous bone histogenesis



3. The secreted osteoid matrix has a high affinity for calcium salts, that are brought into the area of bone formation by circulatory system. These deposit within and on the matrix to form calcified bone.

4. As a strand of matrix is invested with inorganic salts it is called a spicule. Spicules fuse with one and other to form trabeculae. As the osteoblasts at the surface continue to secrete osteoid matrix, growth will continue in an appositional manner. This secretion by the osteoblasts is cyclic and results in layers of bone material called lamellae - lamellar bone.



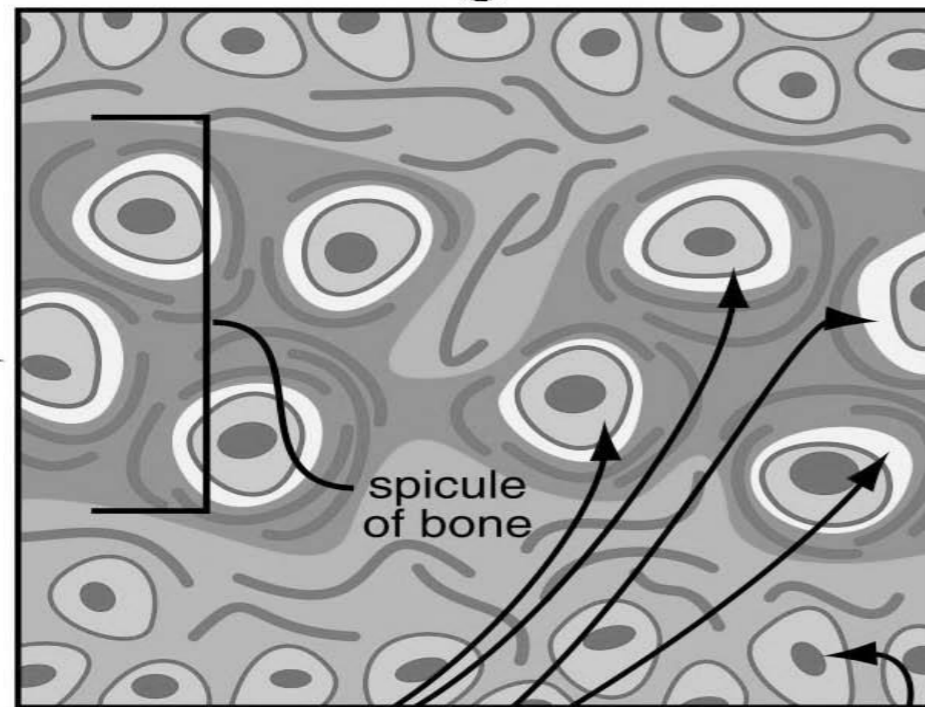
INTRAMEMBRANOUS BONE HISTOGENESIS

5. The initial spicule formation and the deposition of lamellae traps some of the osteoblasts within lacunae in the calcifying osteoid matrix. Once trapped, these cells are considered mature osteocytes or bone cells. Osteocytes have cellular processes that extend through canaliculi and contact similar processes of adjacent osteocytes

6. Growing adjacent trabeculae will contact and fuse forming the structure of the mature bone.

Membranous bone histogenesis

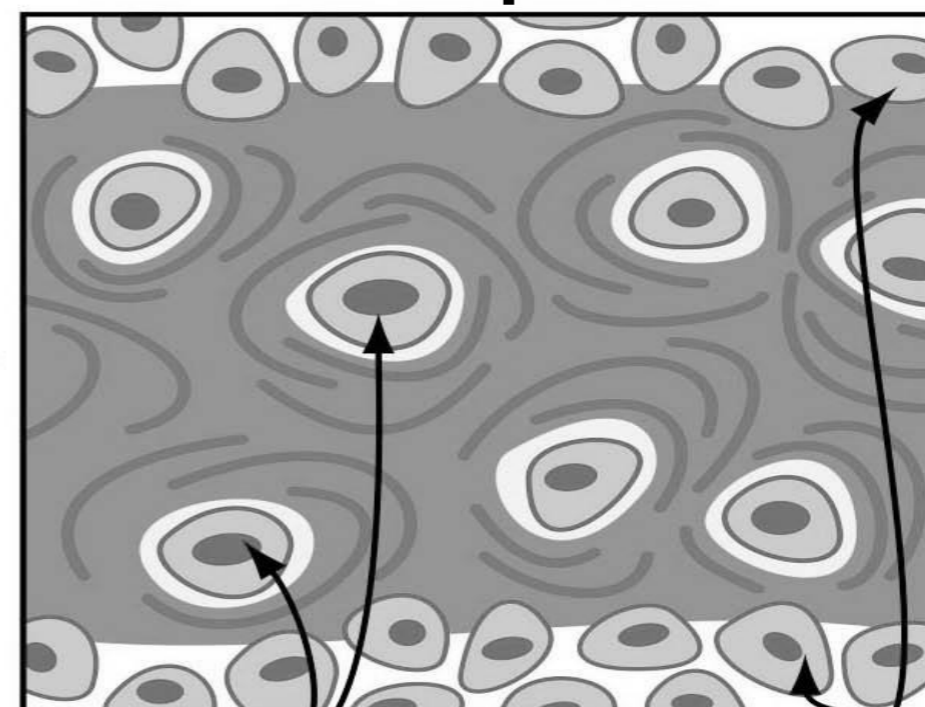
3



osteocytes
in
lacunae

osteoblasts

4



osteocytes
with
organized
matrix

osteoblasts

ENDOCHONDRAL BONE - what is it?

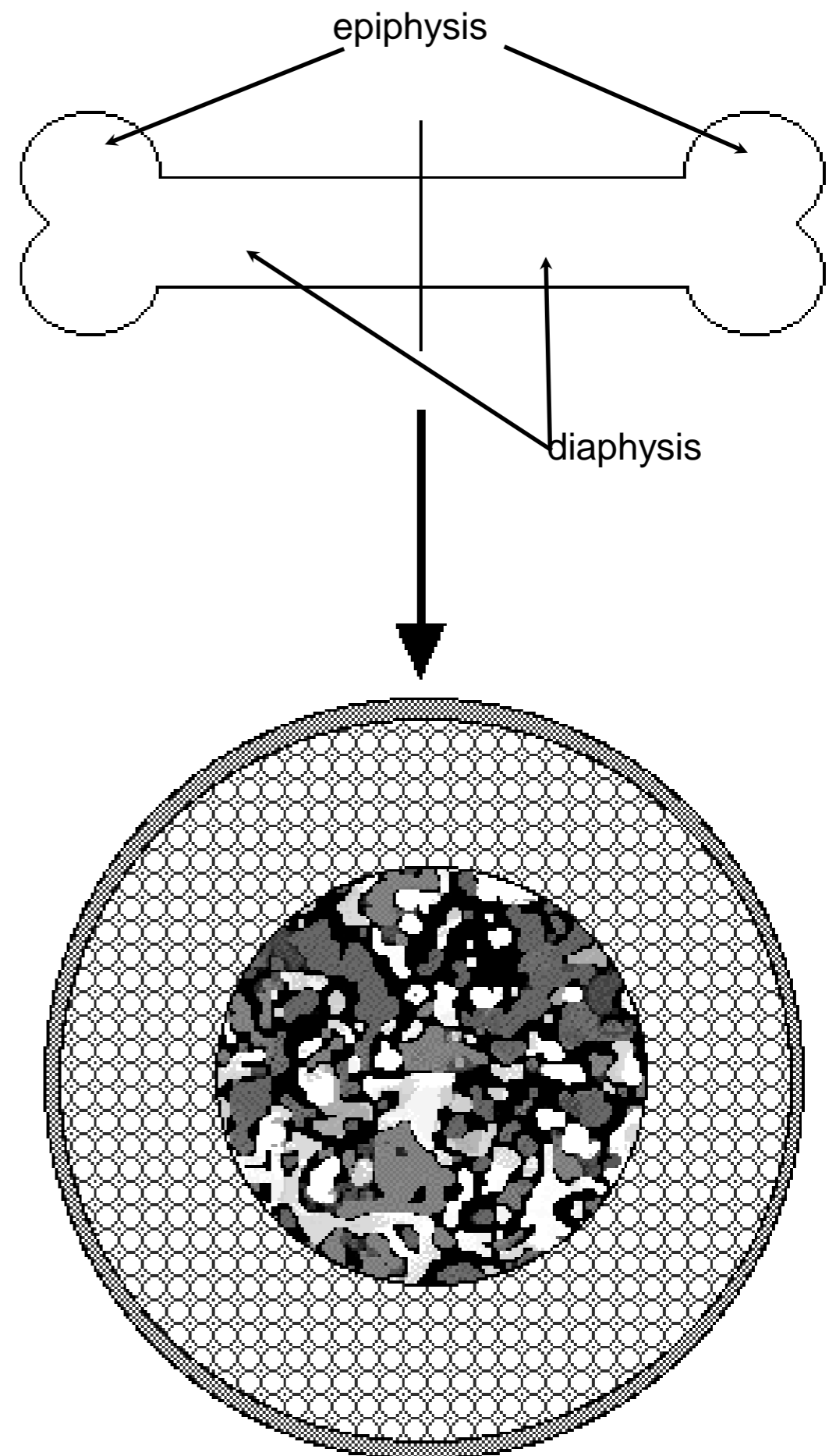
- 1. A template of hyaline cartilage is layed down prior to calcification and the establishment of true bone. During fetal development, this template is shaped like a miniature copy of the bone that will form from it.**
- 2. Most of the bones in the mammalian body are initially formed by endochondral means.**

Endochondral bone structure

1. Basic long bone structure.

- a. An outer layer of connective tissue called the **periosteum**.
- b. A thick cortical layer of **compact (dense) bone**.
- c. A medullary or central volume of **spongy (cancellous) bone** where the bone marrow resides.

2. As discussed osteocytes of this tissue are embedded within a matrix that consists of organic (osteoid matrix) and inorganic (calcium phosphate salts) components.



Endochondral bone structure

Compact bone - 2 regions

1. **Periosteal lamellae** - layers secreted, as the bone grew, by osteoblasts associated with the inner side of the periosteum - appositional growth - circumferential lamellae - lamellar bone. and

2. Inner component consisting of **multiple osteons and interstitial bone**

Osteons:

a. **concentric sub-layers (lamellar bone)** surrounding longitudinal tunnels for blood vessels and nerves that are called the **haversian canals**

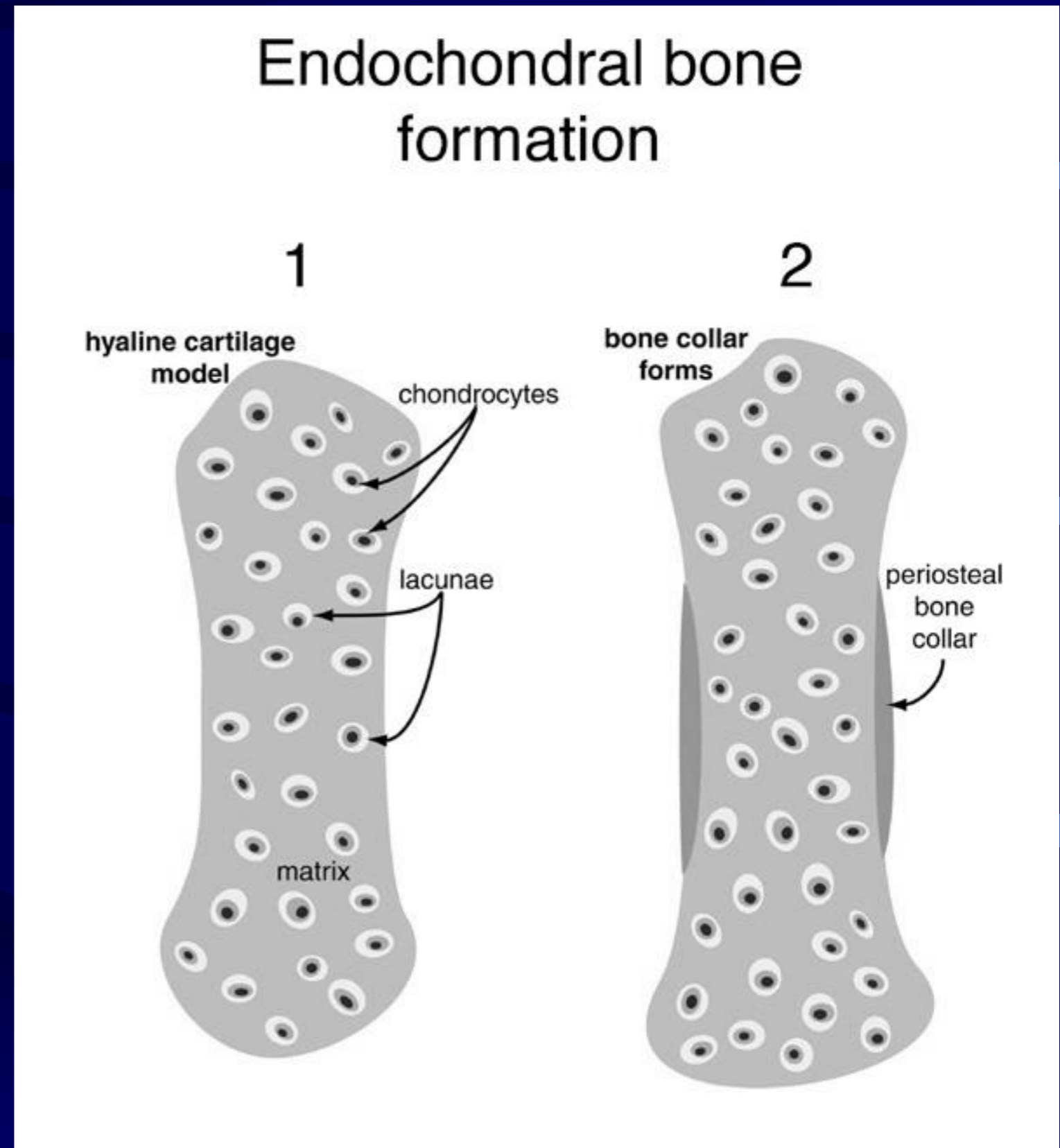
Gross long bone structure.

ENDOCHONDRAL BONE HISTOGENESIS

1. First step in endochondral bone formation is the histogenesis of a hyaline cartilage miniature of the bone.

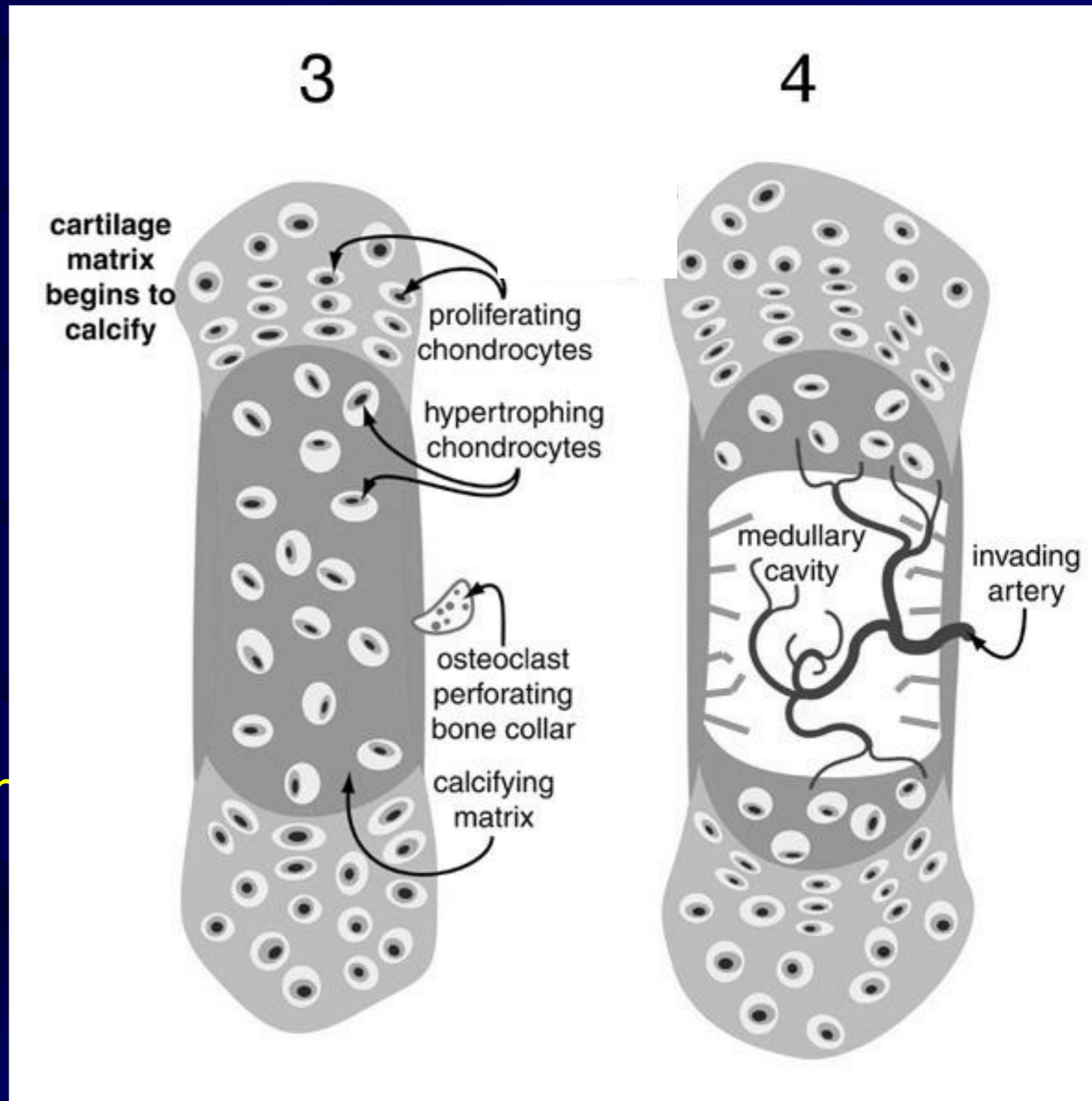
2. Actual osteogenesis (bone ossification) begins with the establishment of a periosteum (fibroblasts/ mesenchyme cells) on the shaft (or diaphysis) of the cartilage template.

3. Osteoblasts from the inner layer of the periosteum lay down an intramembranous collar of bone around the circumference of the cartilage diaphysis.



4. This is followed by the degeneration of the chondrocytes within the cartilage matrix of the shaft/diaphysis. As these cells are dying (apoptosis) they reabsorb some of the cartilage matrix.

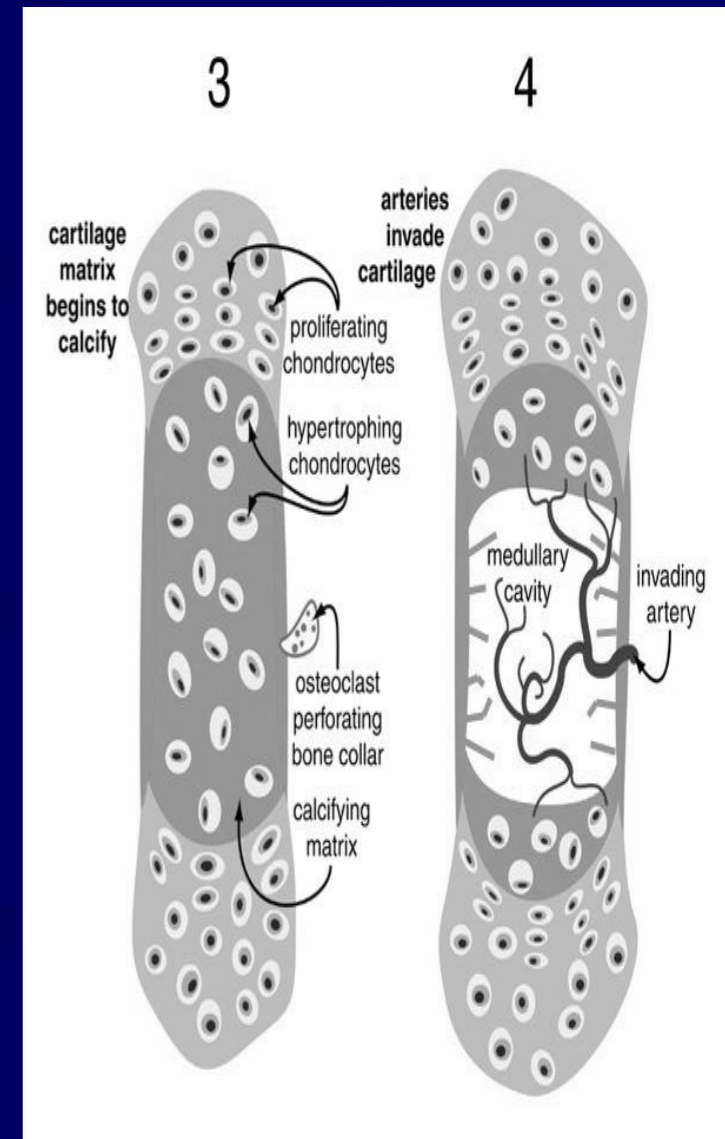
5. As this occurs, the remaining chondrocytes lose their ability to maintain the cartilage matrix and it becomes partially calcified. The end result is an area of porous calcified cartilage within the central regions of the diaphysis.



ENDOCHONDRAL BONE HISTOGENESIS

6. As this is occurring, osteoclasts, that have arrived in the area via the circulatory system, begin excavating passageways or tunnels through the intramembranous collar surrounding the diaphysis.

7. These passageways also provide a way for blood vessels, nerves and undifferentiated mesenchyme cells to enter the remnants of the cartilage matrix. The mesenchyme cells will differentiate into osteoblasts that will be involved in actual ossification of the bone. Blood stem cells also enter the bone as do chondroclasts that will digest the calcified chondroid matrix.

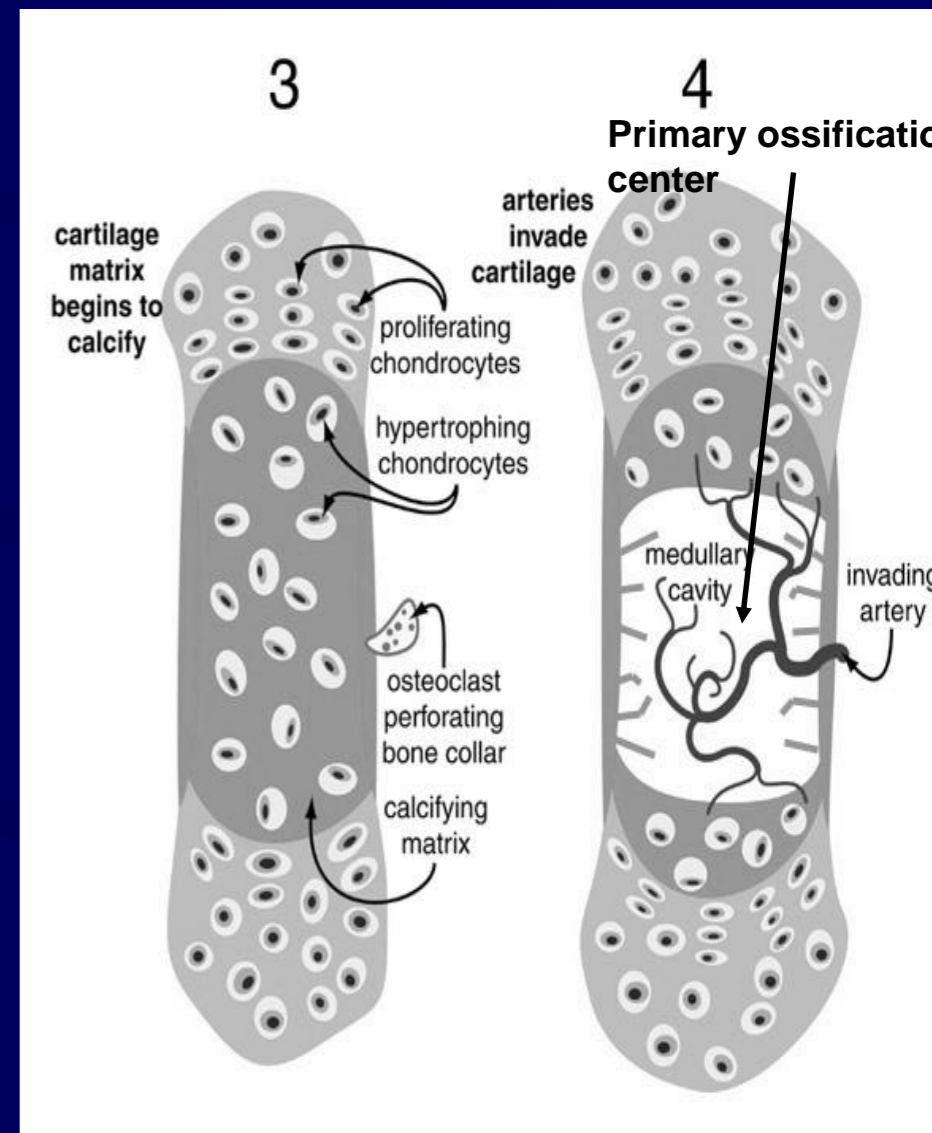


ENDOCHONDRAL BONE HISTOGENESIS

8. As the invading cells spread out within the diaphysis of the degenerating cartilage, true ossification begins (same as what happens when intermembranous bone is formed), this central volume of active bone deposition is called a **primary ossification center**.

9. The **osteoblasts** begin to secrete **osteoid matrix** on the remnants of calcified cartilage. The osteoid matrix becomes mineralized forming the spicules and trabeculae of **cancellous (spongy) bone**. Some of the osteoblasts become trapped in the forming bone and become mature bone cells, **osteocytes**.

10. As the cancellous bone is laid down, **chondroclasts** continue to breakdown and digest the calcified cartilage. More osteoblasts invade the region and secrete osteoid matrix.

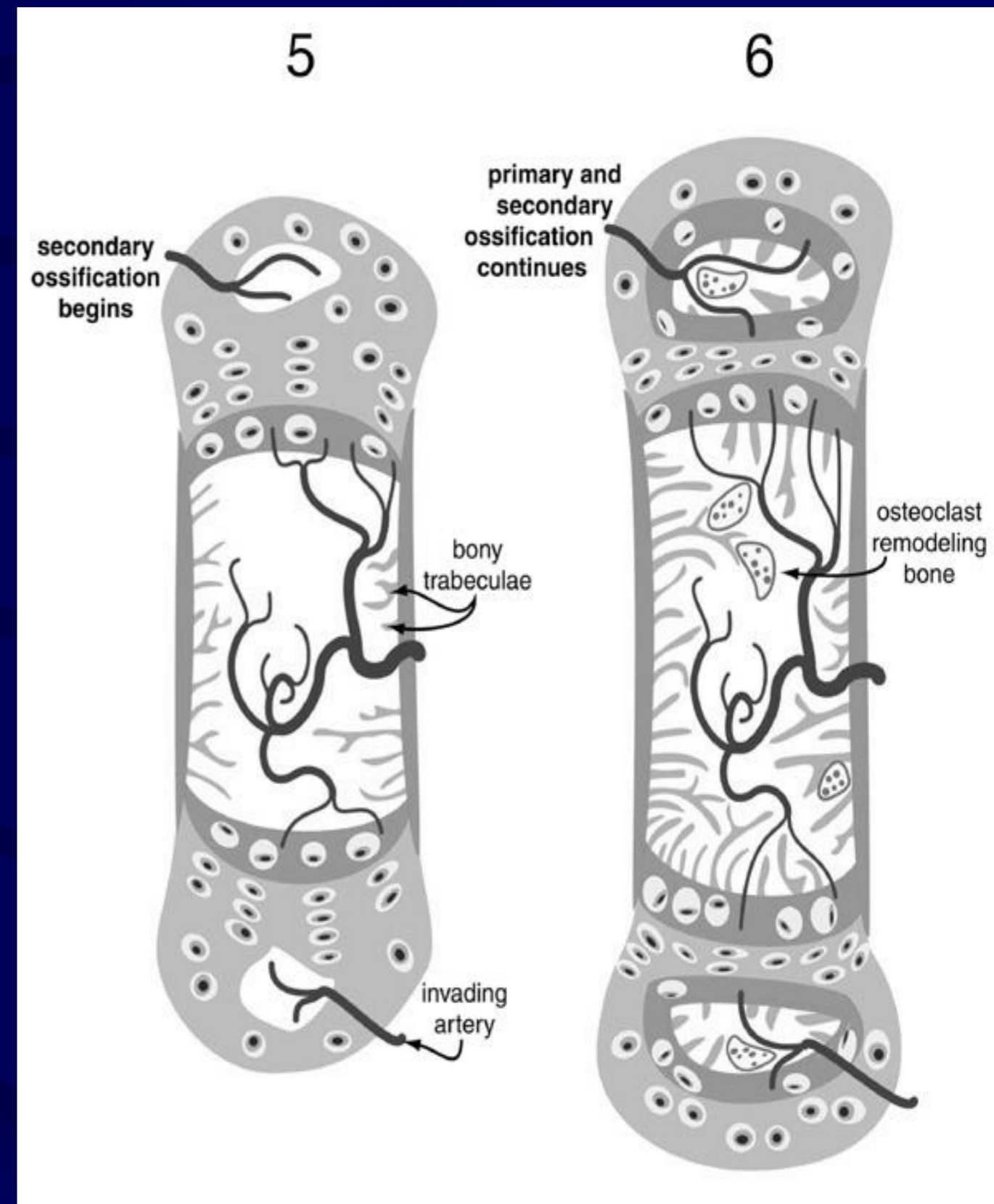


ENDOCHONDRAL BONE HISTOGENESIS

11. The primary ossification center extends rapidly within the diaphysis and the cartilage template of the central shaft is replaced by cancellous/spongy bone tissue.

12. Secondary ossification centers form in the central cartilage of the bulbous ends, or epiphyses, at either end of the shaft. Since there is no periosteum on the surface of the epiphyses, there is no periosteal external collar of bone in this region.

13. During and after endochondral bone formation, there is considerable internal remodeling of the architecture of the bone. This is accomplished by the efforts of osteoblasts, osteocytes, and osteoclasts.



ENDOCHONDRAL BONE HISTOGENESIS

14. The **osteoclasts** continue to breakdown cancellous bone even while more bone is being laid down by the osteoblasts.

15. The central region of **cancellous (spongy) bone persists and** contains the **marrow** cavities. More peripherally, small longitudinal channels are excavated through the spongy bone that will become the **haversian systems**.

16. As these peripheral channels are hollowed out, **osteoblasts** from the marrow invade the channels and form an epithelium on the inner wall (**endostium**).

These osteoblasts lay down cyclical layers of **osteoid matrix** which becomes mineralized and decreases the diameter of the channels - formation of **osteons or Haversian systems** (appositional bone formation).

As this occurs, some of the **osteoblasts** are trapped within the matrix forming concentric circles of **osteocytes**.

ENDOCHONDRAL BONE HISTOGENESIS

17. As this ossification takes place, cavities like those present in spongy bone are not retained, thus, this region becomes a solid compact mass of ossified matrix except for the Haversian and Volkman's canals. This is the **compact or dense bone**. Since there is no cartilage precursor to the compact bone, it may be considered **intramembranous** as far as its mode of formation is concerned.

18. Osteoclasts excavate radial tunnels between haversian canals and also connecting to the marrow cavities and the periosteum. These will become the **canals of Volkmann**.

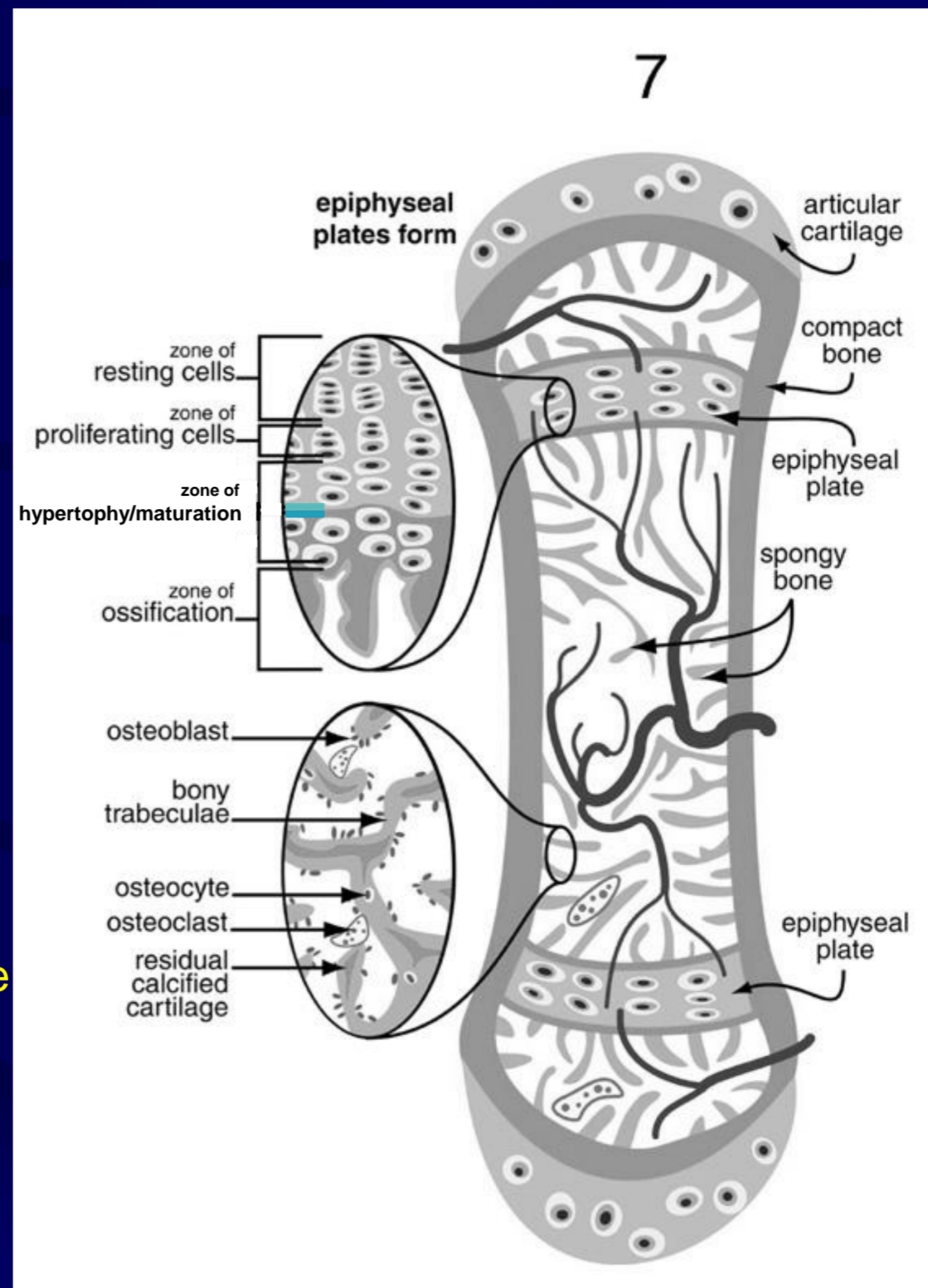
19. The Haversian and Volkmann's canals are tubes through which blood vessels and nerves can pass within the compact bone.

ENDOCHONDRAL BONE HISTOGENESIS

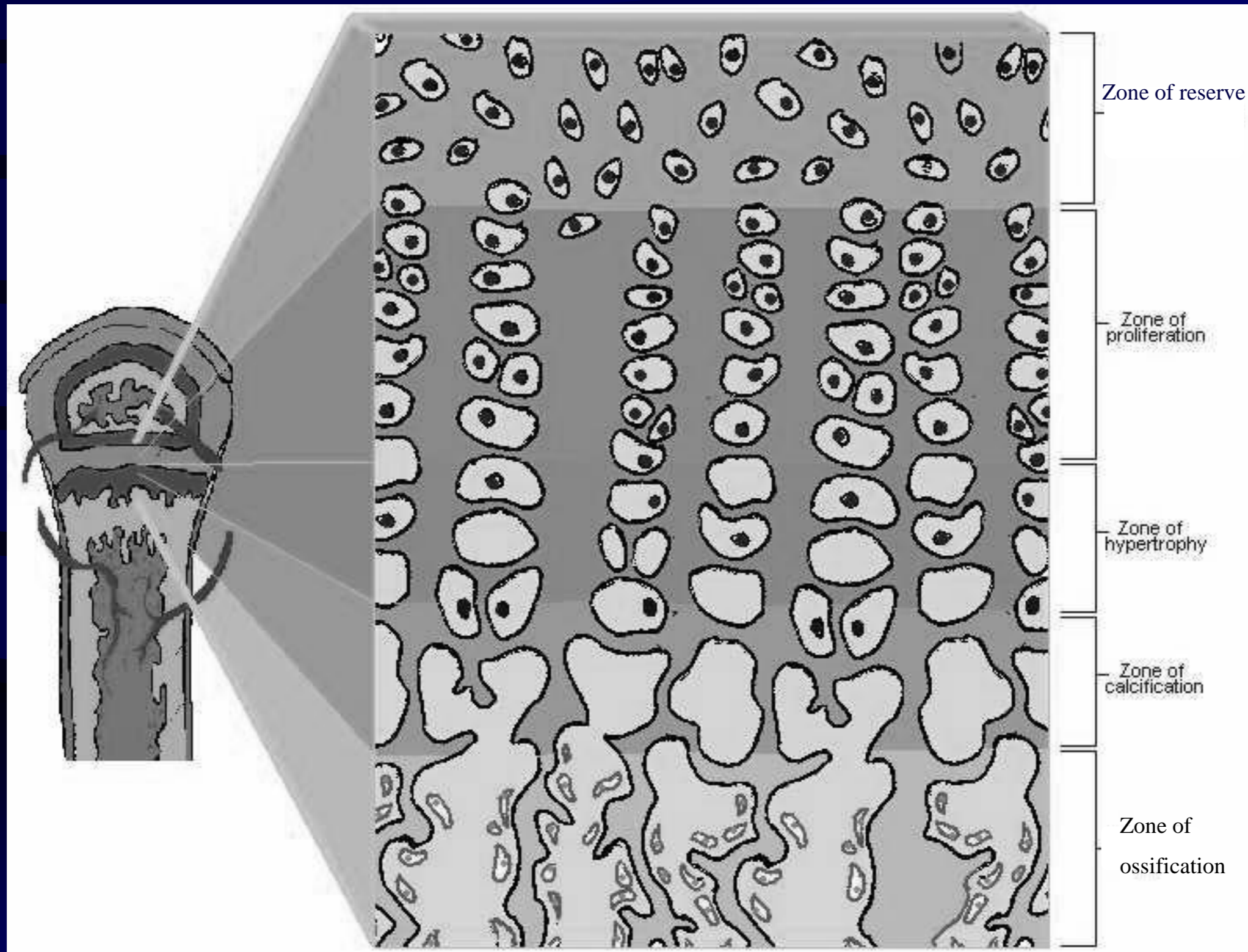
20. Regions between the epiphyses and the long bone shaft remain cartilagenous and form the **epiphyseal plates**.

21. The **epiphyseal plates** are growth regions. New cartilage forms in this region as a person grows. This cartilage initially undergoes endochondral calcification. Take a look at your textbook and lab manual for the details.

22. The reabsorption and redeposition of bone including reworking of the haversian canal systems, continues throughout life. Thus, the bones of your body are living, dynamic structures.



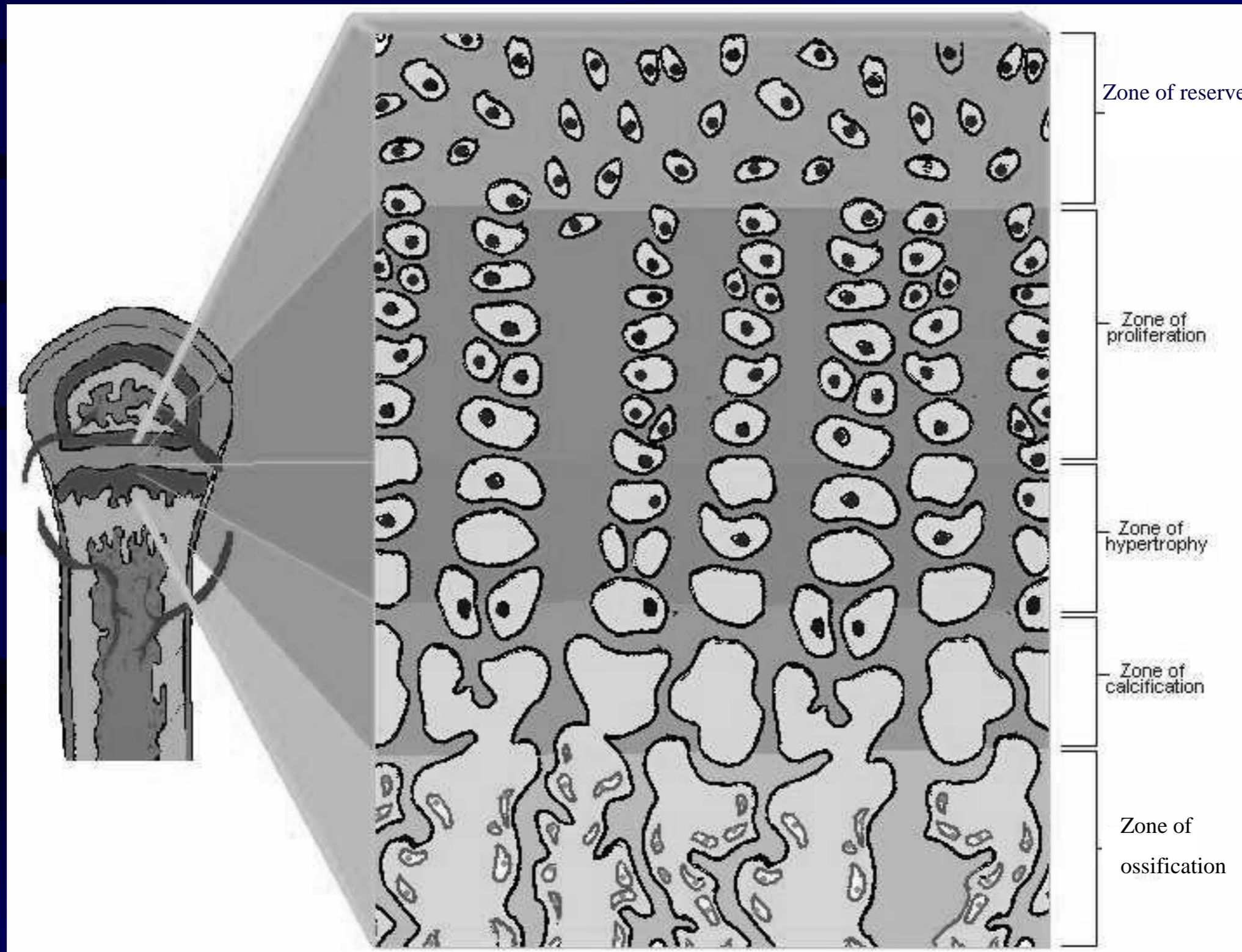
Long bone growth



<http://137.222.110.150/calnet/bones/page6.htm>

http://www.cytochemistry.net/microanatomy/bone/endochondral_bone_development.htm

Long bone growth



<http://137.222.110.150/calnet/bones/page6.htm>

http://www.cytochemistry.net/microanatomy/bone/endochondral_bone_development.htm