


THE NEW SYDENHAM
SOCIETY.

INSTITUTED MDCCCLVIII.

VOLUME XC.



Digitized by the Internet Archive
in 2010 with funding from
Open Knowledge Commons and Harvard Medical School

LECTURES
ON
THE DISEASES OF
THE NERVOUS SYSTEM.

DELIVERED AT LA SALPÊTRIÈRE

BY

J. M. CHARCOT,

PROFESSOR IN THE FACULTY OF MEDICINE OF PARIS; PHYSICIAN TO LA SALPÊTRIÈRE; MEMBER OF THE ACADEMY OF MEDICINE, OF THE CLINICAL SOCIETY OF LONDON, OF THE CLINICAL SOCIETY OF BUDA-PESTH, OF THE MEDICAL SOCIETY OF NATURAL SCIENCES OF BRUSSELS; PRESIDENT OF THE ANATOMICAL SOCIETY, AND EX-VICE-PRESIDENT OF THE BIOLOGICAL SOCIETY OF PARIS, ETC.

SECOND SERIES.


TRANSLATED AND EDITED BY

GEORGE SIGERSON, M.D., CH.M.,

LICENTIATE OF THE KING AND QUEEN'S COLLEGE OF PHYSICIANS OF IRELAND; DEAN OF THE FACULTY OF SCIENCE, C.U.I., MEMBER OF THE ROYAL IRISH ACADEMY; FELLOW OF THE LINNEAN SOCIETY OF LONDON; MEMBER OF COUNCIL OF STATISTICAL SOCIETY, DUBLIN; MEMBER OF THE SCIENTIFIC SOCIETY OF BRUSSELS; CORRESPONDING MEMBER OF THE CLINICAL AND ANTHROPOLOGICAL SOCIETIES OF PARIS; ETC.

THE NEW SYDENHAM SOCIETY,
LONDON.

MDCCCLXXXI.



3322

LONDON

PRINTED BY J. E. ADLARD, BARTHOLOMEW CLOSE.

NOTICE

ACCOMPANYING this volume of Professor Charcot's 'Lectures on the Diseases of the Nervous System,' the reader will find a number of plates and diagrams, with explanatory descriptions. These serve to illustrate not only this, but also the first series of Lectures already published by 'the New Sydenham Society.' References to these illustrations may be observed in the text of the translation of both volumes.

G. S.

CONTENTS.

LECTURE I.

ANATOMICAL INTRODUCTION.

PAGE

SUMMARY.—The task of the clinical observer differs from that of the nosographer. Diversity of opinions concerning the seat of lesion in locomotor ataxia. Insufficiency of the methods of research employed. Sclerosis of the posterior columns: its significance. Appearances presented on examination by the naked eye. First cases of sclerosis of the posterior columns.

Macroscopical examination.—Grey induration; its characters. Original focus of the irritative lesion.

Microscopical examination.—Topographical anatomy. Spinal circumscribed regions. Goll's column. External bands of posterior fasciculi; their alteration seems constant in locomotor ataxia.

Systematic median fasciculated sclerosis. Lateral fasciculated sclerosis.

In locomotor ataxia, sclerosis makes its first appearance in the postero-lateral bands. Relationship between lesions and symptoms.

Manner in which sclerosis is propagated. Internal radicular fasciculi.

Invasion of the anterior grey cornua; consecutive amyotrophy. 3

LECTURE II.

RETROGRADE ACTION IN SPINAL DISEASES; ITS RELATION WITH SCLEROSIS OF THE POSTERIOR COLUMNS; LIGHTNING PAINS AND GASTRIC CRISES.

SUMMARY.—Relations between the internal radicular nerve-filaments and the groups of multipolar nerve-cells of the anterior cornua. Recurrent or retrograde symptoms. Sclerosis of the posterior median bundles; propagation of the sclerosis to the lateral bands of the posterior columns.

	PAGE
Classical type of progressive locomotor ataxia. Prodromic period of shooting pains. Period of established disease, or of tabetic incoördination. Paralytic period.	
Lightning pains. Their varieties; boring pains; lancinating pains; constrictive pains. Symptomatic shooting pains in disseminated sclerosis, progressive general paralysis and chronic alcoholism. Visceral symptoms; vesical, urethral pains; rectal tenesmus.	
Gastric crises; specific characters. Duration. Abortive cases of locomotor ataxia	18

LECTURE III.

TABETIC AMAUROSIS.

SUMMARY.—Cephalic symptoms in locomotor ataxia. Lesions of the cranial and bulbar nerves. Progressive grey induration of the optic nerve. Progressive atrophy of the papilla. Necessity of ophthalmoscopic examination in the diagnosis of some cerebral affections.	
Isolated existence of tabetic amaurosis; its frequency. Characters of the anatomic lesion of the optic nerve, seen by the naked eye and under the microscope. Appearance of papilla; 1°, in the normal state; 2°, in progressive grey induration. Functional derangements accompanying grey induration of the optic nerve and papilla. Modification of the papilla in cases of embolism of the arteria centralis of the retina, in glycosuria, syphilitic retino-choroiditis, and general paralysis.	
Neuro-retinitis; its forms and symptoms; differences which distinguish it from tabetic amaurosis. Clinical facts demonstrating the importance of the signs furnished by the ophthalmoscope	34

LECTURE IV.

ON SOME VISCERAL DERANGEMENTS IN LOCOMOTOR ATAXIA. ARTHROPATHIES OF ATAXIC PATIENTS.

SUMMARY.—Disorders of the genito-urinary organs. Frequent desire to micturate; satyriasis; rectal tenesmus. Oculo-pupillary symptoms. Permanent acceleration and dirotism of the pulse.	
Arthropathy of ataxic patients; its frequency. Cases. This arthropathy is developed at a but slightly advanced period of the spinal disease. Prodromes. Phases of ataxic arthropathy. Joints attacked. Its special characters. Diagnosis between the arthropathy of ataxic patients and dry arthritis.	
Anatomical lesions. Arthropathies consecutive on affections of spinal origin. Mechanism of production of ataxic arthropathies. Lesions of the anterior cornua of the grey substance. Desideratum	47

LECTURE V.

ON SLOW COMPRESSION OF SPINAL CORD. ANATOMICAL PREFACE.

	PAGE
SUMMARY.—Slow compression of cord due to various causes ; importance of its study.	
Causes of compression. Tumours of the cord ; glioma, tubercle, sarcoma, carcinoma, gumma, kystic dilatation of the cord.	
Tumours primarily developed in the meninges. Sarcoma, psammoma, echinococci, inflammatory neoplasias (internal pachymeningitis, hypertrophic pachymeningitis).	
Morbid productions formed in the cellulo-adipose tissue of the rachis. Carcinoma, sarcoma, hydatid kysts, abscess.	
Vertebral lesions. Syphilitic hyperostoses, dry arthritis, Pott's disease. Mechanism of compression of the cord. Cancerous vertebral disease.	
Painful paraplegia of cancerous patients	65

LECTURE VI.

ON SLOW COMPRESSION OF THE SPINAL CORD. ANATOMICAL MODIFICATIONS IN CASES WHICH TERMINATE IN CURE. SYMPTOMS. PSEUDO-NEURALGIAS. PAINFUL PARAPLEGIA OF CANCEROUS PATIENTS.

SUMMARY.—Anatomical modifications which the cord undergoes at the compressed point. Changes in form : softening, induration. Interstitial myelitis. Ascending and descending consecutive sclerosis. There may be restoration of function, notwithstanding the existence of profound lesions. Degeneration of nerve-tubes at the compressed point.

Symptoms. Extrinsic and intrinsic symptoms. Topographical anatomy of the vertebral region.

Extrinsic symptoms ; pseudo-neuralgias. Pseudo-neuralgias in cases of rachidian tumours, of Pott's disease, and in cancerous vertebral disease.

Painful paraplegia of cancerous patients. Pain, its characters, paroxysms. Tegumentary hyperæsthesia. Eruption of zona along the course of painful nerves ; circumscribed cutaneous anæsthesia ; partial muscular atrophy and contracture. Deformation of the vertebral column. Difficulty of diagnosis in certain cases : osteomalacia, hypertrophic cervical pachymeningitis, spinal irritation, &c.

LECTURE VII.

ON SLOW COMPRESSION OF THE SPINAL CORD. SYMPTOMS. DISORDERS OF MOTILITY AND OF SENSIBILITY CONNECTED WITH SPINAL COMPRESSION. SPINAL HEMIPLEGIA AND HEMIPARAPLEGIA, WITH CROSSED ANÆSTHESIA.

PAGE

SUMMARY.—Lesions of the cord at the point of compression. They occupy the whole extent of the cord, in a transverse direction, or only affect one of its lateral halves.

First case: Succession of symptoms. Predominance of motor disorders at the outset; paresis, paralysis with flaccidity, temporary rigidity, permanent contracture of limbs, augmentation of reflex excitability. Disorders of micturition; Budge's theory. Modification of sensibility; delay in the transmission of sensations; dysæsthesia. Associated sensations.

Second case; Lesions bearing on one of the lateral halves of the spinal cord. Lesion circumscribed. Spinal hemiparaplegia with crossed anæsthesia; its characters. Spinal hemiplegia 93

LECTURE VIII.

ON SLOW COMPRESSION OF THE SPINAL CORD. CERVICAL PARAPLEGIA, PECULIAR SYMPTOMS. PERMANENT SLOW PULSE.

SUMMARY.—On cervical paraplegia. Compression of nerves of upper extremities. Lesions of spinal cord in the neck; their mode of action in the production of cervical paraplegia. Distinction between cervical paraplegia due to the compression of peripheral nerves and that dependent on a lesion of the cord. Alteration of motor nerve-cells and tumours of the cord—causes of a third form of cervical paraplegia.

On some peculiar symptoms of slow compression of the cervical cord. Oculo-pupillary disorders. Cough and dyspnœa. Frequently recurring vomiting. Difficulty of deglutition. Hiccough. Functional derangement of bladder. Epileptic attacks.

On permanent slow pulse. Temporary slowing of pulse in fractures of vertebræ of neck. Permanent slow pulse connected with certain organic affections of heart (aortic insufficiency, fatty degeneration of cardiac tissue, fibrinous deposits). Insufficiency of cardiac lesions, in some cases, to explain slow pulse. Phenomena connected with permanent slow pulse. Syncope, apoplectiform state, convulsive fits. In certain cases, the starting point of permanent slow pulse to be sought in cervical cord or bulbus rachidicus. Dr. Halberton's case.

	PAGE
Sudden death from rupture of transverse ligament of the odontoid process.	
Symptoms accompanying lesions of the lumbar enlargement and cauda equina	108

LECTURE IX.

INFANTILE PARALYSIS.

SUMMARY.—Spinal myopathies or myopathies of spinal origin. General characters. Localisation of spinal lesions in the anterior cornua of grey matter.

Infantile spinal paralysis. To be considered as a disease for study. Symptoms. Period of invasion, its modes; second period or retrogression of symptoms with localisation of muscular lesions (muscular atrophy, arrest of development of the osseous system, coldness of extremities, deformities, paralytic club-foot).

Pathological anatomy of infantile paralysis. Lesions of muscles at different periods; fatty deposits. Lesions of the nervous system; history (Charcot and Cornil, Vulpian and Prévost, Charcot and Joffroy, Parrot, Lockhart Clarke and Johnson, Damaschino and Roger). Localisation of lesions in the anterior cornua of grey substance. Secondary alterations; sclerous transformation of neuroglia; foci of disintegration; partial sclerosis of the antero-lateral columns; atrophy of the anterior roots. Reasons tending to demonstrate that the primary lesion resides in the nerve-cells 125

LECTURE X.

SPINAL PARALYSIS OF THE ADULT. NEW RESEARCHES CONCERNING THE PATHOLOGICAL ANATOMY OF INFANTILE SPINAL PARALYSIS. AMYOTROPHIES CONSECUTIVE ON ACUTE DIFFUSE SPINAL LESIONS.

SUMMARY.—Spinal paralysis of the adult. History. Description of a case, borrowed from M. Duchenne (de Boulogne). Personal facts. Close analogies connecting acute spinal paralysis of the adult with that of the child. Symptomatological modifications due to age. Prognosis.

Recent works concerning the pathological anatomy and physiology of infantile spinal paralysis; they confirm in essential points, and complete in certain respects, the results already detailed.

A word as to acute spinal lesions which are not, as in infantile paralysis,

	PAGE
systematically limited to the anterior cornua of the grey substance. Acute central generalised myelitis, hæmatomyelia, traumatic myelitis, acute partial myelitis. Conditions in which these affections determine the rapid atrophy of the muscles	144

LECTURE XI.

CHRONIC SPINAL AMYOTROPHIES. PROTOPATHIC SPINAL PROGRESSIVE MUSCULAR ATROPHY (DUCHENNE-ARAN TYPE).

SUMMARY.—Clinical varieties of cases designated under the name of progressive muscular atrophy (spinal progressive muscular atrophies). Uniformity, in these cases, of the spinal lesion which affects the anterior cornua of the grey substance.

Study of protopathic spinal progressive muscular atrophy as typical of the group: simple spinal lesion. Chronic deuteropathic spinal amyotrophies. The lesion of motor nerve-cells is here consecutive; it is superadded to a spinal lesion of variable position. Account of the principal spinal affections which may produce deuteropathic progressive amyotrophy; hypertrophic spinal pachymeningitis; sclerosis of posterior columns; chronic central myelitis; hydromyelia; intra-spinal tumours; disseminated sclerosis; symmetrical lateral sclerosis.

On protopathic spinal progressive muscular atrophy in particular (Duchenne-Aran type). Symptoms; individual atrophy of the muscles, functional disorders; prolonged persistence of faradaic contractility; fibrillary tremors; paralytic deformations, or deviations, "griffes." Modes of invasion. Etiology: hereditary transmission, cold, traumatic injuries.

Pathological anatomy. Lesions of the cord; alteration limited to the anterior cornua of the grey substance (nerve-cells, neuroglia). Lesions of the nerve-roots and of the peripheral nerves. Muscular lesions and their nature

163

LECTURE XII.

DEUTEROPATHIC SPINAL AMYOTROPHIES. LATERAL AMYOTROPHIC SCLEROSIS.

SUMMARY.—Deuteropathic spinal amyotrophies. Lateral amyotrophic sclerosis; localisation of the spinal lesion in the lateral columns. Causes of this localisation, elucidated by a study of the development of the spinal cord. Formation of lateral columns; of Goll's columns and of Türk's columns.

	PAGE
Lateral sclerosis consecutive on cerebral lesion.	
Primary symmetrical lateral sclerosis. Pathological anatomy. Appearance and topography of the lesion in the cord and bulbus. Consecutive lesions of the grey substance (motor nerve-cells, neuroglia), in the cord and in the bulbus. Secondary changes: anterior nerve-roots. Peripheral nerves. Trophic lesions of the muscles	180

LECTURE XIII.

ON AMYOTROPHIC LATERAL SCLEROSIS. SYMPTOMATOLOGY.

SUMMARY.—Facts which form the basis of the symptomatology of amyotrophic lateral sclerosis. Personal observations. Corroborative cases.

Differences which clinically separate amyotrophic lateral sclerosis from protopathic spinal muscular atrophy.

Symptoms common to both affections. Progressive amyotrophy, fibrillary contractions, preservation of electric contractility.

Symptoms peculiar to amyotrophic lateral sclerosis. Predominance of motor paralysis. Permanent spasmodic contracture. Absence of sensory disorders. Paralytic deformations; attitude of hand. Tremulation of upper extremities in purposed movements. Modes of invasion. Cervical paraplegia. Invasion of inferior extremities. Characteristics of the contracture. Bulbar phenomena; difficulty of deglutition. Impeded speech. Paralysis of the velum palati, of the orbicularis oris, &c. Grave disorders of respiration.

Summary of symptoms. Prognosis. Pathological physiology . . . 192

LECTURE XIV.

DEUTEROPATHIC AMYOTROPHIES OF SPINAL ORIGIN (*CONCLUSION*). HYPERTROPHIC CERVICAL PACHYMEMINGITIS, ETC., ETC.

SUMMARY.—Amyotrophy connected with descending lateral sclerosis consecutive on a circumscribed lesion of the brain and spinal cord. Illustrative cases.

Hypertrophic cervical meningitis. Pathological anatomy: alteration of the meninges; of the spinal cord; of the peripheral nerves. Symptoms; painful period (cervical pains, rigidity of neck; formication and numbness; paresis; cutaneous eruptions); second period (paralysis, atrophy, hand-deformity (“griffe”), contracture, patches of anæsthesia; paralysis and contracture of the lower extremities).

Characters which distinguish hypertrophic cervical pachymeningitis from amyotrophic lateral sclerosis.	
Amyotrophies consecutive on locomotor ataxia. Peculiar form of muscular atrophy in such cases. Pathogeny.	
Amyotrophy consecutive on sclerosis disseminated in patches.	
Subacute spinal general paralysis. Analogies with infantile paralysis. Desideratum.	
Amyotrophies independent of a lesion of the spinal cord, examples; pseudo-hypertrophic paralysis; saturnine amyotrophy.	
New considerations relative to the topographic pathological anatomy of the spinal cord	295

LECTURE XV.

ON SPASMODIC TABES DORSALIS.

SUMMARY.—Provisional denomination; its justification: symmetrical and primary sclerosis of the lateral columns. Spasmodic tabes dorsalis, and ataxic tabes dorsalis. Parallel between the two affections. Characteristics of gait.

On contracture and trepidation in spasmodic tabes dorsalis. Absence of sensory disorders. Invasion. Evolution. Mode of invasion in the limbs. Prognosis and treatment. Diagnosis: disseminated sclerosis (spinal form), hysterical contracture, transverse myelitis, lateral amyotrophic sclerosis, &c 233

LECTURE XVI.

URINARY PARAPLEGIAS.

SUMMARY.—Preamble. Theoretical point of view. Clinical reality of urinary paraplegias. Definition. Classification of cases into three groups.

Myelitis consecutive on diseases of the urinary passages. Rare in women; frequent in men. Conditions of development: gonorrhœa, stricture of the urethra, cystitis, nephritis; prostatic affections; calculous pyelo-nephritis. Exacerbation of the disease of the urinary passages precedes the invasion of spinal phenomena. Symptoms: formication; anæsthesia, dorso-lumbar and girdling pains. Paraplegia with flaccidness; excitation, then abolition of reflex excitability; permanent contracture; bedsores. Position and nature of the lesions. Pathogeny. Propagation of the renal lesion to the cord by means of the nerves (Troja, Leyden). Corroborative experiments. Examples of propagation of nerve-inflammations to the cord.

	PAGE
Reflex urinary paraplegias. Symptoms. M. Brown-Séquad's explanation. Recent experiments. Inhibitory phenomenon. Irritation of the peripheral nerves. False paraplegia. Descending neuritis. Affections of intestines and uterus	249

LECTURES XVII AND XVIII.

MÉNIÈRE'S VERTIGO = VERTIGO AB AURE LÆSA.

<p>SUMMARY.—A case of Ménière's vertigo. Description. Habitual vertigo increased by motion. Its characters: paroxysmal exacerbations; subjective translation movements. Old lesions of the ears; outflow of pus, alteration of tympan. Walking and standing impossible. Evolution of the disease. Complication: hysterical fits.</p> <p>Historical sketch. Vertigo of Ménière as yet little known. Diagnosis; apoplectiform cerebral congestion; epileptic petit mal; gastric vertigo. Relation between the sudden development of noises in the ears and the invasion of sensations of giddiness.</p> <p>Diseases of the ear: labyrinthic otitis; median otitis, catarrh, &c. Prognosis. Cure by deafness. Treatment.</p> <p>Reputedly incurable diseases. Examples of cure. Case of Ménière's vertigo. Situation of the patient in May, 1875; permanent sensations of giddiness; crises announced by shrill whistling. Motor hallucination. Treatment by sulphate of quinine: doses, effects, remarkable improvement. Another example of amelioration due to the prolonged use of sulphate of quinine</p>	261
---	-----

LECTURE XIX.

ON POST-HEMIPLEGIC HEMICHOREA.

<p>SUMMARY.—Post-hemiplegic hemichorea. Clinical facts. Disorders of general and special sensibility. Motor disorders: their resemblance to choreic movements. Trepidation of hemiplegic patients. Instability of members, affected by post-hemiplegic hemichorea. Characters of muscular disorders in rest and in motion.</p> <p>Organic lesions. Foci of intra-encephalic hæmorrhage and ramollissement:—partial atrophy of the brain.</p> <p>Rarity of post-hemiplegic hemichorea. Relation between hemichorea and hemianæsthesia. Seat of lesions to which these symptoms belong; posterior extremity of the optic thalami; posterior portion of the caudate nucleus; posterior portion of the corona radiata.</p> <p>Præ-hemiplegic hemichorea</p>	275
--	-----

LECTURE XX.

ON PARTIAL EPILEPSY OF SYPHILITIC ORIGIN

PAGE

SUMMARY.—Partial or hemiplegic epilepsy. Its relations with cerebral syphilis. Historical considerations. Description of a case of partial epilepsy of syphilitic origin. Characters and peculiar seat of the cephalalgia. Necessity of energetic therapeutical intervention.	
Modes of invasion of the convulsive symptoms. New corroborative examples. Succession of fits. Appearance of permanent contra-ctures. Relations between the cephalalgia and the motor region of the brain.	
Lesions. Gummatous pachymeningitis. Probable seat of those lesions.	
Mixed treatment, with interruptions	286

APPENDIX.


I.—Multiple Pathological Luxations and Spontaneous Fractures in a Patient suffering from Locomotor Ataxia. By J. M. Charcot	305
II.—On the Tumefaction of the Motor Nerve-cells and of the Axis-cylinders of the Nerve-tubes in Certain Cases of Myelitis. By J. M. Charcot	317
III.—Note on a Case of Spinal Protopathic Progressive Muscular Atrophy (Duchenne-Aran Type). By J. M. Charcot	327
IV.—Two Cases of Lateral Symmetrical Amyotrophic Sclerosis	341
V.—Note on a Case of Glosso-laryngeal Paralysis, followed by Autopsy. By J. M. Charcot	363
VI.—Note upon the Anatomical State of the Muscles and Spinal Cord in a Case of Pseudo-Hypertrophic Paralysis. By J. M. Charcot	378
VII.—On Athetosis	390
INDEX	395

Explanation of Plates, Vol. I.

Explanation of Plates, Vol. II.

PART FIRST.

ANOMALIES OF LOCOMOTOR ATAXIA.



LECTURE 1.

ANATOMICAL INTRODUCTION.

SUMMARY.—*The task of the clinical observer differs from that of the nosographer. Diversity of opinions concerning the seat of lesion in locomotor ataxia. Insufficiency of the methods of research employed. Sclerosis of the posterior columns: its significance. Appearances presented on examination by the naked eye. First cases of sclerosis of the posterior columns.*

Macroscopical examination.—*Grey induration: its characters. Original focus of the irritative lesion.*

Microscopical examination.—*Topographical anatomy. Spinal circumscribed regions. Goll's column. External bands of posterior fasciculi: their alteration seems constant in locomotor ataxia.*

Systematic median fasciculated sclerosis. Lateral fasciculated sclerosis. In locomotor ataxia, sclerosis makes its first appearance in the postero-lateral bands. Relationship between lesions and symptoms. Manner in which sclerosis is propagated. Internal radicular fasciculi. Invasion of the anterior grey cornua: consecutive amyotrophy.

I.

GENTLEMEN,—I purpose to study with you, in a series of four lectures, some imperfectly known parts of the anatomical and clinical history of progressive locomotor ataxia. The clinical point of view, especially, is that from which I intend to address you in these conferences.

The task of the clinical observer may be regarded as differing much from that of the nosographer. The latter concerns himself chiefly with the *abstract picture* of diseases; hence, he purposely neglects anomalies—deviations from the typical standard—or willingly relegates them to the background.

The clinical observer, on the contrary, lives more especially on

individual cases which almost always present themselves with peculiarities that separate them more or less from the *common type*. He cannot neglect exceptional, abnormal cases, for these are the cases which chiefly demand the exercise of his sagacity.

Now, with respect to the former class, I should have but little to add to the classic descriptions which, in the last few years, have been over and over again rehearsed, and which, besides, simply reproduce with some variations the masterly description that we owe to Dr. Duchenne (de Boulogne).

On the other hand, the anomalies of locomotor ataxia, the deviations from the normal type, offer for our investigation a yet vast field which is far, indeed, from having been explored in all its directions. In this exposition we intend, of course, to make use of the many cases which are subject to our examination in this hospital. They will enable us to show you, along with the ordinary types, unexpected combinations which have been little or not at all studied, and which yet are far from constituting rare cases.

Without neglecting anatomical investigation, we shall have recourse to it only in so far as it is capable of throwing light on clinical points which are difficult of interpretation. In fact, in the present conference I purpose to show you, with respect to locomotor ataxia, what advantage a clinical observer can draw from anatomical researches carried out in a certain direction, and following a certain method. Let us, therefore, make ourselves anatomists for to-day; examination of the *living* subject will then resume its rights.

II.

The term "locomotor ataxia" answers to a denomination which is altogether symptomatic, and, for some time, there was hesitation as to what department of the peripheral or central nervous system we should correlate the group of symptoms which this term designates. Some accused the brain and cerebellum, others the spinal cord, with or without complicity on the part of the peripheral nerves. Others, in short, maintained that locomotor ataxia was a neurosis, and held that the lesion of the nerve-centres, discoverable on autopsy, was only produced in the long run as a distant but nowise necessary consequence of prolonged functional disturbance. Many of you may have also heard this thesis developed by a skilful master, Trousseau.

They based their opinion, then, upon some necroscopic examinations, reputedly negative, and these resultless investigations made a more striking impression on the mind, because they had been conducted with all the appliances of the most delicate research, and by competent masters of the microscope. But, to-day, those imaginary facts are exploded. The method was insufficient, and we believe we may affirm that, in the very first period of locomotor ataxia, even when the disease, still at its outset, is only marked by lightning pains, easily discernable lesions are to be found in certain well-determined parts of the nervous system—in the posterior columns of the spinal cord.

I hope to show you, gentlemen, that these researches, which are so minute in appearance, only require care, time, and the application of a particular method, simple enough of its kind, to yield results as positive as those furnished by the most elementary process of descriptive anatomy—examination with the naked eye.

III.

But this point you should remark at starting: if it be true that progressive locomotor ataxia is related, as has been said, to posterior sclerosis as “the shadow to the body,” you must not, however, imagine that, in calling *sclerosis of the posterior columns* by the name of *locomotor ataxia*, you possess an adequate definition.

Assuredly this is not the case, and I hope it will be easy for me to establish, on a foundation of facts, the following propositions, which I confine myself, for the moment, to stating in a summary manner:

1°. The posterior columns are sometimes attacked with sclerosis, throughout a great portion of their extent, without symptoms of ataxia being the consequence.

2°. Certain lesions of the spinal cord, originally developed outside the posterior columns, may, at a given moment, invade them to a variable height, and accidentally produce some of the symptoms of ataxia, which I would willingly term *tabetic symptoms*, but we have not really here progressive locomotor ataxia.

3°. In fact, this disease is evolved with an array of symptoms following each upon the other in a determinate order, which is always, or nearly always, the same. It is a disease which takes rank apart, self-dependent. The lesion with which the symptoms are connected occupies, indeed, the posterior columns, but it

systematically occupies, in those columns, a fixed and circumscribed position, which is always the same. The latter point is that which we shall first seek to demonstrate.

IV.

Let us, then, enter at once upon the question of *pathological anatomy*. The anatomical study of spinal scleroses includes, generally speaking, as you are aware—1°, examination with the naked eye; 2°, microscopical examination of fresh sections and of sections hardened by different methods.

We shall be brief with respect to the results of macroscopic investigation in ataxia, for it is manifestly insufficient, stricken with sterility from the outset. In recent cases, in fact, it does not note any alteration, and in cases of old standing it gives us the means neither of determining exactly the seat of the lesion, nor its nature. It simply informs us that there is a grey induration. This is all, and it is not enough.

Nevertheless we should not forget that, in spite of its imperfections, we owe to this mode of examination the discovery of sclerosis of the posterior columns. And, if I notice this fact in passing, it is because this was an entirely French conquest, which dates from the great anatomo-pathologic epoch inaugurated by Bayle and Laennec, and continued by Cruveilhier. In 1827, Hutin showed to the Société Anatomique a specimen of gelatiniform degeneration of the posterior columns. Then followed Monod and Ollivier (d'Angers). But, in these communications the symptoms could not be set face to face with the lesions; hence, these cases excited little attention except as *anatomical curiosities*. Not until a later day was the connection successfully made between grey induration of the posterior columns and the symptoms of ataxia,—definitely coördinated by Dr. Duchenne (de Boulogne),—and then it was shown that the disease, at first considered as exceptional, is in reality very common.

Besides the alterations of the posterior columns, macroscopic anatomy has revealed—1°, alteration of the posterior roots (atrophy); 2°, that of the meninges (spinal posterior meningitis); 3°, that of different cerebral nerves, and, among others, of the optic, the oculomotor, and the hypoglossal nerves (atrophy and grey degeneration). Let us also say that, speaking generally, it has allowed us to note that the lesions are more marked in the cervical region, when the

symptoms predominate in the upper extremities, and in the lumbar region in the common form, that is to say, when the morbid phenomena are especially manifest in the lower extremities. Let us add, in conclusion, that the invasion of the lateral columns by the grey induration did not escape notice by this method of examination.

Still, I must repeat that macroscopic anatomy furnished no information with respect to the state of the grey substance, to the exact localisation of the lesion, to the genesis and nature of the morbid process, nor to many another point besides.

V.

The study of the spinal cord, by means of magnifying lenses, is alone able to supply the desiderata which we have just noticed. Its methods are, besides, applicable from different points of view. It may, in the first place, propose to itself to go back even to the anatomical elements themselves, and to seek out the changes which they undergo in the different phases of the morbid process. It was thus it became recognised that the lesion of the posterior columns, in progressive locomotor ataxia, is one of the forms of sclerosis of the nerve-centres.

Sclerosis or grey induration of the nerve-centres corresponds, you have not forgotten, to one of the modes of primary chronic inflammation. One of its most salient features is the hyperplasia, with fibrillary metamorphosis of the neuroglia, taking place at the expense of the nerve-elements, or proceeding, at least, on parallel lines with the destruction of those elements.

I will not insist here on showing that, as regards its histological characters, grey induration in locomotor ataxia differs in nothing essential from what it is in disseminated sclerosis or in symmetrical sclerosis of the lateral columns, for instance. That question appears to-day definitely set at rest, and nobody now admits, I think, that only simple atrophy is present, as some authors, amongst them Herr Leyden, maintained. Spinal meningitis, which so frequently coexists with sclerosis of the posterior fasciculi, in ataxia, and which, in such cases, always shows itself exactly limited to the surface of these fasciculi, would supply, if necessary, a new argument in favour of the irritative nature of the alteration.

But there is a point on which it seems impossible to pronounce judgment at present in a definite manner :—What is the original

focus of this irritative lesion? Is it the neuroglia? Is it, on the contrary, the nerve-element? I confess that, considering how the alteration remains, in some sort, systematically confined within the area of the posterior fasciculi, whose limits it does not exceed, except in exceptional circumstances, I cannot help being strongly inclined to the latter hypothesis. Parenchymatous irritation would, therefore, be the initial fact; interstitial irritation would be secondary. I shall perhaps find, as we proceed, an occasion for pointing out to your attention some other data which yield support to this view of the matter.

VI.

The study of the spinal cord, by means of magnifying glasses, may also, as we mentioned, be conducted from another point of view. There, in fact, exists a kind of *microscopical topographic anatomy*, the object of which is to examine the parts in their natural relations, without either destruction or dilaceration. The point is then, principally, to determine, in an exact way—within the area of the white columns or in the different departments of the grey substance—what is the extent, the configuration, the precise allocation of the changes, and to trace their mode of extension when, flowing out from their primal source, they spread to adjacent regions or even to distant parts.

To this mode of investigation we owe, if I mistake not, a considerable portion of the progress recently accomplished in the history of chronic spinal diseases, which for such a length of time has been almost undecipherable. This result, indeed, it was easy to foresee. Experiments on animals, notwithstanding the comparatively coarse method employed, had yet sufficed to place beyond doubt the fact that, in this slender cord, which is called the spinal marrow, there exists, even in the white columns alone, several regions corresponding to as many organs, the functions of which are wholly distinct, notwithstanding the analogy of their composition. Thus, the lateral fasciculi are, physiologically, quite distinct from the posterior fasciculi. In the grey substance itself we have grounds, as you are aware, for laying down, from this point of view, a certain number of more or less distinctly-divided districts.

Pathology, in its turn, came to confirm, in a general manner, these data in showing that a lesion, limited to such or such a department, is manifested each time by a particular group of sym-

ptoms ; but it was destined, in our own days, with the help of new means of anatomical study, to go further and, on many points, to advance beyond experimental research. Even in the hands of the most skilful experimenter could the latter method ever, in an organ so delicate and so difficult of access as the spinal cord, determine lesions limited, for instance, to certain groups of nerve-cells, or to certain fasciculi of fibres? It is lawful to doubt it. Disease, on the other hand, daily produces such lesions, and the topographic anatomy of the cord enables us to recognise them with the greatest precision. It permits us to observe what group of nerve-cells, what fasciculi of nerve-fibres have been irritated, atrophied, or destroyed. Face to face with this delicate anatomy, place observations carefully collected (in which the analysis of the symptoms will be all the more complete and profitable when made by the light of preliminary physiological and anatomical knowledge), and you shall have in your hands the conditions of an experiment taking place spontaneously, as it were, and taking place in the human subject, which, as regards this matter, is an inestimable advantage.

We may say that, to-day, thanks to researches directed in this spirit, the history of a good number of spinal affections, whose pathogeny had previously remained in deep obscurity, has been cleared up by an unexpected light. We have learned, for instance, that the *paralysis of children*, termed *essential*, is due to a myelitis systematically confined to quite a small department of the grey substance of the cord—the region of the anterior cornua. We know also that a majority of the cases, designated clinically by the name of *progressive muscular atrophy*, are to be referred to an alteration occupying the same situation, but in which lesion of the nerve-cells takes place, not in an acute manner, but after a chronic progressive fashion. These instances might readily be augmented, but we must limit ourselves, and now return to the principal object of our study.

VII.

We have endeavoured, gentlemen, during the course of the last two years, to apply the method we are lauding to the revision of the anatomical data which concern progressive locomotor ataxia. The results acquired to science, although still imperfect in some respects, appear nevertheless worthy of being placed before you. They

are, for the most part, due to the researches conducted in accordance with my advice by M. Pierret, assistant in my wards. These labours have been made the subject of two memoirs published in the 'Archives de Physiologie.'¹ I shall apply myself only to pointing out to you the most important points which have there been elucidated.

I have given you to understand that the lesion of the posterior columns of the cord, to which belong the symptoms of locomotor ataxia, do not indiscriminately affect all the parts of these fasciculi, but strictly occupy certain regions which it now behoves us to determine.

FIG. 1.

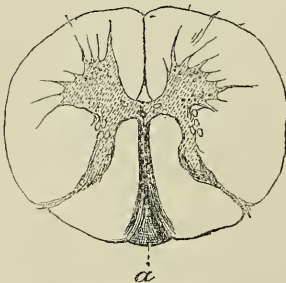
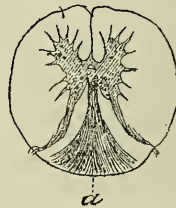


FIG. 2.



Sclerosis limited to the median or Goll's columns.

FIG. 1.—Cervical region.

FIG. 2.—Dorsal region.

It had long been remarked that *fasciculated and ascending sclerosis* of the posterior fasciculi, such as is seen, for instance, in the cervical enlargement, in cases where the cord is compressed in a point of the dorsal region, owing to Pott's disease, does not result, except under special circumstances, in the production of ataxic symptoms (motor incoördination and lightning pains) in the upper extremities. Now, this consecutive sclerosis affects exclusively, in such cases, the median or Goll's columns. Hence, that fact had already made it seem likely that, in ataxia, Goll's columns should be excluded from all participation in the production of the essential symptoms (figs. 1, 2, 3, 4, also Plate I, fig. 1).

Careful scrutiny of the lesions present in the cervico-dorsal regions, in cases of *generalised locomotor ataxia* (that is, ataxia

¹ Pierret, "Notes sur la sclérose des cordons postérieurs dans l'Ataxie locomotrice progressive," 'Archives de Physiologie,' 1872, p. 364. "Notes sur un cas de sclérose primitive du faisceau médian des cordons postérieurs," *ibid.*, 1873, p. 74.

affecting both the upper and lower extremities), confirmed this opinion. In cases of this kind, besides the sclerosis of Goll's column—which is nearly always present—you remark two slender grey bands which were detected with the naked eye and pointed out, at the time, by M. Vulpian and myself.

FIG. 3.

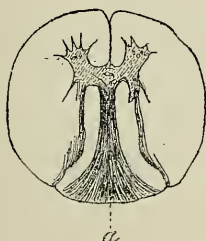
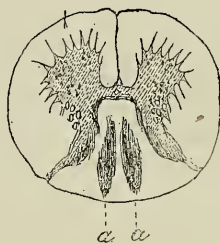


FIG. 4.



Sclerosis limited to Goll's columns.

FIG. 3.—Section made at the 12th dorsal vertebra.

FIG. 4.—Superior portion of the lumbar enlargement. (These figures are borrowed from the 'Archives de Physiologie.')

These bands, seen on the surface of the cord, appear to occupy the posterior collateral furrows, and the most internal of the sensitive roots seem to emerge from them (Pl. I, fig. 2). On transverse sections they show themselves under the form of two grey tracts, running from before backwards and slightly from without inwards; these tracts are separated from Goll's columns on the inner side, and from the posterior grey cornua on the outer side, by thin bands of white substance presenting the normal character. Now, gentlemen, it follows, from numerous observations which we have collected, along with M. Pierret, that the *sclerosed* tracts in question are never met with save in cases in which, during life, the upper extremities exhibited tabetic symptoms. Such tracts exist only on the right side of the cord, or they predominate there, when the right upper extremity was alone or chiefly affected. The contrary happens when the symptoms predominated in the left upper extremity. Moreover, in all the cases in which the superior extremities had remained perfectly free the tracts were completely absent. The presence of tabetic symptoms therefore appears, as you see, to be intimately connected with the existence of these lateral sclerosed bands.

But there was still wanting, to complete the demonstration, a case in which sclerosis of Goll's columns should be completely absent from the brachial enlargement, although ataxic symptoms had been exhibited in the upper extremities. This case, at last, was found ; it was that of a patient, named Moli, whose history has been detailed in full in one of the memoirs of M. Pierret. Motor incoördination and shooting pains had existed, to a high degree, in both the upper extremities of this woman, nevertheless the sclerous lesion was only represented, at the autopsy, in the dorso-cervical region of the cord by two thin *grey bands*. The median fasciculus was exempt from all alteration (Pl. I, fig. 3).

It manifestly follows from the foregoing that, so far as the superior extremities are concerned, the lesion of Goll's columns cannot claim any part in the production of tabetic symptoms. What, then, can be the reason of the habitual existence of this lesion in ataxia? M. Pierret has expressed the opinion that we have here a phenomenon analogous to that which determines ascending median fasciculated sclerosis, consecutive on partial myelitis; according to this view, the lesion of Goll's columns would not be produced in the cervical region, in ataxic patients, except in cases where the sclerosis is very markedly present in the dorso-lumbar region. I fully endorse this opinion, and I have not hitherto met with any fact to contradict it.

What we have said with respect to the upper extremities applies equally to the lower extremities. The case of Moli is a proof of this. In her case locomotor ataxia showed itself in its generalised form. Lightning pains and motor incoördination affected the lower as well as the upper extremities, and yet the lesion of the median columns was absent from the lumbar region just as much as from the cervical enlargement. The two self-same lateral bands, to which I called your attention, were alone engaged throughout the whole length of the cord, and to these, in her case, sclerosis of the posterior fasciculi was restricted.

You see, gentlemen, that the sclerous lesion of the lateral bands is, in short, the only essential anatomical fact in progressive locomotor ataxia. Sclerosis of the median columns, on the contrary, is only a chance, an incidental, and probably a consecutive fact.

The foregoing facts cut short, as you must have remarked, certain recriminations which sceptics have taken pleasure in raising against the results furnished by pathological anatomy. They accuse it of being delusive and faithless, because it sometimes

exhibits ataxia without posterior sclerosis, and sometimes posterior sclerosis without ataxia.

The truth is that sclerosis of the lateral bands of the posterior fasciculi is the only constant lesion in locomotor ataxia : that lesion exists, gentlemen, in every epoch of the disease, but one must know how to seek for it where it is to be found.

VIII.

From what precedes, you understand, we have grounds for establishing two very distinct forms, in posterior sclerosis, which may be manifested separately, independent of each other, or which, on the contrary, may be combined. One of these forms may be designated by the name of *median systematic fasciculated sclerosis*, or *sclerosis of Goll's columns* ; it exists sometimes as a consecutive affection (consecutive ascending sclerosis), sometimes as a primary affection. We know not, up to the present time, what peculiar symptoms are connected with this form of posterior sclerosis. The other form, *lateral fasciculated sclerosis of the posterior column*, or *sclerosis of the external bands*, holds under its dominion the *tabetic symptoms* ; like the first named, it may be deuteropathic, or, on the contrary, protopathic. This form is nothing other than the anatomical substratum of progressive locomotor ataxia.

I think it useful to enter upon some new details in order to make it clearly manifest that this lateral fasciculated sclerosis is, in reality, the fundamental anatomical fact in ataxia. It seems to us possible to establish, in the first place, that it is found from the outset of the disease, even at the period when lightning pains form, by themselves alone, the entire clinical picture, without being accompanied by motor incoördination : then, it may exist alone, no alteration being yet discoverable in Goll's columns. This fact, we believe, has been placed beyond a doubt, in several cases where death, supervening from a complication, came to prematurely arrest the development of the disease. As an illustration, I may quote the case of the patient Allard, noted by M. Pierret. Under such circumstances it must not be forgotten that the naked-eye and even an ill-conducted microscopic examination would be often powerless to discover the spinal alteration which a methodical study of properly prepared and hardened sections alone is sufficient to reveal.

It would result from this datum that, contrary to the assertions of

standard authors, who make the sclerosis of ataxia begin by the median parts, in the vicinity of the meninges, it really commences by the region of the lateral bands. We should add that, according to our observations, at this period of the disease the posterior spinal roots do not yet generally present any appreciable alteration; and, finally, that the lateral sclerous bands are then very narrow, reduced, so to say, to slender linear strips.

There is reason to hope that, with the help of a great number of observations, very varied as regards the symptoms, and noted at different periods of the disease, it will, sooner or later, be possible—by the careful comparison of clinical facts with microscopic results—to identify the mode of progressive invasion of the lesion, whether it proceeds from within outwards, or from without inwards, and, at the same time, to determine the different regions which give rise to the symptoms that successively appear.

The following are some results towards which we have been led, so far, by the researches instituted with that aim. The sclerous bands, which are very slender, very narrow, so long as the symptomatology embraces only the lightning pains, enlarge both outwards and inwards when motor incoördination is added to these. If a very marked anæsthesia have existed, the posterior horns of the grey substance are in their turn invaded by alteration, and at the same time we remark a great number of nerve-tubes affected by atrophy in the posterior roots. Finally, the paretic or paralytic symptoms, with or without contracture, which sometimes come to be added to the incoördination, generally at an advanced period of the evolution, answer to an invasion of the posterior part of the lateral columns. With respect to the habitual extension of the lateral sclerosis to the median columns, we have not hitherto found that it added anything whatever to the ordinary symptoms of the disease.

The progressive extension of the sclerous lesion beyond the foci which it occupied at the outset, may, besides, proceed in two principal directions. We have just seen how, in the transverse plane, it takes place, either outwards, towards the posterior cornua of the grey substance, or inwards, towards the median columns. Vertically considered, it extends progressively, at least under ordinary circumstances, from the dorso-lumbar region towards the cervical region, still preserving the arrangement of lateral bands; whilst, at the same time, the median columns usually become the seat of an

ascending consecutive sclerosis. The prolongations of the lateral bands may, besides, be followed into the *bulbus rachidicus*, where they occupy the region of the restiform bodies.

IX.

It is not devoid of interest to investigate whether, as seems *a priori* very probable, this localisation of the sclerous lesions in a determinate region of the posterior columns, which may be termed the *region of external bands*, may not be correlated with a particular anatomical arrangement. Most assuredly such an arrangement exists. In fact, the bands in question correspond exactly to the intramedullary distribution, described by Stilling, Clarke, and Kölliker, of those of the nerve-filaments, emanating from the posterior spinal roots, which are commonly designated by the name of internal radicular fascicles (Kölliker). But these nerve-filaments do not alone constitute the bands, for the sclerous lesion is found quite as well marked in the space which separates the points of insertion of the posterior roots as at these points themselves. This renders it very probable that, besides the internal root bundles, there exist, in this region of the posterior columns, other bundles of fibres which, doubtless, constitute vertical connections between different parts of the spinal cord. These fibres would serve for the coördination of the movements of the extremities; at all events we know positively, from what precedes, that lesion of them produces incoördination, whilst lesion of the bundles of fibres which constitute the median columns does not appear to have this effect.

The relation which exists between the course of the internal root bundles and the seat of the lesions of the ataxia will doubtless help us to understand the appearance of certain complications which are observed in this disease. I shall confine myself to one example. You know that it is not rare, in the course of locomotor ataxia, to notice the supervention of muscular atrophy, sometimes partial, sometimes, on the contrary, more or less generalised.

The anatomical reason of this complication seems to us to be demonstrated in the following observation. The case is that of the patient Moli, to which allusion has already been made.¹

The ataxia, characterised by acute lightning pains, and very

¹ Pierret, "Sur les altérations de la substance grise de la moelle épinière dans l'ataxie locomotrice considérées dans leur rapports avec l'atrophie musculaire." 'Archives de Physiologie,' 1870, p. 590.

marked motor-incoördination, had been long manifest, in this woman's case, when muscular atrophy supervened, which made

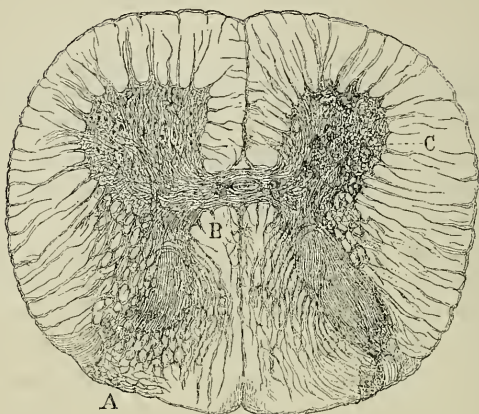


FIG. 5.—A. Posterior roots. B. Internal radical filaments, and sclerosis limited to their course. C. Right anterior cornu atrophied. (This figure is taken from the 'Archives de Physiologie.')

rather rapid progress under our eyes, but confined itself, in a very definite manner, to the upper and lower extremities of the right side. I could not bring myself to look upon this complication as a fortuitous coincidence, and I stated, as my opinion, that the amyotrophy arose, in this case, from the extension of the sclerous lesion of the posterior columns to the anterior grey cornu of the right side (fig. 5). The patient having succumbed to an intercurrent affection, the autopsy fully justified my forecast. In the dorsal, as well as in the cervical region of the spinal cord, the grey cornu of the right side was evidently atrophied. The large motor cells showed great alteration; those, in particular, which formed the external group, had for the most part disappeared to give place to an islet of sclerosis. Now, we know that, according to Kölliker's description, a certain number of the nerve-filaments which compose the internal root bundles proceed towards the anterior grey cornua, and may be followed to this external group of motor nerve-cells. It is, probably, by means of these nerve tubes that the irritative process, primarily developed in the posterior columns, was propagated to the extremities of the anterior grey substance, and there determined the lesions which preside over the development of spinal amyotrophy.

Time presses, and I cannot further prolong my remarks. I venture to hope, however, that the details which I have just discussed, will suffice to enable you to appreciate the advantage which clinical observation may derive from delicate anatomical studies, conducted in accordance with the method I desire to recommend to your attention.

LECTURE II.

RETROGRADE ACTION IN SPINAL DISEASES: ITS RELATION WITH SCLEROSIS OF THE POSTERIOR COLUMNS; LIGHTNING PAINS AND GASTRIC CRISES.

SUMMARY.—*Relations between the internal radicular nerve-filaments and the groups of multipolar nerve-cells of the anterior cornua. Recurrent or retrograde symptoms. Sclerosis of the posterior median bundles; propagation of the sclerosis to the lateral bands of the posterior columns.*

Classical type of progressive locomotor ataxia. Prodromic period of shooting pains. Period of established disease, or of tabetic incoördination. Paralytic period.

Lightning pains. Their varieties; boring pains; lancinating pains; constrictive pains. Symptomatic shooting pains in disseminated sclerosis, progressive general paralysis and chronic alcoholism. Visceral symptoms: vesical, urethral pains; rectal tenesmus.

Gastric crises; specific characters. Duration. Abortive cases of locomotor ataxia.

I.

GENTLEMEN.—Some of my auditors did me the honour, at the conclusion of my last lecture, to ask me for some explanations as to the connection which appears to exist between the *internal radicular nerve-filaments*, issuing from the posterior roots, and the *external group of multipolar nerve-cells of the anterior cornua*. I am led to reply that, generally speaking, we cannot, in the actual state of science, as yet lay down anything absolutely as regards the anatomical relations which may be formed, by means of the cellular prolongations, either from cell to cell, or between the cells and the nerve-tubes, whether of the anterior roots, or of the posterior roots. Here, in a few words, is what the most recent researches teach upon the subject.

Among the prolongations which, varying in number, proceed from the great nerve-cells of the anterior cornua, there is one,

as you are aware, which in every cell is distinguished from the others by certain well-marked anatomical characters. Very fine, very slender at its origin from the cell, it gradually thickens, without ramifying, and soon acquires the histological characters of a nerve-tube. It is this prolongation which Deiters made known, under the name of *Nervenfortsatz*. All, or nearly all of these *nerve-prolongations*, according to Gerlach, proceed evidently towards the anterior extremity of the anterior cornu, where they seem to enter into connection with the radicular filaments, from which arise the motor spinal roots. As to the other cell-prolongations which, to distinguish them from the foregoing, are called *Protoplasmafortsätze* (protoplasm prolongations), they branch out soon after leaving the cell, and the ramifications thus produced branch again and subdivide, almost infinitely, as it were, so as to constitute what Herr Gerlach calls the *nerve-fibre net* (*Nervenfasernetz*). It is through the medium of this net, and not in a direct manner, that the posterior radicular bundles are supposed to enter into connexion with the nerve-cells of the anterior cornua.¹ There is a wide difference between these somewhat vague data and the almost mathematical precision with which certain authors make the nerve-cells communicate either between themselves, or with the nerve-filaments of the anterior and posterior roots. But, it behoves us never to confound problematic with real anatomy; they are wholly different things.

II.

There is another point relating, this time, to the pathological anatomy and physiology of the posterior columns, which want of time caused me to omit mention of, and yet which, I believe, deserves to be discussed.

I have to remind you, gentlemen, that in cases of ascending degeneration, consecutive on a partial lesion of the dorsal cord, (partial myelitis, either primary or connected with Pott's disease, or tumours compressing the dorsal cord), the posterior columns are affected with sclerosis, throughout their whole height up to the vicinity of the bulb; and yet, in cases of this kind the ataxic symptoms are absolutely absent from the superior extremities, at least in the immense majority of cases.

There are, nevertheless, exceptions to the rule, and this leads me

¹ Gerlach, in 'Stricker's Handbuch,' t. ii, p. 683.

to speak a few words about what we may call, in spinal pathology, the *recurrent* or *retrograde symptoms*—symptoms which were well known to Marshall Hall, who referred them, without further explanation, to a *retrograde action*.¹

If I mistake not, M. Louis² was the first author who seems to have been struck by the existence of facts of this nature. A patient, suffering from caries of the dorsal vertebræ, had exhibited, besides paraplegia, complete paralysis with contracture of the upper extremities. Still, the autopsy showed that the dorsal cord alone had been softened in a portion of its extent. Cases of this kind are, undoubtedly, not very rare; Marshall Hall, Nase, and Bieger have mentioned some. I also have seen several.

These cases do not, however, constitute one homogeneous whole, and we may establish at least two principal categories. In the first, we have a true motor paralysis, with or without contracture, occupying one of the superior extremities, or both of them at the same time; in the second, we have no paralysis, properly so called, but there is produced in the upper extremities, on intentional movements, a motor incoördination, augmented on closure of the eyes, and comparable in every respect to what we see in cases of progressive locomotor ataxia. In these patients, also, although the primary spinal lesion occupies a limited point of the dorsal region of the cord, we observe, in addition to the paralysis of the lower extremities which this determines, sometimes ataxic symptoms, sometimes a more or less marked paralysis of the upper extremities.

What is the reason of this singular complication? In order to account for it, Marshall Hall, as I have said above, has recourse to a sort of action from a distance. It is incontestable that certain experimental lesions affecting the inferior segment of the spinal cord, may react, by *distant action*, on the upper regions of this nervous column. This is well illustrated by an experiment of M. Herzen, referred to in a previous lecture. It is the following: a fragment of caustic potash being applied on the lower part of the cord of a decapitated frog, it is impossible, so long as the application lasts, to excite reflex movements in the upper extremities. I would

¹ "Retrograde Action in Spinal Diseases," 'Derangements of the Nervous System,' p. 248.

² "Mém. sur l'état de la moelle épinière dans la carie vertébrale," in 'Mém. et Rech. Anat. Path. sur diverses maladies.' Paris, 1826.

remind you, also, that, in Lewisson's experiments, acute irritation of the visceral nerves (renal and uterine) produced temporary paralysis in the lower limbs. However this may be, it seems very difficult to explain, by an action of this kind, permanent symptoms like ataxia, or paralysis with or without contracture of the superior extremities in the pathological cases which engage our attention. According to my judgment, we must seek the solution of this problem in the modifications which ascending consecutive sclerosis may, under certain circumstances, present.

Thus, as I have pointed out to you, gentlemen, ascending sclerosis, consecutive on partial lesions of the dorsal cord, keeps strictly limited, in the posterior columns, to the median fascicles. Such, at least, is the rule. Now, as was demonstrated in our last lecture, a lesion of the median fascicles, when occupying the cervical enlargement, has not the effect of determining the appearance of tabetic symptoms in the upper extremities. But, when once established, consecutive sclerosis may acquire an individual existence; and it may happen that, spreading beyond the limits usually assigned it, it may in certain cases invade the *lateral bands* of the posterior columns, lesion of which, as you know, produces incoördination. This is how I propose that you should interpret the cases of the second category. It is true that this invasion of the external bands has not yet, so far as I know, been ratified by autopsy; but the foregoing considerations, if I do not mistake, render our supposition most probable.

The facts of the second category remain to be reviewed. The following is the explanation I would suggest in reference to them. Besides the fasciculated sclerosis of the posterior median columns, in cases of partial lesion of the dorsal cord, and especially when this lesion is situated very high, in the neighbourhood of the cervical enlargement for instance, there nearly always exists a more or less well-marked sclerosis of the posterior region of the lateral columns. This ascending lateral sclerosis remains generally in a rudimentary state, and then does not determine any symptom. But, it may, in certain cases, become very marked, and ascend to the bulb, principally, I repeat, when the primary partial lesion occupies the superior portion of the dorsal region. Now, paralysis of the upper extremities, sooner or later followed by contracture, is a symptom connected with lateral fasciculated sclerosis occupying the cervical enlargement of the spinal cord.

To sum up : when ascending secondary sclerosis remains, as the rule is, limited to the median fascicles of the posterior columns, you observe in the upper extremities neither paralysis, nor contracture, nor ataxic movements. If, on the contrary, the external bands are invaded, the superior extremities will be attacked by motor incoördination. Finally, the paralysis and the contracture would appear in cases where the consecutive sclerosis should occupy, to an intense degree, the lateral columns throughout the whole height of the cervical enlargement of the spinal cord.

III.

It is time, gentlemen, to enter upon the principal object of this conference. We have, you remember, to study some points in the clinical history of progressive locomotor ataxia, which are little known, or, at all events in my judgment, insufficiently known.

If the cases which are about to engage our attention diverge all, though in different degrees, from the common type, they yet all are related to it by some essential features which never absolutely fail. It seems to me useful, before entering into details, to recall in a few words the fundamental characters of the most common type. We shall be the better able, after that, knowing the analogies, to set out and define the contrasts.

You have in your minds the description of locomotor ataxia as it was laid down by M. Duchenne (de Boulogne). It will not therefore be necessary to enter into long details to refresh your memory concerning, at least, its principal lines. All of you know that progressive locomotor ataxia is a *primary chronic disease*, which attacks different parts of the nervous system simultaneously, and which, as a general rule—there are some qualifications to be made on this point—as it advances almost inevitably becomes worse.

The spinal lesion, to which our attention has chiefly been given hitherto, does not always, of itself alone, constitute the anatomopathological ground-work. To it are referred the *symptoms* termed *spinal*, which, undoubtedly, form one of the most salient aspects of the symptomatic picture; but it is rare that these exist separately. Usually, there is superadded a whole group of phenomena, which are generally known as *cephalic symptoms*, and whose starting point is a lesion of the cerebral or bulbar nerves, such as the optic nerves, for instance, or the motor nerves of the eye.

In this relation, we can draw a parallel between progressive loco-

motor ataxia and the disease which I have proposed to call disseminated sclerosis. The latter, like the former, invades different points of the cerebro-spinal system simultaneously, and we have cause to discriminate, in the clinical description of both affections, between (1°) the spinal symptoms and (2°) the cephalic symptoms. Disseminated sclerosis, like locomotor ataxia, most usually pursues a doomed downward path. But the analogies cease there, and, in detailing the symptoms, we have only to mark differences which almost always enable us to make a diagnosis without difficulty.

IV.

It is customary to note a certain number of *periods* in the progress of locomotor ataxia, which is supposed to evolve in a normal manner. Generally, three principal periods are recognised.

The first has received the name of *prodromic period*. Wherefore prodromic? The appellation, perhaps, is ill chosen, for when the first symptoms appear the lesion is already constituted and visible. And, besides, can we conceive a prodromic period capable of extending over many years—over eight, ten, twelve, fifteen years, for instance? Perhaps it might be better to term it the *period of lightning pains*. These pains, in truth, are undoubtedly one of the most tangible phenomena, although not absolutely constant. However this be, the disease, in this period, is clinically represented by two orders of symptoms which coexist in complete cases, and show themselves separately in imperfect or *abortive cases* (*cas frustes*) as they are also called. These are: (1°) The cephalic symptoms (paralysis of a motor nerve with all its consequences—more or less marked amblyopia); (2°) spinal symptoms represented, at this epoch, by the *lightning pains*.

In the second period, termed *period of established disease*, which might also be named *period of motor incoördination*, the clinical picture is composed, in the first place, of the symptoms of the first period, in various proportions; thus the cephalic symptoms persist and show themselves in a more aggravated and marked form; the lightning pains occasionally become more intense. But the capital point is this: the spinal symptoms have undergone an important modification.

We observe, in the first place, *tabetic incoördination* of the voluntary movements. In what does this symptom consist? You know that, whilst the inferior extremities have preserved their

dynamometric power, there is asynergia—that is to say, a vicious and inappropriate association of the elementary motor acts, an asynergia whose effect is to produce disturbance in the movements of the patient whilst walking, and in his position whilst standing, and even to render both impossible.

Simultaneously, a little later or a little sooner, we find also different derangements in the transmission of sensory impressions, exhibited: (1°) by abolition of the different modes of cutaneous sensibility; (2°) by insensibility of the more deep-lying parts, such as the muscles, articulations, bones, &c.

The third period would, perhaps, deserve to be qualified as the *paralytic period*. Whilst the other symptoms become aggravated, and the upper extremities, until now free, are being invaded in their turn, after the manner indicated in our anatomical preface, we remark at the same time that the lower extremities become affected by real paralytic debility, which gradually replaces the incoördination. Then, also simultaneously, nutrition frequently suffers, in a general manner; the patients grow thin, and it is very common to find symptoms of phthisis exhibited. In other cases, nutrition is slowly and locally affected; the muscles waste away in the limbs deprived of motion; a tendency to the production of sacral eschars is shown; and symptoms of ulcerous cystitis appear.

Such, in summary, gentlemen, is the common type of progressive locomotor ataxy. We are now in a position to set out the anomalies, the deviations from this standard.

V.

Let us devote our attention, in the first place, to the study of the first period. That is the time when it is most important to recognise the existence of the disease; for, as it is then only beginning, we should hope that it would be the less difficult to arrest its course. Nevertheless, at this period, it is very frequently misunderstood. Many persons also imagine that the disease only begins at the time when the incoördination, the ataxia from which it gets its name, has become manifest. Now, at that period, I repeat, the disease may have been in existence for ten, fifteen, or even twenty years. Besides, it sometimes stops of itself at this period, without ever advancing farther, but also without retrograding. Hence it is, gentlemen, that we shall endeavour to show you that the *lightning pains* and the *cephalic symptoms* may present

themselves—and do in reality present themselves—generally with almost specific characters, which, in the absence of all other concomitant phenomena, commonly allow us to recognise the disease for what it is, and to designate it.

Let us pause, first, at the *lightning pains*, reserving for a near opportunity, a thorough examination of the cephalic symptoms. To show you the importance of this question, it is enough to remind you that, during long years, these pains may, of themselves alone, compose the entire symptomatology of the disease.

Lightning pains, besides, are found in a very large majority of the cases of progressive locomotor ataxia. It cannot be denied, however, that they are absent from some patients; but that is a very exceptional occurrence. Thus, according to the statistical table of M. Cyon, which includes 203 cases, lightning pains were expressly mentioned in 138; in 8 cases only was their absence remarked.

The varieties which they present induce us to form two categories:

1°. *Boring pains*.—Pains of this first variety are compared by the patients to those which would be caused by the abrupt and sudden introduction of a pointed instrument, an awl or a poignard, if this were twisted round on being pressed into the flesh. These pains are limited to a point, and are commonly found in the vicinity of an articulation. However, it would be going too far to assert that they always spare the body of the limbs. Generally, during a paroxysm, the boring pains alternate in different places and occupy successively several points on both sides of the body.

At the point they occupy, a more or less well-marked hyperæsthesia is momentarily produced, within a very circumscribed area; the least rub exasperates the pain, whilst a somewhat strong pressure gives relief. The inferior extremities are always affected, by preference; nevertheless, the superior extremities, the arms, head, and body are far from being always respected.

2°. *Lancinating pains*.—Pains of the second variety which, indeed, generally coexists with the first, deserve, properly speaking, the name of lightning, or fulgurant pains. They seem to follow the course of a nerve along which they shoot, like a flash of lightning. The consequence is that an extremity, or an area of varying extent is rapidly traversed by the painful fulguration. On account of the short continuance of the distressing sensation, it is often difficult to define exactly the affected nerve. This, however,

may be very distinctly done, though the occasion is rare, when cutaneous eruptions break out along the course of the nerve which is the seat of the pain. Such an occurrence marked the case of a patient, named Magdaliat, whom you now see, and who, during a most intense paroxysm of pain, exhibited, in succession, eruptions of ecthyma over the course of the lesser sciatic nerve at first, then over that of the internal saphenous nerve. Even now, you can still see the scars resulting from those lesions, which affected him four or five years ago.

3°. *Constrictive pains*.—Besides the lightning pains, we have also, in ataxia, to take the *constrictive pains* into consideration: these pains supervene either at the same time as the preceding, or irrespective of them. Their duration is longer, and their persistence greater. The patients feel as if, in certain places, the extremity were seized in a vice. Does the pain affect the trunk? They compare it to the constriction caused by an over-tight cuirass, or a corset too closely laced. The constrictive pains become frequently exasperated during the predominance of boring or fulgorant crises, properly so called. We may resume in a few words the *characteristics* of fulgorant pains:

1°. The painful fulguration (or lightning pain) has but a transient duration, as its name indicates.

2°. It is repeated at varying intervals, so as to constitute paroxysms which last for four, five, or eight days.

3°. The pain attains its maximum of intensity chiefly during the night.

4°. The remissions which separate the paroxysms may be perfectly free; the constrictive pains alone form exceptions to the rule, and persist to a certain degree during the intervals of the crises.

5°. The return of the paroxysm varies greatly: it happens every fortnight, every month, every second or third month, sometimes after still longer intervals.

6°. Sometimes the shooting pains are of moderate intensity, and it is requisite to specially question the patient about them to revive their memory; again, on the contrary, they are of extreme violence and compel the unfortunate sufferer to give utterance to frightful shrieks. In this hospital, where the number of such patients is large, we have often to witness scenes of this kind.

VI.

The numerous facts which I have had occasion to observe lead me to admit that lightning pains, when manifested in the manner I have tried to depict, are truly characteristic, I will not say of locomotor ataxia, but rather of posterior riband-sclerosis, in so far at least as that the lesion has invaded the intra-spinal course of the *internal radicular fascicles* (external bands of the posterior fascicles). This reserve was necessary. You have, doubtless, not forgotten that the median fascicles (Goll's column) may be subject to sclerosis, without shooting pains supervening; and, on the other hand, that these pains exist when the sclerous lesion has remained limited to the course of the radicular fascicles. Sclerosis of the external ribands would, alone, as you perceive, constitute the anatomical *substratum* of the lightning pains.

Knowing this you will not, therefore, gentlemen, be surprised to find lightning pains figuring, now and again, in the symptomatology of different diseases, other than ataxia, in which the posterior fascicles may be invaded accidentally, as it were, by sclerous inflammation. Such, for instance, is the case as regards disseminated sclerosis. It is not rare, in this affection, to find different tabetic symptoms, and, particularly, shooting pains superadded to the proper symptoms of the disease. In such circumstances, I have many times noted that the sclerous nodules had invaded the posterior columns, which they occupied throughout a large extent, both transversely and vertically.

Paroxysms of lightning pains are also, somewhat frequently, observed in progressive general paralysis; they should certainly be referred, in this case, to alterations of the posterior fascicles which, as shown by Drs. Magnan and Westphal, are a common accompaniment of the ordinary lesions of general paralysis.

I was consulted a few years ago by two patients who mentioned a host of odd nervous symptoms which I believed might be referred to hypochondria. These two patients complained more particularly of pains, returning in paroxysms, which were entirely similar to those of locomotor ataxia. Ultimately, both of them exhibited the symptoms of progressive general paralysis. I have no doubt that, in their case, the external bands of the posterior fascicles had been already affected at the time when lightning pains, almost alone, constituted the whole of their disease. Some of the

symptoms mentioned in the clinical account of chronic alcoholism recall the description of lightning pains; thus Magnus Huss has made special mention of the *lancinating pains*, occasionally very severe, of which alcoholic patients complain.

Recently, Mr. Wilks and Dr. Lockhart Clarke¹ have called attention to a form of paraplegia which, it appears, is rather frequently observed in London amongst women—and even amongst ladies—and which they unanimously designate *alcoholic paraplegia*. One of the most salient features of this pathologic form appears to be the existence of pains, recurring in paroxysms, and which the patients compare to electric shocks. The pains exist alone for a long time before motor disorders arrive in addition. We have reason to ask ourselves if, here also, we have not to deal with a particular form of *tabes*, of alcoholic origin, indeed, but always referable to some lesion of the posterior columns, which morbid anatomy will, doubtless, one day discover.

I have sometimes observed lightning pains, comparable to those of ataxia, in partial myelitis, and in Pott's disease. In several of these cases, at the autopsy, I identified an extensive fasciculated lesion of the posterior columns, which would account for the presence of special pains.

Apart from the cases which have just been reviewed, and whose dismissal can always be made with ease, by taking note of the concomitant symptoms, the lightning pains may be referred, almost with certainty, to the particular form of posterior sclerosis which leads to progressive locomotor ataxia. There do, indeed, occur, now and again, in practice, some difficulties of appreciation to which I will ask your attention; but, in reality, these are somewhat rare. Besides, the situation is very often simplified by the adjunction to the shooting pains of certain symptoms which have, like them, a special character. Such, for instance, are the symptoms of the ataxia, known as *cephalic*, which we shall have soon to discuss; such also are other symptoms, less noticed though often frequent enough, which may be denominated *visceral symptoms*, because they clearly attest the participation of the visceral nerves of the thorax and abdomen.

In this group of visceral symptoms, I will first of all point out the *vesical* and *wrethral pains*, which sometimes show themselves at the time when the lightning pains hold dominion, and which are

¹ Lancet, 1872.

accompanied by a frequent desire to micturate, the act being also the occasion of acute pains in the canal.

In the second place, I would refer to pains of a peculiar character, the seat of which is in the rectum, and which supervene in the same circumstances as the vesical pains. In the case of one patient, M. C., who suffered from these *rectal pains*, in their most developed type, they had preceded, by seven or eight months, the manifestation of the shooting pains, which they afterwards accompanied. They came on suddenly, and were marked by a sensation similar to what might be caused by the abrupt and coercive entrance of a voluminous body into the rectum. This is how the patient described them, and he added that, at the close of the paroxysm, there supervened a pressing need of expulsion, and even occasionally an actual expulsion of fæcal matter. These phenomena were usually reproduced twice or thrice a month; habitually, there was superadded a pressing desire to micturate, with pains during emission. During several months catheterism and rectal examination had been frequently recurred to, the medical attendant never suspecting the nature of the disease. Not until long after did the apparition of shooting pains arrive to define the situation.

VII.

But of all the visceral symptoms which may display themselves, from the period of *lightning pains*, one which is at once the most remarkable and the least known, if I mistake not, is that which I have proposed to designate by the name of *gastric crises*.

These gastric or gastralgic crises, as you may prefer to call them, offer truly special characters. Very often, however, their real signification remaining misunderstood, they are the occasion of grave errors of diagnosis.

This is not a rare symptom, nor has it been completely passed over. Mention of it will be found in a considerable number of observations collected by different authors, and particularly in case No. 176 of M. Topinard's excellent work. But the connection which really exists between gastric crises and locomotor ataxia appears to me to have been pointed out, for the first time, by M. Delamarre, author of a thesis bearing date 1866.¹ In 1868, in my lectures, I took care to insist upon the importance which I attached to this symptom, and M. P. Dubois, one of my auditors, consigned in his inaugural dissertation of the same

¹ "Des troubles gastriques dans l'ataxie locomotrice."

year the result of the studies which he had made in reference to this subject,¹ in concert with M. Bourneville.

You should, also, be informed that, in 1858, Dr. Gull, in the valuable collection entitled "Cases of Paraplegia," which he published in 'Guy's Hospital Reports,' pointed out the relation which seemed to him to exist between certain gastric symptoms and an affection of the cord, which evidently resembles progressive locomotor ataxia, as at present described.

We shall, also, meet again with gastric symptoms closely analogous, at least, with those for which I wish to obtain your attention, in other spinal diseases than posterior sclerosis, for instance in *spinal general paralysis*. The latter affection, when it predominates in the upper extremities, reminds us, by some of its characters, of saturnine paraplegia, and the cardialgic or enteralgic crises which accompany it are then sometimes, but very wrongly, regarded as lead colics. There is a difficulty of diagnosis, concerning which I shall hereafter have to enter into further details.

But it is time to tell you in what these gastric crises consist. Suddenly, and generally at a period when a paroxysm of shooting pains has seized upon the extremities, the patients complain of pains which, starting from the groins, seem to ascend both sides of the abdomen, and to fix themselves in the epigastric region. At the same time, they complain of pains situated between the shoulders, which radiate around the base of the trunk in a lightning-like manner. Then the pulsation of the heart commonly becomes violent and precipitated. Professor Rosenthal, who has occasionally witnessed these paroxysms, mentions a case in which the pulse was slower than usual during the attack. As regards my own experience, I have always observed, on the contrary, in such cases, a marked acceleration of the pulse, which is accompanied by no elevation of the central temperature.

Frequency of the pulse without fever is, in truth, a very common incident, from the first periods of the ataxia, and even apart from the gastric crises and fulgurant paroxysms, at a time when no trace of motor incoördination as yet exists.

Almost incessant and extremely distressing vomiting is often associated with the gastric crises. Food is first ejected, and then a mucous colourless liquid, sometimes mixed with bile or tinged

¹ "Étude sur quelques points de l'histoire de l'ataxie locomotrice." 'Thèses de Paris,' 1868.

with blood. An intense feeling of sickness and vertigoes are superadded to the vomiting and cardialgic pains; these may be really excruciating, and the situation is then the more afflicting because the painful fulgurations often at the same time affect the extremities with an exceptional intensity of torture.

The gastric crises of ataxic patients habitually persist, like the fulgurant crises, almost without respite for two or three days; and it is very remarkable that, in the intervals of these paroxysms, the functions of the stomach are generally performed with great regularity. Such crises may appear at the beginning of the disease, and may for long years form, together with shooting pains, the whole symptomatology of the disease. When the ataxia is fully established, and motor incoördination has been developed, the gastric crises do not therefore always disappear; often, on the contrary, they are reproduced with every paroxysm of shooting pain until the fatal termination. Such was the case with the patient *Ménil*, to mention but one, whom we have had full opportunity of observing during her sojourn of over six years in these wards.

That is, undoubtedly, a form of cardialgia which is very singular, very remarkable in all its bearings. Nevertheless, you will not find it mentioned, at least I believe it is not mentioned, in any of even the most recent special treatises on diseases of the stomach.

Many a time I have seen this symptom diverting the attention of the physician, and causing him to misapprehend the real nature of the disorder; I also have several times fallen into the snare in other days. A notary came from the provinces, ten years ago, to consult me concerning attacks of cardialgia, presenting the characters which I have just described; he suffered likewise in the extremities from paroxysmal pains which, however, were not very acute. I was not then aware of the link which unites these different phenomena. The gastric crises have disappeared, but the patient suffers to-day from all the symptoms of locomotor ataxia of the most characteristic kind.

The first time it was given to me to recognise the true signification of gastric crises, occurred when attending a young physician, who, besides these crises, suffered from shooting pains and hydarthrosis of one of the knees, spontaneously developed (arthropathy of ataxic patients). Motor incoördination did not show itself, in his case, till some months later. The whole of this group of symptoms—gastric crises, shooting pains, and arthropathies—

which have no affinity in appearance, becomes invested with an almost specific character when looked upon in a true light.

I have also seen gastric crises coexist with lightning pains, during more than five years, without being accompanied by motor disorders, in the case of M. T. The diagnosis was rendered easy in this case, owing to the existence of incipient atrophy of one of the optic nerves. The opinion which I expressed almost from the first, concerning the nature of the case, was, nevertheless, keenly contested by several physicians who visited the patient. To-day my anticipations have been found only too amply justified.

In treating this subject of gastric crises, we are not compelled to recur merely to memories. I can, in fact, introduce to you a certain number of patients in whom you can study this phenomenon. At the same time, this will furnish you with an opportunity for observing abortive ataxia, in some of the various forms which it may assume.

1°. The patient Mar—, at present aged 46 years, suffered during a dozen years from lightning pains, recurring in paroxysms, which often appear in combination with gastric crises. The latter occur about once every three or four months ; they are usually of extreme intensity, and when the patient is a prey to these pains, she shrieks aloud, contorts herself, and assumes the most extraordinary attitudes. At the close of a few days the attack terminates suddenly, as if by enchantment. Digestion is regular, in the intervals. The diagnosis is facilitated in this case by the existence of strabismus, dating from the time when the lightning pains first began to appear. There is no incoördination in the movements of the upper or lower extremities. The gait is regular, and the patient can stand a long time without fatigue. However, when she closes her eyes it becomes somewhat more difficult for her to stand or to walk.

2°. Coud—, aged 55. Twenty-nine years ago this woman became blind. The lesion of the fundus oculi consists of pearly atrophy of the papillæ. She has been subject to lightning pains during ten years. They often occupy, not only different parts of the extremities, but also the occipital region and the nape of the neck. Cardialgic crises frequently coexist with fulgurant paroxysms, and are accompanied by vomiting. This somewhat exceptional seat of lightning pains, in the occiput and nape of neck, deserves to be remarked on account of the vomiting, which often appears at the same time as they do. Such a con-

currence of circumstances might render the diagnosis obscure, and lead one to think of the existence of a cerebral or cerebellar lesion. This, however, is a point to which we shall return. Hitherto, Coud— has not suffered from any disorder of locomotion.

3°. The patient Deg—, aged 52 years, has been blind fifteen years. Here, also, pearly atrophy of the optic nerves has been found. The attacks of lightning pains, which occupy the most diverse parts of the body, and frequently also the brow, the occiput, the nape of the neck, commenced to appear at the time when the blindness began. They are often accompanied by gastric crises of great intensity. The functions of the stomach, in the intervals of the attacks, are regular. No symptom of motor incoördination exists in her case.

4°. Audib—, aged about 35, suffers, now and again, from gastric crises of a thoroughly excruciating kind, accompanied by incessant vomiting, generally coming on at the same time as the attacks of shooting pains which affect her lower extremities. These phenomena have been in existence for five or six years. Two years ago, spontaneous luxation of the right hip supervened, followed, some months after, by luxation of the left hip (ataxic arthropathy). Some symptoms of motor incoördination have shown themselves within the past twelve months.

I shall not pursue the subject further for the present.

LECTURE III.

TABETIC AMAUROSIS.

SUMMARY.—*Cephalic symptoms in locomotor ataxia. Lesions of the cranial and bulbar nerves. Progressive grey induration of the optic nerve. Progressive atrophy of the papilla. Necessity of ophthalmoscopic examination in the diagnosis of some cerebral affections.*

Isolated existence of tabetic amaurosis : its frequency. Characters of the anatomic lesion of the optic nerve, seen by the naked eye and under the microscope. Appearance of papilla : 1° , in the normal state ; 2° , in progressive grey induration. Functional derangements accompanying grey induration of the optic nerve and papilla. Modifications of the papilla in cases of embolism of the arteria centralis of the retina, in glycosuria, syphilitic retino-choroiditis, and general paralysis.

Neuro-retinitis : its forms and symptoms ; differences which distinguish it from tabetic amaurosis. Clinical facts demonstrating the importance of the signs furnished by the ophthalmoscope.

GENTLEMEN,—It is my intention to discuss to-day, in your presence, some points connected with those symptoms of ataxia which we have denominated *cephalic symptoms*. These symptoms correspond to various lesions of the cranial and bulbar nerves. From the early periods, as we have already said, the lightning pains (which are then the sole representatives of the spinal lesion) generally appear combined, in different proportions, with disorders of the bulbar and optic nerves. I will add that the latter may, in the evolution of the morbid process, occasionally precede those very lightning pains, and thus show themselves completely isolated during many months, nay even during many years. This shows what clinical interest attaches to their study.

There is, perhaps, not one of the bulbar nerves which may not be affected at this same epoch; but, commonly, the first invaded are the oculo-motor nerves. Taken in order of frequency we have, first, the nerves of the third and of the sixth pairs; then, but far behind, comes the pathetic nerve; the facial, the hypoglossus, and the fifth pair do not themselves always escape. The symptoms which are correspondent to these lesions are shown in some patients by a paralytic state, in others by pains. But, of all the cranial nerves, the optic nerves are those which, in this disease, deserve to be specially considered, on account of the great frequency of their alteration, and of the gravity of the affection which this lesion determines. Hence, in reference to this subject, we shall enter into some details.

I.

The visual disorders of ataxia may be classed under two principal heads. These are: 1°, disorders of accommodation, diplopia, connected with more or less transitory and fugitive lesions; 2°, visual disorders depending on a peculiar lesion of the optic nerve. These are far more serious than the former, for the diminution of sight, like the lesion which produces it, is distinguished by a progress which seems almost inevitably destined to increase and encroach.

The lesion of the optic nerves in question might be termed *progressive grey induration*. This would distinguish it, on the one hand, from the lesion of these same nerves in disseminated sclerosis, which runs a very analogous course, the progress of which is, so to speak, less inevitable; and, on the other hand, from the lesions known under the name of optic neuritis. In the last two cases, in spite of some features of resemblance, the lesions and the symptoms differ in an essential manner from what they are in tabetic optic atrophy.

During life, progressive grey induration of the optic nerves is identified by special ophthalmoscopic characters which answer to what, in ophthalmology, is known as *progressive atrophy of the papilla*. These characters are, according to certain authors, almost specific; and, even apart from the accompanying functional disorders, which also offer peculiarities of great clinical interest, are such as to enable us to *diagnosè* the ataxia, or sclerosis of the posterior columns, if it already exists, or to *foresee its advent*, at a more or less early date if it be not yet distinctly established. The

assertions of MM. Jaeger, Wecker, and Galezowski, are precise upon this subject.

We will see, gentlemen, what judgment we should form in reference to it. I should, however, say beforehand that, having frequently witnessed the certainty, the exactness of the diagnosis laid down by the gentlemen versed in these matters, I have been induced to share, to a large extent at least, in the conviction which they hold. Although these facts are not absolutely within my special sphere, I shall, however, request your permission to enter into some details respecting them.

My undertaking will, I trust, find its justification in the interest which should attach to all questions that concern the diagnosis of *tabes dorsalis*.

II.

A summary statement of two points, relating to the difficulties mentioned, will suffice to illustrate how important it is for us, as physicians, to familiarise ourselves as much as possible with the regular examination of the fundus of the eye.

In the first place, I shall endeavour to demonstrate to you that ataxia may present itself surrounded by symptoms such as those produced by certain encephalic lesions, by tumours for instance, and so closely resembling them that diagnosis becomes extremely difficult. At the same time, I shall point out to you what advantages you may, under such circumstances, derive from an ophthalmoscopic examination.

In the second place, according to some ophthalmologists, the optic lesion proper to ataxia may, in a certain number of cases, precede all the other symptoms, and of itself constitute the whole disease, often during many long years. Now, nothing is better established, in my opinion, as I have already indicated, than the accuracy of this proposition. If that be correct, it would consequently be of the highest importance, as you perceive, to know precisely the characters which, according to the authors quoted, enable us to recognise the amaurosis of ataxic patients, and to distinguish it from all the other forms of visual decay.

With respect, firstly, to the isolated existence of *tabetic amaurosis* during a series of years, that is a fact the reality of which may be readily demonstrated, in this vast hospital, by means of observations made on a large scale. I believe myself in a position to

declare that a *great majority of the women* who are admitted into these wards, as afflicted with amaurotic blindness, sooner or later present, after admittance, more or less manifest symptoms of ataxia. Already, in my lectures of 1868, I laid stress on this point, and my further observations allow me to confirm what I then asserted in reference to this. I might quote numerous cases in support of my statement, but I shall content myself with summarising the examples which are, in fact, very characteristic.

1°. Mil—(Salle St. Alexandre, No. 12), aged 55 years; she entered this asylum on account of blindness, in 1855. Disorders of vision, accompanied by head-pains, made their appearance in 1850. Confined at first to the left eye, they soon invaded the right. At the end of a year the blindness was complete. Now, it was only in 1860, that is to say, ten years after the outset of the phenomena, that shooting pains appeared for the first time. They soon became complicated with girdling pains; since then the disease has remained almost stationary. However, symptoms of motor incoördination began to show themselves a few months ago.

2°. Coud—(Salle St. Charles), also aged about 55 years. At the age of 26, that is, twenty-nine years ago, she suffered from violent darting pains in the orbit, and shortly after was smitten with blindness first in the left eye, then in the right. Three years later she was seized with lightning pains in the head and muscles, with which gastric crises were associated. The disease since then has undergone no aggravation.

These cases, gentlemen, could be multiplied, if I did not fear to weary you. To sum up, I am much disposed to believe, from what I have seen, that amaurotic patients, the cause of whose blindness is *progressive atrophy of the papilla*, are unlikely to escape this inevitable law.

Hence it is of importance to be able to recognise the identity, from the beginning, of this affection of the optic nerve which, ten or fifteen years after its invasion, shall be followed by ataxia; in other words, to be able, when a case of amaurosis from atrophic lesion of the optic nerve is before us, to declare whether ataxia will almost inevitably follow, sooner or later, or whether, on the contrary, the affection of the optic nerve will remain isolated.

Let us, then, investigate the characteristics of grey induration of the optic nerves, and examine if they be, in reality, almost infallible, as we are told.

III.

And first, one word concerning the anatomical lesion to which attaches the visual disorder we are about to study.

To the *naked eye* the alteration of the optic nerve shows itself under the form of a grey induration, whose appearance, in every respect, recalls that of spinal fasciculated sclerosis. As a general rule, it seems to commence by the peripheral extremity of the nerve, and then to extend, in a progressive manner, towards the central parts. The optic bands (*tæniæ thalami optici*) are also affected, in their turn, at a given moment, and sometimes even the corpora geniculata. Beyond this point all trace of the alteration is lost. It is remarkable that this should, as you perceive, follow a centripetal course in the optic nerve, whilst corresponding lesions of the spinal nerves follow, on the contrary, a centrifugal course.

Histological research, in its turn, allows us to recognise new analogies between the grey induration of the optic nerves and tabetic spinal sclerosis. In connection with this subject it is to be remembered that the optic nerves are much nearer, in texture, to the white substance of the nerve centres than all the other nerves. Thus, we find in the optic nerves, as M. Leber has pointed out, stellate connective cells, and a fibroid reticulum. I should add that the nerve-tubes which form them are very fine, very delicate, and consequently have much analogy with the nerve-tubes of the encephalon.

The lesion which constitutes the grey induration is also marked in the optic nerve, as in the spinal cord, by the fibrillary metamorphosis of the neuroglia and the concomitant disappearance, first, of the medullary cylinder, and then of the axis cylinder. To say which of the two phenomena precedes the other is a difficult thing. I incline greatly to the belief that, just as in the spinal cord, the nerve-tube is affected in the first instance, before the connective matrix. In this way we might explain why, in tabetic lesion of the optic nerves, the nerve-element undergoes a comparatively much more complete and rapid destruction than that which takes place in disseminated sclerosis, in which affection the axis cylinders do, in reality, persist for a much longer time. The grey induration of the optic nerves, in locomotor ataxia, might, accordingly, be designated by the name of parenchymatous neuritis.

However this may be, we cannot yet have recourse to histology

for the distinctive characters; for in this respect there is a very great resemblance between the induration occurring in the optic nerve, in consequence of the *neuritis* connected with cerebral tumours (*optic neuritis*), and the grey induration of the same nerve in the case of tabetic patients. Let us, then, look for more decisive data in clinical observation.

In the first place, let us describe the ophthalmoscopic characters which, in fact, up to a certain point, answer to an anatomical demonstration in the living subject. I shall very briefly remind you of the appearance of the optic papilla in the normal state.

You have not forgotten the somewhat oval form which it presents, its well-defined and distinct borders, the cup-shaped depression in its centre, finally, the slightly rosy tint which, on the other hand, distinguishes its peripheral portion, and which is due to the presence of the *vasæ propriæ* enclosed in the substance of the optic nerve. With respect to the vessels of the papilla, you know that they consist of two veins and one artery, the latter much inferior in volume to the former, and besides, easily identified by the dichotomous divisions which it presents.

Now, here is an account of how all these peculiarities are found modified in a case of *progressive grey induration*.

The papilla shows no change, neither in its form nor in its dimensions; its borders are still well marked. The vessels remain what they were before, only, contrary to what happens in the normal state, we can no longer follow them as they penetrate at a certain distance into the substance of the papilla, on which they appear to be simply laid. Nothing, indeed, is noticed radically different from the normal condition; but here is the decisive characteristic. In consequence of the change of texture which the optic nerve has undergone, and, above all, because of the disappearance of the medullary cylinder, the papilla has ceased to be transparent; it strongly reflects the light, on the contrary, and no longer allows us to perceive the *vasæ propriæ* in its substance. It follows that it shows no more its normal rosy tint, but, on the contrary, a white, chalky colour, of pearly aspect.

Such, gentlemen, is the characteristic which we must sedulously bear in mind, for, that alone, when it is distinctly manifest, is sufficient to specify tabetic amaurosis and to clear up the situation in a decisive manner. Still it is proper not to neglect the functional disorders which, also, have an importance of their own. They can,

in fact, contribute potently to form the diagnosis, in cases where the ophthalmoscopic signs are little marked, by adding more weight to the impression made upon the observer. Besides, amongst these functional derangements, there are some which, even in the absence of the ophthalmoscopic signs, cause the nature of the disease to be, to a certain extent, pre-judged.

I will, in the first place, point to the concentric and unilateral limitation of the visual field, a functional derangement which is not found in *optic neuritis*, and, in the second place, to the more or less marked contraction of the pupils, a striking contrast with what takes place in *optic neuritis*, where the pupils, on the contrary, appear dilated.

We should mention a symptom which, according to certain authors (Galezowski, Benedikt), is in some degree specially characteristic, namely, a peculiar form of achromatopsia thus distinguished: 1° loss of perception for secondary colours (1 and 5 of M. Galezowski's scale); 2°, loss of perception for *red* and *green*, the perception for *yellow* and *blue* persisting, on the contrary, to a high degree and for a long time. These signs may already have shown themselves very strongly marked, at a period when loss of visual acuity is incomplete, and the patient can still read large type.

I should add that the commencement of these phenomena in one eye, and the prolonged localisation of the lesion in this same eye, are quite the inverse of what is observed in *optic neuritis*. Again, in *tabes*, the evolution of visual disorders is, in the immense majority of cases, slow, gradual, progressive; whilst in *optic neuritis* their invasion often enough happens in an almost sudden manner.

The other functional disorders which it remains for us to notice are rather of a kind to obscure the diagnosis; but, on that very account, they also deserve to be remarked. Such are the continuous or almost continuous head-pains which are chiefly situate in the forehead and at the nape. With these permanent pains are, in many cases, associated lightning pains, occurring in paroxysms, and occupying the course of the branches of the fifth pair. In the paroxysm, the patients complain of feeling as if the globe of the eye were being torn out.

Apart from the head pains, which are a somewhat common-place symptom, the phenomena which have just been described form when taken together, an almost characteristic syndroma. They

allow tabetic amaurosis to be easily distinguished, for instance, from the amaurosis accompanying disseminated sclerosis.

Embolism of the central artery of the retina gives rise, in the long run, to ophthalmoscopic appearances which simulate those of the tabetic papilla. There are, however, decidedly distinctive characters, which you will find set out in special works. The sudden invasion, in the case of embolism and the customary coexistence of hemiplegia and heart disease, will not, besides, leave the observer long in doubt.

I shall only make a passing mention of the lesion of the optic nerve which sometimes supervenes in glycosuria and syphilitic retino-choroiditis, as being equally capable of producing, to a certain point, the appearance of tabetic papillary atrophy. Finally, in general paralysis, we occasionally observe a lesion of the papilla which differs in nothing essential from that seen in ataxia; but we have already taken care to point out that tabetic spinal lesions are found, in some cases, connected with general paralysis, and this circumstance, perhaps, may explain the frequent occurrence of progressive papillary atrophy in diffuse chronic meningitis.

I confine myself to a succinct mention of these several affections, as I propose to request your entire attention to the objective symptoms which the alteration of the optic nerve produces, and which are known as *optic neuritis* or *neuro-retinitis*, for there, in point of fact, is the knot of the situation.

Undoubtedly, there are analogies, on the one hand, between the concomitant symptoms of *neuro-retinitis* and those which accompany tabetic atrophy; and, on the other hand, between the appearance of the papilla, which denotes papillary atrophy consecutive on optic neuritis, and that of tabetic amaurosis. But there are likewise distinguishing characters for each of them, and the knowledge of these characters will enable us to render the diagnosis certain.

IV.

In order to attain this object, we must now enter into some details, with respect to *neuro-retinitis* and the circumstances amid which it arises. Of these, two deserve particular notice:

1°. (a) Blindness, so common in cases of cerebral tumours, since it occurs in nearly half the cases (Friedreich and Ladame), appears for the most part to be caused by *neuro-retinitis*.

(b) Meningitis of the base, syphilitic or not, is likewise tolerably often the occasion of neuro-retinitis; and, in such cases, the prognosis is very different from what it is on the hypothesis of cerebral tumours. If we have to do with a syphilitic lesion, in particular, the blindness need not be inevitably progressive, and sight may persist, at least to a certain degree.

Authors admit two principal forms of neuro-retinitis. In the first place, comes *neuro-retinitis par étranglement* (*Stauungs Papille* of the Germans, and "choked disc" of British authors). It is anatomically characterised by a frequently enormous tumefaction of the papilla, caused by simple congestion with serous exudation. This form seems, especially, connected with the existence of intra-cranial tumours. According to Von Graefe, the symptoms which characterise it result from the augmentation of intra-cranial pressure. But it appears to be proved that, besides the papilla, the nerve itself may be affected throughout its whole extent, and present a certain degree of tumefaction and softening, or even exhibit the anatomic characters of inflammatory optic neuritis. This, at all events, is what seems to result from the observations of MM. Hulke, Albutt, and some others. There would exist, according to this, a sort of transition between the two forms of neuro-retinitis.

2°. The second of these forms is usually known by the name of *descending neuro-retinitis*. Some ophthalmologists, and Von Graefe amongst them, assert that this form is connected, in a special manner, with meningitis, and that if it be sometimes associated with tumours, from accompanying them, this happens because basal meningitis exists at the same time. If it is possible to quote three cases of Von Graefe, as mentioned by Mr. Albutt, in support of this opinion, we should state that a recent fact, observed in this hospital, has occurred to contradict it, or at least to abrogate its absolute rule.

The case is that of the patient Ler—, in whom the symptoms of optic neuritis with atrophy of the nerve were observed. These lesions were connected with the existence of a sarcomatous tumour occupying the left occipital lobe of the brain. The cerebellar roof had been pushed back; the mesocephalon, as well as the optic bands and the tubercula quadrigemina, were greatly flattened. Well, in this case, in which intra-cranial pressure was evidently exaggerated (the hypertrophy and flattening of the convolutions leaving no doubt in this respect), and in which probably the

choking of the papilla had taken place, at a certain period, the optic nerves were grey, atrophied, in one word, sclerosed throughout their whole extent. No traces of meningitis existed.

This sclerous atrophy characterises the second form, or, if it be preferred, the second degree of optic neuritis. Anatomically, we have an interstitial neuritis, with fibrillary substitution, consecutive destruction of the nerve elements. The morbid process here assumes a more acute course than in the case of tabetic optic neuritis; multiplication of nuclei is more marked, exudation more abundant, and there, in short, lies the whole difference.

V.

Let us now inquire what are the characters presented to the clinical observer by the papilla, in these two forms, or, if you please, in these two periods of optic neuritis, and contrast them with the characters which distinguish the tabetic papilla.

A. With respect to the choked papilla nothing can be more simple. The papilla, in fact, then exhibits a tumefaction, a swelling, manifest at the first glance.

The borders, ill-defined besides, are, as it were, effaced by an exudation apparently spread both over the papilla and around it. This exudation is of a reddish-grey colour. Here and there the central vessels are, to all appearance, interrupted. This phenomenon, very marked as regards the veins, is less evident with respect to the arteries, which are small in comparison. The capillaries are well developed, at least at a certain period. This assemblage of phenomena is already very striking; but the functional symptoms also merit observation. I shall confine myself to noticing the following features:—Both eyes are usually smitten at the same time, the invasion is sometimes sudden, there is no concentric diminution of the field of vision; finally, no chromatic modification is remarked.

B. What now are the characters of optic neuritis, considered in its second form? The papilla, enlarged after a manner, shows itself with fringed borders, irregular and ill-defined. You would say it was surrounded by a sort of cloud. Because of the opacity which affects the optic nerve the capillaries and the rosy tint seem effaced. The blood-vessels are tortuous and winding, especially the veins, which appear interrupted, as if, here and there, they had been cut.

These are characters, gentlemen, which are never quite effaced, and which contrast with the ophthalmoscopic characters assigned to the tabetic papilla. As regards functional symptoms, they are similar to those of choked papilla.

VI.

It is not enough to have described the characters which, whether functionally or by ophthalmoscopic examination, distinguish *tabetic* alteration of the papilla from that attaching to optic neuritis. It is indispensable, also, to show, in the living subject, what use we can make of these facts for the better advantage of the diagnosis. I shall confine myself to one example.

Quite recently we had two patients, side by side, in our wards. One of them, named Deg—, I showed to you as a specimen of abortive ataxia, with fulgurant and gastric crises, unaccompanied by motor incoördination. The other, named Ler—, succumbed a few days ago. The first-mentioned is an ataxic patient, and no one can doubt the diagnosis, though the anatomic criterion be lacking; the second had a tumour in one of the occipital lobes of the brain.

But, you will ask me, what connection is there between a tumour, occupying the occipital lobe, and a case of ataxia, in its first stage? These are, in truth, two diseases which are not usually mentioned together, because they differ by very decided characters. Well, gentlemen, it behoves us not to depend too much upon these characters; they may deceive you. And, in point of fact, the combination of symptoms in our two patients was such that, for a long time, there was great perplexity, and the diagnosis remained absolutely uncertain. For me, it is not a thing of doubt that certain cases of cerebral tumours, which are of course great exceptions, should be connected, clinically, with locomotor ataxia. A statement of the two cases, just mentioned, will, however, afford a better demonstration than could be got from a lengthy commentary.

The patient Deg— presents the following symptoms: intense remittent cephalalgia in occiput and forehead; pains in the eyeballs, complete blindness on both sides; nearly constant pains in the nape, which appear to spread down the entire length of one arm; fits of vomiting constituting true gastric crises and accompanied by exasperation of cephalic pains; finally, painful fulgurations in all the limbs coming on in paroxysms.

The symptoms observed in the case of Ler— require a more minute description. We find: complete blindness, supervening gradually (sudden invasion, you perceive, is nowise necessary in optic neuritis); intense cephalalgia, occupying the forehead and occiput, well nigh continuous, but liable to be exasperated by paroxysms; acute pains in the eyes, subject to remissions and exacerbations; vomiting coming on in paroxysms, just as in the case of Deg—, and occasionally persisting for some days; finally, pains in the extremities.

These pains, which constitute an exception to the rule I mentioned at the beginning of this lecture, when describing tabetic pains, displayed in an unmistakable manner the characteristic peculiarities of shooting pains. Over a score of times, in the notes taken down from the sincere description of the patient, and registered at the very moment of the paroxysm, we find it stated that these pains come on suddenly, like flashes of lightning, that they affect but a point, either near the joints (knee or wrist), or on the body of the limbs, and that they are accompanied by a sort of starting of the members attacked. When exasperation of these pains and of the cephalalgia occurs then the paroxysms of vomiting come on. In addition to all these symptoms we should add a vertebral pain, spreading round the body and simulating the girdle pain. These peculiar pains, so remarkably manifest in our patient, do form an absolutely exceptional fact in cases of cerebral tumours. Thus, in 233 cases M. Ladame mentions twenty-three times the existence of rheumatoid pains in different parts of the extremities. Undoubtedly, it is but very rarely that these assume the character of fulgurant pains; nevertheless, this author, though not indeed emphasising it, points out the presence of more or less acute pains, recurring in paroxysms, and flitting frequently from one point to another.

However that may be, this singular complication is established in a peremptory manner, were it but by the case of Ler— alone. And to account for it, you cannot appeal to some tabetic complication, for the posterior columns, which were carefully examined at the autopsy, have been found perfectly healthy.

Well, then, gentlemen, with such a case, and in all probability cases of this kind will occur again, is not the question of diagnosis a most embarrassing one? Allow me also to inform you, in order to add to the interest of the situation, that in the tumour case there was titubation, whilst in the ataxic case there was no trace of it.

Now, in this difficulty, the ophthalmoscopic art came to give us its decisive aid. I place before your observation two drawings, done after nature, which I owe to the kindness of M. Galezowski: one of them represents the papilla of Deg—, and you can recognise in it all the characters of the *tabetic papilla*; the other shows the papilla of Ler—, where atrophy, consecutive on optic neuritis, is seen with all its distinguishing signs.

After that examination all difficulty ceased immediately. It became evident that Ler— was affected by cerebral tumour, as the autopsy has verified; with respect to Deg— she is ataxic. The necropsy some day will decide, and justify us, I have no doubt.

This example, chosen from amongst so many others, will suffice, I hope, to bring out, before your eyes, the interest pertaining to ophthalmoscopic study in the clinical observation of diseases of the nerve centres. Consequently, gentlemen, I could not too strongly recommend you to seek in the application of Helmholtz's mirror the invaluable assistance which it is capable of yielding in such circumstances. Cases abound in this hospital, and, in a very short time, you will be able, with a little practice, to put yourselves abreast of the fundamental facts.

M. Galezowski is good enough to give us his assistance, and offers, by means of the special instrument which he has invented, and which renders demonstration so much more easy, to render evident to all of you those particular facts upon which I have dwelt thus minutely to-day.

LECTURE IV.

ON SOME VISCERAL DERANGEMENTS IN LOCOMOTOR ATAXIA. ARTHROPATHIES OF ATAXIC PATIENTS.

SUMMARY.—*Disorders of the genito-urinary organs. Frequent desire to micturate; satyriasis; rectal tenesmus. Oculo-pupillary symptoms. Permanent acceleration and dirotism of the pulse.*

Arthropathy of ataxic patients: its frequency. Cases. This arthropathy is developed at a but slightly advanced period of the spinal disease. Prodromes. Phases of ataxic arthropathy. Joints attacked. Its special characters. Diagnosis between the arthropathy of ataxic patients and dry arthritis.

Anatomical lesions. Arthropathies consecutive on affections of spinal origin. Mechanism of production of ataxic arthropathies. Lesions of the anterior cornua of the grey substance. Desideratum.

GENTLEMEN,—It is my intention to terminate, this morning, the history of those anomalies which are most commonly met with in the first period of progressive locomotor ataxia.

I.

In one of our last meetings, I spoke to you concerning the *gastric crises*, and I showed you the important diagnostic part which this phenomenon plays, when combined with certain cephalic symptoms, such as cephalalgia and amaurosis from grey induration of the optic nerve. It is proper, in connection with these gastric crises, to mention some other *visceral affections* which may also coexist alone with the lightning pains, in the period named after them.

A. Thus, it is not an exception to find, during a fulgorant attack,

that certain disorders of the *genito-urinary organs* supervene, which have an importance of their own. Such are :

1°. Frequent desire to micturate, with painful emission of urine.

2°. *Satyriasis*, on which Trousseau laid stress ;—sexual disorder, of this class, has scarcely been observed except in the male. The symptoms which characterise it in the male consist in frequent and incomplete erections, with premature emission, &c. Analogous phenomena may also be manifested in the female, as M. Bouchard and myself have pointed out. We have found them especially marked in the woman, named Bar—, whom we observed during a long time in La Salpêtrière, and who, on the occurrence of fulgurant crises, often experienced voluptuous sensations, similar to those of coition, and accompanied by an abundant vulvo-vaginal secretion.

3°. The rectum may also be affected by singular sensations. We shall here again refer to the case of the patient, M. C—, of whom we have already spoken ; even before the shooting pains had made their appearance, he, from time to time, experienced sudden sensations in the anus and rectum, which he compared to what would be caused by the forcible thrusting of a long voluminous object into the rectum. These sensations supervened suddenly and disappeared rapidly. At times, a need of expulsion was likewise felt, which was followed by repeated involuntary evacuations of fæces. This kind of painful spasm of the intestine existed in this patient for nearly eight months before the pains in the extremities began to appear.

You will readily understand what interest these epiphenomena may acquire, in certain circumstances where diagnosis has remained uncertain.

B. There is some reason to suppose that the great sympathetic plays a part in the production of these *visceral crises*, as, for brevity's sake, I shall call them ; and this is, perhaps, the place to point out to you certain other phenomena where the great sympathetic is clearly at work. I mean the *oculo-pupillary* symptoms mentioned, for the first time, I believe, by Dr. Duchenne (de Boulogne). Participation of the cervical sympathetic is in question here.

From the first period of the ataxia it is common to find a *pupillary inequality*, and, on the same side with the more contracted pupil (myosis), there occasionally are phenomena which reveal

the paralytic state of the vaso-motors: the cheek is red; the eye, which is injected, presents a sort of chemosis; finally, there is a relative increase of temperature. During the fulgurant attack, the contracted pupil dilates, and the signs of vaso-motor paralysis momentarily disappear.

c. Beside these phenomena I shall place the *permanent acceleration of the pulse* which, as I have shown, is frequently found in ataxic patients (90—100), and the habitual dirotism to which M. Eulenberg has called attention.

Finally, we must mention the genuine fever which, at the onset of the ataxia, sometimes accompanies the fulgurant crises, as I have many times remarked (in B—'s case in particular), and to which testimony is likewise borne by Dr. Finckelburg, director of the hydropathic establishment of Godesberg, and Professor Rosenthal, of Vienna. But, I cannot deal lengthily with these different phenomena which, however, have an interest of their own. I desire, at present, to insist upon an affection, whose existence I have pointed out, and which I am accustomed to designate, in order to prejudge nothing, by the name of *arthropathy of ataxic patients*.

II.

To my mind, and I hope to make you share my way of looking at it, we have here one of the manifold forms of spinal arthropathy. What is spinal arthropathy, some amongst you may ask? I have proposed to designate by this name a whole group of articular affections, which appear to depend directly on certain lesions of the spinal cord, with which, consequently, they should be connected as symptomatic affections. The irritative lesions of the spinal cord, especially those which occupy the grey substance, react sometimes, you are aware, on the periphery, and determine various nutritive disorders, either in the skin or in the deeper parts, such as the muscles. The bones and articulations do not appear to escape this law. It follows that the arthropathies of locomotor ataxia would be, according to my judgment, one of the forms of these articular affections, developed under the more or less direct influence of lesion of the spinal centre.

Here, it may not be useless to make you remark that all the articular affections which supervene, in a patient attacked with locomotor ataxia, do not necessarily come within the following

description. Thus, it is not rare to see nodose rheumatism, common dry arthritis, coincide with ataxia. Then, and on this point I would insist, these rheumatic affections show themselves with their accustomed symptoms. Ataxic arthropathy, on the contrary, is evolved with clinical characteristics, altogether its own, as you will soon see, which cause it to constitute a really distinct disorder.

I would also add that there is no question here of an extremely rare and exceptional phenomenon. I can show you five examples of these arthropathies in about fifty ataxic patients, whom I know in this refuge. Five cases in fifty, is already a respectable number. Taking my own experience, I have observed this complication of ataxia, perhaps thirty times, in private practice and in hospital. Abroad also, Drs. Albutt in England, Mitchell in America, and Rosenthal in Vienna, have recorded analogous instances.¹

Let us first, gentlemen, consider the clinical side of the question. My friend, M. Ball, to whom several important works on this question, are due, proposes to distinguish in ataxic arthropathy : 1°, early development, and, 2°, late development. In my opinion, the arthropathy in question is always an early phenomenon, that is, a phenomenon of the initial period of the spinal disease. To be more precise, I will say that, in the natural evolution of the disease, it occurs, generally at all events, at an intermediate epoch, between the period termed prodromic and the period of incoördination. If the affection sometimes appears at a late epoch, as may certainly occur, it always shows itself in the upper extremity, in the shoulder, elbow, or wrist. Now, you know that posterior spinal sclerosis may be quite recent in the superior regions of the cord, when it is already very old in the dorso-lumbar region. Remark, gentlemen, the date of this manifestation, constant and regular so to speak, in the course of the spinal disease, for there we find a preliminary argument of some weight in favour of the special, not to say, the specific, nature of the articular lesion I am speaking of. In order that you may thoroughly realise how this affection presents itself for observation, permit me briefly to describe a few cases.

¹ The question of the arthropathies of ataxia was recently brought before the Medical Society of Berlin (30th October), in connexion with a case presented by Dr. Ponfick, noted in the wards of Dr. Westphal. See 'Berlin Klin. Wochenschrift,' No. 46, 25, November, 1872; No. 47, 2nd December: see also, same journal, No. 53, note by Professor Hitzig: "Einige Bemerkungen über die Frage nach dem Ursprung der Arthritis deformans."

First case.—M. B— had, in 1860, attacks of lightning pains. In 1866, one morning, on awaking, he was greatly astonished to see that, without the slightest forewarning, his left knee, the upper part of his leg, and the lower part of the thigh, on the same side, had been invaded by a painless, but very considerable swelling. M. Nélaton, being consulted, recognised the presence of liquid in the synovial cavity. At the end of a few days, cracking sounds were noticed in the joint. Five or six months after, all had returned to the normal state. Now, remark this peculiarity,—at the time of this occurrence, there existed no sign of motor incoördination. The legs were not flung out, and no mechanical cause had intervened. Motor incoördination did not show itself until 1866. Later on, in 1870, the ataxia having advanced, the articular affection had, on the contrary, disappeared without leaving any trace.

There, gentlemen, you have a fine specimen of the *early* and *benign form* of the disease.

Second case.—A provincial apothecary, who came to consult me last year, experienced its invasion at a still earlier period; for the arthropathy, which here also affected the knee, had come on with the first crises of shooting pains. And, precisely as in the last case, the affection is not now discernible by any sign, and the incoördination, though very evident, is, nevertheless, not very marked, since it allows the patient to devote himself, with ardour, to botanical excursions.

Third case.—The history of Dr. X— which I related to you, in speaking of *gastric crises*, resembles also that of M. B—. At a period, when the disease was symptomatically constituted by attacks of shooting pains and gastric crises only, Dr. X— became aware of the existence of a hyarthrosis of the knee, with general swelling of the extremity, supervening *without cause* appreciable—such are his own words. There was no local pain, and it was possible for him to walk, although with a little difficulty. The incoördination did not begin to show itself until five or six months after; it was then I saw the patient. The knee still contained a small quantity of fluid, and the member, which remained voluminous, presented a kind of engorgement, of induration rather than œdema.

Fourth case.—I shall here recall the patient Aub—, whom I showed to you, and who, also, had gastric crises and lightning pains, and walked, without incoördination, when a swelling supervened in the right hip, which caused her to be admitted into the surgical

wards. The left hip was invaded at a later period, when this woman was in our halls and we were able to assist at the development of this second arthropathy. It was posterior to the appearance of the arthropathies that the phenomena of incoördination manifested themselves in each of the extremities.

The patient furnishes us with a relatively rare example of a tabetic arthropathy affecting the hip-joints. I believed for a long time, and very wrongly as you see, that this articulation was always spared in such cases. She furnishes us, on the other hand, with an example of the *malignant form*, that is, a form characterised by rapid disorganisation and luxation of the joint. It is proper to contrast this example with the first three cases which, I repeat, belong to the benignant form that may terminate in cure.

Fifth case.—A patient, named Mén—, in whom I had for the first time noticed gastric crises of a well-marked character, presents a typical arthropathy of the shoulder (of all the joints of the upper extremity, the shoulder is the most frequently affected). Mén— for many years had been confined to her bed, and the incoördination was little noticeable in the superior members, when one morning, after a paroxysm of lightning pains, she called our attention to the pathognomonic tumefaction of the shoulder and the whole extremity. We found an enormous hydarthrosis, with swelling of the entire limb, and in spite of that, the patient did not complain of any pain; the rectal temperature had not risen; the pulse as usual, was 100⁰¹. At the end of a few days, we could easily perceive the existence of strong cracking sounds in the joint. M— then informed us that she had noticed them during the seven or eight days preceding the outset of the tumefaction. The swelling passed away pretty rapidly, and, soon after, a luxation of the shoulder backwards took place.

This case belongs, of right, like the previous one, to the destructive form of arthropathy, since there is dislocation of the joint.

Another point of this case now deserves to be remarked upon, I mean the absence of pain and febrile reaction. Without forming an absolute rule, the absence of those symptoms is almost constant.

It was necessary to make this qualification; as, in fact, a patient of the Hôtel Dieu, who formed the subject of an interesting clinical lecture delivered by M. Ball, constitutes an exception to the rule.

¹ Frequency of the pulse, without fever, is a common thing in ataxic patients.

Sixth case.—After having noticed, for some days, the existence of cracking sounds in the left shoulder, this man observed the appearance, in one night's time, of a tumefaction of the entire upper extremity, of such volume that this member was nearly double the size of the other.¹ Besides acute pain of the affected parts, a very marked elevation of the temperature (40° C.) was observed.

I shall not dwell on a great number of other cases of arthropathy, which it has been my fortune to observe, in ataxic patients. However, before closing this enumeration, I should mention to you, in passing, that in M. Ball's patient, the development of a zona was noticed, whilst the swelling still persisted. This complication is well calculated to demonstrate at least the neuropathic, if not the spinal origin, of the affection.

III.

I shall confine myself, gentlemen, to this summary exposition, which suffices, indeed, to make you familiar with the principal aspects of the arthropathy.

A. To sum up: without appreciable external cause, without blow or fall, apart from any traumatic accident whatever, the local affection appears. At this moment the incoördination is not yet marked, the patients do not *fling* about their legs, in a disorderly manner. I must insist on this detail, because it answers an objection made by Herr Volkmann, which has been repeated by other surgeons, who refuse to see, in the arthropathy of ataxic patients, anything else than a traumatic arthritis caused by the mode of locomotion peculiar to these patients.

Nor can you invoke, here, either the influence of cold, or a diathetic state, gout, rheumatism, &c., to account for it; the articular affections due to these causes, have, moreover, a totally different physiognomy.

B. This arthropathy is developed at a *but slightly advanced period of the spinal disease*, and most commonly when its symptomatology is limited to the lightning pains. The incoördination, it is true, does not generally make its appearance when the arthropathy has occurred. Thus it has, as you observe, its place marked for it in the regular succession of the symptoms of locomotor ataxia.

c. The arthropathy is produced, generally, without prodromes,

¹ 'Revue photographique des Hôpitaux de Paris,' 1871, p. 289,

if we except, however, those *cracking sounds* which we find mentioned in a certain number of cases (Buj—, Lel—, Mén—, &c.).

E. Most usually, the first phenomenon discernible is extreme tumefaction of the entire member, no previous difficulty in its movements having existed. This tumefaction is formed—1^o, by a considerable hyarthrosis; 2^o, by an engorgement which, in the majority of cases, presents a hard consistence, and in which the ordinary symptoms of œdema are not generally very marked.

This arthropathy is not commonly accompanied by fever, or by pains; these symptoms are only exceptionally recorded on the notes.

At the end of some weeks, or of some months, the swelling disappears and then all returns to the normal state (*benignant form*); sometimes, on the contrary, serious disorders remain in the joints, crackings, dislocations, answering to a wearing down of the osseous surfaces, and various luxations (*malignant form*). In spite of these profound lesions, the member affected by arthropathy may still serve for prehension, if it be the upper extremity; or for walking, if the hip and knee be the articulations affected. Naturally, this partial freedom of motion diminishes if the incoördination makes progress, or the luxation becomes exaggerated.

F. With respect to the question of frequency, the order of preference begins with the knee, then comes the shoulder, next the elbow, the hips, and the wrists. But the small articulations are not always spared, as we might show by quoting some examples.

IV.

Such, gentlemen, is the symptomatic picture which the arthropathy of ataxic patients usually presents. Well, then, I ask whether there is anywhere to be found, in the domain of pathology, an affection which corresponds exactly to this description.

This is a matter of dry arthritis, I am told, whenever I defend the autonomy, or at least the speciality, of the arthropathy of ataxia; and it is six years since I undertook this defence. I do not dispute that dry arthritis is in question; but, by its clinical characters, I maintain that this dry arthritis is quite special, and does not fall under the common law. Rather let us see what we shall be told by a comparison of the symptomatology of ataxic arthropathy, such as I have sketched for you after nature, with the classic description

of dry arthritis, the substance of which I shall borrow from a recent and justly-esteemed work.¹

1°. Rarely, we are told, does the quantity of fluid augment in the joint affected by dry arthritis. Now, this augmentation of fluid appears to be constant in our arthropathy.

2°. Sometimes, it is true—that is to say, as an exception to the foregoing rule—the effusion is considerable, and extends beyond the joint; now, what is the exception in dry arthritis is, on the contrary, the rule in ataxic arthropathy.

3°. The dislocation of the joint, which is very rare in dry arthritis, is very frequent in locomotor ataxia.

4°. The hip-joint is principally affected in dry arthritis; the shoulder-joint takes only third or fourth place; in ataxic arthropathy the knee and then the shoulder are preferably attacked, whilst the hip-joint is only third or fourth in order.

5°. The course of dry arthritis is necessarily progressive; it never retrogrades. Well, ataxic arthropathy may retrograde, and even be cured, when the organic disorders have not advanced too far, as has been demonstrated by some of the examples which I have mentioned.

6°. We are told that in the immense majority of cases the mono-articular form of dry arthritis has been caused by a traumatic lesion—an intra-articular fracture. I believe, indeed, that the fact is so. But our spinal dry arthritis, which is often mono-articular, acknowledges no such cause; it is not possible to appeal here to a traumatic injury, nor to an intra-articular fracture.

7°. Finally, let us add, as a last characteristic, that the first symptoms of ataxic arthropathy appear suddenly and unexpectedly, whilst in dry arthritis (still according to the standard description) the symptoms manifest themselves, and become aggravated, in a slow and progressive manner.

These differences noted, I am the first to acknowledge the analogy existing as regards the cracking sounds, the osseous tumefactions, &c. But I desire also to demonstrate what special features are to be found in the evolution, the concatenation, and the character of the symptoms; in short, to bring into the foreground the indubitable relationship which exists between our arthritis and the spinal affection—a relationship which presents this noteworthy character in particular, that the articular affection supervenes at a well-deter-

¹ Follin et S. Duplay, 'Traité élémentaire de Pathologie externe,' t. iii, p. 26.

mined epoch in the evolution of the spinal disease. Let us accept the analogies, but let us not forget the very striking differences which are made manifest by the comparison.

V.

It is proper now, gentlemen, to examine what information is supplied us by pathological anatomy. Undoubtedly, in cases of old standing, when the articular surfaces, worn and deprived of cartilage, have continued to move on each other, the limbs being still made use of more or less imperfectly, the signs observed are those of dry arthritis: to wit, eburnation and deformation of the articular surfaces, deformation of the osseous extremities, bony burrs and stalactites, foreign bodies, &c.

There are, however, two points to which I must request your attention:

1°. The predominance of wearing away over the production of bony burrs in recent cases. Compare, for instance, the humerus which I show you (fig. 6), and which comes from an ataxic patient,

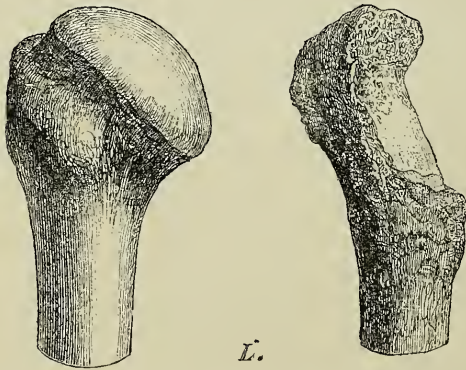


FIG. 6.—Superior extremity of a healthy humerus and of a humerus offering the lesions of ataxic arthropathy.

who succumbed two months after the commencement of the arthropathy, with the plate of Adams's work, representing the lesions of scapulo-humeral dry arthritis, and you will comprehend what reasons I have for insisting on this.

2°. I shall mention, in the second place, the frequency of true luxations, which are, to some extent, the rule in ataxic arthropathy, when the articulations admit such displacement—in the shoulder,

for instance—while they are only exceptions in common dry arthritis, in which they are usually apparent, and not real.

On the whole, anatomically speaking, our arthropathy is included within the group of dry arthritis. To that I have no serious objection to make ; but will it be asserted that this anatomo-pathological classification advances the matter much ? If before your eyes were placed, as an anatomical specimen, an articulation presenting all the signs of arthritis with sero-fibrinous or purulent exudation, you would immediately indicate it by the denomination of *purulent arthritis*, which I have just employed, and histology would change nothing in this altogether local and anatomical diagnosis. But would this completely resolve the problem ? Evidently not, for the arthritis might have been, during life, one of the symptoms of rheumatism, of scarlatina, of glanders, or of purulent infection (pyæmia), &c.

The same thing holds good, gentlemen, with reference to dry arthritis, which is often only a manifestation of nodose rheumatism, of tophaceous gout, or one of the lesions of Heberden's disease ; as it may also be, finally, in some cases, the result of a quite external traumatic cause.

An anatomical examination, even with the assistance of the most advanced histology, cannot supply everything ; its rôle is great, in truth, but not predominating, and, in pathology, to notice this only aspect is to commit that error in reasoning which, in the scholastic language of philosophy, is called an incomplete enumeration.

VI.

Notwithstanding the anatomical characters which connect it more or less closely with the standard type of dry arthritis, the *arthropathy of ataxia* remains no less a distinct variety, because both of the originality of the symptomatic group which it presents, and of its evident relationship with locomotor ataxia, of which, as an epiphenomenon, it really forms a part.

We have now to seek for enlightenment as to the cause of this relationship. If the solution of this problem be difficult, it is not impossible, I think, to supply it, at least partially.

In the first place, I would utilise our knowledge of the fact that the existence of joint-affections, more or less subordinated to a protopathic lesion of the nervous system, is not, by any means, an exceptional phenomenon. I indicated this, when I told you that

in my opinion, the arthropathy of tabetic patients constitutes a genus in the class of spinal arthropathies.

A. Again, we are to-day well acquainted with the articular affections which result from lesions of the peripheral nerves in the same way as herpes, glossy skin, rapid muscular atrophy, and so many other trophic disorders of the same kind. The observations relating to wounds received in battle, which were noted by Dr. Weir Mitchell, during the American war, and published anew in a recent work,¹ are very instructive, in this respect.

B. You are acquainted, likewise, with those singular articular affections which become developed in limbs smitten with hemiplegia, owing to hæmorrhage or ramollissement of the brain, at a certain period of the disease, and which come anatomically under the description of acute or subacute arthritis.

c. But, to speak only of what specially concerns the spinal cord, I believe I can declare that there is, perhaps, not one of the morbid forms to which it is subject which may not provoke, in certain circumstances, an articular affection manifestly correlated as a symptom of the lesion of this department of the nervous centres.

We observe these arthropathies especially: —1°, in paraplegia from Pott's disease; 2°, in acute myelitis; 3°, in certain cases of tumours primarily occupying the spinal grey substance (Gull); 4°, in certain cases of lesions of the grey substance determining progressive muscular atrophy (Rosenthal, Remak, Patruban); 5°, but the case in which it is most easy to demonstrate the connexion which exists, according to my opinion, between the spinal lesion and the articular affection is that of traumatic lesions affecting the spinal cord. I shall confine myself to two examples in support of what I have stated.

In a case, related by M. Viguès, there was a wound of the left lateral half of the spinal cord caused by a blow with a sword. Left hemiparaplegia followed, with preservation of sensibility on the side affected. About the twelfth day, tumefaction of the entire left extremity was observed, and then an arthropathy of the left knee. Finally, two days later, a bed-sore made its appearance over the right lateral portion of the sacrum and nates.²

¹ S. Weir Mitchell, 'Injuries of Nerves and their Consequences,' Philadelphia, 1872.

² For further details, see Charcot, 'Lectures on Diseases of the Nervous System,' pp. 79 *et seq.*, New Sydenham Society.

These phenomena might be considered as only constituting a simple coincidence if they were not all seen to be reproduced, with admirable regularity, in other analogous cases. Such, in particular, is that observed by MM. Joffroy and Salmon, of which the following is a summary.

A man was stabbed with a poignard which wounded the left lateral half of the cord. A few days afterwards there supervened, in succession, complete motor paralysis of the left inferior extremity ; diminution of electric contractility in all the muscles of this limb, indicating rapid and profound nutritive suffering ; eschars occupying the right nates (*i. e.* of the side not paralysed as regards motion), although the patient lay fairly on his back ; finally, an arthropathy of the left knee, in all things similar to that of M. Viguès' patient.¹

Thus, without any appreciable determining cause, there was here produced an articular affection of an acute type appearing constantly a few days merely after the spinal lesion, and accompanied by other trophic disorders, such as bed-sores, modifications of the electric properties of the muscles—trophic disorders which had all evidently the same origin. Have we not, then, gentlemen, sufficient elements to establish that the cord is, under these circumstances, the great motor agent of the symptoms ?

The *arthropathy of ataxic patients* would be, in the chronic state, the representation of the articular affections of an acute type which show themselves after acute or subacute spinal lesions.

VII.

We should now pause to seek what may be the mechanism which presides over the development of these arthropathies, and what, in particular, is the region of the spinal cord the alteration of which determines the articular lesion ; for, manifestly, all the regions of the spinal centre cannot be indiscriminately arraigned. Reverting to locomotor ataxia, where this question has been especially studied, it is clear that, *à priori*, the arthropathy could not be referred to the common and trite lesion of the posterior columns. We must look elsewhere.

By analogy with what takes place in muscular atrophy, and in infantile paralysis where the muscular trophic lesion is evidently linked with an alteration of the anterior cornua of the grey sub-

¹ Charcot, loc. cit., p. 85.

stance, I had supposed that this same region of the grey substance might also be the starting-point of our articular lesion. One fact, observed with M. Joffroy, may be adduced in support of this supposition. The same may be said as regards two other cases, studied with MM. Pierret and Gombault. I should add that a certain degree of muscular atrophy in the affected member is frequently remarked, as a concomitant symptom of the arthropathy, another circumstance which seems to designate the *anterior cornua* as the particular seat of the spinal lesion. I feel, however, bound to add that, in a quite recent case of tabetic arthropathy, in spite of patient investigations, no atrophy of the anterior cornua on the side corresponding with the articular affection was to be discerned, on a level with the points where it had been found in the previous cases. On the other hand, in this case, the spinal ganglia were very voluminous, being evidently altered. It might be, therefore, that they were called upon to play a part in the production of these arthropathies. As regards the peripheral nerves, it was ascertained that in the latter, as in the former cases, no appreciable alteration was presented by them. On the whole, the question relative to the precise seat of the spinal lesion remains yet to be decided, and requires new investigations. However, the subordination of the articular to the spinal affection remains not the less well established, I believe, by the weight of the evidence which I have just laid before you.

Notwithstanding the desideratum which I have noticed above, I would recommend, gentlemen, to your close attention, the arthropathy of ataxia as a pathological and clinical fact of genuine worth. As regards the first point, we have here an element for the solution of an interesting problem of pathological physiology. Clinically, you will learn to know an affection which, if you take up the right point of view, may contribute to elucidate the diagnosis and to avoid deplorable errors. How often have not I seen persons, not yet familiar with this arthropathy, misunderstand its real nature, and, wholly preoccupied with the local affection, even absolutely forget that behind the disease of the joint there was a disease far more important in character, and which in reality dominated the situation—sclerosis of the posterior columns.

I have done, gentlemen, with the considerations which I desired to lay before you in reference to locomotor ataxia. My intention could not be to relate the complete history of this affection; I

have always wished to treat the subject episodically, attacking the most significant and least known points. Those of you who are not already versed in the knowledge of nervous diseases may, however, recompose this classic picture by referring to the numerous descriptions which have been made in these latter times, and I cannot too earnestly recommend them to recur frequently to that given by Dr. Duchenne (de Boulogne), for, after all, it remains ever the best.

There is one point which I should, nevertheless, have wished to develop a little, if time permitted. I allude to the question of treatment. But, at this hour, there is in that domain but one really new aspect worthy of detaining us. I mean the therapeutical application of continuous electric currents. This is a subject all the more deserving of your interest, because the application of continuous currents is recommended not alone in the treatment of ataxia, but also in that of many other chronic diseases of the spinal cord. Marvels are related with respect to this method beyond the Rhine. What are we to think of these accounts? As yet I know not, for to appreciate them at their just value, one should be specially versed in these matters. Happily, a favorable opportunity is offered to us. M. Onimus, who, being indisputably competent, has with great zeal devoted himself during a year in this hospital to galvanic electro-therapeutical investigations, has been good enough to promise that on next Saturday, at our usual time of meeting, he will take my place, and in my stead will indicate in a lecture, in a different manner from what I could, the principles which should control the use of this agent. I cannot too earnestly, gentlemen, invite you to come to hear him.¹ In eight days, I shall resume the course of my conferences, when I shall treat of the symptoms which result from slow compression of the spinal cord.

¹ The lecture of M. Onimus was published in the 'Revue photographique des Hôpitaux de Paris,' 1872.



PART SECOND.

ON SLOW COMPRESSION OF THE SPINAL
CORD.

LECTURE V.

ON SLOW COMPRESSION OF SPINAL CORD. ANATOMICAL PREFACE.

SUMMARY.—*Slow compression of cord due to various causes: importance of its study.*

Causes of compression.—*Tumours of the cord; glioma, tubercle, sarcoma, carcinoma, gumma, kystic dilatation of the cord.*

Tumours primarily developed in the meninges.—*Sarcoma, psammoma, echinococci, inflammatory neoplasias (internal pachymeningitis, hypertrophic pachymeningitis).*

Morbid productions formed in the cellulo-adipose tissue of the rachis.—*Carcinoma, sarcoma, hydatidic kysts, abscess.*

Vertebral lesions.—*Syphilitic hyperostoses, dry arthritis, Pott's disease: mechanism of compression of the cord. Cancerous vertebral disease. Painful paraplegia of cancerous patients.*

I.

GENTLEMEN,—There exists a peculiar form of paraplegia which results from the slow compression that the spinal cord may suffer in various points of its course within the rachidian canal. The organic lesions which are capable of leading to this result are very different in kind. Thus, for instance, we find inflammatory neoplasms, cancerous, sarcomatous, or tuberculous tumours, syphilitic products, even parasitical growths, &c.

Clinically considered, these lesions, howsoever varied as regards their origin, should be brought together at least for an instant. For, indeed, the phenomena which they occasion by interrupting the course of the nerve-fibres in the cord, often constitute the first symptoms which strike the attention of the physician, and, given a

paralysis, it becomes a question for him to trace it up to the organic cause which provoked it.

It is to this kind of paraplegia that I purpose consecrating our conferences of this and the following days. However, before describing to you the particular symptoms which reveal its presence during life, it seems to me indispensable to compare together the many organic lesions which occasion it, as regards their pathological anatomy and physiology. For, gentlemen, the effects of slow compression on the spinal nerve-centre vary but little, save as respects the region of the centre involved, and, apart from this circumstance, they always show themselves nearly identical, whatever may be the cause which determined the compression. Hence, it is not in this direction that we should generally seek for the revelation of distinguishing signs.

But, on the one hand, before they begin to affect the cord in the natural course of their evolution, and, on the other, in the very time when they determine a more or less effective compression of this organ, the lesions in question often have an anatomical and clinical history peculiar to themselves. Now, it is this history, above all, which it will be necessary to consult in order to find the characters which permit us to ascend to the source of the disease.

II.

This preface, gentlemen, dispenses with the necessity of dwelling on the subject at length in order to set prominently before you the importance of the study to which we are about to devote ourselves. Let it suffice for me to remind you that a considerable number of the organic lesions which we are about to pass in review are most common, and consequently hold the foremost rank in ordinary clinical work. Vertebral caries or Pott's disease, vertebral cancer, intra-rachidian tumours, may, in fact, be mentioned as amongst the most frequent causes of paraplegia by slow compression.

III.

With a view to establish a little order in the enumeration which is to follow, we will group the lesions in question after the position they occupy at the outset of their development. With this aim, it is proper to recall to your memory, in a rapid way, the principal

dispositions which are presented by the cord in the midst of the spinal canal. You are aware that this nervous column, covered with its proper envelope, the pia mater, is, as it were, suspended in a sort of sheath formed by the dura mater, to which it is scarcely attached, except by the medium of the nerve roots and dentated ligament. The arachnoid plays the part of a serous membrane interposed between the pia mater and the dura mater. The latter, like the cord, is itself suspended in the spinal canal,—an osseous canal more or less flexible according to the region. The dura mater touches this canal nowhere, unless at the conjugation notches, which serve to let the nerves pass through, and again in the cervical region at a point which corresponds to the anterior face of the spinal dura mater. I should add that this contact is altogether indirect, mediate, and effected solely by means of ligamentous tracts. Everywhere else the dura mater is separated from the osseous parietes by a layer of adipose tissue, which gives passage to the arteries, veins, and nerves. Finally, gentlemen, the rachidian canal encloses the cord and its envelopes in a well-nigh hermetic manner; except, however, at the inter-vertebral notches, which may, as we shall see, admit certain pathological products formed outside of this osseous conduit.

I have been obliged to remind you, thus summarily, of the topographical anatomy, because there is probably not one of the parts I have just enumerated that may not become the seat of a morbid product, which, by the ulterior progress of its evolution, may come into contact with the cord, and exert a more or less well-marked compression upon it.

It follows from this: 1^o, that products which have begun their career outside of the rachidian canal may intrude themselves into this canal through the intervertebral notches; 2^o, that others may develop: *a*, in the bones, or periosteum; *b*, in the cellulo-adipose tissue external to the dura mater (peri-meningeal); *c*, at the expense of the roots and nerve trunks; *d*, in the dura mater or in the arachnoid and the pia mater; *e*, finally, in the cord itself.

IV.

Let us consider, in the first place, the morbid growths which originate in the spinal cord itself. Here, gentlemen, we have of its kind a group truly separate and distinct, for the mechanism whereby they engender paralysis cannot be assimilated, without reserve, to

that which is called into action by compression from without inwards. In fact, generally speaking, the neoplasms which compose the tumours slowly substitute themselves for the nerve-elements, rather than mechanically compress them. Again, you easily understand that the effects caused by the presence of these tumours necessarily manifest themselves *from the outset*, by symptoms corresponding to the interruption of spinal nerve-fibres; whilst in the case of morbid growths, formed externally to the cord, these phenomena only show themselves in a tardy manner, whence you have a first distinguishing character, which I content myself with noticing now. Its application will be found hereafter.

Intra-spinal tumours.—We shall confine ourselves, as regards these tumours, to a brief enumeration, because, on the whole, they are rather rare.

a. The *glioma* comes foremost; not, indeed, on account of its frequency, for it is an exceptional lesion, but because we have here a product special to the region, so to speak. In fact, the organs in which gliomata have been hitherto especially found are the brain and spinal cord.

Every tumour, you know, according to Müller's law, has its paradigm—its physiological type. Now, here, the neuroglia is the normal tissue at whose expense is developed the tumour, denominated glioma, and whose characters are reproduced by it.

It presents itself under the appearance of soft, greyish masses, which, by their colour and other characteristics, recall the grey substance of the nerve-centres, in which, indeed, they form by preference. The gliomata are not well-defined, easily enucleated tumours; they fuse by imperceptible shades with the nerve-tissue. Nevertheless, the glioma is a tumour in the common acceptation of the word, and this is a feature which distinguishes it from foci of sclerosis, with which it has so many analogies, for the parts invaded by it (the optic thalami in the brain, for instance) become swollen in a remarkable manner, whilst still preserving their form.

Histologically, we find in these tumours characters which recall sclerosis, for they are almost exclusively constituted by numerous cellular and nucleate elements, which are nothing else than myelocytes immersed in a finely granular amorphous substance. Under the influence of chromic acid, this intermediate amorphous substance is decomposed, if we may use the expression, into an infinity of slender

fibrils, presenting a great resemblance to what is seen in confirmed sclerosis. But the fundamental difference lies here: nowhere can we detect the alveolar disposition proper to the reticulum of the neuroglia, and, moreover, the nerve-elements are completely absent.

I shall not dwell longer on the glioma for, as regards the cord, its potency, at present, is limited to three or four more or less imperfect cases. I cannot, however, abstain from mentioning the following peculiarity: the glioma is a very vascular growth, and the vessels which traverse it are specially liable to burst, whence effusions of blood, of various extent, within the core of the tumour. These hæmorrhages may reveal themselves during life by sudden symptoms, and, after death, may mislead by suggesting the notion that the lesion was a primary hæmatomyelia (or cord-hæmorrhage), a rare affection, the reality of which has even been questioned.

b. After the glioma I would mention *solitary tubercle*, which may be regarded as one of the most frequent of intra-spinal tumours. It generally coincides with the existence of tubercles developed in other organs.

c. The different varieties of *sarcoma* and *carcinoma* can scarcely be said to show themselves, at the first onset, in the cord itself.

d. The *gumma* or *syphiloma* is also a morbid growth, but little frequent as an intra-spinal tumour. There exist in the records of our science about three or four examples of this kind, and the description is mostly insufficient. Nevertheless, I hope to show you, gentlemen, in connexion with a case which has recently fallen under my observation that we may, with the help of circumstances, recognize with some precision during life the presence of a syphilitic lesion in the cord.

e. I do not wish to quit the group of intra-spinal tumours without pointing out to your notice the *kystic dilatation* which is sometimes presented by the central canal of the spinal cord. In a case of Gull's, and in some others, this lesion was indicated, during life, by paresis with muscular atrophy of the upper extremities. The expansion in this case, affected the canal, throughout nearly its whole length, in the cervical enlargement. The last-mentioned symptom, muscular wasting, is easily understood, because in expanding, the dilated canal should almost infallibly determine a more or less strong compression of the anterior cornua of the grey substance.

V.

Tumours primarily developed in the meninges.—Gentlemen, it may be said with Dr. Gull that the majority of tumours which are developed primarily in the meninges, belong to the class of benignant neoplasms. Carcinoma does not figure there except in a merely accessory way, at least as a primary tumour. It is on the dura mater and on its inner surface chiefly that most of the morbid growths occur. They form more or less rounded tumours, sessile or pedunculated, which do not commonly acquire a large volume. Their dimensions are mostly those of a bean, a cherry, or at the very most of a small egg.

We shall mention amongst the most common :

1°. The different varieties of *sarcoma*, comprising the fusocellular sarcoma, and the medullary or round-celled sarcoma.

2°. The *psammoma* or *arenaceous tumour*, which deserves to hold our attention a little, because here we have a growth proper to the region; this is the *angiolithic sarcoma* of MM. Ranvier and Cornil. The tumour is composed of little rounded or muriform calcareous masses, having an envelope of cells adherent each to each which by their arrangement remind us of epidermal globes.

The physiological type is represented by small analogous tumours which exist, in the normal state, on the surface of the cranial dura mater, and of the choroid plexuses. In the cranial cavity, their volume is rarely considerable enough to determine symptoms of compression; but, in the rachidian canal, even when they do not attain the size of a haricot bean, these tumours, developed under constraint between the dura mater and the cord, promptly occasion the flattening of the nerve column and the phenomena which are its consequences.

3°. I cannot dispense with a mention, as we pass, of the existence of *echinococci*, developed between the visceral layer of the arachnoid and the pia mater, as different cases have demonstrated, amongst others, those related by Bartels and Esquirol.

4°. Finally, in reference to the dura mater, I shall call your attention to the *inflammatory neoplasms* capable of giving rise to the phenomena of slow spinal compression, although, in such circumstances, there is no longer question of tumours in the rigorous acceptation of the term. These are :

First, *internal pachymeningitis* which, here as in the cranium, may become the starting-point of a hæmatoma (as in the case of Rühle).¹

Second, a form of pachymeningitis particularly frequent at the cervical enlargement, and which might be termed *hypertrophic*, for it especially consists in an often enormous thickening of this membrane. Commonly also the other meninges participate in the alteration. The membranous canal, formed by the meninges, grows narrowed, the cord becomes strangled as it were by its hypertrophied envelopes, which, themselves, at a given moment, suffer a sort of retraction operating through a special mechanism, and which differs from ordinary compression. The affection which produces these accidents is not rare, and it is possible to identify it, during life, by the help of certain characters. Thus it merits, from every point of view, a special study which we shall undertake at a future opportunity.²

VI.

With respect to the *cellulo-adipose tissue of the rachis*, this also gives birth to morbid growths which, in developing, succeed in exerting mediate compression on the cord, by thrusting in the dura mater.

I have often seen carcinoma occupying this region in certain cases of cancer of the breast; other tumours, and particularly sarcoma and hydatid kysts, may take up their primary position here. According to Traube, abscesses are also formed in this cellulo-adipose tissue which, issuing out through the intervertebral notches, make their appearance on the borders of the rachis. But, in general, it is the inverse of this which meets the eye; tumours of different kinds, originating on the outside but in the vicinity of the rachis, advance towards the interior, naturally through the apertures offered by these notches, and so penetrate into the spinal canal. Thus it was with the *hydatid kysts* described by Cruveilhier, and the *pre-vertebral abscesses*, those, for instance, which are developed behind the pharynx and which are sometimes designated, in Germany, by the term *Angina Ludovici*, from the name of the author who first described them properly. At other times, these products make themselves a way by a different method. They introduce themselves into the spinal cavity by a broader, if not a

¹ Rühle, 'Greefswalder Medizinische Beiträge,' I Bd., Dantzig, 1863, p. 8.

² See Appendix, note A.

shorter path, by disintegrating and dissociating the vertebræ. I would quote, for instance, in connexion with this subject, the action of hydatids and of aortic aneurisms.

Let us likewise mention the *neuromata*, the *fibromata*, and the *myxomata*, developed at the expense of the connective envelope of the nerves, the structure of which appears formed on the model of the mucous network of Wharton's gelatine. These tumours determine first the compression of the nerve elements, then, lacking room in the spinal canal, they thrust in the dura mater and by that medium press upon the cord itself.

VII.

Vertebral lesions.—I come, gentlemen, to what is undoubtedly the most important point of this exposition :

1°. I shall not speak of the *syphilitic hyperostoses*, which have been admitted rather on hypothetical grounds than on rigorous examination, so far at least as regards their forming tumours voluminous enough to compress the cord.

2°. I shall also confine myself to mentioning *dry arthritis* of the inter-apophysar vertebral articulations, hypertrophy of the odontoid process amongst others, which arthritis in certain rare cases, very rare cases indeed, since Adams who occupied himself specially with this question never met any examples, is capable of producing the phenomena of spinal compression. By way of memorandum, I would cite the report of a case by M. Bouchard, which was noted in my wards.

3°. But I shall make a special delay on coming to *Pott's disease* (vertebral caries), and *vertebral cancer*. These affections may, in fact, be counted amongst the most common causes of organic paraplegias, considered generally, and of paraplegias by compression, studied in particular. Of necessity, I shall not enter into all the details which would suit a complete history of these affections; I shall devote myself exclusively to those points which relate most directly to the compression which these lesions have the power of determining.

A. I will commence with *Pott's disease*. It is a remarkable thing that, though this is evidently a very common disorder, people are not yet agreed as to the manner in which the spinal cord becomes affected. The desideratum has been fulfilled, in recent days, by one

of my clinical assistants, M. Michaud, in an inaugural dissertation which I recommend to your attention.¹

Generally, it is summarily stated that the paraplegia is a result, in such cases, of the exaggerated and often angular bending of the rachidian canal, when one or several of the vertebræ have given way. But then, as Boyer and Louis remarked, the paraplegia may disappear, whilst the curve still continues to the same degree. Again, paraplegia from Pott's disease is to be seen when there is not the slightest trace of deformity.² Finally, a third argument against the current opinion lies in the fact that we know, as M. Cruveilhier particularly noted, that the spine may present the most extraordinary deformities, whilst the cord continues intact.

According to our researches, gentlemen, this is how things happen in the immense majority of cases : at the onset, it is possible that a caseous abscess, formed at the affected veterbræ, may thrust back the anterior vertebral ligament, which then makes a bulge in the canal ; but this is not the ordinary mode. The vertebral ligament becomes dissociated, ulcerates, and, lastly, gets destroyed at a certain point in such a way that, as M. Michaud has well shown, the pus of osseous origin comes into contact with the anterior face of the dura mater which subsequently takes on inflammation, after its manner. A peculiar kind of external caseous pachymeningitis is here produced, whose mode of evolution has been minutely studied by M. Michaud. It is really the external surface of the dura mater which vegetates and proliferates, for the middle portion and the internal surface frequently remain quite intact. The products of the inflammation dissociate these superficial layers and, preserving a certain degree of coherence, go to form a sort of mushroom of more or less volume, which is, in reality, the agent of compression. In the core, the embryoplastic elements are still perfectly visible to histologic scrutiny ; on the surface they have undergone caseous metamorphosis. This inflammation extends along the dura mater from before backwards, but the mushroom is rarely transformed into a perfect ring or belt, so that the cord only appears compressed on one portion of its external surface.

It need not be added that the nerve-trunks, in their course through the altered portions of the dura mater, are, in their turn, the seat of more or less considerable lesions which will be mani-

¹ Michaud, 'Sur la méningite et la myélite dans le mal vertébral.' 1871.

² Cas de M. Liouville,

fested, during life, by corresponding symptoms; this is a fact which we shall make use of hereafter.

B. Along with the vertebral disease of Pott, I will place the *cancerous vertebral disease*. Rarer than Pott's disease, vertebral cancer nevertheless presents itself frequently enough in clinical practice. We meet it tolerably often at *La Salpêtrière*, situated as we are, indeed, under quite special conditions of observation.

Seldom primary, vertebral cancer shows itself particularly after cancer of the breast, and principally when this takes on the hard forms of carcinoma. It is likewise observed consecutively on renal cancer, on gastric cancer, on cancerous degeneration of the pre-vertebral ganglions, supervening either as a secondary manifestation or caused by a sort of gradual extension, a direct propagation, as it were, of the disease.

Vertebral cancer has been the object of important works; I would cite amongst others those of C. Hawkins, Leyden, Cazalis, my own researches, and, finally, the thesis of M. L. Tripier which is founded chiefly on information obtained in this hospital.¹ Let us now see how vertebral cancer appears on anatomical examination.

There are cases in which the cancerous nuclei, developed in a small number in the core of the bodies of the vertebræ remain absolutely latent; this variety of vertebral cancer is very common, but it is not this kind which should command our interest in the present lecture.

In other instances, the bodies of the vertebræ, infiltrated throughout by the neoplasm, soften and give way under the weight of the frame. This subsidence often takes place without the supervision of any well-marked deviation, and this peculiarity is of some importance. In other cases, we remark a rounded curve, of large radius, which is very different from that of Pott's disease.

Cancerous infiltration does not, however, confine itself to the bodies of the vertebræ, it also invades the laminæ and the apophyses. In such cases, the vertebræ are occasionally as soft as caoutchouc. One of the most serious consequences of this state of things will be the compression of the nerve-trunks, in less or greater number, on their passage through the intervertebral notches, owing to a mechanism which I have already described.

This compression, you will carefully remark, may exercise its

¹ Tripier, 'Du cancer de la colonne vertébrale et de ses rapports avec la paraplégie douloureuse, 1866.

influence, though the cord be not involved, and in this way is produced that symptomatic grouping which I have proposed to designate under the name of *painful paraplegia of cancerous patients*; for not only are the nerves thus compressed by the weight of the vertebral column, the starting-point of very keen pains, but they may also bring about a weakening of muscular strength in the members to which they extend—a weakening which is itself followed, in the long run, by a more or less marked atrophy of the muscles.

Compression and nerve-irritation are frequently at work, and that to a high degree, in vertebral cancer. They exist also in Pott's disease, but less marked, more circumscribed, and operating, indeed, by another mechanism. In such circumstances, the nerve irritation is occasioned by their passage through the inflamed points of the dura mater. Nerve compression may also be produced in the case of tumour or inflammatory neoplasm originating in the meninges; hence it is an element which shows itself, in various proportions, in all cases of organic lesions which, developed externally to the cord, produce, in one of their phases, the compression of this organ. The tumours alone which are primarily developed in the central parts of the cord escape this law, and that is a circumstance which must be considered in diagnosis.

But let us return, gentlemen, to vertebral cancer. The compression of the nerve trunks by the means which have just been indicated is not all. Commonly, a circumstance is superadded, the consequence of which is to entail the participation of the cord. The cancerous masses make their way out of the bodies of the vertebræ; they reach the periosteum, and the dura mater, which, for the most part, presents an obstacle that is soon conquered, and thus the cord becomes involved. There are, in truth, many other combinations, but I think the foregoing explanations will be sufficient to make you acquainted with the most usual phenomena.

LECTURE VI.

ON SLOW COMPRESSION OF THE SPINAL CORD. ANATOMICAL MODIFICATIONS IN CASES WHICH TERMINATE IN CURE. SYMPTOMS. PSEUDO-NEURALGIAS. PAINFUL PARAPLEGIA OF CANCEROUS PATIENTS.

SUMMARY.—*Anatomical modifications which the cord undergoes at the compressed point. Changes in form; softening, induration. Interstitial myelitis. Ascending and descending consecutive sclerosis. There may be restoration of function, notwithstanding the existence of profound lesions. Regeneration of nerve tubes at the compressed point.*

Symptoms.—Extrinsic and intrinsic symptoms. Topographical anatomy of the vertebral region.

Extrinsic symptoms: pseudo-neuralgias. Pseudo-neuralgias in cases of rachidian tumours, of Pott's disease, and in cancerous vertebral disease.

Painful paraplegia of cancerous patients. Pain, its characters, paroxysms. Tegumentary hyperæsthesia. Eruption of zona along the course of painful nerves; circumscribed cutaneous anæsthesia; partial muscular atrophy and contracture. Deformation of the vertebral column. Difficulty of diagnosis in certain cases: osteomalacia, hypertrophic cervical pachymeningitis, spinal irritation, &c.

GENTLEMEN,—You know how we passed in review, at our last meeting, the principal organic lesions which may determine slow compression of the spinal cord. At present, we must study the effects which this compression produces on the texture of the cord.

There is no question here, gentlemen, of purely mechanical phenomena; the cord reacts after its manner, and sooner or later inflames under the influence of compression, whatever may be its

cause. This is a fact which, I hope, will be easily placed beyond a doubt.

I.

Let us first examine what takes place on the spinal cord at the point where it is compressed.

Possibly in the early stages we had there *simple compression* only, without other modification than what results from pressure exercised on the parts. This, most assuredly, was what took place in the two following cases. In the first, which Ehrling relates, the compression was due to the luxation of a cervical vertebra. An operation for its reduction was successful, and, at the end of eight days, all symptoms of compression had disappeared. The second case, mentioned by M. Brown-Séguard, relates to a patient, suffering from Pott's disease, who suddenly exhibited symptoms of compression denoted by complete paraplegia; on the application of a suitable prothetic apparatus all trace of paralysis vanished in fifty hours. In both of these cases, rather exceptional as they are, the compression came abruptly into action. Consequently, they differ from those which should here engage our special attention. The numerous observations which, with M. Michaud, we made in the course of the last two years relative either to tumours or to Pott's disease, have always shown, even at an early period, a more or less profound alteration of texture, in addition to the change of form occasioned by the compression.

Mention has sometimes been made of softening by ischæmia, comparable to that produced by arterial obliteration, and supervening in the spinal cord on a level with the point of compression. M. L. Tripier has called attention to this secondary lesion in the case of cancer of the vertebral column. This, however, is undoubtedly rare, and I should also add that the anatomical examination, as conducted in the case in question, is not beyond criticism, the cord having only been examined in the fresh state, and not after a hardening process which could alone have made connective hyperplasias clearly manifest.

In fact, according to my observation, the naked eye perceives sometimes a softening, sometimes an induration either with or without change of colour of the affected region of the cord. But microscopic examination of sections made after hardening always detects, in the compressed part, the existence of transverse inter-

stitial myelitis, recalling the characters of sclerosis and accompanied by a more or less complete destruction of the nerve-tubes.

The plate, which I place before you, enables you to recognise the alterations which the cord presents at the point of compression, in the case of a woman who suffered from Pott's disease: this patient succumbed to an intercurrent disease, at a time when the consecutive paraplegia, of two years' standing, was most marked (see Plates I and II).

The neuroglia appears transformed into a dense and resisting connective tissue. The trabeculæ which it forms are usually thickened. Generally, the medullary cylinders of the nerve-tubes have disappeared, and we find instead groups of fatty granulations agglomerated under the form of granular bodies. Many of the axis-cylinders have persisted; some of them even seem to have augmented in size.

In short, we find here again the characters which are met with in certain cases of primary subacute or chronic transverse myelitis.

But, the spinal lesions in slow compression do not remain confined to the point compressed; they extend, following the laws well known since the labours of Türck, above and below this point, along certain fascicles of the cord; above, they affect the posterior columns, and below, the lateral columns. Finally, the lesion influences only one lateral half of the cord, if the compression itself be hemilateral.

Are these secondary lesions purely passive and analogous to that which the section of a nerve determines? I am unable to say. It is constant that they show themselves, as I have pointed out, in cases of primary myelitis, that is to say, in cases where compression cannot well be accused. It is constant also, and this is an important peculiarity, that at a given moment the lesions in question show themselves in the invaded columns with all the characters of interstitial sclerosis. Hence, we have not to deal with an ascending and descending degeneration only, in the strict acceptation of the word, but with a true sclerosis or consecutive fasciculated sclerous myelitis.

II.

Transverse myelitis with consecutive ascending and descending sclerosis,—such, in short, gentlemen, are the necessary effects, so to speak, of slow compression of the cord, whether it be due to

Pott's disease, cancer, tumours of all kinds, or yet, again, to intraspinal tumours. Here a question suggests itself: Is the marked disorganisation, referred to above, beyond the resources of nature and of art? Can a cord so gravely altered never resume the whole or part of its functions, whilst recovering at the same time, it is understood, the whole or portion of its normal texture, the cause of compression having ceased?

It is not questionable but that this may take place, as regards Pott's disease, and most probably the same would hold good with respect to cases of tumours were it not the nature of these not to retrograde.

The curable character of Pott's disease, which has been well established, particularly by MM. Bouvier and Leudet,¹ even where it entails paraplegia, allowed us already to foresee that this might be the case.

Some classic authors, indeed, seem to believe that, when once it showed itself, paraplegia from Pott's disease scarcely ever retrograded; they make mention only of cases in which paralysis of the superior extremities, after having been more or less well marked, improved or even completely disappeared in proportion as an abscess by congestion was developed on a part of the body.

These assertions, gentlemen, would give you a very false idea of the future of paraplegia from Pott's disease. It is notorious, in this hospital, that paraplegia from Pott's disease is often cured, is perhaps mostly cured, in the conditions in which we see it, even when symptoms, which allow no doubt of the existence of an inveterate myelitis, have been exhibited in a most evident manner, and are of old standing.

I cannot say if the Pott's disease, which is cured in such cases, belongs more specially to one or other of the forms described by M. Broca. All that I can affirm is that the patients are persons who have surmounted the first phases of the disease, and whose general health is satisfactory. And I can also assure you that none of those patients had any abscess externally discernible.

Putting this aside, the paralysis, I repeat, may have shown itself as complete as possible, accompanied by insensibility, by permanent contracture, and may have persisted without change for the better during months or even years.

¹ Leudet, 'Curabilité des accidents paralytiques consécutifs au mal vertébral de Pott, Soc. de Biologie, 1862-3, t. iv, p. 101.

I can introduce to you two patients in whom this happy result has been obtained. One of them had the lower extremities completely paralysed for eighteen months, the other for nearly two years. Both of them, naturally, have retained their spinal deformity; but both have recovered the complete use of their lower extremities; for the last two or three years they have been able to walk without feeling of fatigue, and can go long distances on foot. In other words, they do not retain the slightest remnant of their paraplegia. In this institution and elsewhere, I have already met with five or six similar cases. In such instances, the cure seems to me to be due to the intervention of medical art; it is after the application of the actual cautery, in punctuations upon the hump, on either side of the spinous apophyses that the cure takes place. I do not believe that this can be always attributed to a mere coincidence; it is to some degree a foreseen and predicable consequence.

Well, but what was the state of the cord on a level with the compressed point, in these patients, or rather what is its condition still? I believe I shall be able to give you satisfactory information with respect to this question. The changes which we have observed in the case of a patient named Dup—, who recently succumbed to coxalgia, when her paraplegia had been cured two years, will serve for the demonstration.

In this woman's case, the cord at the part where compression had taken place in consequence of Pott's disease, was no bigger than the barrel of a goose-quill, and in section corresponded to about the third of the section of a normal cord, examined in the same region. It was very firm in consistence, and grey in colour; in one word, the cord presented all the appearances of most advanced sclerosis (Pl. III, fig. 1).

Above and below this contracted part, the white fascicles, in the usual direction of secondary degenerations, were occupied by grey tracts.

Between these appearances which the contracted part of the cord presents, when examined only by the naked eye, and the phenomena observed during life, there seems to exist a most striking and singular contradiction.

The recovery of function, we have said, was perfect at the time of death; nevertheless, at that period, the cord, if we consider the information supplied by macroscopic examination only, was the seat

of lesions so profound that it seemed literally interrupted, in one part of its course, by an apparently sclérous band in which it might fairly be supposed that all trace of nerve-tubes had disappeared.

Histology shows us that the contradiction is not a real one. The connective substitution is here only in appearance. In the heart of the fibrous tracts, which are, indeed, very dense and very thick, and which give to the cord its grey colour and hard consistence, the microscope enables us to discover a tolerably large quantity of nerve-tubes, furnished with their axis-cylinders and their medullary sheaths, and, consequently, very regularly and normally constituted.

By means of these nerve-tubes it was that the normal transmission of the commands of the will and sensory impressions was carried out.

Here, however, we meet with more than one serious difficulty.

In the first place, how has the reparation taken place of those nerve-tubes which re-established the nervous communications between the upper and the lower segment of the spinal cord? Did a complete reproduction of the nerve-filaments happen, or was there only a reappearance of the medullary sheaths to clothe the denuded axis-cylinders?

Again, as I pointed out to you, the section-surface of the piece of contracted cord scarcely represented, in its diameter, a third of the surface of a normal cord, considered in the same region. The number of nerve-tubes was, consequently, much below the normal standard in the compressed part of the cord. I should add that the grey substance was no longer represented in this part, save by one of the horns of grey matter in which we could find but a small number of nerve-cells intact. Nevertheless, these conditions, so unfavorable in appearance, had sufficed, I repeat, for the complete re-establishment of sensation and movement in the inferior extremities.

These are so many problems of pathological physiology which I am not in a position to solve at present, and so I confine myself to offering them for your meditation.

III.

We are now in a condition to study, with advantage, the symptoms which result from slow compression of the spinal cord. But, on the very threshold of the question, the necessity of establishing an important distinction appears before us. The symptoms which

are directly connected with the effects of the interruption of the course of nerve-fibres in the cord are almost never seen completely isolated, in practice. Almost always phenomena are superadded, whose character varies according to the nature of the organic lesion which is at work. And, gentlemen, a thorough knowledge of these phenomena is of the highest interest for the clinical observer, for this it is which, in the immense majority of cases, supplies the elements of the diagnosis. In point of fact, as I explained to you at our last meeting, the consequences proper to spinal compression itself are always the same, whatever be the cause of the pressure. They vary but little, in short, save in proportion to the degree of the compression, or according as it affects one or other region of the cord. Hence, it is not in this direction, you perceive, that we could hope to discover distinguishing characters.

IV.

For greater clearness, we will designate, by the name of *extrinsic symptoms*, those phenomena which intermingle with the peculiar symptoms of spinal compression. For the latter we specially reserve the name of *intrinsic symptoms*. Let us now consider the first mentioned.

In order to facilitate the knowledge of these *extrinsic symptoms*, and the better to understand the cause of their existence, let us refer to the topographic study of the region in which all the phenomena, that we are about to describe, are produced.

Proceeding from without inwards, after the extra-rachidian soft parts abundantly provided with nerves, we encounter the different parts of the vertebral column in which numerous nerve-filaments are distributed, and which, in the pathological condition, may become the seat of acute pain. Then comes the adipo-cellular layer (*périméninge*), which the multiplied nerve-filaments that accompany the vertebral sinuses (*rami sinus vertebrales*, Luschka) penetrate by the intervertebral notches.

Deeper still, we find the envelopes of the cord. The *dura mater* first presents itself; Purkinje, Kölliker, Luschka, hold that it is devoid of nerve branches; Rudinger, on the other hand, maintains that it possesses them. However this may be, according to Haller and Longet, the *dura mater* is insensible in the normal state; but, on the other hand, it is certain, according to Flourens, that in the pathological condition, that is to say, when

it is inflamed, the dura mater may become the seat of acute pain; as to the *arachnoid* membrane, it has no proper nerves. On the other hand, the *pia mater* possesses a large number of them.

This is not all yet. The cord appears, to some extent, endowed with sensibility in its posterior columns, at all events, if we are to judge by experimental conditions. You will understand from this summary sketch, gentlemen, that the different parts we have just enumerated may, all of them, betray their suffering by more or less acute pain. However, I have purposely neglected until now the most important point.

From the spinal cord arise the *anterior* and *posterior roots* which traverse the pia mater, the arachnoid, and finally the dura mater, and then unite to form the original trunks of the mixed nerves which travel some distance through the intervertebral channels before proceeding to spread out beyond. Now, all these parts are eminently sensitive, the anterior roots excepted, and it is precisely because of the irritation which they undergo on account of the compression, that the most interesting of the extrinsic symptoms offered to our study are developed.

V.

It is true we should not neglect the noteworthy indications which may be supplied by, 1°, the presence of an extra-rachidian tumour (aneurism, hydatid tumour); 2°, the discovery of a deformation of the spinal column, presenting itself with varied characters according, for instance, as it is connected with Pott's disease or with vertebral cancer; 3°, nor are we to neglect the existence of local pain corresponding to the place which the lesion occupies, and depending on irritation of the bone or on that of the meninges. But, above all, we must closely attend to the symptoms resulting from irritation of the roots, or of the peripheral nerves. For, it is their presence which, above all, impresses a peculiar physiognomy on the different forms of spinal compression. They are absent, in fact, as a rule, in those cases in which tumours, or yet other lesions, become primarily developed in the substance of the spinal cord. Hence, M. Cruveilhier could say, with justice, that acute pain is a symptom of extra-spinal lesions, and that it is absent in cases of intra-spinal lesions. Although here, as elsewhere, exceptions are not rare, the rule remains. Dr. Gull is of the same opinion, since he, also, asserts that this is a characteristic sign.

According to the foregoing, gentlemen, these symptoms always precede (a point worth noting as it has its own importance) the appearance of the intrinsic symptoms ; so that often, and for a very long period, they constitute of themselves the whole disease, or rather all the external appearances of the disease. This is a circumstance which may, in practice, be the occasion of a multitude of mistakes which require to be carefully shunned. In support of this assertion, it will be enough for me to remind you, for instance, of the difficulties in diagnosing vertebral caries, at the outset.

The symptoms due to irritation of the nerve roots or of the peripheral nerves are constant or little short of it, and you will easily comprehend it, if you would just remark that, at a given moment, an extra-spinal tumour, whatever be its starting point, cannot fail to encounter the nerve-roots, or the mixed nerves in their intrarachidian course, and to cause their compression, that is to say, their irritation, at least in the early stages.

With respect to the extra-rachidian tumours which tend to approach the cord, they bring about an analogous result, by producing irritation of the nerve-trunks after their exit from the rachis (aortic aneurism, hydatids).

VI.

The symptoms in question are commonly designated under the name of *pseudo-neuralgic* ; but, in reality, almost always, at least at a certain period, we have here a true neuritis, comparable in all respects to that which arises and progresses under the influence of a traumatic lesion. The character of the pain is the same (*burning pains*). The absence of painful points, increased by pressure, which is one of the objective characters of neuralgias, is likewise to be remarked. Finally comes the manifestation of the series of trophic disorders which scarcely belong to neuralgias properly so called ; such, for instance, are zona, pemphigoid bullæ, and even eschars, in the cutaneous region ; and more or less rapid atrophy, paralysis, and contracture, in the muscular. Moreover, the inflammatory nature of the nerve-lesions has been several times clearly identified by M. Bouvier, amongst others, in Pott's disease, and by myself in vertebral cancer.

VII.

But let us leave this general point of view, gentlemen, to descend

into the concrete, and show the clinical interest which belongs to the study of these symptoms; we will examine them, successively, in the three principal groups which follow: 1°, intra-rachidian tumours; 2°, Pott's disease; 3°, vertebral cancer. It will be easy afterwards to apply, in a certain measure, to the other forms the results which this first study is about to furnish us.

The principle, in fact, is always the same, whatever be the starting point of the pain; the latter radiates according to the direction of the nerves whose roots are affected, irritated, compressed; and it conforms generally to the law of *peripheral sensation*. On pressure, we observe some varieties; sometimes the pain is circumscribed within a more or less limited region; sometimes, on the contrary, the course of the nerve appears affected throughout its whole extent.

A. *Intra-rachidian tumours*.—The *pseudo-neuralgic pain* here precedes, as the rule is, the development of the myelitic symptoms properly so-called. The nerves adjacent to the tumour are the first compressed; or, rather, the cord may be compressed for a certain time before being irritated, and before manifesting its suffering by symptoms proper to itself, whilst, as to the nerves, they seem to respond almost immediately to the irritating cause. In such a case, the pain often occupies but a very limited region; it is a point or a line which is painful, not a surface. The domain which the pain affects is, other things being equal, limited in proportion as the tumour is small.

The pain, it is well understood, is on the right side, if the tumour be on the right, and on the left, if the tumour be on the left; it is bilateral (not the most common case perhaps), when the morbid growth presses equally on the nerve roots of both sides of the cord.

In support of these assertions, gentlemen, I think it well to quote briefly some examples.

1°. In the case of a patient, observed in this hospital, named Gill—, we had to deal with a sarcoma of the perimeningitic layer which penetrated into an intervertebral notch of the left side, and extended to the corresponding pleura; there had existed, in this patient, a fixed painful point on the left of the thorax, several months before the formications of the inferior extremities, which inaugurated the paraplegia, had shown themselves.

2°. I borrow the following example from Mr. Ceyley, an

English author.¹ The tumour, a psammoma, was situated at the eleventh dorsal vertebra, and compressed the cord. The patient had constantly complained of a fixed painful point, towards the left iliac fossa, during the six months which preceded the first appearance of formications in the lower extremities. The peculiar seat of the painful point in this patient is explained by the fact that the last intercostal nerve, which the tumour pressed upon, gives off terminal branches to the vicinity of the iliac crest.

3°. In a case reported by Dr. Bartels,² an intra-rachidian hydatid tumour compressed the left half of the lower part of the cervical enlargement. During three months, the only symptoms observed were pains radiating into the arm, hand, and shoulder, of the left side, and accompanied by a feeling of constriction at the lower part of the neck. Not till the end of this period did formication supervene in the left foot, and soon after came the other symptoms of spinal compression.

You will understand that such or such other nerve, the sciatic for instance, may be affected in the same manner; that depends on the place occupied by the tumour. The seat of the radiated pain matters little, however. What is important is the fact that the symptom in question, when well and duly identified amongst the prodromes, will be sufficient to differentiate paraplegia, arising from slow compression, from a primary spinal affection.

B. *Pseudo-neuralgias in Pott's disease.*—We will only touch lightly on the description of pseudo-neuralgias in Pott's disease, not that they do not deserve our attention, but that in order to treat such a question thoroughly we should enter into numerous details which it would be indispensable to notice. There, in fact, lies a large portion of the history of *latent vertebral caries*, and you are not ignorant of what difficulties we meet with in diagnosis, during the first period of the disease.

The organic condition has not been completely elucidated here. Probably it is variable; sometimes the nerve lesion is at the dura mater; sometimes it is within the intervertebral notch. The latter case is the rarer, if it be exact, as several authors maintain, that these notches, in Pott's disease, never give way so much as to allow of the compression of the nerves which pass through them.

¹ Ceyley, 'Pathological Society,' t. xvii, p. 25, 1868.

² Bartels, "Ein Fall von Echinococcus innerhalb des Sackes der Dura Mater spinalis" ('Deutsches Archiv für klinische Medicin,' vol. v, p. 180, 1869).

Let it suffice for me to say, gentlemen, that according to the seat of the vertebral disease, the *girdle pain*, or the appearance of a *brachial* or a *sciatic neuralgia* frequently precedes, by a long interval, the first manifestation of the spinal symptoms, properly so called.

The disorders resulting from the pseudo-neuralgias, in patients affected by vertebral caries, may extend to the production of cutaneous eruptions, such as *zona*, as was observed in a case reported by Dr. Wagner,¹ and in another described by M. Michaud.² Muscular atrophy also may be produced; and if so, it may show itself, according to Dr. Benedikt,³ without paralysis, properly so-called; electric contractility may be preserved, whilst electric sensibility has increased, a peculiarity which seems to prove that muscular atrophy is here really the result of an irritative action.

c. But, it is chiefly on the study of *pseudo-neuralgias* connected with *cancerous vertebral disease* that I should desire to concentrate your entire attention. Many motives lead to this decision. In the first place, we have here an order of facts which is yet but little known, or at least but badly known, and badly interpreted, notwithstanding the numerous works which have been published on the subject. In the second place, the knowledge of these facts is, as I hope to demonstrate to you, of very great importance, in practice. Finally, need we say it is a question of much local interest. It was, in fact, in this hospital that the first serious studies were undertaken in France, upon the subject; the first foundations were laid by my master and friend, M. Cazalis. It was he, I repeat (and with all the more willingness, because it seems to have been forgotten in a recent article), who demonstrated the anatomical and physiological reason of this particular species of pseudo-neuralgia, by establishing the fact that it results from the pressure which the nerve-trunks undergo in the intervertebral notches; and that it does not depend, as many persons still seem to think, on compression exercised on the spinal cord. The works of M. L. Tripier,⁴ those of M. Lépine,⁵ have completed, by the addition of some

¹ E. Wagner, 'Archiv der Heilkunde,' 4 heft, 1870, p. 331.

² Loc. cit.

³ 'Electrotherapie,' t. ii, p. 316.

⁴ Tripier (L.), 'Du cancer de la colonne vertébrale,' &c., 1867.

⁵ Lépine (R.), 'Bulletin de la Société Anat.,' 1867.

important features, my first observations which date from 1865.¹ But, we have been preceded abroad, by Mr. Hawkins,² and by Dr. Leyden,³ with whose remarkable works I was not acquainted when my memoir was published. I shall merely mention that these authors do not speak, in any way, either of the mechanism of the lesion, or of the mode of production of the symptoms which it determines.

Here, more than elsewhere, the distinction between the pseudo-neuralgic phenomena and the symptoms of slow spinal compression is of the highest value. Besides, there are grounds for distinguishing a *peculiar species* amongst pseudo-neuralgias, which, in cases where it exists, give a special physiognomy to the disease. With regard to this form, and to this form only, it is just to say with Hawkins, Gull, and Leyden, that the pains in vertebral cancer are almost characteristic. They are so then, in reality, up to a certain point, for they are scarcely found with the same character except in cases of *extra-rachidian tumours* tending towards the cord, as in the case of an aneurism, for instance, or of a hydatid tumour which saps away the vertebral body and gets into contact with the rachidian nerves. In these different cases, the organic cause is always the same; it is the compression, the acute irritation which the nerve-trunks undergo, and, in the case of vertebral cancer particularly, the nerve lesions produced by the giving way of the softened vertebræ.

Apart from this circumstance, vertebral cancer has no other pains peculiar to itself; or, in other words, the cancer may penetrate to the cord without producing other pains than those which are developed as a consequence of all other organic lesions, whatever they may be, which are capable of determining spinal compression.

To sum up, there are: 1°, latent vertebral cancers; 2°, vertebral cancers which induce compression of the cord almost without predominating pains; 3°, lastly, vertebral cancer, when it occasions the softening and giving way of the vertebræ, is the source of pains

¹ Charcot, 'Sur la paraplégie douloureuse et sur la thrombose artérielle qui surviennent dans certains cas de cancer' (Société des Hôpitaux, Mars, 1865).

² C. Hawkins, "Cases of Malignant Disease of the Spinal Column," 'Med.-Chir. Transactions,' t. xxiv, p. 45, 1845.

³ E. Leyden, "Ueber Wirbelkrebs," in 'Annalen der Charité Krankenhaus,' 1^e Band, 3 heft, p. 54; consult also Black, 'Centralblatt,' 1864, p. 493; Th. Simon, "Paraplegia dolorosa. Aus der Allgemeine Krankenhaus zu Hamburg," in 'Berlin. Klin. Wochens.,' Nos. 35 and 36, 1870.

which are almost specific. This giving way of the vertebræ may exist alone or be accompanied by the ordinary symptoms of compression of the cord; but, I do not hesitate to say, as regards the case in point, that the fact of compression of the nerves is much more interesting, in clinical practice, than that of spinal compression.

The assertions which I have just made to you are founded on repeated observations, some of which have been published in the thesis of M. L. Tripier: in these, the organic lesion in question existed with the whole group of characteristic symptoms, without the cord being at all involved. Leyden and Hawkins mention facts of the same kind; and, since the appearance of M. Tripier's thesis, I have several times verified the accuracy of my pathogenic interpretation. The compressed nerves in such cases are red and swollen, but yet without any very serious histological change;¹ in truth our means of investigation as regards this point are still comparatively very coarse. The nerves do not become atrophied and undergo granular fatty degeneration until very late in the disease. Never, so far as my experience goes, did I, under such circumstances, see the cancerous infiltration of the nerve, which several authors have, I believe, rather lightly invoked.

VIII.

It now becomes my duty to describe the symptoms, to which I have desired to call your attention, in a special manner. I have proposed to group these symptoms under the designation of *painful paraplegia of cancerous patients*.² This denomination of painful paraplegia I have borrowed from M. Cruveilhier, who clearly recognised this genus of symptoms, without, however, divining their interpretation.³ The name applies with exactness only in cases where the lumbar vertebral region is affected to a certain extent. This, indeed, is what most commonly happens.

But, as a matter of fact, several other combinations are possible. In the first place, the vertebræ having given way, on one side espe-

¹ Charcot et Cotard, "Sur un cas de zona du cou avec altération des nerfs du plexus cervical et des ganglions correspondants des racines spinales postérieures," 'Société de Biologie,' xvii, 1866, p. 41.

² Charcot, "Sur la paraplégie douloureuse qui surviennent dans certains cas de cancer," 'Bulletin de la Société Médicale des Hôpitaux,' loc. cit.

³ Cruveilhier, 'Atlas,' 32^e livr., p. 6.

cially, there can, in consequence, be only a painful hemi-paraplegia; or else, again, the concomitant pains and phenomena may occupy the brachial plexus or the cervical plexus, when the lesion bears upon the cervical vertebral region. At other times, finally, the pains show themselves exclusively limited to the distribution of this or that nerve-trunk. It is also important to remark that, whatever be the place in which it shows itself, how circumscribed soever it may be, the pain in cases of this kind presents itself absolutely with the same characters as in painful paraplegia properly so called.

Let us suppose that the lumbar vertebræ are affected, this being, as you know, the most common occurrence, and that these have been invaded throughout by the cancer, on the right side as on the left,—conditions which, in fact, you will find reproduced in one of the patients whom I shall introduce to you in a moment;—now, in such a case, the following symptoms are to be noted :

Acute *pains* exist; some constricting the lower part of the abdomen like a girdle, others spread along the course of the crural and sciatic nerves, from their spinal origin to their peripheral extremities.

There is *hyperæsthesia* of the integuments, in points corresponding to the distribution of the painful nerves. This hyperæsthesia, generally, is so great that the least touch is extremely painful.

The pains in question are permanent, or nearly so, but they become exasperated in paroxysms, which are most severe at night, and sometimes assume a periodic character. Movements in bed, whether they be active or passive, provoke the manifestation of these pains or exasperate them. The same holds good, *a fortiori*, as regards standing and walking, which soon become wholly impossible. Hence there results a kind of impotency, which does not arise from a decrease of muscular strength, for, in bed, when the pains do not happen to be too acute, the movements of the lower extremities are performed, if the patient be not very much weakened, as in the normal state.

During the paroxysms, the pains are truly frightful. The patients compare them to those which would be caused by the crushing of the bones, the biting of the deep-seated parts by some huge animal, etc. It is a fact worth noticing that we do not succeed in calming them, except with great difficulty, by the use of high doses of narcotic substances. It should also be remarked that, without appreciable

cause, spontaneous improvements take place, as regards these pains, the physiological reason of which completely escapes us.

To these phenomena may be added, especially in the more advanced stages of the disease, a certain number of disorders, amongst which I would specially mention the eruptions of *zona*,¹ which are produced along the course of particularly painful nerves, —a *cutaneous anæsthesia*, circumscribed in patches and developing in spite of the persistence of pains in the domain of the affected nerves (*anæsthesia dolorosa*),—a more or less manifest *atrophy* of the muscular masses, and finally, *contracture* supervening in a certain number of muscles.

Lastly, I would point out to you that a deformity which causes the spine to describe a curve, having a long radius, and that a local vertebral pain which pressure or percussion provokes or exasperates very distinctly, are concomitant symptoms which you must not neglect to seek for with care, because they may elucidate the situation and are, besides, frequently to be found.

These several symptoms, gentlemen, may be for many months the only revelation of the cancerous vertebral disease; but the symptoms of paralysis by compression of the cord may become superadded.

However this may be, when the phenomena of painful paraplegia appear with the characters just described, it will be right to examine whether there do not exist, in some part of the organism, some other manifestation of the cancerous diathesis; for, as you are aware, vertebral cancer is usually secondary, deuteropathic. Now, in this investigation, we may find ourselves confronted by more than one difficulty of a kind calculated to set the diagnosis astray. I will confine myself, at present, to calling your attention to the following circumstance, which I have recently witnessed. It may happen that the patients have, in the breasts, certain atrophic indolent cancers, to which they do not pay the least attention. I was consulted, a few days ago, by a lady who had been suffering for several months with a cervico-brachial neuralgia; in reality, as you will see, it was a pseudo-neuralgia; it was extraordinarily painful, and had absolutely resisted all the therapeutic agencies which had been tried. Struck by the special character which the pain presented, and remembering the facts observed in La Salpêtrière, I inquired if any mammary lesion existed. I was answered in the negative, but I thought it right to pursue the matter, and examine how things

¹ Charcot et Cotard, loc. cit.

stood for myself. To the great astonishment of the patient, I discovered that one of the breasts was deformed at a spot, very circumscribed indeed, owing to a retraction of the parts consecutive on the puckering occasioned by an atrophic schirrus. Quite recently, an English physician, whose name has escaped my memory, published a similar case in a volume of the 'Proceedings of the Pathological Society of London.' These facts will suffice, I hope, gentlemen, to show you clearly how attentive and circumspect, under such circumstances, it is necessary to be in the examination of patients.

On the other hand, you must not go so far as to believe that the pains of cancerous vertebral disease, even when they appear with all the attributes just defined, are absolutely specific and adapted to guide us to a diagnosis without trouble. Far from it: difficulties may supervene, but, generally, they are not insurmountable. Amongst the affections which may mislead, on account of the pains that accompany them, I have already mentioned the *aortic aneurisms* and the *hydatid kysts*, when these tumours are so disposed as to compress and irritate the spinal nerves. I will now refer to the existence of osteomalacia, cervical hypertrophic pachymeningitis, and lastly, a neurosis, *spinal irritation*.

Senile osteomalacia, as well as that of the adult, occasionally recalls, by the character of the accompanying pains, the symptomatology of the vertebral disease of cancerous patients. *Hypertrophic cervical meningitis*, in the first period, is also often accompanied by somewhat analogous pains; the same may be said of that strange and curious affection, which is sometimes called *spinal irritation*, and which some physicians have very wrongly sought to banish from our nosological lists,—but at present I desire to confine myself to calling your attention to these diagnostic difficulties. I propose at another opportunity to return to the subject.

LECTURE VII.

ON SLOW COMPRESSION OF THE SPINAL CORD. SYMPTOMS. DISORDERS OF MOTILITY AND OF SENSIBILITY CONNECTED WITH SPINAL COMPRESSION. SPINAL HEMIPLEGIA AND HEMIPARAPLEGIA, WITH CROSSED ANÆSTHESIA.

SUMMARY.—*Lesions of the cord at the point of compression. They occupy the whole extent of the cord, in a transverse direction, or only affect one of its lateral halves.*

First case: Succession of symptoms. Predominance of motor disorders at the outset; paresis, paralysis with flaccidity, temporary rigidity, permanent contracture of limbs, augmentation of reflex excitability. Disorders of micturition; Budge's theory. Modification of sensibility; delay in the transmission of sensations; dysæsthesia. Associated sensations.

Second case: Lesions bearing on one of the lateral halves of the spinal cord. Lesion circumscribed. Spinal hemiparaplegia with crossed anæsthesia; its characters. Spinal hemiplegia.

GENTLEMEN,—Before pursuing our studies on slow compression of the spinal cord, allow me to offer for your inspection the anatomical preparations relating to this subject, which we owe to the kindness of Dr. Liouville.

In paraplegia from Pott's disease, as I told you, the deformation of the spine is not, as a general rule, the agent of the compression which the cord undergoes; the spinal cord may even, in such a case, be compressed without the vertebral column presenting the slightest trace of deformity. This preparation of Dr. Liouville furnishes plenary evidence of the fact. The spine, as you perceive, was not at all deformed here, although the bodies of several vertebræ were deeply altered. The anterior vertebral ligament, on a level with the osseous lesion, was as if dilacerated, and the caseous matter, according to the mechanism indicated by M. Michaud, had come

into contact with the dura mater, which, in consequence, presented on corresponding points a remarkable thickening (*external caseous pachymeningitis*). It was evidently this thickening of the dura mater which had determined the spinal compression. The latter was clinically represented by symptoms of paralysis which, as is usual, were preceded, many months before, by pseudo-neuralgic pains simulating intercostal neuralgia.¹

I resume now the course of our conferences.

The question is, you are aware, to indicate the symptoms which directly arise from slow compression of the spinal cord. We are about, I must not conceal it from you, to enter upon a path long to travel and bristling with difficulties of every kind; but I hope that, by planning out proper stages, we may arrive at our goal without overmuch fatigue.

I.

Let us recall to memory the anatomical conditions in reference to which I had to enter into some details. The cord, you have not forgotten, is compressed, strangled as it were, in one part of its course. Now, if this, in the early period, is but a purely mechanical phenomenon, soon, in the immense majority of cases, the elements which compose the spinal nerve-centre react, after their manner. On a level with the compressed part, the lesions of *transverse myelitis from compression* are produced; whilst, above and below this point, develop, according to the laws we have stated, the alterations of *secondary fasciculated sclerosis*, which occupies, in the first case, the median portion of the posterior column, and, in the second case, the hindermost part of the lateral column.

¹ These anatomical preparations were obtained in Professor Béhier's wards. The patient was about fifty at the time of death. Before being seized with paraplegia he had, for several months, experienced localised pains in the course of the thoracic intercostal nerves, which for a moment had induced the belief that he suffered from simple intercostal neuralgia. Later on, on account of the persistence and character of the pains, the opinion was expressed that the neuralgia was symptomatic, though it was found impossible as yet to decide as to the nature of the primary disease. Then supervened the paraplegia, which definitely elucidated the diagnosis. The spine preserved its regular form until the fatal end. Again, in Professor Béhier's wards, M. Liouville has recently observed another case of Pott's disease, likewise without deformation of the vertebral column.

II.

Let us consider then the state of things as observed under ordinary conditions ; as we proceed, we will note exceptional circumstances, and, for greater clearness, let us take as our example the commonest case, that in which the lesion occupies any point in the dorsal region of the spinal cord.

It is time now to make a first distinction. Sometimes the compression affects the whole substance of the cord transversely ; sometimes, on the contrary, it bears upon only one of the lateral halves of the nerve column. It is the first case which, by the way, is far the more frequent, which shall now engage our attention.

III.

Let us thoroughly realise the situation which we are about to examine. For several weeks, or yet longer occasionally, the symptoms termed *extrinsic*, and amongst them the pseudo-neuralgic pains, alone occupy the scene. In the hypothesis which we have adopted, it is understood that we have only to deal with organic lesions primarily situated externally to the cord,—this nerve-centre, then, has not yet exhibited any suffering. What are the symptoms which are about to inaugurate the series of new phenomena ? Shall they be disorders of motion or derangements of sensation ? The order of succession, gentlemen, is difficult to determine, in the actual state of things, for lack of observations collected with the special intention of elucidating this particular fact. That, however, is a matter of detail somewhat secondary in importance as regards practical purposes, but which, nevertheless, is not without some interest when theoretically considered.

In point of fact, formications, pricklings, sensations of heat and cold in the lower extremities, if they constituted the first symptoms, would necessarily indicate, according to the theory, that the conductors of feeling, that is to say the grey substance, had undergone an important morbid change from the outset ; for, it has been shown, by experiments, that, under normal conditions, the grey substance does not provoke any kind of sensation when excited by stimuli. On the other hand, purely motor disorders, paresis or more or less complete paralysis of the lower extremities, are phenomena which may be produced apart from all change in the properties

of the elements of the cord, by the simple fact of a mere mechanical interruption of the continuity of the nerve-fibres.

However this may be, gentlemen, the reality appears to be that sometimes the motor disorders (paresis of the lower limbs), sometimes the sensory disorders, and particularly the sensations referred to the periphery, and indicating irritation of the grey substance (prickling, formication, feeling of constriction, articular pains), take the lead in the procession of symptoms.

IV.

Disorders of motion, in any case, do not delay to predominate, in the first stages at least, over the sensory derangements. Leaving aside the few subjective phenomena just mentioned, the transmission of sensory impressions is long carried on in a physiological manner, when the power of motion is profoundly modified, and it is even rare for such transmission to be ever completely interrupted, or indeed very gravely involved.

It would seem that the grey matter, situated in the centre of the cord, is protected against the influence of causes of irritation coming from the periphery. This is a peculiarity which has long been recognised by clinical observation, and which marks a contrast with what takes place in cases of spontaneous myelitis, or of intraspinal tumours, cases in which these lesions usually occupy the central portion of the cord from the commencement.

Let us delay a moment over the *disorders of motility*.

A. In the first degree, simple *paresis* is observed, but this is soon transformed into more or less absolute *paralysis, with flaccidity* of the limbs, or, in other terms, without muscular rigidity.

This phenomenon in connection with the interruption of the white columns, and of the lateral columns especially, is in conformity, you perceive, with the results of experimental pathology.

B. At the end of some days or of some weeks, later in certain cases, sooner in others, there supervene, in the paralysed members, jerks, cramps, a *temporary rigidity* of the muscular mass,—so many symptoms attaching also to lesion of the lateral columns, but which already indicate that a source of excitation has taken up its abode in the fascicles. These are, in short, the first symptoms which can be referred to descending myelitis of the lateral columns.

c. Lastly, supervenes *permanent contracture of the limbs*, which almost never fails to exist at a certain period of the disease, and

which appears to be, also, connected with the sclerous lesion, which the lateral columns present in the inferior section of the cord. It is the rule that this contracture shall first, for some time, maintain the paralysed limbs in a posture of forced extension, but sooner or later, generally speaking, a posture of forced flexion supervenes.

D. In this phase of the disease, under the combined influence of the suppression of the moderator influence of the brain, and probably, also, because of the irritation of which the grey substance, in its turn, becomes the seat, the reflex properties of the inferior segment of the cord are augmented. Then, we see the paralysed members rise and become convulsed at the least touch, or when the patient micturates or goes to stool.

I will not dwell upon those disorders of motility which to-day are the common knowledge of all. I will confine myself to making you observe that the intensity of permanent contracture of the extremities, and especially of contracture with flexion, is generally more marked in myelitis from slow compression than it is in spontaneous myelitis.

The same rule holds good with respect to the augmentation of the reflex properties of the cord. Still, it will not do to make of this difference, the cause of which completely escapes us, an absolute diagnostic character.

E. It is the rule, also, in myelitis from compression, at all events when the dorsal region is involved,¹ that the bladder shall preserve to a great extent its functional integrity during a comparatively lengthy lapse of time; but more or less marked vesical derangement may finally supervene. With respect to this subject, a distinction must be drawn.

If the compression is seated high up, towards the middle of the dorsal region for instance, we generally remark a difficulty in the emission of urine. This difficulty seems due to this, that the muscles which serve as sphincters remain in a state of permanent spasm. The will does not readily overcome this permanent contraction, and the involuntary emission of urine which sometimes occurs, in such cases, happens by overflow as it is called.

On the contrary, if the lesion is situated low down, towards the upper portion of the lumbar region, it may happen that the

¹ Holmes, 'A System of Surgery,' t. iii, p. 858, "Inclusion of the Spinal Cord in Caries of the Spine."

sphincters shall be paralysed, in a continuous manner, and then the urine flows involuntarily.

It is possible, in some measure, to account for this difference, which seems singular at first glance, if we refer to the theory, founded on experimental research, which Dr. Budge has recently published with respect to the mode of action of the central nervous system on the functions of the bladder.¹

In reality, according to Dr. Budge, there exists no other sphincter of the bladder than the urethral muscles (the constrictor urethræ and bulbo-cavernosus). The nerves which cause the bladder to contract proceed from the crura cerebri. Passing by the restiform bodies, they may be experimentally followed in the anterior columns of the cord as far as the exit of the 3rd—5th sacral pairs. The nerves which cause the muscles of the urethra to contract, follow, still according to Herr Budge, nearly the same course, and they offer this peculiarity, that they are modified in the normal state by a reflex influence which is communicated to them by the centripetal nerves coming from the bladder. Consequently, a reflex act is produced, the effect of which is to determine the permanent contraction of the urethral muscles, but which may be modified or even annulled by a sort of inhibition which the will commands.

According to this view, every lesion which should have the effect of interrupting in the cord (down to the exit of the 3rd, 4th, and 5th sacral pairs) the course of the nerves that proceed either to the bladder, or to the urethra, should likewise have the result of allowing the reflex act which commands the constant closure of the sphincter to subsist; hence it is that lesions of the cervical and dorsal cord produce the permanent spasm of the vesical sphincter which is observed, in certain cases of spinal compression.

If, on the other hand, the lesion is seated lower down, the conditions of the reflex act in question no longer subsist; the sphincter is paralysed in a constant manner, and the urine then incessantly dribbles out, drop by drop, the action of the muscles of the bladder no longer encountering any obstacle.

I am not unaware, gentlemen, that Dr. Budge's theory is not yet classic,—far from it, the experimental facts on which it is based

¹ Budge, 'Zeitschr. f. rat. Heilk.,' xxi, p. 5 und 174; "Ueber die Reizbarkeit der Vorderen Rückenmarksstränge" ('Pflüger's Archiv für Physiologie,' Bd. ii, p. 511).

require to be themselves verified. Nevertheless, I thought it my duty to state it succinctly because, in my opinion, it explains better than any other theory, at present known, the facts revealed by clinical observation.

V.

As I told you, a little ago, sensation, in paralysis from compression, does not generally become gravely altered until very late ; unless, indeed, the lesion be one which primarily occupied the central portion of the cord. However this may be, here is a summary of some peculiarities relative to disturbances in the transmission of sensory impressions which show themselves by preference, but not however exclusively, in paralyzes from spinal compression ; they are not seen, as you must have anticipated after what has been said, except in cases in which compression reaches a high degree of intensity.

In the first place, I would mention *the delay in the transmission of sensations*, a curious phenomenon which, if I mistake not, was first noticed by M. Cruveilhier.¹ Thirty seconds may elapse, as I have once observed, between the moment when the impression is made and that when the patient perceives it.

I should also mention a kind of *hyperæsthesia* or rather of *dysæsthesia*, in consequence of which the least stimuli, such as a slight pinch, the application of a cold body, give origin to a very painful sensation, which is always the same whatever the nature of the stimulus may be. According to the statements of the patients, a feeling of vibration is principally experienced. These vibrations, according to their account, seem to ascend from the root of the limb at the same time as they descend towards its extremity. In most cases, these sensations persist during several minutes, sometimes a quarter of an hour and even more, after the cessation of the exciting cause which determined them. The patient, under such circumstances, always finds much difficulty in exactly designating the place in which the stimulus was applied.

Finally, it is not rare to find that the stimulation applied to one limb, after having produced the effects just mentioned, is followed in a little time by an analogous sensation which seems to manifest itself symmetrically in a part of the opposite limb corresponding to the

¹ Cruveilhier, 'Anat. Pathol.,' No. xxxviii, p. 9 ; M. Schiff, 'Lehrbuch der Physiol. des Menschen,' 1858-59, p. 249.

region which was primarily stimulated. This comes under the head and history of what has been denominated *associated sensations*.

It has been sought, as you know, to account in the following manner for the production of the phenomenon in question :

When transmission of the sensory impressions in the cord has been rendered difficult by the interruption of a certain number of (centripetal) nerve-tubes, these impressions are supposedly transmitted by means of the ganglionic cells, connected together by their prolongations extending to the uninjured tubes : these impressions having reached the centre of perception by this abnormal way would be subsequently referred, in accordance with the common rule, to the periphery of these latter nerve-fibres, and hence would supervene the error in localisation.

I believed it right, gentlemen, to remind you of these peculiarities because, I repeat, they are observed more commonly and in a higher degree in paraplegia by compression than in any other form of paralysis of the lower extremities. But, again, we must not look here for an absolute, distinguishing characteristic. Besides, this qualification must be remembered, these symptoms are rarely observed in paraplegia determined by slow compression of the spinal cord, except in cases where the spinal lesion is carried to its highest point.

VI.

Unless unexpected complications supervene, the nutrition of the paralysed parts remains normal. Thus, the muscles preserve, for many months, their electric properties. Prolonged inaction, however, finally brings about emaciation and diminution of the faradaic contractility of the paralysed muscles. With respect to the external tegument, the bladder and the kidneys, no appreciable nutritive change is presented, for a long time. But, the vitality of these organs appears to become rapidly modified under the influence of certain complications. Thus, for instance, in a case which I observed of paralysis consecutive on Pott's disease, the sudden opening of an abscess into the rachidian canal determined an abrupt irritation of the inferior segment of the cord, which was soon followed by the rapid formation of sacral eschars, and by an alteration in the electric contractility of the muscular masses which, by degrees, became atrophied in a remarkable manner. The urine, at the same

time became purulent. The changes which supervene, under such conditions, are generally speedily fatal. Such alterations, indeed, may, without the apparent intervention of a new cause or any complication whatever, manifest themselves more or less rapidly at a given moment, in the course of paraplegias from compression, and bring about a fatal termination.

VII.

Hitherto, gentlemen, we have only occupied ourselves with the organic lesions which intercept the course of the nerve-fibres in the cord, throughout its whole breadth, in one place. I wish now to call your attention to a case in which one of the lateral halves of this nerve-centre is alone injured by the compression.

It behoves us first to specify clearly the extent and the disposition of the alteration with which we are concerned.

We suppose the lateral half of the spinal cord affected throughout its whole breadth to the median line. Consequently, the lesion should have interrupted the course of the fibres of the posterior and antero-lateral columns of one side, and simultaneously also the corresponding parts of the grey substance to the median line. In these special conditions and in these only, the lesion whose effects we are studying is clinically represented by a most remarkable and thoroughly characteristic symptomatic group.

We may designate this group simply by the name of *spinal hemiplegia with crossed anæsthesia*, when the lesion in question occupies a part of the cervical region.

If, on the contrary, it is a portion of the dorsal region which is affected in this manner, it is not hemiplegia which is observed, but *spinal hemi-paraplegia with crossed anæsthesia*. You will soon understand, gentlemen, the reason of these denominations.

VIII.

Any hemilateral lesion of the cord which fails to fulfil the specified conditions just enumerated will not produce the symptomatic group to which I desire to call your attention, or will only produce it, at most, in an imperfect manner; on the contrary, once these conditions are fulfilled, the symptomatic picture is necessarily presented. Our knowledge of this subject is of quite recent date. It is one of the most precise, and most fruitful of the results furnished in later times by the intervention of experimental physiology

in the domain of spinal pathology, and I am happy to say that this important result is entirely due to the works of my friend Professor Brown-Séquard. Not, indeed, that spinal hemiplegia and hemi-paraplegia had passed unperceived until his time, but, before M. Brown-Séquard, it was thought that these formed, as it were, a fortuitous reunion of strange and contradictory phenomena, inexplicable from the standing point of the prevailing physiology. To-day, thanks to the labours of M. Brown-Séquard, we know, at least to a great extent, the reason of the phenomena which we can trace back, with accuracy, to the anatomical lesion which gave them birth.

For a long time, clinically speaking, the subject chiefly interested surgery, for a hemilateral section of the cord, capable of determining hemi-paraplegia with crossed anæsthesia, appears to be a frequent consequence of injuries done to the spinal centre by a cutting weapon. However, the physician is sometimes called to observe this symptomatic form and, particularly, in cases of spinal compression occasioned by a tumour.

Let us take the case of a meningeal tumour, compressing, towards the middle of the dorsal region, one lateral half of the spinal cord, and suppose, in order to realise the question more clearly, that the compression affects, for instance, the *left side* of the nerve-column, as happened in a case whose history I have related (figs. 6 and 7).¹ Here are the principal phenomena which would be noticeable under such circumstances :

The inferior extremity *on the left side* would be more or less

¹ Charcot, "Hémiparaplégie déterminée par une tumeur qui comprimait la moitié gauche de la moelle épinière," in 'Archives de Physiologie,' t. ii, p. 29, 1869, pl. viii. The tumour, bearing on the anterior face of the dorsal region of the cord, which it strongly compresses from before backwards and from left to right, is rather regularly oval in shape. Its long vertical axis measures about three centimètres and a half, and its transverse diameter one and a half (figs. 6 and 7*a*). It is situated five centimètres above an imaginary line, which would divide across the widest part of the lumbar enlargement. It is partially niched in a depression which it has hollowed out for itself at the expense of the cord (fig. 7, *b*). It is not situated exactly on the median line, but a little to the left of the anterior median furrow, which it has driven towards the right, so that it compresses the left half much more strongly than the right. In one point, the compression of the left half is pushed so far that the two layers of the pia mater appear adherent together; on the contrary, the right half of the cord still exhibits, in the most strongly compressed points, that is, in the vicinity of the median furrow, a thickness of more than two millimètres. See also a case published in the 'Lancet,' 1856, p. 406, by Mr. Ogle.

completely paralysed, as regards movement ; the same thing also would occur, with respect to the abdominal muscles of the same side. The integuments, on the points corresponding to the parts

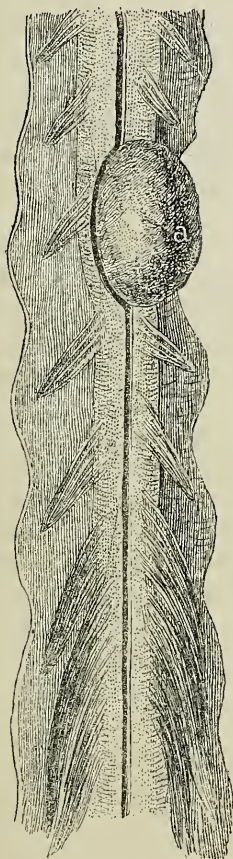


FIG. 7.

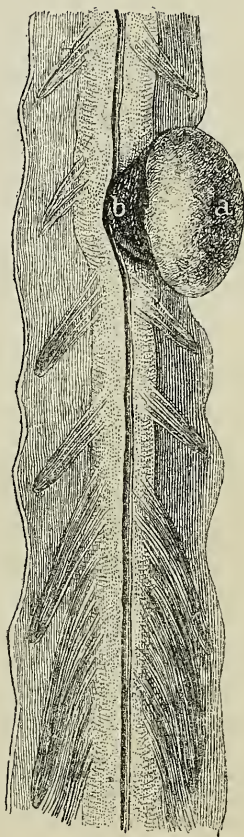


FIG. 8.

affected by motor paralysis present, when compared with homologous points on the opposite side, a more or less marked elevation of temperature, as a consequence of vaso-motor paralysis. Sensation, over the whole extent of these same points, would be found normal or even remarkably augmented on a level with the seat of the spinal compression and, on the same side, an attentive exploration would detect the existence of a *zone of anæsthesia*, disposed in

a transverse direction, and forming the upper boundary of the paralysed parts, the sensibility of which, as has been stated, would be exaggerated or normal.

On the right, that is to say, on the side opposed to the spinal lesion, the power of movement would be perfectly preserved in the lower extremity, and the muscles of the abdomen; but, on the other hand, sensibility would be obscured or even completely extinguished, in all its kinds. We should have a genuine hemi-anæsthesia, bounded above on a level with the spinal lesion by a well defined horizontal line, and bounded very exactly in front by the median line.

You readily comprehend, from what precedes, the reason of the name *spinal hemi-paraplegia with crossed anæsthesia*, proposed as a designation for the symptomatic group in question. If the hemilateral compression, instead of occupying the dorsal region of the cord, should occupy a point higher up, the superior portion of the brachial enlargement for instance, we would have the symptoms of *spinal hemiplegia properly so-called*, before our eyes. Here also we should notice a crossed hemi-anæsthesia, one occupying, that is to say, the side of the body opposite to that in which the spinal lesion is situated; but the insensibility would not remain confined to the lower extremity and one side of the abdomen, it would extend on the same side over the trunk, the upper extremity, and even the neck, so that the face, perhaps, might alone be spared.

On the side corresponding to the seat of the spinal lesion, the motor paralysis would occupy, at the same time, the upper and lower extremities, which would both present a relative increase of temperature. The trunk and the extremities of this side would have preserved their sensibility or become hyperæsthetic. The zone of anæsthesia which would form the upper limit of these parts would be situated very high, and would occupy, for instance, the upper portion of the thorax, and shoulder, and even of the neck.

The anæsthesia, exactly or, as it were, geometrically limited, by the median line, and extended, as we have described, over one entire side of the body, recalls, in some respects, the hemi-anæsthesia of hysterical patients, and that which is observed, as we have elsewhere mentioned, in the case of certain circumscribed (focal) lesions of the encephalon.¹ But, many circumstances may be noticed to

¹ Charcot, 'Lectures on Diseases of the Nervous System,' first series, Lecture X, New Sydenham Society.

serve to distinguish them, if need be. Thus, in hysteria, as in the case of an encephalic lesion, the face would almost necessarily participate in the hemi-anæsthesia, which would not happen in spinal hemiplegia. Besides, the concomitant motor disorders—paresis, paralysis with or without contracture—would show themselves in the latter case, on the side opposed to the anæsthesia, whilst they would occupy the same side as the latter in hysterical patients, and in those affected by organic lesions of the encephalon. I will not dwell longer on the subject of these distinguishing details which might be easily multiplied.

Nor will I stay to develop further the anatomic and physiological interpretation which has been given of the symptoms of spinal hemiplegia and paraplegia. I cannot do better, in this respect, than direct you to the different works of M. Brown-Séguard,¹ and I shall confine myself to the following remarks.

It is supposed that the conductors of sensory impressions, whatever they may be, after having followed in each lateral half of the spinal cord a course tending from without inwards, and from behind forwards, on a plane slightly inclining upwards, arrive and cross each other at the median line. There is also reason to believe that the fascicles, which after this crossing ascend towards the encephalon, do not greatly diverge from the median antero-posterior plane, and that they occupy the central part of the grey substance in the vicinity of the commissure. Now, here are the consequences which result from such an arrangement.

The hemilateral lesion of the spinal cord (whether it be caused by a wound given with a weapon, by a focus of myelitis, or by a tumour, matters little) will have the effect of destroying a number of yet uncrossed conductors which will be great in proportion to its vertical extent. In this way is that transverse zone of anæsthesia produced, more or less high-placed according to the case, which is observed on the same side as the lesion, and on a level with it.

Below the lesion, the conductors coming from the same side of the cord will follow their course to the median line, and there cross with those of the opposite side, without having undergone any interruption in their path. Hence it is that the parts situated below the transverse zone of anæsthesia will preserve their normal

¹ See Brown-Séguard, 'Physiology and Pathology of the Nervous System,' Philadelphia, 1860. 'Journal de la Physiologie,' &c., t. vi, 1863, p. 124. 'The Lancet,' 1869, vol. i.

sensibility. They very often even show themselves remarkably hyperæsthetic.

There has not yet been given, so far as I am aware, a perfectly satisfactory explanation of the latter phenomenon.

With respect to the conductors of sensory impressions, which come from the side of the cord opposed to that occupied by the lesion, they have all, after crossing, to traverse the focus of alteration provided that the latter really extend to the median line; and they consequently all undergo, in this part of their course, a more or less complete interruption. Thus it is that the crossed hemi-anæsthesia is produced.

As regards the motor paralysis which is observed below the hemilateral lesion of the cord, and on the same side with it, that is an easily foreseen consequence of the interruption undergone by the corresponding lateral fascicle, the fibres of which do not decussate anywhere in the cord with the homologous fibres of the opposite side.

I took care, just now, to point out to you that the fascicles—supposing that it be really the fascicles—resulting from the decussation of the conductors of sensory impressions appear not to diverge markedly from the antero-posterior median plane, where they occupy, on either side, the central part of the grey substance.

It follows from this arrangement that a hemilateral lesion of the cord, even though somewhat severe, but which, not rigorously extending to the median line, spares the fascicles in question, would not have the effect of determining crossed hemi-anæsthesia. Such a lesion would produce, according to the case, spinal hemiplegia or hemi-paraplegia, but without crossed anæsthesia. You will meet in practice, with rather numerous examples of this kind.

I have desired to restrict myself, gentlemen, to indicating to you in a very summary manner the most salient features of the symptomatic group which betrays the existence of hemilateral lesions of the spinal cord. I cannot, however, excuse myself from adding to what precedes some complementary details. Rarely do the lesions in question remain always confined within their original boundaries. Soon or late they propagate themselves, either upwards or downwards, or in both directions at the same time, to a certain distance beyond the primary focus. It is almost the rule, for instance, that, below the hemilateral transverse lesion and on the same side with it, the lateral fascicle shall be, at a given

moment, affected throughout its whole height, according to the law of the development of descending fasciculated scleroses. In such a case, permanent contracture would not delay to become super-added to the paralysis determined in the members by the primary spinal lesion. At other times, the irritation seems also to propagate itself, likewise below the lesion and on the same side, so as to invade the anterior horn of grey matter. Then the extremities, already paralysed and contracted would, in addition, exhibit a more or less well-marked atrophy of the muscular mass. Finally, apparently in connection with the consecutive alteration of different points of the grey substance, not yet determined, we may see the symptoms of spinal hemiplegia become complicated by the formation of different other trophic disorders, such as arthropathies, sacral or gluteal eschars, &c.

Enough has been said, I hope, gentlemen, to make you recognise the interest which, from our point of view, belongs to the study of spinal hemiplegia. I cannot too often repeat that this symptomatic array is not produced only, as for a time was thought, in consequence of traumatic lesions of the spinal cord. I have myself observed it, under the well-defined form of hemi-paraplegia with crossed anæsthesia in five cases. In three of these cases, there was transverse sclerous myelitis; in a fourth, an intra-spinal neoplasia.¹ Lastly, in the fifth, already mentioned above, a tumour primarily developed in the internal surface of the dura mater had, at a given moment, by enlarging, in an antero-posterior direction, determined in one part of the dorsal region a compression which was almost exactly confined to one lateral half of the spinal cord.

¹ Charcot et Gombault, "Note sur un cas de lésions disséminées des centres nerveux observées chez une femme syphilitique," in 'Archives de Physiologie,' 1873, p. 173.

LECTURE VIII.

ON SLOW COMPRESSION OF THE SPINAL CORD. CERVICAL PARAPLEGIA, PECULIAR SYMPTOMS. PERMANENT SLOW PULSE.

SUMMARY.—*On cervical paraplegia. Compression of nerves of upper extremities. Lesions of spinal cord in the neck; their mode of action in the production of cervical paraplegia. Distinction between cervical paraplegia due to the compression of peripheral nerves, and that dependant on a lesion of the cord. Alteration of motor nerve-cells and tumours of the cord—causes of a third form of cervical paraplegia.*

On some peculiar symptoms of slow compression of the cervical cord. Oculo-pupillary disorders. Cough and dyspnœa. Frequently recurring vomiting. Difficulty of deglutition. Hiccough. Functional derangement of bladder. Epileptic attacks.

On permanent slow pulse. Temporary slowing of pulse in fractures of vertebræ of neck. Permanent slow pulse connected with certain organic affections of heart (aortic insufficiency, fatty degeneration of cardiac tissue, fibrinous deposits). Insufficiency of cardiac lesions, in some cases, to explain slow pulse. Phenomena connected with permanent slow pulse. Syncope, apoplectiform state, convulsive fits. In certain cases, the starting point of permanent slow pulse to be sought in cervical cord or bulbous rachidicus. Dr. Halberton's case.

Sudden death from rupture of transverse ligament of the odontoid process.

Symptoms accompanying lesions of the lumbar enlargement and cauda equina.

GENTLEMEN,—I shall conclude this series of studies relating to

slow spinal compression, by calling your attention to certain peculiarities which are sometimes observed in cases where the lesion which determines the phenomena of compression affects the cervico-brachial region of the spinal cord.

I.

We will consider, in the first place, a singular form of paralysis which may be met with, under such circumstances, and which we, following the example of Dr. Gull, propose to designate by the very practical name of *cervical paraplegia*.¹ The paralysis here occupies either but one of the upper extremities, or both of them together, exclusively or at least in a predominating manner. The abdominal extremities are also often subsequently affected, but generally in a comparatively minor degree. It is not very uncommon to meet this form of paralysis in Pott's disease of the cervical region.

a. It may happen and, in fact, it somewhat frequently occurs that, in this variety of Pott's disease, the nerves of the upper extremities are compressed, sometimes at the intervertebral notches, sometimes in their passage through the dura mater, where it is thickened by a caseous pachymeningitis. This compression, when carried to a certain degree, will necessarily sooner or later result in the production of a paralysis affecting, according to the case, either both the upper extremities simultaneously or one of them singly. This paralysis is wholly peripheral, and will be represented, gentlemen, by the following train of symptoms nearly :

At the beginning, acute pain will occupy the course of the compressed and irritated nerve-trunks: a more or less marked hyperæsthesia of the integuments may be added, together with various vaso-motor disorders, different vesicular and bullar cutaneous eruptions, &c., in a word—the whole series of phenomena which we but lately learned to know in reference to the *pseudo-neuralgias* of the cord, and to which, consequently, it is needless for us to return. Loss of motor power will not fail to supervene without delay, and the muscles of the paralysed members will soon present a more or less well-marked atrophy, usually accompanied by a greater or less degree of decrease of faradaic contractility in the course of the disease. The hyperæsthesia will give place to anæsthesia which is often very intense. Lastly, it should be remarked that, in the

¹ "Cervical Paraplegia," 'Guy's Hospital Reports,' t. v, 1858, p. 207.

members deprived of motion, diminution or even total suppression of the reflex acts may supervene.¹

6. The compression undergone by the nerve-filaments which give origin to the brachial plexus, is far from being the only organic cause capable of producing cervical paraplegia; the latter may still show itself in consequence of lesions which act upon the spinal cord itself.

If it is true that very severe compression, carried so far, for instance, as to flatten the cord in a marked manner, has necessarily the effect, when bearing on the cervico-brachial region, of paralyzing the four extremities, it is, on the other hand, demonstrated by observation that a lesser pressure, affecting the same region, may under certain conditions result in occasioning a motor paralysis confined, for some time at least, to the two upper extremities or even to one of them.

In order to account anatomically and physiologically for this phenomenon, which clinical observation has set prominently forth, it has been proposed to admit that the conductors for the voluntary motor incitations of the thoracic members occupy, in the anterior columns of the cervical cord, a more superficial plane than that occupied by the conductors of the same incitations for the inferior extremities. It follows naturally from this that the two orders of conductors may be separately and singly injured.²

Whatever be the value of this interpretation, there can be no doubt, gentlemen, I repeat, as to the existence of the form of paralysis of the upper extremities to which I have to call your attention. Here, besides, is a summary statement of the peculiar features under which it presents itself, which allow it to be discriminated from the cervical paralyzes connected with peripheral compression of the nerves. In the latter, as you know, the loss of motor power is accompanied and preceded by acute pains (pseudo-

¹ "On Cervical Paraplegia from Compression of Nerve-trunks," see Brodie; "Injuries of the Spinal Cord," in 'Medico-Chirurgical Transactions,' 1837, t. 20, p. 131; Marshall Hall, in 'Medico-Chir. Trans.,' 1839, t. 22, p. 216; Niemeyer, 'Speciell. Pathol.,' t. ii, p. 358; Prof. Rosenthal, 'Canstatt's Jahresbericht,' 1866, 2 Bd. 1 abth., p. 45, and 'Nervenkrankh.,' Benedikt, 'Elektrotherapie,' t. ii, p. 316; J. A. Michaud, 'Sur la méningite et sur la myélite dans le mal vertébral,' Paris, 1871, p. 56.

² See Brown-Séguard, 'Journal de la Physiologie,' &c., t. vi, 1865, p. 139, 631, and 632. Eulenburgh, 'Functionellen Nervenkrankh.,' Berlin, 1871, p. 379.

neuralgias), followed sooner or later by anæsthesia, a more or less well-marked atrophy of the muscular mass supervenes with greater or lesser rapidity, together with diminution of faradaic reaction. The reflex acts in the paralysed members are diminished or suppressed.

Cervical paraplegia arising from antero-posterior spinal compression, on the contrary, presents itself with quite other characters. Here, the muscles for a length of time preserve their volume as well as their electrical properties. The sensibility of the paralysed members may not be markedly modified; lastly, not only do the reflex phenomena persist, in these members, but they even show themselves sometimes manifestly exalted. This circumstance which, of itself, would suffice to demonstrate that the lesion does not bear on the peripheral course of the nerves has already been pointed out, in a case recorded by Dr. Budd, which forms part of a very interesting memoir, the publication of which goes back to the year 1839.¹ The patient was a scrophulous young girl, affected with caries of the cervical vertebræ, in whom a retro-pharyngeal abscess was subsequently developed. For nearly two years the paralysis was confined to the upper extremities; it afterwards invaded her right lower extremity. Under the influence of different stimuli, as likewise during the acts of micturition and defecation, more or less energetic movements supervened in this limb, and also occasionally but always to a minor degree, in the upper extremity of the same side.

A case recorded by Dr. Radcliffe must be approximated, in certain respects, to that of Dr. Budd.²

c. There is also, gentlemen, another method by which an alteration of the cervico-brachial region of the spinal cord may determine a motor paralysis limited to the upper extremities. You are aware that, in certain cases of infantile spinal paralysis *cervical*

¹ "Pathology of the Spinal Cord," in 'Med.-Chir. Trans.,' 1839, t. 22, p. 141.

² A case noted in Oppolzer's 'Clinique' by Dr. Schott, and another case observed by HH. Vogel and Ditmar, are also examples of slow compression, bearing on the anterior part of the cervical region of the spinal cord, and having determined a motor paralysis limited to the upper extremities. These two cases have been referred to in an interesting work by Dr. Emil. Rollet, "Krankheits-Erscheinungen in Folge von Compression der obersten Dorsalstücks des Rückenmarks," in 'Wiener Med. Wochenschr.,' Nos. 24, 25, 26, and 'Canstatt's Jahresb.,' 1865, t. 3, p. 30.

paraplegia, is observed when the systematic lesion of the anterior cornua of grey matter remains confined, for a certain height, to the brachial enlargement. The paralysed members then present, from the outset, an extreme flaccidity, the result of loss of tone by the muscles; the reflex acts are more or less completely abolished, and the wasted muscles answer no longer to the faradaic stimulus. Sensibility, as a general rule, is changed in nothing.

An acute partial myelitis, having the same position, would produce nearly the same effects,¹ and the same may be said of a tumour which, primarily developed towards the centre of the cervical cord, should principally extend forward so as to affect chiefly the grey substance of the anterior cornua. Only in the latter case the aspect of the symptoms would be necessarily more or less profoundly modified, on account of the relatively slow evolution of the lesion and of its extension, inevitable as it were at a given moment, either to the white columns or to the posterior regions of the grey substance. However this may be, we might quote some instances where a cervical intra-spinal tumour determined a paralysis in the upper extremities which, in many respects, approximated to the infantile type. In reference to this matter, I shall confine myself to pointing out a case, recorded by Dr. Gull, where the patient was a child of eight months, in whom a solitary tubercle had developed at the inferior portion of the cervical enlargement, on a level with the origin of the sixth and seventh cervical nerves. The paralysis at first gradually invaded the right superior extremity; then, at the end of fifteen days, it had extended to the left upper extremity. Two months after the invasion of the first symptoms, the paralysed members which were greatly wasted, hung flaccid and powerless on either side. The abdominal members were weak, but the little patient could move them voluntarily. Death supervened six months after the appearance of the paralysis. Up to the last moment, voluntary movements persisted to a certain extent in the lower extremities.²

I will dwell no longer here upon this last variety of cervical paralysis of spinal origin; it shall, besides, form the subject of a detailed study.

¹ 'Ollivier d'Anger,' t. ii, p. 319, 3e édition.

² 'Guy's Hospital Reports,' 1858, p. 206, Case 32. See also Case 15 of the same work, 1856, p. 181, where the cause was probably a glioma.

II.

I propose now to offer some remarks relative to a certain number of symptoms which are occasionally manifested in consequence of lesions by compression either of the cervical region or of the upper portion of the dorsal region of the cord.

The symptoms in question deserve all the more to detain us because, on the one hand, they have hitherto, generally speaking at least, been little remarked; and because, on the other hand, they may for several weeks or longer exist in a state of isolation, that is to say, independent of all motor paralysis of the limbs, thus constituting as it were, during that time, the only clinical revelation of the spinal disease.

a. You are not unaware that more or less marked *oculo-pupillary disorders* are rather frequently the product of traumatic lesions, bearing on the cervical or superior dorsal cord. Sometimes we find dilatation (*myosis spastica*), sometimes, on the contrary, contraction of the pupil (*myosis paralytica*), under such circumstances; they occasionally affect but one eye, occasionally both are taken at the same time. In the same eye, the two orders of phenomena may occur in succession, and then spasmodic dilatation precedes paralytic contraction.¹ These facts, at the present day, form part of the common stock of knowledge.² But what is perhaps less known is the fact that mydriasis, resulting from permanent irritation of the cilio-spinal region determined by a traumatic cause, may subsist continuously, during several weeks, without the addition of paralysis of the extremities, as was demonstrated by a case recorded by Dr. Rosenthal, to which I will shortly return.

Similar modifications of the pupil may be shown in connexion with lesions by compression of the superior regions of the cord. Mr. Ogle has referred to their existence in several cases of cervical Pott's disease. In a case of the same kind, published by Dr. A. Eulenburg,³ the pupil remained very evidently dilated for four weeks, after which it gradually resumed its normal dimensions.

¹ Gerhardt, 'Centralblatt,' 1865, p. 10.

² Leudet, 'Mém. de la Société de Biologie,' 1863, p. 105. Rendu, "Des troubles fonctionnels du grand sympathique observés dans les plaies de la moelle cervicale." In 'Archives Gén. de Méd.,' Sept., 1869, pp. 286—297. A. Eulenburg und P. Guttman, 'Pathologie des Sympathicus,' Berlin, 1873, p. 9.

³ A. Eulenburg, 'Greifswalder Med. Beiträge,' 1864, iii, pp. 81, 88.

The osseous affection in this patient seemed to occupy the last cervical vertebra and the first three dorsal vertebræ. A case reported by Dr. E. Rollet, from Oppolzer's clinique,¹ is peculiarly interesting as regards the question at issue, because it shows dilatation of both pupils, accompanied by a certain degree of protrusion of the ocular globes, preceding by some time the development of motor paralysis in the lower extremities. The cause was the existence of tuberculosis, occupying the third and fourth dorsal vertebræ, which had determined by compression the softening of the anterior columns in the corresponding region of the spinal cord. It would, no doubt, be easy to multiply examples of the same nature.

b. I would, in the second place, notice in a very particular manner the *cough* and the *dyspnœa* which, in compression of the upper regions of the spinal cord, may exist, as isolated symptoms, long before the appearance of paraplegia. When combined with the neuralgic pains, which, in such a case, naturally occupy the superior part of the thorax, these symptoms have sometimes reproduced the semblance of incipient phthisis, so closely as to render mistakes easy; this is a circumstance to which the practical sense of Dr. Gull has not failed to give suitable prominence, and, with reference to this, he mentions a case which I think it useful you should know, at least in a summary manner.

The patient was a baker, aged thirty years, who at the time of admission to Guy's Hospital, had been suffering for about two months from cough and dyspnœa, accompanied by pains in the upper part of the back, as well as in the right shoulder, by frequent perspirations, by a certain degree of wasting, and, lastly, by prostration. Four days after his entrance he suddenly found himself unable to pass water voluntarily, and fifteen days later his knees became painful (p spinal arthropathies), whilst at the same time the thoracic pain increased; then the power of movement began to diminish in the lower extremities. Motor paralysis progressively supervened in these members, and soon showed itself complete and thorough. Sensibility was also naturally lessened in the paralysed members and in the whole of the lower portion of the trunk, to a level with the third rib. A vast bed sore having supervened in the sacral region the patient succumbed about four months after the invasion of the first disorders. The spinal cord was found softened, on examination, for about an inch in extent, throughout its whole breadth, at the

¹ Loc. cit., 'Caustatt's Jahresb.,' 1863, t. iii, p. 30.

first dorsal vertebra. A tumour as big as a filbert was attached to the inner surface of the dura mater; it had determined the compression of the cord, from before backwards, on a level with the softened point. The lower lobes of both lungs presented the lesions of recent pneumonia; no trace of any anterior lesion could be discovered in these organs.¹

Symptoms, analogous in every respect to those which have just been mentioned, are likewise found in another case, also recorded by Dr. Gull, in which the spinal affection was not the result of compression. It was constituted by an *induration* which occupied the cervical enlargement.²

c. Various gastric disorders, and particularly *oft-recurring vomiting*, should have a place among the phenomena which are sometimes connected with the first symptoms of cervical spinal compression. This symptom showed itself very remarkably in a case where the affection was due to an intra-spinal tumour (probably a glioma), which occupied the central part of the cord in the lower half of the cervical enlargement.³ It existed also in the little patient mentioned above,⁴ who suffered from solitary tubercle, developed in the same region. It is proper to put these digestive derangements on a parallel with the *gastric crises* of locomotor ataxia and general spinal paralysis;⁵ but it is especially important, from the standing point of pathological physiology, to point out that very tenacious, very persistent vomiting is, apart from all cerebral commotion, a rather frequent immediate symptom in connection with spinal lesions occasioned by fracture of the cervical vertebræ. This fact has been already noticed, though in a passing way, by Brodie; but it has been decidedly demonstrated by the interesting statistics of Dr. Gurlt, based upon the analysis of 300 cases of fracture of the cervical vertebræ occurring in different regions.⁶

¹ W. Gull, 'Guy's Hospital Reports,' 3rd series, t. ii, 1856, Case 1, p. 145.

² Same collection, Case 16, p. 185.

³ Gull, loc. cit., t. ii, p. 184, Case 15.

⁴ Gull, loc. cit., t. iv, p. 206, Case 32.

⁵ Charcot, 'Lectures on Diseases of the Nervous System,' 2nd series, ch. viii.

⁶ E. Gurlt, 'Handb. der Lehre von den Knochenbrüchen,' 2th 1 Lief, 1864, p. 62. In one of Brodie's cases the vomited fluid was of a blackish colour. The mucous membrane of the stomach was mottled with ecchymotic patches; and the cavity of the organ was filled with a fluid like coffee dregs, in one of the cases recorded by Gurlt (No. 35).

d. Difficulty of deglutition, of more or less intensity and persistence, and *hiccough*, may be approximated to the gastric derangements in question. They supervene in the same circumstances, and, in certain cases of compression of the cervical cord, sometimes make their appearance long before that of the paralysis of the extremities.¹ The same may be said with respect to the functional disorders of the *bladder and rectum*,² and the latter fact contrasts remarkably with what we have learned with respect to the behaviour of these organs, when the compression bears on the dorsal cord. This is a point which it was of interest to elucidate.

e. I shall merely mention the *epileptic attacks* which sometimes show themselves, in a periodic manner, in patients suffering under spinal lesions from compression. Contrary to what might have been supposed from the well-known effects of sections of half the spinal cord, in certain animals, epilepsy in man appears to be comparatively rather a rare result of spinal lesions. However, I have been able to collect, with care, ten cases of this kind, about half of which relate to lesions of the cervical cord determined by compression.

The most remarkable of these cases is undoubtedly that which was published in 1862, in the 'Gazette des Hôpitaux,' by M. Duménil, of Rouen.³ You will not confound these general convulsions of spinal origin with the symptomatic group described by M. Brown-Séguard under the name of *spinal epilepsy*, to which we have several times already called your attention in the course of these lectures.⁴ The convulsions, whether tonic or clonic, are

¹ Gull, loc. cit., Cases 15, 32.

² Gull, loc. cit., Cases 1, 15, 16.

³ A. Duménil, loc. cit., p. 478. See also the observations of Geddings, of Baltimore. (Brown-Séguard, 'Journal de la Physiologie,' t. vi, p. 633); of Webster ('Medico-Chirurgical Trans.,' 2nd series, t. viii), of Gendrin ('Ollivier d'Angers, t. ii, pp. 502 and 520), of Charcot and Bouchard (Bouchard, "Des dégénérationes secondaires de la moelle épinière"), extract from the 'Archives Générales de Médecine,' 1866, p. 32; in the latter case the compression bore rather upon the bulbus. As regards epilepsy in connection with lesions of the dorsal and lumbar regions of the spinal cord, see Leudet ('Archives de Méd.,' 1863, t. i, p. 266), 'Ollivier, d'Angers,' 3e édition (1837, t. ii, p. 319); Rilliet et Barthez (t. iii, p. 589, 1859); Michaud ('Sur la méningite et la myélite,' Paris, 1871, p. 50); Brown-Séguard ('Researches on Epilepsy,' p. 11); Westphal ('Archives de Psychiatrie,' t. i, p. 84, 1868); 'Ollivier, d'Angers,' (t. ii, p. 319).

⁴ Charcot, 'Lectures on Diseases of the Nervous System,' 1st series, pp. 201, 202.

limited, in the later cases, you know, to the parts situated below the lesion of the spinal cord.

f. One of the most interesting, but also, if I do not mistake, one of the least noticed facts of the symptomatology of cervical spinal lesions is, beyond contradiction, the *permanent retardation of the pulse*, which is sometimes found as a consequence of these lesions.

Surgical observation has long since recognised that fractures of the cervical vertebræ have rather frequently the effect of giving rise to a remarkable slowness in the pulsations of the heart. Such, in particular, is the result of fractures affecting the 5th and 6th cervical vertebræ. In such circumstances, Mr. Hutchinson has seen the pulse—which always, according to him, remains regular, contrary to what occurs in case of cerebral shock—give only forty-eight beats per minute.¹ According to Dr. Gurlt, whose important statistics I have already commended to your notice, the pulsations may even descend to thirty-six and to twenty. Fractures of the 1st dorsal appear to be of themselves capable of inducing slowness of the pulse.² It is understood that all interference from cerebral concussion is eliminated in these cases. As a rule, slowness of the pulse in connection with fractures of the cervical region is an essentially transitory phenomenon, and soon gives place to a very marked acceleration, which is almost always a bad omen.

It sometimes happens, however, that it persists as a permanent symptom for several weeks. In reference to this, I would revert to the case of Dr. Rosenthal, of Vienna, mentioned above. A child of fifteen years received a blow, which struck it in the region of the sixth cervical vertebra. Symptoms of a slight and quite transitory cerebral shock immediately showed themselves, accompanied by hemiplegia of the right side, which did not last more than twenty-four hours. Nevertheless, during the four weeks following the accident, besides the dilatation of the pupil, already mentioned, it was remarked that the number of heart-beats remained permanently lowered to a very notable extent. The pulsations oscillated between 56 and 48 per minute. The patient completely recovered.

¹ Hutchinson, "On Fractures of the Spine," 'London Hospital Reports,' 1866, t. iii, p. 366.

² Gurlt, loc. cit., p. 50, obs. 61, borrowed from Hughes ('Dublin Hosp. Reports,' t. ii, 1855, p. 145), and obs. 22 reported by Tyrrel ('London Med. and Phys. Journal,' t. 61, new series, vol. vi, 1829, p. 232).

Does not this undoubtedly most remarkable case render it already highly probable that the phenomenon of *permanent slow pulse* may, in certain circumstances, be observed, with all its consequences, after irritative lesions of the cervical cord, apart even from all traumatic influence? I say "with all its consequences," because in reality, as you will acknowledge in a moment, permanent slow pulse is far from being an indifferent phenomenon, if it but happen to be very distinctly marked.

Apart from traumatic lesions of the cervical cord or medulla oblongata, slow pulse, in the opinion of the few authors who have studied it, is only observed as a consequence of certain organic diseases of the heart—aortic insufficiency, fatty degeneration of the ventricular muscles,¹ or the presence of fibrinous deposits (? infarctus) in their tissues.² I am far from wishing to deny that the phenomenon of slow pulse may, in fact, have its starting point in an organic lesion of the heart. But I must declare that I have three times observed this persistent phenomenon, in a very marked form (20, 30 beats a minute), established permanently, for several years, in aged inmates of this refuge; and that, in these three cases, after an attentive anatomical verification, the heart was found either quite healthy, or merely presenting changes of a most common-place kind, especially at such a period of life.³ Hence, I have been induced to ask myself whether, at least in cases where cardiac lesions are absent, the organic cause of the slowness of arterial pulsations would not reside in the cervical cord or medulla oblongata rather than in the heart. It is true that the anatomical investigations which I undertook in reference to this subject have remained till now without any definite result. But it is important to observe that they date from a period when our means of exploration, in all that relates to the nerve-centres, were much less powerful than they have since become.

¹ W. Stokes, "Observations on some cases of permanently slow pulse" ('Dublin Quarterly Journal of Medical Science,' Aug. 1, 1846). 'Traité des maladies du cœur et de l'aorte,' trad. par le Dr. Sénac, pp. 138, 332, 308, 315, 337. R. Quain, 'Medico-Chir. Trans.,' t. xxxiii.

² Ogle, "Fibrinous masses deposited in the substance of the heart's walls; remarkable slowness of the pulse; epileptic seizures" ('Pathological Society,' 1863, p. 89.

³ The heart, on auscultation and percussion, did not exhibit any sign of alteration in a very interesting case of *permanent slow pulse* with fainting and epileptic fits, published by M. A. Rotureau, in 'l'Union Médicale' (1er Mars, 1870, No. 25, p. 331). See also Note B.

If I insist, gentlemen, on permanent slow pulse considered in its possible relations with spinal or bulbar lesions, it is not only because this phenomenon is one the interpretation of which is of the highest interest to pathological physiology, but also because, as I gave you to understand, just now, that serious phenomena are very usually superadded, which are capable of occasioning death, with rapidity. These phenomena are thus constituted. They supervene in paroxysms, recurring irregularly at more or less remote periods; sometimes they appear with all the characters of syncope; sometimes, as regards the symptoms, they partake of the nature of those of syncope and of the apoplectic state; there are finally cases in which epileptiform movements are superadded, which are especially noticeable in the face, with change of colour, foaming at the mouth, &c. The pulse, which, in the interval of the crises, beats on an average 30 or 40 times a minute, becomes still slower during the fit, and may descend to 20, or even to 15 pulsations. It may even stop for a moment, and sometimes altogether. The state of syncope always opens the scene; the apoplectic state with stertorous sleep then supervenes, at the moment when the pulse, which had been for an instant suppressed, reappears, and when the pallor of the features gives place to redness of the countenance. The epileptiform convulsions which occasionally appear, supervene under the self same conditions.

The array of symptoms remains invariable, gentlemen, as my three observations demonstrate, whether there be organic lesions of the heart, well and duly attested, or whether these lesions be non-existent. What then is the origin of the slowness of the pulse and of the superadded phenomena, in cases of the last kind? I am much inclined to believe, I repeat, that it should be sought for in the spinal cord or medulla oblongata. In the absence of personal observations adapted to decide the question, I can base my hypothesis not only on what has been just said on the effects produced by traumatic irritation of the superior regions of the cord, but also on the knowledge of a peculiar fact, which is extremely remarkable, though it has hitherto, I know not wherefore, remained in the shade.

The case belongs to Dr. Halberton, who published it in the 'Medico-Chirurgical Transactions,' of London, for 1844.¹ The patient was a gentleman, aged 64, who fell upon his head, whilst

¹ T. H. Halberton, "A case of slow pulse with fainting fits, which first came

out hunting, and lost consciousness at once. He was obliged to keep his bed several weeks, complaining of acute pain in the neck, and much difficulty in moving his head. This difficulty persisted for a long time; however, during the two years subsequent to the accident, he could follow most of his favourite occupations, with more or less ease. Not until the end of these two years, did the first syncopal crisis, a fainting fit, supervene; and it was then noticed for the first time that the pulse had become permanently slow. During the subsequent two or three years, the paroxysms were repeated, and at shorter and shorter intervals, whilst the fits became longer. Generally, in these crises the syncopal state soon gave place to the apoplectiform and epileptiform phenomena which I have mentioned. The pulse which under ordinary conditions gave an average of 33, fell to 20, and even to 15 at the approach of the attack, and it ceased for a moment to beat when this had set in.

Death supervened in one of these crises, and the following signs were observed at the autopsy, which was made by Lister. The upper portion of the spinal canal, and the occipital foramen were considerably narrowed in the antero-posterior direction, so that the little finger could scarcely be passed into the latter orifice. The dura mater and the ligament which covers the posterior part of the body of the axis, were very much thickened. The atlas preserved its normal position, but the articulations which unite it to the occipital bone had undergone osseous ankylosis, so that no motion was possible. The medulla oblongata was very small and very firm. The heart was large, the ventricle walls rather thin, but apart from a certain degree of thickness of the endocardium in several cavities, it presented no alteration worthy of notice.

The author does not hesitate to attach all the symptoms noted in his interesting observation—permanent slow pulse, fainting fits followed by apoplectiform and epileptiform symptoms—to the effects of the compression undergone by the cervical cord and medulla oblongata, owing to the diminution of calibre presented by the vertebral canal and occipital foramen. I endorse his opinion without reserve.¹

on two years after an injury of the neck, from a fall" ('Med.-Chir. Trans.,' t. 24, London, 1841).

¹ *Permanent slow pulse* with fainting, apoplectiform and epileptiform fits are sometimes seen as sequelæ of diphtheria. There is reason to believe, from

This is the place to remind you of the terrible accident which somewhat frequently happens in Pott's disease of the cervical region; I refer to the rupture of the transverse ligament which maintains the odontoid process on the axis, and the dislocation of the process which is the consequence. The history of the effects of the abrupt compression of the cervical cord and medulla oblongata which then supervenes is not adapted for long descriptive details; it is sudden death,—death *sans phrase*,—if I may use the word,—which results. This accident, I repeat, is far from rare. Mr. Ogle has, himself alone, collected four cases of this kind in the course of his hospital work.¹

III.

To finish with all that relates to the history of slow spinal compression, it remains for me to say a few words in reference to the particular symptoms which are met with when the lesion affects the lumbar enlargement or the cauda equina. I will be brief on this point, because it has not yet been, so far as I know, the object of sufficient clinical research. The only facts to be noticed with regard to the occurrence of profound alterations occupying the lumbar enlargement throughout the whole of its inferior position to the *filum terminale* are: the flaccidity of the paralysed limbs, marked inertia of the anal and vesical sphincters, and diminution or even suppression of reflex acts.² If the lesion should be situate on one side only of the enlargement, let us say on the right side, and, for instance, on a level with the third sacral pair of nerves, extending a little above and below this point, the following phenomena would be observed: right motor paralysis affecting little more

what precedes, that these symptoms, which writers have always sought to attach either to an alteration of the ventricle walls, or to the formation of clots in the cardiac cavities, arise in certain cases, at least, from a lesion affecting the medulla oblongata or the superior cervical cord; this is a thesis the discussion of which I reserve for another opportunity. See Milner Barry, 'British Medical Journal,' July, 1858; R. Thompson, 'Medical Times,' Jan., 1860; Eisenmann, "Der Ursache der diphtherischen Lähmungen" ('Deutsche Klinik,' Juli, 1861, No. 29, p. 286); Greenhow, 'Clinical Society of London' ('The Lancet,' May 4, 1872, p. 615).

¹ Ogle, 'Pathological Society,' 1863, p. 17.

² Brown-Séguard, 'Diagnostic et traitement des principales formes de paralysie des membres inférieurs,' Paris, 1864, p. 73. W. Ogle, 'Pathological Society,' 1853, t. iv. 'Fracture of the last dorsal vertebra with destruction of the spinal marrow.'

than the leg and foot; preservation of the sense of feeling on this side in the paralysed parts; complete or nearly complete anæsthesia of the corresponding parts of the left side with retention of voluntary movement. We should also find,—and this it is which enables us to differentiate such a case from those where the hemilateral lesion is seated higher in the cord,—loss of sensibility in different parts of both sides of the trunk and inferior members, especially at the anus, the perinæum, and the knees.¹

The consequences of compression of the nerves of the cauda equina, naturally belong to the history of lesions of peripheral nerves. The pseudo-neuralgic pains, motor paralysis, and anæsthesia would necessarily vary in position and extent, and that according to the mode of distribution and the degree of lesion of these nerves. The sphincters of the anus and of the bladder should, in such a case, remain generally intact, but bed-sores of rapid development might form in the sacral region and on other parts of the lower extremities.²

Here, gentlemen, will terminate our discourse touching the symptoms of spinal compressions. If time had permitted, I should have been glad to show you, by the examination of particular instances, what advantage we can derive from a knowledge of the facts which we have registered, in the clinical observation of diseases of the spinal cord. To my great regret, I find myself coerced to leave, as a project for the future, this labour of applied investigation.

¹ See, in reference to this, the very interesting observation, though not followed by autopsy, reported by M. Brown-Séguard in the 'Journal de la Physiologie,' t. vi, 1863, p. 624, obs. xxiii.

² Brown-Séguard, loc. cit., p. 623; Knapp ('New York Journal of Medicine,' Sept., 1851, p. 198); Desruelles, 'Société Anat.,' 1852, p. 12; 'London Hospital Reports,' t. iii, 1866, p. 343).

PART THIRD.

ON SPINAL AMYOTROPHIES.

INFANTILE SPINAL PARALYSIS; ADULT SPINAL PARALYSIS;
SPINAL PROGRESSIVE MUSCULAR ATROPHY; AMYOTRO-
PHIC LATERAL SCLEROSIS, &c.

LECTURE IX.

INFANTILE PARALYSIS.¹

SUMMARY.—*Spinal myopathies or myopathies of spinal origin. General characters. Localisation of spinal lesions in the anterior cornua of grey matter.*

Infantile spinal paralysis.—To be considered as a disease for study. Symptoms.—Period of invasion, its modes; second period or retrogression of symptoms with localisation of muscular lesions (muscular atrophy, arrest of development of the osseous system, coldness of extremities, deformities, paralytic club-foot).

Pathological anatomy of infantile paralysis.—Lesions of muscles at different periods; fatty deposits. Lesions of the nervous system; history (Charcot and Cornil, Vulpian and Prévost, Charcot and Joffroy, Parrot, Lockhart Clarke and Johnson, Damaschino and Roger). Localisation of lesions in the anterior cornua of grey substance. Secondary alterations; sclerous transformation of neuroglia; foci of disintegration; partial sclerosis of the antero-lateral columns; atrophy of the anterior roots. Reasons tending to demonstrate that the primary lesion resides in the nerve-cells.

GENTLEMEN,—Allow me to call your attention to a nosographical group, which I propose to designate by the name of *spinal myopathies* or *myopathies of spinal origin*.

Atrophic lesion of the muscles, varying in extent and intensity, is a feature common to all individuals of the group, and, in fact, constitutes their most salient clinical characteristic.

Again, the muscular affections in question appear to be always

¹ This lecture, delivered at La Salpêtrière, in July, 1870, was published in 'La Revue photographique des Hôpitaux,' in January and February, 1872.

correlated with an alteration which, in a predominating, if not exclusive, manner, occupies certain well-determined elements of the grey substance, namely, the *apparatus of nerve-cells termed motor*, which, as you are aware, are situated in the anterior cornua of the grey substance of the spinal cord.

Before entering upon a special study of the different affections which constitute this group, suffer me to give you some preliminary details, calculated to bring out the general characters which I desire to indicate in a very summary manner.

Although the central grey substance occupies a comparatively limited space in the spinal cord, it nevertheless is the most important part of the spinal centre, viewed from a physiological standing-ground. It will be enough for me to remind you that this central cord of grey substance is the gangway for the transmission of sensory impressions; that the volitional and reflex motor impulses should also necessarily pass through the grey substance—so that, if this passage were cut, the accomplishment of all these functions would be simultaneously rendered impossible. But it seems to be now demonstrated that all the parts of the grey substance are not indiscriminately qualified for the execution of these different functions. In that limited, that circumscribed space, which the grey substance occupies in the centre of the spinal cord, we have reason to distinguish several regions, several very distinct departments. Thus it is, for instance, that M. Brown-Séguard, and, after him, M. Schiff, separates *physiologically*, in a very clear manner, what he terms the central grey matter from the grey cornua. The transmission of sensory impressions would seriously concern the first mentioned region only (with, at least partially, the posterior cornua). As to the anterior cornua they appear to be destined, above all, for the transmission of motor impulses, and to have little concern with sensibility.

Gentlemen, these results which are founded upon physiological experiments, have been confirmed by pathology. For disease sometimes determines alterations that affect, singly and severally, the different regions of the grey substance, and that in a manner more satisfactory than the most skilful physiologist could effect.

This is precisely the case as regards those affections which we are about to describe. They are determined by a lesion which may occupy exclusively, or nearly so, the anterior cornua; and consequently, whilst the transmission of sensory impressions is

modified in nothing, except perhaps in a merely accessory manner, as if by chance, the motor functions are on the contrary profoundly injured.

This absence of sensory change is a feature which differentiates the diseases of the group from the different forms of myelitis we shall soon have to study, and which, like the preceding, may affect the central grey substance.

In these central myelites the inflammatory lesion bears indiscriminately on all points, on all regions of the grey substance; whence it follows that sensibility and movement are, of necessity, simultaneously altered. The motor functions and muscular nutrition are alone affected, on the contrary, in cases of spinal myopathies, properly so called, at least in pure types—types free from any complication. And, since we are engaged in comparing myelitis with spinal myopathies, let us also mention the following characters which belong to the former and not to the latter.

The muscular affection is, in the latter case, confined to the muscles of animal life, particularly to those of the extremities; the trunk and the head are, indeed, far from being exempt; but the functions of the bladder and rectum are generally respected.

Contrary to what takes place in ordinary myelitis, it is also rare to see *eschars* (bed-sores) or other disorders of the nutrition of the skin in *spinal myopathies*, even in the most serious cases.

Finally, the *exaltation of reflex action*, the *different forms of spinal epilepsy* which are seen in certain myelites, and the *permanent contracture* which is superadded,—and which also constitutes one of the symptoms of sclerous diseases of the white antero-lateral columns at a certain stage of development—all these are absent in cases of spinal myopathies.

In short, gentlemen, lesions of the muscular system of animal life, whose presence is betrayed by motor impotence and by wasting, of a more or less marked degree, are, as I have indicated, the predominating clinical characteristic of the diseases which compose the nosographic group which we propose to study together. But, in reference to this, it is proper to lay down an important distinction.

Sometimes, motor impotence displayed in a certain number of muscles or groups of muscles is the first symptom which observation detects. The muscle is first paralysed; the motor functions are more or less completely annulled; alteration of the muscular structure appears only to take place in a secondary manner.

At other times, on the contrary, the affected muscles are, from the outset, the seat of very marked trophic derangements; and, in such cases, the lack of motor power seems to be in some sort proportionate to the degree of atrophy which the muscles undergo.

These are two extreme types, connected together by numerous intermediate cases; for frequently, most frequently perhaps, the stricken muscles are both paralysed and atrophied, and, besides, more or less completely altered in their structure.

The disorders which we are about to assemble under the same heading have been hitherto entirely separate, in nosography, as though they were radically distinct diseases. As an example, it may suffice to quote *infantile spinal paralysis*, *general spinal paralysis*, recently described by M. Duchenne (de Boulogne), and which has not yet been allowed right of domicile in the standard categories, *glosso-labio-laryngeal paralysis*, certain forms of *progressive muscular atrophy*, &c. I trust to demonstrate that the bringing together of these diseases, which we are about to attempt, will render evident some common characteristics which, up to the present, have been ignored.¹

¹ All the muscular atrophies, developed under the influence of a spinal lesion (*spinal amyotrophies*) may be reduced to two fundamental groups. In one group, the disease is evolved, anatomically and clinically, in an acute or even a superacute manner. In the other, it assumes in its course the characters of a primarily chronic disease. We have here grounds to make a marked division.

The group of rapidly developed spinal amyotrophies, however circumscribed it may be, already offers a tolerably vast field for study; for the lesions of the spinal cord which may entail the speedy development of muscular atrophy are many. We may mention, as examples, *acute central myelitis*, *i. e.* principally localised in the grey substance, *hæmatomyelia*, different forms of *traumatic myelitis*, whether due to sudden compression caused by displacement of a fractured vertebra, or arising from a wound produced by an instrument penetrating the rachidian canal; and, finally, *infantile paralysis*.

Amongst these spinal lesions, so different in origin and in nature, there is one whose fundamental anatomical characteristic is to connect itself systematically, so to say, with the regions of the grey substance occupied by the great motor cells, whose atrophy and even complete destruction it determines. This affection, which is no other than *infantile paralysis*, constitutes, consequently, in the group of acute spinal amyotrophies, a remarkable type which ought, first to be examined, because the medullary lesion and its results are here produced under conditions which are comparatively simpler and therefore more favourable for analysis than anywhere else. ('Cours d'Anatomie Pathologique de la Faculté,' Avril, 1874.)

II.

But it is time, gentlemen, to leave these preliminary considerations, which are too general not to be somewhat vague, and to enter upon an analysis of the facts. We will select as a standard the singular disease which is commonly known by the name of *infantile paralysis*. That is, in fact, one of the most remarkable types of the group; the specific characters are here displayed in the most striking manner; hence, of the kind, *infantile paralysis* may be presented as a model disease for study; for, if we succeed in rightly rendering evident to you the most salient features of its history the task which remains to be accomplished will have been made easy, as I think you will acknowledge.

You are aware that the disease in question is one which, up to a certain point, pertains to childhood. In fact, it is most frequently developed between the ages of from one to three years.¹ After five, the cases are rare;² and after ten, they are altogether exceptional.³ But it is important to observe, gentlemen, that we may find developed in the adult, and even at a mature age, an affection which differs in nothing essential from infantile paralysis; so that, side by side with the *spinal paralysis of childhood*, we have reason to make a place for *spinal paralysis of the adult*. This is a point which M. Duchenne (de Boulogne) has prominently set out, which other observers have recognised also,⁴ and which I shall note in my turn.

I shall state in a few words the symptoms which characterise this affection; and, for greater clearness, we will distinguish, in our description, the existence of two periods.

First period.—1°. The *mode of invasion* of infantile paralysis is, you are aware, a most remarkable one. The disease has an abrupt, sudden beginning, generally ushered in by intense fever, either with

¹ Laborde, 'De la paralysie (dite essentielle) de l'enfance,' Paris, 1864, p. 98.

² Laborde, loc. cit, p. 63. Heine, 'Spinale Kinderlähmung,' 2e Aufl, Stuttgart, 1860, p. 60.

³ Duchenne (de Boulogne) fils, 'De la paralysie atrophique graisseuse de l'enfance,' Paris, 1864, p. 21.

⁴ Duchenne (de Boulogne) 'De l'électrisation localisée,' 3e édit., 1872, p. 437; M. Meyer, 'Die Electricität und ihre Anwendung,' &c., Berlin, 1868, p. 210; Roberts, in Reynolds' 'System of Medicine,' p. 169.

or without accompanying convulsions, or other cerebral symptoms, and sometimes transient contractures.

This *initial fever*, to which we have just called your attention, is observed, I repeat, in the majority of children; however, it may sometimes, it would appear, be altogether absent.¹

However this may be, the paralytic symptoms show themselves with sudden completeness; between day and morrow, and from the very outset, they have reached their summum in extent and intensity. These paralytic symptoms present great diversity as regards the parts affected. At times, the paralysis is absolute, complete, and affects the four extremities, or three of them: again, it may take only one lower extremity, or even one of the superior extremities;² at other times, but very rarely indeed, it affects both superior extremities;³ finally, there are cases where the paralysis, attacking the inferior extremities alone, assumes the paraplegic form.

To sum up, we observe here a *complete absolute paralysis*, with flaccidness of the extremities, and with abolition or diminution of reflex excitability, but—and this is a point on which I still lay stress—without any trace of loss of sensibility, of dermal necrosis, or of functional derangement of bladder or rectum.⁴

Does pain or formication exist, at the commencement, which would indicate at least a temporary participation of the central grey substance? Some observations made by MM. Duchenne and Heine, in the case of children old enough to furnish information on this subject, tend to establish an affirmative. The symptoms remarked in the adult, in similar cases, go to support this opinion, as we shall see elsewhere. This, however, is most frequently but a transitory and incidental phenomenon, and, indeed, the absence of any marked alteration of sensibility, contrasting with so complete and absolute a motor paralysis, is one of the most striking characters of infantile paralysis.⁵

Here also is another feature. At a period very close to the outset

¹ R. Volkmann, "Ueber Kinderlähmung und paralytische contracturen," in 'Sammlung Klinischer Vorträge,' No. 1, Leipzig, 1870, pp. 3, 4.

² R. Volkmann, loc. cit.

³ Duchenne (de Boulogne) fils, loc. cit., pp. 13, 18; L. Clarke, 'Med.-Chir. Transactions,' t. li, 1868.

⁴ Volkmann, loc. cit. This author remarks that the sexual functions, in the adult, are not interfered with.

⁵ Duchenne (de Boulogne) loc. cit., Volkmann, loc. cit., &c.

of the disease, *faradaic contractility* is diminished in a great number of the paralysed muscles, and extinguished in several of them; this is an important phenomenon, which M. Duchenne (de Boulogne) has several times verified after the fifth day, but which is more frequently met with on the seventh and eighth days. I may here remind you that, according to some authors, *galvanic contractility* may still set in action muscles which faradisation no longer affects. Every muscle which, after the lapse of a few weeks from the invasion of the disease, does not react is threatened with destruction for life.¹

Such, gentlemen, are the more salient characters of the first period of infantile paralysis; I request your permission to sum them up in a few words:

1°. Abrupt invasion of the motor paralysis which, at the first blow, attains its summum of intensity, either subsequent to a more or less intense febrile state, or in the absence of fever.

2°. Prompt diminution and even apparent abolition of faradaic contractility in a certain number of muscles smitten with paralysis.

3°. Absence of marked disturbance of sensibility—of paralysis of rectum or bladder; absence of eschars or other cutaneous trophic disorders.

Second period.—Gentlemen, regression of the symptoms we have just discussed inaugurates the second period of infantile paralysis. It begins to show itself from the second to the sixth month after the invasion; sometimes sooner, sometimes later. It takes several months to complete its work—six months, in some cases, according to Volkmann. Eight or ten months after the invasion,—an epoch which marks the close of this retrograde period,—the muscles which have not recovered their functions may, according to most observers, be considered as for ever injured, as irreparably lost. On the other hand, the improvement which may take place does not, as a general rule, show itself in every point. In ordinary cases, there are always some muscles, occasionally those of an entire extremity, or only those of a particular region of a member, in which the lesions continue, on the contrary, to make progress for a certain time still; then they persist indelibly, and offer to the observer a series of phenomena which deserve to detain us for special study.

¹ Volkmann, 'Klin. Vorträge,' p. 5. On the other hand, judging from my own experience, I find that, occasionally, muscles which have long ceased to react, may regain their faradaic contractility and recover their functions, more or less completely.—G. SIGERSON.

a. Atrophy soon becomes manifest in those muscles in which *faradaic contractility* has not reappeared. One does not always correctly apprehend the extent of this atrophy, because it is often masked, we must remember, by an accumulation of cellulo-fatty tissue. It constitutes, nevertheless, one of the salient features of infantile paralysis, and seems to show itself more quickly, in this disease, than in cases of lesions of mixed nerves, where, however, it is very rapid. Thus, according to Dr. Duchenne (de Boulogne), it is already very evident *at the end of a month*, in infantile paralysis; and there are cases, though indeed very rare, in which it may be remarked even from the first days.

b. Arrest of development of the osseous system.—We have to note here an important feature described by M. Duchenne (de Boulogne), and after him, by Herr Volkmann, namely, the arrest of development of the osseous system. The atrophy which affects the bones is not at all in necessary proportion to the degree or extent of the muscular paralysis and wasting.

Thus, according to a remark of Duchenne (de Boulogne) an extremity, stricken with infantile paralysis, may have lost most of its muscles, and yet be no shorter than that of the opposite and healthy side, except by two or three centimètres; whilst, in another case, the loss in length of the paralysed extremity may reach five or six centimètres, although here the muscular lesion may have remained localised in barely one or two muscles at most, and may have allowed a prompt recovery of motion.¹ H. Volkmann, also, has observed cases of considerable shortening of the affected member in children who, on account of the slight degree of alteration in the muscles of the feet, and the small extent of essential deformations, scarcely halted at all, and kept on their legs a good part of the day. He states that he has four or five times noticed, that an infantile paralysis which was quite transient, and which issued a few days later in complete recovery of the functions of the muscles, was nevertheless followed by trophic osseous lesions which lasted for life.²

It would be difficult to find an example better adapted to establish the direct action of lesions of the central nervous system

¹ 'De l'électrisation localisée,' 3e édition, 1872, p. 400.

² R. Volkmann, loc. cit., p. 6. "Even in very circumscribed and very incomplete infantile paralysis, the trophic disorder in question may affect the limb throughout its whole extent; traces are frequently found in the trunk, the pelvis, the shoulders, and in some cases, even in the head." Id. loc. cit.

over the nutrition of the osseous parts, since it is impossible, in such circumstances, to appeal to the influence of prolonged functional inertia.

c. Coldness of the extremities.—Another phenomenon, which deserves to be noticed on the same grounds as the preceding, is the often very marked permanent coldness which, sooner or later, affects the paralysed extremity. This perhaps is the place to point out that, besides the atrophy of the muscles and the bones, we find, on autopsy, in cases of this kind, a remarkable diminution in the calibre of the vascular trunks. There are circumstances where the coldness in question becomes appreciable at a very early hour, occasionally some weeks after the invasion or even sooner.¹

d. A final feature is supplied by the *deformations* which become evident in the paralysed member, in consequence of the predominant action of those muscles which have remained healthy or which, at a given moment, have recovered their tone. The pathogeny of these deformations presents nothing obscure. We know that the atrophy is not uniformly distributed over all the muscles of a limb; it predominates in certain muscles and groups of muscles; and the antagonists of these must, in the long run, impose vicious attitudes according to the direction of their motion. The deformities begin to show themselves about the eighth or tenth month. Thus is developed the club-foot of infantile paralysis which is pre-eminently the *paralytic club-foot*, and which, in the immense majority of cases, assumes the form of *varus equinus*.

There is extreme laxness of the ligaments, and it is easy to place the parts of the paralysed limb in the most abnormal attitudes, reminding you of the postures of a puppet. Taken with the other characters, and especially with the permanent coldness of the limb, this extreme laxity of the joints allows us to distinguish, with certainty, the club-foot due to infantile paralysis from congenital club-foot, even though all information touching the origin of the deformity be absent.²

From the epoch when the lesions have become definitely established in certain muscles, it may be said that the disease has become arrested. Henceforth, we have only to deal with a more or less distressing infirmity which, according to the remark of

¹ Duchenne (de Boulogne) mentions that he has observed it already present from the fourth to the fifth day. Loc. cit., p. 398.

² Heine, loc. cit., pp. 14, 15, 20.

Heine, appears to have no direct influence over the duration of life. In support of this statement, I can introduce to your notice to-day an aged inhabitant of this hospital who presents, after the lapse of threescore and ten years, the well-marked characteristics of the disease which attacked her, when she was five years old.

Such are the fundamental characters of infantile spinal paralysis considered in its regular course; sometimes, in the natural evolution of the disease, irregularities take place which must also claim your attention.

Thus, there are cases in which the initial fever exhibits an exceptional intensity and continuance; there are others where, subsequent to the fever, the paralysis instead of suddenly reaching its highest degree of intensity, develops, on the contrary, in a progressive manner for the space of some days, or even of some weeks.

Finally, there are other cases in which, during the period of regression, halting stations occur, or returns of active aggression may take place.¹

I shall not insist further on these abnormal facts which, besides, seem to be rather rare. However, I did not think they should be passed over in silence; because, in my opinion, they may serve to establish a connecting link between infantile spinal paralysis and the other diseases of this group.

III.

I shall, at present, endeavour to describe to you the lesions which recent researches have shown to exist in infantile paralysis, and to which the very remarkable array of phenomena just mentioned belong.

We shall treat, in the first place, of the muscular lesions; and, in the second, of lesions of the nervous system.

1°. *Lesions of the muscles.*—I will be brief in dealing with the question of muscular change, for this is a subject that still requires further examination.

A. *First period.*—Positive data concerning the histological alteration of the muscles are chiefly lacking in connection with the early phases of the disease. According to what is known, the greater part of the primary, or ultimate, fascicles undergo simple atrophy, in this first period, without fatty degeneration. Microscopical examination, in fact, shows a large number of fascicles of

¹ See Heine and Duchenne (de Boulogne) fils, loc. cit., p. 8.

very small diameter which, however, have preserved their normal striation, and which exhibit no signs of fatty degeneration. A large number of other fascicles, intermingled with these, also enclose, at intervals, clusters of nuclei of sarcolemma. Finally, here and there, we meet with a third order of fascicles, generally very few in number, which have lost their striation and present, in different degrees of development, the characters of fatty granular degeneration. This is, however, I repeat, an exceptional occurrence. In short, it appears established that *irritative lesions* predominate over the *lesions* which are termed *passive*. We shall soon see that, contrary to the opinion generally accepted, the same characteristic is observable in progressive muscular atrophy of spinal origin.

The lesions in question appear to manifest themselves early; M. Damaschino, as we learn from M. Duchenne (de Boulogne), remarked them three weeks after the invasion of the disease, on a fragment of muscle obtained by the assistance of the "*emporte-pièce*;" with the same instrument, Drs. Volkmann and Steudener were likewise able to study the paralysed muscles, at a period closely following the outset, and they have recognised the same alterations.¹ The last-named authors point out, also, a hyperplasia of the connective tissue, which is not mentioned by the other observers, and which we have ourselves identified very distinctly in cases of old standing.

B. *Second period*.—If the altered muscles be examined at an epoch remote from the invasion of the paralysis, as we many a time have had occasion to do at the Salpêtrière, it is seen that all the signs of *fatty substitution and loading* are usually superadded to the lesions above described. Clusters of granulations and fatty droplets accumulate in the sheaths of the sarcolemma, and replace here the primary (or ultimate) fascicle which totally disappears, or which leaves but fragments behind. On the other hand, adipose cells form in heaps on the outside of the sarcolemma, in the intervals which separate the primary fascicles.² This interposed adipose tissue is sometimes sufficiently abundant to distend the enclosing aponeuroses, so that, as M. Laborde³ perfectly observed, the

¹ Volkmann, loc. cit., p. 5.

² See, in reference to this subject, in the second volume of the 'Archives de Physiologie,' observations of MM. Vulpian, Charcot, and Joffroy.

³ Laborde, loc. cit., p. 47.

volume and form of the muscular masses may be preserved to a certain extent, though most of the ultimate fibres have vanished. There are even cases, one of which I have myself observed,¹ where the fatty accumulation is so great in extent that the volume of the muscle is markedly augmented, so as to exactly reproduce the appearance seen in the ultimate period of the affection described by Duchenne (de Boulogne) under the name of *pseudo-hypertrophic* or *myo-sclerotic* paralysis. This is a point concerning which you must have a clear understanding; I will shortly have occasion to show you that, in spite of this analogy of secondary importance, infantile paralysis still differs essentially from pseudo-hypertrophic paralysis (the *atrophia musculorum lipomatosa* of some German authors) by an imposing array of clinical and necroscopic characters. Let it suffice, for the moment, to mention that the spinal lesion which, in infantile paralysis, is never absent, is absolutely deficient, on the contrary, in myo-sclerotic paralysis,—if at least I may judge from my own observations, which are in conformity on this point with those of Cohnheim.

Fat accumulation, although it is usual in infantile amyotrophy of long standing, is not, however, necessarily bound up with it; side by side with muscles distended by fat, there are frequently others which are reduced to a very small volume, in which the adipose tissue is almost entirely deficient.² In the latter muscles, we only find primary fibres of very small diameter, but which have preserved their striation; here and there some sheaths of sarcolemma enclose clusters of nuclei. These wasted primary fibres are separate, one from another, by fibrillary connective tissue, which is evidently of new formation. The muscles which have undergone this mode of alteration present, to the naked eye, the appearance of fibrous tissue, or of dartos. It would be interesting to know if the interstitial connective hyperplasia which is observed, in such cases, is a constant fact, and if it dates back to the first phases of the disease, as the observations of MM. Volkmann and Steudener would lead us to suppose. But this is a point which requires further investigation.

2°. *Lesions of the nervous system; spinal lesions.* The spinal lesions, which I am about to discuss, unquestionably constitute, at the present time, at once the most interesting and the newest.

¹ 'Arch. de Physiologie,' t. ii, p. 142.

² See the observation of Wilson, in 'Arch. de Physiologie,' loc. cit.

element in the anatomical history of infantile paralysis. Hence, I think it will be useful in connection with this, to enter into some details.

Many authors, as you are aware, have considered the affection in question as occupying the *peripheral parts*, muscles or nerves; others have looked upon it as an *essential disease*, which, here, especially, has no great meaning. It is, however, right to observe that the majority of physicians who have particularly taken up the question have, with common consent, designated the spinal cord as being the organ where the primordial and fundamental lesions of infantile paralysis should be sought for. This was a correct assumption, on their part, but it was one which, until later years, was not based upon any really positive data. Reference was made to "*congestions*," to "*exudations*," without any strict demonstration of their existence; for, in the absence of sufficient means of investigation, the results of necroscopic examination were nearly always negative or equivocal. Such was the state of the question when, at the Salpêtrière, the first regular studies were undertaken in reference to the necroscopy of the spinal centre in infantile paralysis.

In 1864, we had detected, M. V. Cornil, then my clinical clerk, and myself, in connection with a case observed in one of my wards, a portion of the spinal alterations which preside over the development of infantile paralysis. But it was, I must say, the least important portion. Thus, we identified the existence of an atrophy of the anterior cornua of the grey substance, and of the anterolateral white columns, in the region of the cord whence were given off the nerves going to supply the wasted muscles; but we did not remark the decrease in number and in volume which the great motor cells had undergone,—an alteration, however, which may be very distinctly observed in a section prepared at that period by M. Cornil, and which is at present in the possession of my friend, M. Duchenne (de Boulogne).¹

The lesion of the motor nerve-cells in infantile paralysis was first pointed out by MM. Vulpian and Prévost, in 1866, in the case of a female inmate of the Salpêtrière. In this case, which was communicated to the *Société de Biologie* by M. Prévost, most of the cells had disappeared from the anterior cornua of the segment of the cord corresponding to the atrophied muscles and, in

¹ 'Comptes Rendus de la Société de Biologie,' 1864, p. 187.

the place they had occupied, the neuroglia exhibited sclerous transformation.¹

A case, reported, in 1869, by MM. L. Clarke and Z. Johnson, under the name of *muscular atrophy*, ought, we think, to be correlated to the foregoing: a critical examination, in fact, allows us to perceive that, though these authors do not state it, the case in question was one of infantile paralysis. The period of life in which the disease showed itself, the abruptness of the invasion, the mode of localisation of the atrophy in the muscles, permit but little doubt to exist in this respect: now, in this instance also, microscopic examination revealed the atrophy of the anterior cornua, the disappearance or granular wasting of a certain number of motor nerve-cells, and in addition, the existence of several *foci of disintegration* in different points of the grey substance.²

But, if I mistake not, the study which has most contributed to determine the character of the spinal lesions of infantile paralysis, is that which was carried out, last year, by M. Joffroy, my clinical clerk, and myself, in a very remarkable case, that of a female patient of my wards, named Wilson, who succumbed to pulmonary phthisis at the age of forty-five. The paralysis had, in her case, suddenly developed itself, when she was seven years old; the four extremities were stricken, and most of their muscles had rapidly atrophied. Her limbs had, also, experienced a remarkable arrest of development, and presented some characteristic deformations.³

Here the lesions were extremely distinct, and they extended nearly the whole height of the spinal cord: throughout, they occupied principally, and in some parts exclusively, the anterior cornua of the grey substance (Fig. 8.)

In all the regions of the cord the great motor cells were greatly altered, though in different degrees; and in the most seriously affected parts, entire groups of cells had disappeared without leaving a trace behind. The neuroglia had almost always undergone sclerous transformation in the immediate neighbourhood, and to a certain distance from the injured cells, but there were points, and this fact deserves prominence, where this cell-lesion was the only alteration which histologic examination could detect, the con-

¹ *Idem*, 1866, p. 215.

² 'Med.-Chir. Trans.,' t. li, London, 1868.

³ 'Société de Biologie,' and 'Archives de Physiologie,' t. iii, p. 135, 1870.

nective web having, in these places, retained its transparency, and very nearly all the characteristics of its normal structure.

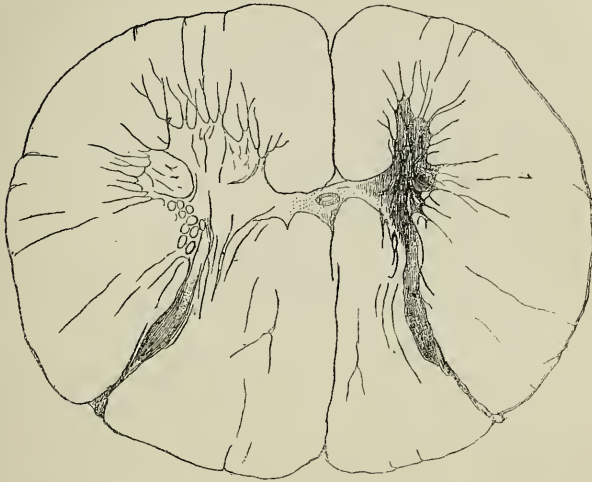


FIG. 9.—Section of the cord, in the cervical region, in a case of infantile spinal paralysis of the right superior extremity. Preparation obtained in the Salpêtrière, in the case of a female patient who died of general paralysis at the age of fifty. Fibroid atrophy of the anterior cornu of the right side, consecutive emaciation of all the white fascicles in the corresponding half of the cord.

Finally, we shall notice, in our observations, an atrophy with partial sclerosis of the antero-lateral columns and a well-marked wasting of the anterior roots, particularly remarkable on a level with the regions of the cord which were most gravely affected, alterations which had been already pointed out in essays published anterior to our own.

In the memoir, based upon our observations, we considered ourselves justified in admitting that the *lesion of the motor nerve-cells*, mentioned already in the cases of MM. Vulpian and Prévost, and in that of L. Clarke, *is a constant fact in infantile spinal paralysis, and one from which the principal symptoms of the disease are derived*, particularly the paralysis itself, and the muscular atrophy as well. We also gave it as our opinion that, in all probability, that is the initial anatomical fact; the lesions of the neuroglia and the atrophy of the nerve-roots being regarded as consecutive phenomena.

I cannot, to-day, give you all the arguments which might be pleaded in support of these assertions; to do so, would be to occupy too much time. Besides, I reserve this task for the period when I shall have made known the other morbid species which belong to the group of myopathies of spinal origin. I expect then to enter upon a regular discussion of the subject, in reference to the part which I attribute to the motor nerve-cells in the production of trophic lesions of the muscles. At present, I shall confine myself to the following considerations which more particularly concern infantile paralysis.

In connection with our first conclusion, it will be enough to point out that it receives confirmation from all the facts, and they are now numerous enough, which have been observed since the publication of our memoir.

Thus, the lesion of the motor cells is expressly mentioned in an observation reported by MM. Parrot and Joffroy, the case being that of a child where the disease had barely lasted a year;¹ in a case noted by M. Vulpian at the Salpêtrière;² and in two other cases observed at the Children's Hospital, by M. Damaschino, the details of which I only know as yet from the information given by M. Duchenne (de Boulogne).³ Finally, the self-same lesion existed, in the most distinct manner, in three new cases quite recently noted in my wards, the anatomical examination of which has been carried on with the greatest care by my pupils, MM. Michaud and Pierret. These new facts, taken in conjunction with the previous ones, go to form a sufficiently imposing array, especially when it is remembered that, up to the present time, no contradictory case of any value has been reported. The cases which have been quoted in opposition to us all date from a period when the methods of investigation as applied to the anatomical study of the cord had not reached the degree of perfection which they possess at present; and, besides, none of these cases bears that character of exactness which we have a right now to require in observations of this kind.

¹ 'Archives de Physiologie,' t. iii, 1870.

² Idem, t. iii, 1870.

³ The observations, three in number, noted in the wards of M. Roger by M. Damaschino, have been recently communicated to the Société de Biologie, and published *in extenso* in the 'Gazette Médicale,' Nos, 41, 43, 45, 48, 51 (October, November, December, 1871).

With respect to the second proposition, I shall put forward what follows:—If, in certain points, the lesions of the neuroglia invade the greater portion of the grey substance, and even sometimes extend to the adjacent parts of the antero-lateral columns, it is not the less true that, in other points, they remain strictly limited to the anterior cornua, which they do not always even occupy throughout their whole extent. They are, in fact, occasionally seen strictly, and as it were systematically, localised in the very circumscribed oval space which corresponds to a group or cluster of motor cells. (fig. 9.)

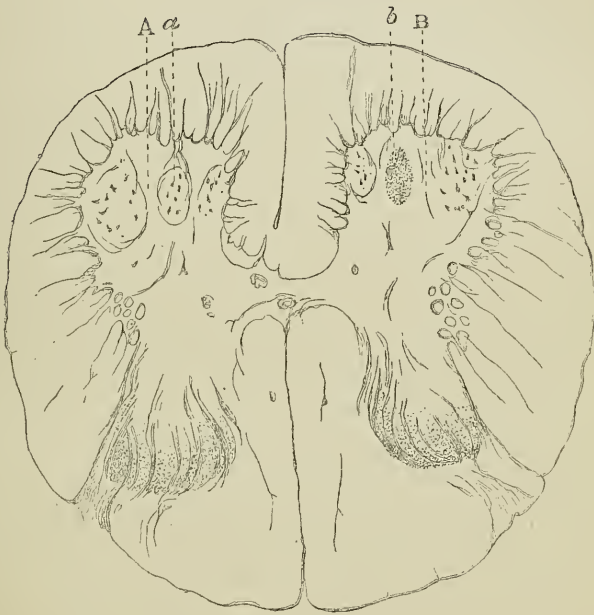


FIG. 10.—Section of the cord, in the lumbar region. A, left anterior cornu, healthy; a, healthy ganglionic nucleus. B, right anterior cornu; b, median ganglionic nucleus, the cells of which are destroyed, and which is represented by a little focus of sclerosis.

How is it conceivable that this could be, if the alteration had its starting-point in the connective tissue interposed between the nerve-elements? Is it not more probable that it has its origin in special organs endowed with proper functions, such as the great nerve-cells, termed motor, are? It is in this way, according to

the theory put forth by M. Vulpian, a theory to which I quite adhere, that the sclerosis systematically limited to the posterior columns should be correlated to an irritation primarily occupying the nerve-tubes which enter into the composition of these columns.

There are occasions, also, and the case of Wilson may be here remembered, where in certain points the alteration of a certain number, it may be an entire group of nerve-cells, is the only lesion which histological examination enables us to perceive, the connective web having, in such points, preserved its transparency, and very nearly all the characteristics of normal structure. In other regions, the lesions of the neuroglia may show themselves much more marked towards the central part of an aggregation of nerve-cells than in the peripheral portion; much more marked likewise in the immediate vicinity of the cells than in the intervals between them, so that the cells shall appear as so many centres or foci whence the morbid process has radiated, to a certain distance, in all directions.

Again, it could not be admitted that the irritation had originally developed in the peripheral parts, and that it had afterwards ascended to the central portion by the channel of the anterior roots of the spinal nerves; for the latter generally, as MM. Parrot and Joffroy have clearly shown, only present, in recent cases, at a level with the altered regions of the cord, comparatively slight lesions, and not at all proportionate in intensity to the lesions of the grey substance.

It appears evident to us, from what precedes, that the motor nerve-cells are, in all reality, the primary seat of the disease. Generally, no doubt, the irritative process subsequently attains the neuroglia, and extends, bit by bit, to the different regions of the anterior cornua; but that is not at all necessary. *A fortiori*, we must regard, as a consecutive and purely accessory fact, the extension observed, in certain cases, of the morbid process to the antero-lateral columns.

The lesion, in question, of the nerve-cells, to judge from the character of the alterations presented by the connective web, is of an irritative nature; but, this is a point as to which direct and purely anatomical examination cannot, at least at present, afford us any information. Similarly, in fact, to what takes place with respect to the nerve-tubes, the *irritated* nerve-cells atrophy and, at the latter end of the process, disappear, without the mode of

the affection which originates them being revealed by any special characters.

One word, in concluding, relative to these changes in the connective web which, in my opinion, are a secondary phenomenon, consecutive on the affection of the nerve-cells. In cases of old standing, they principally consist in a fibrillary or fibroid metamorphosis of the reticulum, with more or less complete disappearance of nerve-tubes and condensation of the tissue; but these are only the last vestiges of a morbid process which has been long extinct, and it is difficult to divine what may be the alterations in the early phases. It is probable enough that we might there find the histological characters of acute myelitis with multiplication of myelocytes and of the nuclei of the vascular sheaths, such, in short, as it has been described by Frommann and by Mannkopf. The existence of foci of disintegration, noticed in Clarke's observation, and in some of the cases we have noticed at the Salpêtrière, shows that, in some spots, the inflamed tissue may undergo real dissociation. The cases of M. Damaschino would even go to establish that, in the most seriously injured points of the cord, we may meet with all the characters of *destructive myelitis* with formation of a focus of red softening with vascular lesions, granular bodies, and the rest of it. However this may be, you will easily understand, gentlemen, that nothing of all this goes to invalidate the theory according to which *the apparatus of motor nerve-cells is the first focus and starting-point, as it were, of the inflammatory process.*

It remains for me now to set the symptoms face to face with the lesions, and to inquire how the former are derived from the latter, a duty which I shall shortly endeavour to perform.

LECTURE X.

SPINAL PARALYSIS OF THE ADULT. NEW RESEARCHES CONCERNING THE PATHOLOGICAL ANATOMY OF INFANTILE SPINAL PARALYSIS. AMYOTROPHIES CONSECUTIVE ON ACUTE DIFFUSE SPINAL LESIONS.

SUMMARY.—*Spinal paralysis of the adult. History. Description of a case, borrowed from M. Duchenne (de Boulogne). Personal facts. Close analogies connecting acute spinal paralysis of the adult with that of the child. Symptomatological modifications due to age. Prognosis.*

Recent works concerning the pathological anatomy and physiology of infantile spinal paralysis; they confirm in essential points, and complete in certain respects, the results already detailed.

A word as to acute spinal lesions which are not, as in infantile paralysis, systematically limited to the anterior cornua of the grey substance. Acute central generalised myelitis, hæmatomyelia, traumatic myelites, acute partial myelites. Conditions in which these affections determine the rapid atrophy of the muscles.

I.

GENTLEMEN,—It is now a long time since M. Duchenne (de Boulogne) noted the existence, in the adult, of an *acute spinal paralysis*, comparable to that of the child.¹ Dr. Moritz Meyer,² of Berlin, and Dr. Roberts,³ have also, in past days, reported cases which evidently belong to this category. I have, myself, been more than once struck with the remarkable resemblance which produces a

¹ See, in reference to this subject, the thesis of M. Duchenne (de Boulogne) *filis*.

² M. Meyer, 'Die Electricität und ihre Anwendung,' Berlin, 1868, p. 210.

³ Reynolds' 'System of Medicine,' t. i, p. 169.

clinical connexion between certain paraplegias, of abrupt invasion followed by muscular atrophy, developed in youth or in adult age, and the paralysis of young children.

I desire to establish before you the reality of the existence of this spinal paralysis of the adult comparable to infantile spinal paralysis. I hope to succeed, by first detailing the principal features of an observation which I borrow from the new edition of the '*Traité d'Electrothérapie*' by Dr. Duchenne (de Boulogne), and by afterwards describing some of the facts which have come under my personal knowledge.

The case of Dr. Duchenne (de Boulogne) relates to a girl, aged 22, who awoke one morning with fever, pains, and difficulty in moving her limbs. An hour later she complained of pains in the posterior cervical region, formications and painful irradiations in her fingers. The latter circumstance, if you refer to the description of infantile paralysis, may seem to constitute a striking anomaly as regards the matter in question; but we have not failed to point out to you, elsewhere, that children,¹ when attacked with spinal paralysis, often complain of similar pains, when they are old enough to express their feelings.

Difference of age, however, even supposing a fundamentally identical process, should necessarily cause differences which must not be overlooked. Thus, for instance, in cases similar to that which we have quoted from Dr. Duchenne, when the development of the patient is complete at the period when the disease makes its appearance, you could not expect to see that atrophy by arrest of development, which, in children, goes at least a good way to determine the shortening of the affected members, and forms one of the most salient features of infantile paralysis.

Referring again to the case of Dr. Duchenne we find that hardly had the pain shown itself than the four extremities were completely paralysed, rendered absolutely inert. Four days later, the fever had ceased.

The paralysis of movement persisted for two months without any noticeable change; it seemed, I repeat, to have been absolute; and, in spite of that, the sensibility of the skin was not at all affected. Nor was any lasting disorder of micturition ever observed, nor the least sign perceived of the formation of eschars.

Towards the end of the third month, the retrogression of the paralytic symptoms began to become manifest.

¹ See Lecture IX, p. 130.

At first, motion was gradually regained in the lower extremities; then, fifteen days later, it reappeared in the upper extremities, but, indeed, in an imperfect fashion. The fact was that in a considerable number of the muscles of the superior extremities, nutrition had suffered to such an extent that atrophy was already visible.

Six months after the invasion of the paralysis, an attentive examination revealed the existence of irreparable disorders. A large portion of the muscles of the arm, fore-arm, and hand was considerably wasted, especially in the right limb; and, in addition, they gave no reaction under the stimulus of faradisation. Contrary to what took place in the upper extremities, gradual amendment continued in the lower limbs; where all the muscles had recovered their functions, with the exception of the tibialis anticus of the right leg, whose alteration, and the consequent predominant action of the antagonistic muscles, had occasioned a sort of paralytic talipes equinus.

It is scarcely doubtful, gentlemen, that in spite of the very peculiar characters of the symptomatic group, cases of this kind have been oft times mistaken or misunderstood. Now, according to what I have read or seen, the form of spinal paralysis in question is far from being absolutely rare among the diseases of adult life.¹

¹ Several examples of *adult spinal paralysis* have, in the last few years, been reported by M. Bernhardt ('Archiv für Physiatrie,' iv Bd., 1873) and Kussmaul (Frey—Aus der medicinischen Klinik der Herrn Professor Kussmaul in 'Berlin Klin. Wochensch.,' 1874, Nos. 1, 2, and 3). One of the cases of Professor Kussmaul is particularly interesting, inasmuch as the oscillations of the central temperature have been noted during the whole time of the initial febrile period. These cases have been published in *extenso* in 'Le Progrès Médical,' 1874, Nos. 11 and 12. In England, in the neighbourhood of Leeds, a few years ago, I met, whilst with my friend Professor Brown-Séquard, a gentleman aged 38, who, two years before, after being out of sorts for four days, was taken with intense fever which lasted nearly a week, and was followed by complete motor paralysis of the four extremities with abrupt development. A month after the invasion, motion began to reappear in the right arm, first, then gradually in the other members. But the patient, at present, exhibits a probably indelible atrophy, particularly evident in the muscles of the right arm and left leg. Excepting some formication no sensory disturbance has ever been experienced. The functions of bladder and rectum have always remained normal. No bedsores were formed.

A case published by Professor Cuming (of Belfast) in the 'Dublin Quarterly Journal of Medical Science,' May, 1869, p. 471, seems to me to belong, like the preceding, to *adult spinal paralysis*. See, in reference to this subject, the interesting work of a student of the Salpêtrière, M. Petitfils, entitled, 'Atrophie aiguë des cellules nerveuses.'

Still, the prognosis, as well as all the other circumstances of the disease, generally differs here in a singular way from what is seen in the other forms of paraplegia of abrupt invasion. This is a fact with which it is important to be familiar. Hence, we do not hesitate to enter, now, into new details, in reference to two cases which I have recently noted, and which are full of significance in my opinion.

On account of the age of the subjects concerned (one being nineteen, the other fifteen and a half) they establish a sort of transition between the observation which precedes and those which belong to infantile paralysis, properly so called.

CASE I.—M. X—, aged 19. The only particulars anterior to the paralysis which deserve notice are the following :—His mother was pregnant thrice, and during two of her pregnancies she was subject to mental disorder.

The health of X— had always been excellent ; he enjoyed great physical strength, and was of a rather placid character. During the months of June, July, and until the 10th of August, 1873, X— made great intellectual efforts in preparing for an examination. During this time he repeatedly suffered from copious epistaxis to which he had not been accustomed. He failed in his examination, and suffered great vexation in consequence.

Such were the circumstances when, on the 16th of August, X— was observed in the park of the Chateau where he lived, breaking down a tree with feverish activity. Questioned as to the reason of his act, he replied—“I want to break something, for I feel myself irritated.” The same day he complained of great fatigue, a feeling of contusion and extreme lassitude (*courbature*), especially in the lumbar region, and suffered from copious perspirations.

Next day, he felt himself worse. He was able to get up, however, but he could only walk by leaning on a staff or on the arm of his serving man.

On the third day, a feverish state set in, with some violence from the outset, and which was soon accompanied by symptoms such as would lead one to believe it the beginning of an attack of typhoid fever supervening, with characters of great gravity. The tongue was dry and loaded with blackish fur ; there was great thirst ; the skin was hot ; the pulse 120 ; there was delirium during the night. Finally, tympanitis was observed, and to empty the bladder it was requisite to pass the catheter several times in a period of thirty-six

hours. It is important to note that the retention of urine was, as may be remarked, quite transitory. It did not subsequently recur.

This febrile period terminated at the end of five or six days, and the general condition of the patient rapidly became quite normal again. Then only was the existence of an almost complete paralysis of motion discerned, which was marked by an absolute flaccidness of the parts, and which affected equally the four extremities. The motor inertia had been already remarked during the course of the fever; but it had been, until then, regarded as the result of extreme adynamia. There never was any tendency to the formation of eschars.

Things remained in this state during the following fortnight. After the lapse of this time, a certain amendment was experienced in the condition of the upper extremities; and, in addition, the patient began to be more or less able to sit up.

I was called to see M. X—, for the first time, on Nov. 1, 1873, two months and a half after the invasion of the disease. I noted then the following facts:—On both sides, but especially on the right, there was rather well-marked atrophy of the shoulders and of the posterior part of the arm; on the contrary, the muscles of the fore-arms, of the chest, of the abdomen, and especially of the neck, contrasted by their prominence, which recalled their normal state. On both sides, but chiefly on the left, the palm of the hand was flattened and, as it were, excavated, in consequence of the atrophy of the thenar and hypothenar eminences. From time to time, in the muscles of the hand, there appeared spontaneous fibrillary contractions, which caused slight movements in the fingers. X— cannot raise his shoulders, lift his arms, nor extend his fore-arm; but, by leaning on his elbows, he can use his hands to feed himself. The several kinds of cutaneous sensibility are in no degree changed in the different portions of the trunk and upper extremities.

As to the inferior extremities, they are, both, flaccid, inert, emaciated. No trace of contracture or retraction is observed. The wasting is greater in the thighs than in the calves. Voluntary movements are almost impossible; on the left, they are limited to some slight motions of the great toe; on the right, all the toes may be either voluntarily flexed or extended, but within very restricted limits. It is carefully noted that here also cutaneous sensibility is not the least changed; it is also particularly noted that the different modes of stimulating the skin provoke no reflex movements.

The patient experiences no distressing sensation in the paralysed.

limbs. He says that he only feels some formications from time to time; he also complains of a frequent need of changing position, more pressing at night than by day. The lower extremities are usually cold, chiefly the left foot and leg, which, in addition, are usually covered with clammy sweat.

The pulse is normal, the appetite excellent, the sleep only broken by the need of changing position, just described. The functions of the sphincters are regular.

It has been found impossible to ascertain exactly the epoch when the atrophy of the muscles began to occur. Assurance was given, however, that it was remarked a few weeks merely after the invasion of the disease. It is also to be regretted that, for want of suitable appliances, an electric exploration of the wasted parts could not be performed at this period.

In the consultation which took place, at the first interview, I essayed particularly to emphasise the abrupt and almost sudden invasion of the paralytic accidents, marked as it had been by a very distinct febrile period,—the flaccidness, and the great atrophy rapidly supervening, which the muscles of the paralysed limbs exhibited—phenomena which contrasted with the absence of anæsthesia, of lasting disorders of bladder or rectum, and of sacral eschars. I stated my opinion that this array of positive or negative symptoms allowed us to approximate the case of M. X—, to the type of *infantile spinal paralysis*.

Lastly, basing my opinion on what is taught by the natural history of this affection, I considered that I could assert that the retrocession of symptoms which had already begun, in the upper extremities, would become still more manifest there, and would doubtless extend, to a certain degree, to the lower extremities; that it might even happen that it would again be possible for the patient to stand and to walk with the assistance of a proper apparatus; that, finally, a return of aggressive symptoms was scarcely to be apprehended.¹

The subsequent history of the case shows that these previsions were fulfilled. A note, taken in February, 1874, states, in fact, that a very remarkable improvement had taken place as regards the

¹ I am informed by my colleague, Dr. Bouvier, who has had great experience in this matter, that only thrice in the course of his long career has he seen the normal retrocession of the symptoms of infantile spinal paralysis impeded by a relapse.

power of motion, and nutrition of the upper extremities; with respect to the inferior extremities, faradaic contractility begins to reappear in several muscles where it had been either greatly weakened, or abolished. On the other hand, on account of the predominant action of the posterior muscles of the thigh and those of the calves, a tendency to flexion of the legs has occurred, and to the formation of equinus club-feet, against which different appliances have been tried.

In April, muscular strength had made such progress, in the lower extremities, that the patient was able to stand and walk a few steps in his room, with the help of two assistants.

Finally, in August, about a year after the invasion, he can, when sitting, rise up without assistance; and, with the help of a pair of crutches, he takes short walks. He can even walk a little, leaning on a cane only, by using an apparatus which hinders flexion of the left knee.¹

The following case, although less regular in some respects than the foregoing, deserves, however, to be compared with it. It may be approximated to those *temporary paralyses*, described by Kennedy, the history of which cannot be severed from that of *permanent infantile paralysis*.

CASE 2.—Charles R—, at present aged fifteen years and a half, is a tall, well-made youth, of an intelligent appearance. In his antecedents, no disease worth notice is found; no convulsions. He has neither experienced any severe moral emotion, nor received a chill. We are only told that he has grown much, in a very short space of time.

On the 27th September, 1873, he was taken with a fever of slight intensity, which did not oblige him to take to his bed. His appetite, however, was gone; the tongue was loaded. The febrile state

¹ During the period, extending from the 19th of August, 1873, to January 1st, 1874, the treatment consisted principally in the application of cupping with scarification, of blisters, and then of the actual cautery along the vertebral column. From the last-mentioned date, the paralysed or wasted muscles were, every second day, subjected to the stimulation of a faradaic current of medium intensity. In addition, X— took strychnine pills daily, each containing one milligram, which were gradually increased to fifteen. In April, May, and June, the galvanic stimulus and hydropathy were associated with faradisation; during the course of this period, especially, the most remarkable progress was made. In July and August, at Bagnères-de-Luchon, baths, douches, and energetic *massage* (kneading).

persisted, on the 28th and 29th, without being so strong as to hinder M. R— from remaining up, out of bed, a part of the day.

The only noticeable peculiarity, during this period of three days, was the appearance on the trunk of a *double zona*, traces of which are still to be seen (Nov., 1873). The eruption occupied the whole of the thorax, from top to bottom. *In front*, we saw; 1°, *on the right*, a first group of vesicles under the axilla; a second, also lateral, in the vicinity of the lower margin of the pectoralis major; a third, median, situated beneath the ensiform process; 2°, *on the left*, a group corresponding to the second right group, and another situated to the left of the median line, at an equal distance from the umbilicus and the lower extremity of the sternum. *Behind*, there existed a group on a level with the lower angle of the scapula; and a second, more lateral, nearly equi-distant from the latter, and the crest of the ilium. It appears certain that this *zona* was not accompanied by any pains localised in the course of the nerves.

Without having experienced either pains or formication, on the 1st October, in the morning, whilst rising, and hardly out of bed, Ch. R— felt his legs give way under him, and he fell heavily on the ground. Hence, it was during the night-time, between Sept. 30th and Oct. 1st, that the paraplegia took place. The patient was replaced in bed. It seems quite established that, on this day, he had no longer any fever. The paralysis was accompanied, from the outset, with marked flaccidness of the inferior extremities. Their cutaneous sensibility was never modified: it cannot be ascertained whether they were cold or cyanosed. Some partial movements have always persisted. Thus R— has always been able to extend and flex his toes; on the other hand, he was quite incapable of raising his legs completely from off the bed. It was stated that the emaciation of the thighs was already noticeable a few days after the invasion.

The upper extremities have not, at any time, been seriously involved, and R— has always been able to use his hands, either for taking food or to hold a book. No disorder has ever disturbed the regular exercise of the functions of bladder and rectum.

The period of retrocession began to set in a very short time after the invasion. Thus, towards the 15th day, R— could stand erect by resting his hands on adjacent objects.

The *actual condition*, noted the 17th Nov., 1873, gives us the

following:—R— can stand erect and even take some steps by leaning with both his hands on the shoulders of his servant. The inferior extremities are emaciated throughout, but the atrophy is particularly evident in the thighs which are flaccid, and, as it were, flattened from before backwards, whilst the calves are still rather full and firm. The muscles of the pelvis seem to be particularly attacked. Thus, when R— is seated he cannot flex the thighs upon the abdomen; he can hardly even make the attempt. When lying on his back, it is quite impossible for him to raise his trunk. When the patient, sustained in the upright position, endeavours with the help of an assistant to walk, he is seen at every step to roll (*hancher*) excessively, and to incline the trunk greatly first to one side, then to the other in succession. The general health remains always good.

We saw M. R— in October, 1874; the motions of the lower extremity have regained their normal strength, and he can now go through all bodily exercises without fatigue. A certain degree of comparative emaciation and of flaccidness of the anterior muscles of the left thigh, a marked tendency of the trunk to incline towards the right, whilst standing or walking, are at present the sole vestiges of the spinal disease.

The facts which have just been detailed, as examples, and which might easily be multiplied, will suffice, I hope, gentlemen, to render it evident that certain cases of acute spinal paralysis observed in the adult, are, from a clinical point of view, quite comparable to the spinal paralysis of young infants. It remains to be determined if, as seems probable, the spinal lesion, whence the symptomatic group results, acknowledges in the adult the strict localisation in the anterior cornua, and all the other characters which distinguish that of the child. Autopsy has not yet given its final decision. There is a void here which cannot fail soon to be filled.¹

¹ Clinically, the case published by my house-surgeon, M. Gombault, in the 'Archives de Physiologie,' Jan., 1873, p. 60, unquestionably approximates greatly to infantile spinal paralysis; it differs from it in some respects, however, from an anatomo-pathological point of view. The motor-cells were seriously altered in the regions of the spinal cord corresponding to the atrophied muscles; but, nowhere in the anterior cornua were limited foci observed, causing the disappearance of entire groups of nerve-cells, and producing fibroid thickening of the interstitial tissue, which appears to be a constant character of the spinal lesion proper to the atrophic paralysis of young infants.

II.

I think it useful to recur, to-day, to several points relative to the *pathological anatomy and physiology of infantile spinal paralysis*. I shall thus have an opportunity of noticing and making use of several works which have appeared upon this subject since the publication of the first investigations undertaken at La Salpêtrière. These first researches concerning the inmates of the asylum—persons, to wit, who had most frequently succumbed a very long time after the period of childhood—were unquestionably, on that account, made in comparatively unfavorable circumstances. They have, however, enabled us already to establish some fundamental data which later investigations, carried on under happier conditions, namely, in young subjects who had died at a period contiguous to the invasion of the disease, have completed in some respects but have not essentially altered. This will be evident, I think, from the short account that follows.

1°. What especially characterises, anatomically, the spinal lesion of infantile paralysis is the strict systematic localisation of the alterations in the anterior cornua of the grey substance, and, more particularly, in the region of the cornua occupied by the great ganglionic cells, which are called motor. Nothing, up to the present, has been found to contradict this proposition, established from the beginning of our researches.¹

The alteration in question, and on this point we have not failed to lay stress, shows itself occasionally exactly confined to only one or two of the distinctly circumscribed oval groups which, as for instance in the lumbar enlargement, are constituted by these cells associating together (fig. 10). Those are, so to say, the primary foci of the affection, for, if the lesion extend beyond, it appears to radiate around the cell-groups as around a centre. Only when the alteration is most intense, and then merely here and there in a few places, the grey cornu is invaded throughout its whole extent transversely (fig. 9). It is the rule, in such cases, that the white columns, especially the anterior and lateral columns, shall present in the region where the grey cornu is so gravely attacked, a kind of

¹ These views concerning the part played by the alteration of nerve-cells in the anterior cornua in the pathogeny of infantile paralysis and progressive spinal amyotrophies were detailed in a lecture delivered by me at the Salpêtrière in June, 1868.

emaciation, of atrophy, with more or less marked decrease in every diameter; but this evidently secondary lesion of the white columns is not necessary. It may be deficient (fig. 9), and cannot, therefore, take its place in the front rank among the characteristics of the spinal lesion peculiar to infantile paralysis.

The very remarkable localisation of the lesions in the area of the cell-group has long led me to admit, as a probable hypothesis, that the morbid process first occupies the nerve-cell, extending afterwards to the neuroglia. How, in fact, is it possible otherwise to explain the very striking circumscription of the alteration to the immediate vicinity of the ganglionic elements? I am aware of no serious argument which has, till now, been advanced against this hypothesis.

2°. The lesion of the anterior horns, in cases of old standing, such as those which served for our researches, generally consists, so far as the nerve-cells are concerned, of a more or less advanced *sclerous atrophy*. The ganglionic elements of a whole group, or of a whole region, when the alteration is carried to its utmost, may even have disappeared altogether, leaving no trace. As to the neuroglia, it exhibits signs of connective hyperplasia with multiplication of nuclear elements and formation of fibroid tissue, often very dense—manifest evidences of the previous existence of irritative action.

Still, as we have mentioned elsewhere, the observations noted at the Salpêtrière had only allowed us to examine the remnants of a long extinct morbid process. In presence of the evidence which they furnished, we could only seek to construct, by a kind of exegesis, the first phases of the process. Undoubtedly, the lesions of the neuroglia presented us with incontestable traces of their inflammatory origin. But had there been here at work, formerly, a *hyperplastic myelitis without dissociation of tissue*; or, on the contrary, a *destructive myelitis, with softening*? The problem was one almost impossible of solution.

Here chiefly lies the interest of the important observations of MM. Damaschino and Roger.¹ These authors have had occasion to make a post-mortem examination in the case of two children who succumbed, one two months, and the other six months, after the outbreak of the disease, and they have remarked in both cases that, in the most seriously altered parts of the cord, the lesions

¹ Loc. cit.

(localised according to rule in one of the grey anterior cornua) consisted of *red inflammatory ramollissement* with vascular injection, production of granular bodies, &c. Above and below these points the alteration could still be followed for a certain distance in the grey substance, but gradually lessening it shortly was only represented by the multiplication of nuclear elements, and by a vascular injection which was especially evident in the immediate vicinity of the groups of nerve-cells.

These observations establish, as may be seen, that red ramollissement must be enumerated among the spinal lesions of infantile paralysis. But nothing has hitherto demonstrated that this is an obligatory accompaniment. It is even highly probable that, just as sometimes happens in common central acute myelitis, the alterations of the spinal cord in infantile paralysis may reach their greatest intensity, and even determine the gravest trophic muscular lesions at the periphery, without the occurrence of dissociation of connective and nerve elements, otherwise called ramollissement.¹

Another interesting fact, rendered evident by the observations of MM. Roger and Damaschino, is this, namely, that the alteration of the nerve-cells is marked by atrophy, with excessive pigmentation of these elements. The sclerous lesion, mentioned in our own observations, would therefore be a subsequent phenomenon.²

¹ Charcot, 'Archives de Physiologie,' 1872; Janvier-Fevrier; Hayem, *idem*, 1874, p. 603.

² This is the place to recall the principal modes of alteration to which the nerve-cells of the grey anterior cornua of the spinal cord are susceptible.

1°. I would, first, mention the often enormous tumefaction which these cells occasionally undergo, and which I believe I was the first to recognise, so far, at least as the cord is concerned (Soc. de Biologie, 1872). The body, voluminous and as if swollen, is at once turbid and opalescent. The prolongations are thicker than in the natural state, and seemingly writen. I have compared this alteration of the nerve-cells of the spinal cord to the hypertrophy which, under the influence of certain irritative processes, is presented by the axis cylinder, either in the cerebro-spinal centre or in the peripheral nerves (Fig. 10, B).

2°. Some authors have described, in the nerve-cells of the encephalon, a multiplication of nuclei (Jolly) which they regard as the sign of an irritative process. M. Leyden states that he remarked the same thing with respect to the ganglionic cells of the cord. But, it is important to observe that, in certain regions of the encephalon, and in the great sympathetic system, the presence of two nuclei in a nerve-cell is a fact, one which is undoubtedly rare, but which yet is seen under normal conditions, irrespective of any trace of irritative action; no proliferation of the nerve-cell, for instance, is observed corre-

3° The spinal lesion, whose principal features have just been sketched, is constant in infantile paralysis; that is a fundamental fact which I have already intimated in my lectures of 1868, and corresponding to the proliferation of the cellular elements of the connective tissue. In short, the different alterations which the cells undergo owing to inflammation, besides the tumefaction mentioned above, are all, anatomically speaking, atrophic or degenerative (Fig. 11, C, D, E).

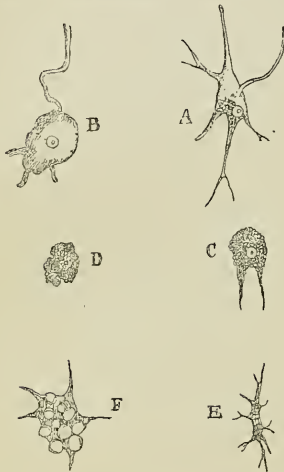


FIG. 11.—Nerve-cells of the anterior cornua of the spinal cord.

- A. Normal state.
- B. Hypertrophic state.
- C. Pigmentary alteration.
- D. Last stage of pigmentary change.
- E. Cell stricken with sclerous atrophy.
- F. Vacuolar alteration.

3°. I will mention, in passing, the alteration, termed *vacuolar*, of the nerve-cells of the anterior cornua. I have oft times met with it in cases where the neuroglia presented unequivocal signs of inflammation in the neighbourhood. I have not yet been able to convince myself that this alteration is not an artificial product (Fig. 11, F).

4°. I will dwell, at more length, on the *alteration of the spinal nerve-cells*, known as *pigmentary*. It is a normal fact, so to speak, that in old age these cells shall be filled and distended by an often enormous quantity of pigment. Is this a fact of no consequence whatever as regards functional exercise? Should we not rather attribute, partially at least, to this senile modification of the cell the motor enfeeblement and the alterations of the muscles of the limbs which show themselves, as it were necessarily, at a certain period of life?

However this be, the accumulation of pigment in a spinal nerve-cell is not sufficient in itself, whatever its intensity, to characterise a profound lesion of the organism. But there is superadded in pathological cases proper, a genuine *atrophy*, whose phases have been well described by L. Clarke. In the first degree of this alteration, the cell diminishes in volume, and the transparent part of the body becomes more and more reduced; in the second, the prolongations atrophy in their turn, whilst the body assumes a globular form; soon after the prolongations are only represented by short slender filaments. Finally, they disappear, in the last stage. Concomitantly, the nucleus of the

which all the observations since published in France or abroad, and they are numerous to-day, go to confirm. Amongst these corroborating observations, to mention only the most recent, I would cite those which have been published in Germany by HH. Recklinghausen, Rosenthal (of Vienna), and Roth (of Bâle).¹

I strove, in addition, at that period, to establish that the lesion in question ought to be considered as an initial, primary lesion, dominating, as it were, the whole morbid drama. It could not, in fact, be admitted that it was a consequence of the functional inertia of the members stricken with paralysis; for it has nothing in common with the peculiar alteration of the spinal cord, which supervenes after amputations of old standing, and which had already been very thoroughly studied by MM. Clarke, Vulpian, and Dickinson.² Again, the hypothesis which would place the starting point of the phenomena at the periphery, either in the muscles or in the nerves, would be very complicated, embarrassed, and unsupported by analogy; whilst the opposite hypothesis, on the contrary, besides the support it derives from the history of common central acute myelitis also counts the results of experimentation upon animals on its side. For, by this method, M. Prevost has shown that a lesion affecting the central parts of the cord determines muscular lesions very similar to those which are observed in the paralysis of young children.³

The opinion which I endeavoured formerly to advance has not, cell becomes atrophied. This *pigmentary atrophy*, which conduces to the entire destruction of the cell, is seen in connection with irritative processes, primarily developed in the adjacent neuroglia; or else, it exists in an isolated fashion, independent of any lesion of the neuroglia, as, for instance, in certain forms of progressive muscular atrophy or of bulbar paralysis (fig. 11, c, d).

5°. Finally, a last form of alteration of the motor nerve-cell is that sometimes designated by the name of *sclerosis* or *sclerous atrophy*. The cell is diminished in volume, sometimes to a considerable extent. It is shrunken, as it were, and more or less rounded; or, on the contrary, lengthened out. The prolongations are short, dried up, or absent. The cell-body is opaque, brilliant; the nucleus is small, irregular, and shrunken. I am not aware if this alteration is always preceded by the lesions of pigmentary atrophy, or if it may be primary. It is frequently met with in cases of spinal amyotrophy connected with a well-marked irritative process (fig. 11, e) ('Cours de la Faculté,' 1874).

¹ Roth, "Anatom. Befund bei spinaler Kinderlähmung," in Virchow's 'Archiv,' 1873, t. lviii, p. 273.

² Vulpian, 'Archives de Physiologie,' 1868, p. 443; *idem*, 1869, p. 675.

³ Prevost, 'Société de Biologie,' séance du 14, avril, 1872.

as you perceive, met with any serious objection; it appears, in fact, to be rather generally disseminated at present. Consequently, I believe that, in accordance with this, I can keep to the theory which I at the time proposed in reference to the concatenation of phenomena. The nerve-cells are, *ex hypothesi*, the primary seat and starting point of the irritative process, and there we find produced an *acute anterior parenchymatous tephro-myelitis*.¹ The process rapidly spreads, bit by bit, to the adjacent connective tissue, without, however, exceeding the limits of the area of the anterior cornua. Whilst, under the influence of this morbid incitation, the cell passes through the different phases of atrophy capable of issuing in complete destruction, the neuroglia itself reacts after its manner, and becomes inflamed. The phlegmasic action may here, in the most altered points, proceed even to the formation of a focus of red softening.

However this may be, to these abruptly developed alterations all the phenomena of the disease are attached; namely, first, the initial febrile action, then the whole series of symptoms which soon succeed. Motor paralysis, marked by suppression of muscular tone and of the other modes of reflex activity, may be considered, according to the physiological view, at present prevalent as a very simple consequence of the disorganisation from which the apparatus of motor nerve-cells is suffering. From this same lesion of the ganglionic elements are also certainly derived the rapid atrophy of the paralysed muscles, and the modifications of electric contractility which form its prelude; but the pathogenetic modus which should be here arraigned is not yet well known. It is readily admitted that the centrifugal nerves, which have their origin in the affected parts of the spinal cord, conduct themselves like the peripheral end of a divided nerve. They would undergo the several phases of destructive alteration (which MM. Neumann, Ranvier,² Vulpian, and Eichhorst³ have, in latter days, studied with such great care in connection with experimental nerve lesions), and the observed loss of

¹ H. Kussmaul has proposed the term *polio-myelitis anterior acutissima* to designate the spinal lesion of infantile paralysis (loc. cit., No. 1, p. 3). I believe *tephro-myelitis* is preferable, and, in reference to this subject, I can invoke the potent authority of M. Littré (*τέφρα, cinis*, Plut.—*τεφρᾶϊος, cinereus*, Ælian).

² Ranvier, 'Comptes-rendus de l'Académie des Sciences,' 1872, 1873.

³ Eichhorst, 'Virchow's Archiv,' 59 Bd., 1874.

faradaic contractility, as well as the atrophy of the muscular bundles, would supervene as a consequence. It must not be forgotten that this is as yet only an hypothesis, though it is, indeed, a highly plausible one; and it is important to remark, in particular, that the state of the peripheral nerves, in the first weeks which follow the invasion of infantile paralysis, has not yet been observed *de visu*.

As to the constantly noted absence of lasting disturbance of the cutaneous sensibility, of paralysis of the rectum or bladder, of cutaneous or visceral trophic disorders, this holds, as you know, an eminent position amongst the characteristics of infantile paralysis and it contributes largely to distinctly separate this affection from the different forms of *diffuse acute* myelitis. It is physiologically correlated to the strict localisation of the spinal lesion within the area of the anterior cornua of grey matter. Here, by the operation of the disease, in the central parts of the spinal cord, a delicate and always successful experiment is made, which demonstrates that the anterior grey cornua are not necessary to the transmission of sensory impressions, and that they have no direct influence over the motions of the bladder and rectum, nor upon the nutrition of the skin or of the genito-urinary organs.

III.

If the views which have just been detailed are sound, it should follow that every acute inflammatory lesion of the spinal cord, whatever may be its origin, would necessarily produce, like infantile paralysis, motor paralysis with rapid atrophy of the paralysed muscles, provided that the express condition, so often prominently put forward already, be here present, namely, *the acute atrophic lesion of the motor nerve-cells*. On the other hand, the phenomena to which I have just called attention, and which are regularly deficient in the symptomatology of infantile paralysis because of this very systematic circumscription of the alteration to the area of the anterior cornua,—these phenomena, I say, ought, on the contrary, to be met with in different degrees in all the other acute forms of the spinal affection, because they all acknowledge as their substratum lesions which are more or less diffused.

So, in reality, things do happen, as we find testified, for example, by the history of one of the commonest as well as one of the

gravest of spinal diseases of the adult. I refer to *generalised acute central myelitis*.¹ The lesion here is generally apparent to the naked eye as red ramollissement. But matters do not always proceed so far, and both the connective and nerve-elements may show themselves greatly altered, without having undergone dissociation.² However this be, it occupies the central regions of the spinal cord, especially the grey substance, and tends to invade a great portion of the height of the nerve-column; so that, for instance, the dorsal and lumbar region will be simultaneously attacked throughout their whole length. In the grey substance, it involves the anterior grey cornua, and consequently the motor cells, but it does not confine itself to this, for it attacks also the posterior grey cornua and the commissures. Finally, it likewise always spreads, here and there, irregularly over the different white columns.

The invasion takes place often abruptly and it may be marked, as in infantile paralysis, by a febrile state of more or less intensity. If the two affections be compared, with regard to local symptoms, it will be remarked that several are common to both. Others belong only to diffuse acute myelitis. The common symptoms are: motor paralysis with complete flaccidness; precocious diminution of faradaic contractility,—observed in several cases of myelitis from the first week;³ and, lastly, rapidly developed atrophy of the muscles. The theory would indicate that these depend on the alteration of the anterior grey cornua. On the other hand, new superadded symptoms only belonging to diffuse myelitis reveal the participation of other lesions of the cord. These are: more or less marked alterations of sensibility, and particularly a more or less intense cutaneous anæsthesia of the paralysed members; paralysis of the bladder and rectum; emission of alkaline, purulent urine; finally, the formation of bed-sores not only in the sacral region, but also over all points of the paralysed member subjected to pressure of some duration.

These bed-sores which, like the other phenomena already mentioned, are absolutely deficient in infantile paralysis, appear as a

¹ The vast alterations which may affect the muscles of the paralysed members in acute central myelitis have been already pointed out by Rokitsansky ('Lehrb. des Path. Anat.,' 1e Bd., 1855, p. 329; 2e Bd., 1856, p. 228).

² See my observations on the histology of acute myelitis ('Archives de Physiologie,' 1872, Janv., Fev.) and those of M. Hayem on the same subject, (*idem*, 1874, p. 603).

³ Observations of H. Mannkopf, 'Amtlich. Bericht über die Versammlung Deutsch Naturforscher und Aerzte zu Hannover,' p. 251, 1866.

common fact in acute generalised myelitis. It is known that they are produced, with singular rapidity, four, six, or ten days after the invasion of the first symptoms, and that they contribute powerfully to determine the fatal issue.

Hæmatomyelia or, in other words, *intra-spinal hæmorrhage*, is open to similar comment. In a number of cases, in fact, its symptomatic history fuses, in all points, as it were, with that of acute generalised myelitis. Thus, to mention merely the faradaic contractility, this has been seen to disappear on the 14th,¹ and on the 9th day;² and, again, large bedsores often rapidly show themselves on the nates. Intra-spinal hæmorrhages, as M. Hayem³ and I, myself,⁴ have striven to establish would, in fact, appear to be only a kind of epiphenomenon of acute central myelitis. It seems certain that, almost always, the effusion of blood takes place there in the midst of parts previously modified in structure owing to the presence of inflammation.

Traumatic lesions of the spinal cord, whether they result from fracture of the vertebral column or from a wound dealt with a sharp instrument, may also determine the occurrence of acute amyotrophy with all its accompaniments, in a word, the formation of bedsores of rapid development. The spinal changes, in cases of traumatic injuries are, at least at first, those of acute transverse myelitis: that is, we shall have inflammatory lesions which, involving both the grey axis and the white columns, only occupy a small extent of the cord, in height. But they often extend very rapidly beneath the point primarily affected, down to the extremity of the lumbar enlargement, for instance, if the lesion have affected a point in the dorsal region. The extension in question takes place in the white column, according to a well known law, along the lateral fascicles; whilst in the grey substance, the parts affected are the columns formed by the anterior cornua. This descending extension of transverse spinal lesions is not a mere supposition or view; I have quite recently observed it distinctly on examining sections taken from a case of acute transverse myelitis, to which I shall again refer. This alone enables us to understand, as I have else-

¹ Observation of Levier, 'Beiträge zur Pathologie der Rückenmarks Apoplexie,' "Inaug. Dis.," Bern, 1864.

² Observation of Duriau, 'Union Médicale,' 1859, t. i, p. 308.

³ Hayem, 'Des Hémorrhagies intra-rachidiennes,' 1872, p. 138.

⁴ Charcot, 'Leçons de la Salpêtrière,' 1870.

where pointed out,¹ how a spinal lesion apparently limited to a circumscribed part of the dorsal region may determine, in the motor-paralysed lower extremities, acute atrophy of the muscles and, in a word, all the phenomena which derive, as the physiological analysis of infantile paralysis proves, from acute atrophy of the motor nerve-cells.

¹ Charcot, 'Lectures on Diseases of the Nervous System,' vol. i, p. 51, note ¹.

LECTURE XI.

CHRONIC SPINAL AMYOTROPHIES. PROTOPATHIC SPINAL PROGRESSIVE MUSCULAR ATROPHY (DUCHENNE-ARAN TYPE).

SUMMARY.—*Clinical varieties of cases designated under the name of progressive muscular atrophy (spinal progressive muscular atrophies). Uniformity, in these cases, of the spinal lesion which affects the anterior cornua of the grey substance.*

Study of protopathic spinal progressive muscular atrophy as typical of the group: simple spinal lesion. Chronic deuteropathic spinal amyotrophies. The lesion of motor nerve-cells is here consecutive; it is superadded to a spinal lesion of variable position. Account of the principal spinal affections which may produce deuteropathic progressive amyotrophy: hypertrophic spinal pachymeningitis; sclerosis of posterior columns; chronic central myelitis; hydromyelia; intra-spinal tumours; disseminated sclerosis; symmetrical lateral sclerosis.

On protopathic spinal progressive muscular atrophy in particular (Duchenne-Aran type). Symptoms: individual atrophy of the muscles, functional disorders; prolonged persistence of faradaic contractility; fibrillary tremors; paralytic deformations, or deviations, "griffes." Modes of invasion. Etiology: hereditary transmission, cold, traumatic injuries.

Pathological anatomy. Lesions of the cord; alteration limited to the anterior cornua of the grey substance (nerve-cells, neuroglia). Lesions of the nerve-roots and of the peripheral nerves. Muscular lesions and their nature.

I.

GENTLEMEN,—I propose, in the lectures which are to follow, to devote some discussion to the history of *chronic spinal amyotrophies*.

The affections comprised under this designation are, even yet, often confounded, in practice, under the common name of *progressive muscular atrophy*. Pathological anatomy, however, has long since established that we have here no homogeneous group.

In reality, the spinal lesions which are to be met with in cases which, in practice, receive this name of progressive muscular atrophy are very various. They possess, however, in common, a peculiar feature, which constitutes, as it were, the fundamental anatomical character of the group; this is, the lesion of the anterior cornua of the grey substance, and, to be more explicit, the atrophic alteration of the motor cells of the region. We find here, in some degree, the reproduction of what we saw in connection with acute spinal amyotrophies. The spinal lesion, however, in the cases which are about to engage our attention is no longer evolved after the acute mode, but, on the contrary, proceeds in a chronic subacute manner, and to this circumstance are due the considerable differences which, in spite of more than one analogy, are observable in the succession of symptoms.

A. You doubtless remember, gentlemen, that, in studying acute spinal amyotrophies, we took as our objective point a regular type, namely, *infantile paralysis*, where the spinal lesions are systematically limited to the anterior cornua of the grey substance. A type of the same kind shall serve as our guide in the history of chronic spinal amyotrophies. In reality, a lesion exactly limited to the anterior regions of the grey matter, and leaving perfectly intact all the other, white and grey, substance of the spinal cord, constitutes the anatomical substratum in a certain form of progressive muscular atrophy which nearly corresponds clinically to the common type, as described by Cruveilhier, Duchenne (de Boulogne), Aran, and which, with your permission, we shall qualify as *protopathic spinal*.

The constitution of this protopathic form of spinal muscular atrophy, which in some sort, I repeat, reproduces infantile paralysis in a chronic guise, is comparatively very simple. Thus, the anatomo-pathological element is represented:

1°. In the cord, by a lesion systematically limited to the grey anterior cornua; the alteration of the great nerve cells being likewise a necessary condition, *sine quâ non*, and sometimes the only observable lesion; 2°, in the motor roots and peripheral motor nerves, by a more or less marked atrophy, as a consequence of the

spinal lesion; 3°, lastly, in the corresponding muscles, by trophic lesions which we shall have to pass in review, and whence proceeds, properly speaking, the entire symptomatology of the affection.

B. Matters are more complicated in a second group of chronic spinal amyotrophies, which, by way of distinction, I shall designate by the name of *deuteropathic*. Here, indeed, the lesion of the anterior cornua and of the nerve-cells is necessarily present also; but it is only second in date, and consecutive in all cases. The original lesion still occupies the spinal cord, but it is developed exteriorly to the grey substance, and it is only secondarily and by extension that the latter has been invaded in its turn. When this invasion has taken place, then, indeed, the same series of consecutive phenomena follows from it, and progressive atrophy of the muscles in particular; however, the amyotrophic symptoms are now found to be intermingled with, or rather superadded to, those of the primary spinal disease. Now you will readily comprehend, gentlemen, how complex and variable may appear the symptomatic group which is observable under these different combinations. For, in fact, there is probably not one chronic elementary lesion of the cord which is not susceptible, at a given period of its evolution, of reacting on the anterior grey substance, and causing atrophy of its motor cells.

To speak only of cases in which an anatomical verification was made, the following is a statement of the chief forms of disease of the spinal cord which may give rise to chronic deuteropathic spinal amyotrophy:

1°. In the first place, I will mention *hypertrophic spinal pachymeningitis*. It consists, as we will see, in an inflammation of the meninges which especially occupies the cervical enlargement of the cord and which unquestionably corresponds to what was formerly called *hypertrophy of the spinal cord*. The meningeal lesion is propagated to the cord itself and, simultaneously, to the origin of the rachidian nerves. The muscular atrophy of the upper extremities is developed under this double influence; it exhibits itself in combination with peculiar symptoms which are due to the meningeal lesion, the spinal lesion, and the lesion of the peripheral nerves.

2°. Next comes *sclerosis of the posterior radicular zones*, the anatomical substratum of progressive locomotor ataxia.¹ The sym-

¹ See Lecture I, p. 11.

ptomatology would here be composed of phenomena connected with consecutive atrophy of the anterior cornua,—slow atrophy of the muscles,—and of those which characterise sclerosis of the posterior radicular zones, special fulgurant pains, motor incoördination, &c.

3°. Different types of *central myelitis*, spontaneous or traumatic, having a chronic course, should be included in this enumeration; an anatomical lesion which is commonly designated under the name of *hydromyelia* or *hydromyelitis*, deserves special mention.¹

Some authors describe this spinal alteration as resulting from a

¹ This spinal lesion has been designated by Ollivier (d'Angers) under the name of *syngomyelia* or *central cavity in the spinal cord* ('*Traité des maladies de la moelle épinière*, 3e édit, 1837, t. 1, p. 202). I have published a case of cervical spinal myelitis with pachymeningitis, remarkable amongst others on account of the presence of three long and narrow canals which, excavated for the most part in the substance of the grey matter, traversed the cervical enlargement throughout its whole extent in a direction parallel to the long axis of the cord. One, and the most considerable, of these canals might even be followed to a level with the inferior third of the dorsal region. In the greater portion of its course it occupied the posterior grey cornu of the left side, or rather it had taken the place of this grey cornu, the several elements of which had disappeared. Of the two other canals, smaller in size, one occupied a position immediately behind the posterior commissure, on the median line, so as to involve both posterior white columns at the same time; whilst the other ran partly in the right posterior cornu, and partly in the posterior column of the right side. The latter canals were found mostly filled by an amorphous, transparent, finely-granulated substance, which, in certain points, had become disintegrated, probably owing to some accident in preparing the section, and had left in its place more or less extensive lacunæ, with more or less irregular borders. This same finely-granular substance, slightly condensed, formed the parietes of the foci and, without any well-marked line of demarcation, became continuous with the adjacent tissue which itself, for some distance, presented the characters of granular degeneration. This case, which appears in a memoir, published in common with M. Joffroy, then my clinical clerk ('*Archives de Physiologie*, Mai, Sept., Nov., 1869), made it already seem highly probable that a certain number of cases of *hydromyelia* till then rather commonly referred to a dilatation of the central canal, might result from the melting down of a pathological tissue, developed in the midst of the central portions of the spinal cord. The reality of the fact seems to me to have been placed beyond question by M. Hallopeau in an interesting work presented to the *Société de Biologie* ('*Mémoires de la Société de Biologie*, 1869). Quite recently, Dr. Th. Simon (of Hamburg) has collected a large number of cases ('*Arch. für Psychiatrie und Nervenkrankheit*, v Bd., 1 Heft, Berlin, 1874, p. 120, *et seq.*) which go to confirm, as regards this subject, the conclusions drawn in the French works.

dilatation of the central canal of the spinal cord. It is certain that in the majority of cases, we have to deal with channelled foci, consecutive on chronic central myelitis. However it be, the grey substance of the anterior cornua may, in similar circumstances, be involved to such an extent, that the motor nerve cells undergo more or less grave alterations and, owing to this fact, muscular atrophy, having a progressive course, will take its place in the symptomatology of the disease.¹

4° There also exist several examples of *intra-spinal tumours* (gliomata or sarcomata), which, developed in the centre of the grey substance, in the cervical region, have formed the starting-point of symptoms of progressive amyotrophy.²

5°. We should also mention *disseminated sclerosis*. Generally speaking, in ordinary cases of this disease, the grey substance is not gravely affected; that, however, may possibly occur, and then progressive amyotrophies would present themselves, in addition to the already very varied symptoms of multilocular induration of the nerve centres.

6°. But the pathological form which I wish particularly to notice, amongst these chronic deuteropathic spinal amyotrophies, is one which is characterised anatomically by a *sclerosis which symmetrically affects the lateral columns of the spinal cord* throughout its whole length. This fasciculated sclerosis may even be followed, as we shall show, into the bulbus and the protuberantia.

Symmetrical lateral fasciculated sclerosis may be met with, separately, irrespective of any lesion of the grey axis. But very frequently it reacts upon the anterior cornua of the grey substance, and more particularly on the nerve-cells of the region, in consequence of which amyotrophic symptoms are superadded to those which depend on lateral sclerosis.

In all the cases comprised within this enumeration the invasion of the anterior grey substance, as we have pointed out, is constantly a consecutive phenomenon. It is possible that the inverse combination may supervene, namely, that a lesion, primarily developed

¹ See, amongst others, the case of H. O. Schuppel, "Ueber Hydromyelus," in 'Archiv der Heilkunde,' Leipzig, 1865, p. 289.

² O. Schuppel, "Das gliom und gliomyxom des Rückenmarkes," in 'Arch. der Heilkunde,' p. 127, 1867; J. Grimm, "Atrophia musculorum progressiva, tumor carcinomatosus intumescentiæ spinalis," in 'Virchow's Archiv,' 4 faeg, 8 Bd.

in the grey centre, may subsequently invade the white columns; but I do not believe that, up to the present, this combination has been regularly observed.

II.

Gentlemen, as I stated to you at the outset, it is, first of all, *protopathic spinal progressive amyotrophy*, defined as you have just heard, which we are about to study in this lecture. When this comparatively simple type is known to you it will be more easy for you to penetrate into the history of the deuteropathic spinal amyotrophies, which is still rather a tangled one.

We will endeavour to separate the description of *protopathic muscular atrophy*, as much as possible, from all the foreign elements which encumber it in the pages of most authors. In doing so, we shall follow the example of Dr. Duchenne (de Boulogne), who has long since begun this work of purification, taking up his position at a clinical standing point especially. The signals, established by that author along the road which he has already travelled, shall more than once serve to guide us in accomplishing the task which we are about to undertake.¹

A. We will begin our account by taking first the clinical side; after which we will descend into the details of the anatomical lesion, and, finally, by way of conclusion, we will offer some considerations in relation to the pathological physiology of the affection.

a. The first feature to notice in the symptomatology of progressive muscular atrophy, after the insidious invasion, without forewarning symptoms, or with long unnoticed prodromes, so to say, is what may be called the *individual atrophy* which the affected muscles undergo; in other words, one or several muscles of a member may have suffered a very remarkable decrease of volume, whilst the adjoining muscles have preserved their normal prominence.

This first feature is in some sort characteristic; it is, writes M. Duchenne (de Boulogne), "the facies of the disease." Let us exactly realise the matter by appealing to a concrete example. Let us suppose a case, one very common in this order, in which the disease shall as yet have invaded but a certain number of muscles in an upper extremity. All the muscles of the hand and of the

¹ See 'Traité de l'Electrothérapie localisée.'—Ch. v.

forearm shall have undergone intense atrophy, I will suppose, with the exception of perhaps one only—the supinator longus, for instance. On the other hand, the muscles of the arm and of the shoulder will be untouched and present their normal volume, so as to form a striking contrast with the intense atrophy of the hand and forearm.

Let us take another and a rarer instance. In this case it shall be the thoracic muscles which have been first affected. The pectorals will be intensely wasted, and, consequently, the chest will have suffered extreme emaciation, whilst the upper extremities, having been entirely spared, will present a comparatively considerable prominence. This mode of invasion of the atrophy, which advances to a certain extent *muscle by muscle*, furnishes an important character, because it is met with again, to the same degree, in deuteropathic amyotrophies.

b. The *functional disorders* represented by the muscle, when atrophying, should arrest our attention. With decrease in volume is connected a certain degree of *enfeeblement of the movements* executed by the muscle, and we may say that these two phenomena advance in parallel lines. In other words, the fewer muscular fibres there are in a muscle, or the more its fibres are atrophied, the greater will be the debility, and this appears hardly to depend on anything else than on the decrease in the number, or more or less marked atrophy of the muscular bundles.

This fact contrasts with what we know in relation to *paralysis properly so called*, or *by default of nerve action*. Take, for instance, a paralysis of the lower extremities caused by compression, bearing on a limited point of the spinal cord in the dorsal region; the motor inertia occasioned in the inferior limbs by the suppression of cerebral action may be complete, absolute, and yet the muscles, in such a case, will not suffer at all in their nutrition, or only suffer in the long run, owing to the fact of their prolonged inaction.

In deuteropathic spinal amyotrophies, on account of the habitual combination of a lesion of the white columns with the lesion of the grey substance, it is the rule that a more or less marked degree of paralysis, by suppression of nerve action, shall be superadded to the effects of the amyotrophy, which does not take place, at least not to the same extent, in protopathic amyotrophy where the grey substance is alone affected.

c. Another fact worthy of notice is the following: the muscle,

even when it has reached an advanced degree of atrophy, preserves its normal faradaic contractility. The diminution or abolition of this contractility only shows itself in the ultimate phases, when the atrophy has attained its climax. This is a character which contrasts considerably with what we know of acute spinal amyotrophies where, from an early date, and even before the mass of the muscle has betrayed by its change a noticeable alteration, the faradaic contractility has already been remarkably modified.

d. It is important not to forget, in the description, the *fibrillary quivering*. This quivering is spontaneously produced, but we may often provoke its appearance by means of a slight shock given to the muscle. It consists, allow me to remind you, in this, namely, that the skin covering the affected muscle, appears suddenly raised by very fine little strings, which stretch in the direction of the principal muscular fascicles. Sometimes quite partial and localised, they are occasionally energetic enough to move the finger, or even the hand. These fibrillary movements do not peculiarly belong to the protopathic form. I will add, also, that they are to be met with, beyond the limits of progressive muscular atrophy, in healthy subjects. They occasionally constitute, in this case, one of the symptoms of a particular form of hypochondria which, be it said in passing, is somewhat frequent amongst medical students.

e. I ought to point out, but only in order to eliminate them from the picture, some other symptoms which in my opinion, have been wrongly included in the description of common muscular atrophy. The spontaneous (continued and neuralgic) pains, the fulgurant paroxysmal pains, mentioned by some authors, belong to the deutero-pathic forms (posterior sclerosis, lateral symmetrical sclerosis, pachymeningitis).

I will say as much of the cutaneous anæsthesia and hyperæsthesia. They are foreign to simple atrophy. The same statement holds good, according to my experience, with respect to the pains, provoked by pressure, which betray an exaltation of the sensibility of the muscular masses.

f. Lastly, I should include in the symptomatology of protopathic spinal atrophy the *deformations* or rather the *deviations* which, necessarily, result from the weakening of the wasted muscles and the predominance which the antagonist muscles consequently assume. Thus is produced, to mention merely the hands, the

various deformations which are known by the name of “*griffes*,” (claws or talons).

In short, we have here *paralytic deviations* which must not be confounded with deformations due to *contracture*, which show themselves in certain deuteropathic forms and there perform an interesting part as may be seen, to take one instance, in lateral amyotrophic sclerosis.

B. After this enumeration of the symptoms which are observed in each of the affected muscles, considered separately, we should fix our attention on some characters drawn from the mode of progression and distribution which is presented by the muscular lesions in their successive invasions. In this order, we have to point out a certain number of phenomena of incontestable utility for nosographic differentiation :

1°. In the immense majority of cases, protopathic spinal progressive amyotrophy begins by one of the upper extremities ; it commences with the hand and ascends the forearm, the arm, the shoulder, gaining then the trunk. As a rule, a fact which I ask you to remark particularly as we shall utilise it presently, it only extends to the inferior extremities when the disease has reached its ultimate limits. I have oft-times shown you, in this asylum, patients stricken with protopathic muscular atrophy of long standing, whose upper extremities, and thorax as well, were reduced to a skeleton ; whilst the lower extremities, either not at all or but little affected, permitted the patient to stand and to walk, nearly as in the normal condition.

2°. Primary invasion of the trunk is far more rare. Dr. Duchenne has noted it in a dozen of cases only : the upper extremities are here attacked subsequently.

3°. Finally, it is proper to mention, as a most exceptional mode of invasion, one which is very rare in common atrophy (the converse will be seen in some deuteropathic atrophies), that mode in which the muscles of the inferior extremities are taken before all the others. Dr. Duchenne says that he has not observed this mode of invasion except twice in 159 cases. Mr. Hammond,¹ indeed, in a recent treatise declares that he has seen it 8 times in 29 ; but, if I am to judge by one of the examples which he relates, the cases which have served for these statistics deviate sin-

¹ W. A. Hammond, ‘A Treatise on Diseases of the Nervous System,’ p. 666, fig. 31, New York.

gularly from the classic type. The case to which I refer relates to a man who, after having experienced some disorder of vision, and suffered, for a long time, from formications as well as pains ("electric pains") in the lower extremities, presented a growing progressive atrophy of the muscles of these members, which had wasted them to a considerable extent. This atrophy of the muscular masses, great as it was, did not absolutely hinder the patient from standing and walking. I cannot refrain from seeing, in this case, an example of locomotor ataxia; it is known that, in this affection, progressive atrophy of the members, stricken with motor incoördination, is not a very rare complication.

c. It may be asserted that, under ordinary conditions, the course of the disease is a very slow one; it is the exception when prematurely invading the muscles which serve for the work of respiration (intercostals or diaphragm), or attacking the bulbar nerves (a combination which shall be specially discussed), the disease runs to a close in from two to five years. Usually, I repeat true atrophy lasts eight or ten years, in its partial form, and even eighteen or twenty years when it has been long generalised over all the muscles.

d. One word now with respect to its *etiology*. What has been written in reference to *consanguinity* or *heredity*, considered as an element in etiology, seems to me, judging from a critical examination of the texts, to apply to protopathic spinal amyotrophy. The latter, I should add, is rarely affiliated to *occasional causes*.

The *spinal amyotrophies* which are called rheumatic, because they appear to have been caused by the influence of cold are, if I am not mistaken, referable to chronic myelitis, pachymeningitis, or lateral sclerosis.

Those which supervene in consequence of a *traumatic cause*, such as a blow on the back, as in a case related by Dr. Gull,¹ or from carrying too heavy a bale of cotton, as in the case of Dr. Robert's patient, &c., are probably also connected with myelitis.²

¹ W. Gull, "Progressive Atrophy of the Muscles of the Trunk and Upper Extremities, after a blow on the neck with the fist," in 'Guy's Hosp. Reports,' 1858, p. 195.

² W. Roberts, Art. "Wasting Palsy," in 'Reynolds' System of Medicine,' p. 168. Other examples of progressive atrophy of muscles, supervening on injuries, are mentioned by Bergmann, 'St. Peterbourger Med.-Zeitsch.,' p. 116, 1864. Thudichum und Lockhart Clarke ('Beale's Archives of Médecine,' 1863).

But, so far as primary atrophy is concerned, the etiologic rôle of hereditary transmission appears to be a very important one. It has been noticed by all authors, and recently H. Naűnyn, Professor at Königsberg, narrated the history of a family in which the transmission of the disease could be traced through five generations.¹

III.

In an account, which is chiefly concerned with rendering evident some fundamental nosographical characters, enough has been said, gentlemen, with reference to the clinical aspect of the question. We have collected, on our way, materials the utility of which may not strike the eye at the first glance, but this will appear in its fulness when, in a few minutes, we shall have to show how deutero-pathic amyotrophies are distinguishable from protopathic amyotrophy, not only anatomically, but also by the entire array of other pathological characters.

At present, it is proper to make you acquainted with what is known as regards the *pathological anatomy* of protopathic spinal progressive amyotrophy.

1°. We will commence by what relates to the *cord*. The lesion in question, necessarily affects the great motor cells.

The neuroglia itself may also be attacked, but, in such circumstances, the alteration remains systematically circumscribed within the grey anterior cornua; the white columns are completely respected.

The lesion of the neuroglia is in its nature an inflammation; hence the vessels of the grey substance are larger than usual and their walls are thickened. The cellular elements of the connective matrix present evident traces of a process of proliferation. Granular bodies, in varying number, are met with in preparations made in the fresh state. When these alterations of the neuroglia are very marked the grey cornu may show a diminution in all its diameters (fig. 12, p. 174).

With respect to the nerve-cells, they exhibit sometimes the characteristics of pigmentary atrophy (fig. 11, C, D, p. 156), and sometimes those of sclerous atrophy (fig. 11, E, p. 156).

In short, we find here, in a chronic form, alterations which

¹ 'Berlin Klin. Wochenschr.,' No. 42, 1873.

we have described in connection with infantile paralysis; and there is reason to suppose that, as in the latter case, the limiting of the alterations to the anterior cornua of the grey substance is accounted for by the circumstance that the ganglionic elements are the primary seat of the affection¹.

Considered in reference to its anatomical characters, the

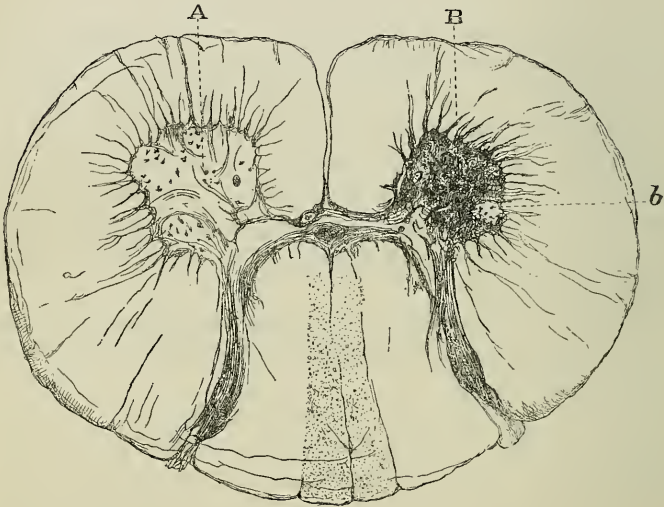


FIG. 12.—Section of the spinal cord in the cervical region in a case of protopathic muscular atrophy. A. Left anterior cornu (the nerve cells have persisted, but present signs of qualitative change). B. Right anterior cornu (almost complete atrophy of the nerve cells, only one small ganglionic nucleus (*b*) remains).

form of progressive muscular atrophy under discussion might be designated by the name of *chronic parenchymatous tephromyelitis*.

The observations on which the foregoing anatomico-pathological description is based, are not numerous as yet. There are only six or seven, we think, in existence. Amongst these we would mention a case described by Dr. Lockhart Clarke, another by M. Duménil,

¹ See Lecture IX, p. 139, and Lecture X, p. 153.

of Rouen,¹ a very important case by M. Hayem ;² three cases³ noted

¹ Unfortunately, in the cases of Lockhart Clarke and Duménil, the state of the white spinal substance is not explicitly indicated.

² Hayem, "Note sur un cas d'atrophie musculaire progressive, avec lésions de la moelle," 'Archives de Physiologie,' 1869, p. 79.

³ The following is a summary of two of these observations which will soon be published, *in extenso*, in the 'Archives de Physiologie.' The third has already appeared in its pages (1870, p. 247). I have given it as an example of glosso-laryngeal paralysis.

OBSERVATION I, noted by M. Gombault.—A Duc—, school-teacher, aged fifty-six, was received into Salpêtrière Hospital 24th June, 1872; died 26th Sept., same year. She suffered greatly from cold and fatigue during the siege. Attacked in April, 1871, by progressive weakening of the left upper extremity. Difficulty of speech occurring at nearly same epoch. No pains or contractures in the limbs. Present state in July, 1872: well-marked paralytic torticollis, with compensation curves in the remainder of the spinal column. Symptoms of labio-glosso-laryngeal paralysis, with manifest atrophy of the tongue. Well-marked difficulty in swallowing. The two *upper extremities*, the left especially, are hanging, inert, without contracture. Their muscular mass is wasted nearly uniformly throughout. Fibrillary contractions very evident. Faradaic contractility not changed. In the *hand*, almost complete disappearance of the thenar and hypothenar eminences. There is no "griffe" deformity. *Lower extremities* not atrophied; standing and walking were possible up to the last moment. Death rapid, owing to lobular pneumonia.

State of spinal cord on autopsy.—Cervical enlargement; in the fresh state, granular bodies exist in abundance within the area of the anterior cornua exclusively. The motor nerve-cells there present all possible degrees of pigmentary degeneration. On hardened sections same alteration of nerve-cells is found. Many of them are only represented by a globular mass of pigment. Numerous islets of *granular disintegration* within the area of the anterior cornua. *The white columns and the lateral columns in particular do not present the least trace of alteration.*

OBSERVATION II, noted by M. Pierret.—The patient C— was received into the Salpêtrière on the 18th Feb., 1850; died April 14th, 1874, aged fifty-five. Affection began, at the age of twenty-six, by the right upper extremity. The lower extremities were not affected so as to make walking impossible, until five or six years ago. No contractures, no disturbance of sensibility, very well-marked fibrillary contractions. Latterly all movements of the limbs have become nearly impossible. The wasting of the muscles is especially noticeable in the right thoracic extremity (hand, shoulder, forearm). Death supervened, in consequence of pulmonary tuberculisation rapidly evolved.

Examination of sections of the hardened spinal cord.—Throughout the whole extent of the cord, but especially in the cervical region, a great number of nerve cells of the anterior cornua have disappeared without leaving any trace; those which resist are very small and present the most advanced degrees of pigmentary degeneration. On a level with the fourth cervical pair of nerves,

at the Salpêtrière in my wards ; and, lastly, a case in every respect very regular, was recently observed in the wards of Professor Vulpian, by Dr. Troisier.¹

This small array of cases forms, nevertheless, a solid whole. All contradictory observations, that is to say, those in which progressive atrophy, according to the Duchenne-Aran clinical type, is supposed to show itself without the accompaniment of the spinal lesions described, are, I believe I have ascertained, defective either clinically or anatomically. With respect to the latter point, gentlemen, I would have you remark that the spinal lesion of protopathic progressive amyotrophy, as well as that of infantile paralysis, cannot be identified with certainty except when properly prepared sections have been subjected to examination. All investigations which have not been carried out, in accordance with this method, and under conditions favourable to success, should, in relation to this matter, be considered null and void.²

the right anterior cornua has suffered reduction in every diameter ; its neuroglia is evidently sclerosed ; the motor nerve-cells have disappeared with the exception of only one little group (fig. 11, *b*). The anterior roots emanating from the cervical region are wasted ; some nerve tubes are found there exhibiting granular fatty degeneration.

¹ The observation of M. Troisier will be published shortly in the 'Archives de Physiologie.'

² Dr. Bamberger has published ('Wiener Mediz. Presse,' Nos. 27, 28, Juli, 1869, and 'Centralblatt,' Oct., No. 46, 1869) two cases of progressive muscular atrophy, in which the autopsy, made by Prof. Recklinghausen, did not, it is stated, permit the recognition of any lesion of the spinal cord. Unfortunately, the account of the autopsy, so far as the nervous system is concerned, is not accompanied by circumstantial details, in these cases. It is not, for instance, mentioned if the microscopic examination was made with hardened sections, which here is absolutely indispensable, and the condition of the cells of the anterior cornua is not specially stated. We consider it necessary once more to recall the fact that the spinal cord may appear quite healthy, to the naked eye, at a time when the nerve-cells of the anterior cornua have, nevertheless, undergone the most complete alterations. We would add that, in such a case, microscopical examination itself may not furnish any decided result if it be made with sections not hardened.

The preceding remarks apply in every point to all the cases, without exception, which Herr Friedreich has arrayed in his recent work ('Ueber Progressive Muskelatrophies,' Berlin, 1873) against the *nerve theory* of progressive amyotrophy (Obs. i, ii, iv, x, and xvii). I speak of the observations collected by the author himself ; all date from a period (from 1858—1867) when the rôle of the alteration of the nerve-cells, themselves, had not been yet elucidated, and nowhere is the anatomical condition of these cells explicitly mentioned.

2°. The *anterior nerve-roots* and the *peripheral nerves* are affected consecutively to the lesion of the grey substance. I would remind you, in reference to this, that Cruveilhier considered the atrophy of the anterior nerve-roots as the anatomical character of that form of muscular atrophy the history of which he contributed to elucidate, and that he, as it were, foresaw that this atrophy would some day be correlated to a lesion of the grey substance.¹

It is important to note that the atrophy of the anterior roots cannot be a destructive atrophy to the same extent as in infantile paralysis. Undoubtedly, in the roots emanating from regions where the grey substance is most seriously altered, we usually find a certain number of nerve-tubes void of medullary matter, or in which this substance is affected, in varying degrees, with fatty granular degeneration. But the greater portion of these tubes may, as I have again verified in a recent case, be preserved intact, or, at most, present no other alterations than those of simple atrophy. This comparative integrity of a very great number of nerve-tubes of the anterior roots is seen even when these offer to the naked eye a very slender appearance and a slightly greyish tint.

The mechanism by which the spinal alteration reacts upon the muscles in progressive amyotrophy seems, therefore, to differ, in some respects, from that which is observed in infantile paralysis. In the latter, a certain number of nerve-tubes take on the same changes as a divided nerve. In muscular atrophy, only a few nerves experience this fate, and even then the destruction is effected little by little, progressively, and is only definitely accomplished in the last stages of the morbid process. The other tubes of the nerve-root preserve the integrity of their constitution, at least in all essential particulars.

I would also point out that several of the cases, grouped by Herr Friedreich under the same heading, do not at all deserve the name of *progressive muscular atrophy*, even employing this term in its widest and vaguest sense. Thus Cases I and II can hardly be taken as other than examples of infantile spinal paralysis; and Case VI, remarkable by its febrile commencement and the rapid course of the disease, seems to me to belong naturally to the type created by Duchenne, under the designation of spinal paralysis of the adult. Such a *laissez aller* in the matter of nosographic differentiation, especially in a question of itself rather obscure, is to say the least regrettable and can only continue the confusion.

¹ Cruveilhier, 'Bulletin de l'Académie de Médecine,' 1853; id., 'Sur la Paralyse Musculaire Atrophique,' 5e serie, t. vii, Janvier, 1856.

What, then, is the mode according to which, in progressive amyotrophy, the muscular lesion is effected in consequence of the spinal lesion? With respect to this question, I cannot well see any but one hypothesis that may be proposed, namely, that the irritative action, occupying the cells, is transmitted by means of the nerve-roots and centrifugal nerves to the muscular bundles which, under this influence, suffer trophic lesion. The atrophy is here the primary phenomenon: it is not at first accompanied by paralysis from interruption of nervous influx, because the latter may still proceed for a long while by the channel of the emaciated, but not annihilated, nerve-tubes.

3°. It remains for me now, finally, to show you in what consist these *muscular lesions*, which thus supervene in consequence of the lesions of the spinal centre. I shall not need to dwell long on this point, for many are the analogies which connect the muscular lesions of protopathic spinal amyotrophic with those of infantile paralysis.

This question of pathological histology has been, in its time, the object of many controversies, which are very interesting to examine from a critical and historical point of view, but which have otherwise lost most of their value. I will only remind you that the fatty-granular degeneration of a certain number of fibres is the fact by which the first observers—Mandl, Galliet, Lebert, Cruveilhier, Aran, and Duchenne — were especially struck. Taking these observations as a basis, Dr. Duchenne believed he could characterise the disease, anatomically, by giving it the name of *progressive fatty muscular atrophy*.

Professor Robin then interposed in the debate, and he rightly remarked that many of the granulations which appear on the fibres are not of a fatty nature, since they dissolve in acetic acid, whilst they resist the action of ether.¹

Next came Professor Virchow, who protested on behalf of fatty degeneration, and even went beyond the opinions that had been advanced, pointing out the fact, which is quite accurate, that the fat does not originate within the muscular fibre only, but that it also occasionally invades the interstitial connective tissue or *perimysium*. It is easy to-day to perceive that, in this debate, the essential fact was allowed to pass nearly unnoticed. In truth, in

¹ Ch. Robin, 'Comptes rendus et Mém. de la Soc. de Biologie,' 1854, p. 201.

progressive spinal amyotrophy, as in infantile amyotrophy, granulo-proteic degeneration, as well as granular-fatty degeneration of the muscular fibres, is only an accessory phenomenon. This is proved by the case of M. Hayem, and by the multiplied observations which we have made at the Salpêtrière.

The capital fact, in this matter, is a simple atrophy of the muscular fibre, with retention of the cross striation. The latter persists to the ultimate limits. This amyotrophy is usually accompanied, on some points, by a more or less marked proliferation of the cellular elements of the sarcolemma. In a certain number of muscular fibres this multiplication may be carried far enough for the new-formed elements to accumulate within the sheath of the sarcolemma, so as to distend it and crowd back the muscular substance. The latter then becomes segmented, and presents the appearance of small blocks, which, however, preserve their striated markings to the last phases of the alteration.

As regards the newly-formed cellular elements, some of them take on the development of cells with protoplasm, but this is rare. Most of them become abortive in their evolution, and tend to atrophy; whilst, at the same time, the muscular substance goes on dividing and subdividing, and sometimes it disappears altogether, without exhibiting the slightest trace of granular fatty degeneration. All these peculiarities have been studied with care in the work of M. Hayem.

Finally, the perimysium also, to a certain extent, undergoes proliferative action, which constitutes a sort of sketch of muscular cirrhosis. In its turn, *interstitial lipomatosis* may intervene, and even proceed to *luxuriant lipomatosis*. The latter fact deserves particular mention, because fatty deposit may, during life, render it impossible to perceive the existence of the atrophy of the muscular masses, and thus mask the principal symptom of the disease.

Such, gentlemen, are the muscular alterations in protopathic progressive amyotrophy. We shall shortly see that they do not exclusively belong to that pathologic form, and that they are found with the same characteristics in the symptomatic amyotrophies which are now to engage our attention.

LECTURE XII.

DEUTEROPATHIC SPINAL AMYOTROPHIES. LATERAL AMYOTROPHIC SCLEROSIS.

SUMMARY.—*Deuteropathic spinal amyotrophies. Lateral amyotrophic sclerosis; localisation of the spinal lesion in the lateral columns. Causes of this localisation, elucidated by a study of the development of the spinal cord. Formation of lateral columns; of Goll's columns and of Türck's columns.*

Lateral sclerosis consecutive on cerebral lesion.

Primary symmetrical lateral sclerosis. Pathological anatomy. Appearance and topography of the lesion in the cord and bulb. Consecutive lesions of the grey substance (motor nerve-cells, neuroglia), in the cord and in the bulb. Secondary changes: anterior nerve-roots. Peripheral nerves. Trophic lesions of the muscles.

GENTLEMEN,—We have finished with the form of *progressive muscular atrophy* arising from a *lesion systematically limited to the anterior spinal grey substance*; the moment has arrived for us to discuss some questions in relation to *spinal amyotrophies* which present a *chronic character*, where the central lesion, no longer strictly circumscribed, besides occupying the anterior cornua of the cord, occupies also either the posterior substance or different white columns.

We have agreed, you recollect, to call the spinal amyotrophies of this kind *deuteropathic*. They compose a complex group, which as yet has been but little elucidated. But, as I intimated to you, this group possesses an individuality which deserves to be closely examined, both on account of its clinical importance, hitherto indeed well nigh misunderstood, and likewise because of the physiological and anatomical peculiarities that belong to it.

Here, the spinal lesion is constituted by a combination, so to speak, of the obligatory alteration of the anterior grey substance,

with a *symmetrical and primary sclerosis of the lateral white columns.*

I.

Let us, in the first place, consider the anatomo-pathological aspect and, at the outset, enter upon a description of this singular lesion of the white columns. Nothing, assuredly, can seem more odd and probably unexpected to some of you than this lesion, geometrically circumscribed, as it were, to a region of the white columns, which in the normal state, is not separated, at least not in the adult, by any perceptible line of demarcation from the remainder of the antero-lateral columns.

But surprise soon ceases when you come to examine the facts supplied by a study of the embryo-development of the spinal cord. Then, in fact, you readily perceive that that portion of the antero-lateral columns to which the inflammatory processes may thus be confined, forms, during foetal life, and even during the early stage of extra-uterine life, a separate system, anatomically distinct from the other columns of the spinal cord.

This, gentleman, is an almost entirely new point of view, at least as applied to pathology. I have already alluded to it, in our opening lecture, but I think we have grounds for referring to it now, in fuller detail.

The results which I am about to state, but briefly, are taken from the labours of Budge, Küffer, L. Clarke, Kölliker, Flechsig, and from other and, on some points, more complete labours which, at my request, were undertaken by M. Pierret, in the laboratory which I direct.

A. The spinal cord is, you are aware, only an incomplete ring made of embryonic matter, in the first stage of its formation. As soon as the central canal is closed behind, the embryonic mass tends to divide itself (owing to the appearance of a lateral furrow on either side), into two portions, an anterior and a posterior half for each lateral moiety of the cord. In this way, are at first sketched out the rudiments of the anterior cornua (fig. 13, *a*), and of the posterior cornua, of grey substance (fig. 13, *b*). Towards the close of the first month, a zone of white substance is added, which is in connection with the nerve-roots.

These zones, in the nomenclature proposed by M. Pierret, receive the following names:—1^o, the *anterior radicular zones* (fig. 13, *a'*) which go to constitute, in the adult, a considerable portion of the antero-lateral columns; and, 2^o, the *posterior radicular zones* (fig. 13, *b'*).

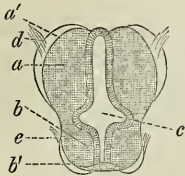


FIG. 13.—Section of spinal cord of human embryo one month old. *a*, anterior cornua; *b*, posterior cornua; *c*, central canal; *d*, anterior roots; *e*, posterior roots; *a'*, anterior radicular zone; *b'*, posterior radicular zone.

When the columns of Goll, not yet developed at this period, shall have been added, they will ultimately form what is usually called the posterior columns.

The lateral columns do not yet exist; they are seen to make their appearance towards the sixth or eighth week in the furrow, which still laterally separates the two portions of grey substance, under the semblance of two little masses or tubercles of embryonic matter, in which the nerve-tubes do not show themselves until very late (fig. 14, *l*).

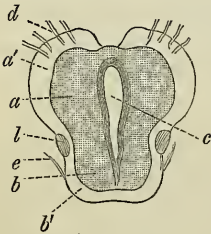


FIG. 14.—Section of the cord of human embryo a month and a half old. *a*, *b*, *c*, &c., as in Fig. 13. *l*, lateral column.

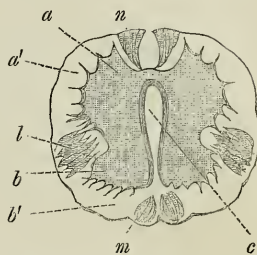
Towards the same epoch, (about the eighth week, namely), are developed, in the furrows which separate the posterior radicular zones, two small symmetrical protuberances, which tend to unite together, and which extend throughout the whole height of the cord; these are the columns of Goll (fig. 15, *m*).

At the same time, an analogous formation takes place in the furrow which separates the anterior radicular zones. It relates to the small columns which I have proposed to designate by the name of the *columns of Türk* (Figs. 15, 16, *n*), and which cannot be followed, in the adult, below the cervical enlargement of the cord.

Thus is completed that aggregation of distinct pieces which, by

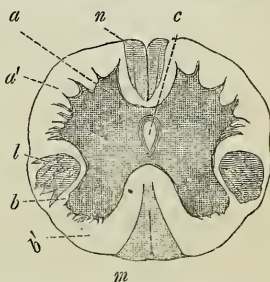
their union and more or less intimate fusion will form, at a more advanced period of life, the antero-lateral columns, such as we see them in the adult.

FIG. 15.—Section of the cord of human embryo aged two months. *a*, *b*, *c*, as in Fig. 13; *l*, lateral column; *m*, development of Goll's column; *n*, development of Türck's columns (the anterior fascicles).



B. But the lateral columns being those which are alone to engage our attention to-day, I should revert more particularly to the cha-

FIG. 16.—Section of the cervical cord of human embryo aged from twelve to fifteen weeks. The letters indicate the same things as above.



racters which they present in the different phases of their evolution. By the progress of development they tend to fuse, *in front*, with the anterior radicular zones, and *behind* with the anterior extremity of the posterior radicular zones, so as soon to become indistinguishable, each from each.

However, even after birth, in the new-born child, we can still, in the area of the white columns, discern the region which belongs to the lateral columns, properly so called by certain histological characters, which betray a comparatively less advanced development. This region is observed, behind an imaginary transversal line crossing the commissure, under the form of a triangular space corresponding to the most posterior portion of the antero-lateral column. In this space the white substance is distinguished by a greyish tint, perceptible by the naked eye. Microscopical examination shows that nerve tubes, having medullary cylinders are rare here; and that, on the contrary, the connective matrix is predominant: hence, these portions are strongly coloured by carmine, but scarcely tinted by

osmic acid. Finally, these same portions include, in the normal state, a certain proportion of cells studded with fatty granulations, which represent in the cord what M. Parrot designates by the name of *physiological steatosis*.

I shall add that, as shown in a plate of Kölliker's work, a more or less marked furrow often denotes, on the exterior of the cord in young infants, a separation between the lateral columns proper and the anterior columns. But, in the adult, all distinction is lost; however, it is right to observe that, even in his case, the regions which correspond to the lateral columns are still marked by the comparatively small diameter of the nerve-tubes and by a certain preponderance of neuroglia.

Enough has been said, gentlemen, I hope, to render evident the incontestable independence possessed in the first period of life by the lateral columns of the spinal cord. I should, however, complete this sketch by pointing out to you that this system is seen represented in the bulbus, above the decussation, by the anterior pyramids, and also in the protuberantia, and in the lower portion of the crura cerebri. Now, these regions of the isthmus of the encephalon and bulbus which are in relation with the lateral columns, are distinguished, like the latter, in the fœtus, by late development, which is but imperfectly accomplished at the time of birth.

II.

The individuality, the autonomy of the lateral columns, which has been already rendered evident by the foregoing remarks, is again distinctly exhibited when we examine the phenomena which pertain to the sphere of pathology. It is not unknown to you—for the subject occupied us last year—that, after a unilateral lesion of certain departments of the encephalon, an entire half of the system of lateral fibres, alike in the crus, in the protuberantia, in the bulbus, and throughout the whole height of the spinal cord, undergoes, separately and singly, a consecutive lesion, which soon shows itself histologically by characters peculiar to sclerosis of the nerve centres. In the isthmus, and in the bulbus, the fasciculated sclerosis may be followed down to decussation, on the same side as the cerebral lesion. Beneath the point of decussation it occupies, on the contrary, the other side of the cord.

This lesion of the system of lateral fascicles is, in such a case, absolutely isolated; it is, in particular, not accompanied, at least as a

general rule, by any alteration of the anterior grey substance or of the spinal motor roots. In connection with this subject I would remind you that the hemiplegia with contracture, which coexists with this lesion, is remarkable for integrity of nutrition in the paralysed muscles, so long as functional inertia has not been overmuch prolonged.

In a case where the primary cerebral lesion should simultaneously occupy corresponding points in both hemispheres, then the system of lateral columns would naturally be affected on both sides, right and left, throughout its whole extent, in the isthmus as well as in the bulb and spinal cord. In this hypothesis, which has been more than once realised, we should consequently have to deal with *a symmetrical lateral sclerosis, consecutive on cerebral lesion.*

But a total symmetrical sclerosis of the lateral columns may supervene protopathically, primarily, without dependence on any encephalic lesion whatever. This is a fact which L. Türk, in 1856, and which I myself, ten years later, have rendered evident, and which it is proper, at present, to set out in a prominent manner.

Here, two cases may present themselves :

1°. Primary symmetrical sclerosis alone is seen to exist, without being complicated with any lesion of the anterior grey substance ; the most salient feature in the syndromus in connection with the lesion, thus established, is a paresis of the limbs, especially of the lower extremities, marked by more or less intense contracture of the muscles, which long preserve all the characters indicative of normal nutrition. This lesion of the spinal cord is rather frequently seen, amongst other matters, in the course of progressive general paralysis—a coincidence which has been particularly noticed by H. Westphal.

2°. But it happens rather frequently that an alteration of the grey substance is associated with the symmetrical lesion of the lateral columns. Now, the combination of these two orders of alteration exactly constitutes the anatomical substratum of the pathological form to which I desire to call your attention. The symptoms of progressive amyotrophy are then associated with those arising from lateral sclerosis.

III.

We have now to study more closely, from an anatomical point of view, the alterations in question. In the following description we shall have to examine successively—1°, the lesions presented by the *system of lateral fascicles* in the several regions of the cord, the

bulbus, and in the isthmus of the encephalon; 2, the concomitant lesions of the *grey substance* in the same departments of the nerve centres; 3°, the consecutive lesions of the *anterior roots* and of the *spinal nerves*; 4°, lastly, the *trophic lesions of the muscles*.

With respect to the first point I shall be brief, because I assume your acquaintance with consecutive scleroses of cerebral origin, the anatomical characters of which are very nearly the same as those of primary scleroses. I will confine my remarks to noting the following points:

A. Let us consider, in the first place, what passes in the *cord*.

a. When transverse sections of the cervical enlargement are examined, it is found that the symmetrical alteration here comprises a greater extent, in breadth, than anywhere else. Thus, the region invaded by sclerosis extends forward to a level with the outer angle of the anterior cornu, and even beyond it. Behind, it is nearly bounded by the posterior grey substance. On the outer side, however, it is constantly separated from the cortical layer of the cord by a tractus of uninjured white substance (fig. 17, A, A). See also Pl. IV, figs. 1, 2, 3; Pl. V, figs. 1 and 2).

FIG. 17.

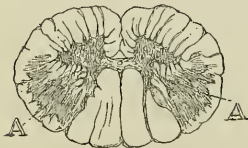

FIG. 18.

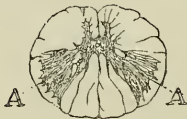

FIG. 19.

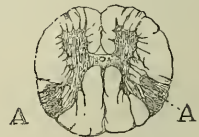

FIG. 17.—Transverse section of the spinal cord, taken from the middle portion of the cervical enlargement.

FIG. 18.—Transverse section, taken from the middle of the dorsal region.

FIG. 19.—Transverse section, taken from the middle of the lumbar enlargement.

All other parts of the white columns are left unharmed, with the exception of the small fascicles of Türck which, in certain cases, are symmetrically affected. These fascicles, I may say in passing, seem to belong to the same system as the lateral fascicles.

b. In the dorsal region, the lesion is more circumscribed (fig. 18). In front, it does not even reach an imaginary line crossing the commissure. Externally it approaches the cortical zone, from which it is only separated by a very thin strip of uninjured white substance.

c. Finally, in the lumbar region the lesion is still less extensive.

It barely occupies the posterior fourth of the lateral columns. It is worth noticing that, externally, it reaches to the cortical zone (fig. 19).

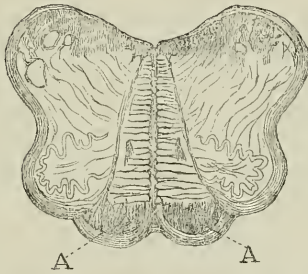


FIG. 20.—Transverse section of the bulbus, from the mid-portion of the olivary bodies. A. A. Anterior pyramids, affected by sclerosis.

B. Secondly, what do we find in the *bulbus*? The lesion shows itself here by an invasion of the anterior pyramids, throughout their whole height (fig. 20). Above, in the lower part of the protuberantia, the lesion may be followed upward so long as the fibres coming from the pyramids are still united in bundles; but, higher again, when these fibres scatter, they are readily lost sight of.

Some authors have traced the lesions of primary lateral sclerosis even into the *foot*, or lower portion, of the crus cerebri; but it is not known how it ends, that is, so far as the brain is concerned. However, the internal capsule which, in part, seems only to be a prolongation of the lower portion of the crus, is, notwithstanding, not invaded.

IV.

This terminates what we have to say in reference to alterations of the white columns. It now becomes our duty, gentlemen, to notice those which belong to the *grey substance*.

They differ in nothing essential from those which we studied in connection with *protopathic spinal muscular atrophy*. This means that here, also, they are systematically localised in the anterior grey cornua. In that region, just as in the former case, they affect both the *neuroglia* and the *motor nerve-cells* which are, more or less numerous, degenerated, atrophied, or even completely destroyed (see Pl. IV, fig. 4).

It is the rule that the alteration of the grey substance shall not exceed the area of the anterior cornua; this peculiarity is rendered especially evident by the perfect integrity, as has been frequently

verified, of the cell-groups of Clarke's column in the dorsal region.

a. The alteration of the spinal grey substance, in all the cases which I have observed, preponderates in the cervical region of the spinal cord; it is also often very marked in the dorsal region; but it tends to become attenuated as we descend towards the lumbar enlargement. This disposition of the lesion is correlated to a circumstance which I shall not fail to bring out, prominently, in the clinical description; it is this, namely, that muscular atrophy, in the nosographical form which occupies us, rarely affects the inferior extremities. These limbs are paralysed and stricken with contracture at a very early period, which the existence of the lateral sclerosis accounts for, but their muscles are either not atrophied or but little wasted, in comparison.

b. The alterations of the grey substance of the spinal cord, as well as those of the white columns, have their pendant in the medulla oblongata. You are not unaware, gentlemen, that there exists, in this part of the nerve centres, a certain number of nuclei of grey substance, which are regarded as analogous to the anterior cornua of the cord, and, consequently, as being the region whence the motor bulbar nerves originate. This supposition is scarcely open to doubt, particularly with respect to the nuclei, whence originate the hypoglossus, the spinal, and even the facial nerves. Now, to speak only of the first named, the great multipolar cells which compose it and which, morphologically, are so closely analogous to the great motor cells of the cord, these cells, I repeat, become atrophied or destroyed simultaneously with the sclerosis of the neuroglia which encloses them (fig. 21). But, for the present moment, I shall content myself with merely indicating the fact, in order not to leave wholly in the shade an entire corner of the picture, and an interesting one besides. I will return to the subject when studying bulbar amyotrophies and labio-glosso-laryngeal paralysis.

V.

All that now remains for me is to make you acquainted with the changes which are produced, consecutively on the foregoing, in the *anterior roots* and in the *peripheral nerves*. I have merely to repeat here what I have already said with respect to protopathic spinal muscular atrophy. Nerve-tubes entirely devoid of medullary matter

are rare in the roots as well as in the peripheral nerves. Granular tubes are in minority. Most of the nerve-tubes are preserved ;

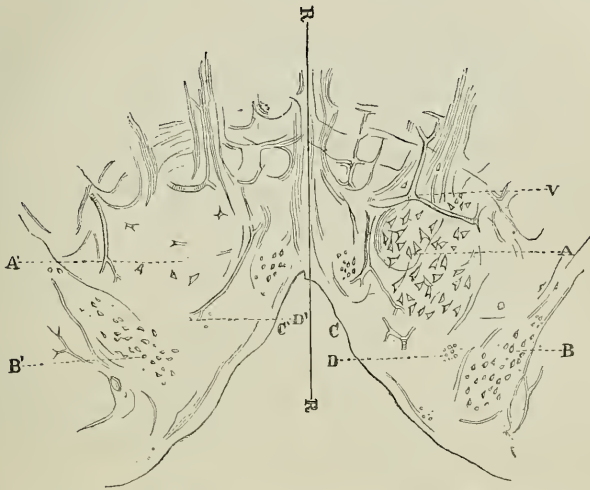

FIG. 21.—Transverse section of the bulb, on a level with the middle of the nucleus of the hypoglossus. A, B (to the right of the imaginary line R, R'), represent the normal condition; A, nucleus of the hypoglossus, composed of a cluster of some thirty great multipolar cells; v, a vessel which bounds the nucleus in front and on the inner side; c, floor of the fourth ventricle; d, *fasciculus teres*; B, nucleus of pneumogastric nerve. A', B', &c. (to left of the imaginary line R, R') represent the same parts in a case of amyotrophic lateral sclerosis. It is seen that hardly five or six nerve-cells are left uninjured in the area of the nucleus of the hypoglossus. A', *fasciculus teres*. B', Nucleus of the pneumogastric, exhibiting no perceptible change.

nearly all of them, however, have undergone a certain degree of simple atrophy. This is a fact which shall be brought out, prominently, when we treat of the pathogeny of consecutive muscular lesions.

VI.

I may also deal very briefly with the *trophic lesions of the muscles*. They do not differ, in any essential manner, from those which are met with in primary, spinal amyotrophy. Still, the inflammatory character of the lesion has appeared to me more marked in amyotrophic lateral sclerosis. Thus, the hyperplasia of the perimysium is more manifest and, in one case, I even found,

with M. Debove, the interstitial connective tissue infiltrated with a considerable number of leucocytes in some places.

I would note particularly that interstitial lipomatosis of the muscles is produced, in the amyotrophy connected with lateral sclerosis, just as in pure amyotrophy. This fact is interesting in connection with the tongue, the muscles of which, in amyotrophic sclerosis, waste equally with those of the extremities, in consequence of the alteration of the cells of the hypoglossal nucleus. Nevertheless, the tongue, in such cases, may almost entirely preserve its normal volume, and not present, on its surface, the convolutions and wrinkles, animated by vermicular movements, which are often observed there. In these diverse circumstances, its muscular fibres are atrophied. This preservation of the form and volume of the organ is explained in the cases I refer to, by interstitial lipomatosis. In one of these cases I have remarked, with M. Debove, the existence of a kind of hypertrophic cirrhosis, produced by the excessive vegetation of the perimysium, both internally and externally (figs. 22, 23).

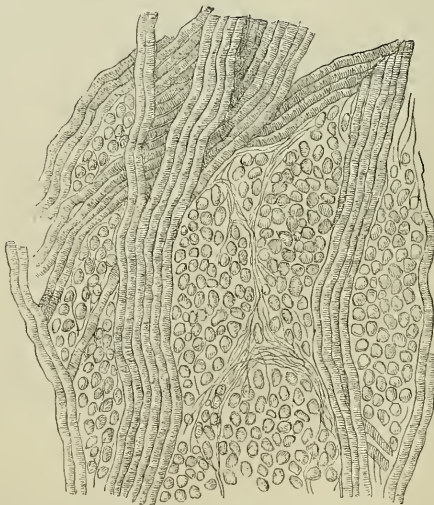


FIG. 22.—Section of tongue; normal condition.

After this description of the lesions peculiar to lateral amyotrophic sclerosis, it is our intention to make you acquainted with the principal symptoms which betray its existence during life, with a

view to determine, as closely as possible, the physiological connection which attaches the lesions to the symptoms.

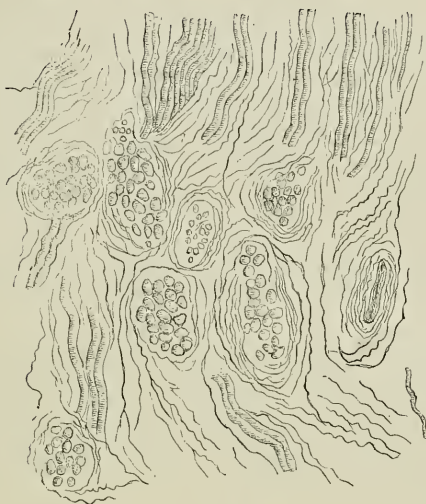


FIG. 23.—Section of tongue in a case of amyotrophic lateral paralysis, with labio-glosso-laryngeal paralysis.

It may be stated, in a very general manner, that the symptoms to which I allude are of two orders : one set is in correlation with the symmetrical alteration of the lateral columns, the other depends upon the concomitant lesion of the grey substance. This is what I shall endeavour to demonstrate at our next meeting.

LECTURE XIII.

ON AMYOTROPHIC LATERAL SCLEROSIS. SYMPTOMATOLOGY.

SUMMARY.—*Facts which form the basis of the symptomatology of amyotrophic lateral sclerosis. Personal observations. Corroborative cases.*

Differences which clinically separate amyotrophic lateral sclerosis from protopathic spinal muscular atrophy.

Symptoms common to both affections. Progressive amyotrophy, fibrillary contractions, preservation of electric contractility.

*Symptoms peculiar to amyotrophic lateral sclerosis. Pre-
dominance of motor paralysis. Permanent spasmodic contrac-
ture. Absence of sensory disorders. Paralytic deformations ;
attitude of hand. Tremulation of upper extremities in pur-
posed movements. Modes of invasion. Cervical paraplegia.
Invasion of inferior extremities. Characteristics of the con-
tracture. Bulbar phenomena ; difficulty of deglutition. Im-
peded speech. Paralysis of the velum palati, of the orbicularis
oris, &c. Grave disorders of respiration.*

*Summary of symptoms. Prognosis. Pathological phy-
siology.*

I.

GENTLEMEN,—After describing the necroscopic changes peculiar to *lateral amyotrophic sclerosis* it becomes us now to enliven the picture by showing you the series of symptoms which, during life, are correlated to these lesions.

I trust, gentlemen, to establish that this symptomatic group is striking and characteristic enough to be readily distinguished from that which depends on the circumscribed alteration in the *anterior spinal grey substance*. It will be, also, easy for me, I believe, afterwards to draw a distinct line of demarcation between *lateral amyotrophic*

sclerosis and the other forms of *deuteropathic spinal muscular atrophy*.

1°. At the outset, I ought to mention that the observations which are to serve as the basis of my description are as yet not numerous, being only a score at most. But, it may be added that the same thing occurred, on a former occasion, in connection with *progressive locomotor ataxia*. And yet the clinical picture traced by Duchenne (de Boulogne) with the help of a few facts, some twenty years ago, has not lost by age. It still remains, at the present moment, such as it was in all essential particulars, without having undergone any serious modifications. May the description which I am about to offer you of *amyotrophic lateral sclerosis* experience the same destiny!

Most of the facts, whose assistance I can rely upon, have been collected by myself or by my students, in the Salpêtrière Hospital. At the commencement, the observations were chiefly noted from the standing point of pathological anatomy.¹ Nevertheless the symptoms had almost always been set down with some care. Hence, at a given period, it became possible, on comparing the different observations, to perceive a certain number of fundamental features, which afterwards enabled us to recognise the disease during life. Such, also, has been the history of *disseminated sclerosis*; for a long time, only the singular lesions which characterise it anatomically were known to us. To-day, it takes rank, in general clinical practice.

In addition to my own facts, I have found in different publications some more or less complete observations, which belong in every particular, to the pathological form in question, and I have consequently turned them to advantage.

I will mention, firstly, amongst facts of this group, Cases II and IV of the excellent memoir, published in 1867 by M. Duménil (of Rouen), on progressive muscular atrophy, in the 'Gazette hebdomadaire.' Then, I would refer to three observations reported by Leyden. They have published, as examples of *bulbar paralysis*, in the 'Archiv für Psychiatrie,' edited by H. Westphall.²

¹ The observations, followed by autopsy, collected by me in the Salpêtrière Asylum are five in number. I shall give a summary of them further on. Two of these observations have been published, with details: one by M. Joffroy and myself ('Arch. de Physiologie,' 1869, p. 356); the other, in the same journal (1871-72, p. 509), by M. Gombault.

² E. Leyden, "Ueber progressive Bulbär-paralyse," in 'Archiv für Psychiatrie,' ii Bd., p. 648; Obs. I, und p. 657; Obs. II, iii Bd., p. 338.

I have also to mention a case inserted by H. Otto Barth in Wunderlich's journal, under the title of *Atrophia musculorum lipomatosa*.¹ The author, little careful of nosographical rules, seems to think that he had before him an example of *pseudo-hypertrophic* paralysis, as understood by M. Duchenne (de Boulogne). In reality, the autopsy, which was made with much care, affords superabundant evidence that the disease in question was *primary symmetrical sclerosis of the lateral columns with concomitant lesions of the anterior grey substance*. A case, recorded by Dr. Hun,² another published by Mr. S. Wilks, in 'Guy's Hospital Reports,'³ are also, in my judgment, examples of amyotrophic lateral sclerosis. Finally, I would also include, in the same category, two observations recently published by Drs. Lockhart Clarke,⁴ and R. Maier, of Friburg.⁵

In concluding this review of corroborative articles, I should mention, gentlemen, that M. Duchenne, de Boulogne, in the new edition of his book,⁶ has opened, under the heading of *Subacute diffuse general spinal paralysis*, a chapter in which appears one of the cases, noted in my wards at the Salpêtrière in connection with *amyotrophic lateral sclerosis*. This chapter also contains a large number of heterogeneous elements which could not be classed elsewhere. The greater number of the *deuteropathic chronic spinal amyotrophies* are grouped together under the same denomination. Evidently, this could only be a tentative chapter, a sort of *caput mortuum*, which requires to be entirely remodelled.

To those amongst you who may be desirous of examining *de visu* the symptoms of amyotrophic lateral sclerosis, I would mention that there exists at the present moment, in La Charité, under the care of Dr. Woillez, a poor mason, aged 44, who presents, at least

¹ O. Barth, "Zur Kenntniss der Atrophia musculorum lipomatosa," in 'Archiv der Heilkunde,' 1871, p. 121.

² 'American Journal of Insanity,' Oct. 2nd, 1871, and 'Centralblatt,' 1872, p. 429.

³ Vol. xv, I. 46, and 'Centralblatt,' p. 239, No. 15, 1870.

⁴ J. Lockhart Clarke, 'Progressive Muscular Atrophy, accompanied by Muscular Rigidity and Contraction of Joints; examination of the Brain and Spinal Cord,' in 'Medico-Chirurgic. Transactions,' t. lvi, p. 103.

⁵ R. Maier, "Ein Fall von fortschreitender Bulbär-paralyse," in 'Virchow's Archiv,' 61e Bd., 1er Heft, p. 1.

⁶ 'Electrisation localisée,' 3e edition, 1872, p. 469.

in my opinion, all the fundamental clinical characters of this affection.¹

II.

1°. One of the first distinctive features which, of itself, radically separates amyotrophic lateral sclerosis from primary muscular atrophy is the comparative rapidity of its evolution, considered from the invasion of the first symptom to the fatal end. This does not usually, on an average, delay more than three years and it may supervene much sooner, at the end of one year, for instance; whilst patients, affected by protopathic spinal progressive muscular atrophy may survive, as you are aware, for eight or ten, and even for fifteen and twenty years.

2°. During this comparatively short period, it is the rule that the four extremities shall be successively, and within a brief space, all stricken with paralysis accompanied by atrophy, or with paralysis only in the lower limbs. The patient after some months, a year or two, three years at most, is confined to his bed, and more or less completely deprived of the use of his limbs. But, in addition, to judge at least from all the cases which I have collected, we regularly find the disease extending to the bulbus, and, it is nearly always to the paralysis of the bulbar nerves, more especially, of the hypoglossus and pneumogastric that the phenomena which determine death are to be attributed. This forms a contrast with what we know concerning common progressive muscular atrophy, since here, according to the statistics furnished by Dr. Duchenne, atrophy of the muscles animated by the bulbar nerves has been found to appear only thirteen times in 159 cases.

3°. The data obtained from an examination of *etiological influences* are not of remarkable importance, so far as we have yet gone,—this, however, is easily understood on account of the small number of particulars which can be tabulated. I shall confine myself to the following observations :

¹ The patient has succumbed, since this lecture was delivered, after the manifestation of bulbar symptoms. The autopsy was made by M. Voisin, acting clinical clerk. An examination of the cord made by M. Gombault, “preparateur” for the course of pathological anatomy, has demonstrated the existence of symmetrical lateral sclerosis, with atrophy of the motor nerve-cells in the cervical region of the cord and in the nuclei whence originate the bulbar nerves. The prepared sections, in connection with this case, have been shown at the *Cours Pratique de la Faculté*.

Hereditary influence has not been mentioned in our cases. As regards *age*, the disease makes its appearance at ages varying from 26 to 50 years. *Females* are more frequently affected than *males*, which is contrary to what is remarked in cases of protopathic atrophy; but it is necessary to notice that most of the cases of amyotrophic lateral sclerosis have been noted in the Salpêtrière, that is to say, in an asylum to which only women are admitted.

Perhaps a third of the patients attribute the development of the disease to the influence of *cold* and *damp*, to which their business exposed them. The mason, in La Charité, rightly or wrongly, lays the blame on a fall which he got, two or three months before the appearance of the first symptoms, the immediate result of which was a fracture of the clavicle.

I will not delay longer over the etiological aspect of the question, which can only be profitably considered in a more or less distant future. Etiology is based especially upon a wide foundation of figures, and we are yet far from being able to furnish them.

4°. It is now time, gentlemen, to come to the analysis of the symptoms. These symptoms are of two orders:

A. Some are common both to progressive amyotrophy and to amyotrophy from lateral sclerosis; these are:—*a*, progressive atrophy, invading the muscular masses; *b*, fibrillary contractions which are especially seen in the active period of the atrophy; *c*, the preservation of faradaic contractility which the wasting muscles exhibit to the last moment.

B. Other symptoms are quite foreign to protopathic spinal amyotrophy; first comes motor impotence, promptly developed, which, if it do not always precede the atrophy, is often strikingly evident even when the latter is not yet well marked. Speaking generally, we may say that, in *protopathic amyotrophy*, motor impotence depends in a great measure on the atrophy of the muscular masses, whilst in *lateral sclerosis*, paralysis certainly dominates the scene; the atrophy of the muscles is then often but a consecutive or even only an accessory phenomenon.

Here again is a new feature of distinction. The extremities, more or less deprived of their natural movements, are usually in lateral sclerosis affected by habitual rigidity, resulting from what is called *permanent spasmodic contracture*. This phenomenon is absolutely foreign to primary atrophy.

Lastly, in the latter disease, the absence of any sensory disorders is the rule, whilst in the former it is common enough for the patients to experience, or to have experienced, in the affected members :—1°, more or less acute spontaneous pains, numbness, or formication in the affected limbs; and also *pains provoked by pressure or traction of the muscular masses*. I lay emphasis on the latter phenomenon, which I have not, as yet, observed in protopathic progressive amyotrophy.

III.

But the real characteristics of the pathological form, whose description engages our attention, are especially rendered evident when we consider the mode of distribution, of concatenation, and of evolution of the symptoms.

a. The disease *begins*, in the great majority of cases, by the upper extremities, without fever, most frequently without any perceptible indisposition, sometimes after sensations of formication and numbness.

From the outset, the complaint is one of diminished motor power, and when this first seriously attracts the attention of the patient, the muscles of the affected members generally present, even at this period, a certain degree of emaciation. But neither the latter, nor the paresis, is usually limited to a circumscribed region of the limb, to some muscles of the hand or forearm, for instance; it extends a little everywhere, in a uniform manner, so to speak, from the extremity of the member to its root. We no longer observe, here, that individual atrophy of the muscles, which we noticed in connection with common muscular atrophy; on the contrary, we see a kind of general emaciation of *atrophy, en masse*.

It never attains, in the commencement, a degree of intensity sufficient to account, of itself, for the motor impotence. In short, we have, in this case, to deal with a true paralysis accompanied, or rather followed, by atrophy, more or less rapid and more or less generalised, of the entire extremity.

Besides, the atrophied or wasting muscles are stirred by fibrillary movements, which are often very marked, and, as in simple atrophy, they preserve the faradaic contractility almost intact, so long as the atrophy has not attained its extreme limit.

b. In addition to the emaciation of the muscles, the paralysed and wasted members soon become the seat of more or less marked deformations or deviations.

The *deformations* depend undoubtedly, in part, on the predominant action of certain muscles which are less intensely affected than the rest (*paralytic deformations*). But this is not the case as regards the majority of them; the deviations, as a rule, are due to the spasmodic contraction of certain muscles, to a true contracture which renders a large number of articulations rigid. Thus, to speak first of the upper extremity only, here is the attitude which it usually presents (fig. 24).

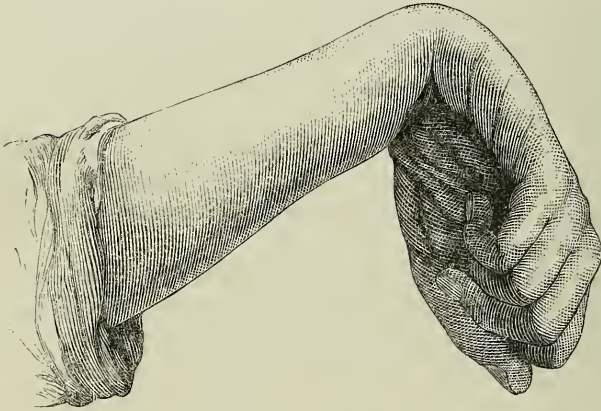


FIG. 24.—Attitude of the forearm and hand in the case of the patient Tr—, aged fifty-eight, suffering from amyotrophic lateral sclerosis.

The arm is extended close along the body and the shoulder-muscles resist any effort made to remove it from that position.

The forearm is semi-flexed, and also pronated; it is impossible to supinate and extend it without using force and provoking pain.

The same thing is found at the wrist which is, also, frequently in semi-flexion, whilst the fingers are bent in upon the palm of the hand (fig. 24).

These constrained attitudes, and the pain caused by any effort to alter them, taken in connection with the almost general and uniform emaciation of the muscles supervening within a few months, would in some sort suffice to show that, in such cases, we have not to do with primary spinal muscular atrophy.

I should not forget to mention another peculiarity. Sometimes, in lateral sclerosis, the paretic upper extremities, contracted and atrophied, have, nevertheless, still preserved some power of move-

ment. Well, in making this movement, for instance, in raising the entire arm, we see the member taken with a *tremulation*, which recalls that observed in disseminated sclerosis, and also in certain patients who, consecutively on a blood-clot cerebral lesion, are stricken with hemiplegia and contracture. This tremulation, in the two latter cases, as in the former, appears to me to depend on lateral sclerosis, a trait common to all three.

It is not superfluous to remark that, when the disease is far advanced, the emaciation may reach its climax; the thenar and hypothenar eminences are entirely wasted away, the palm of the hand is hollowed out, the forearm and arm are reduced almost to a skeleton. Then, generally, the spasmodic rigidity becomes less marked, although the members tend to retain the habitual attitude which they have so long preserved.

Some patients have the head in a *fixed position*, owing to the rigidity of the muscles of the neck; they cannot, without effort and pain, flex or extend it, or turn it to the right hand or to the left.

In one case, which I recently observed, the muscles which raise the lower maxilla were contracted to such a degree that the mouth could be opened only to an extremely limited extent.

As in ordinary progressive amyotrophy, the muscular emaciation is sometimes masked, in amyotrophic sclerosis, by a *luxuriant lipomatosis*, which throws the wasted muscles into relief, as we find shown, to take one instance, by the case reported by H. Otto Barth.

IV.

The form of amyotrophic paralysis, which we are studying, most frequently first shows itself in one of the superior extremities, then it extends to the other so as soon to present the appearance of what is called *cervical paraplegia*. Though the disease may have lasted only four, five, or six months, or a year at most, the emaciation has already attained a degree which is only seen, in protopathic muscular atrophy at an advanced period, say two or three years after the invasion.

Things may remain in this state for two, six, or nine months, rarely longer. After this delay the lower extremities are taken, in their turn, and, as a general rule, they become affected, as you will soon see, in a different manner from the upper limbs.

a. At the outset paresis is perceived, here likewise, preceded and

accompanied during some time by formication and numbness of the member. But, here, the paresis presents this important peculiarity, namely: it does not, like the former, necessarily induce muscular atrophy. The muscles, on the contrary, may, until the last period of the disease, preserve a consistence and prominence which shall form a singular contrast with the state of the upper extremities.

The paraplegia presents this first particular feature, namely: it is not complicated with any paralysis of the bladder or rectum, and there is no tendency to the formation of bedsores.

It is also distinguished, as you will perceive, by other important characters. Difficulty of motion in the lower extremities makes rapid progress. The patient feels his legs heavy, and hard to raise from the ground. Soon he can no longer walk, except when helped by two assistants. Lastly, it becomes impossible for him to stand, and thus he is nearly bed-ridden or reduced to pass the day seated in an arm-chair. When things have reached this stage, an interesting phenomenon has already been, generally speaking, more or less distinctly exhibited. I refer to the *temporary or permanent rigidity*, or, in other words, to the *spasmodic contracture of the muscles*, deprived of voluntary motion. Already, for some time back, the patient has remarked that, whilst in bed or sitting up, his lower limbs stretched out or become flexed in spite of himself, and retained for some instants the attitude which they had involuntarily assumed. Extension is what usually occurs in this kind of fit; it may even go so far as to determine a quasi-tetanic stiffness which makes the lower limbs resemble rigid bars that may be lifted all of a piece. They are also, sometimes, shaken by a convulsive tremulation.

The rigidity becomes exaggerated when the patient, aided by two assistants, tries to rise and attempts to walk. Then the lower extremities become exceedingly rigid in extension and adduction, whilst the feet assume the attitude of the varus equinus club-foot. This rigidity, which is frequently extreme, but sometimes only slight,¹ affecting all the articulations of the limb through the spasmodic action of the muscles, together with the tremulation, which

¹ I cannot say why, in certain cases, the rigidity of the upper or lower extremities should be little marked, whilst in others, on the contrary, it is a predominating phenomenon. Hitherto, I have not found anything, in the anatomo-pathological conditions which could explain such differences.

is, usually, soon superadded, render standing and walking alike impossible.

That which, at first, is but a passing phenomenon, becomes after a little while transformed into a permanent symptom. The muscular rigidity then persists, without cessation or respite, in the flexors as in the extensors, although it predominates in the latter. It is difficult to forcibly flex the extended members, and difficult likewise to extend the flexed extremities. Usually, at this period, if the extremity of the extended foot be flexed, by the hand, a more or less lasting tremulation is set up throughout the whole limb.

Thus, gentlemen, the motor impotence depends less on a weakening of the innervation than on the spasmodic condition of the muscles. Muscular nutrition, it may be remarked, still proceeds, for a long time, in the normal manner.

It is only in the long run that they are seen to be affected by fibrillary movements and to waste generally after the manner of the upper extremities. Usually, when this atrophy has been carried to a certain extent, the rigidity diminishes without, however, ever completely disappearing.

The early invasion of the lower extremities and the nature of the phenomena affecting them, form a feature which contrasts with what we know concerning primary spinal amyotrophy in which, you recollect, these members are only invaded in the later periods. They constitute, as it were, the character of a second period; the third being marked, as we shall see, by the appearance of *bulbar phenomena*.

V.

The appearance of the later symptoms is, in some sort, an obligatory accompaniment; it has never, up to the present, been found wanting. These are the phenomena which, by their union, compose the *syndromus* designated by the term *labio-glosso-laryngeal paralysis*. We will only notice, in passing, this phase of the disease, for this is a subject to which we must recur again, when treating of paralyse of bulbar origin, in particular.

I will mention the following symptoms, merely in order that one of the most curious parts of the picture may not be entirely omitted.

1°. Paralysis of the tongue inducing difficulty of deglutition,

and a difficulty in the articulation of words that may issue in complete loss of speech. The paralysed tongue, generally, soon presents a certain degree of atrophy; it is shrunken, wrinkled, and stirred by vermicular movements.

2°. Paralysis of the velum palati rendering the voice nasal (nasonnée), and concurring with the lingual paralysis to create the difficulty of deglutition.

3°. Paralysis of the orbicularis oris, the chief result of which is to alter the appearance of the features. The mouth is considerably enlarged, transversely, on account of the predominant action of the non-affected facial muscles. The naso-labial furrows are deeply marked. These several symptoms give a lachrymose look to the face. Sometimes, after laughing or crying especially, the mouth long remains half-open in a permanent manner, and allows a certain quantity of viscous saliva to flow continually forth.

4°. Lastly, owing to the invasion of the nuclei, whence originate the pneumogastric nerves, grave disorders of the respiration and circulation supervene and cause the death of the patient, whose strength has long been diminished from insufficient nutrition.

I shall try, gentlemen, to summarise, in a few lines, the symptomatological characters of *amyotrophic lateral sclerosis*, considered in what may be called its normal conditions.

1°. Paresis, without anæsthesia, of the upper extremities, accompanied by rapid emaciation of the muscular masses and often preceded by numbness and formication. Spasmodic rigidity seizes, at a given period, on the paralysed and wasted muscles and determines permanent deformations by contracture.

2°. The lower extremities are invaded in their turn. In the first instance, appears a paresis, without anæsthesia which, promptly advancing, causes standing and walking to be, in a short time, impossible. To these symptoms is added a spasmodic rigidity which, at first intermittent, next becomes permanent and sometimes complicated with *tonic spinal epilepsy*. The muscles of the paralysed limbs only become atrophied in the course of time, and never to the same extent as those of the upper extremities.

The bladder and rectum are not affected; there is no tendency to the formation of bedsores.

3°. A third period is constituted by the aggravation of the preceding symptoms and by the appearance of bulbar symptoms.

These three phases follow each other, in a short space of time. Six months or a year after the invasion all the symptoms have accumulated, and become more or less strongly marked. Death supervenes at the end of two or three years, on an average, owing to the bulbar symptoms.

Such is the rule ; but the chapter of anomalies, it is well understood, is also in existence. These latter, however, are few in number and change nothing essential in the picture which I have just traced. Thus, the disease, in certain cases, begins by the lower extremities ; again, it may be confined, at the beginning, either to one upper, or to one lower extremity ; occasionally, it remains limited, for some time, to one side of the body, under a hemiplegic form. Finally, in two cases, it began by bulbar symptoms. But, these, I repeat, are only secondary modifications. The group of characteristic symptoms does not fail to be soon formed.

The *prognosis*, up to the present, is of the gloomiest. There does not exist, so far as I am aware, a single example of a case where, the group of symptoms just described having existed, recovery followed. Is this doom final? The future alone can decide.

VI.

It remains for me now, gentlemen, to collate the lesions with the symptoms, and to seek, in a short essay of *pathological physiology*, the bond which unites them together.

1°. The paresis which appears, at the beginning, and the permanent contractures which after a brief delay succeed it are, unquestionably, dependent on the symmetrical and lateral sclerosis.

I would remind you that, wherever lateral sclerosis is found, contracture sooner or later appears in a more or less marked manner. Thus, (a) in *disseminated sclerosis* ; (b) in *cerebral hemiplegia* with *consecutive descending sclerosis* ; (c) in *transverse myelites* whether from compression or spontaneous, when lateral descending degeneration results ; (d) lastly, in *primary sclerosis of the lateral columns without muscular atrophy*.

2°. The paresis and contracture precede the atrophy ; that is clinically established. Hence, there is reason to admit that the lateral sclerosis, to which they are due, is produced before the lesion of the anterior grey substance with which the amyotrophy is unquestionably connected.

Through what mechanism does the lesion of the grey substance become combined with the lesion of the white columns?

Does it take place through simple propagation, extending gradually across the neuroglia?

It is much more probable that the propagation is effected by means of the nerve-filaments which, you are aware, normally establish a communication between the lateral columns and the anterior cornua. The system of lateral columns tends to become affected in its entirety and very rapidly. But the lesion does not invade it, throughout, at one blow. Thus, so far as we can judge from clinical revelations, it first of all affects the department which is in physiological relation with the movements of the upper extremities. Later on, it reaches the department which is connected with the lower extremities; lastly, the group of cerebro-bulbar fasciculi is invaded in its turn.

It is remarkable that the alterations, of which the first and third regions are the seat, reach very rapidly the corresponding parts of the grey substance.

The muscles of the tongue, in fact, and those of the upper extremities especially, begin to waste a very short time after the appearance of parietic symptoms. It is not the same with respect to the system of fascicles relating to the lower extremities; in the latter case, the paralysis and contracture persist, for a long time, without the addition of amyotrophy. These are peculiarities which we can only point out, without endeavouring at present to offer any plausible explanation.

LECTURE XIV.

DEUTEROPATHIC AMYOTROPHIES OF SPINAL ORIGIN (CONCLUSION). HYPERTROPHIC CERVICAL PACHYMEINGITIS, ETC., ETC.

SUMMARY.—*Amyotrophy connected with descending lateral sclerosis consecutive on a circumscribed lesion of the brain and spinal cord. Illustrative cases.*

Hypertrophic cervical meningitis. Pathological anatomy: alteration of the meninges; of the spinal cord; of the peripheral nerves. Symptoms: painful period (cervical pains, rigidity of neck; formication and numbness; paresis; cutaneous eruptions); second period (paralysis, atrophy, hand-deformity ("griffe"), contracture, patches of anæsthesia; paralysis and contracture of the lower extremities). Characters which distinguish hypertrophic cervical pachymeningitis from amyotrophic lateral sclerosis.

Amyotrophies consecutive on locomotor ataxia. Peculiar form of muscular atrophy in such cases. Pathogeny.

Amyotrophy consecutive on sclerosis disseminated in patches.

Subacute spinal general paralysis. Analogies with infantile paralysis. Desideratum.

Amyotrophies independent of a lesion of the spinal cord, examples; pseudo-hypertrophic paralysis; saturnine amyotrophy.

New considerations relative to the topographic pathological anatomy of the spinal cord.

GENTLEMEN,—To conclude the history of amyotrophies of spinal origin, it remains for me to notice a certain number of facts relating to this subject, for which no place could be found in the preceding

lectures. This task accomplished, I shall commence the study of the muscular atrophies which depend upon lesions of the bulbus rachidicus.

I.

At the close of our last conference I endeavoured to prove, by taking clinical data as a basis, that, in amyotrophic lateral sclerosis, the symmetrical lesion of the lateral columns, whence paralysis and contracture result, is the first to make its appearance; whilst the alteration of the anterior grey substance, with which muscular atrophy is connected, would be a consecutive phenomenon. The propagation of the inflammatory lesion of the white columns to the grey substance most probably takes place, I added, by means of the nerve-tubes which, in the physiological state, establish a more or less direct communication between these two regions. Some of my auditors have, in reference to this, made a critical suggestion which, unquestionably, is not without its weight. Why, they object, do the scleroses (termed descending), which are produced in the lateral columns after different circumscribed cerebral or spinal lesions, not react, like primary symmetrical sclerosis, upon the anterior cornua, so as likewise to induce the development of muscular atrophy in the paralysed members?

It is, in truth, a character of the scleroses which supervene on partial lesions of the brain and spinal cord that the muscles shall remain, as a rule, free from nutritive disorder, or, at all events, that they shall only become emaciated in the course of time, owing to the prolonged functional inertia to which the paralysed members are condemned.

I am not in a position, gentlemen, to resolve the difficulty in a categorical manner. I shall confine myself to pointing out to you that the propagation of the lesions to the grey substance, in the case in question of lateral sclerosis, is far from being quite devoid of precedent, and that the muscles in the corresponding limbs do, then, suffer atrophy.

Thus, I have several times seen hemiplegias of cerebral origin, (following on blood-clot lesion, for instance), which were accompanied, contrary to the common rule, by more or less marked wasting in the paralysed limbs, supervening not long after the apoplectic invasion. And in some cases of this kind the autopsy allowed us to ascertain that the anterior grey substance—to which,

according to the theory stated, we should refer the trophic alterations of the muscles—participated in the sclerous alteration.

This fact, among others, has been very distinctly established in a case whose history I reported, some time since, to the Société de Biologie. The patient, a woman, aged 70, had been suddenly stricken with left hemiplegia, occasioned, as the autopsy showed, by the formation of a hæmorrhagic focus in the centrum ovale of the right hemisphere. Contracture very rapidly supervened in the paralysed members, and, barely two months after the attack, the muscles of both the lower and the upper extremities began to waste away, exhibiting at the same time a remarkable diminution of electrical contractility. The muscular atrophy made rapid progress and, simultaneously, the skin over every part of the paralysed members, wherever subject to the least pressure, became covered with bullæ and even with eschars.

An examination of the spinal cord showed the presence of descending sclerosis, occupying the left side and presenting the usual characters; but, in addition, in several points of the cervical and lumbar enlargements, the grey anterior cornu on the same side offered the marks of inflammatory action, and in these points, a large number of the great motor nerve-cells had suffered very considerable atrophy.¹

Dr. Hallopeau has collected at the Salpêtrière, in the wards of Professor Vulpian, a certain number of observations which are in complete accordance with the foregoing.

I consider also that certain more or less rapid muscular atrophies, which are produced in paralysed members in consequence of transverse dorsal myelitis, are due to the same mechanism, although the fact of a lesion of the grey substance has not yet, so far as I know, been verified *de visu*. I have described to you, when speaking of wounds of the spinal cord, a case which appears susceptible of such an interpretation.

Still, gentlemen, it is the fact that in consecutive spinal sclerosis, reaction on the grey substance is the exception, whilst, in symmetrical sclerosis, it is, as it were, habitual; and this is a difference I believe, for which, in the present state of things, no plausible explanation can be supplied.²

¹ 'Lectures on Diseases of the Nervous System,' vol. i, p. 53.

² I have taken care to remark elsewhere that lateral symmetrical sclerosis of the cord may exist, without participation of the grey cornua, and consequently

II.

But, I believe, I have gone sufficiently into the consideration of this question of amyotrophic lateral sclerosis, and it is, consequently, time to begin the description of some other forms of *deutero-pathic spinal muscular atrophy*. That form, a knowledge of which is unquestionably the most useful in practice, is the one which appears as a complication of *hypertrophic cervical pachymeningitis*, a morbid state which has engaged my attention for many years,¹ and which, quite recently, has been made the subject of a good monograph, by M. Joffroy, one of my students.²

This, gentlemen, is clinically a rather well-marked type; the symptomatology is usually distinct enough to allow a diagnosis to be made without great difficulty. I will add, in order the more to stimulate your interest, that we have not here to deal with a necessarily incurable affection. At this very moment, you can see, in my wards, a woman who, after presenting for five or six years all the symptoms which characterise cervical meningitis, and having been, consequently, long confined to her bed in a state of complete powerlessness, is now able to walk, and also to make use of her upper limbs to do some kinds of work. Recovery is, therefore, possible; true, it is almost always obtained with the drawback of some infirmities, which result from the deformities that the disease almost necessarily induces.

Α. I will, first of all, give you some details relative to the *lesions*.

a. Hypertrophic cervical meningitis, as its name indicates, consists of an *alteration of the meninges*, more particularly affecting the dura mater. As to the position of the lesion it is variable; but, it is the cervical enlargement of the cord which appears to be, in some sort, the chosen region. Alteration of the meninges is the primary fact, and cervical pachymeningitis is that which shall here alone engage our attention; but, later on, the cord itself, on the one hand, and, on the other, the peripheral nerves, which arise from the cervico-brachial enlargement, are affected in their turn.

It is probable that this is not a rare disease. According to all appearance, the cases formerly published by Laennec, Andral, without being accompanied by muscular atrophy. This is shown by, among others, several observations of Dr. Westphal relating to cases of progressive general paralysis.

¹ 'Société de Biologie,' 1871, p. 75.

² A. Joffroy, 'De la pachyméningite cervicale hypertrophique (d'origine spontanée),' Paris, 1873.

and Hutin, under the name of *hypertrophy of the spinal cord*, belong to cervical pachymeningitis. The fact is that when the rachidian canal is opened, in a case of this kind, one is struck on seeing the cord, at the brachial enlargement, presenting the aspect of an elongated, fusiform tumour, occupying from six to seven centimètres in height, and voluminous enough, consequently, to completely fill the osseous canal.

But, in reality, it is not a true hypertrophy of the cord that is before the eye; for, on transverse sections, properly made (fig. 25), it is easy to perceive that the cord, far from being hypertrophied is, on the contrary, flattened from before backwards, and that the thickened meninges are alone the cause of the apparent augmentation in size of the nerve-column.

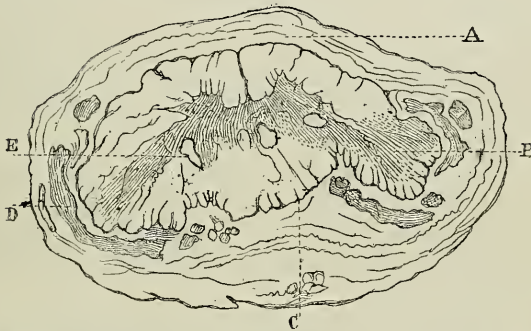


FIG. 25.—Transverse section, taken from the mid portion of the central enlargement of the spinal cord, by A. Castala ('Pachyméningite cervicale hypertrophique,' Thèse de M. Joffroy, loc. cit.).

A. Hypertrophied dura mater. B. Nerve-roots traversing the thickened meninges. C. Pia mater, confounded with the dura mater. D. Lesions of chronic myelitis. E. Section of two canals, newly excavated in the grey substance.

The pia mater is also affected, but to a much less degree than the dura mater. The latter, when closely examined, is seen to be composed of numerous concentric layers (it may attain six to seven millimètres); it is altered throughout its breadth, as is proved by the adhesions which usually unite it, externally, to the vertebral ligament, and internally to the pia mater.

Sometimes, the hypertrophied *pachymeninx* seems composed of two layers, an external and an internal one. The latter, which appears to be of new formation, is composed of a dense fibroid tissue; it is

therefore, very distinct from those soft and very vascular neo-membranes which, in the spinal dura mater, just as in the cerebral dura mater, but less frequently in the former than in the latter, enjoy the privilege of giving birth to hæmatomata.

b. The *spinal cord* participates in the alteration, and all the signs of transverse myelitis are found in it, irregularly disseminated, and attacking indifferently the central grey substance or the white columns.

c. The *peripheral nerves* are attacked, in consequence of the spinal lesion, in so far as it bears upon their radicular course and on the anterior cornua—and also, in their passage through the thickened and inflamed meninges. The peripheral nerve alteration, generally, affects the anterior roots as well as the posterior—a circumstance which requires to be borne in memory for the interpretation of the symptoms.¹

B. The foregoing considerations show that the lesion is nowise systematic, and indicate the possibility of variations in the clinical phenomena. Nevertheless, I repeat, the symptomatic group is, generally, rather easy to characterise.

a. It is not doubtful that the meninges are, first of all, affected, and soon afterwards the nerve-roots. The phenomena connected with this double lesion constitute a *first period*, or *painful period*, which lasts two or three months, the importance of which cannot be rendered too evident.

In the first place, we have extremely acute *pains*, which affect the back of the neck, extending up to the crown of the head, and spreading also to the upper extremities. These pains are accompanied by a sort of *rigidity*, especially marked in the neck, which is kept immovable, so as to recall what we see in sub-occipital Pott's disease.² They are well-nigh permanent, but from time to time exacerbations are experienced, under the form of paroxysms. They react frequently upon the joints which nevertheless are not, usually, subject to any swelling. Concurrently with these pains which, at moments,

¹ Participation of the posterior roots appears to be a condition necessary to the existence of the symptoms of the *painful period*. This was well shown in an observation recently presented to the Société de Biologie by M. Rendu. In this case, which is one of dorso-lumbar hypertrophic pachymeningitis, the posterior roots were spared, owing to the meningeal lesions being limited to the anterior portions of the dura mater, and, as a consequence, the painful symptoms were absent ('Bulletin de la Société Anatomique,' 1874, p. 598).

² 'Thèse de Michaud,' Paris, 1871.

may be extremely acute, and even horrible, *formications* and *numbnesses* are noticed in the upper extremities which, at the same time, are affected by a certain degree of paresis. Lastly, we shall occasionally find *pemphigoid* and *bullar eruptions* affecting the cutaneous surface.

b. The preceding symptoms appear, as you have understood, to depend especially upon an irritation of the peripheral nerves.

New phenomena, which constitute the *second period* of the disease, do not delay their appearance; they seem to depend, particularly, on the extension of the meningeal lesion to the spinal cord, and also on a more severe alteration affecting the peripheral nerves.

The limbs cease to be painful, but, on the other hand, they become *paralysed* and the muscles *atrophy*. The wasting bears nearly equally upon the whole extent of the limb—a phenomenon which recalls that we described when dealing with the question of amyotrophy from lateral sclerosis. However, to speak only of what concerns the hand and forearm, it is worthy of remark that, in pachymeningitis, the muscles included within the sphere of the innervation of the ulnar and median nerves are especially atrophied, whilst those which depend on the radial nerve are comparatively respected. As a result of this preponderance of wasting in certain groups of muscles, we have a sort of “claw” (“*griffe*”) in which extension of the hand is most marked. This *griffe* is not the exclusive appanage of cervical pachymeningitis, in which, indeed, it is not constantly found; but, as it is not observed in the other forms of muscular atrophy, it not the less constitutes an interesting element of diagnosis, and you know that, from this point of view, nothing should be neglected (fig. 26).

What is the cause of this comparative freedom of the dependencies of the radial nerve? I do not know. If it were found that the originating filaments of the ulnar and median nerves emerge from the cord further down than those of the radial, we could thus understand how the latter might, in cervical meningitis, remain outside the limits of the morbid region.

To these symptoms are superadded *contractures*, which seize upon the paralysed and wasted limbs; and often patches of *anæsthesia* make their appearance, on these extremities, and may extend to the upper portion of the trunk.

This is not all: the *lower extremities* become paralysed in their

turn, and are afterwards seized with contracture just as in primary lateral sclerosis; however, in contradiction to what we see produced

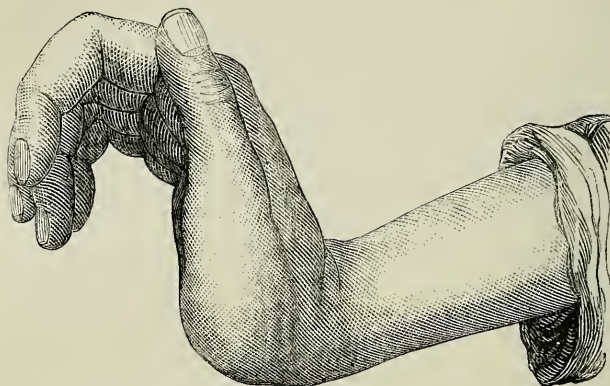


FIG. 26.—Attitude of the hand in cervical pachymeningitis.

in the latter affection, contracture of the lower limbs, in pachymeningitis, does not seem to be complicated with any muscular atrophy.

It does not appear to me difficult to supply the anatomical and physiological reason for this paralysis, and to comprehend, from this double point of view, the absence of muscular atrophy and the necessary existence, so to say, of the contracture in the paralysed members. The motor paralysis is here determined by the formation of a focus of transverse myelitis, which is produced consecutively to the meningitis. The spasmodic rigidity of the muscles depends on the descending sclerosis which, consecutively to the transverse myelitis, sooner or later takes possession of the lateral white columns, and, as in cases of descending consecutive sclerosis, the anterior grey cornua remaining, as a rule, absolutely intact, we can thus understand why the nutrition of the muscles is not directly involved.

The constant absence of amyotrophy is a feature which already distinguishes the paraplegia that accompanies amyotrophic lateral sclerosis from that which is connected with cervical pachymeningitis. I would add that, in the latter, we may observe the production of anæsthesia, rapidly developed bedsores, and disorders of the bladder and of the rectum, finally—a phenomenon that is absent from amyotrophic lateral sclerosis.

Many other distinctive characters, taken in connection with anatomo-pathological differences, would also enable us to clinically separate the two affections in question, in spite of the points of resemblance which bring them together. Thus, the groups of symptoms which constitute what I call the *painful period*, the partial, disseminated anæsthesias, and the bullar eruptions are the peculiar property of pachymeningitis; whilst, on the other hand, the participation of the medulla oblongata, which is very rare in the latter disease, appears, on the contrary, to be, as we have said, one of the necessary elements of amyotrophic lateral sclerosis.

III.

Enough has been said in reference to hypertrophic meningitis; at present, I propose to say a word concerning the amyotrophies that sometimes supervene in the course of *locomotor ataxia* and of *disseminated sclerosis*.

A. It is known that progressive amyotrophy, more or less generalised, is not a rare accompaniment of posterior sclerous myelitis. To be convinced of it, it will suffice to refer to the numerous observations where this coincidence has been noted, and, in particular to those published by MM. Duménil,¹ Virchow,² Marotte,³ Friedreich,⁴ Leyden,⁵ Foucart,⁶ Laborde,⁷ Pierret,⁸ and some others. It results from these observations that, clinically, this muscular atrophy of ataxic patients is distinguished by some special characters. Thus, it does not present the regular mode of invasion, nor the doomed progressive course, peculiar to progressive amyotrophy. Sometimes disseminated over the most diverse parts of the body, the muscular lesions, at other times, remain confined to very circumscribed regions, to the foot, for instance (Friedreich), to the leg (Leyden), to the back (Leyden, Friedreich), to the nape (Leyden), where they may merely occupy a single muscle, or even only a portion of a muscle. If the thenar and hypothenar eminences are sometimes affected (Foucart), they remain perfectly

¹ Duménil (de Rouen), 'Union Médicale,' 1862, No. 17.

² 'Virchow's Archiv,' Bd. viii, Heft 4, 1855.

³ Marrotte, 'Union Médicale,' 11 Juin, 1852.

⁴ Friedreich, 'Ueber Degeneratrophie der Spinalen;' Hinterstiange, 'Virchow's Archiv.' Bd. xxvi, xxvii, 1863.

⁵ Leyden, 'Die grauer Degener.' &c., Berlin, 1863.

⁶ Foucart, 'France Médicale,' &c., Nov., 1857.

⁷ Laborde, 'Soc. de Biologie,' 1859.

⁸ Pierret, 'Archives de Physiologie,' t. iii, 1870, p. 600.

normal in a large number of cases. Often the muscles of the lower extremities, affected with motor incoördination, are alone invaded (Laborde, Duménil). In the case noted in my ward, a report of

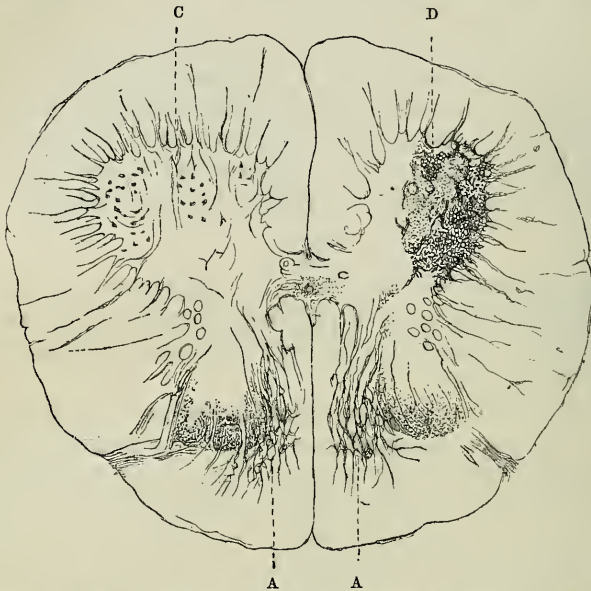


FIG. 27.—Section of the spinal cord in the lumbar region, in a case of ataxia complicated with muscular atrophy.

A. Sclerosis of the posterior radicular zone; left anterior cornu healthy. D. Right anterior cornu atrophied.

which has been published by M. Pierret, the atrophy affected the whole extent of both the upper and the lower extremities of the same side (fig. 27).

This mode of distribution of the muscular lesions is already a very peculiar phenomenon. It should be added that the symptoms of posterior sclerosis, such as the fulgorant pains, ocular disorder, and motor incoördination, &c., will be always present to throw light on the diagnosis.

I have several times mentioned the mechanism, according to which, in my opinion, the invasion of the anterior cornua is effected, in such cases. The irritation is propagated along the internal radicular bundles, whose course can be followed, anatomically, to the anterior grey substance.¹ Quite recently, M. Hayem has

¹ Charcot, 'Leçons sur les maladies du système nerveux,' 2^e serie, fascic. 1, 1873, p. 16. See *ante*, p. 16.

given experimental confirmation to this theory. Avulsion of the sciatic nerves, in the case of rabbits, results in a rent which takes place in the intra-spinal course of the posterior roots. As a consequence, inflammation is set up, which extends along these roots to the anterior grey cornua, where the groups of nerve-cells consecutively undergo great alterations.¹

In all known cases, the symptoms which attach to posterior sclerosis precede the development of the amyotrophy. I do not believe that a single example has been published in which the amyotrophy was, on the contrary, developed before the tabetic symptoms.

B. I will only make mention of the muscular atrophy which is sometimes superadded to the ordinary symptoms of disseminated sclerosis. It supervenes, according to my observations, in cases where the sclerous patches (which, as a rule, predominate in the antero-lateral columns), invade the grey cornua, and there produce profound alterations.

IV.

I cannot omit calling your attention to another form of myopathy, which M. Duchenne (de Boulogne) was the first to describe, a long time ago, under the name of *spinal general paralysis*, and which, speaking for myself, I as yet only know clinically.²

This affection, up to the present, has not occupied the position which it rightfully should take in clinical observation. Why is this? I cannot say, for the facts of this group are not very rare. It is an omission to be regretted. How often, in fact, has not this form of amyotrophy, which is almost always confounded with progressive muscular atrophy, been the occasion of errors in the diagnosis, and also, still worse, in the prognosis! Consulted on a case of this kind, and believing that it is a case of common progressive amyotrophy, you pronounce a verdict of "incurable" and, some months later, the patient may return to you, completely cured. Could there be anything better adapted to throw discredit on the physician? Allow me, therefore, to describe as tersely as possible, the principal characters of *subacute spinal general paralysis*.

This is a disease of adult life, for it makes its appearance at the

¹ Hayem, "Des alterations de la moelle, consécutives à l'arrachement du nerf sciatique chez le lapin" ('Archives de Physiologie').

² 'De l'Électrisation localisée,' 3^e édition, 1872, p. 458.

age of from 35 to 40. Hereditary influence appears to count for nothing in its production; but sometimes, just as in other spinal affections, the influence of cold or of a damp abode has been blamed.

Spinal general paralysis is encroaching, without being necessarily progressive, and recovery,—a complete recovery, as I indicated a moment ago—may be hoped for. Apart from their mode of invasion and progress, the incidents of the disease reproduce rather faithfully, as you will admit, the type of infantile paralysis.

The paralysis begins either by the lower or by the upper limbs, whence the course is sometimes ascending, sometimes descending. The motor inertia is accompanied by a well-marked flaccidness of the parts affected.

Some passing formication excepted, it is not complicated with any sensory disorders. The functions of the bladder and rectum are respected, whatever may be the extent of the paralysis, and no bed-sores are ever produced.

The atrophy, which does not long delay to show itself in the paralysed members, recalls what is observed in infantile paralysis. Although it predominates in certain muscles and groups of muscles, it yet attacks the entire limb, or a whole region of it. At the same time, the skin, over the paralysed and wasted parts, becomes cold, cyanosed, and mummified, as it were.

Lastly, and this is a distinctive feature which it is important to contrast with the classic symptoms of progressive muscular atrophy, the muscles, even those which have not undergone extreme loss of volume, present a remarkable diminution if not a total disappearance of faradaic contractility.

These muscles, which suffer so seriously as regards nutrition, may however occasionally, as experience demonstrates, recover all their functions. Nevertheless, it is rare not to find several of the most seriously stricken muscles remaining atrophied for ever.

It must not be forgotten that a favorable prognosis is not the absolute rule. In certain cases, in fact, the disease in its ascending course may invade the bulbous and there determine disorders analogous to those which we have mentioned in connection with symmetrical lateral sclerosis and which we find again in labio-glosso-laryngeal paralysis, properly so called. In such circumstances, the aspect of things is changed, and we may see the disease shortly terminating in death.

Another peculiarity ought to be known to you ; in its slow evolution, which sometimes covers several years, subacute spinal general paralysis is subject to illusory improvements and to relapses. This irregularity in the progress of the disease should arrest the attention of the physician and make him very reserved in his judgment.

I will, lastly, notice as a curious coincidence—which is not rarely observed in spinal general paralysis—namely, the occurrence of gastric disorders, supervening in paroxysms, which are analogous to those described under the name of gastric crises in connection with locomotor ataxia.

Its clinical aspect, judged from what precedes, would indicate for this type an intermediate place between the acute forms and the chronic forms ; but pathological anatomy has not as yet pronounced upon the question. It is most probable that it will contradict this classification in nothing. However, it becomes us to wait for its decree, before coming to a definite conclusion.

V.

I will not delay, gentlemen, after what has been said, to enumerate all the other possible forms of deuteropathic spinal atrophy,—that would take us far too long. The principles which I have endeavoured to render evident will, I think, suffice to guide you in the interpretation of most of the cases of this kind. But I cannot omit discussing, at least in a summary manner, certain amyotrophies which do not depend upon a spinal lesion, and which are yet susceptible of becoming generalised, and taking on a progressive course. Among the amyotrophies of this group, I shall only mention, as examples, the disease called *pseudo-hypertrophic paralysis*, and *saturnine amyotrophies*. I am far from wishing to enter particularly into this question, I intend solely to show that, as regards progressive amyotrophy, we must take care not to give way to a desire to explain everything, physiologically, by the lesion of the anterior grey spinal cornua. This lesion has its own pathogenic domain, which is already very vast ; it must not be excessively extended if we do not wish to run the risk of compromising everything.

Pseudo-hypertrophic paralysis, which is also termed *myo-sclerotic* is often met with, as you are aware, in young children ; some observations, however, tend to prove that it may also show itself in the adult.

However this may be, considering the disease clinically we may

distinguish two periods, which, in fact, have been noticed by other authors. The first period only lasts a few months, or a year at most; it is characterised by a sort of paresis of the lower extremities especially, due to loss of strength in the muscles, which as yet show no signs of seeming hypertrophy,¹ or which may even, sometimes, exhibit distinct atrophy.² In the second period, which is much longer, the paresis tends to become generalised, and moreover the affected muscles, chiefly those of the calves, augment in size and present an often enormous prominence.

All kinds of suppositions have been made in reference to the pathogeny of the affection in question. Of late, many authors have shown themselves inclined to look for the starting-point in the nervous system,³ and more particularly in the spinal cord. This, in reality, is an hypothesis which, in my opinion at least, is not founded on any solid basis. Already we see, that in a case presented to the Medical Society of Berlin, by H.H. Eulenberg and Cohnheim, a post-mortem examination of the nerve centres gave negative results. It is true that in this case, the spinal cord having been examined in the fresh state, or after insufficient hardening, very delicate lesions, such as atrophy of the motor nerve-cells and sclerosis of the anterior cornua of the grey substance, might, possibly, have escaped scrutiny.⁴ But the case which I published

¹ Duchenne (de Boulogne), 'Elect. localisée,' 3^e edition, p. 605.

² Pepper, 'Clinical Lectures on a Case of Progressive Muscular Sclerosis,' Philadelphia, 1871, pp. 14, 16.

³ This opinion was formulated in an old edition of Carpenter's 'Principles of Human Physiology,' edited by F. G. Smith, Philadelphia, 1855, p. 342, note.

⁴ 'Verhandlungen der Berliner Medicinischen Gesellschafts,' Berlin, 1866, H. 2, p. 161.

⁵ Charcot, "Note sur l'état anatomique des muscles et de la moelle épinière dans un cas de paralysie pseudo-hypertrophique," in 'Archives de Physiologie,' 1871—1872, p. 228.

The observation in question relates to a young patient attacked with *pseudo-hypertrophic paralysis*, who succumbed at the Hôpital Sainte Eugénie, in the wards of M. Bergeron, in consequence of an intercurrent disease. The history of this little patient is well known. It was related by Dr. Bergeron in a communication made to the "Société Médicale des Hôpitaux," in 1867 ('Bulletins et Mémoires de la Soc. Méd. des Hôp. de Paris,' t. iv, 1^e série, 1867, p. 157). Dr. Duchenne (de Boulogne) reproduced it in his memoir on pseudo-hypertrophic muscular paralysis ('Archives Générales de Médecine,' Janvier, 1868, *et seq.* p. 19, ch. xii). A good photograph of the patient standing, appended to Dr. Bergeron's paper, shows the exaggerated promi-

twenty years ago, in the 'Archives de Physiologie' is not open to the same objections, and it testifies absolutely to the same effect as that of M. Cohnheim.

nence presented by most of the muscular masses in the case of the boy in question, and enables us especially to understand the characteristic attitude which he assumed when standing (see also figs. 3, 4, and 9, in Dr. Duchenne's memoir). With reference to the clinical aspect of the case, I can do no better than refer to the works just mentioned. With respect to the state of the spinal cord, our observations were made on transverse sections, coloured with carmine, and prepared with great skill by M. Pierret. These sections have, besides, been very numerous, and were taken from different parts of the cervical and dorsal regions of the cord. I should here notice that the muscles which receive their nerves from the cervical enlargement were, for the most part, affected to a high degree, and that the deltoids, amongst others, exhibited most markedly the characteristics of hypertrophy by fatty substitution. If in this case, the muscular lesions had been connected with spinal lesions the latter should not have failed to show themselves well marked in the cervical enlargement of the spinal cord.

Now, the result was absolutely negative. We everywhere found the antero-lateral and posterior white columns in a state of perfect integrity; the grey substance, which was the subject of a very special investigation, presented no trace of alteration. The anterior cornua were neither atrophied nor deformed. The neuroglia retained its wonted transparence, and the motor cells, normal in number, did not present, in the several parts which go to constitute them, any deviation from the normal type. Let us remember that the spinal roots, both anterior and posterior, appeared also perfectly sound.

Having recognised the fact that the muscular alterations, in this case, did not depend on an alteration of the nerve-cells of the anterior cornua or of the nerve-roots, it was important to investigate whether or not they should be connected to some lesion of the great sympathetic or of the peripheral nerves. With respect to the first point, I can give no information, the great sympathetic not having been amongst the parts placed at my disposal. As regards the second, I must declare, after having carefully examined different fragments taken from the sciatic, median, and radial nerves, that these nerves seemed to me to present, in every part, the appearances of their normal condition. We even found, in the substance of the affected muscles, several nerve filaments, which also appeared to us entirely free from all change. Quite recently, two most competent observers, Messrs. Lockhart Clarke and W. Gowers, presented to the Royal Society of London a case which, considered from an anatomico-pathological point of view, appears to be in direct contradiction with the foregoing ("On a Case of Pseudo-hypertrophic Muscular Paralysis," in 'Medico-Chirurgical Transactions,' vol. lvii, London, 1874). But I would point out that, in the observation of these English authors, the spinal lesions found on autopsy, and chiefly constituted by *foci of disintegration*, only occupied in a very accessory, and as it were, accidental manner, that region of the cord (anterior grey cornua, and anterior radicular fascicles) which alone have any direct influence over the nutrition of the muscles, so

According to these observations, pseudo-hypertrophic paralysis ought to be considered as independent of all perceptible lesion of

that the spinal lesions, in this case, seem to me to have been in some sort fortuitous. At the very least, it does not appear to me they could have been the starting-point of the marked alterations of the muscular system.

An observation published, three years ago, in the 'Archiv der Heilkunde' ("Beitraege zur Kenntniss der atrophia musculorum lipomatosa," Leipzig, 1871, p. 120), by H. O. Barth, would also tend to include *pseudo-hypertrophic paralysis* in the group of spinal myopathies. In fact, the autopsy, made with the greatest care, places beyond doubt the fact of the existence of well-marked spinal lesions; nevertheless, I am far from believing that this fact has the significance attributed to it. The patient was a man, aged about forty-four, who experienced in 1867, three years before the fatal termination, the first symptoms of motor paralysis in the lower limbs. Two years after the invasion, the patient was confined to bed, and had lost nearly all power of motion. With the progress of the motor paralysis, more or less acute pains, and disagreeable formications occupied the limbs; in addition, the paralysed muscles exhibited great atrophy and became, in certain parts, the seat of very marked fibrillary contractions. Finally, the movements of articulation and deglutition became difficult.

In the course of the last months, several of the atrophied muscles, particularly the adductors of the thumb and the muscles of the calf, underwent a remarkable increase in size, although the motor impotence persisted to the same degree.

At the autopsy, the muscles of the extremities mostly exhibited, in different degrees, the characters of fatty degeneration.

As to the *muscular bundles*, some of them showed the alterations of simple atrophy, others, fewer in number, those of fatty granular degeneration. In the interval between the bundles, there was a certain degree of consecutive hyperplasia in several points. An examination of the spinal cord furnished some interesting results: the lateral columns were sclerosed, symmetrically, throughout their whole height, from the superior extremity of the cervical enlargement to the inferior extremity of the lumbar region.

The anterior cornua of the grey substance were evidently atrophied; in addition a good number of the large motor nerve-cells presented more or less marked atrophy and many of them had even disappeared.

Lastly, it was found that a large quantity of adipose tissue had accumulated under the skin of the members and on the surface of most of the viscera. It seems to me quite legitimate to refer the observation, the principal traits of which I have just summarised, to the classic type of pseudo-hypertrophic paralysis.

The comparatively advanced age of the patient, the existence of acute pains and of formications in the limbs, the fibrillary contractions, the difficulty of utterance and of deglutition—all these symptoms would, if need be, protest against such an association. On the contrary, they very naturally connect with the morbid type, to which I have called attention in the last two lectures, and in which—as occurred in the lesion reported in the observation by H. O.

the spinal cord; I would add that, in my own case, the nerve-roots and also the peripheral nerves showed themselves, as here, quite free from all alteration. Hence, it is in the muscle itself that we should seek the starting-point of the lesions, whence arise the symptoms observed during life.

In connection with the muscular changes in pseudo-hypertrophic paralysis, here are some details taken from my work (*loc. cit.*), and which will doubtless not seem to you devoid of interest.

What first strikes the eye, in those muscles in which it was pos-

Barth—the symmetrical sclerosis of the lateral columns is combined with progressive atrophy of the nerve-cells of the anterior cornua.

Undoubtedly, the muscular lesions described in the case of H. O. Barth recall, to some extent, those which are uniformly found in all cases of hypertrophic paralysis hitherto published. But this circumstance would not, of itself, be sufficient to justify a nosographic association. In reference to this, I think I ought to make a remark which might appear a truism, if the fact to which it refers had not been misunderstood. It is this, namely: none of the muscular lesions in question are absolutely the peculiar property of pseudo-hypertrophic paralysis, and would not consequently suffice to identify it. Thus the hypertrophy of the interstitial connective with simple atrophy of the muscular fibres may be met with, for instance, after traumatic lesions of the nerves (Mantegazza, 'Gazetta Comb.,' p. 181, 1867; Erb, 'Deutsch Archiv,' t. iv, 1868), and in some cases of infantile paralysis. (Volkman, 'Samml. Klin. Vortraege,' Leipzig, 1870; Charcot and Joffroy, 'Archives de Phys.,' t. iii, 1870, p. 134). As to the fatty substitution with or without augmentation of size in the muscle, it may also occur, as an eventual complication, in infantile paralysis (Laborde, 'Thèse Inaug.,' 1864; Prevost, 'Soc. de Biologie,' 1865, t. xvii, p. 213; Charcot et Joffroy, *loc. cit.*; Vulpian, 'Archives de Phys.,' t. iii, 1870, p. 316; W. Muller, 'Beiträge zur Path. Anat. der Rückenmarks,' Leipzig, 1870, Obs. II); in progressive muscular atrophy; in spinal paralysis of the adult (Duchenne, de Boulogne, *loc. cit.*); and in many other circumstances which it would take too long to enumerate. It is to be noticed that, in such a case, the fatty substitution of the muscle appears sometimes to be attached to a *generalised lipomatosis*, which especially betrays itself—as we find exemplified in Herr Barth's case—by the accumulation of adipose tissue under the skin and in the visceral cavities. Quite recently H. W. Muller (*loc. cit.*) has rightly insisted on this point. But I dissent altogether from the author just mentioned when, refusing all autonomy to pseudo-hypertrophic paralysis, he maintains that all the cases which have been grouped under this name—artificially grouped according to him—might be withdrawn by a critical examination, and classified under one of the forms of amyotrophy connected with atrophy of the motor nerve-cells. Nothing, in my opinion, is less justifiable than this opinion; and the very case which is the principal subject of the present note would of itself suffice to demonstrate its inanity.

sible to exactly study the first phases of the morbid process, is that the thin strips of connective tissue—depending on the *perimysium internum*—which, in the normal state, barely separate the ultimate muscular fibres and leave them almost in reciprocal contact, are here replaced by thick septa, the short diameter of which, in some places, equals that of the muscular fibre, and even exceeds it (fig. 28).

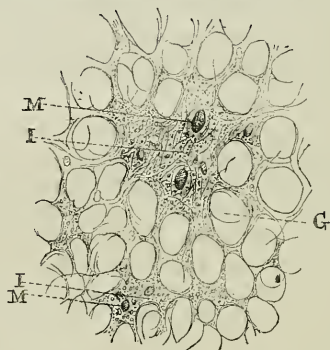


FIG. 28.—Transverse section of a muscle, in pseudo-hypertrophic paralysis (intermediate stage between the first and second period of the morbid process). I, I. Islets of connective tissue. M, M. Section of muscular fibres. G, G. Adipose cells.

These septa, as you may convince yourselves particularly by the examination of dissociated longitudinal sections, are constituted by connective tissue of recent formation, where the laminar fibres, especially disposed in a direction parallel to the long axis of the muscular fibres, are often intermingled with embryo-plastic cells, rather numerous present.

The interposition of adipose cells between these fibrillæ marks a new phase of the process (fig. 28, G). The cells are, at first, scattered, isolated, and, as it were, lost amid the bundles of fibrillæ; but their number increases, on certain points, in such proportions that they take the place of the fibrils, which finally disappear completely. This fatty substitution, already outlined, as it were, in some places on non-hypertrophied muscles, becomes almost general on those in which the increase of size is much marked. In the latter case, a microscopical examination shows the greater portion of the surface of the sections to be occupied by fat cells, almost in contact throughout, heaped on the top of each other and rendered polyhedral by reciprocal pressure.

Here and there, amid the adipose tissue, we meet— i^o , either

islets composed of primary (ultimate) muscular fibres (of from 2 to 8, 10, or 12 at most), entirely enveloped by connective fibrillæ (fig. 28, 1); or 2°, isolated fibril-tracts without muscular fibres; or 3°, finally,—and the last is the rarest—with isolated muscular fibres, deprived of their fibrillary envelope and placed in immediate relation with the cells of the adipose tissue (fig. 29).

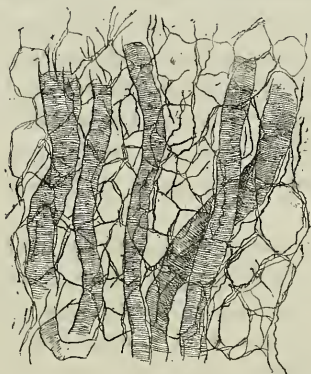

FIG. 29.—Longitudinal section of a muscle, in pseudo-hypertrophic paralysis (second period of the morbid process). Fat cells in contact throughout and rendered polyhedral by pressure. Isolated muscular fibres, deprived of their fibrillary envelope and placed in immediate relation with the cells of adipose tissue. The muscular fibres, even to the smallest of them, have preserved their cross striation.

In short, the fatty substitution evidently represents the ultimate phase of the morbid process, and, according as it advances, the new-formed fibrillary tissue, together with the muscular fibres, tends to disappear.¹

¹ According to Duchenne de Boulogne (loc. cit., p. 603) and Foster ('The Lancet,' May 8, 1869, p. 630) the apparent hypertrophy, observed in the last stages of the disease, would be due to the connective hyperplasia. "This it is," says Duchenne, "which produces the increase of volume in the muscles, in direct ratio with the quantity of connective and interstitial fibroid tissue formed by hyperplasia. This opinion is founded on the results several times obtained on examining morsels of muscle extracted, during life, by means of the *emporte-pièce histologique*. But, it may be asked whether, in this little operation, the islets of tissue are not taken in preference, by the instrument, which would, on the contrary, find more difficulty in laying hold on the clusters of fat-cells. It is constant that, in cases where fragments of hypertrophied muscles were extracted, during life, by incision, these have also exhibited, in a high degree, the histological characters of fatty substitution (Griesinger and Billroth, Heller and Zenker, Wernich. See Seidel, 'Die atrophie musculorum lipomatosa,' Jena, 1867). The impres-

As regards the latter, the alteration which issues in their complete disappearance is already present in the first period, when hyperplasia of the interstitial connective tissue begins, irrespective of any trace of fatty substitution. It consists in a more or less marked diminution of the diameter; many of the fibres are so atrophied that it requires the greatest attention to distinguish them in the substance of the interstitial connective tissue. The greater portion of them, however, even those which have undergone the greatest atrophy, preserve to the ultimate limits of emaciation their cross striation most distinctly evident. Neither the sheath of the sarcolemma, nor the nuclei which it encloses, present any alteration, and, as regards the muscular substance, it exhibits no trace of granulo-fatty degeneration.

You cannot fail to have been struck by the analogy between the muscular alteration which has just been described and that which, when viscera are in question, is generally designated by the name of cirrhosis. Now, the lesions of muscular sclerosis are observed in very various conditions; and they may, in particular, present themselves, accidentally it is true, in different forms of deuteropathic spinal amyotrophy. This circumstance alone, namely, that the invasion of adipose tissue occurs, at a certain epoch of the pseudo-hypertrophic paralysis, as if inevitably, seems to me to constitute a really distinctive character; so that the term *myo-sclerotic* proposed by Duchenne (de Boulogne) should in strictness be only applied to the first periods of the disease, whilst that of *atrophia musculorum lipomatosa* (Seidel), of *lipomatosa luxurians* (Heller), which are somewhat generally employed by German authors, would only apply to it at an advanced period.

VI.

The history of pseudo-hypertrophic paralysis furnishes us, as a lesson which I have received, after frequent examination of the pieces which I have studied, is that hyperplasia of the connective tissue and atrophy of the muscular fibres advance, as it were, by equal stages; the latter showing itself all the more general and more marked in proportion to the extent of the spaces left vacant by the atrophy or disappearance of the muscular fibres. It is, however, possible that the connective hyperplasia may sometimes take the upper hand and thus produce a certain degree of seeming hypertrophy. But I find it difficult to comprehend how it could ever account for the often enormous increase of volume which the muscular masses exhibit at a certain epoch of the disease, and I am induced to believe that substitution of fatty tissue here plays the principal rôle.

you see, with an example of generalised myopathies, having a progressive course, which develops, irrespective of any influence of the nervous system. In the *amyopathies of saturnine origin*, on the contrary, the amyotrophy appears to be produced in consequence of a lesion of the peripheral nerves. The existence, in such circumstances, of an alteration of the nerves proceeding to the paralysed and wasted muscles, was noticed for the first time, if I mistake not, by M. Lancereaux.¹ This same alteration has been again met with in the case of a female patient in my wards, stricken with lead palsy, by M. Gombault, my clinical clerk, who, in addition, after a strict and methodical examination, ascertained the absence of all spinal lesion in this instance.²

The results obtained by M. Gombault have been entirely confirmed by a very interesting observation, recently published by H. Westphal.³ Saturnine muscular atrophy seems therefore arranged, according to this, on the same model as the *partial rheumatic amyotrophies*, or *amyotrophies of traumatic origin*, inasmuch as it, also, seems to depend on a lesion of the peripheral nerves, and this association will appear all the more legitimate because, in both cases the amyotrophy is marked, as you are aware, by decrease or even by a more or less rapid abolition of *faradaic contractility*.

However this may be, I know not if there at present exists, lead-wasting apart, a well-verified example of generalised amyotrophy arising from an alteration of the peripheral nerves. I am aware that, under the name of *progressive nervous atrophy*, the description has been given of an affection, characterised by atrophy of progressive evolution, arising from a lesion of the nerves, without participation of the spinal cord. I see no reason which should authorise the denial, *a priori*, of the existence of such an affection.⁴ But, I should add that, at the moment, this chapter of nosography seems to me somewhat to resemble a frame without a picture. There does not, in reality, exist, to my knowledge, at least, a single published observation in which anatomical

¹ Lancereaux, 'Société de Biologie,' t. iv, 3e serie, 1862-3, p. 75.

² Gombault, in 'Archives de Physiologie,' t. v, 1873, p. 592.

³ Westphal, 'Archiv f. Psychiatrie,' iv Bd., 3e Heft, 1874, and 'Progrès Médicale,' 1874, p. 553.

⁴ M. Joffroy and M. Pierret have each recently communicated to me a case in which a generalised atrophy, rather ill characterised clinically, would seem to be connected with lesion of the peripheral nerves. The spinal cord was quite healthy in both cases.

demonstration has been given of this neuritis, or this progressive nerve atrophy, whence the form of amyotrophy in question should arise. The observation of M. Duménil, interesting in its way, which has been relied on, in this matter, has not the significance attributed to it. In this case, in fact, in addition to the lesion of the peripheral nerves, there existed in the spinal cord very serious alterations of its central grey substance, and particularly of the motor nerve-cells. Consequently we have a right to ask whether the spinal lesion may not have been the first in date.

Remarks of the same kind may apply to the cases published by several authors, where progressive amyotrophy is represented as the consequence of an alteration of the great sympathetic. It is not doubted that lesions of the great sympathetic, both of the *rami communicantes* and of the *ganglions*, have been several times observed in progressive muscular atrophy; but I am not aware that, in any of these cases, the non-existence of a lesion of the nerve-cells of the anterior cornua has ever been methodically established. On the other hand, it is constant that lesions of the great sympathetic are often absolutely deficient in the most varied forms of progressive spinal amyotrophy. This is peremptorily established by, amongst other proofs, the observations collected at the Salpêtrière, by Dr. Lubimoff, of Moscow, and published in the 'Archives de Physiologie' (1874).

VII.

Here terminates, gentlemen, the statement of the considerations which I desired to lay before you in reference to spinal amyotrophies. On our way, you have been able to assure yourselves, if I do not mistake, that the history of these affections has been placed in a new light, owing to the results supplied by recent researches relating to the topographic pathological anatomy of the spinal cord.

The particular characteristic of these studies has been, you remember, to press onward, with equal steps, and in close connection, clinical work and pathological anatomy. It seems opportune to show you, in a brief summary, since the occasion presents itself, the principal acquisitions which are due to these investigations.

In a general manner, they tend to establish that the spinal cord

is composed of a certain number of regions, answering in some sort to so many organs endowed with special functions. The spontaneous, isolated lesion, whether general or partial, of each of these organs is manifested and revealed, during life, by so many particular symptomatic compounds, which can, at present, be correlated by diagnosis to their organic origin. Thus are constituted, in spinal pathology, a certain number of elementary affections, the combination of which produces complex forms. The latter may, in their turn, by means of clinical analysis, be decomposed and resolved into their constituent elements.

Experimentation had already, and for some time, shown the way and had even determined a certain number of these fundamental regions to which I have just alluded. But it had not at all advanced so far as pathology has been able to advance with the assistance of the potent means of anatomical investigation which we now possess.

I place before you a kind of topographic chart, where you will see, indicated by different tints, the several regions of the spinal cord which have hitherto been explored by the pathologist. The *terra incognita* are left blank; their extent, as you perceive, is still great; but, it tends to become less, day by day. This is far from being a complete *chart*, or even remotely comparable to our improved modern geographical maps; however, it is, perhaps, a sketch superior, in some respects, to the attempts of a Strabo or a Pomponius Mela.

You remark the old *posterior columns* decomposed into two very distinct regions: 1° *Goll's columns* (fig. 30), whose separate lesion has been several times observed; it corresponds to a symptomatic group, which will doubtless be soon clearly determined and take its place in the clinical series; 2°, the *posterior radicular zones* (fig. 30, B, B), the anatomical substratum of progressive locomotor ataxia.

The *antero-lateral columns* of authors must, in their turn, be decomposed into three regions: 1°, the *lateral columns proper*, A, A; they show themselves systematically affected, throughout their whole extent, on both sides of the cord, in the case of *symmetrical lateral sclerosis* and, partially, on one side of the cord only, in *descending sclerosis*, consecutive on circumscribed cerebral or spinal lesions (*en foyer*).

2°, Türck's columns, A'; their pathology is nearly always confounded with that of the lateral columns; 3°, the *anterior radicular*

zones, F; they have been left blank. It has been, however, established by some observations that they can be affected separately

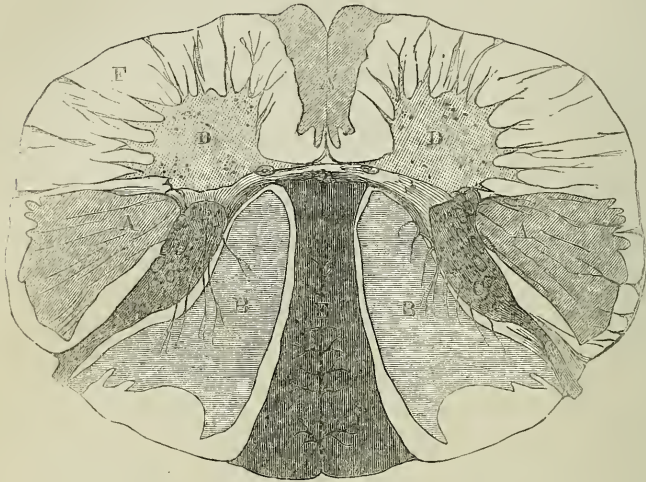


FIG. 30.—A, A. Lateral columns. A'. Türck's columns. B. Posterior radicular zones. C, C. Posterior cornua. D, D. Anterior cornua. F. Anterior radicular zone. E. Goll's columns.

from the rest (fig. 31, A). The alteration was represented in such cases, as might have been foreseen, by paralysis with amyotrophy in the member corresponding to the affected region of the spinal cord.

With respect to the grey substance, we know but ill the effects of an isolated lesion of the *commissures*; and, as regards the posterior cornua (fig. 30 C), we only know that, when they are the seat of serious alteration, a more or less marked cutaneous anæsthesia is produced in parts of the body situated on the same side as the spinal lesion. Our knowledge is more advanced in reference to the pathological rôle of the *anterior grey cornua*. It is, in fact, well established to-day that they may be affected separately, primarily; or, on the contrary, in a secondary manner, and it is known that, in both cases, if the alteration bears upon the *great motor cells* the production of amyotrophy necessarily follows.

The latter is developed with rapidity, if the spinal lesion be evolved in an acute manner (*infantile spinal paralysis*); or, on the

contrary, slowly and progressively, if its evolution be of a chronic character (*protopathic spinal atrophy* ; *amyotrophic lateral sclerosis*,

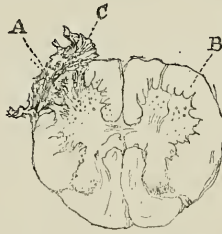


FIG. 31.—Transverse section of the lumbar region of the cord, from a patient the muscles of whose left lower extremity were paralysed and atrophied.

A. Left *radicular zone*, partly sclerosed. B. Right radicular zone, healthy
 c. The meninges, at this part, thickened and inflamed. The corresponding anterior cornua is, on the contrary, free from alteration (case communicated by M. Pierret).

&c). The anterior grey cornua (*motor nerve-cells*) and the anterior radicular zones (*intra-spinal course of the anterior roots*) appear to be the only regions of the spinal cord which directly affect the nutrition of the muscles.

Such is the state of affairs at present. I know not if I delude myself, but it seems to me that the results which have been acquired, all imperfect though they are, allow us already to anticipate a brilliant future for spinal pathology.

PART FOURTH.

V A R I A.

SPASMODIC TABES DORSALIS. URINARY PARAPLEGIAS,
PARTIAL MENIÉRE'S VERTIGO. POST-HEMIPLEGIC
CHOREA. EPILEPSY OF SYPHILITIC ORIGIN.

LECTURE XV.

ON SPASMODIC TABES DORSALIS.

SUMMARY.—*Provisional denomination ; its justification ; symmetrical and primary sclerosis of the lateral columns. Spasmodic tabes dorsalis, and ataxic tabes dorsalis. Parallel between the two affections. Characteristics of gait.*

On contracture and trepidation in spasmodic tabes dorsalis. Absence of sensory disorders. Invasion. Evolution. Mode of invasion in the limbs. Prognosis and treatment. Diagnosis : disseminated sclerosis (spinal form), hysterical contracture, transverse myelitis, lateral amyotrophic sclerosis, &c.

GENTLEMEN,—I shall to-day cause several patients to pass before you, in whom you can study at your leisure, the symptoms of a peculiar spinal affection radically distinct, in my opinion, from all the other forms of chronic myelitis with which it has been hitherto confounded. This affection, which I would propose to designate, at least provisionally, by the name of *spasmodic tabes dorsalis*, is not very rare, and certainly there is not a physician who has not frequently met with it in his practice. But, it has not, I think, been observed as it deserves. In fact, so far as I know, only one author, Dr. Erb (of Heidelberg), has mentioned it in a special manner, and endeavoured to determine its character. You will read with advantage, in the ‘*Berliner Klinische Wochenschrift*’ (No. 26, 1875), the short but substantial description which he has given of it.¹

¹ “Ueber einen wenig-bekanntem spinalen symptom-complex,” in ‘*Berlin Klin. Wochensch.*,’ No. 26, 1875. Consult, on the same subject, an interesting work recently published by H. O. Berger, of Breslau (“*Zur Pathologie und Therapie der Rückenmarkskrankheiten-Primäre-Sclerose der Seitenstränge*,” Separatabdruck aus der ‘*Deutschen Zeitschrift für Praktische Medicin.*’)

I.

It will not be out of order, in commencing, to endeavour to justify in a few words the denomination, that may appear strange at first sight, which a moment ago I proposed we should adopt to distinguish this pathological form. The affection in question depends, I concede, and this indeed is scarcely open to discussion, on an organic *substratum*, a more or less grave anatomical lesion situated in the spinal cord. It is likewise certain that this lesion, to judge merely from the nature of the symptoms, acts particularly on the lateral spinal columns.

It is lastly possible that, according to a remark made by Dr. Erb, the spinal alteration in question may be nothing other than the systematic lesion, first described by L. Türk and which I, in my turn, have long since made known under the name of *primary and symmetrical sclerosis of the lateral columns of the spinal cord*. But, be it remembered, the observations in which primary symmetrical lateral sclerosis, without participation of the anterior grey cornua,¹ has been anatomically established and in which clinical observation had, during life, revealed the existence of symptoms that to-day appear to be attributable to the spasmodic dorsal tabetic group—these observations, I say, owing to a curious concurrence of circumstances, are all of comparative old date.

They are in some sort old memories, which have become a little indistinct, and require to be refreshed. Hence, I think that it will be prudent to await their verification by autopsies, before deciding to name the disease from any anatomical character.

On the other hand, the old appellation of *Tabes dorsalis*, in spite of the rather vague meaning always attached to it, may serve well enough to designate at least a primarily chronic spinal affection which, like that before us, advances almost as of necessity though slowly, and which, after the manner of locomotor ataxia with which it may be paralleled on more than one point, rarely shows mercy to its victim.² As to the adjective *spasmodic* it is employed to give

¹ Symmetrical lateral sclerosis, with participation of the anterior cornua, is the anatomical substratum of the very distinct affection described by Professor Charcot under the name of *amyotrophic lateral sclerosis* (*ante*, Lectures XII, XIII).

² “*Tabes Dorsalis*” (Sauvages, ‘*Classis*,’ x, I, i), or “*Dorsualis*,” (Romberg, ‘*Lehr. der Nervenkrankh.*,’ Berlin, 1851, p. 185). The descrip-

prominence to the dominant clinical phenomenon; I allude to the contracture which, almost from the beginning, occupies the affected members, soon becomes permanent, and in some sort constitutes symptomatically, nearly the whole disease. In fact, whilst progressive locomotor ataxia, which might by way of opposition be called *ataxic tabes dorsalis* as I proposed, first of all attacks the sensory spinal system (fulgurant pains, patches of anæsthesia, and of hyperæsthesia) and only secondarily determines, in the great majority of cases, incoördination of the movements, spasmodic tabes, on the contrary, remains confined through nearly the whole duration of its course to the motor machinery. It is especially characterised, in short, during its stage of complete development, by permanent contracture, which gradually increases and sooner or later renders the limbs powerless, without ever being accompanied by any marked disturbance of sensation.

What we have just said is sufficient to show that, at present, spasmodic tabes has as yet no real existence except in the clinical domain, as was, indeed, long the case with respect to locomotor ataxia. It is true that it generally offers itself to the clinical eye with features marked enough to allow of its being almost always possible to distinguish it, in practice, not alone from the great systematic spinal disease, termed progressive locomotor ataxia, but also from *amyotrophic lateral sclerosis*, from *common transverse myelitis*, from *myelitis from compression*, and lastly, though often with great difficulty, from *disseminated sclerosis, spinal form*. In other words, it may be separated from all the spinal affections which in the description given by Ollivier (d'Angers)—a remarkable one in its way—are collected into a heterogeneous group under the name of *chronic myelitis*,¹ and which clinical analysis, enlightened by pathological anatomy, tends daily to disentangle.

If, in fact, analogies be frequent amongst the several pathological states which I have just enumerated, differential characters are themselves not deficient. I hope to succeed in demonstrating this immediately. But I think it opportune, as a preliminary, to offer you a description in which I shall try to depict prominently

tion given by Romberg refers, as is known, to locomotor ataxia, "*Tabes accipitur commune pro omni corporis aut partis extenuatione*" (B. Castelli, 'Lexicon medicum, Gen.,' 1745, art. "Phthisis").

¹ Ollivier (d'Angers), 'Traité des maladies de la moëlle épinière,' 3e edit., Paris, 1837, t. ii, p. 426.

the dominant symptoms and the usual mode of evolution in spasmodic tabes. In the course of this description I shall, at every step, keep in view the clinical history of locomotor ataxia, which will serve in some sort to bring out the contrasts.

I would first of all remind you of the principal phenomena which denote the early stages of locomotor ataxia—I mean, of the ordinary form of the disease—that which belongs to the classic type created by Duchenne (de Boulogne). In the first rank, and long before the motor incoördination, whence the disease gets its name, appears, come the different disorders of sensation: shooting and piercing pains, returning in paroxysms, and affecting the limbs, the face, and the trunk; permanent fixed pains in certain points; partial anæsthesias and hyperæsthesias. The *cephalic* disorders, such as amblyopia or amaurosis, and paralysis of the motor muscles of the eye, likewise belong to this period. Lastly, incontinence of urine, dysuria, gastric crises, often testify already, in this period, to the participation of the visceral nerves.

Quite different, from the beginning, is the physiognomy of spasmodic tabes dorsalis. Here, the first and for long the only symptom consists in a paretic condition, affecting equally both the lower extremities or more marked in one of them, and which has at first no other effect than to make walking rather difficult, especially in the morning or evening. The patients depict the situation by saying that they grow quickly fatigued, and that, whilst walking, they *drag the leg*. To that paresis is soon superadded a more or less marked tendency to muscular spasms.

Then, in the horizontal position, whilst in bed for instance, the affected members commence to stiffen more intensely from time to time, in paroxysms, especially in the movements of extension and adduction. They become, momentarily, like rigid inflexible bars. They are often, besides, without visible cause, taken with a trepidation, which sometimes remains limited to the extremities, and sometimes spreads over the whole extent of the limb, and may even affect the entire body (*spontaneous trepidation*). This trepidation may be provoked by the physician at will, as it were, by abruptly turning up the extremity of the foot, or toes, with the palm of the hand (*provoked trepidation*). The rigidity—and the same thing may be said of the trepidation—becomes more striking when the patient gets out of bed and stands up. It grows an ever greater hindrance to walking in proportion as, owing to the progressive aggravation of

the disease, it grows more developed and tends to become permanent.¹ But not till it has arrived at an advanced stage, and often after many years, does it definitely render walking quite impracticable. I confine myself to indicating these different phenomena without entering into a regular description because we have already studied them at length in connection with disseminated sclerosis, where they are found in full detail.¹

Still, whatever may be the intensity of these symptoms affecting motion, sensation remains unharmed—no anæsthesia, no hyperæsthesia—no disorders of cutaneous sensibility, of whatever kind, nor of the sensibility of the parts situated beneath; no lumbar pains, no girdling pains, no formication, numbness, nor feeling of constriction in the limbs; or, at most, these symptoms, if they exist, are so slightly marked that they must evidently be relegated to the background; finally, no lightning nor piercing pains. Again, the symptoms, which we term cephalic, are, likewise, completely absent; and it is nearly the same as regards disorders of bladder and rectum of any note. Lastly—and this is a feature which it is not uninteresting to remark—the genital functions which, in the male, are so often seriously attacked when locomotor ataxia is concerned, usually continue active, so to speak, to the last, and in nearly the normal condition, in the case of patients affected with spasmodic tabes.

The demarcation between the two affections becomes probably more striking still, in the more advanced phases of their evolution. Usually, you are aware, the second period of locomotor ataxia is made to date from the moment when the phenomena of locomotor ataxia are superadded to sensory disorders and to the other symptoms which we just now enumerated. Then it is that we find manifested, on the occurrence of voluntary acts, those contradictory, disorderly movements of the lower extremities, which are so exaggerated, when the patient is placed in the dark, as to render walking or standing very difficult, or even wholly impossible, the peculiar character of which had already so strongly attracted the attention of the predecessors of Duchenne.

The locomotor disorders become more distinctly defined in tabes

¹ When the contracture has become permanent it exists even when the patient is in bed; but it shows itself more intense when the patient attempts to get up and walk. If he be seated on a somewhat high arm-chair it often happens that his legs will remain horizontally extended, scarcely inclined, and that his feet shall not touch the floor.

¹ 'Lectures on Diseases of the Nervous System,' 2nd edition, vol. i, p. 195.

dorsalis, as the disease advances and gets worse; but they are characterised here according to a quite different type.

We do not find in *tabes dorsalis* those supple limbs, flexible to excess, appearing sometimes as if dislocated, that unbridled profusion of movements which give to the walk of the ataxic patient its characteristic look; and, in consequence of which, the feet, projected forward and outward, fall at every step heavily back upon the floor, with a stamp. Here, on the contrary, the lower extremities, rigid in every joint, energetically drawn together, cannot separate save after efforts in which the pelvic muscles seem to play the chief part and during which the trunk is thrown backward. The feet, during this time, are not detached, save with great trouble, from the floor, to which they seem strongly to adhere, producing as the patient advances a rubbing or shuffling sound, catching in the least obstacle, and often becoming entangled together. They are frequently, in addition, stirred by the trepidation which may extend to the root of the member, and may even, sometimes, communicate to the entire body a kind of vibration. The patient advances in this way, assisted by a cane or by crutches, slowly and laboriously. But yet the gait is firm enough, and it is a noticeable fact that, contrary to what would occur in ataxia, it is nowise modified on closing the eyes.

This very peculiar gait, which I am trying to depict, I have enabled you to study, which is better, upon the living model. It had already been remarked by Ollivier (d'Angers), who drew a successful picture of it in a passage which I cannot omit to quote:

"Each foot," he says, "is withdrawn with trouble from the ground, and, in the effort which the patient then makes to lift it entirely and to advance it, the trunk is raised erect and thrown backward as if to counterbalance the weight of the lower extremity which is shaken by involuntary trembling before it be rested anew upon the ground. In these advancing movements, sometimes the point of the foot is lowered and drags more or less along the ground before being detached, sometimes it is lifted suddenly whilst, at the same time, the foot is thrown outward and downward. I have seen some patients who could not walk a step, although assisted by a cane, without throwing the body and head backward so that their attitude had some analogy with that caused by tetanus."¹

All this is perfectly accurate and is applicable, in every line, as

¹ Loc. cit., p. 427.

you can verify for yourselves, to most of the patients whom I have caused to defile before you. But, there exists one variety in the type which I should mention. You can study its characteristics in the case of one of them, named Oss—. You see how, leaning on her crutches, this woman walks literally on tip-toe, her body bent forward. This is because at every step, owing to the predominance of the tonic spasm in the muscles of the calf, the heel is forcibly lifted, and scarcely touches the ground. Hence, this woman's slippers are much worn at the toes. The foot, as indeed in the foregoing cases, is taken with trepidation every time it is put forward, and, at times, the trembling extends to the whole body. When the patient is going down a slope, she feels as if borne on by the weight of her body, obliged to quicken her step, and in danger every instant of falling upon her face. This second mode of progression, according to Dr. Erb, would be the most usual in cases of this nature. I am inclined to believe, judging from my own observation, that it is, on the contrary, less frequently met with than the first. Be this as it may, we have now to consider the two diseases, which we contrast, at the moment when they have reached the last term of their evolution. You will be enabled to observe that the distinctive characters are not less marked in this period than in the preceding.

Henceforth, deprived of the use of their lower limbs, incapable of standing or walking, both the ataxic patient and the victim of spasmodic tabes pass the day on a sofa, in an arm-chair, or remain confined to bed. But it is easy to perceive that the cause of the impotence is radically different in the two cases. In the case of the ataxic patient reduced to this state, it is still the deficiency of co-ordinating power which must bear the blame. The movements are energetic yet, even violent, and may long remain so; but they can no longer be adapted to the execution of physiological acts. In spasmodic tabes, on the contrary, the motor impotence is evidently due to the contracture, which, carried to an extreme and having become absolutely permanent, keeps the limbs invincibly in forced extension and abduction, thus rendering all voluntary movement impossible. On the other hand, the spontaneous or provoked trepidation which, except in the case of some very rare complications, is not observed at any period in locomotor ataxia, continues here to be produced to a high degree.¹ It sometimes even becomes so

¹ It would be hard for me to say at what period the phenomenon of trepi-

exaggerated as to determine in the lower limbs real convulsive crises, coming on paroxysmally, of which the denomination *spinal epilepsy* gives a sufficiently good idea.

dation, so often mentioned in the course of this lecture, was first observed and described.

In an observation relating to a woman, affected with disseminated sclerosis, which we, Professor Vulpian and myself, made in 1862 at the Salpêtrière, we referred to it in the following terms: "When one of this woman's feet is flexed and kept flexed, by the hand of an observer, there is then produced a trembling, difficult to repress, and even impossible to stop at times, when the experiment is made with the right foot." Here we find clearly indicated, and that for the first time, I believe, both the epileptoid tremor and the best method of inducing it.

In 1866, in a note read before the Société Médicale des Hôpitaux, M. Vulpian published a complete history of the case in question, with the addition of the other observations which I had communicated to him, and in which the phenomenon was likewise mentioned ('Union Médicale,' June, 1866).

In this inaugural thesis, composed under my direction, Dr. P. Dubois pointed out anew this epileptoid trepidation, as showing itself at a certain period of *disseminated sclerosis*, of *paraplegias by compression*, of *sclerosis of the antero-lateral columns*, of *chronic myelitis*, &c. "Different manœuvres," says the author, "contribute to originate it, such as the application of cold to the skin, compression of the paralysed muscles, energetic (dorsal) flexion of the foot" ('Étude sur quelques points de l'ataxie locomotrice progressive,' Paris, 1868). I would add, that in the course of the teaching of both Professor Vulpian and myself, we have oft-times called the attention of students to this singular phenomenon (Charcot, 'Leçons sur les maladies du Système nerveux,' 1re édition, t. i, p. 218, 1872-73).

Professor Brown-Séquard, in his turn, made known in 1868, in the 'Archives de Physiologie,' an interesting peculiarity relative to the trepidation. It was known already that the best method of developing it consisted in abruptly raising the toes, or the whole anterior part of the foot. He showed that the inverse manœuvre, namely, plantar flexion of the toes, when abruptly made, would determine its cessation.

Two years ago, Drs. Erb and Westphal studied anew and with great care the epileptoid trepidation, under the name of Foot-phenomenon ("Fuss-phänomen:" W. Erb, "Ueber Sehnenreflexe bei gesunden und bei Rückenmarkskranken," in 'Archiv für Psychiatrie,' 1874, p. 792; C. Westphal, "Ueber einige Bewegungs-Erscheinungen an Gelähmten Gliedern," idem, p. 803). Considering that the percussio or excitation of the tendo patellæ or of the tendo Achillis are effective ways to develop this kind of tremor, these authors have sought to establish that it has its origin in an excitation of these tendons. According to Dr. Erb, it would be a reflex act, the starting-point of which would be an irritation of the nerves of certain tendons. The interpretation suggested by Dr. Westphal is different; according to him, the struck or stretched tendon acts upon every part of the corresponding muscle, which under this influence enters into contraction. M. Joffroy ('Gazette Médicale,'

In addition to these disorders, there also exists in the period which we are considering many other phenomena calculated to differentiate the two diseases. Thus, in ataxia, the different sensory disturbances, so marked even in the first stages, persist or grow worse. The same may be said with respect to the cephalic symptoms, and functional disorders of the rectum and bladder. Most usually, the urine becomes fetid, and purulent in consequence of ulcerous inflammation of the vesical mucous membrane. This, indeed, is one of the great dangers which threaten the lives of the patients. Nothing of the kind is observed in the case of persons attacked with spasmodic tabes. Sensibility, for instance, remains untroubled in their case, till the last moment; no disorders of the sight, nor strabismus, nor, in a word, any of the symptoms which we name cephalic. The only disorder in the emission of urine which is remarked takes place in the case of women, and chiefly depends on the difficulty they experience in separating the thighs. Let us add that there is no tendency to the formation of eschars, and that the muscular masses of the lower extremities which in ataxic patients often become extremely emaciated, on the contrary preserve, in spasmodic tabes, a prominence and consistency in some sort proportionate to the intensity of the spasmodic contraction which holds them.

II.

Enough, I think, has been said to show, as I had indicated, that between progressive locomotor ataxia and spasmodic tabes, the contrast is striking on some fundamental points. Consequently I can now leave the parallel aside, in order to concentrate your atten-

1875, and 'Société de Biologie'), in criticising these works, has defended the opinion current till then, according to which the epileptoid trepidation would be generally provoked by cutaneous peripheral stimulation. He combated the opinion of Dr. Erb, where it appeared to be too absolute. He admits, with this distinguished pathologist, that excitation of the tendons is one of the principal causes which determines trepidation, and he does not refuse to look on this as an example of *tendon-reflex*; but, on the other hand, he quotes cases where unquestionably the sole provoking cause of the phenomenon was a slight irritation of the skin (*skin-reflex*). As regards the theory of Dr. Westphal, it seems invalidated by the recent experiments of H.H. Schultze and Farbinge ('Centralblatt,' 1876).

I would point out that the phenomenon of epileptoid trepidation is not peculiar to the lower limbs. It may be provoked, as I have long since demonstrated, in certain cases of hemiplegia, in the contracted upper limb, by bending back the digital phalanges.

tion on the last of these affections, the description of which I wish to complete by a few additional traits.

It appears to show itself, chiefly between the ages of thirty and forty. I am inclined to believe that it is slightly less frequent in women than in men. It is not a very common disease; I have not been able, after searching through this vast hospital, to gather together more than five cases of the kind, while it would have been easy for me to collect two score of ataxic patients.

The causes under the influence of which it is developed remain, up to the present, absolutely unknown; however, a rather commonplace influence, namely, the prolonged action of damp cold, is found mentioned in several of our observations. Its evolution is progressive, but eminently slow. In the case of the patients whom I introduce to you, and of whom several can yet stand and walk in a kind of a way, its first symptoms date back eight, ten, and fifteen years. It is not, besides, rare to find that, after having reached a certain degree, it will remain stationary for several years.

Often confined during the whole of its course to the lower extremities which, as a rule, are the first to be attacked, it may extend but always at a late period to the upper limbs. The latter, then, become the scene of the different phenomena which we have noticed above, and which appear in succession. At first it is a paretic state of the hands, which become inexpert in taking and holding things. From time to time the fingers are involuntarily bent in upon the palm of the hand. Afterwards, this pathological flexion becomes permanent and incurable. Next comes the turn of the wrist, then that of the elbow, which stiffen in extension and pronation. When this point has been reached, the upper limbs remain motionless, rigid, and more or less strongly applied to each side of the body. In the upper limbs, the trepidation is certainly always less marked than in the lower extremities; I have not yet often remarked it there in a very distinct manner.¹

The sacro-lumbar muscular masses and the muscles of the abdomen may also be affected. Hence the belly is prominent, hard upon pressure, separated from the base of the thorax by a hori-

¹ There is one circumstance which is nearly absolutely hostile to the artificial production of trepidation; it occurs, namely, when the rigidity of the limbs in extension is carried to the extreme. The manœuvre, on the contrary, succeeds nearly always when we are able to produce a slight flexion in the knee-joint.

zontal furrow, more or less deep. At the same time, the back becomes somewhat hollowed. These phenomena are especially discernible when the patients are in bed. The exacerbation which is, at moments, produced in the contraction of the abdominal muscles may have the effect of temporarily determining a certain amount of difficulty in the breathing.

However, in spite of the progress of the disease, the general health remains indefinitely unshaken. The function of nutrition in particular, even in patients almost completely confined to bed, goes on in the normal way, alike in the motionless limbs and throughout the system generally. It does not appear that the disease can, by the fact of its own symptoms merely, ever directly determine the fatal termination. The latter, undoubtedly, always supervenes through the intervention of some intercurrent affection. One of our patients has, for some months back, exhibited unequivocal signs of pulmonary tuberculisatio*n*. I would remind you, in reference to this point which I have already oft-times remarked upon, that this is a rather frequent complication of spinal sclerosis, at an advanced period.

When spasmodic tabes has once been established, can it ever spontaneously recede, or can its course be terminated by therapeutic means? I cannot say. With respect to the latter point, the attempts which I have made, even when the disease had not reached its utmost development, have hitherto had been of little effect. The lengthened employment of methodical hydropathy which, in certain forms of ataxia, induces such happy results;—the repeated application of the actual cautery, in points, along the vertebral column;—that of the continued current have not succeeded up to the present, so far as my practice is concerned, in doing more than effecting a temporary improvement. The exhibition of the bromides of potassium, sodium, or ammonium, whether administered in combination or separately, has the almost certain effect of diminishing or even of completely putting an end to the trepidation and contracture. But it has been always necessary to go on to very large doses in order to obtain this result, which, besides, has never persisted more than a few days after the use of the medicine. Dr. Erb has been more fortunate; he has seen recovery take place, in one case which, was indeed, of recent date, and, in other cases, he states that he has obtained real and lasting improvement by means of galvanotherapy.

Hence we have still reason to hope that the prognosis of the disease will become more favorable, when it shall have been better studied, and when, above all, observers shall have learned to detect it at the first period of its evolution.

III.

Clinically to distinguish between spasmodic tabes and locomotor ataxia, as I trust to have sufficiently established in the preceding remarks, is generally an easy task. The difficulties of diagnosis do not lie on this side; where they are, in truth, to be found is where the other forms of chronic myelitis come to be considered. I should wish to try to show you, now, by some examples, how the solution of the problem may most frequently be accomplished. In the first place, I would have you remark that not a single symptom of spasmodic tabes is really peculiar to itself. Permanent contracture, preceded by paresis and trepidation, may in fact, as the history of hysteria shows, be produced without any trace of spinal lesion existing, so far at least as our means of investigation can detect. The selfsame phenomena are, on the other hand, as you know from our preceding studies, the obligatory accompaniments, as it were, of all sclerous inflammations of the spinal cord, whatever their origin may be, provided only they affect the lateral columns to a certain extent; whether we have to deal with the *insular* form or, on the contrary, with the *fasciculated* form of spinal sclerosis. Hence it is that you see them figure in the symptomatology of very different affections, in which the columns in question are engaged; lasting hemiplegic contractures, consecutive on a circumscribed cerebral lesion (*en foyer*), progressive general paralysis, transverse partial myelitis, whether primary or caused by compression, amyotrophic lateral sclerosis, sclerosis in disseminated patches, &c. In the diagnosis of spasmodic tabes, therefore, our consideration must be given far less to the symptoms themselves than to their mode of distribution and evolution; their isolation, especially, whence results the monotony of the clinical picture so peculiar to the disease, ought to be regarded as an element of the first importance. For, it may be asserted that, saving some fortuitous complication, every spinal affection, in which sensory or mental disorders, functional disturbance of the bladder or rectum, paralysis of the oculi-motores, trophic muscular lesions, &c., are shown, in association with contracture, is not an example of spasmodic dorsal tabes. This

established, I will put aside certain morbid states, as, for instance, hysterical¹ and hemiplegic contractures, the differentiation of which offers no serious difficulty, in order only to dwell upon the diseases which might sometimes mislead even a practised eye.

I have caused to be placed before you the woman Seb—, aged about forty, confined to bed for the past two years, having become incapable of walking or even of standing. You may remark that her lower limbs, to which it is impossible for her to give the least voluntary movement, are not flaccid and inert, as happens in certain forms of paralysis; on the contrary, they are rigid in extension and adduction; as much resistance is felt, when you wish to flex them, as you would feel in extending them, had they been previously flexed. Trepidation is provoked at will when you turn up the point of the foot, and it often occurs spontaneously under the form of spinal epilepsy. I have known this patient for many years able still to make some laborious steps in the ward, leaning on the bed-rails or pushing a chair before her, with a firm grasp on its back, and making it slide along the waxed boards; at every step, her trunk was strongly thrown back, at the same time lurching alternately to one side and then to the other. In short, her gait was then nearly what I have just endeavoured to depict in my description of spasmodic tabes. If the examination were carried no further you might imagine that this is an example of that affection. In order to undeceive you, it will be enough to emphasise some details revealed by a less superficial scrutiny.

One day, eight years ago, after having been much fatigued, she remained for some time in a draught of very cool air, whilst her person was still in a state of perspiration. Shortly after, she experienced a sensation which she compares to that which might be caused by a stream of iced water poured down along her back. This sensation was soon followed by a rather acute pain, accompanied by a feeling of constriction, and occupying, at the same time, both back and loins. The pain, which extends like a belt on either side of the thorax, persists at present. At the same time, there supervened prickling and formication in the lower extremities. It seems to her as if now a stream of very hot water, and again a stream of very cold water, were passing through them, that they are

¹ On the diagnosis of hysterical contracture, see Charcot, 'Leçons sur les Maladies du Système nerveux,' t. i, p. 347 *et seq.*; Bourneville et Voulet, 'De la contracture hystérique.'

at moments bound by very tight cords. These phenomena have never since ceased to exist.

Some days after the appearance of these sensory disorders paresis supervened, to which soon were superadded first temporary, then permanent rigidity, trepidation, and fits of spinal epilepsy.

At the present moment you can ascertain, as we have oft-times found during her five years of hospital life, the existence of very marked obtubilation of sensibility of every kind over the whole extent of the lower limbs and abdomen. When you pinch the skin of the legs or thighs, or tickle the soles of the feet, you also find muscular tremor produced by reflex action, and various phenomena of *dysaesthesia* to which I called your attention while speaking of paraplegias consecutive on slow compression of the spinal cord.¹ I should add, in order to complete the picture, that, from the commencement, the need of micturition had become imperious, and required to be promptly satisfied; that, for many years back, vesical paresis has supervened, necessitating from time to time the use of the catheter; that, finally, the urine is usually fetid, turbid, and constantly leaves a more or less abundant muco-purulent sediment.

The different symptoms, which have just been reviewed, their mode of succession and concatenation—in a word, all things combine, as you have understood, to establish that the spinal lesion with which our patient is affected is nothing else than *chronic dorsal transverse myelitis*, with consecutive descending sclerous degeneration of the lateral columns. It seems to me useless to insist, in order to render prominent the fact that the various sensory disorders, enumerated above, that vesical paresis and the existence of muco-purulent urine, should be especially counted among the symptoms adapted to deepen the demarcation between this form of myelitis and spasmodic tabes.

In cases where partial myelitis is connected with slow compression of the spinal cord, it would be characterised in addition, in the absence of vertebral deformations, by the existence of those *pseudo-neuralgias*, the clinical importance of which I strove, on another occasion, to demonstrate, and the interest of which, in the category we are considering, would be all the greater, seeing that these pains are already exhibited, as preludes, even before the parietic symptoms began to appear. If, instead of comprising the whole breadth of

¹ 'Lectures on Diseases of the Nervous System,' vol. ii, p. 99.

the cord across, the lesion, whatever it be, remained confined to a lateral half of the nerve column, the symptomatology would present itself under the type of *spinal hemiparaplegia with crossed anaesthesia*,¹ and the diagnosis would be thereby rendered more easy of determination.

Amyotrophic lateral sclerosis has these symptoms in common with spasmodic tabes, namely : paresis followed by rigidity of the limbs, absence of sensory disorders, absence of disturbance of functions of bladder and rectum ; but, it is deeply distinguished from it, as it were from the beginning, by the atrophy which the muscular masses undergo in the affected limbs, by the more rapid evolution of the disease taken as a whole, and by the regular appearance, so to speak, of the bulbar symptoms, in the last period. Besides, in this affection, it is, as a rule, the upper extremities which are first invaded, contrary to what takes place in spasmodic tabes.²

It remains, for me, in the last place, to point out the clinical relationships which, in certain cases, may exist between spasmodic dorsal tabes and *disseminated sclerosis of the nerve centres*. Here it is, as I have already indicated to you, that you must expect to meet, more than once, with a stumbling-block to your diagnosis. When multilocular sclerosis presents itself, with all its singular apparatus of spinal, bulbar, and cerebral symptoms, it is certainly not difficult, in general, to establish its identity ; but, when we have to deal with imperfect forms—abortive forms, as they are still called—it becomes a different question. In fact, there is not a single piece of the symptomatic apparatus mentioned, if I might so speak, which may not occasionally be deficient. Thus, to give but one instance, the clinical representation of disseminated sclerosis is found, in some cases, to be reduced almost to mere contracture of the lower limbs, with or without concomitant rigidity of the upper extremities (*spinal form* of disseminated sclerosis).³ Even in such a case, the present or past coexistence of some of the cephalic symptoms, such as nystagmus, diplopia, peculiar difficulty of utterance, vertigo, apoplectiform attacks, special disorders of the mind—

¹ Loc. cit., p. 101.

² Loc. cit. p. 202.

³ Many cases of this kind are collected in the memoir presented by M. Vulpian to the Société des Hôpitaux ('Union Médicale,' 1865). M. Charcot has collected some others since then (see 'Lectures on Diseases of the Nervous System,' vol. i, p. 214).

this coexistence, I say, would furnish evidence of almost conclusive worth. But, external to this combination, I no longer see on what solid basis the diagnosis may be grounded; there would remain little resource but what we could draw from presumption. Perhaps, a more attentive and minute examination may some day enable us to note, either in the symptomatology itself, or in the etiological conditions which have been so little studied as yet, some new traits which have hitherto escaped observation, and which will henceforth allow a line of demarcation to be drawn between the two diseases, at every epoch. The future will reveal whether or not our hopes in this respect are illusory.¹

¹ One of the patients exhibited at this lecture, who presented an example of *spasmodic dorsal tabes*, has since succumbed. The autopsy has not confirmed the diagnosis, which, indeed, was given with some qualifications. It revealed the existence of disseminated sclerous patches, limited to the lower portions of the crus cerebri, to the anterior pyramids in the medulla oblongata, and, in certain points, occupying the posterior columns (cervical region); in other points the lateral columns (lower dorsal region). The cerebral hemispheres were quite free from alterations throughout. The details of this case (the fourth in the thesis of M. Bétous) will be published *in extenso* on another occasion. We will then be able to notice, in the history of the patient, the existence of cervical and dorso-lumbar pains, vertigo, an increase of the paresis of the limbs in darkness, and various other circumstances which ought to have shown the way to a right diagnosis, had more attention been given. Just at present, I wish to confine my remarks to pointing out the difficulties which the clinical observer may meet when he finds himself confronted with certain abortive forms of *disseminated sclerosis*.

LECTURE XVI.

URINARY PARAPLEGIAS.¹

SUMMARY.—*Preamble. Theoretical point of view. Clinical reality of urinary paraplegias. Definition. Classification of cases into three groups.*

Myelitis consecutive on diseases of the urinary passages. Rare in women; frequent in men. Conditions of development: gonorrhœa, stricture of the urethra, cystitis, nephritis; prostatic affections; calculous pyelo-nephritis. Exacerbation of the disease of the urinary passages precedes the invasion of spinal phenomena. Symptoms: formication; anæsthesia, dorso-lumbar and girdling pains. Paraplegia with flaccidness; excitation, then abolition of reflex excitability; permanent contracture; bedsores. Position and nature of the lesions. Pathogeny. Propagation of the renal lesion to the cord by means of the nerves (Troja, Leyden). Corroborative experiments. Examples of propagation of nerve-inflammations to the cord.

*Reflex urinary paraplegias. Symptoms. M. Brown-Sé-
quard's explanation. Recent experiments. Inhibitory phe-
nomenon. Irritation of the peripheric nerves. False para-
plegia. Descending neuritis. Affections of intestines and
uterus.*

GENTLEMEN,—I intend to-day to speak to you about the various affections which are sometimes designated under the collective term of *urinary paraplegias*. That is a subject, as you are aware, which has of late years given rise to many controversies. The debate has been a lively one, conducted at times with not a little heat, on either side; but, in spite of all, it must be confessed, that the

¹ This lecture, delivered in June, 1870, was published in the 'Mouvement Médical,' 1872.

questions raised appear, even to-day, to be, at all events in part, still wrapped in great obscurity.

In truth, the theoretical aspect of the subject seems to have been that with which the physicians, who took part in the debate, were especially preoccupied. It appeared to them of particular interest to investigate by what means a pre-existing affection of the urinary passages could react on the spinal centre, and there determine either an organic lesion or a superficial disorder which should, in both cases, be manifested by a paralytic or paretic state of the lower extremities. Much less attention has, generally speaking, been given to the establishing, on regular observations, of the clinical and anatomico-pathological characters of these consecutive spinal affections.

No doubt, the pathogenic interpretation is a point of the highest importance; it is, in some sort, the crowning of all pathological erections. But yet it is necessary, before even thinking of building the edifice, to carefully examine every portion of the ground on which it is to be founded, and to be very certain of the worth of the materials which shall be made use of. Well, gentlemen, in this particular instance, I do not hesitate to declare that this elementary precaution has been too often neglected; and this, if I mistake not, is the reason that confusion still reigns over most points of the history of *urinary paraplegia*.

You understand, from the foregoing, that it is to a foundation of clinical observation and pathological anatomy, I wish, first of all, to guide you, in this study of paraplegias consecutive on diseases of the urinary passages. We will not, however, neglect the physiological point of view; and we will try to penetrate in this direction as far as may be possible, in the actual state of science.

I.

It is indispensable, in the first place, to prove the reality of the existence of urinary paraplegias. You know that, under this name, we designate the *paretic or paralytic affections of the lower extremities, supervening in the course of certain diseases of the urinary passages, and appearing to be connected with these, as consecutive effects, deuteropathic affections*.

At the outset it is necessary, of course, to exclude from our plan those affections of the kidneys or bladder which appear not as causes, but, on the contrary, as consequences of a disease of the

spinal cord ; our former studies have enlightened us as to the nature and genesis of these consecutive affections of the genito-urinary passages ; it is not necessary to return to them.

To accomplish the object proposed, we might quote numerous observations. The very number of the cases in which we see paraplegia appear, in the course of disease of the urinary passages, is of itself enough to show that the phenomenon is no chance coincidence. But when we desire to specify the clinical or anatomical characters of these paraplegias, and indicate what circumstances preside over their development, we are met with obstacles of all kinds, and the number of *facts* is then strangely reduced. Whatever be the cause of this, even if we only take count of the regular observations, we soon come to recognise, on comparing them, that they ought to be grouped into distinct categories.

1°. One group comprises the urinary paraplegias in which the spinal cord is the seat of an inflammatory lesion, that shows itself, during life, by the array of symptoms which belong to myelitis.

2°. The second group includes the cases in which the paraplegia presents itself with quite different symptoms ; in these conditions we remark a paresis, a weakness of the lower limbs rather than a paralysis, in the literal acceptance of the term. The symptoms are transient, subject to successive amendments and exacerbations. The invasion of phenomena is sometimes rapid, their cessation may also take place suddenly. Moreover, beyond the phenomenon of *paresis* nothing is observed which would recall the grave symptoms peculiar to serious spinal lesions, and necroscopy has, in fact, several times in such cases shown the, at least apparent, integrity of the spinal cord.

Gentlemen, it is this form of urinary paraplegia, designated *reflex paraplegia*, which was the especial subject of the discussion to which I have just alluded.

3°. The third group is composed of cases in which the weakness of the limbs, observed in the course of the urinary disease, depends, not on a spinal affection, but on a lesion of the nerves of the sacral plexus directly produced, as it were, by gradual propagation of the morbid process.

The two first groups shall especially engage our attention ; as to the third we will confine ourselves to giving a rapid account of the cases which concern it.

II.

Myelitis consecutive on diseases of the urinary organs.—In such a case as this, we have to deal with a *partial myelitis*, occupying, at least primarily, a position in the upper part of the lumbar enlargement. This indication allows you already to divine the array of symptoms which go to mark the disease.

However, before proceeding further, it is necessary to know the conditions in the midst of which consecutive myelitis have their origin.

Rare amongst women, this kind of myelitis appears to be, on the other hand, common enough among men. Usually, it is developed in the course of diseases of the urinary passages of long duration.

A more or less prolonged gonorrhœa opens the scene; then follows stricture, which may occasion the repeated introduction of the catheter. Cystitis and nephritis even may have occurred consecutively. It is, as a rule, in these circumstances that the paraplegia makes its appearance. It may also show itself, in connection with disease of the prostate, with a cystitis or pyelo-nephritis of calculous origin. We may regard as exceptional the case reported by H. Leyden, where the myelitis is said to have followed upon a cystitis developed under the influence of simple retention of urine, occasioned by a chill.¹

Generally, the spinal disorders only appear several years after the invasion of the urinary affection; often two, five, and even ten years may have elapsed. They show themselves on the occurrence of an exacerbation of the symptoms of the primary disease, or of an unexpected complication. Thus, in a case reported by Mr. Ogle,² the paraplegia supervened at a time when renal suppuration had occurred in a patient who had been affected with calculous cystitis for five years.

In an analogous case, cited by Dr. Gull, the spinal ramollissement showed itself when, in consequence of gonorrhœa, an abscess had formed near the bulb of the urethra, and created a communication between the rectum and the bladder.³

¹ Leyden, 'Centrablatt,' 1865, first case.—Retention of urine for over forty-eight hours, supervening after a chill. Consecutive cystitis. Four weeks after the retention the first symptoms of paralysis of the lower extremities appear. On autopsy, red ramollissement of the lumbar cord.

² 'Transactions of the Pathological Society of London,' 1864, t. xv.

³ 'Med.-Chir. Trans.,' t. xxxix, p. 200, 1856.

The case of H. Leyden, mentioned above, in which paralysis supervened only four weeks after retention of urine, caused by a chill, shows that the spinal complication may present itself in a less dilatory manner in the course of disease of the urinary organs.

I shall not, of course, pause to describe the symptoms of the disease of the urinary organs on which the spinal affection follows ; nor shall I delay much over the phenomena which reveal the latter disease, for they are none other, as you have understood, than the symptoms belonging to every *transverse myelitis* occupying a position below the lumbar swelling, or in the upper part of this enlargement.

Formication, numbness, a feeling of constriction, first appear in the lower limbs, and are soon followed by an anæsthesia or an analgesia, which chiefly affect their extremities ; the dorso-lumbar pain and the girdle pain are rarely absent. A paraplegia with more or less complete flaccidness does not long delay its appearance ; it is accompanied, at a given moment, by increased reflex excitability, which [may give place to absolute inexcitability, when the lumbar enlargement is itself invaded by the ramollissement ; there have been cases in which permanent contracture was developed, in the course of time, in the paralysed limbs.¹ The myelitis may sometimes extend beyond its primary position, as is proved by several cases in which the upper extremities were, in their turn, invaded by the paralysis. Lastly, in grave cases, it is rather usual for bedsores to form in the sacral region, and decide the fatal termination.

The course of this form of myelitis is ordinarily subacute. However, in the case reported by Dr. Gull, death supervened only fifteen days after the invasion of the paralytic symptoms.

The following is the information supplied by autopsy. There are cases where, to the naked eye, the cord appears to present no alteration ; if the microscope be then employed, as was done, for instance, in Dr. Gull's case, more or less marked histological lesions, and particularly the existence of *granular bodies*, are rendered evident. But, as a general rule, the most superficial examination suffices to detect, in the affected parts of the cord, the diminution of consistency and change of colour which belong to ramollissement.

It is not uninteresting to note that the lesion in question appears,

¹ See, in particular, the case of the celebrated surgeon Sanson, reported by Cruveilhier.

at least at first, to occupy a position a little above the lumbar enlargement, that is to say, in the place where Budge and Gianuzzi (basing their opinion on anatomical and experimental facts) place the genito-spinal centre from which the nerves of the bladder emerge.

It seems to be sufficiently proved by what precedes that transverse myelitis may be sometimes developed as the more or less direct consequence of certain affections of the urinary passages. It is now time to inquire what is the reason of this relation, or, in other terms, by what mechanism the genito-urinary lesion reacts upon the spinal centre, and determines inflammation there.

The simplest idea, if I mistake not, which first of all occurs to the mind is the following:—The nerve-trunks are the conduits through which, little by little, the lesion is propagated in a centripetal direction, from the kidneys or the bladder, to the spinal cord. Such is the opinion adopted by H. Leyden,¹ in an interesting study recently published, and this opinion strikes me as very probable. I would add that it is not new, for, as H. Leyden, indeed, acknowledges, it was published, in 1780, by Troja, who, as you see, was not ignorant of urinary paraplegia.

It must, however, be acknowledged that necroscopic results have not hitherto given evidence in support of this pathogenic interpretation. Lesions of the urinary passages have been demonstrated, on the one hand; and, on the other hand, a spinal lesion; but it has never hitherto been possible to find the trail of the presumed propagation of the inflammatory action, along the nerves.

On the other hand, here is an experimental fact which, up to a certain point, may be appealed to in favour of our hypothesis. In a series of studies on neuritis, H. Tiesler, a pupil of H. Leyden,² had occasion to apply different kinds of irritant agents to the sciatic nerves of rabbits; one of these animals became paraplegic and succumbed three days later; the autopsy revealed in the substance of the sciatic nerve, and in the place where the irritation had been produced, a primary purulent focus, and another focus in the vertebral canal around the roots of the nerve, near their point of emergence. The spinal cord in the same region was softened and infiltrated with granular bodies and leucocytes. The portion of

¹ 'Sammlung klinisch. Vorträge,' No. 2, Leipzig, 1870.

² 'Ueber Neuritis, p. 25, Königsberg, 1869; Leyden, loc. cit.

the nerve comprised between the two purulent foci seemed to be perfectly healthy.

This is the only experiment fact, within my knowledge, which directly relates to our subject.¹ But if it be thought well to enlarge the field and appeal to analogies, we may introduce some evidence here the significance of which cannot be mistaken.

In inaugurating the lectures of this year,² we endeavoured to show that lesions of the nervous system sometimes react, by means of the nerves, on different parts of the body so as to cause trophic disorders there. The converse is also observed, or, in other words, it may happen that irritant lesions, primarily occupying the peripheral parts react, here again, by means of the nerves, on the central parts of the nervous system, and determine more or less marked morbid action there. The facts which testify to this effect, are few in number as yet; but, they appear to me sufficiently significant to require a moment's attention.

You are not unaware that Graves, in several passages of his writings, expressed the opinion that inflammation of the peripheral nerves may be propagated to the cord. Lallemand mentions the case of a neuritis primarily occupying the brachial plexus, where the inflammation is supposed to have ascended to the encephalon. But the assertions of Graves and Lallemand are too vague for us to delay longer over them. Here are more explicit facts.³

The alterations of the nerves of the *cauda equina*, when they are above the intervertebral ganglion, may ascend to the cord and there determine the lesions of grey degeneration. The latter, in such a case, occupies the posterior spinal columns. This fact has been demonstrated by an observation contributed by M. Cornil.⁴

Eight days after the invasion of a sciatic neuritis, developed under the influence of asphyxia from charcoal fumes, M. Leudet

¹ Since this lecture was delivered (July, 1870) results, similar to those announced by H. Tiesler, have been obtained by Dr. Feinberg, "Ueber reflexlähmungen," in 'Berliner Klin. Wochensch.,' No. 42, 1871. See also the important researches of Dr. Hayem on the same subject, "Des altérations de la moelle consécutives à l'arrachement du nerf sciatique chez le lapin," 'Arch. de Physiologie,' 1873. pl. iii, *bis*, p. 504.

² Reference is here made to the "Leçons sur les troubles trophiques consécutifs aux lésions du Système nerveux," delivered in 1870.

³ See Leudet, 'Archives Générales de Médecine,' 1865, t. ii, p. 528.

⁴ See Bouchard, 'Des Dégénérationes secondaires,' p. 42.

remarked paretic weakening to supervene at first, in the lower extremity corresponding to the seat of the neuritis, then extending to the limb of the opposite side, and, lastly, to the upper extremities.¹

H. Leyden has quoted from H. Benedikt the following fact:—A fracture of the neck of the humerus, ending in pseudarthrosis, had been the source of acute permanent pains occupying the whole length of the lower extremity of the side corresponding to the fracture. Shortly after, complete paralysis with muscular atrophy supervened in the upper extremity of the same side.²

In a very interesting case, related by M. Duménil—who, I should warn you, has given a different interpretation of it from that which I propose—there were successively observed in one of the extremities, first, a sciatic neuritis, next a paraplegia, and lastly a paralysis of the upper limbs. Muscular atrophy with decrease of electric contractility attacked the motor-paralysed limbs, in succession. The tongue, itself, was finally involved. The autopsy revealed some remarkable lesions principally occupying the central grey substance, the white substance, on the contrary, being scarcely affected.³

I shall lastly mention a case of my own which I contributed to Brown-Séquard's 'Journal de Physiologie,' for 1856. It refers to a nerve lesion of the forearm, which determined, firstly, a neuritis of the peripheral end, followed by atrophy of the muscles of the hand and by a pemphigoid eruption. Afterwards, the upper extremity of the opposite side was, in its turn, stricken with atrophy and anæsthesia.⁴

¹ Leudet, loc. cit.

² Leyden, loc. cit., p. 21.

³ 'Gazette hebdomadaire,' 1866.

⁴ The following case ought, I believe, to be considered as an example of ascending neuritis, followed by transverse myelitis. M. X—, aged fifty, had amputation of the left thigh performed at the age of twenty. During several months he felt, in the stump, acute pains, formication, and sometimes startings, when, one day in August, 1875, vesical paralysis and lumbar pains supervened. Shortly after formication and startings were experienced in the right lower extremity which, together with the stump, soon became stricken with motor paralysis and flaccidness. After some days of treatment, the patient recovered the functions of the bladder, and some weeks after he was able to leave his bed and to walk, of course with the help of crutches. A year after, he walked still better; but in the right lower extremity a certain degree of permanent rigidity had been produced. On forcibly flexing the point of the foot, very marked trepidation was without fail caused in this limb.

It is at least very probable that, in all these cases, the nerves have been the seat of inflammatory action which was propagated to the cord and, according to all probability, to the central grey substance. In fact, in most of these cases, the anæsthesia and muscular atrophy of the paralysed limbs seem to indicate that we had here a form of subacute central myelitis, to which I intend soon to call your attention, and in which the muscular atrophy and different disorders of sensibility appear to be constant phenomena.¹

III.

The cases which constitute the second group of urinary paraplegias are those which Rayer, Brown-Séquad, and M. R. Leroy d'Etiolles have chiefly had in view in their descriptions. Paralysis shows itself here, under precisely the same circumstances as in the preceding cases, and, in its etiology, we again find diseases of the urethra, of the bladder, prostate, and kidneys.

Nothing, therefore, in this respect, separates these from those. This, however, does not hold good as regards their clinical characters. They differ radically, as I have indicated, from those which distinguish *urinary myelitis*.

The picture, drawn by Brown-Séquad, of what he calls *reflex paraplegia*, has excited sufficient attention to render any long discussion of this subject unnecessary. I shall confine myself to reminding you of the following characters; they will enable you to group the differences which exist between this form of urinary paraplegia which, in reality, is rather frequently observed in ordinary practice, and that which is connected with partial myelitis arising from a renal or vesical cause.

The paralysis never extends to the upper extremities; besides, we have here to deal with a paretic weakness of the limbs rather than with paralysis properly so called; the reflex power of the cord is never augmented; never is paralysis of bladder or rectum superadded to that of the lower extremities; neither muscular spasms nor contracture are observed; dysæsthesia, like anæsthesia, is altogether absent; no bedsores nor any kind of trophic disorders are produced, and the absence of dorsal pains, and of all sensations of abdominal constriction is expressly remarked. Lastly, and this is a character well worth noticing, there is often a rapid and sometimes even a

¹ See Lectures IX—XIV on "Spinal Amyotrophies."

complete modification of the paralytic phenomena, under the influence of an amendment in the affection of the urinary passages.

In short, gentlemen, as you see, the symptoms are relatively little marked, when compared with those depending on urinary myelitis. The affection in question never, in fact, endangers life of itself; it does not appear to have ever resulted in myelitis, and in the (not very explicit) cases where autopsy has been performed, the cord has always appeared free from alteration. It is true that, up to the present, verification by microscopic study has been deficient. But, on the other hand, the rapidity of the improvements, and even of the recoveries, observed in a number of cases is such that it is very improbable that microscopical investigation could have added anything to the examination made with the naked eye.

Nevertheless, gentlemen, this paralytic debility of the lower extremities, developed in consequence of a disease of the urinary passages, is, at all events, a very curious phenomenon, and it is not surprising that it has so keenly engaged the attention of physiologists. You are not ignorant of the interpretation proposed by M. Brown-Séguard. It is based upon an experiment. Ligature of the hilum of the kidney has, it would appear, the effect of determining a sort of prolonged contracture of the vessels of the spinal cord and of its envelopes, and it is in consequence of the spinal anæmia thus developed in a reflex manner that paraplegia is produced. The validity of the experiment has been contested by Dr. Gull. I will not insist upon this point, not having any personal experiment to mention; but I cannot omit giving you a brief description of the results of the most recent experiments, which, if they do not completely reveal the mechanism of reflex paraplegias, at all events, if I mistake not, demonstrate their reality.

The phenomena of *inhibition*, observed in consequence of the irritation of certain nerves, are well known to you; you know how irritation of the vagus stops the heart, that of the splanchnic nerve paralyzes the intestine, and, lastly, how that of the superior laryngeal nerve causes momentary suspension of the respiration. But, it is probably less generally known that irritation of certain points of the cord or of the spinal nerves is, also, capable under certain circumstances of forming a hindrance to the regular functions of the cord, of momentarily abolishing, for instance, the play of the motor functions and reflex acts.

The encephalon of a frog having been destroyed, if you irritate

the spinal cord, in its lower region, by a caustic application, the reflex acts are diminished, to a remarkable extent, in the upper extremities during the whole time that the irritation lasts. This experiment is due to M. Herzen. Here is another which we owe to the same physiologist: the brain and cord of a frog having been destroyed to a level with the brachial plexus, if you then irritate, in any manner, the sciatic nerves of the left side, for instance, as long as the irritation persists, the reflex movements are abolished in the lower extremity of the right side. If the electric stimulus be employed, amongst other tests, the movements reappear immediately on the current ceasing.¹

The experiments of H. Lewisson² probably possess, from my point of view, still greater interest than the foregoing. His first series is, indeed, little more than a reproduction of the experiments of M. Herzen, with variations and some modifications, which render the results more delicate and more precise.

We shall only refer to the facts which touch most nearly the subject that occupies us. One of the first points, demonstrated by this experimenter, is the non-existence of reflex paraplegia, consecutive on the extirpation of the kidney. The experiment of Comhaire, which has so long served as a stock-in-trade, does not, it is asserted, give the results which have been attributed to it. But if, after having laid bare the uterus, the kidneys, the empty bladder of a rabbit, you press these different organs more or less strongly between the fingers, motor paralysis is produced in the lower extremities, which persists as long as the pressure is kept up, and even for some time after. The constriction of a loop of the intestines determines, also, the same effects, and is likewise followed by temporary paraplegia.

I am far from denying that, in many respects, the application of these results to the explanation of the paraplegias termed reflex is open to criticism. It may be, for instance, objected that the paralyzing influence caused by pressure of the viscera ought, necessarily, to exhaust itself at the end of a certain time;

¹ Herzen: 'Expér. sur les centres modérateurs de l'action réflexe,' Turin, 1864.

² Lewisson, "Ueber Hemmung der Thatigkeit der motorischen Nerven-centren durch Reizung sensibler Nerven." Du Bois, 'Archiv,' 1869, s. 255, 266. Nothnagel, 'Virchow's Archiv,' Jan., 1870. 'Centralblatt,' 1869, p. 623.

that the irritation of the peripheral nerves, resulting from cystitis or nephritis, is not exactly comparable to compression of the bladder or kidney. All this is perfectly true, but, without going so far as to admit that there is, between these two classes of facts, a complete identity, it is allowable to recognise the analogies which bring them together, and to hope that experimental facts will some day guide us to the interpretation of the clinical phenomena.

IV.

As I announced, at the beginning, there exists a third group of urinary paralyses. The cases, few in number, which compose it are, so far, examples of false paraplegia, at least in this respect that it is not the cord which is attacked.

In such cases, the phenomena take place as in the well-known example reported by H. Kussmaul.¹ In that instance, descending neuritis, directly propagated, had become developed owing to a serious inflammation of the urinary passages, and had occupied the lumbar and sacral plexus. During life, besides paresis of the lower extremities, acute pain had been remarked along the course of both sciatic nerves. Cases of this kind rarely make their appearance, I repeat, contrary to the opinion of Remak, who seems to believe that this is the usual form of urinary paraplegias.

The pathogenic modes which have just been reviewed are not the only examples which might be appealed to in order to explain the development of paraplegias consecutive on diseases of the genito-urinary organs. Thus, in cases reported by Dr. Gull, a phlebitis consecutive on an abscess of the lesser basin, itself being caused by an ulcerous cystitis, was propagated to the intra-spinal veins ; there resulted, by a mechanism easily understood, a partial myelitis, which was soon followed by death.

You are aware, gentlemen, that uro-genital lesions have not alone the power of determining paralyses of the kind which we have just been studying. Various affections of the intestine or of the uterus may also, though more rarely, be followed by the same consequences. I confine myself, for the moment, to pointing out this fact to you : it deserves to engage your attention, in a special manner.

¹ 'Wurzburg. Verhand.,' 1868.

LECTURES XVII AND XVIII.

MÉNIÈRE'S VERTIGO = VERTIGO AB AURE LÆSA.

SUMMARY.—*A case of Ménière's vertigo. Description. Habitual vertigo increased by motion. Its characters: paroxysmal exacerbations; subjective translation movements. Old lesions of the ears; outflow of pus, alteration of tympan. Walking and standing impossible. Evolution of the disease. Complication: hysterical fits.*

Historical sketch. Vertigo of Ménière as yet little known. Diagnosis; apoplectiform cerebral congestion; epileptic petit mal; gastric vertigo. Relation between the sudden development of noises in the ears and the invasion of sensations of giddiness.

Diseases of the ear: labyrinthic otitis; median otitis, catarrh, &c. Prognosis. Cure by deafness. Treatment.

Reputedly incurable diseases. Examples of cure. Case of Ménière's vertigo. Situation of the patient in May, 1875; permanent sensations of giddiness; crises announced by shrill whistling. Motor hallucination. Treatment by sulphate of quinine: doses, effects, remarkable improvement. Another example of amelioration due to the prolonged use of sulphate of quinine.

I.

GENTLEMEN,—I wish to call your attention to a case which, in my opinion, is very interesting, and to which you have probably not often seen a parallel in the hospitals. The symptoms appear here in a very marked manner, but abnormally in some respects, so that the affection in question is rendered to a certain extent difficult of diagnosis. You can at once observe, *de visu*, the utterly scared look which the physiognomy of the patient presents. If you approach her bed, she at once gives signs of great anxiety; you see her, at the slightest shake, seize and cling to the objects around, as though she felt in danger of falling.

The fact is that she is under the influence of a state of giddiness which is, as it were, perpetual, and which the slightest motion exasperates. This vertigo she, herself, describes in picturesque terms. It is, she says, the sensation which one might feel when standing on the summit of a high tower, unprotected by any rail; or such as might be caused by the sight of a precipice. This vertigo, I repeat, is almost incessant; it exists by night as well as by day, when in dorsal decubitus as well as when standing upright. The latter position, however, augments it enormously. This also happens, I have said, from the least shake of the bed and, in a moment, when the patient shall be lifted in order to be taken to the ward which she usually occupies, you will perhaps hear her shrieking wildly, owing to an exasperation of the sensations of giddiness.

At times, in the midst of apparent calm, and without any provocation whatever, the patient, as you may doubtless soon remark, suddenly gives a start. If she be then asked what is the reason of this abrupt movement she invariably replies that she has just had her *fit*. The fact is, that besides the state of habitual giddiness which I endeavoured to depict a moment ago, she is subject to paroxysmal exacerbations of the vertigo which constitute a kind of fits. These appear to be, especially, characterised by the sensation of a sudden *translation movement*, not of the surrounding objects, but of the patient herself—an altogether *subjective* sensation, the only exterior sign of which is the starting. Still, consciousness is not at all lost, and the patient, on emerging from her fit, can give an account of all she experienced. Sometimes, and most frequently, it seems to her that she makes a summersault forward; at other times the summersault is made backward. Lastly, and most rarely, she experiences a sensation as if her body were rapidly spinning around on its vertical axis—the rotation always taking place from left to right. Whichever may occur, this species of motor hallucination is always followed by keen anxiety, facial pallor, and cold sweats. Finally, nausea and also sometimes vomitings terminate the crisis; after which the state of giddiness re-descends, so to speak, to its normal standard.

In addition to the phenomena which have just been mentioned there is yet another, gentlemen, which deserves to be noticed in a special way, because, in relation to this subject, it is I think, of capital importance, especially from a diagnostic point of view. I allude to a whistling sound which occupies both ears of our patient,

but is predominant in the left. This *whistling* exists almost constantly to a certain degree, but becomes exasperated at times and then occasionally acquires an extreme shrillness. In fact, the patient sometimes confounds it with the shriek of the steam-whistle sounded in the railway station adjacent to the hospital; she has had to inquire of her neighbours to make certain of the fact. This exacerbation of the habitual whistling, gentlemen (and this point deserves to be remarked), always heralds the near arrival of the fit of giddiness. When it acquires this shrill character, the "summersaults" are imminent.

The constant appearance of the symptoms, under the circumstances just indicated, naturally directed our attention to the ear, and this is what we found on examination: 1°. From time to time, for a long period, there comes an outflow of pus, mixed with blood, from both ears, but especially from the left; 2°, on the right, the *membrana tympani* is thickened, covered with greenish deposits; on the left, it has disappeared, and is replaced by fungoid growths. On this side, there is considerable loss of hearing power. These several lesions have been duly verified by a physician more particularly versed in the study of diseases of the ear, who has obligingly given us his assistance.

Under the extraordinarily marked form which it assumes in the case of our patient, this symptomatic group, which is commonly known by the name of *Ménière's disease*, is undoubtedly difficult of recognition; but this is not the case if, by a study of its antecedents, you refer back for some years, namely, to an epoch when the crises, *dissociated*, as it were, made their appearance with characters which recall the classic description in its principal features.

It is not much more than six years ago, in fact, since the state of giddiness was established in a permanent manner, here, so as to render it impossible for the patient to walk or even to stand, and necessitating confinement to bed. Before this epoch, the fits were long distinct, separated by more or less lengthy intervals, during which everything seemed to fall into good order. This is what we learn from the details of the observation which M. Debove has noted with the greatest care.

The first symptoms must be dated from about the age of seventeen, and G— is now fifty-one. At first, the left ear suffered, the affection being chiefly marked by shooting pains which, oftentimes disturbed her sleep; the runnings of pus mixed with blood have

been frequent from this epoch. For a long time the patient was placed under the care of Ménière. The fits of giddiness, at first rare and of little intensity, have become gradually more marked and closer ; but, from the very beginning, they appear to have presented, though in an abridged form it is true, all the more marked characteristics which distinguish them to-day. Thus, the patient remembers quite well that, between the ages of twenty-five and thirty-eight, she often experienced, whilst sitting, very intense buzzing in the ear, and immediately the chair seemed to break down under her. She gave a cry, rose up quickly, and all was over. Afterwards, about the age of thirty-eight, the premonitory buzzing gave place to shrill whistling, and, at the same time, nausea and vomiting began to form an integral part of the fits. The latter often supervened in the street ; Gir— then habitually experienced the sensation of *falling forward*, and, in order not to fall, was obliged to lean against the wall.

They frequently came on at home, during work hours, and Gir— in the course of the years preceding her admission into this hospital, had adopted the singular custom of placing herself, during the time she spent at home, in such a position as that her head was slightly thrown back, whilst her legs were somewhat raised. Thanks to this position, which is still habitual to her, the vertigo, she declares, was less frequent and less distressing.

Towards the age of forty-five, the fits had approximated to such an extent as to become subintrant, so to speak ; shortly afterwards, the patient was admitted to the Salpêtrière, where she has remained for six years, under our eyes, in the lamentable state in which you see her to-day.

In order not to overload the clinical picture, which is already a complicated one, I have purposely neglected to mention certain nervous accidents which G— has experienced during a considerable portion of her life, and traces of which she bears to-day ; I refer to fits of convulsive hysteria which have often intermingled with fits of *vertigo ab aure læsâ*, without, however, ever becoming confounded with them. At present, the convulsive fits have disappeared, and the hysteria, for many years, has only been represented by an incomplete hemianæsthesia and ovaralgia, of the left side.

II.

Very important works have been published concerning the symptomatology of the *vertigo ab aure læsâ*. As examples, I will mention the communication made to the Académie de Médecine, June 8, 1861, by Ménière, who, as you are aware, was undoubtedly the first in the field: then the description, traced with a master-hand, by Trousseau in different places in his 'Clinique Médicale de l'Hôtel Dieu' (t. ii, p. 28, t. iii, p. 11). I would also cite a very important memoir by Dr. Knapp (of New York), where most of the elements noted in reference to this subject, up to the present, have been collected (Knapp and Moos, 'Archives of Ophthalmology and Otology,' t. i, No. 1, New York, 1870); lastly, an excellent article published by M. Duplay in the 'Archives de Médecine.'

Nevertheless, I believe I may assert that, in spite of these works, a knowledge of the pathological condition in question has not yet entered, as it ought, into every-day practice. Although cases of Ménière's disease are not rare, far otherwise, at least in civil practice, they are nearly always misconstrued, connected as they are with more common disorders, as, amongst others, with apoplectic cerebral congestion, or apoplectic stroke, epileptic *petit mal*, or, again, and chiefly with gastric vertigo. I have, for my own part, often witnessed mistakes of this kind; as an example, I will mention the case of a patient, whom I have attended, and who, having fallen on the Place de la Bourse, owing to a fit of labyrinthic vertigo, had been treated by bloodletting. The real character of the disease was not recognised until very late, at a time when the fits, which were of great intensity, had been already very frequently reproduced. Complete, absolute deafness of both ears put an end to all the symptoms. I might also cite the case of a young American lady who had, for many years, been considered as epileptic, and consequently treated, without indeed the least improvement, by large doses of bromide of potassium. It would be easy for me to multiply examples.

The error in some cases is, to a certain point, justified by the difficulties, often very serious ones, which may stand in the way of the diagnosis. I think, however, that, as a rule, the labyrinthic vertigo presents itself with a sufficiently characteristic aspect to allow of its identity being determined without over-much difficulty. I request your permission to note the principal characters, for if I should succeed in gravating them on your mind, they would enable

you, I am convinced, nearly always to steer clear of the rocks which I have just described.

In the first place, I would point out the close relation which exists between the sudden development of noises in the ear, or the abrupt exasperation of these noises, and the invasion of the sensations of giddiness. In reality, one of the specific features of Ménière's disease is that it is, of necessity, heralded and accompanied by the noises in question. Undoubtedly, tinkling, buzzing, and whistling noises in the ear constitute a somewhat commonplace phenomenon, which frequently accompanies different kinds of vertigo other than that connected with Ménière's disease, but in the latter affection it acquires, at the moment of the fit, an intensity and prominence which are certainly not elsewhere observable. According to the statements of the patients it is "the shrill sound of a locomotive whistle," or a rattle, like "the violent shaking of a sack of nails," or, again, "the crackle of fireworks, or a fusillade." This noise occupies one of the ears, either exclusively or especially. It ceases with the fit of giddiness in recent or slight cases; but sooner or later, if the case is grave, it becomes persistent, in the intervals, in the form of a buzzing or a tinkling, more or less disagreeable; the affected ear, besides, does not fail to soon present a more or less marked and permanent deafness.

When the attention of the physician has been once aroused by these phenomena, an examination of the auditory apparatus always enables him to recognise the existence of local symptoms, denoting either idiopathic labyrinthic otitis, or sclerematous median otitis, with ankylosis of the ossicula, propagated to the vestibule and labyrinth, or again, a simple catarrh of the ear, as shown in an observation published by Mr. Green ('Boston Med. and Surg. Journal,' 21st Jan., 1869) and quoted by Mr. Knapp. There is reason besides to believe, from the general aspect of the facts, that any pressure exercised upon the tympanum and carried on to the labyrinth by the chain of ossicula, suffices to determine the symptoms of Ménière's vertigo.

With respect to the vertigo, considered in itself, it also offers some special characters. Most frequently, if I am to judge from ten or a dozen of my own cases, it is the sensation of a translation movement of the whole body, from behind forward, or from before backward, so as to simulate, according to the case, a fall forward or backward; or again, when a feeling of rotation round a transverse

axis is added, it is a genuine summersault, as if from a spring-board. Occasionally, on the contrary, the rotation of the body seems to take place round a vertical axis, sometimes from left to right, sometimes from right to left. There are patients who, in their different fits, imagine that they experience sometimes one, sometimes another of these different modes of rotation. All this, remark it well, refers, generally, to purely subjective movements, genuine hallucinations, which are only betrayed externally by a start, a movement of surprise, occasionally by the patient's catching at adjacent objects or sitting down, for fear of falling. But it may happen that a fall actually takes place, and that the patient may be thrown violently down, in a direction corresponding with the vertigo sensation. In connection with this, I may mention the case of a lady who, in her fits, always felt herself precipitated head foremost and who, in fact, in one of them, did fall heavily on her face, breaking the bones of her nose. I am aware that the feeling of rotation or translation may be observed in the most different kinds of vertigo, but I believe I can affirm that you never find it there either so marked, or so constant, as it is in Ménière's vertigo.

It is important to remark that, during the crisis, whatever may be its intensity, the patient absolutely preserves perfect consciousness of his actions, and that, once the first effects of the seizure have been dissipated, he is immediately in a position to render, without hesitation, an account of all that he has felt.

As accessory phenomena, I would point out the following:—Nausea and vomiting, almost constantly, mark the end of the crisis; whilst it lasts, the face is pale, the skin cold and covered with sweat in such a way as to reproduce the semblance of syncope rather than that of an apoplectic stroke. A more or less acute cephalalgia may exist for the moment. There is never any difficulty of utterance, nor muscular spasms in face or limbs; never in the extremities any formication nor numbness, nor sensations like an aura, never any temporary pareses nor paralyzes.

At the outset, that is to say when Ménière's disease is yet but beginning, the vertigo appears under the form of distinct crises, of short duration, separated by intervals of absolute calm, during which the symptoms of the local disease, on which they depend, alone persist. But, in the natural course of things, as the affection progresses, the crises tend to draw closer, to become confounded, so as to finally constitute, as it were, a permanent

vertiginous state, in the midst of which more or less frequent paroxysms appear, and reproduce all the phenomena of the old crises. The patient whom I have introduced to you offers a very marked example of those *subintrant* crises, which it is in some sort customary to see, I repeat, in patients who have been for years suffering from the grave forms of Ménière's disease.

You readily understand, gentlemen, the use which may be made of all the elements which have been here put together for the elucidation of the diagnosis.

I reserve the privilege of telling you, on another occasion, what is most surely known relative to the *pathological anatomy* and to the *theory* of the disease. With respect to the latter, the experiments of Flourens, MM. Brown-Séguard, Vulpian, Czermak, Gall, and Loewenberg, which consist in reproducing different lesions of the semicircular canals in animals, have furnished important data, as we are aware. To-day, I shall terminate by some observations relative to prognosis and therapeutics.

It is very remarkable to find that, as a rule, the grave lesions of the nervous centres which are so frequently the consequence of different diseases of the ear do not usually intervene in Ménière's disease, even when the latter has reached its highest degree of intensity. This is how matters most usually proceed in the most marked cases: deafness progressively augments and, at a given moment, it becomes complete, absolute.

The vertiginous symptoms and the whistling sounds proceed, as it were, abreast, in this sense, namely, that they gradually diminish and finally disappear. It has been so, for instance, in the patient of whom I spoke above, as having fallen in one of his fits in the Place de la Bourse. Subject to whistlings, and to vertigos, since 1863, he is now completely freed from them. But, on the other hand, he has become deaf, so deaf that although he lives near the Champ de Mars, he heard absolutely nothing at the time of the explosion of the powder-magazine in the Avenue Rapp (1871). I have often asked myself if it would not be proper to endeavour to hasten this consummation, by some intervention, at least in the graver cases; for instance, when the patients are reduced to the lamentable state in which you have seen the patient G—; this is a view which I submit for your consideration.

However this may be, I should not hide from you that the vertigo of Ménière very often resists the best directed treatment.

I have, however, several times seen the vertigo, when connected with catarrh of the cavity of the tympanum, improve and even disappear under the influence of the ordinary treatment of the latter affection; this is the place to remind you of the very interesting case noted by M. Hillairet, in which the vertigo ceased completely after the opening of an abscess in the middle ear.

The application of energetic counter-irritation ought not to be neglected in severe cases. I will mention, in connection with this, the following fact, which I have recently witnessed. One of our provincial brethren, now aged 44, experienced, six years ago, for the first time, a sense of heaviness in the head and buzzing in the ears, coming on in fits. Some months later, whilst driving alone in the country, he suddenly felt intolerable whistling in his left ear, and at the same moment his head became heavy, and seemed to drag him forward. He was obliged to get down from his carriage, and to lie down, at full length, upon the roadside. Nausea, followed by vomiting of glairy matter mixed with bile, terminated the crisis. Fits of the same kind frequently recurred since that period, and, at the same time, the hearing power of the affected ear diminished. Nothing was discovered on examination, except a certain degree of thickening of the membrana tympani. All the remedies applied having failed, I proposed, for want of something better, the application of the actual cautery, in points, upon the left mastoid region. The applications were repeated three or four times. After this treatment all the symptoms became very distinctly milder.¹

GENTLEMEN, I thought it would be interesting to inaugurate the conferences of this year² by showing you, at the Salpêtrière—that is, in an institution largely devoted to reputedly incurable chronic cases—two examples of cure, or, at all events, of amendment equivalent or nearly equivalent to recovery. The term incurable diseases cannot, of course, be taken in an unqualified sense; for if it applies to cases which really are beyond remedy, it also applies to those for which the remedy has not yet been, but for which it yet may be found.

¹ This lecture was delivered in January, 1874, and first published in 'Progrès Medical,' Nos. 4 and 5, 1874.

² Lecture delivered in November, 1875, and published in 'Progrès Medical,' No. 50, 1875.

The cases which are about to be introduced to your notice form two very distinct groups; in one, the recovery or improvement took place spontaneously without the intervention of the medical art; in the other, it has been intended, sought for, premeditated. I shall particularly dwell upon a case which belongs to the latter group.

This, gentlemen, is the case of a patient whom I showed you, for the first time, two years ago, and whom I again showed you last year. I will not discuss at any length the clinical history of the case; you can read it in the '*Progrès Médical*,'¹ which contains all the details. It has, besides, been republished in most of the French and foreign medical journals. I shall confine myself to stating the most salient feature of this history, in order, chiefly, to enable you to thoroughly realise what the condition of affairs was when therapeutic treatment began.

It is, in my opinion, a very fine example of *Ménière's disease*, or, better still, of *Ménière's vertigo*; for the syndromus to which these denominations relate do not exclusively answer to one morbid state only; it may show itself common to very different diseases of the ear.

The position of affairs at this epoch, that is, in last May, was absolutely the same as in 1874, that is to say, that G— was, for several years, literally confined to bed under the influence of a vertiginous state, permanently established, so to speak, and was thereby rendered nearly incapable of spontaneously executing movements of any extent. The slightest shake of the bed also exasperated it, to a high degree, and doubtless many of you remember the scared and anxious look of the patient's face, the rending shrieks which she uttered, when she was carried on a litter into the lecture hall.

In addition to this vertiginous state, which was, in some sort, habitual, and which is accompanied by an incessant rustling heard in the ear, G— was subject to the occurrence of great vertiginous crises, from time to time. I dwelt much, on a former occasion, on the description of these crises, because I believe they constitute the fundamental symptomatic fact, in *Ménière's disease*, whilst the habitual vertiginous state may, in some sort, be considered as a complication, an epiphenomenon which only shows itself in exceptional cases.

The fits in question are, as you recollect, always heralded and

¹ 1874, Nos. 4 and 5. M. Charcot here refers to the preceding lecture.

immediately preceded by the sensation of a shrill piercing sound, which supervenes suddenly and unexpectedly, and which, in the case of G— in particular—as well as in many other patients of the same kind—simulates, it seems, the strident sound of a railway whistle so closely as that it might be mistaken for it. I have been led to consider this abrupt whistle as one of the constant necessary elements, and, consequently, as a characteristic of *vertigo ab aure læsâ*. Quite recently, Dr. Lussana, in a series of interesting articles published in the 'Gazetta Medica Italiana Lombardia' (1875, t. xxxv, ser. vii, t. ii, No. 43, *et seq.*), has confirmed this point, which is of interest, both to clinical art and to pathological physiology.

As to the vertigo itself, it shows itself, in G—, conformable to the classic type; after the whistle a feeling of abrupt translation movement, in consequence of which the patient imagines herself flung forward or backward, as if by the impulse of some external force. Lateral impulses are much rarer in her case. Then we note absence of loss of consciousness, and presence of nausea and sometimes vomiting at the end of the fit.

I would remind you, as we pass, that this sort of motor hallucination is not always Platonic, if you will excuse the word; I have quoted several cases where the patients actually impelled by the vertigo fell heavily on the face; one of them broke the nasal bones; another, of whom I shall soon speak, broke several teeth.

I will conclude by remarking that, in the case of G—, the disease is of very old standing, the first symptoms dating back over ten years; that there exists in the left side a lesion of the drum with thickening of the membrana tympani, and an habitual running of pus mingled with blood.

Now, that you have present to the mind the former symptom-picture, I shall enter into some details to show you under what circumstances the improvement was effected which has enabled G— to stand upright, as you perceive, and to walk without assistance; to spend the day tranquilly seated in an arm-chair and to endure, without much emotion, all the shaking and shocks to which curiosity may subject her.

At the time of my conference on the vertigo of Ménière, delivered in 1874, I stated some therapeutic considerations. Amongst others, I noticed that vertigo, *ab aure læsâ*, even when most inveterate, recovered sometimes spontaneously, when the

patient became completely and irreparably deaf, and ceased to hear the whistling. I also asked myself if it might not be possible to purposely obtain this often desirable result by surgical intervention. I also recommended the employment of cauterly in points over the mastoid processes. The method which I did employ in the case to which I invite your attention, is both much simpler and much less radical.

The idea occurred to me that, by means of sulphate of quinine, which as every one knows, determines, amongst other phenomena, more or less marked rustling and buzzing in the ear, we might perhaps succeed in producing lasting modifications in the action of the auditory nerve, by sufficiently prolonging the employment of large doses. The result, as you will see, has justified these anticipations.

Giraud has taken sulphate of quinine, in doses of from 0.50 centigrammes to 1 gramme daily, in a regular manner—excepting several interruptions of some days, rendered necessary by gastric pains—during the whole of the months of May, June, and the first twenty days of July.

Towards the beginning of June, that is to say, about four weeks after the commencement, it was remarked that for some days the patient might be shaken in her bed, and transferred from one bed to another without giving utterance to any cry of distress, as had been once constantly the case under such circumstances.

When interrogated, she informed us that the shrill whistling had, towards the same epoch, first diminished in intensity and then completely ceased, simultaneously with the great vertiginous crises. The permanent buzzing had been replaced by a rustling, quite different in character, which seems to be connected with the action of the quinine. Encouraged by these first results, I requested G— to rise, and to try to stand and walk. She, at first, refused energetically, dreading the return of the vertigo, and also judging the attempt impracticable, to say no more. I insisted; finally, she consented and, one fine day, aided by two assistants she succeeded in making, not without great effort, two or three steps, rendered very difficult owing, it appears to excessive sensitiveness of the soles of the feet rather than to any vertiginous state. I required the experiment to be repeated every day. Rapid progress was made, for, about the 20th June (when the sulphate of quinine was suspended) G— had already been able several times, with suffi-

ently firm gait and no other help than her stick, to walk around the inner boundary of this vast hospital. The disease, since that period has made no aggressive return, and you may judge by yourselves that the attitude of the body and the gait do not much diverge from those of a person in good health. I would add that she is neither more nor less deaf than before. Hence, as you see, the sulphate of quinine has not operated here by determining complete paralysis of the auditory nerve.

The case to which I have just called your attention is not unique of its kind; I could mention others where the happy influence of the prolonged use of sulphate of quinine has been reported. I shall confine myself to one of them, because the result obtained was verified by several of my professional brethren.

I was called, in June, 1875, to give my advice concerning the state of a lady, aged about 30, who, for the past eighteen months, had become subject to epileptiform crises, it was said, or at all events to hystero-epileptiform fits. The bromide of potassium had completely failed.

At the consultation, it was thoroughly established that neither syphilis, nor hysteria, nor any traumatic cause whatever played a part in her antecedents. The patient, a very intelligent lady, at my request, willingly entered into the most minute details concerning the character of her fits. I learned from her that, during these attacks, she was greatly disturbed, greatly agitated, undoubtedly, but had never lost consciousness. The onset had always been abrupt and unexpected. The sensation of falling forward came on suddenly and, in point of fact, she had been actually flung forward several times, with her face to the ground, and, once, two of her teeth were broken. Hence, we had here a vertigo of translation, with abrupt onset, antero-posterior falling, no loss of consciousness, and therefore, some of the most marked characters of the vertigo of Ménière. In order to complete the resemblance I will add that, in the case of Madame X—, the fit often concluded by nausea, or even by vomiting.

These preliminary data once obtained, I summarily explored the state of the auditory acuteness, by the help of a watch, and I found that the hearing was very manifestly weakened on the left side. Then, I asked a final question. The reply to this should, in my opinion, decide the matter. I enquired whether it did not sometimes happen that a shrill sound more or less analogous to that of a

whistle was heard in the ears. The husband, who was present at the consultation, now spoke, quickly replying that Madame X—, in fact, was often surprised to hear the whistle of locomotives from a neighbouring railway station at unusual hours, whilst nothing of the kind had, in reality, occurred. The connexion between the abrupt development of whistling sounds and the invasion of the vertiginous fits was, after this, readily established.

I believed I could announce that we had here neither epilepsy, nor hystero-epilepsy, but Ménière's vertigo. I gave hopes that, by the assistance of an appropriate treatment, the fits might be made milder, and perhaps suppressed. Sulphate of quinine was prescribed in doses of 60 centigrammes, and the employment of this dose was to be continued for two months. Shortly after the commencement of the treatment, the whistling, and, simultaneously, the vertiginous fits ceased to be experienced. They have not made their appearance since.¹

¹ I could, to-day, quote a good number of other examples where the vertiginous phenomena, in question, have been very remarkably amended or even completely cured by the influence of the *prolonged use* of sulphate of quinine. Dr. Weir Mitchell related several facts of this kind, at the last congress at New York.

LECTURE XIX.

ON POST-HEMIPLEGIC HEMICHOREA.

SUMMARY.—*Post-hemiplegic hemichorea. Clinical facts. Disorders of general and special sensibility. Motor disorders: their resemblance to choreic movements. Trepidation of hemiplegic patients. Instability of members, affected by post-hemiplegic hemichorea. Characters of muscular disorders in rest and in motion.*

Organic lesions. Foci of intra-encephalic hæmorrhage and ramollissement;—partial atrophy of the brain.

Rarity of post-hemiplegic hemichorea. Relation between hemichorea and hemianæsthesia. Seat of lesions to which these symptoms belong; posterior extremity of the optic thalami; posterior portion of the caudate nucleus; posterior portion of the corona radiata.

Præ-hemiplegic hemichorea.

GENTLEMEN,—I will, this morning, ask your most particular attention to a group of phenomena which I propose to designate by the name of *post-hemiplegic hemichorea*. This denomination I borrow from Dr. S. Weir Mitchel, of Philadelphia, who has made use of it in a recent work.¹ Those amongst you who have followed my lectures, during the last few years, will easily recognise this morbid state, interesting examples of which I have, on different occasions, exhibited to them.²

According to the line of conduct, which I traced for myself, in resuming these clinical lectures—which I would in some sort compare to the “object-lessons,” so widely adopted in American

¹ “Post-paralytic Chorea,” in the ‘American Journal of the Medical Sciences,’ Oct., 1874, 342.

² *Léçons cliniques sur les maladies du Système Nerveux,* t. I, 1872-73, p. 279.

schools—I shall do my best to form a clear and full picture of post-hemiplegic hemichorea out of the history of the three patients whom I am about to question, in your presence.

The first patient, R— Marie, is fifty-one years of age. In her antecedents which, on the whole, possess but a mediocre interest, I will only notice the following points : the patient had typhoid fever at 18, and at 30, she had intermittent fever which lasted six months.

At 41, R— got an apoplectic attack, with loss of consciousness, and accompanied, it appears, with vomiting. Having regained her senses, she presented a hemiplegia with complete flaccidness of the right side. During the six months that followed the patient had, as she declares, an exact notion of objects. She remembered their names—consequently she had no verbal amnesia—but she was incapable of pronouncing them, owing to a difficulty in the articulation of words. I will add, moreover, that during this same period, there was momentarily, if we are to accept her statement, a certain degree of contracture in the muscles of the right hand.

However this may be, at the end of these six months, R— was able to walk more or less well. But, whilst she little by little and progressively recovered motion in the right lower limb, the movements of the corresponding upper extremity, although they had become possible and even extensively so, were soon embarrassed by a trembling of a special kind, choreic in character :—it is on this trembling that I am about particularly to insist.

Matters continued in the same way since that period, that is to say, for about ten years, and, especially, during the five years which have just elapsed, and during which R— has not ceased to be under our observation at the Salpêtrière.

We have to consider, in its present condition, the state of the right side of the body, first as regards the sensibility, then with respect to the motor functions. I show you, in the first place, the patient reposing on her couch, in order to facilitate our investigations ; but I will, in a few minutes, show her to you in the vertical position, and whilst walking.

a. There exists in R—'s case a general *hemianæsthesia* of the right side of the body. In other terms, sensibility is, on this side, gravely altered in the face, trunk, and members. Thus far with respect to *general sensibility*. This is not all ; *hearing, taste,* and the true cephalic senses : *smell* and *vision* are dulled on the same side. From this point of view we shall find in this patient, as you

have guessed, an exact reproduction of the characters of hysterical hemianæsthesia which are so well known to you.

Thus: 1°. As regards vision, there is, in the right eye, a modification, though a slight one; visual acuity is here simply diminished. 2°. With respect to smell, the alteration is more marked; the patient is absolutely unable to perceive, with the right nostril, the odour of ether. 3°. The change is still more distinct where the hearing is concerned: the patient who hears very distinctly the ticking of a watch with the left ear only perceives it in a very confused manner with the right. This diminution of hearing power was noted from the commencement of the observation, for R— complained of it, herself, at the outset, without having had her attention called to this point. 4°. The loss of taste will be placed beyond question by the test with colocynth which we are going to apply. You see that she does not perceive its bitterness on the right, whilst she denounces it the moment the substance touches the left side of the lingual mucous membrane.

You have just verified, by yourselves, gentlemen, the exactness of our assertion so far as the special senses are concerned; you will be convinced, in an instant, that the examination will not be less conclusive when it bears on the question of general sensibility: the latter is, I repeat, manifestly diminished over an entire half of the body. The contact of a cold substance is much more keenly felt on the left than on the right. Tickling, introduction of a foreign body into the right nostril, scarcely produces any reaction. Lastly, over all this side of the body: face, trunk, and limbs, an analgesia of the most marked character exists, since you can plunge, deeply and rudely, a large pin into these parts without the patient showing the slightest sign of suffering.

This, gentlemen, as I reminded you a few months ago, is an union of symptoms which we have often occasion to observe in hysteria, and more especially in *ovarian hysteria*.

But, in the case of R—, hysteria is, however, not in any way at work, an additional proof, if need were, that in diseases of the nervous system, as in all others, no phenomenon, taken singly, can be truly characteristic. It is the mode of grouping of the phenomena, their mode of evolution, concatenation, the whole array of circumstances which chiefly serve, here as elsewhere, to establish nosographic distinctions.

b. I now approach the second point, to wit: the study of the

motor disorders which this woman presents. These disorders are very peculiar. If they be deficient in the face, in this instance, they are, on the contrary, very evident in the upper and lower extremities of the right side. These, as I can show you at once, present neither atrophy nor contracture, nor any deformity whatever. We will now examine them successively, when at rest, and when in motion.

In intentional movements of the upper limb a choreiform agitation is manifested which is altogether comparable to that which I have, on a former occasion, described in connection with disseminated sclerosis. So long as R— is quiet, at rest, there is *almost* no motor disorder in the limb; on the other hand, in the act of lifting a glass of water to the lips, the arm is immediately seized with very extensive rhythmical movement, so that, if she were not watched, the water would be violently dashed about in all directions. We shall see, in one moment, when she is walking, analogous phenomena exhibited in connection with the right lower limbs.

This motor-disorder not only resembles the trembling of disseminated sclerosis, as I have just said, but it also, in some respects, resembles a phenomenon which is ordinarily observed in common cases of hemiplegia; I allude to the tremulation which rarely fails to appear when the lateral columns of the cord are affected with sclerosis to a certain degree, provided always that, contracture being little marked, the voluntary movements are still possible to a certain extent. These post-hemiplegic choreiform movements diverge, on the other hand, from the incoördination of ataxic patients, were it only because of the fact that vision exerts no influence over them.

But, there is a character which fundamentally divides these choreiform movements from the trembling of disseminated sclerosis; the tremulation of hemiplegic patients, and the motor incoördination of ataxia; and which, on the other hand, brings them close to chorea; this is the existence of an *instability of the affected members* at a time when the patient does not *will* any movement. The limbs, even in this case—it is very important to remark—are stirred by small involuntary movements analogous to those which, in the same circumstances, are seen in ordinary cholera. These movements, as you may observe, are very manifest in the lower extremity. You see in fact, the patella, as it were, incessantly raised, and that in a rhythmical manner, by the sudden and involuntary contractions of the anterior muscles of the thigh; you

see, at the same time, the foot, in spite of the patient's will, twisted by turns into adduction and abduction, and then flexed and extended.

The hand, as is also seen, cannot remain at rest, by the patient's side; it is constantly shaken by sudden and unexpected jerks, whilst, at the same time, the fingers are stretched or flexed, without cause.

I will add that, in cases absolutely comparable to the preceding, but still more marked, these involuntary and very extensive movements constitute a perpetual agitation which, in fact, causes this state, so far as the character of its motor disorders is concerned, to differ in no essential features from chorea properly so called.

Hence, it is to the term *chorea* that we shall have recourse in order to designate the phenomenon in question. Of course we wish to indicate a simple resemblance, and by no means a real nosographic assimilation with common chorea (*chorea minor*); undoubtedly the habitual coexistence of hemianæsthesia, long since noticed in ordinary chorea, according to the observations of my former colleague, Moynier, is also a trait which the latter possesses in common with the disease which occupies us; but, on the other hand, distinguishing characters abound. It will be enough for me to point out, as regards cases of *post-paralytic hemichorea*, the exact and definite limitation of the motor disorders to one side of the body only: next, the pre-existence of a long established hemiplegia with flaccidness of the muscles at first, then marked by a certain degree of contracture, finally the sudden and truly apoplectic onset of the phenomena. These, you see, are phenomena which do not belong to the common St. Vitus's dance.

In short, the affection from the beginning, showed itself in R—'s case, under the form of cerebral apoplexy followed by abrupt formation of a focus of intra-encephalic ramollissement or hæmorrhage. And in reality, gentlemen, it is, beyond a doubt, to one or other of these organic lesions that we must refer the phenomena which I have pointed out in our patient's case.

The choreiform movements, of which I have striven to make you acquainted with the principal characters, present themselves under a new aspect, when the patient endeavours, with the help of a stick which she holds in her left hand, to stand upright and motionless, or proceeds to walk. Then the whole body, as you see, is shaken with jerks which result from the fact that successive movements of sudden flexion and extension take place, involuntarily, in the knee,

and in the ankle-joint on the right side. You will remark that, on the contrary, the upper limb of the same side remains nearly motionless. But that happens simply because of a subterfuge; the hand is, in fact, held closely applied along the side of the body, or else thrust into a pocket; without which, it would, like the lower extremity, be constantly in motion.

Post-hemiplegic hemichorea does not exhibit itself connected only with the existence of foci of intra-encephalic hæmorrhage, and ramollissement, such as we commonly see in the adult. It may also supervene, owing to those lesions, still rather imperfectly known, at least in the first phases of their development, which, in young children, determine what is termed *partial atrophy of the brain* (Cotard, 'Thèse de Paris,' 1868). The usual consequence of these alterations, as Bouchet and Cazauveilh have long since shown, is an incurable hemiplegia, most frequently with contracture (spasmodic hemiplegia of Heine). But, in such a case, it may occur, though, indeed, very exceptionally, that the hemiplegia gives place, as it were, from the outset to a hemichorea, quite similar to that which we have just described. When once constituted, this hemichorea will persist so long as life lasts. I am in a position to place two examples of this kind before your eyes.

R— is, at present, aged 18. Placed soon, after her birth, in the country, she seems to have been subject to convulsions since she was two years old; it is certain that when she was taken home, by her parents, at the age of four and a half years, the upper and lower extremities, on the right side, were paralysed, and that she got epileptic fits from time to time. Her general health was, moreover, much affected, and she remained constantly sitting or lying down. Thanks to the care lavished on her, she gradually recovered strength, and even at the end of some months became able to walk and to make some use of her right arm. From this moment, it was remarked that the right hand was agitated by a sort of trembling, during intentional motion; but the choreiform movements, supervening independently of any voluntary act, were, it appears, chiefly marked from the time she was seven years of age. They have not ceased to exist since that period. I shall not enter into details respecting them. That would only be to reproduce every point of the description given in reference to our first patient. I will only point out that, contrary to what takes place in the great majority of cases of *post-hemiplegic hemichorea* of the adult, hemianæsthesia

is here completely deficient.¹ This very peculiarity, that is to say, the absence of anæsthesia in the limbs attacked with chorea, was also exhibited in the following case, which also relates, like the foregoing one, to hemiplegia of young infants.²

Gr—, aged 29, experienced at the age of eight months convulsions qualified as epileptiform, and followed by hemiplegia of the left side. Since that time she has not ceased to be subject to epileptic fits. The limbs on the right side are, at present, somewhat weaker and more slender than those of the other side, but they are neither contracted nor insensible. They appear incessantly shaken with choreiform movements, in which the face does not seem to participate, and which are exaggerated by the performance of intentional acts.

I return now to the case of Ronc—. The motor disorders, which we have studied in this patient, are far from being a commonplace phenomenon in the history of intra-encephalic hæmorrhage and partial ramollissement of the brain. In fact, in a considerable number of cases, relating to these lesions, which I have collected at the Salpêtrière during a dozen years, I have remarked post-hemiplegic hemichorea five or six times at most. As a rule, when hemiplegia supervenes, owing to the formation of an intra-cerebral focus of hæmorrhage or ramollissement, motor paralysis, if the case be favorable, gradually lessens and finally disappears completely without the appearance of choreiform movements at any period; or else, if the case be grave, the paralysis persists such as it was, with or without the accompaniment of permanent contracture, sometimes complete, sometimes incomplete. Here, again—I speak, of course, of the rule, and I reserve the chapter of anomalies—the choreic shaking is entirely deficient; only, if motor inertia be incomplete, it may happen, principally when there is a certain degree of contracture, that the intentional movements are disturbed by a kind of *trepidation*, which we have already discussed, and which has nothing in common, I told you, with the convulsive shaking seen to be manifested in chorea, even irrespective of the performance of voluntary acts.

What, then, are the apparently very special conditions which,

¹ Permanent hemianæsthesia is, sometimes, produced in consequence of partial atrophy of the brain, dating from early childhood: I have recently met with an example of this kind, in the infirmaries of the Salpêtrière.

This patient, and the next mentioned, belong to M. Delasiauve's wards.

in some exceptional cases of cerebral hæmorrhage or ramollissement (*en foyer*), cause the hemiplegia, contrary to the usual rule, to be, at a given moment, replaced by hemichorea? I cannot, at present, answer this question by a regular solution. Here, however, in my opinion, is the direction in which this may be sought for. I believe that these foci of hæmorrhage or encephalomalacia which determine hemichorea assume, in the encephalon, a peculiar, fixed position, quite different from the very varied positions occupied by the foci which produce common hemiplegia. I base my opinion chiefly on this remarkable circumstance, already made prominent, namely, that *cerebral hemianæsthesia* (that is, with participation of all the special senses, including vision and smell)—this phenomenon, which is so rarely seen connected with common hemiplegia—is, on the contrary, a very usual, though indeed not a necessary, accompaniment of *post-hemiplegic hemichorea*. Now, it appears to be established that this particular form of hemianæsthesia depends on lesions localised in certain points, ever the same, of the cerebral hemispheres, the seat of which seems, to-day, to be well nigh ascertained. It is therefore already probable from this, that the nerve elements, fibre-fascicles or ganglionic corpuscles, the lesion of which will produce hemichorea, border on those whose destruction determines hemianæsthesia.

Necroscopy, besides, has testified in favour of this hypothesis. Three times, I have had occasion to make the autopsy of subjects, in whom hemichorea of several years' standing had followed on hemiplegia, marked by an abrupt, apoplectic onset. In these three cases, the hemianæsthesia existed, well marked, as we have seen in the case of our patient, Ronc—. In addition, just as in her case, but undoubtedly owing to a mere chance coincidence, it is the left side which is here affected. However it be, the lesion revealed, on autopsy, consisted of *ochreous cicatrices*, unmistakable vestiges of the former existence of hæmorrhagic foci. The cicatrices in question occupied, in the right hemisphere, always the same region, or very nearly so, and here is a note of the parts which they involved: these were constantly, that is to say, in all the three cases: 1°. The posterior extremity of the optic thalamus. 2°. The most posterior part of the nucleus caudatus. It is expressly noted that the anterior two thirds or three fourths of these grey nuclei had remained perfectly sound. 3°. Lastly, the most posterior portion of the crus of the corona radiata.

In two of the cases only, one of the tuberculi quadrigemini, the foremost one on the side corresponding to the ochreous focus, participated in the alteration.

What, in this enumeration, are the lesions which determined hemichorea; what, on the other hand, are those to which the hemianæsthesia is due? The latter, as we have endeavoured to show elsewhere, depends on an alteration of the most posterior fascicles of the corona radiata. The alteration of the hindermost portion of the optic thalamus, that of the tail of the corpus striatum, should therefore remain to the credit of the hemichorea, for we cannot rely on the non-constant lesion of the tuberculi quadrigemini. But, on the other hand, we have often and often seen the optic thalamus and the lenticular nucleus affected in their several parts with the most varied lesions, and not the slightest trace of choreic movements resulting. So that, according to all appearance, neither should these organs be arraigned in the present instance. I believe it more probable, (but this is simply an hypothesis which I submit for your consideration and criticism), that on one side, undoubtedly in front of the fibres which, in the corona radiata, serve for the transit of sensory impressions, there are fascicles of fibres endowed with particular motor properties, the alteration of which determines hemichorea. A delicate anatomico-pathological analysis, guided by clinical observation, will perhaps some day succeed in circumscribing exactly the adjacent regions corresponding to these two orders of fascicles.

Along with post-hemiplegic hemichorea we may mention a pathological condition which is, as it were, the converse of this, that is, a condition in which the choreiform movements, suddenly developed in the limbs of one side of the body, after the apoplectic shock, soon give place to more or less complete hemiplegia. Hemianæsthesia usually accompanies this kind of hemichorea, which may be termed *præ-hemiplegic*. Cases of this kind are, no doubt, rather rare; I have not collected more than three examples. An autopsy was made in only one of them. A hæmorrhagic focus was found, about the size of a small nut, which distended the posterior half of the optic thalamus. The patient had succumbed about three weeks after the invasion of the apoplectic symptoms. A complete and absolute hemiplegia had replaced the hemichorea, three days after the invasion.

According to what has been stated above it is, evidently, not by

disorganising a part of the optic thalamus that the hæmorrhage here produced either the hemichorea, or the hemianæsthesia. Here two orders of symptoms ought, apparently, to be both correlated to the effects of the compression which had borne upon the internal capsule and the foot of the corona radiata, in the immediate neighbourhood of the focus.

Hemichorea, whether accompanied by hemianæsthesia or not, may again be produced, not now suddenly, but in a slow and progressive manner, and without being necessarily either followed or preceded by hemiplegia, in consequence of the development of certain neoplasias in the substance of the hemisphere. Cases of this kind are rather frequently met with; and I quoted, on a former occasion, several remarkable examples. It is as probable as can be that the morbid products which determine such effects depend on a localisation analogous to that which we endeavoured just now to determine in connection with hæmorrhagic foci; but we do not yet possess any positive data, with respect to them. This will be an interesting subject for future research. The patient, whom I am now about to introduce to your notice, evidently belongs to the category of cases which I have just pointed out.

She is about 60 years of age. She has been suffering for some fifteen years with wandering pains, occupying the whole extent of the right upper limb. From 1869, she became subject to epileptiform crises, rather imperfectly defined, and towards the same period this same upper extremity was seized with choreiform trembling. The tremor in question is, as it were, permanent; it becomes manifestly exaggerated in purposed movements, but it subsists irrespective of any voluntary act. It is, besides, brought much closer, by the general aspect of its characters, to the shaking of chorea than to the trembling proper to paralysis agitans or senile "palsy." I will add that a total hemianæsthesia, with participation of the special senses, has been observed in this patient, during the whole of last year. It occupied the right side of the body; at the present moment, special sensibility appears to have been re-established throughout, and as to general sensibility it has again become nearly normal in the face, the trunk, and the lower extremity of the right side. The right upper limb alone, the seat of choreiform movements, still presents throughout its whole extent a well-marked weakening of tactual sensibility.

In concluding, I would, yet once more, bring out the, at least,

external, analogies, which draw together the symptomatic choreas, connected with coarse lesion of the encephalon, and common chorea. The latter, like the former, may remain temporarily at least confined to one side of the body; it is often accompanied by hemianæsthesia, it may be preceded or followed by hemiplegia, &c., &c.; in short, the difference that separates these two orders of affections, which are so radically distinct, from a nosographic point of view, is rather perhaps in what we are accustomed to call the *nature of the disease* than in its anatomical position. If the latter, so far as symptomatic choreas are concerned, were once exactly determined, we would know at least one of the regions of the encephalon where we should seek for those delicate alterations to which the symptoms of common chorea are due.

LECTURE XX.

ON PARTIAL EPILEPSY OF SYPHILITIC ORIGIN.

SUMMARY.—*Partial or hemiplegic epilepsy. Its relations with cerebral syphilis. Historical considerations. Description of a case of partial epilepsy of syphilitic origin. Characters and peculiar seat of the cephalalgia. Necessity of energetic therapeutical intervention.*

Modes of invasion of the convulsive symptoms. New corroborative examples. Succession of fits. Appearance of permanent contractures. Relations between the cephalalgia and the motor region of the brain.

Lesions. Gummatous pachymeningitis. Probable seat of those lesions.

Mixed treatment, with interruptions.

GENTLEMEN,—*Partial or hemiplegic epilepsy*, of which I recently endeavoured to make you grasp the principal symptomatic characters and varieties, basing my remarks on the description of Bravais,¹ on the more recent work of Dr. H. Jackson, of London, and also on my own observations, is one of the most frequent manifestations of *cerebral syphilis*. That, we may say, is a fact emphatically recognised and proclaimed to-day, amongst our British brethren, as witness, among others, the writings of R. B. Todd, those of MM. Jackson, Broadbent, T. Buzzard,² and some others. On the other hand, in France, if I mistake not, it has not yet been remarked as much as it deserves to be on account of its practical interest, although one of the most competent authorities on these matters, Dr. A. Fournier, laboured last year to popularise a know-

¹ 'Thèse de Paris,' No. 118, t. iv, 1827.

² Broadbent: 'The Lancet,' 21 Feb., 1874. T. Buzzard: 'Aspects of Syphilitic Nervous Affections,' London, 1874.

ledge of it, in a work which I cannot too strongly recommend to your consideration.¹ Consequently you will, I trust, regard it as opportune if I call your attention, for a moment, to a subject which has yet been perhaps insufficiently studied, and give you a summary abstract of a certain number of rather regular examples of partial epilepsy of syphilitic origin, which I have lately had occasion to observe. In the course of my statement I will try, as we proceed, to give you an opportunity of laying your finger on certain peculiarities which are often exhibited by this clinical form of cerebral syphilis. But, I shall always have at heart to render prominent the fact that, in such cases, the opportune administration of appropriate agents, when it is resolutely, I was about to say, daringly carried out, according to a certain method, may triumph, and sometimes very rapidly triumph over all obstacles, and bring about a lasting cure even in cases where the same agents, administered on other principles, or at least more timidly, would have completely failed.

I.

On the 13th December, 1874, I was called by Dr. Malhéné to see M. X—, aged 40, affected by serious cerebral symptoms, and confined, on this account, to his room for several months. In his statement, M. X—, carries the present disease back to the month of July, of the same year. Having been employed in a banking house, he was seated, one day as usual, at his desk engaged in writing, when, suddenly, without having noticed any immediate precursory phenomena he felt, not without dismay, his right lower limb shaken by convulsive, rhythmical, hurried, and very energetic jerks. This species of trepidation lasted for, perhaps, some seconds, then the rigid lower extremity rose in one piece, and immediately afterwards M. X— fell to the ground, senseless. He did not recover consciousness for about an hour, and he knows nothing of what happened during that time. On the morrow, he was able to return to business, and no new accident had been experienced, when, one day in September, just as he was getting down from an omnibus he fell on the pavement, in a state of unconsciousness, after having experienced for some seconds, as before, the selfsame trepidation with rigidity of the right lower extremity, already mentioned. A slight paretic weakening of the limbs of the right side,

¹ "De l'épilepsie syphilitique tertiaire," leçon professée, par A. Fournier, (Clinique de Lourcine.) Paris, 1876.

a noticeable confusion of ideas, a certain degree of dulness of the mind, such were the symptoms which followed this second attack, and which have persisted after it. From this period, M. X— gave up work, and left his dwelling only at rare intervals, chiefly because he was always in dread of being seized in the street, with another attack.

Towards the middle of the month of November, without apparent cause, without any warning, the third attack smote him; this time the duration of the phenomena of the *motor aura* continued longer, and the patient, before losing his senses, had time to perceive that the convulsive rhythmical shaking, as well as the rigidity, after occupying the right lower limb, did, without abandoning this position, rapidly invade the upper limb on the same side. A spectator of the accident relates that the head was next twisted towards the right shoulder, whilst the right side of the face was grimacing; then the convulsions extended to the whole body, but still predominated on the left side; and after their cessation, stertorous sleep supervened. It is certain that during the fit M. X— did not bite his tongue, nor micturate under him. Whilst still in a state of unconsciousness several other fits occurred, all similar in every respect to the first, so as to constitute a *status* which lasted for about three hours. The consecutive phenomena, mentioned already in connection with the September fit, simply became more marked after the last-mentioned attack: for some hours there was found, in addition, a certain degree of difficulty in speaking and verbal amnesia, a feeling of numbness in the cheek of the right side, in the vicinity of the labial commissure; but the latter symptoms have been quite transitory, they had quite disappeared when I saw M. X—.

After verifying the existence of the weakening of the right extremities, of which I had been informed, and which was only slight, I remarked that they were not the seat of any feeling of formication, and that they did not show any trace of anæsthesia. Lastly, I found that the vision was nowise disturbed.

On hearing the narrative of M. X—, I had been naturally led to suspect that, in his case, syphilis might be at work, and I at once proceeded to an examination of the different parts of the body accessible to the eye, hoping to meet the traces of some one of the later manifestations of that disease. The result of this investigation was wholly negative.

It was not so as regards the study of his antecedents, which, on the contrary, enabled me to gather some very significant information. I learned, in fact, what follows:—At the age of twenty-nine, that is to say, twelve years before the appearance of the first epileptiform attack, M. X— had contracted a hard chancre, soon followed by various manifestations due to constitutional syphilis, roseola amongst the rest. The treatment of the disease, at this period, seems to have been regularly directed and continued for several months.

Matters remained so, and for more than ten years M. X— had lived in good health, enjoying perfect security, when, towards the close of 1873, he began to experience a singular indisposition, chiefly denoted by great prostration of strength, inaptitude for intellectual work, well-marked dyspeptic disturbances, which were very tenacious and showed themselves rebellious to the administration of the usual remedies. A certain degree of wasting, a rather marked cachectic state, which no visceral affection seemed to account for, and, lastly, a cephalalgia of a peculiar kind arrived soon after to fill up the picture.

This cephalalgia has never entirely ceased to exist to a certain extent since then. I have not, however, discussed it hitherto, whilst enumerating the symptoms, because I desired to commend it specially to your attention. At the outset, it was always localised in a circumscribed space, not larger than a franc, above the right eyebrow, towards the temple. Afterwards, when an exacerbation occurred, it often extended to the top of the head, and even to the occiput, without, however, ever quitting its primary position. It appears to be well established that the exacerbations take place, usually, towards seven o'clock in the evening, extending more or less into the night, and sometimes hindering sleep: they have never been followed by vomiting.

If I insist upon this head-pain, it is because you will find the same phenomenon, with the peculiarities just described, in the history of many cases of syphilitic epilepsy. This fact has, indeed, been several times pointed out by the authors who have occupied themselves with these questions: “If pain in the head,” remarks, for instance, Dr. Buzzard, “be associated with the convulsive attacks, it generally precedes the outbreak in syphilitic convulsion, and is often localised in one particular spot. There is frequently a history of antecedent pain for months before the first fit.”¹ Unquestionably

¹ T. Buzzard, loc. cit., p. 14.

we ought not, by any means, to go so far as to compare this cephalalgia, fixed in one spot, and long preceding the convulsive attack as a characteristic sign; it may, in truth, be met with in different forms of partial epilepsy, independent of syphilis. Nevertheless, in this disease, it is generally much more marked than anywhere else, hence it is an element which the clinical observer should not disdain to utilise, since it may sometimes contribute to elucidate the diagnosis.

After collecting the information which has been related, I believed myself authorised to declare that the different accidents, experienced by M. X—, for eighteen months, were attributable to syphilis and that probably they would give way to the properly directed use of the mixed treatment. I was then informed that, in accordance with the advice of a physician who had been previously consulted, M. X—, for more than a year, had perhaps never completely ceased to make use of either syrup of iodide of mercury, or of iodide of potassium, taken in medium doses. This revelation did not discourage me, and, relying on the experience of former cases, I expressed the opinion that we should here proceed, as it were, by a *physical-force assault* and endeavour to precipitate the *denouement*; that, in other words, the immediate administration of large doses would triumph perhaps, rapidly, where the prolonged action of medium doses had been found inefficient to prevent the occurrence of the symptoms and to combat them, when once developed. We agreed, Dr. Malhéné and myself, to prescribe a treatment as follows: each day, 5 or 6 grammes of Neapolitan unguent was to be rubbed in, whilst, at the same time, iodide of potassium should be taken in doses of from 6 to 8 or 10 grammes in the twenty-four hours, one portion to be swallowed, the other to be injected as an enema. The treatment should be continued, as much as possible, in all its rigour for about twenty days, then completely suspended for some days; recommenced anew in the same manner as at first, and so on for three or four turns.

I saw M. X—, at the end of 1875. He informed me that the treatment had been begun on the day following the consultation; that, two months later, the improvement in all the permanent symptoms—cephalgia, paresis, dyspepsia, cachectic condition—was such that he had already been able to resume his business; that, a month later, he regarded himself as completely cured; that, lastly, as to the epileptiform attacks, they had not again reappeared,

and that he had not experienced any sensation which would make him apprehend their return.

I saw M. X—, again, at the end of 1876. At this period, his recovery had never been marred for a single instant.

II.

As I have already had occasion, several times, to point out to you, it is in one of the upper extremities, or, in one side of the face, that the outbreak of the convulsive attacks occur, in the great majority of cases of partial epilepsy, whatever its origin may be.¹ Hence, an invasion which should first begin by assailing one of the lower extremities ought to be considered, in this category, as a rare and exceptional fact. Yet, we have just seen this mode of invasion noted in the preceding observation; owing to a curious concurrence of circumstances, we are about to meet with it, once again, in the following case, in which as in the former, cerebral syphilis was the disease at work.

A foreign physician, passing through Paris, requested me, August 26, 187—, to visit him in order to advise him in the following circumstances:—When dining with a friend, on the second previous evening, he had been tormented, during the entire time of the dinner, by the exasperation of a headache from which he had been suffering, in a moderate degree, for some days. On rising from table, he resolved to return home immediately, on foot; but he had only taken a few steps in the street when, suddenly, his right lower extremity became rigid, and, at the same time, was shaken, in some sort, by hurried and violent rhythmical convulsions. Almost immediately after the upper limb, of the same side, was invaded in its turn, and, at this moment M. B— fell, insensible, on the pathway. On recovering consciousness he was much surprised to find himself reposing in his own bed, whither he had been carried. The time during which he was insensible may have lasted for an hour.

During the night he was sleepless, and during the following day attacks of the same kind came on two or three times. None of them, however, went, like the first, so far as loss of consciousness. Each time they occurred the patient assisted, not unmoved, at the

¹ This fact, already pointed out by Bravais, has been still more explicitly described by Dr. H. Jackson, "A Study on Convulsions," in 'Transactions of the St. Andrew's Medical Graduates' Association,' t. iii, 1870. My own observations fully confirm it.

gradual and regular invasion of the convulsive movements which, always beginning by the left lower limb, next took possession of the upper extremity on the same side, and sometimes also of the corresponding half of the face. A new attack, which was also an *abortive* one like those of the day before, had taken place in the morning of the day in which I saw M. B— for the first time. During all this period the headache had not ceased to plague him, becoming cruelly exasperated at the instant when the convulsive phenomena were about to show themselves.

I found M. B— to be an individual in the prime of manhood, tall, strongly made, and habitually enjoying excellent health; for some weeks, however, he had been feeling indisposed, without appetite, heavy, easily fatigued by the least effort, and, moreover, his features had grown visibly paler.¹ Having noted, at the outset, in this case, the absence of motor paralysis, and—headache excepted—of all disturbance of sensibility, alike in face and in limbs, I readily perceived that there existed a certain degree of confusion in his ideas, and perhaps also a little trouble in speaking, without, however, any symptoms of aphasia.

The question of remote antecedents was particularly interesting. M. B— confided to me that, eighteen months before, he had contracted a hard chancre, and that, subsequently, various diathetic symptoms had appeared, amongst the number being palmar psoriasis, traces of which, indeed, could still be remarked.

I did not hesitate, as you may guess, to connect the nervous disturbances which M. B— experienced with the syphilis from which he had suffered, and I advised him to act, consequently, in a prompt and energetic manner. It was agreed that the treatment should be begun in accordance with the plan described when speaking of the case of M. X—, and put in practice immediately. The administration of iodide of potassium and mercurial frictions were commenced the same day. An *abortive* attack, this time confined to the lower extremity, took place once more on the morrow, or after morrow: it was the last, and at the end of a fortnight his general health had become so much improved that M. B— was able to return to his native land.

During a short stay which I made in —, about a year after the occurrence of the 24th August, 187-, I had the pleasure of meeting

¹ With respect to the cachectic state and earthy pallor which individuals, affected with cerebral syphilis habitually present, see the interesting remarks of Mr. Buzzard, in reference to diagnosis, *loc. cit.*, p. 83.

M. B— at —, and of finding him in a state of perfect health. The treatment, prescribed in Paris, had been followed, with due interruptions, for the space of about three months. No nervous disorder had reappeared.

It may happen that attacks of syphilitic partial epilepsy are preceded by a certain number of fits, in which loss of consciousness suddenly occurs, quite unexpectedly, without immediate forewarning symptoms, whilst the convulsive movements simultaneously show themselves everywhere; and thus, consequently, we get the classic picture of common epilepsy. The case, of which I am about to state the principal details, gives us an example of this kind. It also presents a certain number of other interesting peculiarities.

M. K—, born in the Antilles, of a delicate constitution, and in the highest degree impressionable, was attacked with indurated chancre in 1868, at the age of 29. Among the syphilitic manifestations, which, sooner or later, followed on the primary disease, was a double iritis of extreme tenacity, spots (^p) on the brow, palmar psoriasis, intense and prolonged rheumatic pains, great and lasting anæmia, and, finally, subacute arthritis which had chiefly affected the tibio-tarsal articulations. Treatment, suitable to the circumstances, had been followed almost continuously for about six months and was then finally abandoned.

All went well till 1873. Towards the close of this year, M. K—, who, for several months, had filled an official post in Cochin-China, was attacked with the diarrhœa of the country, and, owing to this, he became extremely weak. Towards the same period, he began very often, almost constantly, to suffer from pains in the head, which he believed to be megrims, and which persisted, growing worse, up to recent times.

In May, 1874, about six years after the outbreak of syphilis, although the diarrhœa had a little improved for some time, M. K—, who was always very weak, and always suffering from headaches, was, after an excited discussion, suddenly attacked with an epileptic fit, with immediate loss of consciousness, convulsions generalised from the outset, foaming at the mouth, and involuntary micturition, &c. The invasion, I repeat, appears to have been literally sudden, unannounced, and the patient knows nothing of the fit, save what he was afterwards told by those present.

In consequence of this attack it was decided that M. K—, on account of the long ailing state of his health, should take unlimited

leave and return to France. On the steamboat, during the voyage home, a new fit came on, quite similar to the first; then, some days after, another, but this one was very different from the previous attacks. On this occasion, the patient had first felt his left hand close up convulsively and the arm stiffen, then the neck twisting round brought his face towards the left shoulder. Lastly, as though drawn by an invincible force towards the left, he fell over on that side, and it was at this moment only, that is, some seconds after the invasion of the attack, that loss of consciousness supervened. The true character of the convulsive symptoms was thus revealed, henceforth, the fits never again made their reappearance but under the form of partial or hemiplegic epilepsy, sometimes with, oftener probably without, loss of consciousness.

From the 9th July, when the patient landed at Marseilles, to the end of October, in other words, during a period of nearly four months, they have never ceased to appear every five or six days, and sometimes even several times a day.

During the three first months, if we except the cephalalgia which was almost always present and localised as I shall describe, in a circumscribed spot in the right parietal region, the intervals between the attacks remained free from any persistent symptom; but, in the first days of October, the contracture began to take possession of the left upper limb, of the hand especially, and to occupy it in a persistent manner so as to keep it, permanently, in semiflexion. It even invaded, though to a less extent, the corresponding lower extremity. It should be added that the contracted hand and forearm had, at the same time, become the seat of disagreeable formication, and also of an exquisite hyperæsthesia; the patient dreaded extremely lest this limb should be struck, or even lightly touched; and if this happened, by chance, to occur, he shouted with the pain. He declared that, on several occasions, a shake experienced by his painful hand had given rise to one of his convulsive attacks.¹

It will, probably, not be out of place to give you a description of the principal phenomena which mark these attacks, such as I have received them from the lips of a very intelligent person, who witnessed the principal phases of M. K—'s disease. I shall also utilise, in my statement, the observations made by the patient

¹ It is not unknown that fits of partial epilepsy of cerebral origin may be provoked by certain acts. In one of my patients, named P—, affected by contracture of the upper and lower limbs of the left side, which is to

himself during the occurrence of those of his attacks in which consciousness was preserved.

The invasion of the convulsions is constantly announced by an exasperation of the cephalalgia localised, as has been said, in a spot of the right parietal region. The pain, at this moment takes a throbbing character, and, at the end of some minutes, it seems to spread over half the face and neck of the same side. Warned by these premonitory phenomena, the patient has almost always time to get to bed, and lie down. Then, the left upper limb is seen to become excessively flexed, at the wrist- and elbow-joints, and at the same time to assume the attitude of forced pronation; some seconds after, rhythmical shocks are experienced which shake it throughout its whole length. The hand is soon brought round towards the left shoulder, and is also shaken by the same jerks; at the same time, on the left side of the face, grimaces occur and are rapidly repeated. The left lower extremity is invaded, in its turn, it stiffens out in forced extension, rises above the level of the bed, then after some seconds it is taken with trepidation. Lastly, in certain fits, the stiffness and rhythmical convulsions invade the regions of the opposite side of the body. When loss of consciousness takes place, this is the moment at which it supervenes. I should add that the patient, after having experienced the feeling of being drawn towards the left, several times became subject, during the fit, to a real rotation-movement, from right to left, round the longitudinal axis of the body, and, at the end of the attack, has found himself lying prone, his face to the ground.¹

some extent permanent, but which becomes considerably exasperated when she stands or walks, the *spontaneous* fits begin, by the lower extremity, and the latter then becomes excessively stiffened in extension, the foot taking the attitude of spasmodic talipes equinus, and trepidation soon supervenes. The upper limbs, and then the face, are next invaded, successively, and loss of consciousness supervenes in certain cases. When the fits have not appeared for some time it is always possible to provoke artificially their development by suddenly turning up the top of the left foot; trepidation almost certainly shows itself as a consequence, and all the other phenomena of the fits follow.

¹ It is remarkable that, in the case of M. K—, the attacks came on, nearly always between five and six o'clock in the evening. M. Lagneau fils, 'Maladies syphilitiques du système nerveux,' Paris, 1860, p. 125, has collected several examples of syphilitic epilepsy, in which the fits came on chiefly in the evening or night.

Such is the regular and constant order of the succession of convulsive phenomena. I believe I ought to mention to you, incidentally, that the mode of invasion takes place here in conformity with the rule established by the ingenious studies of Dr. H. Jackson. You have not, in fact, forgotten that, according to this distinguished physician—whose assertions with respect to this matter I have more than once been able to verify—when convulsions in partial epilepsy, commencing by the upper extremity, tend to become generalised, they only invade the lower limb after having first affected the face. If, on the contrary, the case be one in which the face is first affected, the upper extremity is the next taken; and, lastly, comes the turn of the lower limb. Finally, if, as in the two first observations which I have reported, the convulsions should first invade the lower extremity, they spread successively to the upper limb first, and then to the face. This order seems to be almost never inverted, a fact which is not merely curious, but one well adapted, you will understand, to throw light upon various questions belonging to the domain of pathological physiology.

From this same point of view of physiological interpretation, I will notice that the cephalalgia, the exasperation of which announced in M. K—'s case the development of the fit, occupied a circumscribed spot in the right parietal region, whilst the convulsions affected parts on the left side. This alternate arrangement of the convulsions and the head-pain has been more or less mentioned in a certain number of cases of partial epilepsy of syphilitic origin,¹ or independently of syphilis; and perhaps the relationship in question may be, in similar cases, more frequently noted in future, when greater attention shall have been paid to seeking it out. However it be, the fact is one worthy of interest when it is known that those parts of the surface of the cerebral hemispheres, which are in relation with the parietal region of the head, and more particularly the convolutions which border on Rolando's fissure (parietal and ascending convolutions), are designated by recent studies as representing the *motor zone*; or, in other terms, as the only region of the cerebral cortex whose irritation may determine, on the opposite side of the body, the production of the phenomena of partial epilepsy. You should not, however, expect always to meet an

¹ See, amongst others, the observations of Dr. Todd: 'Clinical Lecture on Paralysis,' &c., London, 1856. Lecture XVII, "On a Case of Syphilitic Disease of the Dura Mater," p. 301.

arrangement of convulsions and cephalalgia so exactly in conformity with the theory. You have, in fact, seen, in our first observation, the premonitory head-pain and the initial convulsions occupy the same side. I could also cite some other examples of the same kind.¹

But it is time to return to the particular case of M. K—. During a long period of four months, ill-directed hydropathic operations, insignificant doses of bromide of potassium had been the only agencies opposed to the progress of the disease. Thus, the position of affairs had been daily growing worse, and, towards the middle of October, it had become most disquieting. The attacks came on with renewed vigour, amnesia, hebetude, a genuine dethronement of the intellect supervened; and the diarrhœa, which had been for an instant exorcised, had reappeared. The patient's debility had reached its climax. Having been, for several weeks, confined to his chamber, he had now found it completely impossible to leave his bed.

Matters had reached this point, when Drs. Cornuel, Picard, and myself, met in consultation on M. K—'s case. It was agreed that as energetic action as the general state of the patient allowed should be adopted.²

He was put upon milk diet, and nitrate of silver was prescribed in the form of pills; at the same time mercurial frictions were to be employed, and iodide of potassium administered in doses of from 3 to 5 grammes in the twenty-four hours.

Thanks to the intelligent co-operation of devoted relatives, our prescriptions were followed to the letter. The results obtained were immediately of the most encouraging character. At the end of only eight days it had already become evident that the disease was not beyond the resources of medical art; only one new fit had taken place on the 30th October; the permanent contracture had disappeared as if by enchantment; and finally the patient's general condition had

¹ In several cases of partial epilepsy which I have observed, the premonitory head-pain of the attacks was localised in two spots simultaneously; one was situate in the parietal region on one side, the other in the temporal region of the opposite side. The parietal pain, in these cases, always occupied the side opposite to the convulsions.

² The good effects of mercurial preparations against the cachectic state, which depends on tertiary syphilis have been perfectly illustrated by Dr. Reade (of Belfast), in an interesting passage of his book, 'Syphilitic Affections of the Nervous System,' London, 1867, p. 18.

remarkably improved. Eight days afterwards, the patient was able to leave his bed, and take some steps about his room.

At the beginning of December, he had become able to leave his dwelling, and to take rather long carriage drives; at the end of this month, he had several times walked about, in the open air, for over an hour at a time.

Unfortunately, during the course of the first six months of the year 1875, the diarrhœa, which he had contracted in Cochin-China, showed itself anew at different intervals and, in consequence of this, the projected repetition of the *mixed interrupted treatment* could not be put into practice in a regular manner. Three or four times, during this period, there were relapses of the cerebral affection, marked by epileptiform attacks, but yet less intense and much more rare than the preceding seizures. But, at last, during a sojourn of several months at Amélie-les-Bains, the state of the intestines having become modified in the happiest manner, the treatment of the convulsive affection could be taken up in earnest, and continued for a sufficient space of time. At the end of this treatment, the nervous symptoms definitely disappeared.

M. K.— came to pay me a visit at the close of 1876; for fourteen months he had not experienced any further attacks; his health, in fact, was completely restored. He was about to leave for our American colonies, where he intended to resume at once his former official functions.

Undoubtedly, it would only be self-deception to expect always to meet with such fortunate results as those which were obtained in the three preceding observations, and I am not ignorant of the fact that it would be easy to quote a number of cases of cerebral syphilis, with partial epilepsy, where, in spite of the assistance given by an enlightened zeal, things turned out badly. I cannot help believing, however, that, in cases where the nature of the nervous symptoms is recognised in time, the plan of treatment proposed might be put into practice,—want of success will be the exception.¹

¹ Transient motor paralysis of a limb, supervening suddenly, without being preceded by contracture or tonic convulsions, and returning repeatedly after more or less lengthy intervals, ought to be placed, beside partial epilepsy, among the many various manifestations of cerebral syphilis.

In September 1872, I was consulted by M. A—, cavalry officer, for a cephalalgia which had been well-nigh permanent for about six weeks, and which had previously shown itself several times in the course of the year. In addition to the head-pain, there were well-marked dyspeptic disturbance,

The lesions of circumscribed *gummatous pachymeningitis*, with participation of the subjacent membranes, appear to be the most usual frequent vomitings, great prostration of strength, emaciation, and extreme anæmia. The seat of the cephalalgia is unfortunately not stated in the note which I have kept.

M. A—, had contracted a hard chancre fifteen years before, and from that until a recent date, he had not ceased to be subjected, from time to time, annually so to speak, to mercurial treatment, and chiefly to the exhibition of iodide of potassium, with the object of combating various symptoms which were always, rightly or wrongly, referred to the syphilis by the physicians consulted. Under the influence of, I know not what, preoccupations, I misunderstood, I must confess, during nearly a month, the true character of the cephalalgia, and the other phenomena which accompanied it. Hence the symptoms grew constantly worse.

One day I was informed that, for some time past, M. A— experienced from time to time, what they called *absences* (transient loss of consciousness). He would stop suddenly, with fixed look, in the middle of a conversation, grow pale, and at the close of one of those fits, which barely lasted a few seconds, he would remain for some time as if stupid. Nothing resembling aphasia was noticed, nor any trace of convulsions anywhere, at the beginning of the crisis. The patient himself had no knowledge of these *absences*, the existence of which, indeed, he was disposed to deny.

One evening towards seven o'clock, I was sent for in all haste. M. A— had been stricken two hours before, during an *absence*, the duration of which had not exceeded the usual time, with sudden paralysis affecting the left upper extremity. On coming to his senses, he found his limb quite inert, flaccid, hanging by his side. I ascertained that the paralysis was limited to the left upper extremity, which it occupied throughout, and it affected neither the face, nor the corresponding lower extremity. The persons present assured me that, at no time, had anything resembling convulsions occurred. Nor was there any disturbance of sensibility in the paralysed part; neither anæsthesia, nor analgesia, nor formication. The monoplegia progressively improved, during the evening, in a very rapid manner. On the morrow morning no trace of it remained.

The different circumstances just related struck me very vividly; the influence of syphilis seemed to me no longer susceptible of being misunderstood; I immediately prescribed the mixed treatment, according to the method which has been several times mentioned in the course of the present lecture.

A new attack of left brachial monoplegia, similar in all respects to the preceding one, which did not last longer than from four to five hours, took place three or four days after the beginning of the treatment: it was the last. The cephalalgia, the anæmia, the prostration of strength, all these also vanished with marvellous rapidity, in such a way as to demonstrate to the most incredulous that I had now struck home. The treatment was continued, with the interruptions ordered, for nearly three months.

Five or six months ago I received news of M. A—, and was happy to learn that, from the time I lost sight of him, no symptoms of the disorder had reappeared.

anatomical substratum of syphilitic partial epilepsy. They have been already described, with a certain exactness, in one observation relating to this affection, published by Todd, in 1857.¹ Two chromo-lithographic plates, annexed to the work of M. G. Echeverria,² which give a faithful representation of these lesions,—not often to be met with in post-mortem sections,—likewise concern a case of partial epilepsy. The same is true of a design by Lackerbauer, published by M. Lancereaux, in his ‘*Traité de la Syphilis*.’³ Unfortunately, the clinical observations which these figures are intended to illustrate leave much to be desired.

Besides partial epilepsy, very different clinical forms of cerebral syphilis may also depend on gummatous pachymeningitis. It is no longer doubtful to-day that there are often deep differences in the symptomatic expression of the same organic alteration, which especially depend on its mode of localisation on the surface of the hemispheres. According to a theory, founded on recent work, the gummatous patches, in partial epilepsy, ought to be situated on the surface of the frontal, or ascending parietal convolutions, or, at all events, in their immediate neighbourhood. The reality of this statement has not yet been regularly verified, so far as I am aware, up to the present; but it will, doubtless, not long remain so. In the meanwhile I may point out that, in the plate of Echeverria, just mentioned, it is easy to recognise that the gummatous lesions of the pia mater occupied the immediate neighbourhood of Rolando’s fissure, behind it, not far from the median fissure, that is to say, a region, in part, belonging to the domain of the cortical motor zone.

So long as the syphilitic partial epilepsy is not inveterate, so long as the attacks which constitute it, clinically, remain separated by intervals free from all permanent symptoms, the cerebral grey substance, in contact with the altered pia mater, has as yet suffered, as everything leads us to believe, only lesions of a kind which has sometimes been called dynamic—transient lesions at most, and not disorganising ones. In such cases there would, according to H. Jackson, be produced in the nerve matter, owing to an irritative process determined by vicinity, a sort of storing-up, an accumulation of energy which would be expended from time to time, under

¹ ‘*Medical Gazette*,’ January, 1851, and ‘*Clinical Lectures*,’ loc. cit.

² ‘*On Epilepsy*,’ New York, 1870, pl. iii, and 6.

³ Paris, 1866, pl. ii, fig. vi.

the influence of the most trivial and often imperceptible causes, in a sort of explosion of sudden, convulsive, and disorderly motor acts, bearing upon the side of the body opposite to the meningeal lesion. The discharge would always be followed by momentary exhaustion, which is clinically translated, by the temporary paralysis with flaccidity, which is, in truth, very frequently observed after attacks of partial epilepsy, in those very parts which have been the principal seat of the convulsions. If this be not, properly speaking, a regular theory, it is at least an ingenious manner of grouping the facts.

In the course of time, owing to the repetition of these acts, or else because of the progressive extension of the meningeal lesions to the nerve substance, the latter, in its turn, becomes gravely altered; then, at the same time when descending secondary degenerations are produced, permanent and indelible hemiplegia may supervene.¹

These anatomo-pathological and physiological considerations concur, as you see, to emphasise, once again, the importance of prompt and energetic decisions when dealing with partial epilepsy of syphilitic origin.²

¹ On the production of secondary degenerations consecutive on lesions of the cortical motor zone, see Charcot: 'Leçons sur les localisations dans les maladies du cerveau,' p. 160, Paris. 1876. M. Hanot, four or five years ago, presented to the Société Anatomique, an example noted in M. Charcot's wards, of descending degeneration, with permanent hemiplegia, consecutive on a gummatous lesion of the brain.

² Consult also, "A Case of Syphilitic Disease of the Brain," by J. Dreschfeld, 'Lancet,' 1877, vol. i, p. 268. This observation is peculiarly interesting from the point of view of lesion localisation.

APPENDIX.

I.

MULTIPLE PATHOLOGICAL LUXATIONS AND SPONTANEOUS FRACTURES IN A PATIENT SUFFERING FROM LOCOMOTOR ATAXIA. By J. M. CHARCOT.

(See Lecture IV, p. 47.)

THE case, of which I am about to state the details, presents a new example of those *trophic disorders* of the peripheral parts, produced in consequence of a lesion of the nerve-centre, to which I have called the attention of physiologists and physicians. The question here relates to multiple arthropathies and spontaneous fractures in the case of a woman attacked with progressive locomotor ataxia.

OBSERVATION.—*Progressive locomotor ataxia. Consecutive luxations and spontaneous fractures. Complete ilio-pubic luxation of the left coxo-femoral articulation. Shortening of left femur. Fracture of the anatomical neck of the left femur. Complete ilio-ischiatic luxation of the right coxo-femoral articulation. Complete sub-coracoid luxation of the left scapulo-humeral articulation. Consolidated fracture with deformed and oblique callus of both bones of the left fore-arm. Chronic arthritis of the right scapulo-humeral articulation. Consolidated fractures with voluminous callus, of both bones of the right fore-arm.*¹

The patient, A. Co—t, aged 57, domestic servant, was admitted to the Salpêtrière, as an invalid, February 8th, 1866. She entered the Infirmary of the Asylum, Salle St. Jacques, No. 23, Oct. 15, 1873.

This woman had nine children; seven of them died between the ages of five and fifteen months. Another succumbed at the age of thirty-four, after childbirth. There is nothing to note in the history of

¹ Edited from notes taken by M. Bourneville. See also, Forestier, 'Thèses de Paris,' 1874.

the patient, if not some violent megrims, accompanied by vomiting, usually coinciding with the menses. The megrims disappeared to a great extent when she was about thirty-five (1850)—at which period, the *lightning pains*, which marked the onset of the present disease, made their appearance. These pains occupied the lower limbs, first of all, especially the calves, and the instep. "I felt," she said, "like lightnings going through my legs." The pains were violent, more severe by night than by day, coming on in paroxysms, which lasted for about from twelve to fifteen hours. Towards the same period, a constant feeling of painful constriction at the base of the chest supervened. The painful crises which, in the early stage, showed themselves about every three weeks became afterwards more frequent and more violent. They appear to have reached their maximum of intensity and frequency towards the age of thirty-eight.

At the age of forty-two, after sensations of numbness in the right foot, the patient one day remarked that the *right thigh was considerably swollen*; the limb, here, it would appear had nearly doubled in size. This swelling was accompanied neither by redness nor by pain; it did not hinder C— from continuing, as before, and without marked hindrance, her work as a servant. The swelling and numbness remained for several months. These symptoms were improving, when, one morning (1858), on getting out of her bed, the patient remarked with astonishment, that she was lame, and that her right lower extremity was shorter than the left. During the night, in bed, and without pain, *luxation of the right hip* had taken place.

Walking, from this time, became difficult, but not impossible, far from it; for C—, being unable to continue to act as a servant, was still able, for nearly a year, to proceed daily on foot to a distant "Hôtel meublé," where she was employed to make the beds.

Towards the commencement of the year, 1859, there supervened in the left foot a numbness similar to that which had, previously, occupied the right. This numbness remained for several months when, one night, in consequence of a movement whilst in bed, a crack was heard in the *left hip, which became luxated*.

From this day, both the lower extremities being alike shortened, all active work became henceforth impossible. C— had herself taken to the Hôpital de la Charité, where she remained for four months. At this time, she could stand up, and even walk, by leaning against the walls as she went; she experienced, as in the

past, paroxysms of lightning pains in the lower limbs. These pains had not yet shown themselves in the upper extremities.

After leaving La Charité, C— was successively admitted into several hospitals; lastly, she was received, July, 1865, into the Hôtel Dieu, M. Vigla's Ward. At this period, the patient had the full use of her upper extremities, which were not affected by any pain; as to her lower extremities when the lightning pains continued to appear from time to time, she could, whilst in bed, move them about strongly, but these movements had become irregular, ill-coördinated, recalling those of the legs of a puppet. The several joints of these limbs had acquired an extreme laxity; thus C— could easily "embrace her foot," even put it behind her head, things which it had been impossible for her to do formerly. One day, whilst in bed, and wishing to show off her suppleness, she brought her left foot towards her mouth as if to embrace it, and in this movement the left *femur fractured*.

The lightning pains commenced to appear in the upper extremities about a year after her admission to the hospice of La Salpêtrière (end of 1866), and since then they have not ceased to supervene in crises. Sometimes they are felt in one spot, sometimes in another; they are never so violent as those which, from time to time, still invade the lower extremities. The movements of the upper limbs were not affected until lately. Thus, at the end of June, 1873, C— could still, without difficulty, lift her food to her mouth, do needlework, pick up from her bed the smallest objects, a needle, a bit of thread. However, she sometimes experienced a stiffness in her fingers, which stretched out stubbornly. This excepted, no trace of motor incoördination existed in the upper extremities at that date.

Towards the middle of July, 1873, C—, whilst she was changing her position in bed, *fractured both bones of the left forearm*. She could not tell exactly how this fracture came about, but it is certain that there was neither a fall, nor any violent effort. No apparatus was applied. Consolidation took place rapidly; the callus is voluminous and deformed. Since the time of the accident, the left hand presents a peculiar deformation which tends each day to grow worse. The thenar and hypothenar eminences are approximated each to each; the thumb stretched out rests on the index which is slightly flexed. The other fingers are likewise in demiflexion.

Three months after (September, 1873), at the time when C— was helping herself to sit up in bed, with her right hand, the *right forearm fractured*, in its turn, about midway. No pain was felt when the fracture happened. An apparatus was adjusted to the arm. Consolidation took place rather promptly without much difficulty. The right hand begins to exhibit a deformation analogous to that presented by the left hand. The movements of the different segments of the members are still easy and regular. C— can carry her food to her mouth with her right hand, pick up small objects, &c. Finally, October 11th, 1873, after some insignificant movement, a *luxation of the left shoulder* occurred. The shoulder had exhibited no preliminary swelling; and the patient had felt no pain in it.

Towards the same period, visual disorders were remarked, for the first time; now and again, objects appeared double; sparks sometimes passed before the eyes. It is noted that the right pupil is, permanently, more dilated than the left.

Present state (noted 26th November, 1873).—At my request, my colleague Dr. Meunier, Surgeon to La Salpêtrière, has been kind enough to study and describe with great care the lesions presented by the joints and bones in this case of C—. I reproduce, *in extenso*, the note which he has obligingly made in reference to this subject.

“Left lower extremity.—It is much shortened, and measures 62 centimètres from the anterior and superior iliac spinous process to the external malleolus. It is placed on its external side in abduction and rotation outwards. There is no noticeable peculiarity to be remarked as regards the foot, the leg, the knee, or even the lower part of the thigh. It is the upper part of the thigh and hip, and, to be exact, it is the femoral articulation which is injured. The trochanter major is depressed, and in such a position that it is carried towards the postero-external portion of the thigh. It is situate at a distance of about 12 centimètres from the anterior superior iliac spinous process, when the member is brought straight (see Plate VI).

“All the internal part of the thigh, from 8 centimètres above the internal condyle of the femur, presents a succession of transverse folds, more or less deep, to the number of about a dozen: some occupy the whole of this internal part, even going beyond it, at the back; others, nearer to the groin, pass across and beyond the an-

terior part of the thigh, extending even towards the external lateral part, but not reaching it.

“On the external part of the thigh are noticed some rolls of skin, in the longitudinal direction of the limb—rolls which are effaced on movement.

“The form of the thigh is that of a truncated cone. The entire thigh is shortened, and measures, from the anterior superior iliac spinous process to the internal condyle of the femur, a distance of 23 centimètres.

“The hip-joint possesses its six movements: flexion, extension, adduction, abduction, rotation, and circumduction. The motion of extension is limited. The movement of abduction is most extended; the leg and the thigh can be wholly placed on their external lateral part where they lie on the bed-surface. These are the movements performed by the patient herself. One can produce them as completely as described above. In assisted movements, especially when the limb is rotated outwards, well-marked cracking sounds are heard, doubtless owing to the rubbing of two rough surfaces.

“We infer from the above description that there is a *luxation of the hip*. The head of the femur being carried upwards and inwards, the variety of luxation is that designated by the name of *ilio-pubic luxation*; let us add that this luxation is *complete*, and due to a *pathological* cause.

“The femur, very much shortened, exhibits no alteration in its lower part, nor in its median part, up to and inclusive of the trochanter major. In all this part of the diaphysis of the bone, there is neither solution of continuity nor augmentation of size. It is otherwise higher up, where we note impotence of the limb, which cannot be raised completely from the bed-level, especially the heel. At the root of the limb, also, abnormal mobility exists, with crepitation—characters indicative of fracture of the anatomical neck of the femur: consequently, *intra-articular fracture*; such are the most marked rational and perceptible signs observed on examination.

“*Right lower limb*.—Its length is 74 centimètres, and, therefore, 12 centimètres more than that of the opposite side: this length is measured from the anterior superior iliac spinous process to the external malleolus. The limb is placed in rotation inwards, the knee and internal border of the foot touching the bed. Less numerous but more oblique folds or wrinkles than were seen on the other extremity are found on the internal part of the thigh from

the inner border of the knee to the groin. Six or seven rather marked folds may be counted, extending from the knee and from the internal part of the thigh to within a few centimètres of the anterior superior iliac spinous process. These wrinkles extend obliquely from below upwards, from within outwards, in an oblique and almost vertical direction. The trochanter major is brought up, and placed on a line which may be supposed to unite transversally the anterior superior iliac spinous process to the ischium.

“The several movements of the right coxo-femoral articulation may be performed by the patient herself. They may also be practised by the observer; but whilst the movements of adduction and flexion are exaggerated, on the other hand, the movements of abduction and rotation outward are limited and even markedly diminished. It is whilst producing these movements that the sensation of cracking is experienced in the coxo-femoral articulation. The femur, throughout its entire length, and at both extremities, exhibits no solution of continuity, and no augmentation of volume; the head of the femur can be easily felt through the skin, from the external part of the hip. It is carried directly backwards and upwards. Hence there is an *ilio-ischiatic luxation*.

“*Upper left limb.*—It presents lesions in the shoulder and forearm. From the acromion to the epitrochlea the arm measures 31 centimètres. It is consequently somewhat lengthened. The shoulder itself is manifestly flattened. The anterior wall of the axillary hollow exhibits several vertical wrinkles. The several movements of the scapulo-humeral articulation are spontaneously produced, with abnormal vivacity, in consequence of the ataxia which affects the patient. These movements may likewise be performed by the observer; the movement of elevation of the arm is the most limited of any; the movements of adduction are diminished, the patient not being able to completely bring the arm close to the body; the signs of the existing luxation are not very marked; however, we find, on pressing the axillary cavity with the fingers, that the head of the humerus is approximated to the internal part and depressed. From this array of signs we conclude that there exists a complete *subcoracoid luxation*. The crepitation is well marked in the movements. The remainder of the humerus is sound.

“The *left forearm* appears slightly shortened; it shows augmentation of size in its upper third. There, in fact, we find a

slightly deformed callus occupying both bones, beginning at the upper third of the ulna, nearly 6 centimètres from the olecranon, and proceeding down the forearm towards the radius. This callus describes a curve with convexity in front, and concavity behind. It extends to nearly 4 centimètres from the styloid apophysis of the radius. It occupies all the interosseous space towards the upper third of the forearm, especially behind. This voluminous callus, elongated from above downwards, from within outwards, indicates an old consolidated fracture. This spontaneous fracture affected both bones, the ulna at its upper third, and the radius in its middle portion; that is to say, that there was here an *oblique fracture of the forearm*. The callus, just described, greatly interferes with the movements of flexion and extension of the fingers. The fingers of the left hand are habitually stretched, but extension and flexion can be completely executed; still, in their usual condition, the fingers are placed in relatively different positions, the index being permanently stretched.

“*Right upper limb*.—Its length, measured from the acromion to the epitrochlea, is 29 centimètres; it is, consequently, shorter by 2 centimètres than that of the opposite side; there is no luxation of the shoulder. The movements of the scapulo-humeral articulation are all made in their entirety, only at times some cracks are heard on moving, indicating *incipient arthritis*.

“The forearm exhibits lesions analogous to, if not identical with, those described above for the left forearm. A voluminous callus exists, which we are about to describe. This callus indicates *a fracture involving both bones* near and below their middle part. The larger callus is that of the ulna; it is situate on the inner border of this bone. This callus is about 4 centimètres long, and descends to about the same length from the inferior portion of the bone. It is about 3 centimètres in thickness; much less in length is the callus of the external side, that is to say, that of the radius; its thickness may be regarded as perceptibly the same as that on its companion bone. The movements of the fingers, namely, those produced by the action of the flexor and extensor muscles of the digits, are much more easily made than in the opposite extremity. This greater facility of motion must be attributed to the conditions in which we find the forearm.

“In conclusion, there was *complete fracture of both bones, which is now consolidated and presents a voluminous callus*.”

I shall complete this statement by some details relating especially to different sensory and motor disorders, and to the general state of the patient.

Digestive apparatus.—The tongue, when protruded, is stirred by a slight trembling, chiefly marked at the tip on the right side. The appetite is good. Deglutition easy. No difficulty of defecation. The patient several times experienced lightning pains occupying the inferior part of the rectum and labia majora. These pains are, generally, less intense than those which are felt in the limbs.

Circulation and respiration.—Pulse small, regular, middling frequent, heart normal. Auscultation and percussion give negative results, with respect to lungs.

Urinary function normal.—The urine exhibits no alteration in its physical and chemical constitution.

During the course of late years C— has suffered considerable emaciation. She formerly measured 85 centimètres around the waist; to day, she measures no more than 64. This emaciation has made especial progress, since 1868.

The *ribs are solid* and do not give way at all to pressure, as usually occurs in osteomalacia. Neither the pelvis, nor the fingers, exhibit the deformations usually connected with this affection.

Movements, sensibility.—It is found that the movements of the lower extremities, limited though they be, are still rather energetic; but they are manifestly incoördinate; moreover, the patient has completely lost sense of the positions in which her limbs may be placed. Provoked as well as spontaneous movements are effected completely without pain.

On the limbs, the patient feels touch, tickling, pinching, pin-pricking. There is no perceptible difference in this respect between the two lower members. However, it appears manifest that sensibility is markedly blunted in the feet. Examination of sensibility to cold furnished the following results: If, after closing the patient's eyes, a pewter vessel be applied to the different segments of the lower limbs, sometimes, a burning sensation is perceived, sometimes the touch merely. Neither the cold nor the weight of the vessel is felt. But if during the experiment the patient be permitted to look, she succeeds, after making a kind of effort to get at the true sensation, in recognizing that she is at first deceived and that the object touching her is really cold.

The patient cannot at present make use of the left upper ex-

tremity, even to help in feeding herself. She has little strength in the hand on this side, and the motor incoördination is well-marked throughout the limb, whether the eyes be shut or open, when she is executing the movements. The motor incoördination has shown itself especially during the past month. The different modes of sensibility are preserved here. However, the patient does not distinctly perceive the difference between two bodies unequally cold. The movements of the right upper extremity are less gravely affected; incoördination is less marked; it is notably increased when the eyelids are closed. To-day she cannot raise a glass to her lips with this hand, except with great difficulty.

December, 1876.—The cracking sounds in the right shoulder are becoming more and more manifest; no pain nor swelling is observed at the joint.

December 15th.—C— has remarked, for some days, that she experiences crackings in the left *temporo-maxillary* articulation. It is observed that the articulation in question possesses exaggerated mobility, spontaneous or provoked movements do not cause any pain.¹

¹ This patient died in 1876, of rupture of an *aortic aneurism*. The spinal cord showed sclerosis of the posterior columns characteristic of the locomotor ataxia. The lesions on which we have here to insist are those of the *bones* and of the *joints*.

The two scapulæ which were fractured are shortened, because the inferior segment has slipped up on the posterior surface of the superior segment. They exhibit a callus, regular enough and complete on the right—irregular and incomplete on the left, inasmuch as the fracture which has the form of a right angle with apex internally, is only consolidated in its vertical portion—the two lips of the horizontal portion of the fracture are not united and are covered with osseous vegetations. The fractures are situated at the middle part of the sub-spinous fossa.

The *left clavicle* exhibits a consolidated fracture, situated at the junction of its external fourth with its internal three fourths.

The *right ulna* and *radius* present voluminous calluses consecutive on fractures which took place at the junction of the inferior third with the middle third. Both are shortened.

On the *left ulna* is found a very large callus at the junction of the upper fourth with the lower three fourths. From the external and posterior border of this callus starts an osseous jetty, which proceeds obliquely downwards, describing a curve, concave behind, and unites with the radius, a little below its upper third. The *radius* which was fractured, in its middle portion, presents a callus, five or six centimètres in length, voluminous, and which gives origin below to another osseous jetty, which proceeds to unite with the anterior surface of the ulna, in such a manner as that the superior jetty is situated behind the two

This observation, I think, does not require a long commentary; the lessons which it contains speak for themselves.

The peculiar circumstances in which, under the influence of quite insignificant traumatic causes, the several fractures were produced, alike in the thigh and in the two forearms, do not permit us to recognise in this case the intervention of any of the influences which, as a rule, preside over the development of the *fractures called spontaneous*. Thus, for instance, we had grounds for eliminating all action of hereditary predisposition, and again all influence of a diathetic element, such as syphilis, cancer, gout, rheumatism. I will add that the different parts of the skeleton, particularly the ribs and the pelvic bones, do not present any of the lesions which, clinically, may serve to mark the disease known as osteomalacia.

Lastly, and this point deserves particularly prominence, we cannot invoke the existence of a nutritive disorder of the osseous tissue resulting from a prolonged functional inaction of the limbs, itself consecutive on the spinal affection. All the details of the observation, on the contrary, establish clearly, so far as the upper bones, and the lower one on the contrary, anterior to them. On both sides, the bones of the fore-arm are shortened, the radius principally, and the left radius in particular (Plate IX).

The *coxo-femoral articulations* exhibit the usual lesions of the *arthropathies of ataxic patients*. Right and left, the border of the cotyloid cavities which is so marked in the normal state, is mostly effaced, it has even disappeared in the lower half, especially on the right. In fact, on this side, the cotyloid cavity becomes confounded with the external surface of the ischium. Above, the cotyloid cavity is not more than a centimètre in depth, and hardly a centimètre and a half on the left.

The lesions are still more marked as regards the *femurs*. On the right, the head, the neck, and a considerable portion of the trochanter major have disappeared. On the left, the head no longer exists, the neck persists but reduced to a rudimentary state, reduced in size by two thirds; the trochanter major is worn down, and what remains of the upper extremity of the femur terminates in an irregular callus, presenting in its inferior and interior part a sort of triangular jetty in the form of a lamina separated from the corresponding surface of the bone by an interval of three or four millimètres. In a word, besides the lesion due to the arthropathy, we have here a fracture. Nearly the whole of the upper fragment is destroyed by atrophy, by rubbing, and the remaining portion is united with the inferior fragment. From the lesions just described it also results that, whilst the right femur is 50 centimètres in length, the left is only 19 centimètres (Plate X).

It will be seen, by the preceding description, and these are very interesting lesions, of a kind altogether peculiar, that are not to be met with in the ordinary forms of dry arthritis.—B.

limbs are concerned, that the fractures occurred at a period when these limbs still possessed all their physiological movements, the spinal disease being here represented by shooting pains only; and, with respect to the left lower limb, it also still possessed, when the neck of the femur was broken, extensive and energetic movements, modified merely, for some time past, by motor incoördination.

After these successive eliminations, we are led to admit, if I am not mistaken, as an hypothesis which is at least a very probable one, that the fragility of the bones has here been a consequence, in some sort an immediate one, of the lesion of the nerve-centres. This hypothesis, being closely connected with that which I formerly proposed, in reference to the determination of the pathogenic mode in which the *arthropathies of ataxia* are produced, I believe I may hold myself dispensed from here re-entering into its discussion, and I will confine myself to referring the reader to the arguments which I have several times brought forward.¹

This vice of nutrition, subordinated to an influence of the nervous system which renders the bones brittle and which enables us to understand the occurrence of spontaneous fractures, is also, I think, one of the principal elements that concur in the production of those singular *arthropathies* of which our observation presents a most remarkable example. It is, in fact, known from the description I have given, that the very rapid and extreme wearing away of the articular extremities of the bones is the principal character which, from an anatomico-pathological point of view, distinguishes the *arthropathies of ataxia* from *common dry arthritis*.

It is not without interest to notice that the production of fractures, supervening under the influence of the most trivial causes, is far from being an absolutely rare fact in the history of progressive locomotor ataxia. I have, for my own part, already met with a certain number of examples of this kind, and quite recently Dr. Weir Mitchel² called attention to the fragility of the bones of the lower extremities in ataxic patients, and to the frequency, in these patients, of the fractures termed spontaneous. I will add that

¹ "Sur quelques arthropathies qui paraissent dépendre d'une lésion du cerveau ou de la moelle épinière," in 'Arch. de Phys.,' t. 1er, p. 161. See also, *idem*, t. ii, p. 121, and t. iii, p. 306; 'Leçons sur les Maladies du Système Nerveux,' t. ii, p. 54.

² "The Influence of Rest in Locomotor Ataxy." 'The American Journal of Medical Science,' July, 1873, 113, 116; and 'Centralblatt,' p. 720, 5 Oct., No. 45, 1873.

amongst the cases which have been collected in the different writings consecrated to the study of this kind of fractures, there is a certain number in which we may perceive—although they have not been noticed by the writers—tabetic symptoms, and particularly attacks of lightning pains. I will mention as examples, amongst others, the cases No. 32, and 33, of the work of Dr. E. Gurlt.¹

Extract from the 'Archives de Physiologie Normale et Pathologique,' 1874, p. 166.

¹ E. Gurlt, 'Handbuch der Lehre von den Knochenbrüchen,' 1er Theil, p. 147, 'Die Knochenbrüchigkeit.'

II.

ON THE TUMEFACTION OF THE MOTOR NERVE-CELLS AND OF THE AXIS-CYLINDERS OF THE NERVE-TUBES IN CERTAIN CASES OF MYELITIS. BY J. M. CHARCOT.

(See Lecture X, p. 144.)

In the case of subacute myelo-meningitis, which he has made the subject of a work full of important details, Dr. C. Frommann has noted with care the remarkable tumefaction which is here and there presented by the axis-cylinders of the nerve-tubes of the white substance, not only at the most gravely injured part of the cord, but also at a great distance from this focus, in spots which he believes to have been affected in a secondary manner.¹ I have recently had occasion to meet with this alteration of the axis-cylinders, in three cases of irritative lesions of the spinal cord; the observations which I have made in reference to this subject will allow me to confirm and complete, in some respects, the description given by Dr. Frommann. I may add that, in at least one of these cases, I remarked a tumefaction of the nerve-cells of the anterior cornua which, if I mistake not, has not yet been noticed in such cases; and which deserves to be brought into connexion with the same kind of alteration presented by the axis-cylinders.

OBS. 1.—During the siege of Paris, a Garde Mobile was wounded, early one morning, in a reconnoissance, and was brought a few hours afterwards to the ambulance of Arcueil, completely paralysed in his lower extremities. He succumbed the same night, about twenty-four hours after the accident. A ball had entered near the right shoulder, and came out on the opposite side, in the lumbar region. At the autopsy the cord was found completely

¹ 'Untersuchung über die normale and patholog. Anatomie des Rückenmarkes.' Jena, 1864, pp. 98-99, and 104-105. See also, in same work, figures 11 and 12 of plate iv.

divided at the upper part of the dorsal region; a shred of dura mater alone kept together the two separate ends of the spinal cord. A microscopical examination of two sections of the cord, in the fresh state, taken from the vicinity of the wound, to the extent of about two centimètres, gave the following results. There did not seem to exist any perceptible alteration of the nerve-elements, either in the white or grey substances; no granulo-cellular or non-cellular bodies; no isolated fatty granulations, on the contrary the myelocytes appear perceptibly more voluminous than in the normal state. Many of them are enveloped in a thin layer of protoplasm, sometimes globular, sometimes slightly elongated. Some of the rudimentary cells contain two nuclei. On the capillary vessels, the walls of which exhibit no trace of granular fatty infiltration, the nuclei are more voluminous, and many show traces of segmentation. A study of the sections hardened in chromic acid, and coloured by carmine, enables us to perceive alterations which had escaped the eye, in the fresh state. We find, on transverse sections, scattered over different spots of the lateral and posterior columns, a kind of rounded or oval islets, in the area of which all the axis cylinders have acquired relatively considerable diameter (fig. 32, *a*). Some measurements yield the following results: axis cylinder

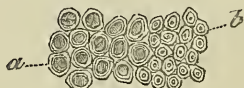

FIG. 32.—*Traumatic myelitis.* *a*, Axis-cylinders of abnormal volume, measuring $0\mu, 01-0\mu, 0099$. *b*, Normal axis-cylinders measuring $0\mu, 0033$.

remaining normal in the affected spots, $0\cdot 0033^{\text{mm}}$; hypertrophied axis cylinder, from $0\cdot 0099^{\text{mm}}$ to $0\cdot 01^{\text{mm}}$. The medullary sheath is not developed in proportion, and it forms around the hypertrophied cylinder a thin circular layer. Here and there, some nerve-tubes with voluminous axis-cylinders are met with, not assembled in fascicles like the preceding ones, but scattered and isolated in the midst of healthy nerve-tubes.

The reticulum of the neuroglia is nowhere thickened, but the stellate connective cells are manifestly more voluminous and more clearly defined than in the normal state; some of them enclose two large nuclei. The connective cells do not appear more voluminous

or more numerous in the places where the axis-cylinders have increased in size, than in the regions where the nerve-tubes have preserved all the characters of the normal state. Longitudinal sections enable us to note that the hypertrophied axis-cylinders have not an uniform diameter throughout their whole length; far from that, they present fusiform swellings at intervals, and it is only at these swollen places that they acquire the colossal dimensions already referred to. In the parts between, the diameter of the axis-cylinder go scarcely beyond the normal figure. The nerve-cells of the grey substance do not appear to show any perceptible alteration.

OBS. 2.—I owe the knowledge of the second case to M. Joffroy, who has enabled me to verify the anatomical details connected with it. It relates to a tall and robust man, aged 36. After some rather vague, premonitory signs, not exceeding the four-and-twenty hours, this man was taken, almost suddenly, without perceptible cause, with complete paraplegia, accompanied by loss of sensibility and retention of urine. Six days after the invasion, the urine, withdrawn by means of a catheter, contained blood. Seventh day, disappearance of reflex movements in the lower extremities; formation of bed sore on the left nates. Eighth day, respiratory disorder; fetid urine. Electric contractility is preserved in the lower limbs. Thirteenth day, chilling of extremities. Patient succumbed on the fifteenth day.

AUTOPSY.—On a level with the sixth and seventh dorsal vertebræ, the cord throughout its thickness, with the exception of a small extent of the posterior white columns, is softened, transformed into a complete mash, enclosing vessels gorged with blood. Above this chief focus the ramollissement ascends to the second and third dorsal vertebræ, gradually diminishing in extent, and limiting itself to the central regions of the cord. Below, it descends, limited likewise to these regions, to near the commencement of the lumbar enlargement. Neither this nor the brachial enlargement appears, to the naked eye, to have undergone any perceptible alteration.

Microscopic examination in fresh state.—In the softened spots are found granular corpuscles, with or without nuclei, and numerous free myelocytes. There are no leucocytes.

On the parietes of the vessels, which present also a slight degree of fatty infiltration, the nuclei are more numerous than in the normal state. In some preparations deeply pigmented nerve-cells

are found, which, however, do not exhibit any other modification of structure.

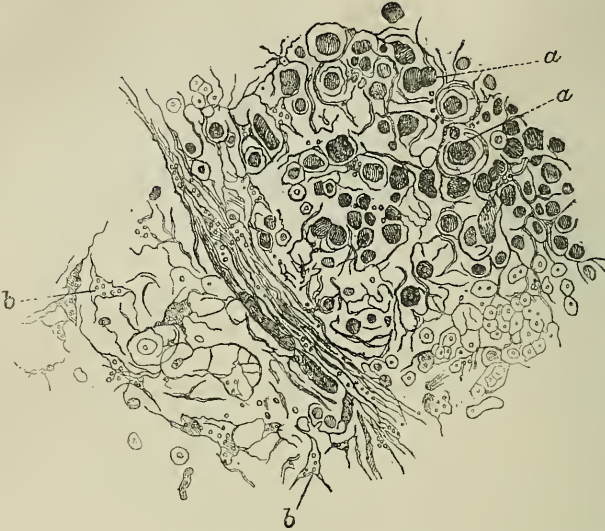


FIG. 33.—*a, a.* Largest axis-cylinders, measuring $0\mu,01$ — $0\mu,0099$.
b. Normal axis-cylinders measuring $0\mu,0033$.

Examination of sections hardened by chromic acid and coloured by carmine; transverse sections; dorsal region.—All the places which were found softened have disintegrated; but, elsewhere than in these parts are found scattered, here and there, a large number of small lacunæ or foci of disintegration, sometimes rounded, sometimes oval; these foci, chiefly occupy the lateral or posterior white columns; but a certain number of them is also met with in the grey substance, and particularly in the posterior cornua. In the vicinity of these foci, as around the parts disintegrated by ramollissement, the reticulum of the neuroglia is remarkably thickened, but without the adjunction of fibrillæ of cord-formation. The knots of the reticulum here present star-shaped spaces, enclosing three or four and sometimes five myelocytes. Many alveolæ are empty; others contain healthy nerve-tubes; most enclose axis-cylinders, generally deprived of medullary matter, the diameter of which largely exceeds the normal standard. The largest of these axis-cylinders measure $0,045^{\text{mm}}$; others $0,035^{\text{mm}}$; others, again, $0,025^{\text{mm}}$. only, the normal condition being represented by the figure $0,0025^{\text{mm}}$. Beyond the vicinity of the foci of disintegra-

tion, in the spots where the connective reticulum is not thickened, the large axis-cylinders are found sometimes isolated and scattered here and there, and sometimes united in rounded or oval groups. They are also seen either isolated or clustered in the cervical and lumbar regions of the spinal cord, where the foci of disintegration of the reticulum-hyperplasia are completely absent.

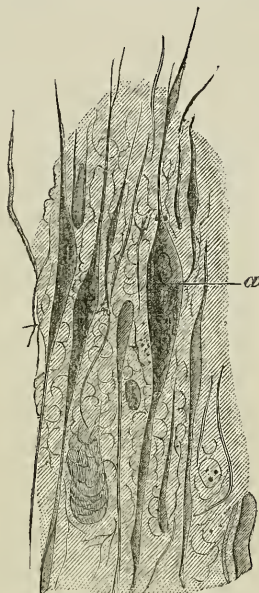


FIG. 34.—*α*. Largest axis-cylinders.

An examination of the longitudinal sections shows that the extraordinary dimensions, which have just been stated, correspond to the fusiform swellings of the axis-cylinders; in the intervals between, the cylinder recovers almost its normal diameter (fig. 34). We can follow the axis-cylinders with moniliform dilatations on successive sections representing a length of from half to one centimètre; above and below, they resume their normal character.

By means of comparative measurements, we appear to see that a considerable number of the motor nerve-cells, in different regions of the cord, have increased in volume. However this may be, this cell-swelling is much less marked and less easily determined than in the following case.

OBS. III.—This third case was noted at the Hôpital de la Pitié by M. Bourneville, who left to me the task of the histological examination of the spinal cord. With respect to the details of the clinical history and the macroscopic anatomy, I would refer the reader to the account published by M. Bourneville, in No. 40 of the 'Gazette Médicale' for 1871 (7th Oct., p. 451), as I desire to confine myself to some very summary remarks on these points. The subject of this observation is a woman, aged 58, who awoke one morning with a rather sharp pain in the nape of the neck, and a contraction of the right sterno-cleido-mastoid muscle. Five days later an incomplete motor paralysis, with diminished sensibility of the left upper extremity, showed itself. On the eighth day from the appearance of the first symptoms death supervened suddenly, in consequence of a fit of dyspnoea. In this woman's case the disease, it would appear, had shown itself without forewarnings. The patient, however, stated that she had, two years before, experienced symptoms very analogous to her recent symptoms, which, after a very short time, disappeared, leaving no trace.

AUTOPSY.—Transverse sections of the spinal cord, after only a few days' maceration in dilute chromic acid show, in the lateral half in the cervical region, an oval blood-clot focus, measuring 4 millimètres in its widest part (antero-posterior diameter), by 3 millimètres (transverse diameter), which extends, in height, from about the level of the first cervical pair to that of the seventh. This focus occupies the internal and posterior half of the left anterior cornu of grey substance. It is prolonged forward, in the substance of the antero-lateral column of the same side, following the direction of the intra-spinal course of the anterior roots.

The hæmorrhage is only partially of recent date. On certain points of the focus it evidently belongs to a distant epoch, for here and there are found pigment-granulations and rounded masses presenting the appearance of a cell, and enclosing clusters of blood-corpuscles. In addition we find, either in the focus itself, or in the substance of the parts which constitute its parietes: 1°, capillary vessels, presenting moniliform dilations at intervals, the walls of which, laden with very numerous nuclei, present here and there clusters of fatty granulations; 2°, axis-cylinders deprived of medullary matter, and much larger than in the normal state; 3°, numerous myelocytes, some free, others enveloped in a small mass of proto-

plasm; 4°, lastly, *débris* of connective reticulum, the meshes of which, apparently fibroid, are remarkably thickened.

After complete hardening of the cord an examination of transverse sections shows, besides, what follows: on points of the white substance, very distinct from the walls of the blood-clot focus—in the most posterior part of the posterior columns, for instance—are found irregular spots where the axis-cylinders, surrounded solely by a layer of medullary matter, have generally acquired enormous dimensions of from $0\cdot026^{\text{mm}}$. to $0\cdot018^{\text{mm}}$. in transverse diameter. In the intervals between these nerve-tubes with swollen axis-cylinders the meshes of the reticulum are sometimes thickened; generally, however, they are no thicker than in the normal state.

But what appears most striking in this examination are the truly *colossal* dimensions which, in the left anterior cornu of grey matter, in the vicinity of the clot-focus, are exhibited by the *multipolar nerve-cells*. Thus, whilst the largest cells of the right cornu measure, on an average, $0\cdot0495^{\text{mm}}$. in their greatest diameter, those of the right cornu may reach $0\cdot0825^{\text{mm}}$. The least voluminous of the latter are still $0\cdot056^{\text{mm}}$. in diameter. Besides, the tumefied cells are not only more voluminous than in the normal state; they are also manifestly deformed. They have lost their elongated shape, and become globular; they look as if excessively distended, and their parietes appear bossed. Nor do the cell prolongations now present their usual slenderness; they are thickened and tortuous. The substance which forms the body of the cells, thus altered, becomes strongly coloured with carmine; it is finely granular, slightly opaline, and, moreover, a little opaque, for the glance with difficulty penetrates to the pigmentary mass and to the nucleus. The latter, however, and the nucleus also, have always appeared to present the characters of the physiological condition. I was fortunate enough to make Dr. Lockhart Clarke, during his last visit to Paris, a witness to all the peculiarities which have just been described.

The longitudinal sections show the moniliform aspect of most of the swollen axis-cylinders, already mentioned in the first two observations. But one fact peculiar to the third case is that a certain number of these voluminous cylinders preserve their abnormal dimensions uniformly throughout a great length, without traces of dilatation or narrowing. A final point which deserves particular notice is this, that in this same case a first examination in the fresh state enabled us to recognise the tumefaction of the axis-cylinders;

so that this cannot possibly be an artificial product, an accidental result of the method of preparation.

I am inclined to believe that the tumefaction of the axis-cylinders described in these observations, and that of the nerve-cells likewise, ought not to be considered merely as curiosities of pathological anatomy. On the contrary, it appears very probable that these alterations will be met with again in a good number of cases of acute or subacute myelitis (where without any doubt they play an interesting part), when they shall have sufficiently attracted the attention of observers, and when, on the other hand, our means of anatomical research shall have been still further improved. As regards the swelling of the axis-cylinders, at the moment of concluding the present note, I find it mentioned, once again, in an observation which forms part of an interesting memoir that has just been published at Leipzig by Mr. W. Müller. This case, like the first one of those I have reported, relates to a traumatic lesion of the spinal cord. The brachial enlargement, especially, had been injured, and at the autopsy it was found softened; death supervened thirteen days after the accident. The swollen and varicose axis-cylinders were met with, not only in the vicinity of the focus of ramollissement, but also much beneath this focus in the lateral columns (*consecutive descending myelitis*), throughout nearly the whole length of the dorsal region.¹ It is known, from the histological researches of H. Frommann,² and from my own,³ that, in most forms of sclerosis, and particularly in disseminated sclerosis, at a certain period of the alteration, a very perceptible augmentation of diameter is observed in a certain number of axis-cylinders, besides the fibrillary metamorphosis of the neuroglia reticulum; indeed, the tumefaction, in the latter case, is uniformly spread over a great length of the cylinder, and not simply localised in certain spots, as occurs in acute myelitis. However this may be, the alteration in question appears to be, it is clear, common with some variations to primary, acute, subacute, and chronic forms of inflammation of the spinal cord.

What is the signification of this alteration? If I do not mis-

¹ 'Beitrage zur Patholog. Anatom. und Physiol. der menschlichen Rückenmarks.' Leipzig, 1871, pp. 11—13.

² 'Untersuchungen,' &c., 2 Theil, Jena, 1867.

³ 'Histologie de la Sclérose en plaques,' Paris, 1869, pp. 11—13.

take, it ought to be approximated to the swelling frequently presented by various anatomical elements, glandular epithelial cells, and cartilage capsules, for instance, under the influence of certain irritations. If it be thus, the reader may convince himself by referring to the observations contained in this note, that the tumefaction of axis-cylinders may, in certain cases, be the first anatomical expression of the inflammation of the spinal cord. It may, in fact, be found existing alone, independent of every appreciable concomitant alteration of the medullary cylinder, the neuroglia-reticulum, and the capillary vessels.

From this point of view, our first observation especially is most instructive. It also shows with what rapidity irritation may modify, in the cord, the structures of the nerve-elements, even in parts comparatively very distant from the primary seat of mischief. The latter fact, that is, the propagation of irritation to a distance is equally well illustrated in our second observation; as also in the cases of MM. Frommann and Müller, where, at a great distance from the principal focus, we see the axis-cylinders swollen, here and there, either along the course of the posterior columns, or in that of the lateral fascicles. Everything tends besides to show that the irritation of the nerve-tubes and, more explicitly, of their axis-cylinder is, in acute or subacute myelitis, sometimes the initial primordial fact (*parenchymatous myelitis*); sometimes, on the contrary, a deuteropathic phenomenon, consecutive on inflammation of the connective reticulum (*interstitial myelitis*). Hence, we have reason to apply to acute or subacute myelitis the fundamental distinction proposed by M. Vulpian,¹ in reference to spinal scleroses.

The morbid process, the most salient features of which have just been recalled may, if it be not hindered in its development, issue in the disintegration, and finally in the complete destruction of the axis-cylinder. It is not, in fact, rare to meet, in cases of some standing, with a certain number of swollen axis-cylinders, which, when examined in longitudinal sections of the cord, appear to be unequal, humped on the surface, and furrowed across with more or less deep slits. At the most advanced stage, owing to the augmentation of these slits, the swollen part of the cylinders may be divided into several irregularly globular and independent masses. This mode of alteration was very marked in our second and third observations; it has been perfectly described in the cases of MM.

¹ 'Archives de Physiologie,' t. ii, p. 289.

Frommann and W. Müller.¹ When matters are at this point, the axis-cylinders have been already long deprived of their medullary covering. It is scarcely doubtful that the swollen nerve-cells may, also, experience a consecutive atrophy, corresponding to this disintegration of the axis-cylinders. I shall confine myself, at present, to these remarks, which I hope soon to resume and develop in a general study on the pathologic histology of acute myelitis; but, I do not wish to conclude this note without pointing out that the tumefaction of the axis-cylinders does not exclusively pertain to the nerve-tubes of the spinal cord. I have myself observed it several times in parts of the brain affected with anæmia, but not yet softened, in consequence of the obliteration of an artery of the brain by thrombus.

Moniliform tumefaction of the axis-cylinders has besides, been long observed in the retina, by MM. Zenker,² Virchow,³ H. Müller,⁴ Schweigger,⁵ and Nagel,⁶ in the brain (yellow ramollissement of the cortical layer, and congenital interstitial encephalitis) by H. Virchow.⁷ Lastly, and more recently, Dr. H. Hadlich⁸ has noted the varicose swelling of the axis-prolongations (*Hauptaxencylinderforsatz*), of the great nerve cells of the cortical layer of the cerebellum in a patient affected with cerebellar hæmorrhage.

(Extract from the 'Archives de Physiologie Normale et Pathologique,' 1871—1872, p. 93.)

¹ 'Archives de Physiologie,' t. 11, p. 289.

² 'Archiv für Ophth.,' Bd. ii, S. 137.

³ 'Virchow's Archiv,' Bd. x, S. 175.

⁴ 'Archiv für Ophthal.,' Bd. iv, 2, S. 1.

⁵ Ibid., Bd. vi, 2, S. 294.

⁶ Ibid., Bd. vi, 1, S. 191.

⁷ 'Virchow's Archiv,' Bd. x, S. 178, and Bd. xlv, S. 475.

⁸ Ibid., Bd. vi, 4^o fig. S. 218, 1869.

III.

NOTE ON A CASE OF SPINAL PROTOPATHIC PROGRESSIVE MUSCULAR ATROPHY (DUCHENNE-ARAN TYPE). By J. M. CHARCOT.

(See Lecture XI, p. 163).

THE principal clinical characters which allow us to diagnose, protopathic muscular atrophy, during life, will be found assembled in the following observation, which is a remarkable example of this form of chronic amyotrophy. Here, in fact, the diagnosis, which anatomical examination afterwards confirmed, was made during the patient's lifetime :

Laure W— was admitted to the Salpêtrière, March 19th. She was affected with progressive muscular atrophy, the first symptoms of which she had experienced in 1862, at the age of about thirty-seven.

The patient's history gave only negative results on inquiry ; none of the members of her family had been affected with muscular atrophy, nor had she herself ever had any disease, save the eruptive fevers of childhood ; finally, she had been a sempstress all her life, and has never experienced privations, nor inhabited an unhealthy dwelling.

A certain progressive weakness, not accompanied by any sensory disturbance, marked the invasion of the symptoms in the upper extremities. Soon after atrophy attacked the muscles of the left hand ; then, six months later, the right was attacked, in its turn. Dating from this period, the disease pursued its career in a regular and slow manner, occupying one after another, from below upward, the several segments of the upper extremities, but proceeding much more rapidly in the right than in the left side. It should, however, be remarked that, for about eight years, the lower extremities had been the seat of singular phenomena. Real paroxysms of pain used to occur, accompanied by violent muscular jerks. These fits come on, by preference, whilst the patient was in bed ; but they might also take place whilst she was walking, and they were violent enough to compel her to perform odd movements (curtseys,

bows, &c.).¹ They were calmed by the application of cold water to the lower extremities.

Present state, May, 1869, seven years after the invasion of the disease.—The atrophy has invaded both hands, both arms, both shoulders, especially the right, as likewise the muscles of the supra- and sub-spinous fossæ. No fibrillary movements are noticed either in the forearms, nor in the arms, but they have a very distinct existence in the right shoulder, where they are determined by the slightest shock; they are likewise observed in almost the whole of the upper part of the back. The lower limbs are perfectly free; the patient walks about the whole day long. Nothing noticeable in face, tongue or larynx. From time to time slight fits of dyspnoea, but not of an urgently threatening character. About a year ago, the patient experienced pains in the neck, on the side of the vertebral column, in the lateral muscle-masses. To-day, these pains have disappeared, but similar ones have come on in the left side of the neck. In addition, for some time past, the patient experienced formications and numbness in both arms.

1872.—The patient was, for six months, put under treatment by continued (descending) currents, but if there were any improvement, it did not last. The atrophy whilst making progress in the upper extremities and in the trunk, had not perceptibly invaded the lower limbs, the functions of which were freely carried on. Still, the patient always complained of the existence of pains, coming on by fits and starts, in the neck, the back, and the lower extremities; and it was directly determined that pressure on the spinous apophyses was painful all along the vertebral column.

From 1872 to 1875 the state of the patient remained much the same. She was several times shown to those who assisted at the lectures given in the Salpêtrière, as an example of protopathic spinal muscular atrophy. This diagnosis was based upon the following chief characters: in spite of the considerable reduction in volume which the muscular mass of the upper extremities had undergone, these were not in reality affected by true paralysis; certain partial movements were possible, particularly the movement of elevation by the shoulder-muscles. Thanks to these movements, the patient could yet to some extent make use of her hands. By means of some manœuvring she could still manage to turn the handle of a lock, open a drawer, lift a chair, or at least drag it where she pleased.

¹ In conjunction with M. Gombault.

Generally speaking, her upper extremities were flaccid, usually hanging down by her sides, free from articular stiffness. The fingers, however, were flexed on the palm of the hand, without it being actually possible to extend them.

The lower extremities were quite free; their muscular masses were voluminous; the patient walked easily, and even went rather long distances outside the hospital, without great fatigue.

1875.—The atrophy of the muscles is extremely marked in the upper parts of the body. It bears, almost equally, on both upper extremities. The deltoids, the pectoral muscles, are almost completely destroyed; the intercostal spaces are deeply hollowed out; the same thing is seen in the supra- and sub-spinous regions; throughout all the upper portion of the body the skeleton shows itself, and seems merely covered by the skin. The head, no longer upheld by the muscles of the neck, falls forward, and remains habitually flexed upon the chest. From this attitude a certain difficulty of deglutition results, which is probably altogether mechanical; the patient can only swallow with great trouble whilst sitting, and consequently she has to eat standing. The dorso-lumbar column is greatly curved in, and the arms, which are always flaccid, hang usually behind the chest.

Still the lower extremities are voluminous, and walking is always easy. The difficulty of breathing has become very great; the utterance is broken, panting, and the voice somewhat husky (*voilée*); however, the articulation of sounds is perfectly distinct; the tongue has preserved its original volume and the freedom of all its movements. The vocal troubles should, therefore, be attributed to the difficulty of breathing, which is remarkably increased by efforts and by walking, the patient cannot go up a flight of stairs without getting palpitations at once. Her pulse was not counted in 1875; in 1873, it was calm and regular. The cutaneous *sensibility* is normal, pressure on the muscular masses does not cause pain, the *intellect* is perfectly preserved.

During the last two months, the general debility makes rapid progress; the appetite is completely lost, vomitings supervene, copious leucorrhœa, and, lastly, œdema of the feet and hands. At the same time, the respiration grows more and more embarrassed. However, in spite of this state of extreme weakness, the patient continues to walk a little, and on the day before her death she was still able to go to the consulting-room of the infirmary.

On the 18th of May, it was impossible for her to quit her dormitory to go to the chapel, as she was accustomed. During the night, she was seen to leave her bed in order to go and sit in her arm-chair; as she remained there for a considerable time without stirring, her neighbours called her; they came to her, found her motionless, extremely pale, having nearly lost consciousness altogether. She was put back in her bed, where she soon died.

AUTOPSY, May 19. *Nervous system.*—The brain and cerebellum are not the seat of any lesion; neither are the protuberantia or bulbous affected. The bulbar nerve-roots are normal in size, and have their usual white colour.

Spinal cord.—The anterior roots are reddish, transparent, manifestly wasted. Their colour contrasts with the fair white hue of the posterior roots, which appear healthy. This state of the anterior roots is only met with in the cervical and dorsal regions. It ceases almost entirely at the first lumbar pair. The cord itself does not exhibit any grey coloration on its surface, its tissue is neither softened nor indurated, there is no manifest thickening of the meninges. On a transverse section, taken in the cervical region, we remark the gelatinous aspect of the anterior cornua, and the total absence of all grey tint on a level with the lateral columns.

Muscles.—In a general manner, the affected muscles are discoloured; they have assumed the yellow dead-leaf tint, and have undergone a more or less considerable reduction in size; nowhere do we observe remarkable adipose substitution. They are not, however, all affected to the same extent, and some may even be met with which, like the trapezius, are only partially atrophied.

Upper right limb.—The deltoid is yellow, and considerably thinned. In the arm, the triceps alone has retained a size and colour which approach to the normal state; all the other muscles of this region are more or less wasted and discoloured. They are, however, less thoroughly affected than the muscles of the forearm, which, for the most part, are reduced to thin membranes; the flexor carpi ulnaris and the palmaris longus have almost completely disappeared; the flexor carpi radialis and the pronator radii teres are a little less wasted. In the posterior region, all the muscles are deeply affected, with the exception of the extensor pollicis longus, which is still red and rather larger. In the hand, the

lumbricales have alone preserved their red hue, and a certain degree of prominence.

Lower right limb.—Here all the muscles retain a still considerable volume and their normal colour; none of them is manifestly wasted. The *sacro-lumbar* mass is perfectly preserved; at the nape of the neck, on the contrary, most of the muscles are wasted and discoloured. The *latissimus dorsi* and the whole of the posterior part of the trapezius have undergone extreme atrophy. The clavicular fascicle of the latter muscle is, on the contrary, red and voluminous. The muscles of the supra- and sub-spinous fossæ are wasted. The *pectoral* and *intercostal* muscles, and the muscles of the anterior part of the abdomen have undergone extreme atrophy. The intercostal space is absolutely translucent. The *diaphragm* has thinned greatly; on raising the peritoneum, we can see numerous yellow streaks, corresponding to bundles of diseased fibres, alternating with less numerous red fibres. The sterno-mastoid muscles appear almost healthy, as well as the supra- and sub-hyoid muscles. The muscles of the pharynx are of a fine red, and remarkable for their thickness; those of the larynx appear equally normal. The *tongue* has its normal volume, its different muscular layers are red, there is no trace of fatty substitution. The different viscera appeared healthy.

Histological examination. Cervical region.—The dissection of small fragments of substance, taken on a level with the anterior cornua allows us to perceive the existence of alterations which bear alike on the vascular parietes, on the interstitial elements, and on the nerve-cells.

State of the vessels.—Generally speaking, the condition here was that of a chronic irritative process, determining the formation of new elements, and issuing in a sometimes considerable thickening of the vascular parietes. The different phases of this hyperplastic process may be followed easily enough on the walls of the capillaries.

At an early stage, at intervals over the external surface of these walls large nuclei are met with, taking a deep tint with carmine, and surrounded by a rather abundant granular protoplasm. These elements make a noticeable prominence on the surface of the vessel, and are readily distinguished from the nuclei of the epithelium, which are paler, and, in certain positions, prominent, on the contrary, towards the concave side. Further on, proliferation is produced, then we find sometimes three or four nuclei united together

by a common mass of protoplasm; sometimes clusters of young cells more completely developed (Pl. VII, fig. 6, *a*, *b*).

It is probable that these elements are susceptible of undergoing, afterwards, modifications which bring them to a more complete organisation; for in some spots, we find true fusiform bodies, furnished with very long prolongations and forming a sort of incomplete adventitious coat to the capillary. The proper wall of most of these capillaries has undergone a very noticeable thickening. As to the endothelium, it does not appear to be manifestly modified. In spite of an attentive examination it has been impossible for us to distinctly ascertain the fact of the neoformation of capillaries.

In vessels provided with several coats, the phenomena which we have just described are also produced. Here, again, it is the external parts of the wall which were the almost exclusive seat of the morbid process; the lymphatic sheath is thickened, its cavity no longer exists, it adheres closely to the surface of the vessel. However, the aspect exhibited by these parts varies, very probably, with the age of the lesion; sometimes they are charged with abundant cellular elements, sometimes, on the contrary, it is the fibrous element which predominates. Lastly, we should notice, in these same spots, the habitual presence of leucocytes, occasionally so numerous as to almost completely mask all other histological details (Pl. VII, fig. 7). Here again the internal membrane and the endothelium in particular; appear to be respected. As to the middle coat, it is evidently altered in certain points. Its muscular fibres become granular, and a number of them have disappeared.

The alteration of the *neuroglia* is betrayed by the presence of some granular bodies, by a very considerable number of cellular elements, some of which present the characters of multiplication by scission (hour-glass nucleus), and finally by the unusual abundance of fibrillary tissue.

As to the *nerve-cells*, they have largely disappeared. We may go over entire preparations without finding a single cell of any considerable size. A strong magnifying power must be employed, in order to distinguish a number of them. The smallest that can still be discerned are constituted by a voluminous nucleus, readily coloured by carmine, provided with a large nucleolus and surrounded by a small rounded or oval zone of yellow pigment (Pl.

VII, fig. 4, *a, a*). Some others, less reduced in size, have preserved vestiges of their prolongations in the form of angles; their nucleus is nearly normal, like that of those already mentioned, and their protoplasm is quite infiltrated with pigmentary granulations (Pl. VII, fig. 4, *b*). In a word, atrophy of the protoplasm, loss of the prolongations, comparative increase of the yellow pigment, long persistence of the normal characters of the nucleus and nucleolus,—such are the characters of the process, which here presides over the destruction of the nerve-cells.

In the lumbar region the substance of the anterior cornua is comparatively healthy; the nerve-cells are abundant, most of them appear healthy, and merely a little more pigmented than usual. However, some of them, but, indeed, only a few, are found to be as completely wasted as those of the cervical region. The walls of the vessels are not absolutely healthy, in the large vessels especially they are manifestly thickened.

Portions of the white substance, taken from the centre of the lateral columns, in the cervical and lumbar regions, contained in the fresh state no granular body. Some fragments of the nucleus of the hypoglossus, examined by the method of dissociation, exhibited the perfect integrity of all the elements which composed it.

Examination of sections after hardening in chromic acid.—The grey substance of the anterior cornua is gravely altered in the cervical and dorsal regions. The maximum of the alterations occupies the lower part of the cervical enlargement. Above and below this spot they diminish as they go. At this level, we note the almost complete disappearance of nerve-cells, and of most of the medullated tubes, which, in the normal state, traverse the area of the anterior cornu, in every direction. It results from this, that the grey substance takes with carmine a much deeper tint than in the normal state. In spite of the disappearance of the nerve elements, the dimensions of the anterior cornua have not noticeably diminished. This must be largely attributed to the truly enormous development taken by the capillary system of the region.

In the upper parts of the cervical region, the vascularisation diminishes, medullated tubes appear anew, here and there some recognisable nerve-cells are remarked; some of them, two or three at most, in each preparation, are even almost normal in their

dimensions. In the dorsal region, the lesion becomes equally lessened as it approaches the lumbar region.

On a level with the lumbar enlargement, the grey substance has almost completely resumed the characters of the normal state. The nerve-cells are numerous, provided with prolongations, collected in distinct clusters, nearly all contain a considerable mass of pigment.

At long intervals an atrophied cell is met with. The large vessels have their walls thickened, but much less than in the cervical region. This state of the vessels is again met with throughout the whole extent of the posterior cornua which are more vascularised than is usual.

Throughout the entire cord, the lateral columns properly so-called, Türk's columns, and the posterior fascicles are untouched. But the great vascular tracts which traverse them are a little larger than usual, and the vessels which they contain have their walls thickened.

As to the anterior radicular zone, it is attacked with sclerosis in the cervical and dorsal regions. The extent of this sclerosis is manifestly in relation with the intensity of the lesion which occupies the anterior cornu, it augments, diminishes, ends simultaneously with it. It is also largely dependent on the lesion of the anterior roots in their intra-spinal course. Thus, in the inferior part of the cervical enlargement, it forms around the anterior cornu an almost complete belt, which sends towards the circumference broad processes, while in the dorsal region it is limited to the cornu of the radicular fascicles and cortical zone.

In addition, at the point of emergence of the anterior roots, the pia mater is thickened and manifestly inflamed. This inflammatory state of the pia mater is met with again, though less marked, on every point of the periphery of the cord. It has reacted upon the immediately subjacent layer, and the result is a thin zone of cortical sclerosis, the maximum thickness of which is at the level of the anterior radicular fascicles, diminishing over the lateral columns, to disappear altogether on a level with the posterior columns. In the lumbar region, these various lesions disappear, the cortical layer and the anterior radicular zone are in a state of perfect health.

Bulbus rachidicus, section taken from the middle of the olivary bodies.—The anterior pyramids are healthy. The hypoglossus nucleus is filled with numerous cells, somewhat strongly pigmented, but

normal in size. The *pneumogastric nucleus* is rather strongly vascular.

Spinal roots.—The *anterior roots* of the cervical region are nearly completely destroyed. It is with difficulty that we find, at long intervals, a tube filled with medulla. Elsewhere, we only find empty sheaths, provided at very regular intervals with large granular and ovoid nuclei, and pressed against each other by the thickened endoneura. This state is exactly the same as that of the anterior roots of the dorsal region. In the lumbar region, we scarcely find any atrophied tubes. The *posterior roots* are normal, as are those of the hypoglossus.

Peripheral nerves.—The *phrenic nerve* of the left side and two intercostal nerves have only been examined. These three nerves have undergone analogous alterations. The phrenic nerve, the lesions of which we are about to describe, received a more special examination. One portion of this nerve, taken from about the middle part of the pericardium, was placed in osmic acid, then one part was examined by dissociation; another was hardened by alcoholic gum, which allowed sections to be made. Generally speaking, we find here the same alterations as in the anterior roots; it has merely arrived at a less complete degree of development.

The longitudinal sections already enable us to detect the disappearance of a large number of tubes, and show broad connective bands, strewn with numerous nuclei, separating those which survive (Pl. VII, fig. 5). On the transversal sections, these connective bands appear under the form of round discs, or little polygons, very like what is seen on a section of bundles of fasciculated connective tissue. Carmine tints them a rose colour, and in one point of their surface a black spot is seen from time to time, which is the section of a medullated tube. It seems, however, that the atrophy does not invade the nerve in an absolutely irregular manner, that it proceeds with a certain degree of order and destroys it, so to speak, by fascicle. In fact, the tubes preserved are grouped beside each other and form islets, which contrast, by their colour, with the other points of the preparation where the destruction took place (Pl. VII, fig. 1, *a*).

These cross sections furnish other information yet: they allow us, when compared with similar sections of a healthy nerve, to form a good idea of the number of tubes which have disappeared (more than two thirds are certainly absent), at the same time, we see the consi-

derable diminution in its diameters which the nerve has undergone—a diminution of about a third. The preparations by dissociation, also, enable us to form an idea of the process which has, apparently, presided over the atrophy of the nerve. We, in fact, meet with some, but very rare, tubes analogous to that of which we have given a sketch (Pl. VII, fig. 3).

These tubes have preserved their normal size, but the axis-cylinder has disappeared, or, at least, is no longer visible, the medulla is fragmented, and in the intervals between the lumps formed by it, we note the existence of nuclei, either isolated or collected together to the number of two or three, evidently contained in Schwann's sheath—the signification of which from the view-point of parenchymatous neuritis could not, we believe, be an instant dubious.

Muscles.—A certain number of muscles have been examined by means of the different methods at present in use. In all, the predominant lesion is a simple atrophy of the primary fascicles, with a purely relative augmentation of the interstitial connective tissue, and the absence of all exaggerated production of adipose tissue.

The unsound fibre usually preserves to the last, its cross striæ, and generally no pigmentation takes place in the muscular nuclei, properly so called.

However, some exceptions to this general rule are met with. Thus, in the diaphragm, and in the spinalis dorsi, certain fibres are filled with granular contents, and in others the muscular substance is interrupted at intervals by clusters of nuclei to the number of five, ten, and sometimes more. Still there are exceptional cases. An examination of longitudinal sections taken at different heights, from these muscles, enable us to form a more precise idea of the extent of these lesions.

The latissimus dorsi, for instance, is almost entirely converted into a thin lamina of connective tissue. It is with difficulty that a muscular fibre is found at wide intervals, and, singular to say, this single fibre left there as if to attest the existence of the muscle, is occasionally voluminous. The *trapezius*, in its lower portion, and the *rectus abdominis* are almost as profoundly smitten also. As to the diaphragm, which has most especially attracted our attention, on account of the lesion of the nerve which animates it, the alteration is very far from being equally advanced. The muscular fibres are still numerous here; they have preserved their striæ, and at first sight, it seems difficult to admit that this muscle can be the seat of

grave alteration. But when we compare with sections taken from it other sections taken from a healthy muscle and prepared in a like manner, the difference becomes striking by the fact of this simple comparison (Pl. VIII, figs. 4 and 5).

In one, the fibres are large, from 45μ to 90μ in size, all nearly equal, and barely separated from each other by a little connective tissue. They are exactly parallel. In the other, they are, generally speaking, extremely reduced in size, of from 5μ to 35μ , of very unequal dimensions, and separated from each other by comparatively large connective spaces. The latter circumstance explains the wavy form which they have assumed, owing to the fact that they could not follow the connective fibres which retreated under the influence of reagents.

The above case reproduces exactly enough, as will be seen, the principal clinical characters which we have assigned to protopathic spinal muscular atrophy: long duration, slow evolution; absence of all spasmodic phenomena, attested by the general flaccidity of the upper extremities, the mobility of the large joints, the patient's ability long to perform partial voluntary movements enabling her to secure a certain object. The fingers alone were flexed and their articulations rigid; but this rigidity only supervened in the course of time and owing to prolonged immobility. We would say as much of the attitude of the head, which was only produced slowly, in proportion as the muscles of the nape of the neck became incapable of upholding its weight. The integrity of the lower limbs is a not less remarkable fact, since the patient still walked easily enough even the day before her death.

However, some unwonted phenomena were exhibited; there were pains in certain parts of the body, then jerks which occurred in the lower limbs. The latter symptom has evidently but little importance, for it took place long before the invasion of the affection; moreover, it only happened at long intervals, so rarely that no physician ever had the opportunity of observing it. It has, however, been noted that the lesion was not exactly limited to the substance of the anterior cornua; it had, on passing through the radicular fascicles produced a certain degree of meningitis and a slight cortical sclerosis. Hence, it is natural enough that these incidents, in the anatomical order, should be translated during life by some exceptional symptoms which cannot modify in any essential particular the general aspect of the clinical picture.

It is now our duty to show that a study of the lesions leads to similar conclusions. We will admit, at once, without staying to reproduce the arguments in favour of this opinion—arguments which have already been several times stated in the ‘*Archives de Physiologie*’—that the lesions observed in the muscles, the nerves, and the roots, are only produced consecutively to the spinal alteration. As to the sclerosis of the anterior radicular zones, the examination of a certain number of sections of the spinal cord suffices to show that this is an accessory lesion, varying in extent from one section to the next, and largely dependent on the irritation propagated by the anterior radicular filaments during their intraspinal course. It is most marked in the points where they are most numerous; lastly, it takes the form of sclerous bands, extended from the anterior cornu to the periphery of the cord, thus very exactly recalling the direction of the nerves which are being destroyed.

The points where it takes a more considerable extension, where it forms around the anterior cornu a zone of some width, are precisely those where the anterior grey myelitis attains its maximum of intensity; all the elements of the region are altered, at this level, and we may admit, either that the irritation of the neuroglia, which is manifest in these points, has propagated itself gradually to a certain distance from the principal focus; or else, as is more probable, that this irritative process has been transmitted to the radicular zone by means of the nerve-fibres which it receives from the anterior cornu.

Finally, and this last reason is a most important one, we again find nerve-cells in process of destruction, in the lumbar region, when the anterior radicular zones are found perfectly normal in that region.

As to the slight degree of meningitis which is observed, it is very natural to admit that it is produced under the influence of the lesion of the radicular filaments on their passage through the pia mater; and that the latter, once inflamed, has become the cause of the cortical sclerosis. If now we consider that, in certain points—in the upper part of the cervical region, for instance, as well as in the dorsal region,—the nerve-cells are again greatly altered, even when the interstitial tissue only exhibits minute lesions, we shall be led to the belief that, in all probability, the ganglionic element was, in this case, the primary seat of the disease.

This lesion of the nerve-element should be of an irritative nature, at least if we are to judge by the character of the alterations which it provokes when, later on, through its influence the interstitial tissue is invaded in its turn. Thickening of the walls of the large vessels, multiplication of the nuclei of the capillaries, proliferation of the cells of the neuroglia, sclerosis of the white columns in the spots where they are invaded—all these phenomena very evidently depend upon a chronic irritative process.

For all these reasons, therefore, it is quite legitimate to class the cases which occupy us in the category of primary anterior chronic myelites, and more particularly of chronic parenchymatous tephromyelitis.

As to the exaggerated pigmentation of the nerve-cells, although that may not be a necessary fact, since it has sometimes been absent, it is none the less one of the most habitual expressions of the organic deterioration of these elements, and on that account deserves special mention.

It has been seen that, with respect to the peripheral nerves, those which were examined showed considerable atrophy. The phenomena which preside over this atrophy appear, in this case, to be identical with those which are produced in the peripheral extremity of a divided nerve, but with this difference, that here, in the case of amyotrophy, the nerve is only invaded slowly and, as it were, fibre by fibre (Pl. VIII, fig. 1 and fig. 3).

In concluding, it is right to remark the radical alterations undergone by most of the muscles of respiration, particularly the intercostals and the diaphragm; for it is to the alteration of these muscles that we should attribute the fatal termination. In fact, there was no apparent lesion of the lungs, nor of the heart, and the medulla oblongata can scarcely be arraigned here. Hence it is natural to admit, in order to explain the habitual dyspnoea, as likewise the symptoms which brought the life of the patient to a rapid close, the existence of progressive paralysis of the respiratory muscles. The number of fibres, which retained their functions, diminishing day by day, motor impotence would have developed in a parallel manner, till the day came when the lesion had grown general enough no longer to allow of the regular play of the thoracic cage.

Still, to explain so complete a paralysis in muscles provided with yet numerous fibres, which though considerably reduced in size had

nearly all retained their cross striæ (Pl. VIII, fig. 5), it may perhaps be right to recognise the intervention of the well-marked nerve-lesion, particularly so far as the phrenic nerve is concerned, which for the most part left them in the condition of muscles paralysed by the subtraction of nerve action.

Extract from the 'Archives de Physiologie normale et pathologique,' 1875, p. 741.

IV.

TWO CASES OF LATERAL SYMMETRICAL AMYOTROPHIC SCLEROSIS.

(See Lecture, XII, p. 180.)

WE reproduce here two cases which completely confirm the descriptions traced by M. Charcot in his lectures on *deuteropathic amyotrophy*. They were published by M. Charcot, M. Joffroy¹ assisting in the preparation of the first, and M. Gombault in that of the second.²

CASE I.

Progressive muscular atrophy, especially marked in the upper extremities. Atrophy of the muscles of the tongue and orbicularis oris. Paralysis with rigidity of the lower extremities. Atrophy or disappearance of the nerve-cells of the anterior cornua in the cervical and dorsal regions. In the bulb, atrophy and destruction of the nerve-cells of the hypoglossus nucleus, atrophy of the anterior spinal roots, of the roots of the hypoglossus and of the facial nerve. Symmetrical ribbon sclerosis of the lateral columns.

Catherine Aubel was admitted to the Salpêtrière (M. Charcot's wards), in the month of June, 1865; she then presented, in a marked degree, the symptoms of progressive muscular atrophy, the beginning of which dated back for about nine months at that time.

Her relations, brothers and sisters, five in number, had had no disease worthy of notice, and all enjoyed good health. Of a lymphatic temperament, she had glandular enlargements in her childhood; some glands even suppurated, and her neck is marked by numerous characteristic scars. Her menses have been regular since the age of eleven.

Her state of health does not offer anything noticeable until the age of 28, from which time she dates the beginning of the present affection. On the 2nd September, 1864, having gone her full time,

¹ 'Archives de Physiologie normale et pathologique,' 1869, p. 356.

² Ibid, 1871—1872, p. 509.

she was delivered of a child, which has ever since enjoyed good health. On the 6th September, the patient says that, having tried to get up, she found it impossible, as her legs were too weak to support her, and appeared paralysed. On the 12th, a new attempt to rise from bed had the same fate; walking and standing are almost impossible, owing to the weakness of the lower extremities. About the 20th September, she felt pains in her hands, and from this time forth her upper extremities in their turn became progressively weaker.

Towards the 1st of October, she was "taken in the tongue," according to her own expression, and her utterance began to grow very much embarrassed. The patient then went on foot, as well as she could travel, to the Hôpital Saint-Antoine. Sent away because there was no vacancy, she returned on the 11th, but this time the lower extremities had become too weak to allow her to walk and she was obliged to go in a car. Admitted on the same day, she was at once put under a course of nitrate of silver, administered in pills. This treatment was suspended at the end of three weeks. It had not impeded in the least the course of the disease; on the contrary, the weakness of the upper and lower extremities had rapidly advanced; walking had become quite impossible; the voice had taken a peculiar nasal sound (*nasillarde*),¹ her utterance was embarrassed, difficult, almost unintelligible.

It was impossible for us to ascertain from the patient the epoch at which began the characteristic atrophy and deformation of the upper extremities which she presented, in a marked degree already, when she entered the asylum. However this may have been, at the time she was admitted to the Salpêtrière, the affection seemed to have entered on a stationary period, and no aggravation of the symptoms were observed from the month of June to the 11th September, 1865, at which date the following note was taken: "The face is still covered with a very marked mask. The physiognomy has a singular expression: whilst the brow, the eyebrows, and the upper part of the cheeks have retained their mobility, it is remarked that, except at the moments when the patient experiences a somewhat lively emotion, the lower part of the face remains, as it

¹ The voice is said to be *nasillarde* when, the mouth being open and the exterior nares closed, it appears to sound within and throughout the nasal cavities. It is *nasonnée* when, mouth and nostrils remaining free, it resounds in the posterior portion of the nasal cavities into which it is directed.—S.

were, motionless and lifeless. But, when she laughs or weeps, the labial commissures are very strongly drawn back, the mouth opens very widely, and the naso-labial furrow appears exaggerated. The patient, however, can shut her mouth firmly enough, and pout, but she cannot whistle, blow, or simulate the act of kissing.

She seems very intelligent, and appears to understand all the questions put to her; but she only answers with the greatest difficulty, and in an almost unintelligible manner. The voice is nasal (*nasonnée*): speech is accompanied by a sort of grunting, and the articulation of most words is accomplished slowly, laboriously, with extreme trouble. Speech becomes somewhat less indistinct when the patient's nostrils are closed.

The tongue is small, shrunken, as if covered with convolutions on the dorsal surface, which is the seat of almost incessant fibrillary and vermicular movements. It cannot be raised towards the palate, but it can be put out between the teeth, but with difficulty. It is almost impossible for the patient to elongate it to a point, or to hollow it like an augur. The saliva gathers in the mouth, and is continually flowing out. The velum palati, the uvula, present their normal appearance, and when a spoon is pushed back into the throat, the palate rises, but indeed rather slowly.

For some days past, Catherine experiences a sensation of constriction in the pharyngeal region, though direct examination does not discover any redness in the mucous membrane, nor any swelling of the amygdalæ.

Deglutition is sometimes difficult, and it happens that portions of the food enter the larynx and cause fits of suffocation; but neither drink nor food ever return by the nostrils, nor does solid food accumulate between the cheeks and the dental arch.

The movements of the chest seem normal. Auscultation shows nothing pathological neither in the heart, nor in the lungs, and all the functions of organic life are accomplished in a normal manner.

State of limbs.—The upper extremities are, taken altogether, remarkably emaciated and weakened, they hang down beside the body; but, in addition, at the shoulder, forearms, and hands, there is predominant atrophy in certain muscles, or sets of muscles. The deltoid, on either side, is much wasted, and the shoulder prominence is lacking. In the forearms, the atrophy affects both the flexor and extensor muscles of the fingers; in the hands, the thenar and hypothenar eminences are remarkably effaced; the palmar

hollow is excavated owing to wasting of the interossei; moreover, the fingers are rather strongly and permanently flexed, especially at the joints of the first phalanges; so we have a fine example of the deformation known as a claw or talon hand (*main en griffe*). The movements of the different parts of the upper extremities are, besides, extremely restricted. The patient can scarcely raise her hands from her knees, where they usually rest almost inertly; this movement of elevation, which seems to require much effort, cannot long be maintained, and is accompanied by a sort of trembling of the hands, especially in a lateral direction, which is very singular. The movements of flexion and extension of the fingers are very restricted. Since the month of January, the patient, who knows how to write, cannot hold a pen; her hands, besides, are of no use to her, and it is wholly impossible for her to lift her food to her lips. The movements of her shoulder, those of the forearm, and those of the arm are also much restricted. Generally speaking, the left upper limb is perhaps a little less weak than the right. There is no sign of any alteration of *sensibility* whatever throughout the whole extent of the upper extremities.

The patient can neither walk nor stand alone. Assisted by two persons, if she tries to take a few steps, her legs stiffen, cross each other, and, at the same time, her feet turn in, owing to an involuntary movement of forced adduction.

The lower limbs are, also, greatly emaciated; but this is a general emaciation. We do not find, as in the upper limbs, deformations owing to predominant wasting of certain sets of muscles. The feet are a little rigid, in semi-extension, and strongly turned in.

There is also rigidity, contracture, in the knees, which are half flexed, and in adduction; the hips likewise appear a little rigid. Muscular strength, however, is not completely abolished in the lower extremities, and the patient can flex a little and extend her legs. These movements, which are very limited in extent, are not accompanied by tremulation.

No sensory disorders exist in the lower limbs, where the patient feels neither pains, nor cramps, nor formication. Electro-muscular sensibility appears normal, whilst it seems rather exaggerated in the upper extremities.

A large number of muscles, especially those of the superior extremities, are the seat of extremely marked fibrillary contractions. These are particularly noticeable in the forearms and hands. They

come on, sometimes spontaneously, sometimes under the influence of a touch. They are strong enough to produce very marked extension movements of the fingers, and of the whole hand. When a slight tap is given with the finger to the dorsal surface of the forearm, an extension movement is made, which is soon succeeded by a flexion movement, and this is repeated three or four times, after a single stimulation.

If the forearm be placed in pronation, by striking the supinator muscle a slight blow, we may determine a movement of supination, owing to which the hand is turned over on its posterior surface. Electric exaltation determines these same fibrillary contractions in a still more marked manner. These spontaneous or provoked fibrillary contractions are also remarked in all the muscles of the upper part of the trunk. They are, likewise, very marked in the muscles of the neck, but they are most frequent and most marked in the sterno-cleido-mastoid muscles, particular in that of the left side.

No trace of fibrillary movements is seen in the various muscles of the lower extremities. We have already mentioned that they are very evident in the tongue. The most emaciated muscles, those of the forearm, for instance, have preserved electric contractility in a high degree. Some of the lower extremities also contract under the influence of faradisation.

Such was the state of the symptoms in the month of September, 1865, one year after the beginning of the disease. From that period to the month of February, 1869, no noteworthy change took place. The numbness of the upper limbs simply increased, but impotence was not complete, and the patient could still move her fingers a little. Contracture of the lower limbs has also made progress, but never to any excessive extent. Finally, atrophy of the muscles, becoming more and more marked, rendered still more characteristic the deformations of the upper limbs, and particularly those of the hands.

The motor impotence and atrophy have, likewise, only proceeded very slowly as regards the face, and sub-hyoidean region. Nevertheless difficulty of pronunciation and all the other phenomena, recalling the picture of labio-glosso-pharyngeal paralysis, had become worse, whilst no noteworthy disturbance of the respiratory functions were superadded.

In the trunk no new symptoms had appeared. The emaciation was considerable, but without any evident sign of muscular atrophy.

The respiratory muscles acted normally, and, in particular, there was no sign of diaphragmatic paralysis.

The lower extremities exhibited the same weakness, the same emaciation already described. No atrophic deformation of different sets of muscles, nor fibrillary contractions were observed. The feet still retained their vicious attitude, they were turned in and slightly extended on the leg. It had been remarked that the patient was growing weaker, and was coughing for some time, when on the 5th of February, 1869, during the evening visit of the house physician, she was found in a rather grave state of asphyxia, which had almost suddenly shown itself. The pulse was at 136, there were 50 inspirations per minute. A moist laryngo-tracheal râle appeared, extending to a great distance. The upper part of the respiratory tubes was the seat of a considerable accumulation of mucous matter, which the patient could not get off. Next day these symptoms appeared to be partially dissipated; but, in the evening, they returned with all their gravity. The patient succumbed in the evening of the 11th February.

Autopsy.—February 13th, 1869. *A. a.* Cadaveric rigidity was several times observed in this case; it was complete twelve hours after her death, when the first examination of the body was made. It persisted thus throughout the entire day, on the 12th, and still very manifestly existed on the morning of the 13th. It was very strong even in the upper limbs, where atrophy was most marked. Before making an autopsy, the circumference of her wrists, arms, and legs was measured, and the following figures were the result :

Circumference of wrist	0·125 m.
„ arm	0·17
„ mid-thigh	0·365
„ leg, a little above the malleoli	0·175

There was no difference between the members on the right side and those of the left.

b. Thoracic cavity.—The *lungs* present tubercular granulations, in the inferior lobe of each, and nuclei of incipient caseous pneumonia. The summits were healthy. The *heart* weighed 185 grammes. Its tissue was red, firm, and it appeared entirely sound. There was no valvular lesion.

The other *viscera* offered nothing noticeable.

c. Muscular system.—Dissection of the muscles gave the

following results: 1°. *Face*.—The muscles of the cheeks and chin, but chiefly the buccinato-labial muscles were atrophied, pale, yellow, reduced to thin muscular slips. The orbicularis palpebrarum, the frontal, temporal, and masseter muscles presented nothing abnormal.

2°. *Neck*.—The sterno-cleido-mastoid muscles appeared healthy. The muscles of the supra-hyoidean region are very small. They present a yellow dead-leaf colour at the point of the tongue. They are, on the contrary, rather red, but manifestly wasted, at the base of this organ.

3°. *Upper extremities*.—The deltoid is atrophied in a very marked manner; it is thin, of a pale yellow dead-leaf hue. The muscles of the arm are small, but of an almost normal red colour. In the forearm, the muscles are exceedingly slender, but the red colour is sufficiently well preserved. The muscles of the hand are a dead-leaf yellow, and much wasted, especially the interossei. The muscles of the hand are certainly, with those of the tongue, the most altered.

4°. *Trunk*.—The sacro-lumbar muscular mass, in its lower part, seems to have undergone a certain degree of atrophy. Its colour is yellowish. The muscles of the abdomen present the same characters; and with respect to them, as well as those of the back, the lesions seem to diminish, and even to disappear, as we approach the breast. The pectorals are red, and do not exhibit much marked atrophy. The interossei are rather thin, and somewhat yellowish. The diaphragm appears healthy, at least, to the naked eye.

5°. *Lower extremities*.—The emaciation is rather marked; the muscles are not large, but yet their emaciation is not excessive, if we consider the general emaciation of the subject. On the whole, there seems here to be no atrophy properly so called. The muscles are red, and their tissue appears healthy.

d. Peripheral nerve system.—Viewed with the naked eye, one is struck by the considerable changes which are produced in the size and colour of the anterior roots. They are formed by the union of nerve-bundles, reduced almost to filaments, so that they are exceedingly slender. Their colour has assumed a very marked greyish hue, without, however, exhibiting that semi-transparence which is seen in nerves which have undergone complete atrophy. These changes of size and colour are all the more striking, because nothing of the kind is found in the posterior roots, which have pre-

served their normal volume and their white colour. In the cervical region, especially, these lesions are most marked, however they are seen throughout the whole height of the dorsal region; but they tend to become effaced, as we go away from the cervical region. In the lumbar region, the anterior roots have resumed their normal size and colour.

The facialis and hypoglossus, also, present a greyish hue, analogous to that of the anterior cervical and dorsal roots. This change in colour becomes particularly manifest, when we compare these nerves to the others, such as the lingual, for instance, which have preserved their whitish lustre. No diminution in the size of these nerves is remarked, analogous to that exhibited by the anterior roots. The other peripheral nerves do not show any perceptible modification.

e. Central nerve system.—The encephalon shows no alteration. We have mentioned, in speaking of the peripheral system, those of the cranial nerves which presented any change in colour. The *cord*, examined in the fresh state, has not revealed any alteration, perceptible to the naked eye, in the greater part of its extent, but for about 5 centimètres above the dorso-lumbar enlargement, it exhibited excessive diffluence. Large vessels, gorged with blood, and a diffuse red tint, were observed in the softened portion. The ramollissement principally affected the left side and the posterior part of the cord. It is possible that, in spite of all the care taken in removing the cord, this ramollissement may have been produced artificially; we shall see that a microscopic examination seems to lend support to this view.

B. Microscopic examination: Muscular system.—We shall begin the account of the microscopic examination of the muscular system we made by the description of the muscles of the hand; these, indeed, are the muscles which exhibit the most advanced lesions. The muscles of the thenar and hypothenar eminences, and the interossei had reached the same degree of degeneration, and gave the same results, on microscopic examination. The preparations were made in the fresh state. We shall take as type of our description the changes observed in the right opponens pollicis.

On shredding the muscular substance with needles on the glass slip, it is found that the consistence of the fibres is somewhat greater than usual; it recalls that of connective tissue. In most of the muscular bundles there exist fine dark granulations, becoming brilliant and pearly at a certain focus, which seem to be

fatty granulations; neither acetic acid nor potash dissolves them. We have repeated these tests several times, and the result has been always the same. These granulations vary much in number and size, in different fibres. The transverse and longitudinal striæ, which are very distinctly marked in certain atrophied but only slightly granulated fibres, are more or less completely masked in those where the granulations exist in abundance.

The striæ have entirely disappeared in a certain number of muscular fibres, which resemble cylinders filled with transparent matter, and which enclose a more or less considerable number of granulations that are generally large in proportion to their fewness. These granulations are no more dissolved by acetic acid nor potash than were those of the fibres which have retained their striæ.

The size of a number of the muscular fibres seems normal, but mostly we remark an often considerable diminution. Thus, beside a muscular fibre of normal size, we see others the cross diameter of which is reduced to a third or a half. Certain fibres even present a diameter four and sometimes five times smaller than the normal. And it is a noticeable and important peculiarity to see a large number of fibres, which have undergone an atrophy so complete, still exhibiting very distinct striation, and being scarcely or even not at all granular.

Among the most altered muscular fibres, only a small number have shown fragmentary division of the muscular substance. In the fibres where we observed this division, the lumps of muscular substance were pressed against each other; very rarely they have an interval between, and, then, in these points, the sarcolemma had shrunk back. We have not found any multiplication of nuclei in the tubes of the sarcolemma, as recently remarked by M. Hayem in a case of progressive atrophy lately published.

The *vessels* in the affected muscles did not reveal any alteration. We have several times succeeded in very distinctly seeing the *little nerves* of the muscles; we did not, in these cases, remark that they contained any degenerated nerve-fibres. The *interfibrillary connective tissue* appears more abundant than in the normal state, and an exaggerated proportion of rounded or fusiform nuclei are perceived.

In addition to the preceding alterations, most of the muscular bundles show a finely shredded appearance, which is very remark-

able at the broken ends of the fibres; this shredded appearance is, however, also met with in alterations of the muscle which have nothing in common with progressive atrophy; these are commonly observed in the muscles of the lower extremities in the case of individuals who have long remained motionless.

To sum up: in the muscles of the hand, that is, where the lesions were most marked, we have observed what follows: 1°, a diminution of volume in the muscular mass; 2°, a pale yellow hue of the muscles; 3°, greater consistency of the muscle, recalling that of connective tissue; 4°, granular fatty alteration, little marked in certain fibres, very evident in others; 5°, fragmentary division of the muscular substance; 6°, atrophy of certain muscular fibres, simple and independent of all fatty or waxy degeneration; 7°, proliferation of interfibrillary connective tissue.

We shall conclude this abstract by pointing out that, in one and the same preparation, all these alterations might be seen simultaneously.

Side by side, with an entirely healthy or but slightly granular muscular fibre, a fibre might be remarked whose striæ were almost completely masked by fatty granulations. Beside these, others had wholly undergone vitreous degeneration; others, again, showed every degree of atrophy. Some presented division in lumps of the muscular substance. In the intervals between these fibres was seen a large quantity of connective tissue and rounded or fusiform nuclei.

With respect to the *muscles of the tongue*, we may confine ourselves to repeating the foregoing description. Let us only observe that the lesions were most marked in the intrinsic muscles of this organ. The *muscles of the forearm* have nearly preserved their normal colour. However, we find in the intervals of the fibres a marked increase in the connective tissue; there also are granular fatty fibres, vitreous fibres, and others considerably wasted, but, generally speaking, all these lesions are much less marked than in the hand. In the *deltoid*, we discover all the most advanced alterations which we have described.

The *sterno-cleido-mastoid* muscles have been specially examined. It will be recollected that, in the observation, they were mentioned as being, especially the left, subject to fibrillary contractions, which are remarkable for their spontaneity, frequency, and intensity. The preparations of muscular substance, taken from the left sterno-

cleido-mastoid, to our great astonishment, presented absolutely no alteration whatever. The fibres were remarkable for their comparatively considerable size, their distinct striation, and the absence of all degeneration. We did not even remark in these muscles that shredded appearance which was well-nigh general in the muscles of the upper and lower extremities.

The *pectorales* did not exhibit any alteration.

The *intercostales* showed only a slightly marked granular fatty degeneration, and the shredded appearance. The same is to be said of the *diaphragm*, where we only met with a small number of fibres in which the granulations were abundant enough to mask the cross striæ.

The *muscular elements in the lower extremities* enclosed few or no fatty granulations. They are not perceptibly atrophied; the striæ are clearly marked, and they offer no alteration other than the shredding.

2°. *a. Anterior spinal roots. Examination in the fresh state.*—

The number of the nerve-tubes which have preserved their normal character, in these roots, is greater than might be supposed, to judge by the diminution of their size, and the greyish hue which they exhibit. However, in at least one half of the tubes, we can note every degree of atrophy, from simple emaciation to complete disappearance of the medullary cylinder. In these tubes, we nowhere met with trails of fatty granulations. What we have said relates especially to the cervical region of the cord; in the dorsal region, the atrophic lesions are less marked, especially in the lower parts of this region; and, on a level with the lumbar enlargement, they are completely absent.

b. The *posterior spinal roots* have been examined in comparison with the anterior; no trace of the nerve-tubes was observed.

c. Cranial nerves.—The facial and hypoglossus, examined in the fresh state, in different parts of their course, presented, especially the last, lesions comparable to those which have been mentioned in reference to the anterior spinal roots. But the number of healthy tubes was relatively greater. The lingual and the pneumogastric nerves have been the subject of a special examination; they did not appear to offer any alteration.

d. Rachidian nerves.—The two phrenic nerves, especially that of the right, have seemed to us to enclose a certain number of nerve-tubes atrophied in different degrees. Analogous alterations

were remarked in the median and ulnar nerves, examined in the forearm; in the latter nerves, some atrophied nerve-tubes presented evident granular degeneration. The examination of the *great sympathetic*, in the neck, and inferior ganglia, did not yield any decisive result.

e. Spinal cord. Examination of softened portion in the fresh state.—It will be recollected that, immediately above the lumbar enlargement, the cord showed a remarkable diffuence over a certain extent; fragments of nerve-tissue, coming from this softened spot, were placed under the microscope immediately after the autopsy; the nerve-tubes exhibited the characters of the normal state; in the intervals which they left between them we saw neither granular bodies, nor fatty granulations, neither did the sheaths of the vessels enclose any granular elements.

This negative result ought to make us think either that the ramollissement was of quite recent date, or that it was artificially produced.

Examination of preparations hardened by chromic acid and coloured by carmine. Cervical region.—The examination of transverse sections, taken at different heights, shows alterations, some of which affect the antero-lateral fascicles of the cord, and others the grey substance, particularly the anterior cornua—they are nearly the same throughout the whole extent of the region.

On every point of the antero-lateral columns, the septa of connective tissue have assumed considerable importance; they are remarkably thickened, and they appear to have multiplied. In the spaces circumscribed by them, as they anastomose and cross, we readily recognise the section-surfaces of nerve-tubes which, on a level with the anterior fascicles and in the anterior portion of the lateral fascicles, have almost entirely preserved their normal diameter. But, in a part, which corresponds to the most posterior part of the latter fascicles and in the whole extent of a region which, internally, bounds the posterior cornua, whilst externally it extends almost to the cortical layer, the connective matrix has become quite predominant. The nerve-tubes, which have retained their normal diameter, have here become very rare; most of the tubes are atrophied in different degrees, and a large number of them are only represented by an axis-cylinder. When the sections are examined under a low power, the points where the sclerous alteration of the lateral columns thus predominate appear under the

form of two little red, transparent, irregularly rounded patches, which are placed symmetrically towards the most posterior parts of these columns, immediately external to the posterior grey cornua. The posterior white columns exhibit no alteration.

In the examination of the *greysubstance*, the high degree of atrophy which most of the nerve-cells have undergone in the anterior cornua first strikes the eye; it is, also, evident that a certain number of these cells have disappeared without leaving any trace. The cells of the inner or anterior group are those, especially, which have undergone the deepest alterations; here, all the cells that remain are more or less wasted, whilst in the outer group, in most of the preparations, we see one, two, three, and even sometimes four of them, which have nearly completely preserved their dimensions and all the other characters of the healthy state. Among the wasted cells some, though six or seven times smaller than in the normal state, have still retained their stellate form, their prolongations, and still possess a distinct nucleus and nucleolus. Others are only represented by small irregular angular masses, without prolongations, yellow, brilliant, vitreous looking. In such cases the nucleus is generally no longer distinct. All these alterations may be clearly discriminated when the injured parts are compared with corresponding parts in sections of the healthy cord. As a standard of comparison, we have taken the beautiful preparations which we owe to the kindness of Dr. Lockhart Clarke.

The connective matrix of the anterior cornua showed itself under the appearance of a finely granulated mass; we did not remark that the nuclei of the neuroglia were more abundant than in the normal state. Matters were different in the anterior and posterior commissures; here the nuclei appeared numerous, especially in the neighbourhood of the central canal. The latter was completely obliterated by a mass of epithelial cells.

In the substance of the commissure, as in the anterior cornua, the vessels exhibited walls manifestly thickened, at times covered with numerous nuclei. The *posterior cornua* of grey substance appeared to possess all the conditions of the healthy state.

Dorsal region.—Only the upper two thirds of this region could be examined. The sclerosis of the lateral columns was seen throughout its height, at least as well marked as in the cervical region; as in the latter, though to a lesser degree, the cells of the anterior cornua were atrophied, and reduced to a few.

Lumbar region.—The symmetrical sclerous alteration of the lateral columns is also very distinctly marked here, but yet less extensively than in the other regions of the cord; it occupies the same position. The cells of the anterior cornua are almost normal in number; they generally present the dimensions of the healthy state. Only a few exhibit well-marked atrophic lesions.

Bulbar region: Sections made above the calamus.—By means of cross-sections, taken at different heights, in the olivary region and beneath, we have been able most distinctly to observe that the *cells of the origin-nucleus of the hypoglossus* are generally throughout the entire extent of these nuclei, profoundly altered, atrophied, or even destroyed. This alteration recalls exactly that which was noted in reference to the cells of the anterior cornua of the cord, in the cervical and dorsal regions. We have taken, as a standard for comparison in this department of our investigation, some very fine sections of healthy bulbi, prepared by Dr. Lockhart Clarke. We have also utilized the yet unpublished plates of the 'Iconographie photographique' of M. Duchenne (de Boulogne), relative to the structure of the bulbus. Now, on Clarke's sections, made at about half a centimètre above the point of the *calamus scriptorius* and representing the normal state, one could count from 40 to 50 tripolar or quadripolar large cells, in the nucleus of the hypoglossus, which in this region is voluminous and well defined everywhere; on the other hand, on sections taken from our patient, we could only find 3 or 4 at most of these cells, which were nearly normal; shorn the others had, for the most part, totally disappeared.

Some, which were considerably wasted, could still be discerned under a high magnifying power; others were only represented by small irregular masses, of an ochreous yellow colour, brilliant, and of their prolongations.

In addition, it could be seen that the delicate tracts (cell prolongations, probably), which, in the normal state, cross and recross in a thousand directions in the intervals between the cells, were completely effaced here; and between the cells nothing now was found save an amorphous, finely granular mass; finally, the nucleus of the hypoglossus, considered as a whole, appeared to have lost its rounded outlines; it presented an oval form transversely, and had evidently diminished in all directions.

On the same sections, immediately external to the nucleus of the hypoglossus, could be recognised the little group of cells which

Clark connects with the *inferior origins of the facial*. All the cells were healthy, and seemed normal in number.

Still more external is found the *origin-nucleus of the pneumogastric*. Most of the cells of the group were untouched, a few of them only (7 or 8 in each nucleus, and each preparation), and these the most anterior, exhibited yellow degeneration to a very marked extent, or else had undergone a very remarkable black pigmentation.

Sections taken at the point of the calamus.—In front of each side of the central canal the nuclei of the hypoglossus are found. There, also, the cells are wasted or degenerated. Behind the canal and on either side, the nuclei of the spinal nerve may be studied; both of them show some cells which have undergone yellow degeneration or black pigmentation, and they are at the same time deformed. The other cells of these nuclei are normal.

Section made above the olivary bodies.—The origin-nuclei of the facial, external oculo-motor, and auditory nerves, appeared to us to present all the characters of the normal state.

CASE II.

Symmetrical sclerosis of the lateral columns of the cord and anterior pyramids in bulbus. Atrophy of the cells of anterior cornua of the cord. Progressive muscular atrophy. Glosso-laryngeal paralysis.

Elizabeth P—, aged 58, entered, July 11, 1871, the infirmary of the Salpêtrière (wards of M. Charcot).

Data supplied by her son.—The affection with which she is stricken does not seem to have begun suddenly. In the month of July last, P— was still able to walk, though with some difficulty. Her left hand was already useless, and was kept close to the body. She also complained of finding her right hand becoming weak for some time, which was a hindrance to her taking food. She had, likewise, a slight difficulty in speaking, but deglutition was performed with ease.

Present state: 29th September, 1871.—The physiognomy is stupid; from the mouth, which is always wide open, the saliva is constantly flowing.

It seems as if all the muscle of the face were in a state of per-

manent contracture, which becomes exaggerated whenever the patient laughs or weeps; the sort of grimace which is then produced only passes away with extreme slowness.

The movements of the orbicularis oris are notably impeded. The lips cannot meet as in the act of whistling or blowing. In blowing out a candle, the mouth is half open; she succeeds in extinguishing it even when it is placed at some distance from her mouth. Diduction-movement of the maxillæ appears impossible. Contraction of the masticatory muscles is of but little strength, hence she can only triturate food when it is soft.

Articulation of words is abolished; the efforts of the patient only result in the production of a sort of grunting, which is quite incomprehensible. Intelligence seems preserved to some extent, and the patient seems to understand all the questions put to her.

The tongue is stricken with almost absolute motor impotence, whilst it also presents all the characteristics of an already far advanced atrophy. Small, shrunken, stirred by fibrillary movements, ploughed with furrows, and habitually covered with a blackish fur, it remains glued to the floor of the mouth, and it is with difficulty carried forward and a few millimètres beyond the lips. As to the movement of elevating the tip towards the palatine arch, this is totally abolished.

Difficulty of deglutition, though a little less incomplete, is yet very noticeable. It is only in the last few days that it became suddenly marked. When a liquid is introduced into the mouth, the greater part of it flows out between the lips; then a series of deglutition-movements follows, with considerable ascent of the larynx and very sonorous pharyngeal noise. If the liquid be carried on a spoon to the fauces, the deglutition takes place in a more complete manner, but it brings on a state of extreme anxiety. Whatever may be the mode of introduction of the alimentary substance, its entrance into the œsophagus seems to take place with extreme slowness, and some minutes after, noisy pharyngeal movements, provoked by liquid remaining at its upper orifice, are still remarked. The fluids never return towards the nasal fossæ, and, moreover, direct examination of the velum palati shows that it is symmetrical, and that it has retained the perfect freedom of its normal movements.

Up to the last few days the patient could still be got out of bed, and she passed the hours of daytime seated in an arm-chair. But

the symptoms having become suddenly worse, she is now completely confined to bed.

Motor impotence, complete in the left upper limb, is a little less marked in the left. This paralysis is accompanied by a certain degree of contracture; the fingers are flexed on the palm; the wrist is in pronation; the half-flexed elbow resists when one tries to straighten it. The muscular masses are wasted, and stirred with fibrillary movements. The atrophy, which is more marked on the left than on the right, is probably more advanced at the root of the limb than at its extremity. Whilst the muscles of the shoulder, particularly the deltoid, have nearly disappeared, leaving the bony projections bare, the thenar and hypothenar eminences, though lessened, have still preserved a considerable thickness.

In the thorax, the pectorales majores are affected in the same degree as the deltoid muscles; the least touch brings up fibrillary motion, when it does not show itself spontaneously.

The lower limbs, which are much less deeply affected, are equal in size. They present a noticeable emaciation over the whole limb; no group of muscles seems more specially taken than the others. They can execute some movements on the bed-level. The muscular masses, those of the calves especially, are the seat of abundant fibrillary contractions. Faradaic examination of the muscles enables us to state that they all contract under the influence of electricity, though the lower limbs react with greater force than the upper. The orbicularis oris in particular seems very sensitive to electric excitation. But muscular contraction does not everywhere take place with its normal character, and, in many muscles, it assumes the form of fibrillary motion.

Sensibility seems to be preserved in all its modes. The pulse is 104. Respiration regular.

1st October.—P. 100. Commencement of bed-sore.

2nd.—P. 108; R. 26.

6th.—P. 100; R. 20.

7th.—P. 120.

10th.—P. 130. Extremities cold. Urine turbid, containing neither sugar nor albumen. Retention of urine.

13th.—P. 124.

14th.—P. 120.

23rd.—Debility has made considerable progress. The patient has scarcely strength to cry out. Feeding has become impossible.

Extremities cold. Pulse imperceptible. The bed-sore has spread over a great breadth.

25th.—Death.

NECROPSY: *State of viscera*.—The *heart* is small; no valvular lesions exist; the walls have their normal thickness and colour. No lesions in the *lungs*. The *liver*, normal in size, exhibits no cicatrices; same thing as regards *spleen* and *kidneys*. The *vesical mucous membrane* is red, covered with mammillated projections, lined with purulent exudation.

State of muscles.—The muscles of the face are very slender, but their colour is perceptibly near the normal hue. The masseter, red on the surface, is yellowish within. The sterno-mastoid, scalene, and trapezius muscles are well nourished, and present a fine red colour.

The pectorales and the muscles of the left upper limb are yellow, discoloured, thinned, and their appearance strikingly contrasts with that of the muscles of the neck; the deltoid is especially altered. In the hand, the muscles of the thenar and hypothenar eminences are discoloured. The serratus magnus, like the pectoralis major, is pale and wasted. It is the same thing, but to a less degree, as regards the abdominal muscles. The *diaphragm* has preserved its normal colour, consistence, and thickness.

In the lower extremities, the muscles, although slender are scarcely discoloured—a certain number of them have been examined. The sartorius, the rectus femoris, for the thigh—in the leg, the gemelli, the tibialis anticus, the extensor communis digitorum—but none of them presented even that dead-leaf colour which long confinement in bed so frequently gives to muscles.

State of nerve centres.—The *brain*, the *cerebellum*, and the *isthmus* of the encephalon do not present any perceptible alteration; the arteries of the base are healthy. The bulbus rachidicus presents all the signs of the normal state. The tissue of the *cord* is firm in consistence throughout; there is no evident atrophy affecting the different columns of the organ. The originating filaments of the *bulbar nerves*, situated below the facial, namely, the hypoglossus, glosso-pharyngeal, pneumogastric and spinal, contrast, by their fineness and their grey colour, with the nerve-roots situated above; the facial in particular is free from all alteration. This extreme tenuity and this grey tint are again met with in a certain number of the anterior roots of the cord.

Histologic study: Muscles.—Examination of the muscles of the

tongue, several times repeated, has always given an almost negative result. At least, we have never found that granular condition of the muscular fibre, nor that abundant nuclei proliferation which characterises atrophic degeneration of the muscles, arrived at an advanced degree of evolution. In the muscles of the *face*, on the contrary, numerous fibres had lost their cross striation, and presented a very marked granular condition of the contents of the sheath.

In the *muscles* of the *upper limbs* which, to the naked eye, exhibited a yellow colour and a very evident diminution in size, microscopic examination revealed the presence of a large number of degenerated primary bundles. In the thenar and hypothenar eminences, particularly the fibres had undergone very marked simple atrophy; in other places, they had largely lost their cross striation, and the nuclei of the interstitial connective tissue were extremely multiplied. On certain preparations, examined in glycerine after the addition of acetic acid, we could see the contents of broken sheaths, forming islets arranged in parallel series, separated from each other, and partly masked by clusters of nuclei. The muscles of the *trunk* and *lower limbs* presented the same alteration, but, especially the latter, to a much less advanced degree.

Nerves.—The originating filaments of most of the bulbar nerves have been examined, and all exhibited histologic characters closely akin to the normal state. We could barely distinguish a few fibres with granular contents, whilst some others, deprived of their medullary cylinder, were reduced to their sheaths and covered with more numerous nuclei than usual. The trunks of these nerves were not, any more than their roots, notably altered in their ulterior course. In particular, the integrity of the fibres of the *hypoglossus* at the base of the tongue have been observed; the same holds good as regards the *spinal*, *pneumogastric*, and *facial* nerves.

The *anterior roots* of the *rachidian nerves*, examined on a level with the cervical enlargement, showed some degenerated fibres in the midst of a large number of healthy fibres.

The left *median nerve* examined, after being hardened, in transverse sections was found healthy.

Nerve centres.—Preparations made after hardening in chromic acid and coloured by carmine:

Bulbus rachidicus.—Examination of transverse sections of this organ, taken at different heights, enables us to discern lesions of the white and grey substances.

1°. *Grey substance*.—The *origin-nuclei of the bulbar nerves* are the seat of alteration here. The latter, which is essentially characterised by pigmentary alteration and consecutive atrophy of the nerve-cells which enter into the composition of these nuclei, is especially marked in that of the hypoglossus nerve. Beside some cells which have remained healthy, we can see in the others the characters of the lesion at all stages of its development. Most of them, already invaded by yellow degeneration, refractory to the action of carmine, and notably diminished in volume, have assumed a globular form. They give birth to rare prolongations, pale and thin, which it is impossible to follow, as in the normal state, for a certain distance from their point of origin.

The *neuroglia* does not appear to take any part in the morbid process, it has preserved its normal transparency, and it is impossible to discover any evident augmentation in the number of its nuclei.

The cell groups, belonging to the several other nerves of the region, are less severely smitten. The cells are here in considerable number, and if some appear to have undergone a decrease in size, we find but very rare examples of that pigmentary invasion which is so distinct in the hypoglossus-nucleus.

The *olivary bodies* are normal in all the sections.

2°. *White substance*.—The lesion of the white substance here occupies the whole extent of the anterior pyramids, which are the seat of very manifest sclerosis, and are vividly coloured by carmine. It may be traced, in the fascicles, from the point where they emerge from the protuberantia to a level with their decussation. It is easy, on the same sections, to perceive the perfect integrity of the nerve roots in their intra-bulbar course. It is especially very evident as regards those of the hypoglossus, and contrasts in a striking manner with the very marked atrophy of their origin-nucleus.

The decussation-region possesses particular interest; whilst, in the anterior part, what remains of the pyramid stands out distinctly under the form of a transverse red band, we see the sclerosis advance, like a wedge, the broad end of which is behind, into the decussation-region, and proceed to invade, passing from the opposite side, the reticulated formation and the superior part of the lateral columns. The anterior cornua which, at this level, are represented by two islets of grey substance completely isolated from the central substance, contain a notable proportion of degenerated cells.

Cord.—The cord is the seat of very extensive alterations which bear both on the anterior cornua of the grey substance, and on the antero-lateral columns. It is, also, to be remarked that, at least, in the cervical region, the lesions appear to have reached a more advanced period of their evolution in the left than in the right side of the organ, which has consequently become unsymmetrical (Plates IV and V).

Antero-lateral columns.—These present, on transverse sections of the cord, all the characters of sclerosis of the white substance. The great connective tracts, which extend from the periphery of the organ to the grey substance, are thickened. The meshes of the reticulum, considerably broadened, exhibit numerous nuclei. They bound very unequal spaces, in which sections of the axis-cylinder are seen. The latter are mostly more slender than in the normal state; in some places, and on the contrary, they appear hypertrophied. The altered regions are vividly coloured by carmine.

If we study the distribution of this sclerosis, it is seen to occupy, throughout the whole length of the cord, symmetrical points in each of the halves of this organ. It also recalls by its mode of distribution the descending degenerations, consecutive on certain circumscribed lesions (*en foyer*) of the encephalon, though it differs in certain particulars.

In the entire cervical region, it occupies, in the innermost part of the anterior columns, a sort of triangle, the base of which rests on the white commissure; one of the sides of the triangle borders the anterior sulcus, whilst its apex tapers to an end towards the middle part of this sulcus. This triangle, broader on the right than on the left, is seen no more towards the lower part of this region.

In the *lateral columns*, commencing in front at the outer angle of the anterior cornu, it follows, within and behind, the contour of the grey substance without penetrating its interior; whilst, on the outside, it is separated from the periphery by a narrow band of healthy tissue.

The superior portion of the region, that which is situated immediately below the collar of the bulbus, diverges a little from this description. Here, in fact, the anterior cornu is surrounded on all sides by a sort of crown of sclerosed tissue. If, from the upper portion, we descend towards the dorsal and lumbar regions, we see the sclerosis leave the anterior column and progressively diminish in

extent in the lateral column. In the dorsal region, the peripheric circle of healthy tissue enlarges notably, whilst the sclerosis leaves the contour of the anterior cornu. In the lumbar region, it has gone off from the posterior cornu and forms a sort of islet situated in the posterior part of the column, and surrounded on all sides by normal tissue, except behind, where it sends a prolongation towards the periphery and the entrance point of the posterior roots. All the rest of the white substance, and particularly the posterior columns, is exempt from alterations. The same thing holds good for the anterior roots in their intra-spinal course.

Grey substance.—Here, exactly limited to the area of the cornua of grey substance, and symmetrically disposed in the two halves of the cord, we again meet with the cellular lesion which has been described in reference to the nucleus of the hypoglossus. Striking indiscriminately and at hazard, as it were, different groups of these cornua, it gradually diminishes in extent, in proportion as it approaches the inferior region of the cord. Whilst, at the cervical enlargement, we can hardly compute the number of cells spared at one fifth of the total number, in the lumbar region more than a half have preserved the characters of the normal state. The vesicular column of Clarke has not been spared; but all the elements of the posterior cornua have escaped degeneration.

The *neuroglia* has not here, any more than in the bulbus, taken an active part in the morbid work; and, in all the sections, we may see cells reduced to a few pigmentary granulations in the midst of a perfectly normal tissue. However, the grey substance has, in certain spots, been disorganised in its entirety, and we can observe, in the upper region of the cord, the presence of genuine foci. Vertically elongated, they occupy symmetrically the two anterior cornua, the limits of which they do not exceed. The sections which were made across their middle portion show only a thick mass of tissue becoming strongly coloured by carmine, projecting above the surface of the section, in which it is difficult to distinguish any element. But these foci, swollen in their middle part, taper off at both ends, and it is in these points we should examine them. We then see that they begin by a certain number of little rounded islets, the tissue on a level with which is evidently thickened and rendered less transparent without any manifest multiplication of neuroglia-nuclei being remarked.

V.

NOTE ON A CASE OF GLOSSO-LARYNGEAL PARALYSIS, FOLLOWED BY AUTOPSY. BY J. M. CHARCOT.

(See Lecture XIII, p. 192.)

By the general aspect of its symptoms, the case, which I am going to describe in full detail, belongs to the clinical type created by Dr. Duchenne (de Boulogne), under the name of progressive muscular paralysis of the tongue, of the velum palati, and of the lips; but, considered anatomico-pathologically, it differs remarkably from all cases of the same kind which have been published up to the present. It is on this account, chiefly, that it has seemed to me worthy of attracting the attention of the reader for an instant.

CASE.—Baj— Marie-Françoise, aged 68, was first admitted to the General Infirmary of the Hospice de la Salpêtrière April 11, 1869, to be treated for a slight bronchitis; it was not remarked at that time that her speech was embarrassed. However, her children affirm that they had remarked that, during the past year, she expressed herself with great difficulty from time to time. About last May deglutition difficulties appear to have begun. It is certain that, since that period, it often happened that, in swallowing, food went the wrong way, and that the patient was taken with violent fits of coughing. During meals, she very often, also, threw up food through the nasal passages. An exasperation of all the symptoms appears to have been suddenly produced, about a month before her second admission into the infirmary, which took place on the 10th September. In the space of a few days the articulation of words seems to have become almost impossible, and, from this moment, the difficulty in swallowing food and drink appears to have grown rapidly worse. The patient declares that this abrupt aggravation was not accompanied by giddiness or any other phenomena of the same kind. The weakness in the voluntary movements which at

present exist in the left upper limb, to which reference will again be made, dates back four months, and was produced slowly, in a progressive manner.

Present state, September 10, 1869.—The articulation of words is already so much embarrassed that the patient cannot succeed in making herself comprehensible; all the attempts at speaking which she makes result, in fact, in the production of a hollow grunting, with nasal twang. However, as well as can be determined in the case of a patient who can only express herself by signs, her intelligence seems perfectly preserved. The tongue is not so inert as one might believe from what has been said; it has retained its normal shape, thickness, and dimensions; its surface offers no abnormal wrinkle or furrow; however, on examining its border with the greatest care, some slight fibrillary movements seem, from time to time, to be perceptible. B— can still protrude it easily enough, and move it from right to left, but she cannot either turn up the point, nor apply its dorsal surface to the palate.

The movements of the orbicularis oris are very markedly weakened. The patient cannot simulate the act of kissing or whistling, but she can, by exerting all her strength, blow out a candle distant 10 centimètres or more from her mouth.

The difficulty of deglutition is most marked. When B— wishes to swallow a fluid, she first rejects, almost always voluntarily, a considerable quantity from her mouth. Then, putting the thumb of the right hand on one side of the larynx, she seems to desire to assist the upward movement of this organ, which soon occurs; but, hardly has the first stage of deglutition taken place than a state of extreme anxiety supervenes; for over five minutes the patient seems threatened with suffocation; she does not generally cough, but at every inspiration a sonorous laryngeal sound is heard resembling, to a certain extent, what is observed in certain cases of œdema glottidis. It often happens that some drops of the fluid taken in are returned through the nose. The deglutition of solid food, or better still, semi-liquid food, is, perhaps, less difficult than that of fluids proper, but it is still generally troubled by the same symptoms.

Direct examination of the velum palati does not detect any deformity; the uvula occupies the mesial line, and does not hang down too much; the membranous velum appears likewise to contract in a nearly normal manner when titillated.

A thick and viscid saliva gathers constantly in her mouth and sometimes runs out. The patient is often found using her fingers to clear her mouth of the thick mucus and portions of food which have accumulated there. On account of the difficulty of deglutition the process of feeding takes place in a very incomplete manner; the patient shows, at every instant, by significant signs, how distressing it is for her to be unable to satisfy her hunger.

She is very thin, and is already much weakened. On examining the state of the muscular system in the different parts of the body, we remark what follows:—The muscles of the left shoulder are manifestly more emaciated than those of the right; besides, the deltoid is almost constantly stirred by very marked fibrillary movements, which are spontaneously produced or which are readily aroused by a slight touch when they cease to occur. Owing to the debility of these muscles, the patient finds it difficult to raise her arm, and she cannot lift her left hand to her mouth. The arm and forearm, on this side, are not more emaciated than the corresponding parts of the right upper extremity; their muscular masses, however, are here and there the seat of some fibrillary contractions. Finally, movements of prehension are accomplished with the left hand as well as with the right, and there is no trace of predominant atrophy in the muscles of the thenar and hypothenar eminences.

The right upper extremity is uniformly emaciated throughout; no partial atrophy exists anywhere. However, fibrillary movements, but slightly marked in truth, occur in some parts, chiefly at the shoulder.

The lower extremities are both emaciated to the same degree; there is no difference in this respect between the right and left sides. Their movements are normal, but notably weakened. B—, however, can stand, and take some steps in the ward, but not without great fatigue. On the left, the muscles of the anterior part of the thigh and those of the calf are the seat of fibrillary contractions.

Fibrillary contractions are likewise observed in the cervical portion of the trapezius, and in the sterno-cleido-mastoidei. Nevertheless, the action of the muscles which move the head is of sufficient strength, and the attitude of the latter is quite normal.

No visual disturbance appears to exist; the pupils are of the same diameter. Sensory derangements are nowhere to be discerned.

The pulse is weak, but not quickened; the temperature of the body is normal. Neither sugar nor albumen was found in the urine, although it was frequently examined.

October 25th.—Debility has made vast progress. B— can no longer sustain herself on her legs. Yesterday, she fell when getting out of bed, and was unable to rise without help. Deglutition has become absolutely impossible, and, for some days past, recourse was had to the stomach-pump. It is again remarked that the movements of the velum palati take place tolerably well under the influence of direct stimulation. It is also remarked that the tongue can still be protruded beyond the lips, and slightly turned from right to left, but its movements are evidently slower and weaker than in the past. Its size, however, has not been notably diminished; its dorsal surface is still perfectly smooth, and no capillary contractions are observed. Its borders alone, are, in certain points, plaited, wrinkled, and exhibit almost incessant vermicular movements.

26th.—For the first time, it is observed that the pulse is frequent, —130. However, the temperature of the rectum is 37.4° C.

27th.—The pulse is still quicker than on yesterday. The number of its pulsations rises probably to 150 per minute. It is very small, almost imperceptible. The respiration is at 32. The inspirations are very distressing, and accompanied by strong contraction of the sterno-cleido-mastoidei and scalmi. There is extreme anxiety. When we ask the patient if she is suffering, she puts her hands over the precordial region, and gives us to understand that she there experiences a suffering which she cannot define. By palpation, and percussion, it is ascertained that the pulsations of the heart are sufficiently strong. The second sound is, at the base, hardly distinct; it is, on the contrary, tolerably well marked at the apex. No abnormal sounds are heard.

28th.—Pulse 128; temp. rect. 37.6° (C.); resp. 28. The inspirations have become more and more distressing, and are accompanied by energetic contractions of the sterno-mastoidei, scalmi, pectorales majores, and of the anterior border of the trapezius. It is remarked that the belly subsides in the epigastric region when the ribs and clavicles rise. Hence there is inertia of the diaphragm.

29th.—Same condition as yesterday. The pulse is extremely rapid; temp. rect. 37.6° . The patient refused to permit the stomach-pump to be introduced. In the evening: extreme dyspnœa; 32

respirations; there were probably more than 150 pulsations per minute; the rectal temperature is 37.6° C. The patient suddenly succumbs in the night, without a struggle.

NECROSCOPY, made twenty-four hours after death.—Cadaveric rigidity is well marked everywhere.

A. a. *State of viscera.*—The heart is normal in size; the right ventricle is distended by black clots. No lesion of the valves exists; the muscular walls of the left ventricle are perhaps a little pale, but rather firm. The lungs are very emphysematous, especially the right; they do not exhibit any other alterations. The liver is of normal size. The supra-renal capsules, kidneys, and spleen are healthy. The stomach and intestines are shrivelled and shrunken; otherwise they present no perceptible alteration.

β. *State of muscles.*—The extrinsic muscles of the tongue and of the supra- and sub-hyoid regions exhibit a fine red colour; per contra, the proper muscles of the tongue are distinguished by their pallor and by an evident diminution in firmness.

In the *larynx* all the intrinsic muscles appear to be healthy, with the exception of the arytenoidei, the posterior crico-arytenoidei, and the crico-thyroidei, which are manifestly atrophied, and, here and there, show a very evident yellow hue. The crico-arytenoidei and the crico-thyroidei of the left side are besides much more altered than their congenerous muscles, and they are noticed to have little ecchymotic spots in the vicinity of their insertion.

The muscles of the *pharynx* do not seem to have undergone any perceptible alteration. The muscular wall of the œsophagus appears to be normal in size and consistence. Both sterno-cleido-mastoidei are slender, but red.

The trapezius has a yellow tint throughout; this abnormal colour is especially marked at the left anterior border of the cervical portion of this muscle. In this spot, the muscular fibres are very pale, very friable, and separated by little lumps of fat.

The same alteration is remarked in the anterior portion of the deltoid on the left side. The posterior part of the same muscle is relatively little altered. The right deltoid presents a fine red colour.

The two pectorales are slender, but nowise discoloured; the intercostales, on the contrary, are atrophied and yellow.

In the arms, forearms, and hands, the muscles, alike in left and right side, present the appearance of the normal state. The diaphragm

does not show any perceptible alteration. Some muscles of the lower extremities have been examined; they present the normal characters, so far as colour and consistence are concerned.

γ. *State of nerve-centres and of bulbar nerves.*—The brain proper and the different parts of the isthmus do not exhibit any perceptible alteration; the bulbus in particular and the protuberantia offer all the appearances of the normal state. No trace of atrophy or induration is detected. The arteries of the base are barely atheromatous. The cord, examined externally and in sections taken at different heights, appears also to be perfectly healthy.

The root-filaments of a certain number of bulbar nerves, namely, the hypoglossus, the pneumogastric, the glosso-pharyngeus, and the spinal, especially, are slender. As to the nerve-trunks, arising from these roots, they appear to be a little less in size than in the normal state, but they have not undergone any change in colour.

B. *Histologic study: a. Muscles.*—Towards the tip of the tongue, where the muscular fibres were paler, perhaps one half of the primary fibres presented throughout, with no well-marked reduction in size, a certain degree of granular alteration, with or without the disappearance of the cross striæ.

Next we find, by means of preparations coloured with carmine, a very evident multiplication of sarcolemma-nuclei on a great number of primary fibres. The connective tissue, interposed between these bundles, exhibits nearly everywhere a greater number of nuclei than in the normal state.

It is remarkable that the proliferation of the nuclei of the sarcolemma is, perhaps, more manifest on the sheaths of the bundles which have preserved the cross striæ, and which are only affected in a very mild degree, by granular degeneration, than on the bundles where this degeneration is most marked.

Here and there some sarcolemma-sheaths were found void of contractile substance, and filled by masses of nuclei. These, sometimes, exhibited the hour-glass form. Finally, on some preparations, we saw sheaths shrunken on themselves, and only enclosing, in their almost effaced cavity, granulations of fatty aspect, or clusters of nuclei.

The fatty granular alteration of the primary bundles, the absence of cross striæ, and the proliferation of nuclei of the perimysium, and of the sarcolemma, are met with in all the other regions of the tongue, but in a less degree than at the tip.

Although they have preserved their normal red colour, the extrinsic muscles of the tongue here and there show some primary fascicles where we readily recognise the granular fatty alteration and the multiplication of the nuclei of the sarcolemma or of the perimysium. The same remark may apply to the muscles of the pharynx, which, likewise, appear healthy to the naked eye. As to the muscles of the larynx, those among them which presented a marked yellow colour to the naked eye, as the posterior crico-arytenoidei, for instance, exhibit nearly the same degree of granulo-fatty degeneration as the tongue.

The muscles of the arm and forearm, those of the hand (thenar and hypothenar eminences), although they appeared quite healthy to the naked eye in colour and consistence, yet exhibited, under the microscope, a good number of primary fibres which had lost their cross striæ, and displayed granulo-fatty change, and multiplication of the sarcolemma-nuclei in a more or less marked manner.

The yellow muscular fibres, derived from the anterior portion of the trapezius and of the deltoid on the left, in addition to the granulo-fatty alteration extending to a very large number of primary fibres, exhibited an accumulation of large fatty drops interposed between the primary bundles.

The muscles of the lower extremities (thigh and plantar muscles) have been examined in several parts. The granulo-fatty alteration of some of the primary bundles has been noticed, in a very distinct manner. But the bundles thus altered were less numerous there than in the corresponding parts of the superior extremities.

β. *Cranial nerves*.—On all the preparations, in the fresh state, derived from the very slender radicular filaments of several bulbar nerves, from the hypoglossus for instance, it is remarked, not without surprise, that the nerve-tubes have preserved their medullary cylinders.

We did not succeed in distinctly detecting the existence of empty and shrunken sheaths. Fine granulations, few in number, however, are uniformly disseminated over the whole extent of some nerve-tubes. Nowhere are they in masses, under the form of granular bodies.

The trunks of the hypoglossus, spinal, and pneumogastric nerves did not present any other alteration than this same granular state of some nerve-tubes. This alteration is very marked in the

inferior laryngeal nerve. The phrenic and the great cervical sympathetic present the characters of the normal state.

γ. *Examination of nerve-centres, preparations hardened by chromic acid and coloured by carmine.* 1°. *Spinal cord.*—Cross sections of different parts of the lumbar enlargement.

Examination of the white columns shows neither diminution in the diameter of the nerve-tubes, nor multiplication of the neuroglia-nuclei, nor, lastly, any thickening of the connective tracts which radiate from the grey centre towards the periphery of the cord.

In the grey substance, and more especially in the area of the anterior cornua, all the alterations are concentrated and, again, they occupy only the nerve-cells here; for here, also, the neuroglia is normal, or only presents scarce visible traces of nuclei multiplication.

Some of the nerve-cells have preserved all the characters of the normal state; they are few in number, since they stand for less than a third on each preparation. They are readily recognised by the following peculiarities: they are still furnished with their prolongations which, like the cell itself, are coloured vividly and uniformly by carmine. The nucleus and nucleolus are very distinct. The small quantity of pigment which they often contain in the normal state is not augmented.

The cells which show the first degree of alteration are immediately recognised by the very intense yellow ochreous hue which they exhibit in the greater part of their extent. This colour results from the presence of pigmentary granules united under the form of little lumps, and not affected by carmine. The parts of the cell which have not been invaded by pigment become, on the contrary, coloured, almost as in the normal state. The nucleus and nucleolus are yet more visible and more coloured, but the prolongations are generally very short, as if withered, or worse still, they have completely disappeared. At the same time, the cell diminishes in size; it tends to lose its angular outline, and acquires a globular form.

At a more advanced degree of the morbid process, the cell, yet more diminished in its dimensions, absolutely deprived of its prolongations, is now only represented by a little mass of yellow granules. The nucleus and the nucleolus have, in general, completely disappeared. There are, however, cases where the latter still persists;

then it is the only portion of the cell which has retained the property of being coloured with carmine.

Lastly, we find here and there, in points formerly occupied by a cell, scattered yellow disintegrated granulations. This, doubtless, is the final term of the alteration. In such a case, we no longer find the slightest trace of nucleus or nucleolus.

The alteration of the ganglionic cells is uniformly spread over the whole extent of the anterior cornua ; it does not specially affect certain groups of cells, so that healthy cells, and cells diseased in different degrees, are everywhere intermingled. The small cells of the posterior cornua did not appear to exhibit any trace of yellow degeneration.

Comparative measurements, taken with the help of good preparations obtained from the same points in the same region of a healthy cord, have shown what follows :

The cells which have retained the property of being coloured by carmine throughout (healthy cells), have the same dimensions as the cells of the normal preparation ; all the cells which have lost their prolongations are atrophied. So long as the nucleolus is visible, it preserves its normal size.

Sections from dorsal and cervical regions.—The cell-alterations are identical with those in the lumbar region, but more marked, especially in the cervical enlargement. The cells of the vesicular column are altered to the same degree as those which constitute the groups of the anterior cornua.

2°. *Bulbar region : a. Section from immediately above the calamus point.*—The origin-nucleus of the hypoglossus, the lower part of which is visible at this level, exhibits very manifest alterations, which, here also, bear exclusively on the nerve-cells ; the neuroglia is intact ; its vessels perhaps are larger than in the normal state ; in any case, they appear gorged with blood-corpuscles.

The greater part of the cells (about two thirds of them) exhibit all the grades of the pigmentary alteration, described above in reference to the different regions of the spinal cord. The altered cells are disseminated everywhere and mingled with healthy cells ; they do not occupy any particular spot by preference ; yet perhaps they are more numerous than elsewhere towards the external limit of the nucleus.

Behind and external to the hypoglossus-nucleus we can study the originating cell-groups of the spinal nerve. These cells have mostly

preserved the characters of the healthy state. A considerable number of them, however, have gone through different stages of pigmentary alteration, principally towards the external region of the nucleus. It is known that, in the normal state, there exists in this spot some more or less pigmented cells, but the number then is much more restricted.

b. Section from the middle of the olivary bodies.—The cells of the convolutions of the olive do not exhibit any appreciable alteration. Those which constitute the nucleus of the hypoglossus at this level are, on the contrary, very numerous affected. The origin-cells of the pneumogastric do not appear to be so deeply altered. Between the nucleus of the hypoglossus and that of the pneumogastric in this region, lie the small cell-groups, which L. Clarke connects with the nucleus of the facialis. The cells of this group appear remarkably small and few in number. They do not, however, exhibit the pigmentary alteration. A section taken a little above the preceding one enables us to state that the origin-cells of the glosso-pharyngeus are not obviously altered.

c. Section from the most superior portion of the olivary bodies.—This section, which contains the nuclei of the facial and of the external oculo-motor, as well as that of the trigeminus (? sensory portion) according to Stilling, shows that a large number of cells of the *fasciculus teres* and a small number of cells of the trigeminus exhibit all the characters of the alteration above described.

One of the most interesting points of this observation is, unquestionably, the existence of an alteration which, in a systematic manner, so to say, occupies the nerve-cells, not only throughout the whole height of the spinal cord, but also in the bulbus, from which comes the progressive disorganization or even the complete destruction of a considerable number of these organic elements. In the bulbus, the alteration bears particularly on the origin-nuclei of the hypoglossus and of the spinal nerves; but, it is also observed, though in a lesser degree, in the nuclei of the pneumogastric and of the facial. In the spinal cord, it is limited to the great nerve-cells of the anterior cornua, termed motor cells; the cells of the posterior cornua do not appear to be affected. It is met with in all the regions of the cord, but it certainly predominates in the cervical enlargement.

In what does this alteration consist? The accumulation of

yellow pigment seems to play a large part; it appears to be the initial fact. The atrophy of the cell-prolongations, that of the nucleus, and lastly, that of the nucleolus, are consecutive phenomena. Have we here a process of slow irritation, or, on the contrary, of a quite passive atrophy? Nothing can be decided with respect to this from a consideration of the anatomical characters merely; but it may, I believe, be affirmed that this morbid process, whatever it be, affected *primarily* the cell; it was not communicated to it from without. In fact, the reticulum which, on all sides, surrounds the diseased cells, exhibits no other alteration than in being more transparent than in the normal state—this being due, in all likelihood, to the disappearance of a great number of cell-prolongations; in cord, as in bulbus, we observe in it neither foci of *granular disintegration*, nor trace of fibrillary metamorphosis, nor even multiplication of myelocytes. Hence, it cannot be admitted that a process of irritation, or even of simple disintegration, should have first been set up in the connective web of the grey substance, thence to be propagated to the nerve-elements. But one might be tempted to suppose that the starting-point of the alteration of the ganglionic cells should be sought for external to the nerve-centres, that is to say, in the peripheral nerves. This view is not acceptable; it is in formal contradiction with numerous facts, all of which it is needless to recall. We will confine ourselves to pointing out that, according to the researches of M. Vulpian, complete section of the peripheral nerves, and of the hypoglossus in particular, has no marked influence on their origin-cells. Now, it has been seen that, in the case which occupies us, the branches of the different bulbar nerves exhibit very minute histologic alterations at most, though the cell-groups from which they emanate were, for the most part, profoundly diseased. Whence, we think, it is legitimate to conclude that the ganglionic cells have been, in bulbus and in cord, the primary seat of the disease, that the peripheral nerves have been only secondarily affected consecutively on the lesion of the nerve-centres.

If now the attention be directed to the trophic lesions which are presented by the muscular system of the life of relation, we shall be struck by the singular mode of distribution of these fascicle-lesions in different parts of the body. Manifestly, we have not here to deal with a common case of progressive muscular atrophy; the lesions of the primary (ultimate) bundles are, indeed, those which belong

to the latter affection; and we find here sometimes granulo-fatty degeneration, sometimes simple atrophy of the fascicles with proliferation of the sarcolemma-nuclei. But they are not, as it were, concentrated on any muscle or sets of muscles; they are disseminated a little everywhere, and we always found, in the most various regions, diseased fibres intermingled amongst perfectly healthy fibres. They were, however, more affected and more common in certain muscles than in others; but here also is an exceptional fact which deserves to be pointed out: contrary to the rule, the muscles of the extremities, and particularly those of the thenar and hypothenar eminences and of the forearms, are comparatively little affected. *Per contra*, the lesions were relatively great in the deltoid and the trapezius, especially on the left side, in different muscles of the larynx, and lastly, in the tongue. It is important to remark that this mode of distribution could only be revealed by a necroscopic examination, for, during life, the left shoulder was the only part of the body where clinical observation was able to detect partial atrophy of the muscular masses of some little extent. The tongue, especially, it is explicitly stated in the observation, had retained its thickness, its dimensions, its smooth surface, and, in a word, all the appearances of the normal state, although its proper muscles contained a rather large number of degenerate or wasted primary fibres, and that its movements were otherwise remarkably impeded. On the whole, putting aside the information supplied by the partial emaciation of the left shoulder, the generalised progressive muscular atrophy which, in our observation, was found combined with the symptoms of labio-glosso-laryngeal paralysis, might have passed completely unnoticed, had not attention been aroused by the existence of intense fibrillary movements spread over nearly all points of the body.

Confronting the muscular lesions in question with the alterations which the nerve-cells present in the different regions of the cord and bulbus, it will be remembered that, between these and those, an exact correlation exists. In both, the lesions are diffuse, disseminated intimately amongst them. Ought we to believe that, in this case, the alterations of the muscular system have proceeded from the lesion of the nerve-centres along the bulbar and rachidian nerves? The arguments in favour of this opinion have been detailed on several occasions in this volume; we do not think it necessary to reproduce them here anew, hence we propose to admit, as a

probable hypothesis, that such, in fact, has been the pathogenic mode of these morbid phenomena. But this being conceded, do we possess all the elements necessary for the construction of a somewhat satisfactory theory of the affection such as it has shown itself in the case reported? We do not think so; besides, knowing absolutely nothing concerning the nature and origin of the lesion of the nerve-cells, there are many other desiderata yet which we might mention.

We shall only notice one point; it is known that, in our patient, the different movements of the tongue, and especially those connected with the articulation of words and deglutition, were considerably weakened, and that, at the autopsy, we found in the muscles which constitute that organ lesions which were evidently insufficient to account for so marked a paralytic condition. Whence should we deem this motor impotence, independent of the trophic lesion, to be derived? We find nothing to refer to save this same lesion of the nerve-cells, from which we have already derived the nutritive alteration of the muscular fibres, and it is difficult to comprehend by what mechanism this selfsame lesion has been able to produce simultaneously such different effects. Let us remark, in passing, that we cannot suppose the intervention here of some peculiar influence of the great sympathetic, since we have to explain, this time, not the presence of trophic lesions of muscles which are accounted for by the alteration of the hypoglossus-nucleus, but the existence of a muscular paralysis independent of the atrophy, at least in part.¹ This is a serious difficulty, which we have already met with in connection with progressive muscular atrophy and infantile spinal paralysis.² Manifestly, in the present state of our knowledge a definite judgment cannot be pronounced; let us, therefore, content ourselves, at present, with registering the positive data supplied by anatomical examination, and wait until new facts arrive to throw light on these obscure questions.

It has been several times already proposed to connect with a primary lesion of the grey nuclei, situated in the bulbus, the symptomatic groups known under the name of glosso-labio-laryngeal

¹ The integrity of the great cervical sympathetic has, besides, been explicitly mentioned in one report.

² In progressive muscular atrophy, muscular paralysis without atrophy, and atrophy without paralysis, are often found intermingled in the same points; this is a fact which has been properly pointed out by M.M. Roberts ('Reynolds'

paralysis.³ Pathological anatomy comes to-day, to offer decisive support to this hypothesis, which hitherto was based on physiological induction. But, it is not at all certain that all the clinical facts to which this denomination may be given are identical, and acknowledge the same origin. It is easy to foresee, that coarse lesions of the bulbus, such as a tumour, a diffuse swelling, might under certain determined circumstances produce very nearly the same effects as the primary atrophy of the nerve-cells. On the other hand, it is evident that in the cases in which the alteration bears, not only on the original nuclei, but also on the nerve trunks after emerging from the bulbus, should form a category apart. In truth, for want of complete examination of the bulbus, the reality of cases of this kind is not yet sufficiently established. Lastly, the absolute anatomical integrity of the paralysed muscles, several times mentioned by skilful observers seems, in its turn, to suggest an important distinction. I would, however, point out, in connection with this, that in such a case the absence of granulo-fatty alteration of the muscular fibres has, most frequently, been alone distinctly affirmed. Now, we know, by rather numerous examples, that the best characterised progressive muscular atrophy may reach its final term, without the primary fibres losing their cross striæ or showing the least trace of granular fatty degeneration. The multiplication of the sarcolemma-nuclei, and the more or less marked reduction of the diameter of a certain number of primary fibres are then the only muscular alterations which histological examination allows us to remark.

In conclusion, I would request attention to the very remarkable circulation disturbance which, in our patient's case, marked the last days of her life. The pulse beat 130 to 150 times a minute, without the thermometer marking the slightest increase of the central temperature. This disorder of the movements of the heart was accompanied by a quite peculiar feeling of anxiety, of which the word dyspnœa would give but a very imperfect idea. These phe-

System of Medicine,' t. ii, p. 171, 1867), Duménil of Rouen ('Atrophy musculaire graisseuse progressive,' pp. 93 et 108, Rouen, 1867), and more recently Herr Benedikt ('Elektro therapie,' p. 385, Wien, 1868). It is observed in the simplest cases of progressive amyotrophy, where there exists no sign of any lesion of the white columns of the spinal cord.

³ See, amongst others, A. Wachsmith, 'Ueber Progressive Bulbar Paralysis. &c.,' Dorpat, 1854; and 'Centralblatt,' 1864; L. Clarke, 'Researches on the Intimate Structure of the Brain,' 2nd series, 1868, p. 318.

nomena recall those which have frequently been remarked in man, in cases in which the action of the pneumogastric nerves was impeded in consequence of the compression exercised by a tumour of the mediastinum; the alteration of the origin-nuclei of the pneumogastric nerves which the examination of the bulbus has revealed in our case, appears to us to account for those cardiac disorders which have not a little contributed, undoubtedly, to determine the fatal termination.

(Extract from the 'Archives de Physiologie normale et pathologique,' 1870, p. 247.)

VI.

NOTE UPON THE ANATOMICAL STATE OF THE MUSCLES AND SPINAL CORD IN A CASE OF PSEUDO-HYPERTROPHIC PARALYSIS. BY J. M. CHARCOT.

(See Lecture XIV, p. 205.)

SOME months ago, my friend, M. Duchenne (de Boulogne), gave me several anatomical fragments, requesting me to examine them; they were obtained from a young patient, suffering from the affection described under the name of *pseudo-hypertrophic* or *myosclerotic paralysis*, and who had succumbed, some weeks before, in the Hôpital Sainte-Eugénie, in the wards of Dr. Bergeron, in consequence of an intercurrent disease. The clinical history of the little patient in question is well known; it has been traced with great care by Dr. Bergeron, in a communication made to the Société Médicale des Hôpitaux, in 1867.¹ M. Duchenne (de Boulogne) has reproduced it in his memoir on pseudo-hypertrophic muscular paralysis.² A good full-length photograph of the patient, annexed to the communication of M. Bergeron, shows the exaggerated prominence presented by most of the muscular masses in the child in question, and shows perfectly the characteristic attitude which he assumed, when standing erect.³ For all that concerns the clinical history of the case, I refer the reader to the works just quoted, and I wish to confine myself to describing, in the present note, the anatomical facts which I have been able to ascertain, with the assistance of my house surgeon, M. Pierret. Some short remarks concerning the pathological anatomy and physiology of

¹ 'Bulletins et Mémoires de la Société Médicale des Hôpitaux de Paris,' t. iv, 1^{re} série, 1867, p. 157, Communication faite le 24 Mai, avec une photographie.

² Extract from the 'Archives Générales de Médecine,' Nos. de Janvier, 1868 et suivants, p. 19, Obs. xii.

³ See also the figures 3, 4, and 9 of the memoir of M. Duchenne (de Boulogne).

pseudo-hypertrophic paralysis will follow the principal points of the statement and serve as its corollary.

The fragments which I possess had all been hardened in chromic acid; they comprise—1°, different fragments of the deltoid, psoas, pectoral, and sacro-lumbar muscles; 2°, the cervical enlargement of the superior half of the dorsal region of the spinal cord; 3°, various morsels of the sciatic, median, and radial nerves; 4°, a fragment of the muscular wall of the left ventricle.

I.

In the first place I shall mention what concerns the external muscles. As follows from the details of the clinical report, the pectorals and sacro-lumbar muscles had, so to speak, alone escaped the apparent hypertrophy which, at a given moment, had seized upon the greater part of the muscular masses; the same may be said with respect to the psoas, which, on autopsy, were found to be rather reduced in size. The alterations exhibited by these muscles may be considered as representing the first phases of the morbid process; the ultimate phases, on the contrary, could be studied in the deltoid muscles, which were distinguished, during life, by a very marked increase of volume.

The examination of the hardened fragments, with the naked eye, enables us already to observe a first distinction; thus, whilst the fragments of the deltoid exhibit, in the sections, a yellowish colour, having the appearance and consistence of a lardaceous mass—phenomena plainly owing to the interposition of a large quantity of fatty tissue—the psoas, sacro-lumbar, and pectoral muscles, in their turn, present very nearly the appearance of normal muscles, treated under the same conditions by chromic acid, but with an evidently firmer consistence, and a resistance which recalls that of fibrous tissue.

The histological alterations of these muscles consist in this: on transverse sections, what first strikes us, in the psoas, for instance, where the lesion is least, is that the thin laminæ of connective tissue (appurtenances of the *perimysium internum*), which, in the normal state, barely separates the primary muscular fibres and leaves them almost in contact with each other, are here replaced by thick septa, the narrow diameter of which equals, in some parts, or even exceeds, that of the muscular fibres. These septa, as we can make

sure, especially, by the examination of shredded longitudinal sections, are constituted by connective tissue of recent formation, where the laminate fibres, directed chiefly parallel to the long axis of the muscular fibres, are intermingled with embryoplastic nuclei and fusiform cells in considerable number. In other muscles, as the pectoral, and the sacro-lumbar muscles, where the evolution of the alteration appears to be more advanced, the nuclei and the cells have diminished in number or seem to have disappeared, and the septa are almost exclusively formed by bundles of long wavy fibres, disposed parallel to each other, with very distinct and well-marked outlines.

The interposition of adipose cells between these fibrillæ marks a new phase of the process (fig. 35). The fat cells are sparse, at first, isolated, and lost, as it were, in the midst of bundles of fibrillæ; but their number augments, in certain points, in such proportion that they substitute themselves for the fibrils, which in the end completely disappear. This fatty substitution, sketched out already in some parts in the non-hypertrophied muscles, becomes almost

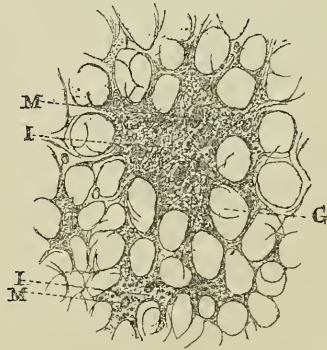


FIG. 35.—*Transverse section of a muscle in pseudo-hypertrophic paralysis (intermediate phase between the first and second period of the process). I, I, islets of connective tissue; M, M, sections of muscular bundles; G, G, adipose cells.*

general in the deltoid, where the augmentation of size was, it is known, well marked. In fact, the microscopic examination of this muscle shows the greater part of the surface of the transverse section to be occupied by adipose cells, almost contiguous throughout, heaped against each other, and made polyhedric by pressure; here and there, in the midst of the adipose tissue, we meet entire islets

composed of several primary muscular fibres (from two to eight, ten, or twelve at most), and completely enveloped with fibrillæ, or isolated fibrillary tracts without muscular fibres; or, lastly, and most rarely, isolated muscular fibres, deprived of their fibrillary envelope, and placed in immediate relation with the cells of the adipose tissue (fig. 36). But, I repeat, everywhere, in the deltoid, is the fatty tissue predominating. The islets composed of fibrillary connective tissue and of primary muscular bundles are only seen here and there, at long intervals, and, in certain parts, they are even altogether deficient; on the contrary, in the pectoral muscles, and in the sacro-lumbar masses, the presence of fatty cells is a rare and accidental fact: in the psoas, where the alteration is seen in its first stage, there are no traces of it.

In short, fatty substitution evidently represents the last phase of the morbid process, and in proportion as it advances the fibrillary tissue of new formation, as well as the muscular bundles, tends to disappear. It is time now to seek out the mode by which this disappearance of muscular fibres takes place; it is already noticeable in the first period, when the interstitial connective tissue begins to

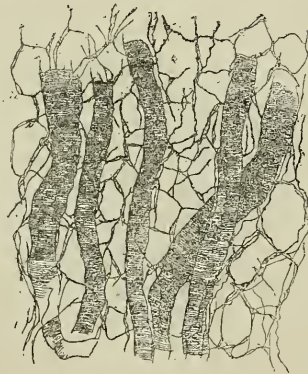

FIG. 36.—*Longitudinal section of a muscle in pseudo-hypertrophic paralysis* (second period of the morbid process). Adipose cells everywhere in contact, and rendered polyhedral by pressure. Isolated muscular fibres, deprived of their fibrillary envelope and placed on immediate relation with the cells of the fatty tissue. The muscular bundles, even the slenderest, have preserved their cross striation.

show hyperplasia, irrespective of any trace of fatty substitution. Thus, in the psoas, on transverse sections, the muscular bundles,

surrounded on all sides by considerably thickened septa of *perimysium internum*, appear at first sight to have preserved nearly all their dimensions and other characters of the normal state; but a less superficial examination soon shows that a good number of these bundles have suffered a more or less marked diminution in diameter; many even are so much wasted that it requires the closest scrutiny to discern them in the substance of the interstitial connective tissue.

The examination of longitudinal sections, and especially of those prepared by dilaceration, completes these data: the greater part of the muscular bundles, even those which have undergone very well-marked atrophy, preserve to the last limits of emaciation most distinct transverse striation. Neither the sarcolemma-sheath, nor the nuclei which it encloses, present any alteration, and, as to the muscular substance, no trace of granulo-fatty degeneration is there observed. Such is the rule; here and there, however, we meet some bundles, few indeed in number, where the cross striæ are absent, whilst a longitudinal striation has become very apparent; other bundles, absolutely devoid of all striation, whether transverse or longitudinal, have a hyaline appearance and are charged with granulations; lastly, there are others,—which are always of the smallest diameter,—the muscular substance of which seems to be broken into fragments in which the transverse striation is still very manifest, and in the interspaces of which more or less numerous clusters of nuclei are accumulated, which distend the sheath of the sarcolemma. But, in short, it is rare that muscular bundles, on the way to destruction, exhibit any one of these modes of alteration. The greater part of them do only present, to the final term, the characters of simple atrophy, without multiplication of nuclei and with persistence of transverse striation.

In the deltoid the muscular bundles are found with the same appearances; only those of them which have preserved their normal diameter are much more rare. Most of these have suffered manifest atrophy; many of them are remarkable for their extreme slenderness.¹ The hyaline state, with fatty granular degeneration, segmentation of the muscular substance with multiplication of the

¹ Measurements give:—1°, for the primary fibres in the psoas muscle, transverse diameter, 0·0429^{mm.}, 0·026^{mm.}, 0·0066^{mm.}, 0·0033^{mm.} (fibres exhibiting the last dimensions are rare); 2°, in the deltoid, 0·03^{mm.}, 0·012^{mm.}, 00·066^{mm.}, 0·0033^{mm.}, and under.

nuclei of the sarcolemma are here, perhaps, more frequent than elsewhere, but it is still simple atrophy which is always supreme. With respect to the pectoral and sacro-lumbar muscles, the lesions of the primary fibres which are there met with hold a medium between the two extremes, and allow the transition to be traced out.

Keeping in mind the results just stated, one might endeavour, we believe, to reconstruct, at least in a most general way, the mode of evolution of muscular alteration proper to pseudo-hypertrophic paralysis. At the commencement, besides the thickening of the walls of the vessels, connective hyperplasia and simple atrophy of a certain number of muscular fibres are the only lesions observed. At this period, fatty substitution is either totally absent, or else it plays an evidently accessory part. This first phase seems to correspond with the first clinical stage, noticed by all observers—a period in which the only appreciable symptoms consist in the more or less marked weakness of certain muscles, which do not as yet exhibit any apparent hypertrophy,¹ or which even sometimes show themselves manifestly atrophied.²

What takes place in the second period of the disease, when the paralysed muscles begin to increase in volume? According to M. Duchenne (de Boulogne) the apparent hypertrophy in question would be the consequence of connective hyperplasia. "It is this," he says, "which produces the augmentation in size of the muscles in direct ratio to the quantity of connective and fibroid interstitial tissue produced in hyperplasia." This opinion is based on the results repeatedly obtained from examination of morsels of muscle extracted, during life, by means of the *emporte-pièce histologique*;³ but it may be questioned whether, in this little operation the islets of connective tissue are not withdrawn in preference by the instrument, which, on the contrary, would find much more difficulty in laying hold of the clusters of adipose cells. It is certain that in cases where fragments of muscles have been removed during life by *excision*, they have always exhibited, to a high degree, the characters of fatty substitution.⁴

¹ Duchenne (de Boulogne), 'Electrisation localisée,' 3^e édit., p. 605.

² Pepper, 'Clinical Lecture on a Case of Progressive Muscular Sclerosis,' Philadelphia, 1871, pp. 14 and 16.

³ Duchenne (de Boulogne), loc. cit., p. 603; Foster, 'The Lancet,' May 8, 1869, p. 630.

⁴ Griesinger and Billroth, Heller and Zenker, Wernich, *vide* Siedel, 'Die Atrophia Musculorum Lipomatosa,' Jena, 1867.

The impression which remains on my mind, after often-repeated examinations of the fragments confided to me, is that hyperplasia of the connective tissue and atrophy of the muscular fibres advance, as it were, with equal steps, the latter showing itself all the more general and marked in proportion as the former is itself more developed; so that the production of connective tissue would be in some sort proportionate to the extent of void left by the atrophy or disappearance of the muscular fibres. It is, however, possible that the connective hyperplasia may sometimes assume the upper hand, and thus produce a certain degree of apparent hypertrophy; but I find it difficult to understand how it could ever explain the often enormous increase in size presented by the muscular masses at a certain epoch of the disease, and I am led to believe that substitution of adipose tissue here plays the predominant part. However this be, I am ready to acknowledge that the question which I have just raised cannot yet receive a definite solution.

In what does the morbid process consist which, in pseudo-hypertrophic paralysis, determines the alteration of the muscular tissue? I am struck, like many others, with the analogies which exist between this alteration and that which, where the viscera are concerned, is generally designated under the name of *cirrhosis*, or again, of *sclerosis*, and I do not see that any serious objections have ever been formulated against this approximation. The circumstance, alone, that invasion of fatty tissue takes place, at a certain epoch of the disease, in a fated manner, at least in some muscles, appears to me to constitute, in the case in point, a really distinctive character, so that the denomination of *myosclerotic paralysis*, proposed by Duchenne (de Boulogne), can only strictly be applied to the first periods of the disease, whilst those of *atrophia musculorum lipomatosa* (Seidel), and of *lipomatosis luxurians* (Heller), generally used by German authors, are appropriate only to advanced periods. But I do not wish to insist further on this point; at present I shall confine myself to the examination which I have made of the spinal cord.

II.

The recent researches relating to the pathological anatomy and physiology of spontaneous amyotrophies have allowed us, as is known, to connect with a lesion of certain well-determined regions

of the spinal cord, a considerable number of these affections. Latterly the opinion has been several times put forth that pseudo-hypertrophic paralysis which, in some respects, approximates to progressive muscular atrophies, is also referable to a spinal source. This hypothesis rests upon no solid foundation, and there even exists, in scientific records, an observation, followed by necroscopy, which tends to completely invalidate it. I here allude to the case presented by H. Eulenburg to the Medical Society of Berlin, in which the autopsy was conducted by Dr. Cohnheim.¹ It is true that, in this case, the spinal cord having been examined in the fresh state, or after imperfect hardening, very delicate lesions—such as atrophy of the motor nerve-cells and sclerosis of the anterior cornua of grey substance—might in strictness have escaped observation. In this respect, our case, on the contrary, leaves nothing to be desired, and it pleads absolutely in the same direction as that of Dr. Cohnheim.

Although we have only had in our hands, a portion of the cord comprising the upper half of the dorsal region, and the entire cervical enlargement, the results which we obtained from our examination are not the less very significant. It must not, in fact, be forgotten that the muscles which receive their nerves from the last-named region of the cord were mostly affected to a high degree, and that the deltoid muscles, amongst others, exhibited in the most distinct manner the characters of hypertrophy from fatty substitution. If, therefore, in this case, the muscular lesions had been connected with spinal lesions, the latter would not have failed to show themselves well marked in the cervical enlargement of the spinal cord.

Our observations have been made on transverse sections coloured with carmine, and figured with great skill by M. Pierret. These sections, also, have been very numerous and were taken from the most various parts of the cervical and dorsal regions. Now, the result has been absolutely negative; throughout we have found the antero-lateral and posterior white columns in a state of perfect integrity; the grey substance which we have made the special object of our investigations did not exhibit any trace of alteration. The anterior cornua were neither atrophied nor deformed; their neuroglia had retained its usual transparency, and the motor nerve-cells,

¹ 'Verhandlungen der Berliner Medicinischen Gesellschaft,' Berlin, 1866, Heft. 2, p. 191.

normal in number, did not exhibit, in their various constituent parts, any deviation from the physiological type. Let us, lastly, add that the spinal roots, both anterior and posterior, appeared also perfectly healthy.

I do not think it necessary to insist further to show the interest which, as regards the question that occupies us, belongs to these necroscopic facts, corroborated as they are by the previous observation of MM. Eulenburg and Cohnheim; if I do not deceive myself, the conclusions to which they naturally lead is, that, according to all probability, *pseudo-hypertrophic paralysis ought to be considered as independent of all appreciable lesion of the spinal cord or nerve-roots.*

An observation recently published in the 'Archiv der Heilkunde,'¹ by H. O. Barth, assistant at the Pathological Institute of Leipzig, seems to be in formal contradiction with the proposition that has just been formulated. This case is, indeed, referred by the author to pseudo-hypertrophic paralysis, and it is followed by an account of the autopsy, made with the greatest care, where the existence of very marked spinal lesions is placed beyond doubt; but I do not believe that this case has the signification given to it,—far from it. The case is that of a man, aged about forty-four, who experienced in 1867, three years before the fatal termination, the first symptoms of motor paralysis in the lower extremities. The paralysis grew progressively worse and spread to the upper extremities. Two years after its beginning, the patient was condemned to remain in bed, and was deprived of power of most movements. As the paralysis of motion advanced, more or less sharp pains and disagreeable formications occupied the limbs; moreover, the paralysed muscles showed great atrophy and, in some points, became the seat of very well-marked fibrillary contractions. Finally, vocal and deglutition-movements grew difficult. During the course of the last months of his life, many of the atrophied muscles, the adductors of the thumb and the muscles of the calf in particular, underwent remarkable increase in size, although motor impotence persisted to the same degree as before. At the autopsy, the muscles of the members generally exhibited, in varying degrees, the characters of fatty substitution. Some of the muscle-fibres presented the alterations of simple atrophy, others and fewer showed those of granulo-

¹ Otto Barth, "Beiträge zur Kenntniss der Atrophia Musculorum Lipomatosa," in 'Archiv der Heilkunde,' Leipzig, 1871, p. 120.

fatty degeneration. There also exists, in several points, in the intervals of these fibres, a certain degree of connective hyperplasia.

An examination of the spinal cord yielded interesting results: the lateral columns were sclerosed, symmetrically, throughout their entire height, from the upper end of the cervical enlargement to the lower extremity of the lumbar region; the anterior cornua of the grey substance were manifestly atrophied; in addition, a good number of the great motor nerve-cells exhibited more or less marked wasting, and many of them had even disappeared. Lastly, it was remarked that a large quantity of adipose tissue had been accumulated under the skin of the limbs, and on the surface of most of the viscera.

It seems to me quite illegitimate to refer the case, of which I have just sketched, in a very brief way, the principal traits, to the classic type of pseudo-hypertrophic paralysis. The relatively advanced age of the patient, the existence of sharp pains, and formication in the limbs, the fibrillary contracture, difficulty of articulation and swallowing supervening at a certain stage of the disease, all these circumstances, amongst others, protest, if need be, against such an assimilation. They very naturally connect themselves, on the contrary, with the morbid type to which I have called attention in my lectures, in which (as took place in M. Barth's case) symmetrical sclerosis of the lateral columns was combined with progressive atrophy of the nerve-cells of the anterior cornua.¹ Unquestionably, the muscular lesions described in the case of Dr. O. Barth's recall in many respects those which are found uniformly noticed in all cases of pseudo-hypertrophic paralysis hitherto published; but this circumstance would not, of itself alone, justify a nosographic approximation. I think I should in reference to this substance make a remark which might appear commonplace, if the fact to which it is applicable did not seem to have been sometimes misunderstood: it is that none of the muscular lesions in question belong peculiarly to pseudo-hypertrophic paralysis, and could not, consequently, suffice to differentiate it. Thus, hypertrophy of the interstitial connective tissue with simple atrophy of the muscular fibres is found, for instance,² after traumatic nerve-lesions, and in

¹ "Deux cas d'atrophie musculaire progressive, avec lésion de la substance grise et des faisceaux antéro-latéraux de la moelle épinière," par MM. Charcot et A. Joffroy ('Archives de Physiologie,' 1869, t. ii, p. 334).

² Mantegazza, 'Gazetta Lomb.,' p. 18, 1867; Erb, "Zur Physiologie und

some cases of spinal infantile paralysis;¹ as to fatty substitution, with or without increase in size of the nuclei, it may take place as an eventual complication in infantile paralysis also,² in progressive muscular atrophy,³ in spinal paralysis of the adult,⁴ and in many other circumstances which would take too long to enumerate here. It is to be remarked that, in such cases, the fatty substitution of the muscles appears to be sometimes connected with a *generalised lipomatosis*, which shows itself particularly, as exemplified by H. Barth's case, by an accumulation of adipose tissue under the skin and in the visceral cavities. Quite recently, Dr. W. Müller has justly insisted on this point, in an interesting collection of observations relating to the pathological anatomy and physiology of the spinal cord.⁵ But, I must separate completely from the author mentioned when, refusing all autonomy to pseudo-hypertrophic paralysis, he maintains that all the cases that have been (artificially, according to him) grouped under this name might critically be referred to some one of the forms of amyotrophy due to atrophy of the motor nerve-cells. Nothing, in my judgment, is less justifiable than this opinion, and the very case which forms the object of the present note would, of itself, be sufficient to show its inanity.

After recognising that the muscular alterations in pseudo-hypertrophic paralysis do not depend on atrophy of the nerve-cells of the anterior cornua, we have reason to inquire whether they should not be correlated to some lesion of the great sympathetic, or the peripheral nerves. With reference to the first point, I can give no information, the great sympathetic not having been amongst the specimens which were at my disposal. As regards the second point, I must declare, after having carefully examined the various fragments, taken from the sciatic, median, and radial nerves, that *Pathologie, Anatomie peripherischer Paralysen*," in 'Deutsch Archiv,' t. iv, 1868.

¹ Volkmann, "Ueber Kinderlahmung," in 'Sammlung Klinischer Vorträge,' Leipzig, 1870; Charcot et Joffroy, 'Archives de Physiologie,' t. iii, 1870, p. 34.

² Laborde, 'De la Paralysie de l'Enfance,' Paris, 1864; Prevost, 'Comptes-rendus et Mémoires de la Société de Biologie,' 1865, t. xvii, p. 215, Paris, 1866; Charcot et Joffroy, loc. cit.; Vulpian, 'Archiv. de Physiologie,' t. iii, 1870, p. 316; W. Müller, 'Beiträge zur pathologischen Anatomie et Physiologie des Menschlichen Rückenmarks,' No. 2, Ein Fall von Umschriebener Muskelatropie mit Interstitieller Lipomatose, Leipzig, 1870.

³ (and) ⁴ Duchenne (de Boulogne), Communicated cases.

⁵ W. Müller, loc. cit.

these nerves have appeared to me to present, in every part, the appearances of the normal state. We have even met, in the substance of the affected muscles, with several nerve-filaments, which seemed to us exempt from alteration, with the exception, however, that in one case, one of these filaments belonging to the psoas muscle displayed, in a thin carmine-coloured section, a remarkable lesion consisting of a very marked hypertrophy of the axis-cylinders. On the whole, we believe that before coming to any decision as to the state of the peripheral nerves in pseudo-hypertrophic paralysis it is necessary to undertake new investigations.

In terminating, I would point out, as a fact worthy of interest, that the muscular wall of the left ventricle of the heart did not, in our case, at all participate in the alterations which were so marked in the muscles of the extremities.

Extract from the 'Archives de physiologie normale et pathologique,' 1871—1872, p. 228.

VII.

ON ATHETOSIS.

IN one of his last lectures at the Salpêtrière,¹ M. Charcot has described the characters which distinguish a variety of *post-hemiplegic hemichorea*, to which Mr. W. Hammond, of New York, has given the name of Athetosis. But whilst Mr. Hammond, who first pointed out these movements, considers them in some sort as constituting a particular morbid state, quite autonomous, M. Charcot considers that they are simply choreiform movements, and that they should be connected, nosographically, with the history of symptomatic chorea, as a simple variety.²

According to Dr. Hammond, *athetosis*³ is characterised by its being impossible for the patients to keep their fingers and toes in the position in which they may be placed, and by their continual movement.

This definition is imperfect, for the following reasons:—1°. It should be added that the movements of the fingers are performed slowly, and that the fingers have a tendency to assume constrained attitudes; 2°. Moreover, the *athetosis* does not always remain limited to the muscles which move the fingers and toes; sometimes, in fact, the entire hand and foot are affected. 3°. Lastly, in the case of one of the patients whom Professor Charcot has shown to his audience, some muscles of the face and neck are stirred by choreiform movements, simultaneously with those of the hand and foot.

The following cases illustrate perfectly the principal characters of athetosis:

CASE I.—Gr—, now aged 32, had convulsions when eight

¹ December, 1876.

² This opinion has already been expressed, in an interesting work, by H. Bernhard, 'Ueber den von Hammond Athetose genannte Symptomencomplex.'

³ 'Ἀθετος, "without a fixed position."

months old, which were followed by paralysis of the left side. From that time until she was six years of age she had epileptic fits every second month. They disappeared between the age of six and nine; then they came on anew, and have persisted ever since.¹

At present she is affected by left hemiplegia, without anæsthesia or contracture, but with choreiform movements confined to the left side of the body, and affecting the face, neck, hand, and foot.

The fingers are constantly in motion; they extend and flex in succession and independently; at other times they separate or approach, whilst, at the same period, the wrist executes various movements of extension, pronation, adduction, and abduction. Gr— cannot keep her fist closed; immediately the fingers extend and move in all directions, the thumb is often caught between the two first fingers. She scarcely makes use of her hand; when she has caught an object she soon drops it in consequence of her fingers opening. When the patient is standing, the foot at first is at rest upon the ground; but, from time to time, the great toe separates, the other toes rise, are flexed, or the heel is raised. These movements take place every three or four minutes.

Let us remark that there is a species of synergy between the movements of the hand and those of the foot; when the patient is told to open the left hand or to close it, the foot is set in movement each time, and the toes are flexed or extended.

Some slight grimaces are noticed in the left half of the *face*; the muscles of the commissures seem especially to act. In the neck, the motor disorder seems to occupy the left platysma myoides and sterno-cleido-mastoideus.

CASE 2.—Maur—, aged 33. At nine months convulsions, followed by paralysis of the left side. Epileptic fits at fourteen.

To-day, M—, in addition to her epileptic fits, exhibits *left hemiplegia*, with *analgesia*, involving the face, trunk, and members, and choreiform movements occupying only the hand and foot of the paralysed side (*post-hemiplegic hemichorea*, variety *athetosis*).

The joints of the left upper extremity are stiff. The hand is flexed upon the forearm. The fingers are unstable, sometimes flexing, sometimes extending. The habitual attitude of the two first fingers seems to be of forced extension. When the patient is desired

¹ For further details, see Raymond, 'Étude anatomique, physiologique, et clinique de l'Hémichorée,' &c., p. 69.

to open her hand, the fingers pass into forced extension, the tips are turned back, and almost immediately the fingers and the hand are flexed. If she tries to flex the thumb she can succeed, but simultaneously, and in spite of herself, the fingers are extended. The large movements of the arm are not jerky.

Foot tends to adduction. The great toe rises and flexes continuously. It is the same with respect to the other toes, and their movements are independent.

If the patient be ordered to close or to open her hand, the foot is at once taken with movements; the heel rises, the toes stir. When observed in bed, the patient's left hand and foot are seen to be nearly constantly stirred by jerking, synergic movements; in order to lessen them, she holds the left hand with the right.

Many times, during lectures previous to those which we summarise, here Professor Charcot has shown the patients, whose history we have briefly related; and, on his side, M. Raymond has published, *in extenso*, in his thesis, an account of the first-mentioned case. Without a doubt these cases, described as belonging to hemichorea, are included in the description of athetosis, as Dr. Hammond has traced it. In fact, in the second case, we find mention made not only of *instability* of the fingers, but also of hemianæsthesia, under an attenuated form, it is true, since there was no analgesia. This coincidence of anæsthesia with athetosis, which has been noticed by Dr. Hammond, is a circumstance which might have been expected. The opinion expressed by Professor Charcot that we have here a simple variety of *post-hemiplegic hemichorea* is, as may be remarked, justified by clinical facts. Between our two patients there is but a difference relating to the extent of the abnormal movements, limited to the hand and foot of the paralysed side in the case of the first patient; in that of the second they, in addition, occupy the corresponding side of the face and neck.

Between the latter patient and another attacked with post-hemiplegique hemichorea, who is also in Professor Charcot's wards, the difference again only relates to the extent, and also to rhythm of the involuntary movements. The few details which we are about to give will make this clear:

CASE 3.—P—, at present aged 19, was seized, when five years old, with *convulsions* which lasted four hours, and were followed

by incomplete paralysis of the left side. The paralysis is stated to have disappeared two months later. At the age of six, *convulsions* lasting five hours, incomplete paralysis of the members of the left side. When seven and a half years old, convulsions for six hours, *complete paralysis*. Since the time when P— began to use her arm choreiform movements have been observed. Three months later, appearance of fits of partial epilepsy.

Present state.—Hemiplegia without contracture, but with hemichorea and diminution of sensibility on the left side.

When the left hand is closed, it is observed that the fingers constantly want to open out, and that movements of supination and pronation are superadded to these movements. If the hand be open, movements of extension of the fingers are observed. In order to obtain a little rest, the patient is obliged to press her hand strongly against some resisting substance.

If the voluntary movements be considered, they are seen to be disorderly, jerking, abrupt. Does the patient raise her hand to her face? She smites it. Made to take a light object, she executes a disproportionate movement with the hand, and, at every moment, threatens to let the object fall. Between these movements and those of chronic chorea, the only dissimilarity consists in the fact that, in the latter, the movements are more rounded, more festooned, as it were.

If, with Professor Charcot, we confront these two patients, P— and Gr— (Cases 3 and 1), we remark at once that the choreiform movements differ only in so far as regards their intensity, their extent, and their rhythm. In Case 1 they are limited to the left half of the face and of the neck, to the hand and foot of the same side; whilst, in Case 3, besides being more abrupt and jerking, they affect all the movements of the members of the left side.

From the foregoing considerations, it follows that these three patients present abnormal motor disorders which are similar, or differ only in so far as they are more or less extensive, more or less rapid, or affect a less or greater number of muscles, according to the patient examined.

Other reasons there are which corroborate this assimilation. In the three patients, the lesion is of the same nature; all three are suffering from unilateral *cerebral atrophy*, consecu

encephalic lesion, dating from childhood; all three are hemiplegic, and subject to fits of partial epilepsy. Thus, we have an analogy in the form of the motor disorders, and an analogy in the conditions of their development; this appears sufficient to show that *athetosis*, is only a variety of *post-hemiplegic hemichorea*.

INDEX.

- A.
ABORTIVE cases of locomotor ataxia, 23
ACHROMATOPSIA, 40
ACTION, distant, 20
ACUTIFY, visual, 40
ALCOHOLISM, chronic (lightning pains in), 28
AMAUROSIS, tabetic, 34, 36, 41
AMBLYOPIA in ataxia, 23, 32, 44
AMYOTROPHIES, spinal; varieties, 128
— chronic, 163
— varieties, 164
— protopathic, 164
— deuteropathic, 165, 180 (*see* SCLEROSIS, LATERAL)
— in locomotor ataxia, 213
— propagation of lesion by internal radicular fibres, 214
— in disseminated sclerosis, 213, 215
— lesions of the great sympathetic, in, 226
— saturnine, 225
— rheumatic, 225
— traumatic, 225
ANATOMY, topographic microscopic, 6, 227
ANÆSTHESIA in ataxia, 14, 237
— in painful paraplegia, 91
— in spinal hemiparaplegia, 106
— in acute central myelitis, 160
— in pachymeningitis, 212
AORTA, aneurisms of, opening into the rachis, 76, 83, 92
ARTHRITIS, dry, of the rachis, 72
ARTHROPATHIES of ataxic patients, 31, 33, 49, 305
— frequency, 50
— epoch of appearance, 50, 53, 58
— clinical facts, 51, 305
— temperature, 52, 53
— forms and symptoms, 54
— diagnosis, differential, 55
— lesions of bones, 56, 307
— lesions of anterior cornua, 60
— consecutive, on lesions of the peripheral nerves, 58
— consecutive, on cerebral hemiplegia, 58.
ARTHROPATHIES, consecutive, on traumatic lesions of the spinal cord, 58
— in spinal hemiplegia, 96, 114
ATAXIA, LOCOMOTOR, progressive, 3
— anomalies, 4
— classic description, 22
— cephalic symptoms, 22, 28, 34, 44
— spinal symptoms, 22
— lightning pains, 23, 25, 306
— incoördination, 23
— paralytic period, 24
— visceral symptoms, 28
— treatment, 61
— luxations, pathological, in, 305
— spontaneous fractures, 307
— summary of symptoms, 236 (*see* ANÆSTHESIA; ARTHROPATHIES; ATROPHY, muscular; CRISES, gastric; PAINS, lightning; TABES dorsalis spasmodic)
ATHETOSIS, 390
ATROPHY, muscular progressive protopathic, 9, 60, 144, 163, 164
— individual, of muscles, 168
— functional disorders, 169
— modes of invasion, 171
— course, duration, causes, 172
— lesions of spinal cord, 173
— lesions of anterior roots and peripheral nerves, 176
— lesions of muscles, 178, 336
— lesions of bones, 313
— pathogeny of, 315
— case, 327
ATROPHY, deuteropathic, 91
— in ataxia, 15
— in hemiparaplegia, 107
— in cerebral hemiplegia, 207
— in acute central myelitis, 159
— in pachymeningitis, 212
— in general spinal paralysis, 216
— in infantile paralysis, 131, 134
— in cervical paraplegia, 109
— consecutive on nerve-lesions, 256
— nervous, progressive, 243
— partial, of brain, 280

- AXIS CYLINDERS of nerve-tubes, tumefaction of, 317
 AURA, motor, 266, 288
 B.
 BANDS, EXTERNAL, of the posterior fascicles of the cord, 15, 27
 BLADDER, contraction of neck of, 97
 — paralysis, 98
 — Budge's theory as to action of nerve-system on functions of, 98
 — disorders of, in compression of cord, 116
 — in *acute spinal paralysis*, 159
 — in *acute myelitis*, 160
 — in *urinary paraplegias*, 257
 BONES, arrest of development of, in infantile paralysis, 132 (*see* ARTHROPATHIES, ATAXIAS)
 BRAIN, 280 (*see* ATROPHY, PARTIAL)
 BROMIDE OF POTASSIUM, 265, 273, 297
 BULBUS RACHIDICUS, 334, 354, 360, 368 (*see* CORD, NERVES, PARALYSIS, glosso-laryngeal; SCLEROSIS)
 C.
 CANCER, vertebral, 84, 88
 CARIES, vertebral, latent, 88, 91
 CAUTERISATION, with actual cauterly, 269
 CELLS, motor nerve- (tumefaction of), 317
 — in myelites, 137, 156, 207 (*see* ATROPHY, muscular; BULBUS CORD, CORNUA)
 CENTRE, genito-spinal, 254
 CEPHALALGIA in syphilitic epilepsy, 289
 CHOREA, common, 279
 — symptomatic, 284 (*see* ATHETOSIS, HEMICHOREA)
 CLAW-HAND, 171
 — in pachymeningitis, 212
 — in lateral amyotrophic sclerosis, 344
 COLUMNS, lateral, development of, 182
 CONCUSSION, cerebral, 119
 CONSANGUINITY, 172
 CONTRACTILITY, ELECTRIC, in saturnine and rheumatic amyotrophies, 225
 — in protopathic muscular atrophy, 170, 197
 — in acute central myelitis, 160
 — in general spinal paralysis, 216
 — in infantile paralysis, 131
 — in paraplegia from compression, 100, 112
 CONTRACTURE, 14, 21, 91, 96, 127, 171
 — in hemichorea, 279, 281
 — in hemiparaplegia, 107
 — in pachymeningitis, 212
 — in infantile paralysis, 127
 — in lateral sclerosis, 127
 — in spasmodic tabes, 238, 244
 CORD, SPINAL, embryonic development of, 181
 — topographic anatomy of 67, 82, 227 (*see* COLUMNS, GOLL, TURCK)
 — elementary affections of, 227
 — hypertrophy of, 165
 — tumours of, 67
 — kystic dilatation of, 69
 — echinococci of, 70
 — glioma of, 68
 — gumma of, 69
 — tubercles of, 69
 — compression of cord, 76
 — transverse myelitis, 78
 — secondary sclerosis, 78
 — lesions of, in cured cases of Pott's disease, 80
 — regeneration of nerve-tubes, 81
 — symptoms of compression of, 81
 — pseudo-neuralgias, 84
 — disorders of motility, 96
 — of sensibility, 99
 — abrupt compression of cord at neck, 121
 — lesions of lumbar enlargement, 121
 — of the cauda equina, 122
 — traumatic lesions, 161
 — state of cord in pseudo-hypertrophic paralysis, 378 (*see* ATAXIA, ATROPHY, BULBUS, CELLS, CORNUA, PARALYSIS GLOSSO-LARYNGEAL, and INFANTILE SCLEROSIS, &c.)
 CORNUA, anterior, of the cord, relations with the radicular nerve-filaments, 16
 — lesions of nerve-cells of, 112, 155
 — after old amputations, 157
 — in protopathic muscular atrophy, 174 (*see* ARTHROPATHIES, ATAXIA, ATROPHY, muscular)
 — posterior, lesions of, 11, 14
 COUGH, in compression of cord, 114
 CRISES, gastric, 29, 44, 115
 — visceral, 28, 48
 CYSTITIS, 252
 D.
 DEFORMATIONS in muscular atrophy, 170
 — in lateral amyotrophic sclerosis, 198 (*see* PARALYSIS, INFANTILE)

- DEGENERATIONS, secondary, 19, 21, 94, 106, 205, 207, 246
- DIPLOPIA, 35
- DISORDERS of genito-urinary organs in ataxia, 28
- DURA MATER, 70, 83
— tumours of, 70, 115 (*see* MENINGES)
- DYSÆSTHESIA, 99, 246
- DYSPHAGIA in compression of the cord, 116
— in glosso-laryngeal paralysis, 364
- DYSPNŒA in compression of the cord, 114
— in glosso-laryngeal paralysis, 364, 366
- E.
- EAR, lesions of, in Ménière's vertigo, 263, 266
- EMBOLISM of the *arteria centralis retinae*, 41
- EPILEPSY in compression of the cord, 116
— partial, 281, 287
— partial, of syphilitic origin, 287
— cephalalgia, 289
— description of fits, 288, 294
— treatment, 290, 293, 298
— spinal, 116, 127, 202, 236, 245
- EPILEPTIC acme, *status epilepticus*, 288
- ESCHARS in spinal hemiplegia, 100
— in lesions of cauda equina, 122
— in central myelitis, 160
— in paraplegias from compression, 107
— in urinary paraplegias, 253, 257
- G.
- GLIOMA, 68, 167
- GLYCOSURIA, with lesion of optic nerves, 41
- GOLL, development of Goll's columns, 180 (*see* SCLEROSIS)
- H.
- HALLUCINATION, motor, 262, 267
- HÆMATOMA, 69, 71, 210
- HÆMATOMYELIA, 69, 128, 161, 322
- HEMIANÆSTHESIA of cerebral origin, 276, 282, 284
— decussated, theory, 103
— hysterical, 105, 264
— spinal, with crossed anæsthesia, 101, 103, 247
- HEMICHOREA, post-hemiplegic, 275, 280
— præ-hemiplegic, 283
- HEMIPARAPLEGIA, spinal, with crossed anæsthesia, 102, 247
- HEMIPLEGIA, CEREBRAL, with contracture, 199
— spasmodic, 280
— spinal, 101
- HÆMORRHAGE, intra-encephalic, 281
- HEREDITY, 172, 196
- HICCUP in spinal paralysis, 116
- HYDROMYELITIS, 166
- HYDROTHERAPY, 297
- HYPERÆSTHESIA, 170, 294 (*see* HEMI-PARAPLEGIA)
- HYPERTROPHY of the cord, 209
- HYPOCHONDRIA, 27, 170
- HYSTERIA, ovarian, 277
- I.
- INCOORDINATION, motor, 23
- INHIBITORY phenomena, 259
- K.
- KYSTS, hydatid, 69, 71, 83
- L.
- LIPOMATOSIS, generalised, 217, 221, 224
— interstitial, 179
— luxuriant, 179, 224
- LUXATIONS, 305 (*see* ATAXIA)
- M.
- MEDIASTINUM, dyspnœa in tumours of, 376
- MENINGES, spinal, 67, 208
— tumours of, 70 (*v.* DURA MATER)
- MENINGITIS of base of brain, 42
— spinal, posterior, 6
- MONOPLÉGIA, transient, of syphilitic origin, 294
- MUSCLES, lesions of, in glosso-laryngeal paralysis, 221, 378
— pseudo-hypertrophic, 368 (*see* AMYOTROPHIES, ATROPHY)
- MYELITIS, central, 127, 154, 159
— consecutive, on diseases of urinary passages, 252, 257
— partial, lightning pains, 28, 252
— spontaneous, 96
— transverse, 78, 94, 245, 253
— from compression, 97, 235 (*see* CORD, SPINAL)
— tumefaction of motor nerve-cells and of axis cylinders in certain cases of, 317 (*see* ARTHROPATHIES)
- MYOPATHIES, spinal, 125
- N.
- NEPHRITIS, 252
- NERVES, lesions consecutive on section of, 158

- NERVES, bulbar lesions of, 34 (*see* AMYOTROPHIES, PARALYSIS)
 — cerebral, atrophy of, 6, 34
 — optic, atrophy of, 38
 — grey induration of, 39
 — atrophy of optic papilla, 35
 — diagnosis, 39 (*see* NEURITIS)
 — phrenic, 335
 — peripheral, lesions of, 53, 219, 221, 335
 — sciatic, avulsion of, 215
 NEURITIS of optic nerves, 35, 41
 — parenchymatous, 38
 — of sciatic nerve in urinary paraplegias, 260
 NEUROGLIA, 138, 142, 338, 352, 360, 370
 NEURO-RETINITIS, 41
 NUTRITION, disorders of, in paraplegias from compression (*see* AMYOTROPHIES, MUSCLES, &c.)
- O.
- OBJECT-LESSONS, in amyotrophies, 275
 OSSEOUS SYSTEM, 132 (*see* BONES)
- P.
- PACHYMENINGITIS, 71
 — caseous, 73, 94, 109
 — cervical hypertrophic, 92, 165, 209, 212
 — gummatous, 299
 PAIN, 23, 197; boring, 25; lancinating, 25; constrictive, 26; general characters, 26; anatomical substratum, 27; vesical and urethral, 28, 48; rectal, 29, 48
 PARALYSIS agitans, 284
 — from compression, 169
 — general progressive, lightning pains, 27
 — lesions of optic papilla, 34
 — general spinal, gastric crises, 29, 128, 215
 — glosso-laryngeal, 128, 201, 363
 — lesions of muscles, 367, 368
 — of motor nerve-cells, 126, 370
 — pseudo-hypertrophic, 221
 — anatomical state of muscles, 378
 — spinal, acute, of adults, 144
 — spinal, acute, of children, 129, 156
 — modes of invasion, 129
 — chilling of limbs, 133
 — deformations, 133
 — lesions of muscles, 134
 — lesions of cord, 137
 PARAPLEGIA, alcoholic, 23
 — cervical, 108, 199
 — of cancerous patients, 74, 89
 PARAPLEGIA from compression, 65
 — consecutive, on intestinal lesions, 259
 — consecutive, on uterine lesions, 260
 — reflex, 257
 — saturnine, 225
 — urinary, 250
 PEMPHIGUS, 213
 PROLONGATIONS, nerve, 19
 — protoplasmic, 19
 PSEUDO-NEURALGIAS, 76
 — in cervical paralysis, 109
 PSORIASIS, palmar, syphilitic, 292
 PULSE, retardation and frequency of, in gastric crises, 30, 49
 — frequency in ataxia, 49
 — in glosso-laryngeal paralysis, 366
 — retardation in lesions of cervical cord, 108, 117
 — permanent slow, 118
 — probable lesions of bulbos, 118
 — in lateral sclerosis, 357 (*see* RACHIS)
 PUPILS, 113
 PYELO-NEPHRITIS, 252
 PYRAMIDS, anterior, sclerosis of, 355 (*see* CORD, SCLEROSIS)
- Q.
- QUIVERING, FIBRILLARY, 170
- R.
- RACHIS, abscess of cellular tissue of, 71
 — Pott's disease of, 72
 — cancer of, 74
 — hydatid kysts of, 71
 — narrowing of,—with slow pulse and epilepsy, 71, 116, 117, 120 (*see* ARTHRITIS)
 ROOTS, anterior, of nerve, 347, 351, 359
 — posterior, 5, 83, 347, 351
 RAMOLLISSEMENT of brain, 281
 RECTUM, disorders of, in compression of cord, 29, 48 (*see* PAINS)
 REFLEX, exaltation of phenomena, 111, 127, 130
 RENAL disorders, 252 (*see* PARAPLEGIAS, urinary)
 RETINO-CHOROIDITIS, syphilitic, 41
 RETRECISSEMENT of urethra, 252
- S.
- SARCOMA, angiolithic, 70
 SATYRIASIS, 48
 SCLEROSIS, 7, 341
 — of external bands, 11, 12, 13, 27
 — of Goll's columns, 10, 11, 27
 — of lateral columns, 7, 21, 139, 180
 — lateral amyotrophic, 167, 180, 341
 — lesions of lateral columns, 180

SCLEROSIS of grey substance, 167, 353
 — of anterior roots, 177
 — of peripheral nerves, 177
 — of muscles, 178, 190, 349
 — symptoms, 192
 — evolution, 197
 — causes, 196
 — atrophy, *en masse*, 197
 — rigidity, 200
 — bulbar phenomena, 201, 341, 355
 — pathological physiology, 203
 — diagnosis from spasmodic tabes, 235, 247
 — two cases, 341
 — *disseminated*, 7, 27, 247
 — lightning pains, 24, 27, 170, 197, 248
 — of *posterior columns*, 3
 — by extension of lateral sclerosis, 13
SENSATIONS, retardation in transmission of, 99
 — associated, 100
STEATOSIS, physiological, 184
SULPHATE OF QUININE, 272, 274.
SYMPATHETIC, lesions of great, 226, 388
SYMPTOMS, recurrent or retrograde, 19
SYPHILIS, 286 (*see* CORD, EPILEPSY, MONOPLÉGIA, PSORIASIS, RETINOCHOROÏDITIS)
SYRINGOMYELIA, 166
 T.
TABES DORSALIS, 234
 — spasmodic, 233, 245
 — comparison with *ataxic tabes*, 235
 — gait, 238
 — causes, 243
 — diagnosis, 244, 248
 — course, 243
 — duration, 243
 — seat, 242
 — treatment, 243
 — trepidation, 236, 240

TABETIC symptoms, 3, 5
TEMPERATURE, gastric crises, 30
 — lightning pains, 52
 — arthropathies, 52, 53
 — spinal hemiparaplegia, 103
 — acute spinal paralysis of adults, 147
 — glosso-laryngeal paralysis, 366, 376
TENESMUS, 29, 48
TEPHRO-MYELITIS, acute parenchymatous, 158
 — chronic, 173
TREMBLING, senile, 284
TREPIDATION in transverse myelitis, 245
 — of hemiplegic patients, 236 (*see* TABES DORSALIS)
TUBERCLES of vertebræ, 281 (*see* CORD)
TUMOURS, cerebral, (*see* CORD, MENINGES)
TURCK, development of columns of, 181

U.

URETHRA, URINE, UTERUS (*see* PARAPLEGIAS, RETRECISSEMENT, DISORDERS)

V.

VESSELS, lesions, in lateral sclerosis, 331
VERTIGO, epileptic, 265
 — gastric, 265
 — of Ménière, 261
VOMITING in ataxia (*see* CRISES, GASTRIC)
 — in Ménière's vertigo, 262, 269

Z.

ZONA, 91, 151
ZONES, radicular, anterior, posterior, 181, 182, 183

PLATE I¹, VOL. I.

DISSEMINATED SCLEROSIS (ENCEPHALON).

FIG. 1.—*Base of the brain.*

- a. Patches of sclerosis disseminated along the olfactory nerves.
- b. Islets of sclerosis along the optic nerves.
- b'. Healthy portion of one of the optic nerves.
- c. Islets of sclerosis on the left crus cerebri.
- d. Patches of sclerosis disseminated over the protuberantia, some being superficial, others deep-seated; surface somewhat depressed at the patches. The nerves emerging from the protuberantia appear healthy.
- e. Patches of sclerosis irregularly distributed over different parts of the bulbus rachidicus and medulla oblongata—*anterior pyramids (especially the right) olivary body, antero-lateral column.*
- e'. Healthy portions of the medulla oblongata.
- f. The terminal transverse section, showing how deeply the sclerous lesion has penetrated the substance of the cord at this level, and the irregularity of its distribution.
- f'. Some healthy remnants. The nerves emerging from the bulbus appear healthy.

FIG. 2.—*Horizontal section of the cerebellum, made so that the two parts thus symmetrically divided may be readily folded together.*

- x. y. Intersection line of the horizontal and vertical planes, formed by the section.
- a. Patches of sclerosis disseminated in the white substance.
- b. Sclerous patch invading the corpus rhomboideum.
- c. Patches of sclerosis which have been divided almost symmetrically in two.
- d. Blood-vessels plainly visible in the midst of the sclerous nodules.
- e (*rectè f*). Blood-vessels in the white substance becoming more evident on exposure of the section to the atmosphere. Scattered red dots, very plainly marked.

FIG. 3.—*Portion of base of the brain.*

- a. Olfactory nerves apparently healthy.
- b. Islets of sclerosis in the optic nerves.
- c. Islets of sclerosis in the crura cerebri.
- d. Patches of sclerosis, disseminated over different parts of the protuberantia, some superficial, others deep-seated. Surface slightly depressed at these points. The nerves emerging from the pons appear healthy.
- e. Patches and islets of sclerosis irregularly distributed over different parts of the bulbus rachidicus and medulla oblongata,—*anterior pyramids (completely invaded), olivary bodies (incompletely).*
- f. The terminal section displays the depth to which the sclerous lesion has penetrated the cord itself, and the irregularity of the induration. The nerves emerging from the bulbus appear healthy.
- g. Sclerosis beginning in the constituent tissue of the posterior locus perforatus.

¹ This and the three succeeding plates have been taken from the Note (already quoted), by M. Henri Liouville, Director of the Laboratory, at the Hôtel Dieu.

Fig. 1

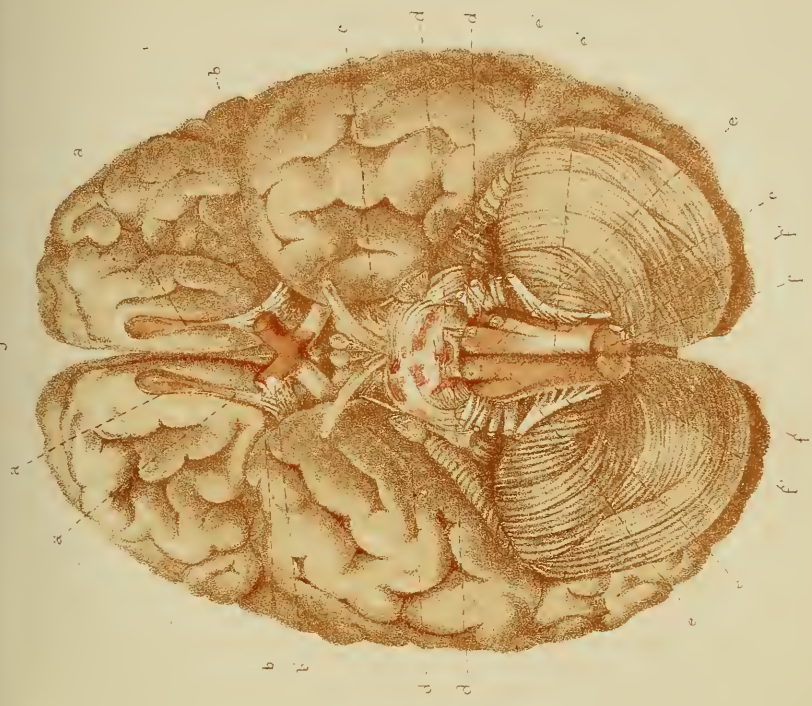

Fig. 3

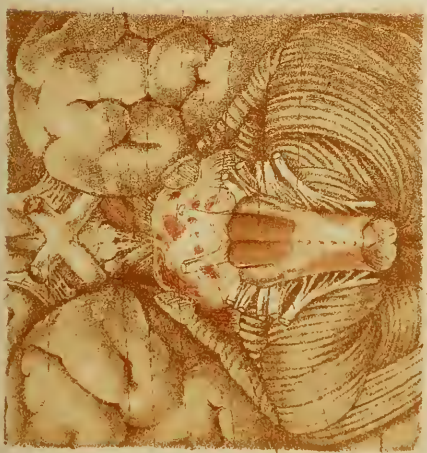


Fig. 2



PLATE II, VOL. I.

DISSEMINATED SCLEROSIS (CEREBRUM).

FIG. 1.—*Horizontal section of the cerebrum, displaying the islets of sclerosis in different regions (both of white substance and grey substance).*

- a. Patches and islets of sclerosis in the anterior regions (anterior commissure, part adjacent to third ventricle).
- b. Sclerous patches invading the anterior parts of the margin of the lateral ventricles (ventricular patches).
- c. Extension of sclerous islets to the posterior extremities of the lateral ventricles (ventricular patches).
- d. Islets of sclerosis, irregularly disseminated in the white substance of the posterior cerebral regions; some of them are very deep-seated.
- e. Blood-vessels plainly visible in the midst of the zones of sclerosis.
- f. Blood-vessels in the apparently healthy white substance becoming more and more evident on exposure of the section to the air.

FIG. 2.—*Another horizontal section of the same cerebrum, displaying the islets of sclerosis in other regions (both of white and grey substances).*

- a. Patches and islets of sclerosis in the anterior regions (anterior commissure).
- b. Sclerous patches in the anterior parts of the lateral ventricles.
- c. Patches of sclerosis in the grey substance of the intra-ventricular nucleus of the right corpus striatum. (They are multiple, divided by healthy spaces; some are deep-seated).
- d. Extension of the sclerotic islets to the posterior extremities of the lateral ventricles.
- d. Islets of sclerosis disseminated irregularly through the white substance of the posterior cerebral regions. Some are very deep.
- e. Blood-vessels, in apparently healthy parts of the white substance, becoming more and more evident on exposure of the section to the atmosphere. (Very marked dotting.)

Fig. 2.

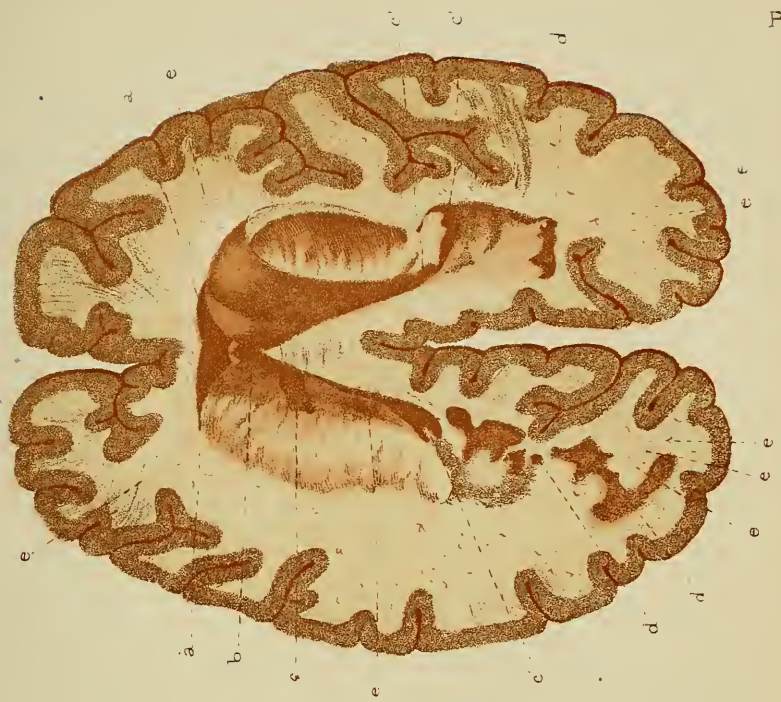

Fig. 1.

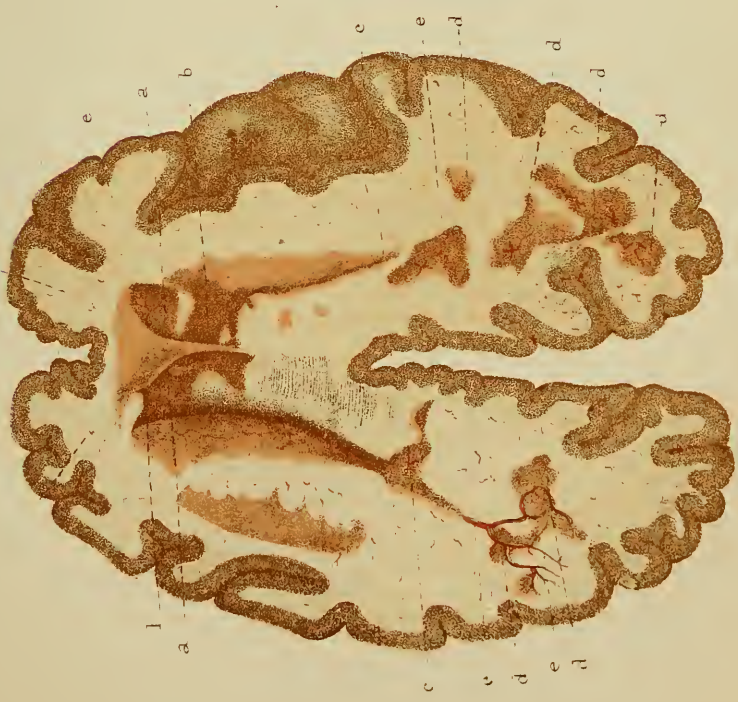

PLATE III, VOL. I.

DISSEMINATED SCLEROSIS (SPINAL CORD).

FIG. 1.—*Posterior aspect of the spinal cord (the dura mater is divided and thrown back at either side).*

- s. Patches and islets of sclerosis, irregularly disseminated, various in form and dimensions, irregular, isolated or partially united by connections visible on the surface. They predominate here, especially in the dorsal region.
- v. Very marked meningeal (pia mater) vascularisation, which prevents the special vascularisation of the sclerotic patches from being discerned.

FIG. 2.—*Anterior aspect of the spinal cord (the dura mater, divided from top to bottom, is thrown back at either side).*

- s. Patches and islets of sclerosis, irregularly disseminated, with unsymmetrical borders; isolated or united by connections visible on the surface.
- v. Meningeal (pia mater) vascularisation, predominating and preventing the special vascularisation of the sclerotic zones from being discerned.

FIG. 3.—*Horizontal sections taken from different levels of the spinal cord and displaying, in every region, the depth of the sclerotic islets, their unequal distribution, and the irregularity of their disposition, both in the white substance where they predominate, and in the grey substance.*

All these sections represent the fresh and unprepared condition of the cord. They are seen from above, the cord being vertical.

- a. Anterior margin.
- p. Posterior margin.
- s. Islets of sclerosis.

The sclerous patches are represented with their natural hue, which contrasts so plainly with the white substance and even with the grey central substance.

No. 1.—Superior portion of the cervical region immediately beneath the bulbus rachidicus.

„ 2.—Middle portion of cervical enlargement.

„ 3.—Inferior portion of cervical enlargement.

„ 4.—Superior portion of dorsal region.

„ 5.—Two centimètres (= 0·78 inch) lower, superior dorsal region.

„ 6.—One and a half centimètres (= 0·58 inch) lower, superior dorsal region.

„ 7.—Two centimètres lower, junction of the superior third with the middle third of spinal cord.

„ 8.—One centimètre and a half lower, dorsal region.

„ 9.—One centimètre and a half lower.

„ 10.—Two centimètres lower, middle of dorsal region.

„ 11.—One centimètre (= 0·39 inch) lower.

„ 12.—One centimètre and a half lower.

„ 13.—Three centimètres (= 1·18 inch) lower.

„ 14.—Superior portion of dorso-lumbar enlargement.

„ 15.—Middle of dorso-lumbar enlargement.

„ 16 and 17.—Terminal cone.

Posterior aspect.

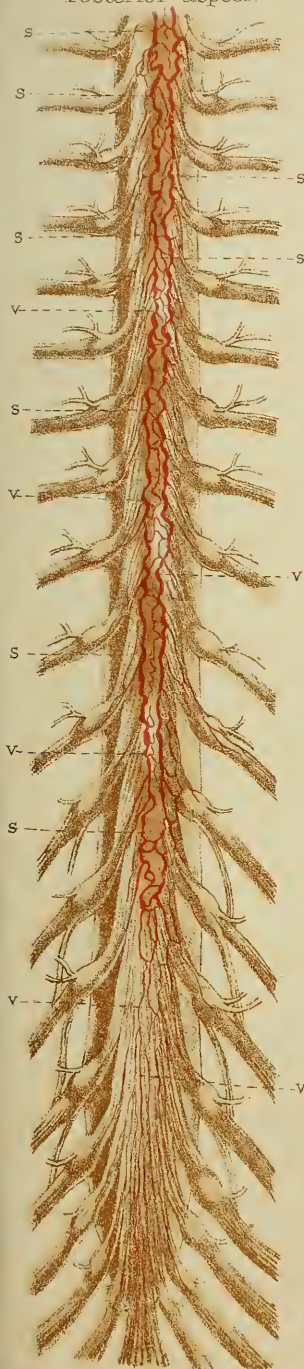


Fig. 1.

G. Peitner ad nat. del.

Anterior aspect.

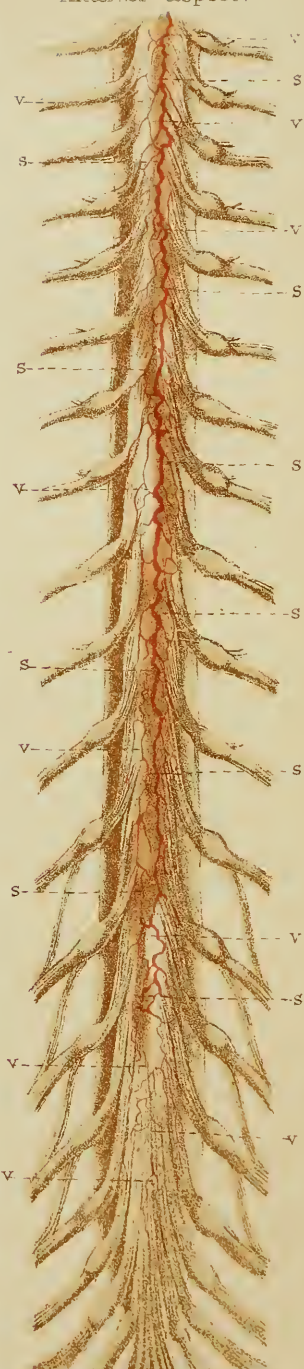


Fig. 2.

West Newman & Co. chrom. lith.



Fig. 3.

PLATE IV, VOL. I.

DISSEMINATED SCLEROSIS (SPINAL CORD).

FIG. 1.—*Posterior aspect of the spinal cord (the divided dura mater is thrown back at either side).*

- c. Patches of sclerosis, disseminated irregularly.
- v. Meningeal (pia mater) vascularisation, predominating and preventing the vascularity of the sclerotic patches from being discerned.

FIG. 2.—*Anterior aspect of the spinal cord (the divided dura mater is thrown back at either side).*

- s. Patches and islets of sclerosis, disseminated irregularly.
- v. Meningeal (pia mater) vascularisation.

FIG. 3.—*Horizontal sections of the cord, taken from different levels, and displaying in every region the depth of the sclerotic islets, and their unequal and irregular distribution, both in the columns of the white substance, where they predominate, and in the grey substance.*

(All these sections were taken from the fresh unprepared cord.)

- a. Anterior margin.
- b. Posterior margin.
- s. Sclerosis.

(The sclerosed portions are represented in their natural tint, which contrasts plainly with the white substance, and even with the central grey substance.)

- No. 1.—Superior portion of cervical enlargement.
- „ 2.—One centimètre and a half (= 0·58 inch) lower.
- „ 3.—Two centimètres (= 0·78 inch) lower (end of cervical enlargement).
- „ 4.—Two centimètres lower (superior portion of dorsal region).
- „ 5.—One centimètre and a half lower.
- „ 6.—Two centimètres lower.
- „ 7.—Three centimètres (= 1·18 inch) lower.
- „ 8.—One centimètre and a half lower.
- „ 9.—Two centimètres lower.
- „ 10.—A little more than one centimètre (0·39 inch) lower; the cord here is healthy, or nearly so.
- „ 11.—One centimètre above the dorso-lumbar enlargement.
- „ 12.—Middle of the dorso-lumbar enlargement.
- „ 13.—A little below the beginning of the terminal cone.
- „ 14.—Filum terminale, completely invaded by sclerosis.

Posterior aspect

Anterior aspect

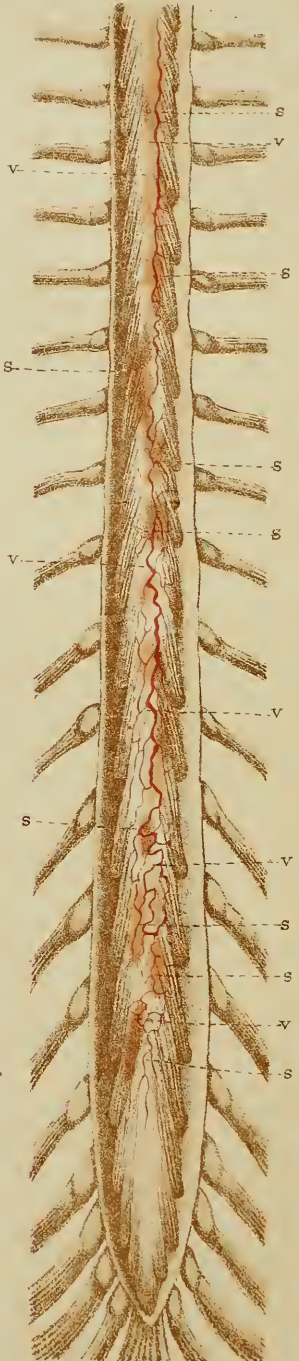
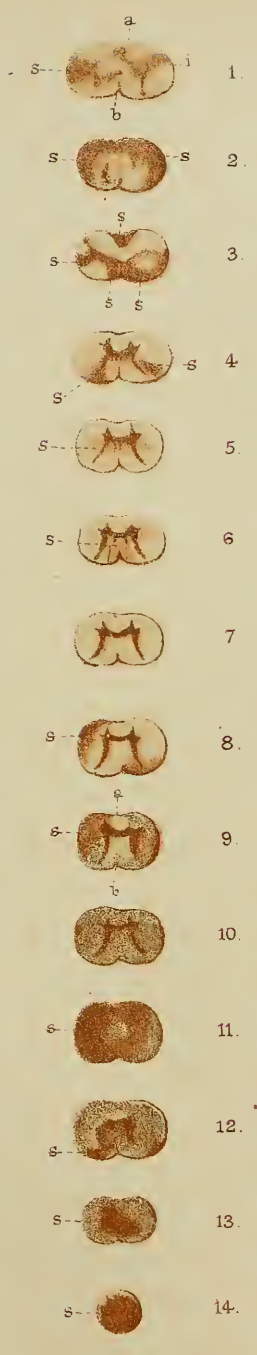
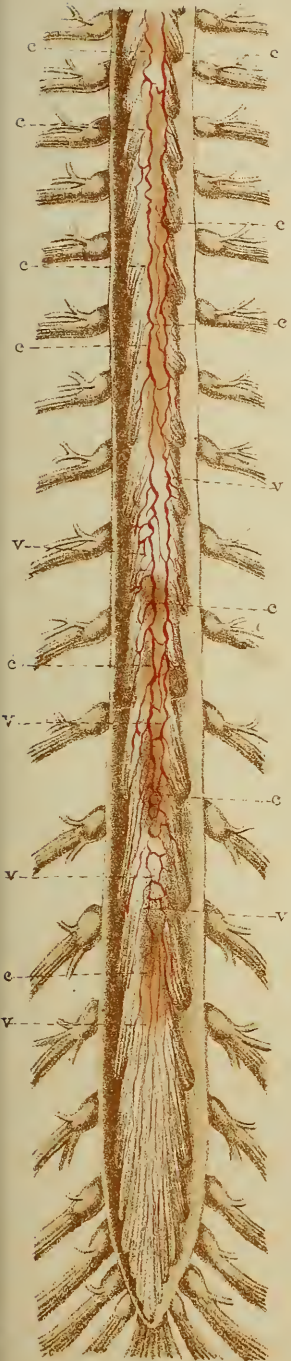


Fig. 1.

Fig. 2.

Fig. 3.

Peltier ad nat. doi

West Newman & Co chro lith

PLATE V, VOL. I.

HYSTERICAL ISCHURIA.

The *blue line* indicates the quantity of urine passed in the twenty-four hours, and the *red line* the amount of vomited matter. [The daily average is given at foot of the Table.]

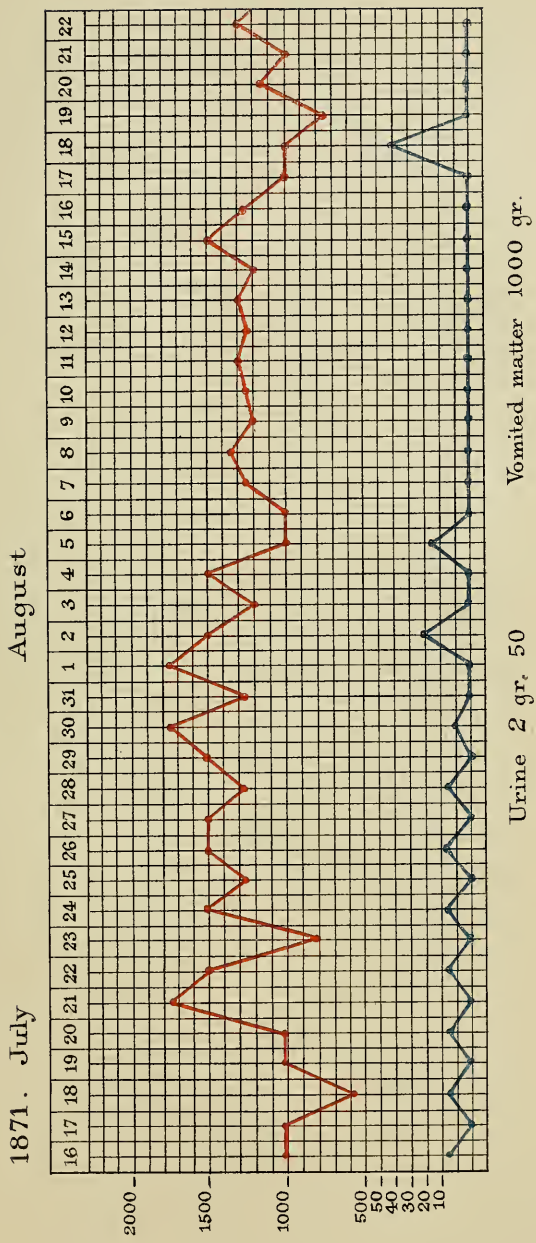


PLATE VI, VOL. I.

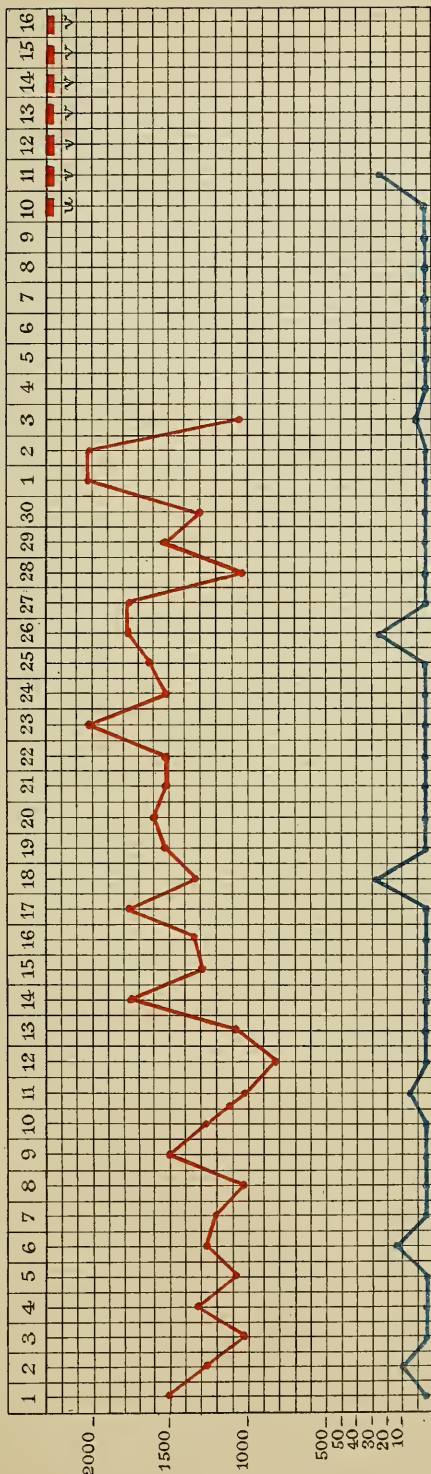
HYSTERICAL ISCHURIA.

The *blue line* indicates the quantity of urine passed in the twenty-four hours, and the *red line* that of the vomited matter.

The small *red squares*, placed immediately beneath certain dates, denote the days of analysis.

[The daily average is given at foot of the Table.]

1871. September October



Urine of the 10. October = 22^{cc} Urea = 0. gr. 179.
 Vomited matter from 11th to 18th daily mean, Urea = 3 gr.

Analysis of Urine (u.) and of vomited matter (v)

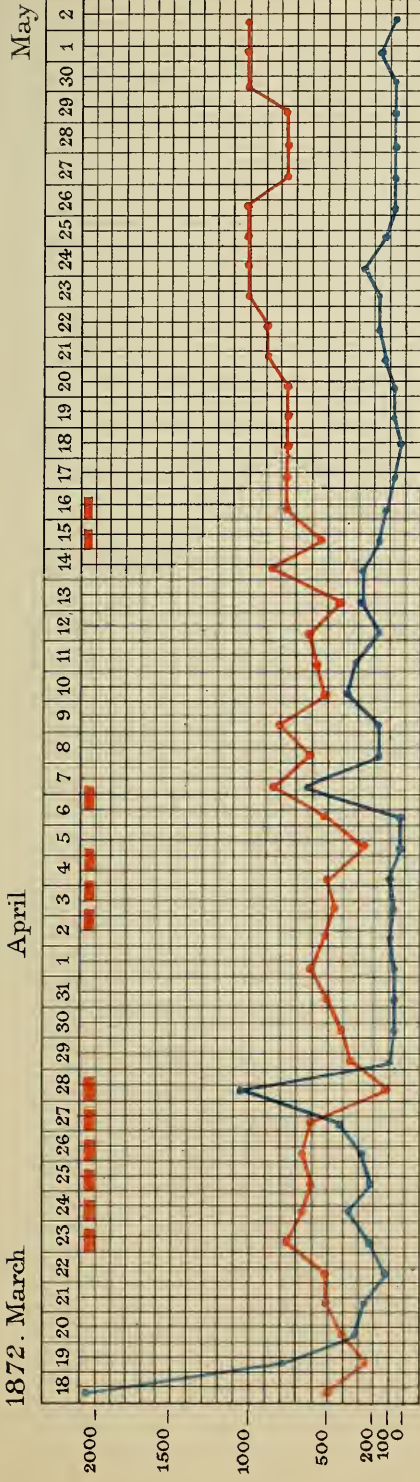
PLATE VII, VOL. I.

HYSTERICAL ISCHURIA.

The *blue line* indicates the quantity of urine passed in the twenty-four hours, and the *red line* that of the vomited matter.

The small *red squares*, placed immediately beneath certain dates, denote the days of analysis.

[The daily average is given at foot of the Table.]



12 days Analysis

Urine daily mean	206 cc	in 1000 gr.	15 gr. of Urea															
Vomited matter	362 cc	in	30 d.															
Urea in	<table border="0"> <tr> <td>{</td> <td>Urine</td> <td>.....</td> <td>3 gr.</td> <td>095</td> </tr> <tr> <td>{</td> <td>Vomited matter</td> <td>2 "</td> <td>138</td> <td></td> </tr> <tr> <td></td> <td></td> <td>5 "</td> <td>133</td> <td></td> </tr> </table>			{	Urine	3 gr.	095	{	Vomited matter	2 "	138				5 "	133	
{	Urine	3 gr.	095														
{	Vomited matter	2 "	138															
		5 "	133															

PLATE I, VOL. II.

SCLEROSIS OF THE POSTERIOR COLUMNS.

FIG. 1 (left side).—*Transverse section of the spinal cord at the sixth dorsal vertebra.*

a, a. Small nodules of sclerosis, situated in the external ribands of the posterior columns.

b. Sclerosis of the intermediate column.

FIG. 1 (right side).—*Transverse section of the cord in the cervical region.*

a, a. External ribands of the posterior columns, not exhibiting any trace of sclérosis.

FIG. 2 (left side).—*Transverse section of the cord in the cervical region.*

The external ribands, *a, a*, the median column, *b*, the posterior cornua, including the point of emergence of the posterior roots, *c*, are wholly invaded by sclerosis.

FIG. 2 (right side).—*Section of the dorsal region of the cord.*

The sclerosis has invaded the same parts as in the cervical enlargement.

FIG. 3 (left side).—*Transverse section of the cord in the inferior portion of the dorsal region.*

a, a. Islets of sclerosis, situated in the external ribands of the posterior columns and connected with the emergence points of the posterior roots, *c*.

b. Small sclerous islet, situated immediately behind the posterior commissure.

FIG. 3 (right side).—*Transverse section of the cord in the middle of the cervical region.*

a, a. External ribands invaded by sclerosis.

b. Median column remaining intact.

Fig. 1.

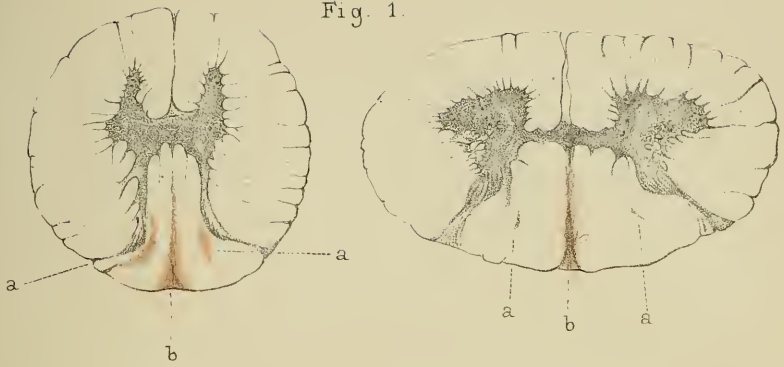


Fig. 2.

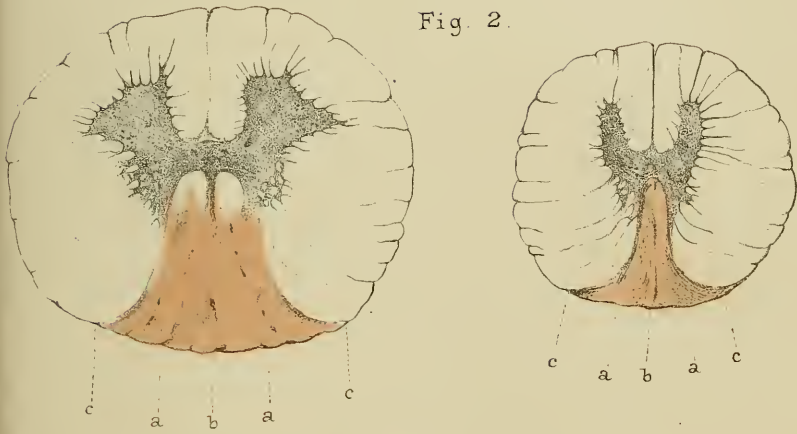


Fig. 3.

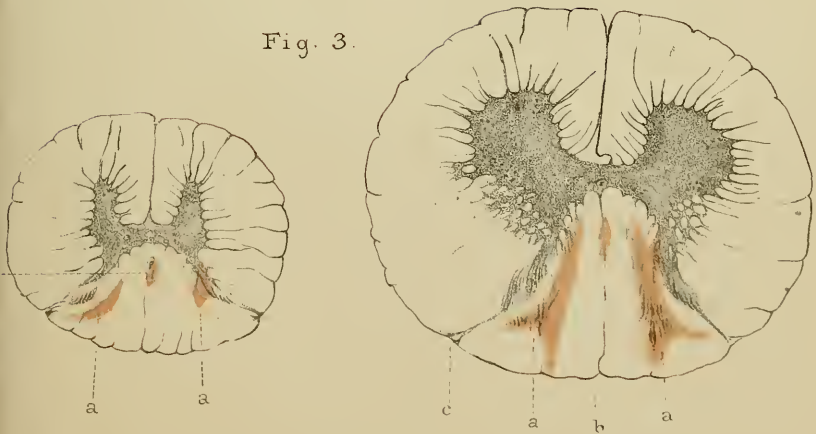


PLATE II, VOL. II.

POTT'S DISEASE; PARAPLEGIA.

FIG. 1.—*White substance of the cord at the compressed part in a completely paraplegic subject.*

- a.* Trabeculæ of sclerosis.
- b.* Nuclei disseminated in the sclerous tissue.
- c.* Section of a vessel whose sheath is continuous with the sclerous tissue.
- d.* Altered nerve-tubes.
- e.* Schwann's sheath, filled with granular corpuscles, *f.*
- g.* Nerve-tubes, which have undergone considerable dilatation and deformation.
- h.* Axis-cylinder, driven back on the lateral parts.

FIG. 2.—*White substance of the cord in a subject who had been cured of paraplegia, and who died of an intercurrent disorder.*

- a.* Sclerous tissue.
- b. c.* Regenerated nerve-tubes: some, *b*, are of the normal size; others, *c*, are very much smaller.

FIG. 3.—*External pachymeningitis: longitudinal section of dura mater commencing to thicken.*

- a.* Healthy internal portion.
- b.* Internal portion presenting clusters of nuclei in the intervals of the fibre fascicles.
- d.* Section of vessel.
- e.* Section of vegetating tissue.
- f.* Elements of new formation: nuclei, fusiform cells and corpuscles.
- g.* Looped or wavy capillaries.
- h.* Stratum devoid of vessels, and formed of caseous elements.

Fig. 1

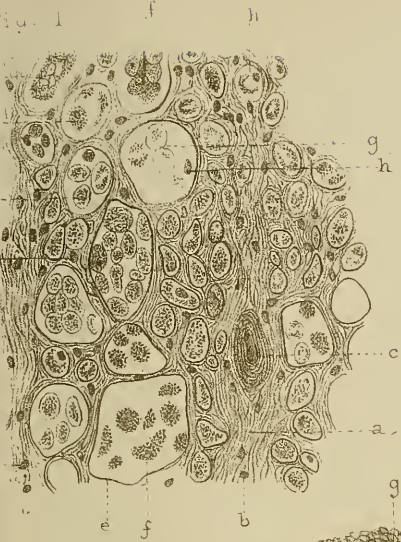


Fig. 2

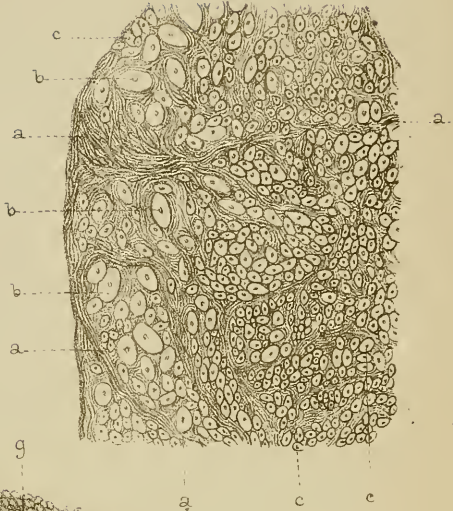


Fig. 3

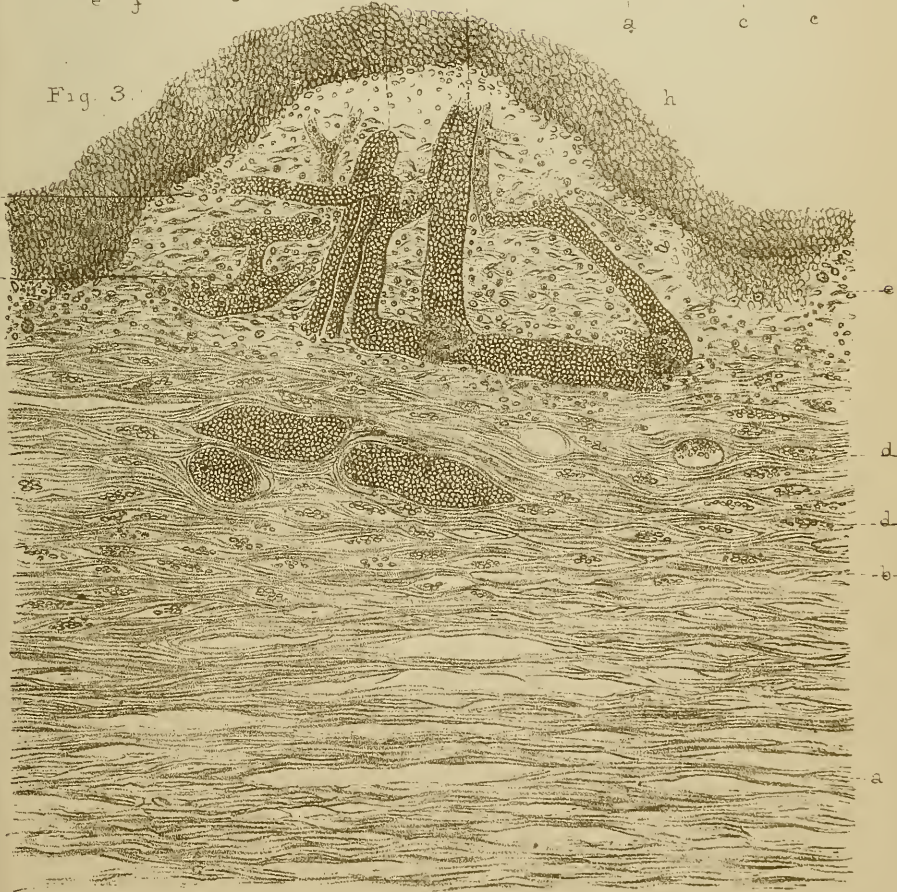


PLATE III, VOL. II.

POTT'S DISEASE; PARAPLEGIA.

FIG. 1.—*Examination of cord in successive sections in a case of dorsal Pott's disease. Secondary degenerations.*

- d.* Compressed point.
- d'*. Same, more highly magnified.
- c.* Dorsal region. Lateral and posterior sclerosis.
- b.* Inferior cervical region. Sclerosis confined to Goll's columns.
- a.* Cervical enlargement, *id.*
- e.* Inferior dorsal region. Diffuse sclerosis of lateral columns.
- f.* Lumbar region.
- g.* Lumbar enlargement.

FIG. 2.—*Section in the cervical region in a case of dorsal Pott's disease. Annular sclerosis, especially manifest towards the posterior roots.*

Fig. 1.

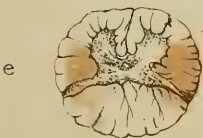
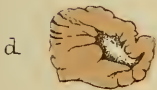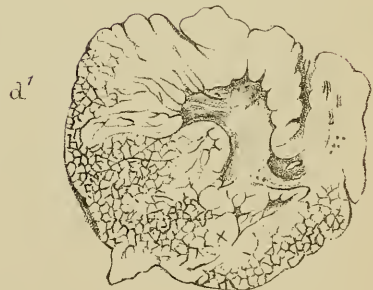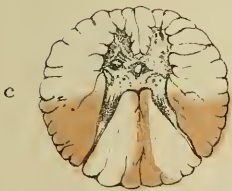
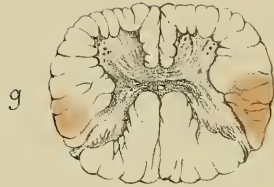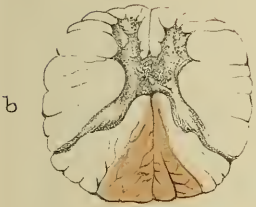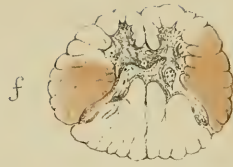
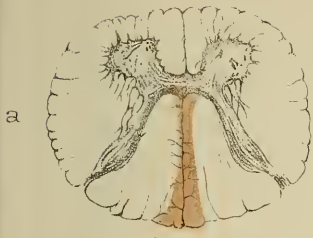


Fig. 2.

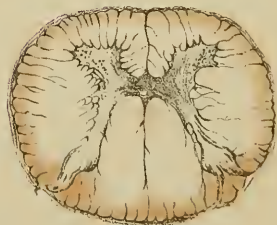

PLATE IV, VOL. II.

SYMMETRICAL SCLEROSIS OF THE ANTERO-LATERAL
COLUMNS.

FIG. 1. *Transverse section of the bulbus rachidicus on a level with the decussation of the pyramids.*

a, a. Reticulated formation of Deiters and lateral columns.

b, b. Anterior pyramids.

c, c. Anterior cornua of grey substance.

e. Decussation of the pyramids.

p, p. Posterior cornua.

FIG. 2. *Transverse section of the spinal cord in the upper part of the cervical enlargement.*

a, a. Lateral columns.

b, b. Anterior columns.

c, c. Anterior cornua.

p, p. Posterior cornua.

FIG. 3. *Transverse section of the spinal cord in the lower part of the cervical region.*

a, a, c, c, p, p. As in the preceding figure.

f, f. Foci of disintegration occupying different points of the anterior grey substance.

FIG. 4. *Represents the different phases of pigmentary degeneration of the cell of anterior cornua.*

a. Normal cell.

b, c, d. Degenerated cells.

Fig. 2.

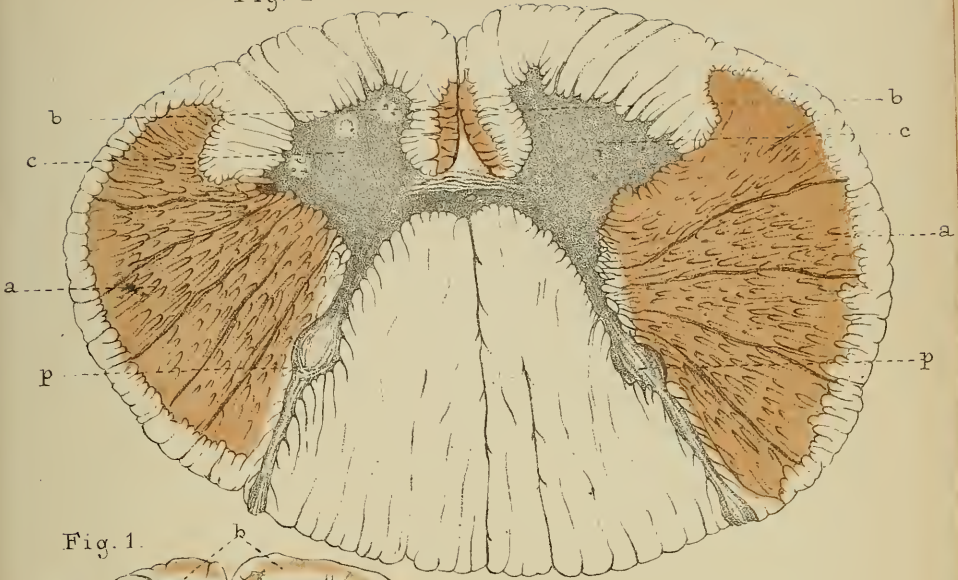


Fig. 1.

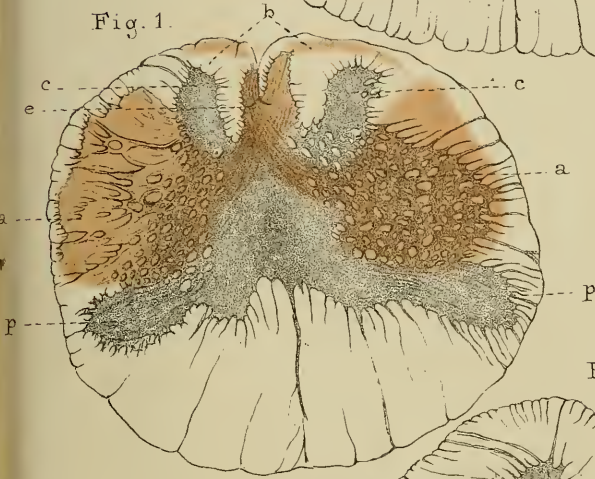


Fig. 4.

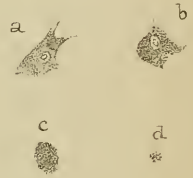


Fig. 3.

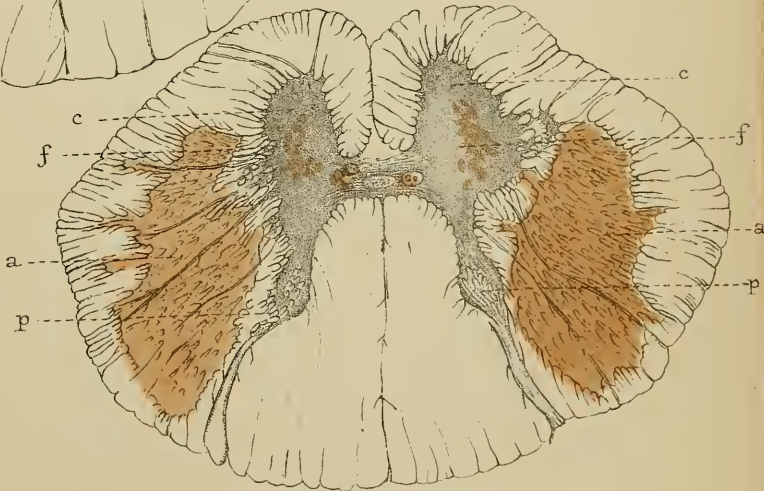


PLATE V, VOL. II.

SYMMETRICAL SCLEROSIS OF THE ANTERO-LATERAL
COLUMNS.

FIG. 1.—*Transverse section of the spinal cord in the middle part of the dorsal region.*

a, a. Lateral columns.
c, c. Anterior cornua.
p, p. Posterior cornua.

FIG. 2.—*Transverse section of the spinal cord in the middle part of the lumbar enlargement.*

a, a. Lateral columns.
c, c. Anterior cornua.
p, p. Posterior cornua.

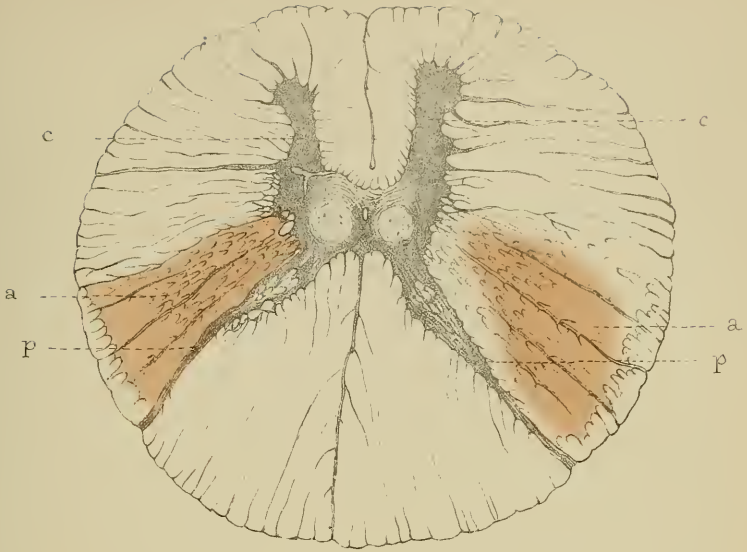


Fig. 2.

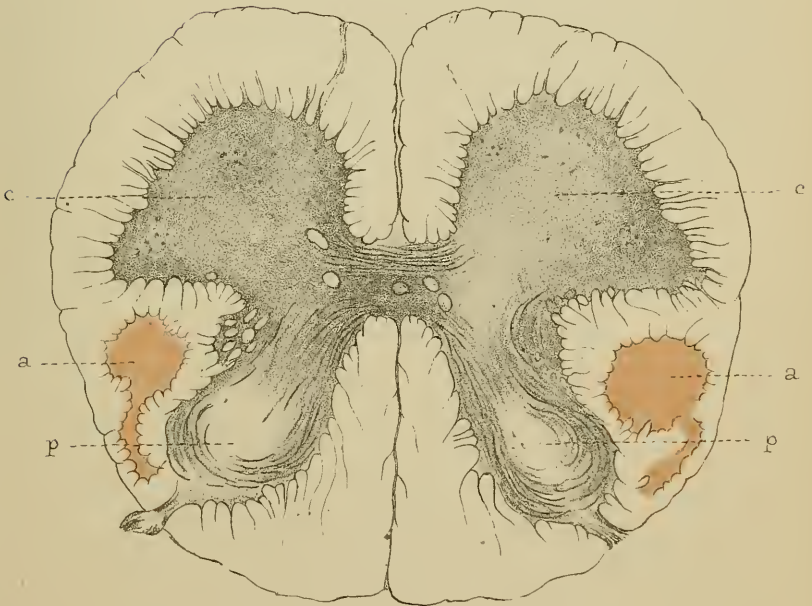


PLATE VI, VOL. II.

LOCOMOTOR ATAXIA.

This engraving, from a drawing by M. Richer, House-Surgeon, represents the patient Cott—, whose case is related in Appendix_I, p. 305.

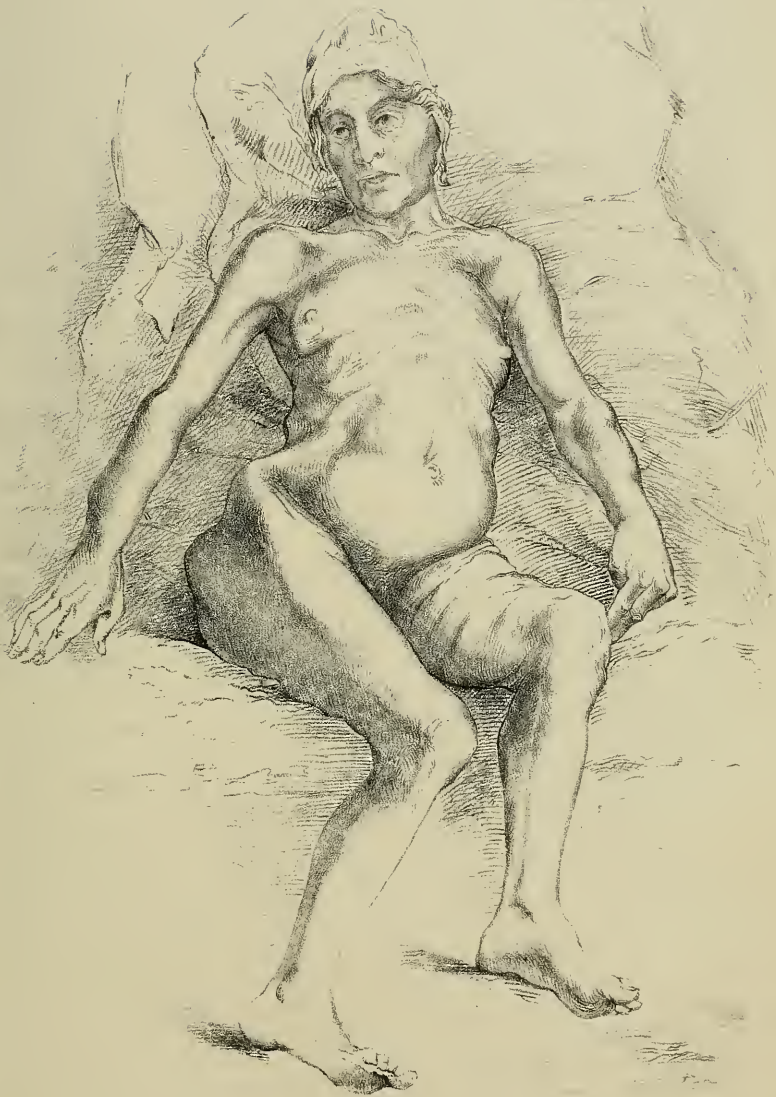

PLATE VII, VOL II.

PROTOPATHIC MUSCULAR ATROPHY.

FIG. 1.—*Transverse section of the spinal cord in the cervical region.*

A. Anterior radicular zone, sclerosed.

C. Anterior cornu, filled with numerous vessels; the nerve-cells have completely disappeared.

L. Lateral column.

P. Posterior column.

T. Türk's fasciculus.

These three fasciculi are completely healthy.

FIG. 2.—*Transverse section of the spinal cord in the lumbar region.*

The letters have the same signification as in Figure 1.

The anterior cornu, *C*, is perfectly normal, and contains numerous nerve-cells. There is no longer any sclerosis of the anterior radicular zone, *A*.

FIG. 3.—*Middle part of the dorsal region.*

A. Anterior radicular zone, sclerosed.

C. Anterior cornu, much less vascular than in the cervical region, and containing one or two nerve-cells.

FIG. 4.—*Different phases of the destruction of nerve-cells.*

a, b. Cells in process of destruction.

c. Normal cell.

FIG. 5.—*Longitudinal section of the phrenic nerve.*

a, a. Normal tubes, in which the myeline is coloured black by osmium separated from each other by broad connective bundles.

FIG. 6.—*Small vessel taken from the grey substance of the anterior cornu.*

a. Tumefied cell.

b. Cells containing several nuclei.

c. Nucleus of an endothelial cell.

FIG. 7.—*Vessel taken from the same region, with its walls covered by numerous leucocytes.*

Fig 2.

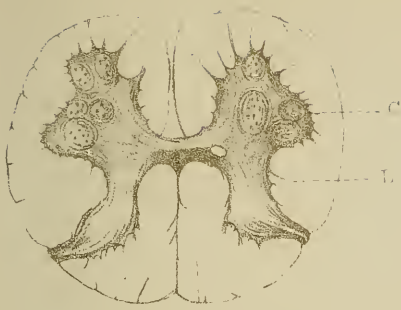


Fig 3

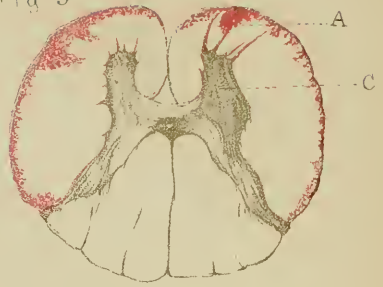

Fig 1. T A

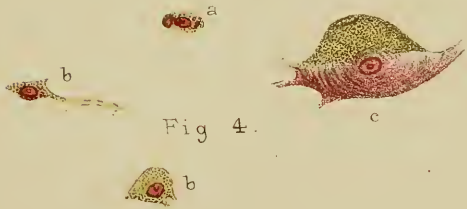
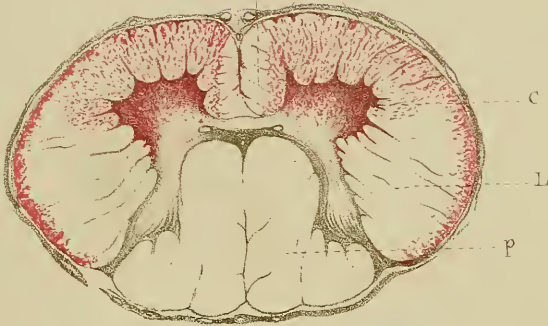
Fig 5.

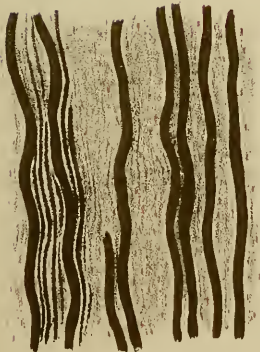


Fig 6.

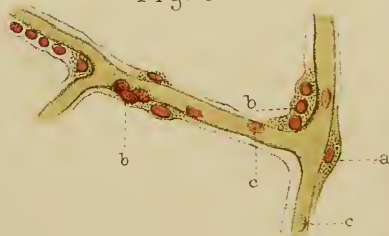

Fig 7.



PLATE VIII, VOL. II.

PROTOPATHIC MUSCULAR ATROPHY.

FIG. 1.—*Transverse section of the phrenic nerve.*

a, a. Section of fascicles, where the retained nerve-tubes are still rather numerous.

b. Spaces from which the nerve-tubes have totally disappeared.
(Drawing taken in the camera lucida.)

FIG. 2.—*Transverse section of a normal phrenic nerve.* (The outlines have been drawn in the camera lucida, with the same magnifying power as in Fig. 1.)

FIG. 3.—*Tube of diseased phrenic nerve (parenchymatous neuritis).*

a, a. Nuclei contained in the interior of Schwann's sheath.

b. Fragmented medullary matter. The axis-cylinder has disappeared.
Magnified about 700 diameters.

FIG. 4.—*Longitudinal section of fibres of normal diaphragm.*

FIG. 5.—*Longitudinal section of diseased diaphragm.*

a. Fibres atrophied, but still retaining their cross-striation. They are unequal in size. The connective intervals, *b*, are enlarged, owing to the atrophy of the muscular fibres.

Fig. 1.

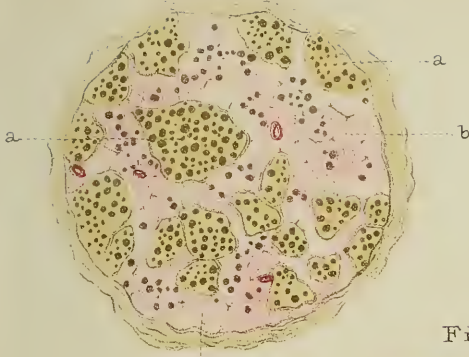


Fig 3

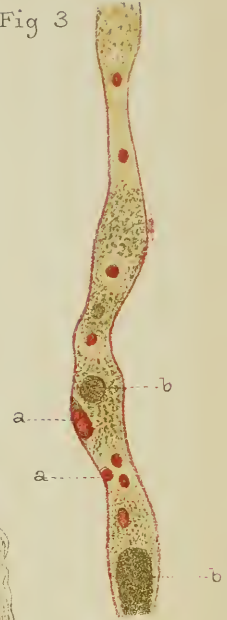


Fig. 2.

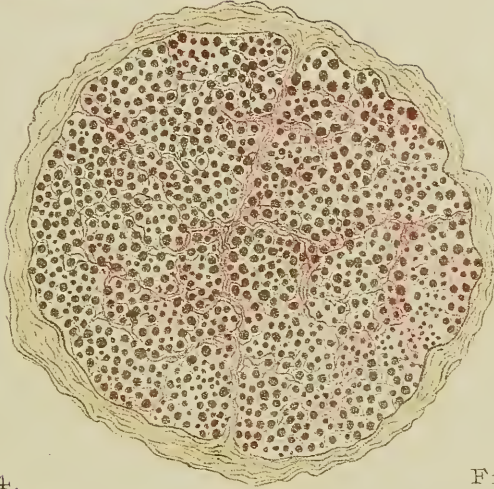

Fig. 4.




Fig 5.

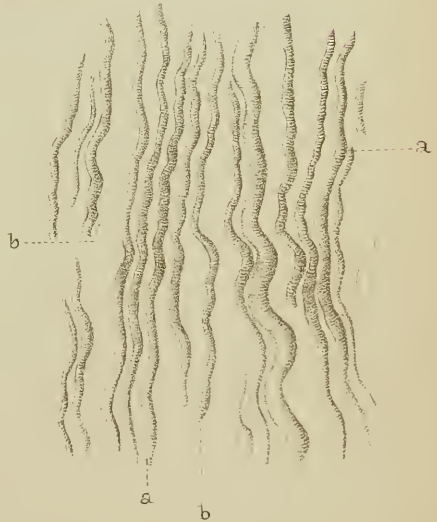


PLATE IX, VOL. II.

LOCOMOTOR ATAXIA.

Spontaneous fractures of left radius and ulna.

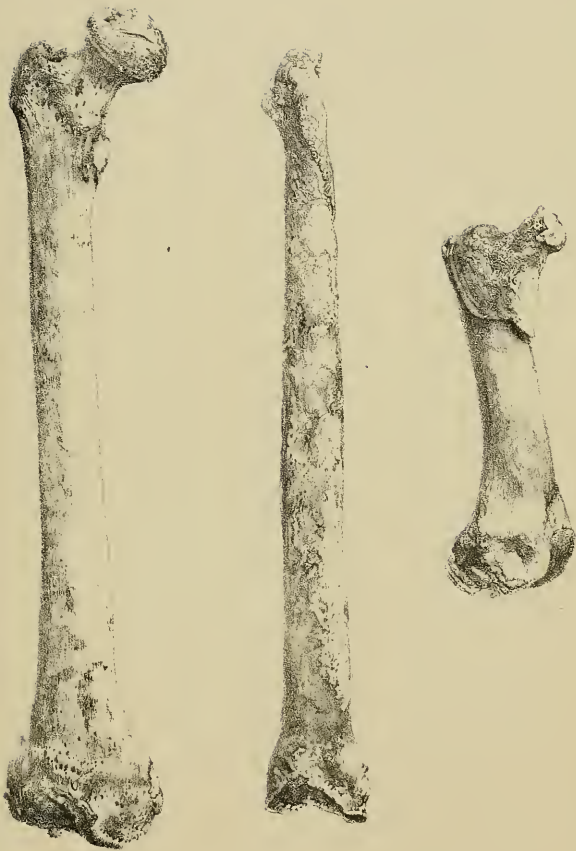

PLATE X, VOL II.

LOCOMOTOR ATAXIA.

Spontaneous fractures of the femur. Coxo-femoral arthropathies: lesions of the superior extremities of both femurs.

The representation of a normal femur, on the left of the plate, is given to enable an exact idea of the lesions to be at once obtained.



CV 17 1904

