

Montezuma County Poisonous Plant Guide



Photo Source Unknown

What are your animals eating?



Montezuma County Weed Program
103 North Chestnut
Cortez, CO 81321
(970) 565-0580

If you have questions contact your Veterinarian, County Weed Department, or your Colorado State University Extension Agent.

Montezuma County Poisonous Plant Guide

Prepared by:

Bonnie Loving

Montezuma County Noxious Weed Program Director

970-903-0535

bloving@co.montezuma.co.us

References:

- Colorado State University Guide to Poisonous Plants
- <http://phoenixfriends.proboards.com/thread/4676/plants-toxic-sheep-goats>
- <https://wagwalking.com/condition/iris-poisoning>
- <http://alpacasofmontana.blogspot.com/2012/07/plants-that-are-poisonous-to-alpacas.html>
- <https://www.proflowers.com/blog/poisonous-plants>
- <https://www.cathelp-online.com/emergency/poisonplants.php>
- <https://wagwalking.com/horse/condition/toadflax-poisoning>
- <http://poisonousplants.ansci.cornell.edu/php/plants.php?action=display&ispecies=cattle>
- <http://www.chickens.allotment-garden.org/poultry-illnesses-ailments/poisonous-plants-toxic-to-poultry-north-america/>
- <https://wagwalking.com/cat/condition/indian-hemp-poisoning-1>
- Weeds of the West 11th Edition
- Colorado Department of Agriculture Website

Poisonous Plant Quick Reference

*The vertical axis are toxic plants and the horizontal axis are animals that can be affected.

*There are varying degrees of harm for minor irritation to death depending on the type of toxic plant, amount consumed, overall health of animal, etc...

	Native / Non-Native	Alpaca	Cat	Cattle	Dog	Goat	Horse	Human	Llama	Poultry	Sheep	Swine
Arrow grass	Native	X		X		X	X		X		X	
Black henbane	Non-Native	X		X		X	X	X	X	X	X	
Bracken fern	Native			X			X	X			X	
Buffalo bur	Native	X	X				X					
Choke Cherry	Native			X		X	X		X		X	X
Cocklebur	Native	X	X	X				X		X		X
Curly dock	Non-Native		X				X			X		
Curlycup gumweed	Native			X			X					
Dalmatian toadflax	Non-Native			X								
Deathcamas	Native			X								
False hellbore	Native	X				X			X		X	
Flixweed	Non-Native			X								
Foxglove	Non-Native	X	X	X	X	X	X	X	X	X	X	
Gambel oak	Native			X			X		X			
Greasewood	Native	X	X			X			X		X	
Hairy vetch	Non-Native			X			X					
Halogeton	Non-Native	X	X	X							X	
Houndstongue	Non-Native		X	X		X	X				X	
Horsetail	Native		X			X	X			X	X	
Indian hemp	Native		X	X			X					
Iris	Native	X	X		X	X		X			X	X
Kochia	Non-Native		X									
Lambs quarter	Non-Native		X	X		X	X	X		X	X	X
Larkspur	Native	X	X	X	X	X		X	X		X	
Leafy spurge	Non-Native	X		X		X	X			X	X	
Lupine	Native	X	X	X	X	X	X	X	X	X	X	
Marijuana	Non-Native	X	X			X					X	
Milkweeds	Native	X		X		X	X			X		
Nighshades	Both	X	X	X		X	X	X	X	X	X	
Pigweed	Native			X		X				X	X	X
Prince's plume	Native			X		X					X	

	Native / Non-Native	Alpaca	Cat	Cattle	Dog	Goat	Horse	Human	Llama	Poultry	Sheep	Swine
Poison hemlock	Non-Native	X	X	X	X	X	X	X	X	X	X	X
Ponderosa pine	Native		X	X		X					X	
Purple locoweed	Native	X		X		X	X		X		X	
Puncturevine	Non-Native			X							X	
Russian knapweed	Non-Native		X			X	X				X	
Russian thistle	Non-Native	X		x								
Salt brush	Native			X			X				X	
Service berry	Native			X		X					X	
Snakeweed	Native			X		X	X				X	
Woody aster	Native			X			X					
Yellow starthistle	Non-Native		X			X					X	

Non toxic but Physically Hazardous

Common burdock	Non-Native	X	X	X	X	X	X	X	X	X	X	X
Foxtail	Native	X	X	X	X	X	X	X	X	X	X	X
Downy brome	Non-Native	X	X	X	X	X	X	X	X	X	X	X

Do you know what is in your hay? Purchase certified weed free hay to be safe...



<http://www.horsesinthemorning.com/wp-content/uploads/2014/01/hay-baler-tractor.jpg>

Arrowgrass



<https://www.bidib.cz/IMG/GAL/166994.j>

Arrow grass

Description

Perennial "grass like" plants with fleshy, half rounded, dark green leaves clumped at the base of the plant. Leaves are 6-8 inches long, linear, unjointed, and sheathed at the base. In cross section, the leaves are round with a flat or concave side. The inflorescence is a pediceled raceme up to 1 1/2 meters in length that appears as an unbranched, unjoined flower spike. The flowers are inconspicuous and numerous, with a greenish, 6-parted perianth. The fruits are made up of 3-6 celled capsules which turn a golden brown before splitting.

Toxic Principle

Cyanogenic glycoside triglochinin, which is hydrolysed in the rumen by microorganisms to produce hydrogen cyanide (HCN). All parts of the plant are poisonous especially if wilted. The cyanide blocks the action of cytochrome oxidase that prevents hemoglobin from releasing oxygen to the tissues. Death results rapidly from anoxia.

Treatment

Without stressing the animal, sodium thiosulfate and sodium nitrite should be given intravenously. A mixture of 1ml 20% sodium nitrite and 3ml of 20% sodium thiosulfate should be prepared and given at the rate of 4 ml of the mixture per 100lbs body weight. Sodium thiosulfate should be given orally via stomach using 30gm dissolved in a gallon of water.

Cardiovascular system

Sudden death may be the only presenting sign. A rapid heart rate, red mucous membranes, and cherry-red venous blood is highly suggestive of cyanide poisoning.

Respiratory System

Severe difficulty in breathing. Rapid respiratory rate.

Nervous System

Animals become anxious and excited because they are unable to breath.

Diagnosis

Sudden death with supporting evidence of cherry-red venous blood and absence of other diseases. Rumen contents or plant material can be tested for cyanide using the sodium picrate test. Commercial test kits for cyanide are available.

Animals Affected

Alpacas, Cattle, Goats, Horses, Llamas, and Sheep.



https://www.fws.gov/uploadedImages/Region_8/NWFS/Zone_1/San_Diego_Complex/Tijuana_Slough/Images/712_pix/arrow%20grass_712.jpg

Black henbane



<https://upload.wikimedia.org/wikipedia/commons/5/54/Henbane2.jpg>

Black henbane

Toxic Principle

Tropane alkaloids hyoscyamine(atropine), and hyoscine(scopolamine)are found in all parts of the plant. These atropine-like alkaloids act on the autonomic nervous system blocking acetylcholine receptors of parasympathetic postganglionic receptors. Poisoning is rare in animals as the plant has a strong pungent odor and is not palatable. Human poisoning occurs as result of chewing the flowers, leaves and seeds to experience the hallucinogenic effects of the alkaloids.

Description

A large, very hairy, sticky, branching annual or biennial erect herb growing to 5 feet in height. The leaves are alternate, simple, stalkless except at base, coarsely toothed, and 4-8 inches in length. The flowers are greenish yellow or white with prominent purple veins. The flowers are produced in the leaf axils, and each is made up of a 5 lobed calyx. The fruit is a characteristically urn-shaped capsule, the top of which detaches when ripe to release many grey brown, hard seeds.

Gastrointestinal

Decreased salivation (dry mouth), bloat, intestinal stasis, colic, and diarrhea may result.

Musculoskeletal

Ataxia due to muscle weakness.

Nervous System

Dilated pupils (mydriasis) are common, and animals may have difficulty seeing normally. Excitement and convulsions may occur when large amounts of plant are eaten.

Treatment

Cholinergic drugs such as physostigmine will help reverse the atropine effects.

Animals Affected

Alpacas, Cattle, Goats, Horses, Humans, Llamas, Poultry, and Sheep.



<https://slco.org/uploadedImages/depot/publicWorks/tWeed/weedPictures/blackHenbane2.jpg>



<http://media.mnn.com/assets/images/2014/09/black-henbane.jpg>

Bracken fern



http://www.easttennesseewildflowers.com/gallery3/var/albums/ferns/Bracken_fern10001.jpg?m=1348908358

Bracken fern

Description

Herbaceous, perennial that spreads via its horizontally branching black roots. Leaves arise directly from the rhizomatous roots and may be up to 5 feet tall. The triangular leaves are bipinnate and have brown reproductive spores on the under side, lining the leaf margins. A distinctive feature of bracken fern is that the subleaflets are distinctly lobed at the base but not at the apex or tip.

Toxic Principle

Bracken fern has been associated with a variety of different syndromes in animals and people, the best recognized of which include: 1. Thiamin deficiency - an enzyme, thiaminase, in the plant causes a thiamin(vitamin B1) deficiency resulting in blindness, depression, weight loss in horses. 2. Retinal degeneration and blindness (Bright blindness) occurs in sheep eating bracken over a period months. 3. Hemorrhaging syndrome (Enzootic hematuria, red water) is encountered in cattle grazing large quantities of bracken fern over a period of months. Over time cattle develop urinary bladder tumors(hemangioma, hemangiosarcoma, adenocarcinoma) 4. Digestive tract cancers are quite common in certain societies where bracken fern is regularly eaten. The young fronds ('fiddle heads'), that have the highest concentration of the carcinogen ptaquiloside, are a delicacy of some Oriental peoples. Ptaquiloside is a carcinogen found in the roots and new shoots of bracken. The prevalence of esophageal and stomach cancers is disproportionately high in those eating bracken fronds on a regular basis. Large quantities of bracken fern must be consumed over a period of weeks to induce poisoning. Horses eating hay containing 3-5% bracken for 30 days will be affected. The dried bracken in hay remains toxic. Ptaquilosides are present in many other species of fern that have been tested. Lactating cows grazing bracken will pass the ptaquiloside through the milk, which poses a potential risk to people drinking the milk.

Gastrointestinal

Cancer of the digestive tract in people has been associated with eating the uncooked bracken fern new growths.

Treatment

Thiamine deficiency can be treated with large doses of thiamin. There is no effective treatment for the bone marrow depression and resulting loss of clotting factors. Blood transfusions may be helpful. Batyl alcohol may have some benefit as bone marrow stimulant.

Cardiovascular system

Cattle may develop severe bone marrow depression and depletion of platelets (thrombocytopenia) that results in a hemorrhaging disease referred to as enzootic hematuria. Affected animals usually die from hemorrhaging because they lose the ability to clot their blood.

Nervous System

Horses and pigs are most affected by the thiaminase present in bracken. Severe depression, blindness, weakness and eventual death may result from the deficiency of thiamin (vitamin B1).

Renal System

Cattle develop red colored urine (hematuria) resulting from the development of tumors (hemangiosarcomas) in the urinary bladder. Hematuria may also result from the loss of platelets and hemorrhaging into the bladder.

Ocular System

Blindness may be due to thiamin deficiency, or may in the case of sheep be due to retinal degeneration.

Diagnosis

Diagnosis of bracken fern poisoning should be based on the history of the fern being eaten for an extended period of time, a hemorrhagic syndrome, caused by bone marrow depletion resulting in thrombocytopenia, and leukopenia. The presence of blindness (horses), or bladder tumors warrant consideration of bracken fern poisoning. At post mortem examination, there is usually multiple, diffuse hemorrhaging involving all organs.

Buffalobur



https://wnmu.edu/academic/nspages/giliflora/solanum_rostratum.jpg

Buffalo bur

Description

Annual weeds growing 1-2 feet in height, with showy yellow flowers with 5 partially united petals. The leaves and stems have prominent long yellow spines. Leaves are alternate and deeply lobed. The berry is completely enclosed in a calyx covered in yellow spines.

Toxic Principle

Solanine: an atropine-like alkaloid that acts on the autonomic nervous is present in all parts of the plants. The plant however, is rarely eaten because of its extensive protective spines. More problems are associated with the trauma from the spiny burs.

Gastrointestinal

Bloating, colic and diarrhea may result from eating the young green plants.

Treatment

Animals usually recover if they are removed from the plants, and treated symptomatically.

Animals Affected

Alpacas, cats, and horses.



http://www.opsu.edu/Academics/SciMathNurs/NaturalScience/PlantsInsectsOfGoodwell/plants/pasturebig/srostratapasture6_11_3.jp

Choke Cherry



Choke cherry

Description

Shrub or small tree with greyish bark marked by lenticels. Leaves are simple, glossy, alternate, ovate with serrate margins. The white flowers are produced in cylindrical racemes that are fragrant. The berries turn purple when ripe and are not toxic except for the seeds. Similar species include *Prunus pennsylvanica* (pin cherry) and *P. serotina* (black cherry).

Toxic Principle

Cyanogenic glycosides (prunasin, and amygdalin) which are readily hydrolysed by rumen microorganisms to free hydrogen cyanide (HCN). All parts of the plant contain the cyanogenic glycosides except the ripe berries. The wilted leaves are more toxic than when fresh. The Cyanide blocks the action of the enzyme cytochrome oxidase that prevents hemoglobin from releasing oxygen to the tissues. Death results rapidly from anoxia. All members of the *Prunus* family including cherries, apricots, almonds, peaches and their hybrids contain cyanogenic glycosides in their stems, leaves and seeds. The concentrations of the cyanide glycosides increases when the plant is stressed by drought or frost. The cyanide potential is highest in the new growth of the plants.

Gastrointestinal

Excessive salivation, nervousness and weakness precede death.

Treatment

Without stressing the animal, sodium thiosulfate and sodium nitrite should be given intravenously. A mixture of 1ml 20% sodium nitrite and 3ml of 20% thiosulfate should be prepared and given at the rate of 4 ml of the mixture per 100lbs body weight. In ruminants Sodium thiosulfate may also be given orally via stomach by dissolving 30gm in a gallon of water.

Cardiovascular system

Sudden death. Mucous membranes appear pink and redder than normal. Venous blood is cherry red in color. Stressing the animal rapidly leads to collapse and death.

Respiratory System

Initially animals show difficulty in breathing. Open-mouth breathing is common as the animal becomes oxygen deprived. Death occurs rapidly.

Diagnosis

Sudden death with evidence of animal eating cyanogenic plants. Severe respiratory difficulty, cherry-red mucous membranes are highly suggestive of cyanide poisoning. Plant material or fresh rumen contents can be submitted for detection of cyanide (Picrate test).

Animals Affected

Cattle, goats, horses, llamas, sheep, and swine.



<https://newfs.s3.amazonaws.com/taxon-images-1000s1000/Rosaceae/prunus-virginiana-fr-dcameron.jpg>

Cocklebur



Cocklebur

Description

Cockleburs are annual, bushy weeds 2-5 feet tall, with stout stems, often with red spots. The leaves are large, rough, glandular, triangular from 2-14 inches long and 1-8 inches wide. Flowers are produced in the leaf axils, the inconspicuous male flowers being clustered at the top, with the larger female flowers towards the base. The characteristic oval burs are covered by hooked spines. Each bur contains 2 seeds which can remain fertile for years.

Toxic Principle

Carboxyatractyloside, a sulfated glycoside, is present in high concentration in the burs and the 2-leafed cotyledonary stage. Toxicity disappears by the 4-leaf stage, and is not present in the mature plant. The liver appears to be the primary target organ. Fatalities occur when 0.75% to 3.0% body weight of cotyledons are consumed. The toxin is a potent inhibitor of oxidative phosphorylation.

Gastrointestinal

Vomiting and abdominal pain. The spiny burs are also a mechanical source of injury to animals causing oral injury when consumed.

Treatment

Supportive therapy may be attempted. Mineral oil via stomach tube may help in decreasing further absorption of the toxin.

Nervous System

Severe depression, ataxia, recumbency and convulsions.

Renal System

Granular and hyaline casts are common in the urine due to renal tubular nephrosis.

Integumentary System

The burs also cause economic losses to the wool producer because they become tangled in the fleece.

Hepatic System

Acute hepatitis as indicated by marked elevation of serum liver enzymes. Severe hypoglycemia is a common finding in acute cocklebur poisoning.

Diagnosis

Elevated liver enzymes, severe hypoglycemia, granular casts in the urine. Acute, diffuse centrolobular and paracentral coagulative liver necrosis is typical.

Animals Affected

Alpacas, cats, cattle, humans, poultry, and swine.



<http://www.theequinest.com/images/cocklebur-1.jpg>

Curly dock



http://1.bp.blogspot.com/-7rGEPUkwlPs/WTsE2DaHLRI/AAAAAAAAAHFE/WkS_AP0rG1wKfGpEdMrxiCOZF2sqEK7mACK4B/s1600/IMG_3775.jpg

Curly dock

Description

Perennial weed from a stout tap root. Stems may reach 100 cm without axillary branches. Leaves are 10-30 cm long, oblong to linear-lanceolate with crisped, wavy margins. An ocrea is present at the base of each petiole. The flower is a compound raceme or panicle having many small perfect or unisexual flowers. The perianth is six-parted with the inner three segments becoming the wings of the fruit. The inflorescence turns a dark red-brown when dry.

Toxic Principle

Soluble oxalates rapidly combine with serum calcium and magnesium, causing a sudden drop in soluble serum calcium and magnesium. In the acute phase of oxalate poisoning the sudden decline in serum calcium impairs normal cell membrane function, causing animals to develop muscle tremors, weakness, collapse and death. In chronic oxalate poisoning, insoluble calcium oxalate filtered by the kidneys causes severe damage to the kidney tubules. Oxalates also interfere with cellular energy metabolism. Livestock poisoning from eating curly leaf dock is relatively rare. Cattle would need to eat considerable quantities of the plant to be affected (10-20 lbs of green plant for an adult cow.)

Musculoskeletal

Within a few hours of consuming toxic levels of oxalates, muscle tremors, tetany, weakness, reluctance to move, depression, and recumbency result from hypocalcemia.

Treatment

Intravenous calcium gluconate, magnesium sulfate, glucose, and a balanced electrolyte solution to maintain kidney perfusion may be helpful early in acute oxalate poisoning. Giving limewater $[Ca(OH)_2]$ orally will help prevent absorption of further soluble oxalate.

Renal System

Coma and death may result within 12 hours. Animals that survive the acute effects of oxalate poisoning frequently develop kidney failure. If animals do not die from the acute effects of the low blood calcium levels, death results from kidney failure.

Diagnosis

The demonstration of calcium oxalate crystals in the kidneys and rumen epithelium histologically is diagnostic of oxalate poisoning. At necropsy, perirenal edema may be evident.

Animals Affected

Cats, horses, and poultry.



https://upload.wikimedia.org/wikipedia/commons/5/59/Curled_dock_%28321229944%29.jpg https://2.bp.blogspot.com/-xH4a64sZQY/WKnLnFDXXI/AAAAAAAAAcpO/TwIEYZQkuMgTN_X6VD16fyWKwGq8SwLQCPeB/s640/blogger-image-1944923998.jpg

Curlycup gumweed



Curlycup gumweed

Description

Biennial or perennial herbaceous plants growing 2-3 feet in height. Leaves are alternate, simple serrate and more or less dotted with resin. The flowers have yellow ray flowers (some are rayless) and are surrounded by several layers of pointed bracts that are recurved. The flower buds often contain abundant white gum-like resin.

Toxic Principle

Selenium. Gumweeds accumulate selenium when growing in seleniferous soils. Selenium, rich soils are found in the central United States, typically in the dry, alkaline soils of the western states. Excess selenium in the diet causes abnormal hair and hoof formation as a result of selenium replacing sulfur in keratin, the primary protein in hair and hoof.

Musculoskeletal

Initially circular ridges forms in all feet. As the hoof wall grows out, the ridges may crack, causing severe lameness due to laminitis. The hoof wall distal to the crack may slough off exposing the pedal bone. The fore feet are often most severely affected, but all four feet are generally affected.

Treatment

Affected animals should be removed from any food or water source containing more than 5 ppm. of selenium. Diets containing adequate amounts of sulfur and copper have a protective effect against chronic selenium poisoning. Alfalfa has sulfur-containing amino acids and is a useful food source in areas with selenium-rich soils.

Integumentary System

Chronic selenium poisoning causes loss of the long hairs of the mane and tail.

Diagnosis

A diagnosis of selenium poisoning is best confirmed by submitting samples of hay or forages for analysis. Selenium levels greater than 5 ppm should be considered potentially toxic. Blood levels of 1-4 ppm are typical of chronic selenium poisoning, whereas serum levels up to 25 ppm have been reported in acute poisoning. Liver and kidney levels greater than 4 ppm are indicative of selenium toxicosis. Hoof wall containing 8-20 ppm is indicative of chronic selenium poisoning. Hair samples containing in excess of 10 ppm selenium indicate excessive selenium intake capable of causing toxicity.

Animals Affected

Horses and cattle.



Dalmatian toadflax



https://uploads-ssl.webflow.com/595e9d5be9a5752409f9a35a/596fd58ca18e1f1ba60fb01c_Dalmatian%20Toadflax.jpg

Dalmatian toadflax

Description

A non-native, perennial forb introduced from the Mediterranean region as a folk remedy, fabric dye and ornamental. It reproduces both by seed and by extensive, creeping rhizomes. A single plant produces 500,000 seeds, most of which fall within 18 inches of the parent plant. Seed can remain viable for at least 10 years. Dalmatian toadflax grows to 3 feet and has bright yellow snapdragon-like flowers with an orange throat on elongated racemes. The alternate leaves are broad, with a thick, waxy cuticle and a bluish cast. Each leaf is heart-shaped and wraps the stem.

Toxic Principle

Toadflax contains quinazoline alkaloids, vasicine, vasicinone, quercetin, acacetin and deoxyvasicinone, with the concentration varying throughout the season. The plant also contains several flavonoid glycosides to include linarin and linarisan and the cyanogenic glucoside prunasin. The alkaloid concentration will vary throughout the growing season. Fortunately, animals tend to avoid eating this plant, however poisoning can occur should your horse be fed hay that has a high amount of toadflax.

Treatment

When poisoning is a concern, your veterinarian will want to clear the plant material and toxins from your horse's system. Activated charcoal may also be used to absorb any toxins remaining before your horse's body absorbs them. Fluid therapy may be utilized in order to help flush the toxin from your horse's body, as well as to prevent dehydration that may result from diarrhea. Medication may be administered in order to help with any nausea that your horse is experiencing as a result of the toxicity.

Symptoms

Should your horse ingest toadflax, they may experience gastrointestinal upset, which can include colic and diarrhea. Fortunately, symptoms of toadflax poisoning are relatively minor in comparison to those of other toxins. Diarrhea Gastrointestinal upset Colic.

Diagnosis

If you notice unusual gastrointestinal symptoms in your horse, contact your veterinarian, who can conduct a physical examination. Your veterinarian will ask you about the symptoms you have noticed in your horse, when you first noticed them and any changes that you have observed. You will also be asked about your horse's diet. If you noticed your horse ingest toadflax, or any plant that you are concerned may have been problematic, bring a sample of the plant with you. This may help your veterinarian in making a diagnosis.

In addition to getting your horse's vital signs, your veterinarian will take a complete blood count, request a chemistry panel and packed cell volume (PCV). A urinalysis can help in assessing kidney function. Your veterinarian may also seek to study the feces of your horse to determine if your horse ingested something that can be causing his symptoms.

Animals Affected

Horses and cattle.

Death camas



Death camas

Description

Hairless, perennials, with linear, grass-like, v-shaped, parallel-veined leaves arising basally from an onion-like bulb. The leaves are not hollow like those of onions, and do smell like onion. The inflorescence is a terminal raceme with numerous 6 petalled, small, white, cream to green flowers. The fruit is a 3 lobed capsule. Common species of death camas include: Showy or mountain deathcamas- *Z. elegans* Meadow death camas - *Z. venenosus*.

Toxic Principle

Death camas has several steroidal alkaloids similar to those found in *Veratrum* (false hellebore). The bulb and mature leaves are most toxic. The alkaloids have potent hypotensive activity. Sheep show signs of poisoning after eating as little as 1/2 lb of the green plants.

Gastrointestinal

Excessive salivation, vomiting.

Musculoskeletal

Muscular weakness, tremors, ataxia and prostration occur with death camas.

Treatment

There is no specific treatment for death camas poisoning. The injection of 2 mg of atropine sulfate and 8 mg picrotoxin per 100 lbs body weight is reported to be effective in treating early poisoning of sheep. Supportive therapy with intravenous fluids is helpful in combatting the hypotensive effects of the death camas. Bloat animals should be kept in a sternal position and a stomach tube passed to relieve rumen pressure.

Nervous System

Convulsions, coma and death.


Diagnostic Tests

A diagnosis of death camas poisoning is usually based on finding an evidence of the plant being eaten and recognizing the plant parts in the rumen contents. Zygacine may be detectable in the rumen contents using mass spectrometry.

Pulmonary congestion is the most significant post mortem finding.

Animals Affected

Sheep, cattle, pigs, and humans.



False hellbore



False hellebore

Description

Erect, 1-2 meters tall, with short perennial root stalks. The leaves are smooth, alternate, parallel-veined, broadly oval to lanceolate, 12-30 cm long, 12 cm wide, in three ranks and sheathed at the base. The inflorescence is a panicle of very numerous, small, greenish-white flowers, the lower ones often staminate and the upper ones perfect. The fruit is 3-chambered with several seeds. *Veratrum californicum* has whitish flowers on an erect panicle. It is found at higher altitudes of the rocky Mountains. *Veratrum viride* is very similar, but has greenish-white flowers produced in a pannicle with drooping lower branches. It grows at lower altitudes throughout North America.

Toxic Principle

Over 50 complex alkaloids, many with potent hypotensive effects have been isolated from *Veratrum* species. Highest concentration of the alkaloids are found in the young plant in early spring. The roots and all parts of the plant are toxic. Experimentally it has been shown that 1.25mg/kg body weight of the root is lethal to sheep, while a dose of 0.88mg/kg body weight of ground root produce craniofacial malformations in the lambs without causing severe toxicity in the ewe.

Gastrointestinal

Some alkaloids (cyclopamine) have specific teratogenic effects in sheep. Pregnant ewes consuming *Veratrum* in the 13-14 day of pregnancy produce lambs with a single eye and deformed facial bones.

Congenital Defects

Veratrum causes cyclops in lambs born to ewes eating the plant on the 13-14th days of gestation. If eaten on the 27-33rd. days of gestation, lambs are born with tracheal agenesis. Lambs with cyclopia have a single eye and varying degrees of malformation of the bones of the mandible and maxilla. Lambs are either born dead or die shortly after birth. Consumption of the *Veratrum* from the 28-30th. days of gestation may result in lambs with shortended legs.

Cardiovascular system

Decreased blood pressure leading to hypotension and shock. Decreased heart rate often occurs.

Diagnosis

Lambs born with cyclops are highly suggestive of veratrum poisoning. Similarly lambs born with shortened legs, or which die due to the fact they have a collapsed or absent trachea should lead to suspicion of veratrum poisoning.

Animals Affected

Alpacas, goats, llamas, and sheep.



Flixweed



<http://hasbrouck.asu.edu/imglib/seinet/Brassicaceae/photos/Descurainia-sophia-P-web-jpg>

Flixweed

Description

Annual or biennial weed growing up to 3 feet in height, and branching above. Leaves alternate, hairy, 2 or 3 times pinnately compound, each segment very narrow and linear. The flowers are produced terminally on the branches in slender racemes, each flower being small (1-2mm), yellow to green in color. The seed pods are slender, cylindrical, 1-2cm long, ascending, with 2 compartments, each with a row of seeds. *Descurainia pinnata* (tansy mustard) is very similar in appearance to flixweed except the seed pods are usually less than 1cm in length.

Toxic Principle

The toxic principle of Tansy mustard or flix weed is not known. The plant is most often eaten when it is young and succulent, and it is at this stage that it is most toxic. The toxicity of the plant varies from year to year. The neurological signs seen with tansy mustard poisoning are suggestive of sulfate poisoning.

Gastrointestinal

Difficulty chewing and swallowing because the animal's tongue appears to be paralyzed.

Musculoskeletal

Weight loss

Treatment

Most animals will recover if removed from the tansy mustard or flixweed. Severely affected animals need symptomatic treatment including water and electrolytes via stomach tube. Large doses of thiamin may help resolve the blindness.

Nervous System

Blindness, head-pressing is seen in some animals.

Integumentary System

Severe photosensitization occurs in cattle grazing Flixweed and tansy mustard in early Spring.

Ocular System

Blindness

Hepatic System

In cattle with photosensitization, the liver enzymes are elevated indicative of a toxic hepatopathy.

Animals Affected

Cattle



<http://www.luontoportti.com/suomi/images/23488.jpg>



<http://static.inaturalist.org/photos/2782637/medium.JPG?1450297782>

Foxglove



Foxglove

Description

Perennial herb growing 1-2 meters tall with alternate toothed, hairy, basal leaves. The characteristic purple or white tubular pendant flowers have conspicuous spots or streaks on the inside bottom surface of the flower. Other common species introduced into North America include *Digitalis lanata* (Grecian foxglove), *D. lutea* (straw foxglove). Many hybrids have been developed.

Toxic Principle

Several cardiac glycosides, the most important of which are digoxin, digitoxin and their genins, are found in all parts of the plant. Livestock are infrequently poisoned, but will eat the plant occasionally either fresh or in hay. The plant remains toxic when dried.

Gastrointestinal

Diarrhea

Treatment

Induction of vomiting, gastric lavage, or administration of activated charcoal is appropriate for removing the plant and preventing further absorption of the toxins. Cathartics may also be used to help eliminate the plant rapidly from the digestive system. Serum potassium levels should be closely monitored and appropriate intravenous fluid therapy initiated as necessary. Phenytoin, as an anti-arrhythmic drug effective against supraventricular and ventricular arrhythmias can be used as necessary. The use of commercially available digitalis-specific antibody (Digibind – Burroughs Wellcome) may be a beneficial in counteracting the effects of the cardenolides.

Cardiovascular system

A variety of cardiac arrhythmias and heart block including first and second degree heart block and ventricular tachycardia may be encountered with cardiac glycoside poisoning. Rapid, weak, irregular pulse. Sudden death may be the only finding in acute poisoning.

Respiratory System

Rapid breathing.

Diagnosis

Blood for detection of digitalis glycosides should be submitted to a laboratory for analysis.

Animals Affected

Alpacas, cats, cattle, dogs, goats, horses, humans, llamas, poultry, and sheep.



<http://higgledygarden.com/wp-content/uploads/2011/11/11.jpg>



<https://sep.yimg.com/ay/monticellostore/foxglove-digitalis-purpurea-15.jpg>

Gambel oak



<http://nrindepth.com/wp-content/uploads/2014/08/F1c10-WEB-771x655.jpg>

Gambel oak

Description

Gamble's oak is a shrub or small tree reaching heights of 15-20 feet. Shinnery oak (*Q. havardii*) is a shrub seldom attaining heights over 4 feet. Oaks have alternate, simple, toothed, or lobed dark green glossy leaves. The plants are monoecious with the staminate flowers occurring in long catkins and the pistillate flowers occurring singly or in small clusters. The fruit, an acorn, is a nut partially enveloped by an involucre of scales (acorn cup). Other oaks have similar characteristics.

Toxic Principle

The tannins found in the leaves, bark, and acorns of most *Quercus* spp produce poisoning through their effect on the intestinal tract and kidney. Tannins are potent, precipitators (astringents) of cellular protein. Oaks at any stage of growth are poisonous, but are particularly toxic when the leaf and flower buds are just opening in the spring. As the leaves mature they become less toxic. Ripe acorns are less toxic than when green. Ruminants frequently browse on oak without apparent problems provided they have ample access to normal forages.

Gastrointestinal

Initially animals stop eating, become depressed, and develop intestinal stasis. The feces are hard and dark but a black tarry diarrhea often occurs later in the course of poisoning. Abdominal pain is evidenced by teeth grinding and a hunched back.

Treatment

Once clinical signs are evident, renal damage is severe warranting a poor prognosis. Aggressive fluid therapy may help to rehydrate the animal and maintain kidney function. Supplementing cattle with 10% calcium hydroxide is useful in reducing oak toxicity in areas where oak brush is likely to be consumed in quantity.

Renal System

red colored urine. Marked elevation in serum creatinine and urea nitrogen.

Hepatic System

Severe liver damage is detectable by marked elevations in serum liver enzymes. Animals may live for 5-7 days after the onset of clinical signs.

Diagnosis

A mucoid, hemorrhagic gastroenteritis is a common finding in oak poisoning. Hemorrhages on various organs and excessive amounts of fluid in the peritoneal and pleural spaces are often present. The kidneys are usually found to be pale swollen and covered with small hemorrhages. Histologically the kidneys show tubular necrosis. Liver necrosis may also be evident.

Animals Affected

Cattle, horses, and llamas.

Special Notes

Oak poisoning often occurs in the early spring when a late snow will cover the ground and cattle then browse on the oak buds that are leafing-out. Other oak species that have been associated with oak brush poisoning include *Q. undulata*, *Q. turbinella*. Oak trees make excellent shade trees when mature, and ideally should be planted outside animal enclosures. In years when there is a heavy acorn crop, fallen acorns should be raked up and removed from areas where horses and other livestock may eat them in quantity. 'Acorn calf' syndrome is a feed associated congenital anomaly of beef calves in which the calves are born with deformed heads, joint laxity and dwarfism. Although originally thought to be caused by the pregnant cows eating large quantities of acorns, there is no proof that acorns or the tannins present in oaks are responsible for the problem.

Greasewood



<http://stevensonintermountainseed.com/wp-content/uploads/2012/07/Black-Greasewood-Fic-crop.jpg>

Greasewood

Description

An erect, deciduous shrub with woody, spiny branches often growing to 150 cm. The plants are many branched turning gray with maturity. The leaves are alternate, bright green, fleshy, loosely round in cross section, and up to 1-1/4 inches long. The flowers are unisexual with the plants having both sexes of flower on the same plant. The female flowers being inconspicuous in the axils and the male flowers occurring as terminal spikes (catkins). The fruits are winged and conical in shape.

Toxic Principle

Sodium oxalate. (10-22% dry matter). The leaves contain the highest concentration of oxalate. Toxicity occurs when 1.5-5.0% of an animal's weight of the plant is ingested over a short period of time.

Musculoskeletal

Muscle tremors, tetany, weakness, reluctance to move, depression, and recumbency resulting from hypocalcemia and hypomagnesemia. Coma and death may result within 12 hours. Animals that survive the acute effects of oxalate poisoning frequently develop kidney failure.

Treatment

Calcium gluconate, magnesium sulfate, glucose, and a balanced electrolyte solution can be given intravenously to maintain kidney perfusion, and treat the effects of the low blood calcium. Giving limewater [Ca(OH)₂] orally will help to prevent absorption of further soluble oxalate from the rumen. The prognosis is usually very poor because of the severe kidney damage that results.

Renal System

Animals that survive the acute effects of oxalate poisoning frequently develop kidney failure. Insoluble calcium oxalate filtered by the kidneys causes severe damage to the kidney tubules. Animals die from renal failure.

Diagnosis

Sudden deaths, or weak,

Animals Affected

Alpacas, cats, goats, sheep, and llamas.



<https://wildfoodgirl.com/wp-content/uploads/2013/05/black-greasewood-sprig-nevada.jpg>

Hairy vetch



[https://amc-nh.org/resources/guides/wildflowers/images/Vicia%20villosa_Hairy%20Vetch%20Fodder%20Vetch%20Winter%20Vetch_primary_2_Hanover,%20NH_20120617_Tom%20Todd_IMG0070%20\(2\).jpg](https://amc-nh.org/resources/guides/wildflowers/images/Vicia%20villosa_Hairy%20Vetch%20Fodder%20Vetch%20Winter%20Vetch_primary_2_Hanover,%20NH_20120617_Tom%20Todd_IMG0070%20(2).jpg)

Hairy vetch

Description

An annual with stems 4-6 feet in length, with hairy stems and leaves. The leaves have 10-20 leaflets up to 1 inch in length which are narrow and lance-shaped. Tendrils at the end of the leaves are well developed. Flowers are purple to red in color, 20-60 per spike, all on one side of the flower stalk. Pods are about 1 inch in length containing several hard seeds.

Toxic Principle

The toxin in hairy vetch responsible for the symptoms is not known. The toxin appears to cause an immune-mediated disease as prior exposure or sensitization is necessary for the disease to develop. Animals grazing the green vetch develop a severe granulomatous disease affecting many organs. The seeds of hairy vetch when eaten in quantity by cattle and horses cause nervous signs and death. The seeds of *Vicia sativa* have been reported to contain cyanide.

Gastrointestinal

Diarrhea, poor appetite.

Cardiovascular system

Sudden death may be associated with cyanide in the seeds.

Nervous System

Abnormal behavior, excessive bellowing, difficulty in standing, convulsions and death from eating quantities of the hairy vetch seed.

Integumentary System

Initially animals have welts on the skin, with hair loss, thickening of the skin, itching and rubbing of the affected areas, and peeling of the skin around the nose and eyes. Lymph nodes are swollen and ventral edema is common.

Diagnosis

Lymphocytosis and hyperproteinemia are common features of hairy vetch poisoning. Microscopically, the skin, heart, liver and other organs have cellular infiltrates of lymphocytes, monocytes, and multinucleated giant cells typical of an immune-mediated granulomatous reaction. Mortality is usually high.

Animals Affected

Cattle and horses.



<https://thelifeofyourtime.files.wordpress.com/2011/10/dscf4533.jpg> https://p63zw5onad-flywheel.netdna-ssl.com/wp-content/themes/jupiter-child/seed-images/organic_common_vetch-159.jpg

Halogeton



<http://www.worldbotanical.com/images/halogeton383.jpg>

Halogeton

Description

An annual, many-branched herb with branches spreading horizontally before curving upwards as high as 50 cm. Seedlings are usually prostrate with four main branches in the form of a cross. Mature plants have red colored stems with succulent blue-green leaves terminating in a solitary hair. The small, inconspicuous flowers appear in the leaf axil. The fruit are bracted and often mistaken for the flowers. The single seed is surrounded by 5 reddish to yellow-green bracts.

Toxic Principle

Halogeton contains 30-40% soluble sodium oxalates on a dry matter basis. Poisoning in sheep occurs when 0.3-0.5% the animal's body weight of plant is consumed over a short period. In animals not adapted to eating Halogeton, the toxic dose is about one third to one quarter of that needed to induce poisoning in adapted animals.

Musculoskeletal

Muscle tremors, tetany, weakness, reluctance to move, depression, and recumbency resulting from hypocalcemia and hypomagnesemia. Coma and death may result within 12 hours. Animals that survive the acute effects of oxalate poisoning frequently develop kidney failure.

Treatment

Calcium gluconate, magnesium sulfate, glucose, and a balanced electrolyte solution can be given intravenously to maintain kidney perfusion, and treat the effects of the low blood calcium. Giving limewater [$\text{Ca}(\text{OH})_2$] orally will help to prevent absorption of further soluble oxalate from the rumen. The prognosis is usually very poor because of the severe kidney damage that results.

Renal System

Animals that survive the acute effects of oxalate poisoning frequently develop kidney failure. Insoluble calcium oxalate filtered by the kidneys causes severe damage to the kidney tubules. Animals die from renal failure.

Diagnosis

Sudden deaths, or weak.

Animals Affected

Alpacas, cats, cattle, and sheep.



https://www.usu.edu/weeds/plant_species/weedspecies/weed_images/halogeton/Halogeton1.jpg https://upload.wikimedia.org/wikipedia/commons/9/91/Halogeton_glomeratus_%284050299568%29.jpg

Hbundstongue



http://wildflowerfinder.org.uk/Flowers/H/Hbundstongue/Hbundstongue_2011_06_14_Southport_Ainsdale_Freshfields_470pl.jpg

Houndstongue

Description

Biennial, forming a rosette the first year of based leaves up to 18 inches long, densely hairy and tongue shaped. In the second year a 2-4 foot erect flowering stem is produced. Flowers are reddish purple in color and are produced from the terminal leaf axils. The fruits are pyramidal, separating into 4 nutlets which are covered in hooked ??? (velcro) enabling adhesive to animal hair and clothing.

Toxic Principle

Pyrrrolizidine alkaloids. All parts of the plant are toxic, even when it is dried. Toxic dose 15mg of dried plant per kilogram bodyweight over 2 weeks induces severe liver disease. Pyrrrolizidine alkaloids interfere with cell division, affecting especially the liver. The PA are cumulative in effect and cause severe liver fibrosis and eventual irreversible liver failure after several months.

Musculoskeletal

Weight loss as a result of chronic liver disease

Treatment

There is no effective treatment for animals with terminal liver disease due to pyrrrolizidine alkaloids as the liver changes are irreversible. Keeping the animal out the sun will relieve the photosensitization but not affect the underlying liver disease.

Nervous System

Abnormal behavior - excessive yawning, walking in circles, and depression result from liver failure(hepatic encephalopathy).

Integumentary System

Secondary photosensitization develops as a result of severe liver disease. White skinned (non pigmented) areas become red, swollen, and painful before the skin dies and sloughs-off as is severely burned.

Hepatic System

Yellow coloration to the mucous membranes (jaundice), weight loss, diarrhea, rectal prolapse, edema of the legs, red urine (hemoglobinuria) are signs of severe liver disease.

Diagnosis

Elevated serum liver enzymes, decreased albumen, and a liver biopsy that shows megalocytosis, fibrosis and biliary hyperplasia are diagnostic of PA poisoning.


Animals Affected

Cats, goats, sheep, cattle, and horses.



http://colaplata.co.us/UserFiles/Servers/Server_1323669/Image/Government/Departments/Weeds/Enforceable%20Weeds/Houndstongue/houndstongue_rosette.jpg

Hbrsetail / Smooth scouringrush



Copyright Gerald D. Tang

Horsetail / Scouring rush

Description

Herbaceous, perennial, leafless plants with hollow stems that readily separate at the nodes. The leaves are reduced to papery scales with black tips that surround the stems at each node. The stems are cylindrical, ridged and rough to the touch owing to the high silicate content. There are 2 types of stem. Fertile stems are unbranched, and are tipped by a cone-like structure containing spores. Infertile stems have multiple whorled branches at the nodes. The plant reproduces from a deeply buried rhizome and from terminal spore bearing cones.

Toxic Principle

Thiaminase is the suspected toxin. Also contains aconitic acid and polustrine, and silicates. Plant is rarely eaten except when dried in hay. All species of Equisetum should be considered potentially toxic to animals until proven otherwise.

Gastrointestinal

Weight loss, and diarrhea.

Treatment

Horses suspected of horsetail poisoning should be immediately taken off the hay or pasture containing the Equisetum and fed a nutritious diet. Treatment with thiamine hydrochloride (1-2 mg/kg subcutaneously for several days) is beneficial in restoring thiamine levels to normal. Feeding grain as part of the diet affords a protective effect against the thiaminase.

Nervous System

Weakness and incoordination the of hind legs progressing to recommitting. Animals continue to eat relatively well. Once horses are down and cannot get up, the prognosis is poor because of muscle degeneration. Horses may appear blind and have difficulty in seeing. Central nervous system depression develops in the more severely poisoned animal.

Diagnosis

Blood pyruvate levels may be elevated. Response to thiamine therapy.

Animals Affected

Cats, goats, sheep, cattle, and horses.



<http://www.backyardnature.net/ny/14/140105eq.jpg>



<https://upload.wikimedia.org/wikipedia/commons/7/7c/Equisetopsisida.jpg>

Indian hemp



Indian hemp

Description

A perennial plant that grows throughout much of North America. It grows up to 6 feet tall. The stems are reddish and contain a milky latex capable of causing skin blisters. The leaves are opposite, simple broad lanceolate, entire, and smooth on top with white hairs on the underside. It flowers from July to August. The flowers are hermaphrodite and are pollinated by moths and butterflies.

Toxicity

Indian hemp poisoning in cats is a form of plant toxicity resulting from direct or indirect ingestion of any portion of the Indian hemp plant, including the pollen, roots, stem and leaves. A feline can also be poisoned by drinking contaminated water that held the Indian hemp plant, such as from a vase. The Indian hemp plant contains toxins called cardiac glycosides that directly interfere with the heart's electrolyte balance. Clinical signs are, therefore, usually cardiovascular but can also be neurological and gastrointestinal.

The toxic components of the Indian Hemp plant are naturally-occurring poisons; bufadienolides and cardenolides. These two types of poisons are called cardiac glycoside toxins, which interfere with the heart's electrolyte balance of the contracting muscle. In veterinary medicine, drugs like digoxin and digitalis affect the heart in a very similar way to the Indian hemp plant's bufadienolides and cardenolides. A lethal dose is estimated at 0.5 grams per kilogram of the feline's body weight, but adverse reactions can result in lower dosages.

Symptoms

The Indian hemp plant contains toxins called cardiac glycosides, because they interfere with the hearts electrolyte balance directly. Due to the poison's direct focus being the heart, a feline will develop clinical signs of Indian hemp poisoning that are centered around the heart muscle and functions. Common signs are convulsions, body weakness, blue colored mucus membranes, pupil dilation, fever, elevated pulse, seizures, tremors, vomiting, drooling, nausea, high potassium levels, and irregular heartbeat.

Treatment

Indian hemp poisoning in cats has an antidote know as digoxin-specific Fab fragments. The treatment is rather expensive and is only used in severe, life-threatening cases of plant toxicity. If your cat is not in a life-threatening state of Indian hemp plant toxicity, the veterinarian will want to encourage the feline's body to eliminate the toxin. An emetic drug will be administered to encourage the feline to vomit. If your cat has not vomited, activated charcoal will likely be administered by the veterinarian. Activated charcoal will bind with the toxic agent and prevents the body from further absorption of the plant chemicals. The feline's treatment may end with intravenous fluids to flush the toxin from the blood and restore his or her hydration. Vomiting and diarrhea will cause the cat's fluid levels to drop significantly, therefore, intravenous fluids are almost always given.

Animals Affected

Cats, cattle, and horses.



Iris



Iris

Description

There are over 200 species of Iris plants in the family Iridaceae. The iris was used as a symbol of monarchs and royalty and is represented by the commonly known symbol of “Fleur de Lys”. The iris comes in a variety of colors and varies slightly in appearance, but all of the species are toxic to dogs if ingested. The iris also goes by the common names snake lily, yellow water iris, yellow flag, western blue flag, Douglas’s flag, and water flag.

Western blueflag iris is a native found around Montezuma County. Typically Iris are perennial species that have stout stems that are 1 to 2 feet tall. The Western blueflag iris has a blue violet flower, but generally, irises have a wide range of flower colors.

Toxicity

The toxic compounds in the iris plant are resinous purgative irisin and cytotoxic terpenoids. The exact function of the toxin in the iris flower is still unknown, but scientists believe it contains ribosome inactivating proteins (RIPs) that interfere with RNA and protein synthesis. The disruption of the cell’s normal pathway usually leads to cell death. The highest concentration of toxin in the iris is believed to be in the bulb, however, the roots and leaves are also toxic if ingested.

Treatment

The symptoms of iris poisoning your animal is suffering will determine the course of treatment. Since the iris plant causes gastrointestinal upset, your veterinarian may try to induce vomiting in your dog or cat. If too much time has passed since the ingestion of the iris plant, your veterinarian may administer activated charcoal. This will bind with and absorb any remainder toxin that has not been absorbed by the body. Additional medications to protect the intestinal lining may also be administered. With profuse vomiting and diarrhea, dehydration is a common result. Fluid therapy with electrolytes will be started to help correct any dehydration your dog is experiencing and to prevent it from worsening. If your animal is experiencing eye, skin, or mouth irritation, the veterinarian will attempt to flush any remaining toxin from the affected area. Eye health can deteriorate in a matter of hours; the sooner your animal receives proper medical attention, the higher his chances of retaining full function of his eyes.


Animals Affected

Alpacas, cats, goats, horses, humans, sheep, and swine.



http://4.bp.blogspot.com/_sMbBX-uOWbQ/TAiUgCdhYtI/AAAAAAAAABiY/LnBBruSYypo/s1600/184604681_szfjx-XL.jpg

Kochia



<https://i.pinimg.com/736x/37/5f/4e/375f4e7fdd2780e761a4f98adb05264f.jpg>

Description

A rapidly growing, drought tolerant annual weed growing to a height of 6 feet under ideal growing conditions. It is a bushy plant with a many branched stem, and soft hairy lanceolate, alternate leaves. The inconspicuous flowers formed in the axils of the upper leaves, are green in color, sessile, and often in dense bracted spikes. Leaf veins and mature stems are often red in color. In the fall the stems turn bright red. Many wedge-shaped seeds are produced in late summer, which are readily dispersed in the fall when the dried plant is blown about by the wind.

Toxic Principle

Toxicity varies with the growing conditions of the plant, with more problems associated with the mature, droughted plant. Kochia weed has been associated with the following: Nitrate poisoning Oxalate poisoning Photosensitization secondary to liver disease Thiaminase activity leading to polioencephalomalacia (This is possibly a sulfate related toxicity) Sulfate toxicity - Kochia weed may accumulate high levels of sulfate which can result in sulfide production in the rumen and subsequent blindness and death. This syndrome may be precipitated by hot weather that increases water consumption, especially if the water is high in sulfates. Other potential toxins present in the plant include saponins, and alkaloids.

Treatment

If nitrate poisoning is suspected, methylene blue should be administered intravenously. The recommended dose range for methylene blue is from 4-15 mg/kg body weight administered as a 2-4% solution. A dose of 8 mg/kg body weight intravenously has been reported to be effective in cattle. The half-life of methylene blue is about 2 hours in sheep, indicating that small doses of the drug can be repeated as needed every few minutes to reduce methemoglobinemia to the point that the animal is not in severe respiratory distress. Excessive administration of methylene blue to animals other than ruminants will result in a hemolytic anemia due to Heinz body formation. Horses, and especially dogs and cats are particularly susceptible to methylene blue toxicity.

Cardiovascular system

Sudden death may result if Kochia is high in nitrates(>1% nitrates is poisonous to ruminants). Brown colored mucous membranes and blood are typical of nitrate poisoning.

Respiratory System

Severe difficulty in breathing due to nitrate poisoning inducing methemoglobinemia.

Nervous System

Severe depression, blindness, incoordination due to sulfate induced polioencephalomalacia.

Renal System

Kidney failure due to high levels of soluble oxalates in the plant causing precipitation of calcium oxalate in the kidney tubules.

Integumentary System

Photosensitization, especially of the white skinned areas is secondary to liver failure.

Ocular System

Blindness is due to polioencephalomalacia that is secondary to the high sulfate levels in some kochia weed.

Hepatic System

Liver disease has been associated with Kochia weed that induces a secondary photosensitization.

Diagnosis

Kochia weed containing in excess of 1% nitrate dry matter should be considered toxic. Water levels of 1,500 ppm or greater are potentially toxic especially if consumed with forages high in nitrate.

Special Notes

In some areas of the arid southwestern States Kochia weed is grown as a forage crop for cattle because it has a higher yield per acre than alfalfa and various grasses. The nutritive value of Kochia is also comparable to alfalfa although it may be less palatable and digestible. Do not feed pregnant cattle forages containing nitrates. Levels of nitrate approaching 1% nitrate have the potential to cause abortions. Ensure cattle receive adequate energy (grain) in their ration to ensure the conversion of nitrate to protein occurs rapidly, and thereby prevents the buildup of toxic nitrite in the rumen. Feeding some grain concentrate enables rumen bacteria to effectively utilize nitrite and reduce the chance for toxicity. Dilute nitrate rich hay with hay contain no nitrates, so that the total nitrate level is <1%. Nitrate levels are often highest in the plants in the early morning or on cloudy, overcast days.

Lambs quarter



<https://hasbrouck.asu.edu/imglib/seinet/Chenopodiaceae/photos/Chenopodium-album-FL-web-.jpg>

Lambsquarter

Description

Annual weed, with erect, branched stems, alternate leaves, that have a grayish, powdery under-surface. The basal leaves have a more serrated edge than do the upper, smaller leaves. The stems often have red/purple stripes or markings. The flowers are produced at the ends of the branches and are small, gray-green in color. Large quantities of small dark seeds with a "netted" surface are produced.

Toxic Principle

Lamb's quarter can accumulate toxic levels of nitrate especially if growing in rich organic soils or if it is fertilized as might occur when it grows in arable cropland. Toxic levels of oxalates and sulfates may also accumulate in lamb's quarter.

Treatment

If nitrate poisoning is suspected, methylene blue should be administered intravenously. The recommended dose range for methylene blue is from 4-15 mg/kg body weight administered as a 2-4% solution. A dose of 8 mg/kg body weight intravenously has been reported to be effective in cattle. The half-life of methylene blue is about 2 hours in sheep, indicating that small doses of the drug can be repeated as needed every few minutes to reduce methemoglobinemia to the point that the animal is not in severe respiratory distress. Excessive administration of methylene blue to animals other than ruminants will result in a hemolytic anemia due to Heinz body formation. Horses, and especially dogs and cats are particularly susceptible to methylene blue toxicity.

Respiratory System

Sudden deaths may occur as a result of acute respiratory failure induced by the formation of methemoglobin. When greater than 20% of hemoglobin is converted to methemoglobin, oxygen transport in the blood is reduced to induce respiratory difficulty. Death occurs when methemoglobin levels exceed 60%, especially if the animal is stressed.

Reproductive System

Pregnant animals may abort at any stage of pregnancy if consuming plants/forage containing >1% nitrate.

Diagnostic Tests

Methemoglobin levels detectable in the blood and nitrate levels of >1% in the plant would be strong evidence of nitrate poisoning

Diagnosis

Acute respiratory difficulty and brown colored mucous membranes of the mouth and vulva due to the presence of methemoglobinemia is highly suggestive of nitrate poisoning.

Animals Affected

Cattle, cats, goats, horses, humans, poultry, sheep, and swine.



<https://green-mom.com/wp-content/uploads/2016/09/lamb-quarter-300x225.jpg>

<http://www.homecomers.org/janesville/img/lambsquarters2b.jpg>

Larkspur



Larkspur

Description

Tall larkspurs are erect, perennial, herbaceous plants with simple or branched hollow stems; the leaves are alternate and palmately divided. The flowers are perfect and irregular, and are carried in terminal racemes. The flowers are dark blue in color. There are 5 sepals, the upper most one having an obvious spur. The corolla comprises two sets of two petals each, the two lower ones forming a claw and the upper two extending into the spur. The flowers have multiple stamens and 3 pistils which may be fused at the base. The fruits are follicles that split open to release numerous dark brown/black seeds.

Toxic Principle

Diterpene alkaloids, methyllycaconitine, 14-deacetylnudicauline, and nudicauline. The alkaloids act principally at the neuromuscular junction causing a curare-like blockade with resulting muscle weakness and paralysis.

Gastrointestinal

Bloat, secondary to the muscle paralysis induced by the alkaloids, is a major contributor to the rapid death of cattle.

Musculoskeletal

Muscle tremors, weakness, staggering gait and recumbency.

Treatment

Avoid stressing the affected animals. Gently herd the cattle away from the larkspur area. Where possible give physostigmine intravenously (0.08mg/kg) with as little stress as possible. Neostigmine sulfate administered intravenously or intramuscularly at a dose of 0.02 – 0.04 mg/kg can also be used for treating larkspur poisoned cattle. Keep the animal on its sternum to reduce bloating, and if necessary treat the bloat by passing a stomach tube, or by trocarizing the rumen.

Respiratory System

Death due to respiratory paralysis and bloat.

Nervous System

Muscular paralysis due to the neurotoxic alkaloids binding to acetylcholine receptor sites causing muscular paralysis.

Diagnosis

Sudden deaths of cattle on summer range at higher altitudes where larkspur is abundant should prompt suspicion of larkspur poisoning. Rumen contents and the suspect larkspur plants can be submitted to the Poisonous Plants Research Lab in Logan Utah for analysis. When alkaloid concentrations are <3 mg/gm of plant, cattle can safely eat large amounts

Animals Affected

Alpacas, cats, cattle, dogs, goats, humans, llamas, and sheep.



<https://nwwildflowers.files.wordpress.com/2015/03/dsc08307-2.jpg> <https://garden.org/pics/2013-06-01/gardengus/e8a134.jpg>

Leafy spurge



© 2009 Katy Chayka

Leafy spurge

Description

A prolific perennial, up to 3 feet tall, reproducing by seeds and an extensive root system. Leaves are alternate, narrow, 1-4 inches long. Multiple stems arise from the root crowns. The plant contains a milky sap in the stems and leaves. Flowers are very small, yellowish-green, and arranged in terminal clusters. Conspicuous yellowish-green heart-shaped bracts surround each flower. Seed capsules explode when dry, scattering seeds. Leafy spurge is a member of a very large family of plants with at least 2000 species. There is wide variety in the genus, but all spurges contain a milky sap in the stems and leaves.

Toxic Principle

Diterpene esters in the milky sap are strong irritants causing blistering of the skin in some humans that handle the plants. Salivation, vomiting and diarrhea may result from irritation to the digestive tract.

Gastrointestinal

Excessive salivation, vomiting, colic and diarrhea may occur in animals other than sheep eating leafy spurge. Sheep will lose weight if on a diet exclusively consisting of leafy spurge. Leafy spurge does not provide a nutritious diet by itself.

Musculoskeletal

Sheep fed diets consisting of 100% leafy spurge lose weight because of its poor nutritive value.

Treatment

Once removed from the spurge animals recover uneventfully.

Integumentary System

Reddening, swelling and blistering of the skin may occur in some people handling the milky sap of leafy spurge. Some species of spurge (*Euphorbia myrsinites* - creeping spurge) appears to be especially irritating to human skin.

Ocular System

The sap can cause severe eye irritation.

Animals Affected

Alpacas, cattle, goats, horses, poultry, and sheep.



<http://extension.colostate.edu/docs/pubs/natres/natring/Leafy%20spurge%20leaves%20and%20stem2%20JK%20WEB.jpg> https://www.grainews.ca/wp-content/uploads/sites/4/2015/12/IMG_8390spurge5.jpg

Lupine



https://upload.wikimedia.org/wikipedia/commons/0/0c/Lupinus_polyphyllus_LA_2013_G3.jpg

Lupine

Description

Perennial or annual herbs with characteristic palmate leaves. Each leaf has 6-9 narrow leaflets. The flowers are white to blue/purple, pea-like, produced at the end of branches. Seeds are produced in pea-like pods.

Toxic Principle

Quinolizidine alkaloids. Highest concentrations are found in the seeds. Anagyrine is the principle teratogenic alkaloid found in wild lupine species (not in grain lupines). The anagyrine stops uterine motility, constraining fetal movement that results in skeletal deformity. Not all lupine species are poisonous. Lupines are associated with several different poisoning syndromes: 1. Lupin poisoning is a disease most often seen in sheep eating the seeds and pods of certain lupine species. (*L. argentus*, *L. leucophyllus*, *L. leucopsis*, *L. sericeus*) 2. Crooked calf disease (*L. caudatus*, *L. latifolius*, *L. laxiflorus*, *L. sericeus*, *L. sulphureus*.) 3. Lupinosis - a liver toxicosis caused by a fungus growing on lupine stubble. 4. Decreased growth rates due to quinolizidine alkaloids present in grain lupines

Musculoskeletal

Bony deformities of the legs and vertebrae.

Congenital Defects

Deformities of the bones of the legs, vertebrae and cleft palate occurs in calves who consumed lupine during the 40-70 days of gestation.

Treatment

No known treatment

Respiratory System

Sheep eating large quantities wild lupine seeds/pods (1.5% body weight) develop acute respiratory failure and die.

Hepatic System

Lupinosis is a liver disease caused by mycotoxins (phomopsins) produced by a fungus growing on the pods or seeds. Common in Australia but not in North America.)

Special Notes

Since lupines are most toxic in early growth and when seed pods are present, cattle should be kept from grazing the plants at these stages. Pregnant cows should not have access to lupines during the first 3 months of pregnancy, and especially between the 40-70th days of pregnancy.

Animals Affected

Alpacas, cats, cattle, dogs, goats, horses, humans, llamas, poultry, and sheep.



<http://3.bp.blogspot.com/-obCkyU-IgvU/UAXoc5hWZnI/AAAAAAAAACSA/Bz5UNxRGSds/s1600/Lupine08.jpg>

Marijuana



<https://www.growweedeasy.com/sites/growweedeasy.com/files/young-plant-7-finger-leaves.jpg>

Marijuana

Description

Cannabis toxicity in dogs and cats is becoming increasingly common. Cannabis has become legalized for both medicinal and recreational use in many states, leading to increased access and development of more potent forms. As access increases and public opinion of cannabis is changing, toxicity is both occurring more frequently and being reported more readily. An understanding of the available formulations and pharmacology of cannabis can be advantageous in the approach to the intoxicated patient.

Toxic Principle

Marijuana refers to a tobacco-like preparation derived from the *Cannabis sativa* plant. Within this plant, there are more than 100 psychoactive substances known as cannabinoids, which alter neurotransmitter release at cannabinoid receptors CB1 and CB2. Tetrahydrocannabinol (THC) and cannabidiol (CBD) are the predominant cannabinoids with effects at CB1 and CB2 receptors, respectively. Binding of THC at the CB1 receptor produces most of the psychoactive effects seen with cannabis, such as dysphoria, agitation, and hyperesthesia. Binding of CBD at the CB2 receptor generates the immunomodulatory and analgesic effects of cannabinoids. Relative to humans, dogs have fewer CB2 receptors.

Marijuana leaves contain less than 10% THC, however, with selective breeding of the plants, the concentration of THC within the plants is increasing over time. Hashish resin is a more highly concentrated form, containing up to 50% THC. Medical-grade oils and butters contain the highest concentration of THC, with some substances containing over 90% THC.

Clinical Signs

The clinical signs of cannabis ingestion in dogs and cats vary greatly and are dose-dependent. Mild signs include depression, hyperesthesia, mydriasis, ataxia, urinary incontinence, and bradycardia. More severe intoxications can develop severe agitation, hyperexcitability, seizures, hypotension, and can progress to development of coma. These symptoms start within 30-60 minutes of oral ingestion and typically continue for 6-12 hours but can persist for up to 96 hours in severe intoxications.

Treatment

Decontamination is rarely of value for cannabis intoxication. Once patients are symptomatic, induction of emesis is not advised due to the risk of aspiration. Cannabis also has anti-emetic properties that take effect within 30 minutes of ingestion; after this time, induction of emesis is rarely successful. Activated charcoal can be used to bind to THC, however, due to the risk of aspiration in affected animals, it is rarely used.

Animals Affected

Alpacas, cats, and dogs.



<http://4.bp.blogspot.com/-e8XSWXkJhg/UDFxqEbdDTI/AAAAAAAAAGI/wkEY0SqNI6Y/s1600/Male+vs+Female+009.JPG>
<https://www.ismokemag.co.uk/wp-content/uploads/2016/08/marijuana-fundamentals.jpg>

Milkweeds



UGA5087044

Milkweeds

Description

Milkweeds are erect perennial herbs which have either 6-12 cm broad, veined leaves or narrow linear leaves seldom more than 2-4 cm wide, arranged either alternately or in whorls. Most species (except *A. tuberosa*) contain a milky sap or latex. The flowers are produced in terminal or axillary umbels consisting of two, 5-parted whorls of petals, the inner one being modified into a characteristic horn-like projection. The color of the flowers varies amongst species from greenish-white to yellow-red. The characteristic follicle or pod contains many seeds each with a tuft of silky white hairs that aids in its wind born dispersion.

Toxic Principle

Milkweeds contain various toxic cardenolides (cardiac glycosides) that have cardiotoxic effects. The cardenolides act by inhibiting $\text{Na}^+\text{-K}^+\text{-ATPase}$ thereby affecting myocardial conduction and contractility. In addition to the cardiotoxic effects of the cardenolides common to most milkweeds, other glycosides and resinoids identified in milkweeds have direct effects on the respiratory, digestive and nervous systems causing dyspnea, colic and diarrhea, muscle tremors, seizures and head pressing. Milkweeds are most toxic during rapid growth, and retain their toxicity even when dried in hay. Toxicity varies with the species and growing conditions, however all milkweeds should be considered potentially poisonous, especially the narrow-leafed species. Some broad-leafed species that contain high levels of cardenolides include *Asclepias asperula*, *A. labriformis*, *A. eriocarpa*, and *A. curassavica*. The verticillate or narrow leafed species such as the whorled milkweed (*A. subverticillata*), the eastern whorled milkweed (*A. verticillata*) and the plains milkweed (*A. pumilla*) are neurotoxic, although they may have some affect on the cardiovascular system.

Gastrointestinal

Abdominal pain, colic, bloat and diarrhea due to gastroenteritis.

Musculoskeletal

Muscle tremors, weakness and recumbency.

Treatment

There is no specific treatment for milkweed poisoning. Those animals that have not consumed a lethal dose of the plants recover over several days. Affected animals should be moved from the source of the plants and given fresh water, good quality hay and shade. Sedatives, laxatives and supportive intravenous fluid therapy.

Cardiovascular system

Slow irregular heart rate. Heart block may cause sudden death of the animal eating the milkweed.

Respiratory System

Labored and slow respiratory rate.

Nervous System

Animals consuming the narrow-leafed species of milkweed develop severe colic, muscle tremors, incoordination, seizures and respiratory failure prior to death.

Diagnosis

Since there are no specific post mortem signs in animals poisoned by milkweeds, diagnosis is based on identifying the plants in the animals stomach and food source.

Special Notes

Milkweeds remain toxic when dry, and therefore can be a problem when incorporated in hay.

Animals Affected

Alpacas, cattle, goats, horses, and poultry.

Nightshades



http://www.toronto-wildlife.com/Plants/Nightshade_family/ground_cherry_5sh25_081212_640x480.jpg

Nightshades

Description

A hairless, spineless, erect, or trailing, branched annual plant with simple, ovate to lanceolate sinuate-toothed leaves. The flowers have 5 white petals arranged in a 6-10 mm star. The flower clusters arise from a stalk that is situated between leaf nodes. The smooth, round, 5-10 mm fruits are initially green, turning black when ripe. The green fruits are toxic, but the ripe, black fruits are edible. *S. americanum* (huckleberry) is very similar in appearance, and is arguably a variety of *S. nigrum*.

Toxic Principle

Steroidal alkaloids such as solanine have atropine-like effects on the nervous system inhibiting the enzyme acetylcholinesterase. Some nightshades also contain irritants such as saponins that cause salivation and diarrhea. Nightshades may also accumulate toxic levels of nitrate.

Gastrointestinal

Excess salivation, colic, diarrhea.

Musculoskeletal

Muscle tremors and weakness.

Treatment

Supportive therapy including intravenous fluids and electrolytes, intestinal protectants. Physostigmine may be tried cautiously to reverse some of the atropine-like effects.

Cardiovascular system

Slow heart rate, decreased cardiac output, shock, coma, and death

Respiratory System

Labored breathing

Nervous System

Depression, drowsiness, muscle tremors, incoordination.

Renal System

Kidney failure.

Ocular System

Dilated pupils

Diagnosis

Signs of an atropine-like poisoning.

Special Notes

Cooking destroys the toxic alkaloids in members of the nightshade family. Other members of the night shade family including potatoes and tomatoes, hairy nightshade (*Solanum sarrachoides*), cut leaf nightshade (*Solanum triflorum*), and silverleaf nightshade (*S. elaeagnifolium*) are toxic in the green state. Cattle can tolerate nightshades better than horses.



http://ipcc2.orst.edu/mint/images/nightshadem_l.jpg <https://files.growingproduce.com/growingproduce/wp-content/uploads/2018/02/Black-Nightshade-fruit-Photo-by-Bruce-Ackley.jpg>

Pigweed



<http://www.unce.unr.edu/programs/sites/ipm/images/PedrootPigweed.jpg>

Pigweed

Description

Annual plants, with stout, erect stem 30-150 cm tall, usually much-branched and hairy. The leaves are petiolate, ovate to lanceolate and acute at apex. The flowers are monocious in densely crowded spikes 8-20 cm wide, borne in panicles. The flowers are greenish with long, spine-tipped bracts. Many small shiny black seeds are produced.

Toxic Principle

Oxalates and nitrates are present in pigweed. Oxalates and/or possibly other unidentified compounds in *Amaranthus* spp. cause kidney tubular nephrosis and death of the animal. The soluble oxalates in the plant are absorbed from the gastrointestinal tract and bind with calcium in the blood to produce insoluble calcium oxalate. The calcium oxalate is then filtered by the kidneys where it causes an oxalate nephrosis and kidney failure. Pigweed can have as much as 30% oxalate in the dried plant and ruminants eating large amounts of the plant are very likely to be poisoned especially if they have not been exposed to high levels of oxalates previously.

Gastrointestinal

Decreased rumen activity. Pigs may develop abdominal distension due to the accumulation of ascitic fluid.

Musculoskeletal

Muscle weakness and muscle tremors, ataxia, knuckling at the fetlock joints, recumbency.

Treatment

There is no specific treatment other than supportive therapy. Administration of insulin, glucose, and fluids intravenously may help manage the hyperkalemia and renal failure. If the animals urine output stops and creatinine levels remain high despite aggressive fluid therapy, the prognosis is very poor. Nitrate poisoning should be treated with methylene blue.

Cardiovascular system

Death may result from increased serum potassium levels.

Renal System

Renal failure. Marked increase in serum creatinine, blood urea nitrogen and potassium.

Diagnosis

The most characteristic postmortem finding is the accumulation of hemorrhagic fluid around the kidneys in the retroperitoneal space. Nephrosis is often present without the presence of oxalate crystals, suggesting that *Amaranthus* spp. may contain other as yet undefined toxic substances.

Special Notes

Pigweed poisoning may appear very similar to Halogeton, oak poisoning, and ethylene glycol poisoning and should be considered in the differential diagnosis. Oxalate levels remain high in the dried plant. If there is a lot of pigweed remaining in the pasture it is best to cut, gather and burn or remove the plant material from where animals may have access to it. NITRATES: See Kochia weed for comments on managing nitrates in forages for cattle.

Animals Affected

Cattle, goats, poultry, sheep, and swine.

Prince's plume



Prince's plume

Description

A perennial up to 5 feet in height. Stems are branched, the leaves are entire, pinnately compound, from 2-8 inches in length. The inflorescence is showy and plume-like. Individual flowers are yellow, each petal with a claw. The fruit is slender, nearly round in cross-section, with a stipe from 1-3 cm long.

Toxic Principle

Prince's plume will accumulate high levels of selenium. It is consequently seldom eaten by livestock. As an obligate selenium accumulator, its presence in the area is indicative of selenium-rich soils. Other plants in these soils will also contain selenium. Excess selenium in the diet causes abnormal hair and hoof formations as a result of selenium replacing sulfur in keratin, the primary protein in hair and hoof.

Musculoskeletal

Horses, in particular, may become severely lame. Initially circular ridges forms in all feet. As the hoof wall grows out, the ridges may crack and lames can be severe due to laminitis and even sloughing of the hoof.

Treatment

Affected animals should be removed from food or water sources containing more than 5 ppm. Diets containing adequate amounts of sulfur and copper have a protective effect against chronic selenium poisoning. Alfalfa has sulfur-containing amino acids and is a useful food source in areas where forages are high in selenium.

Integumentary System

Chronic selenium poisoning causes loss of the long hairs of the mane and tail.

Diagnosis

Samples of hay or forages containing selenium levels greater than 5 ppm. should be considered potentially toxic. Blood levels of 1-4 ppm are typical of chronic selenium poisoning, whereas serum levels up to 25 ppm have been reported in acute poisoning. Liver and kidney levels greater than 4 ppm. are indicative of selenium toxicosis.

Special Notes

Prince's plume and other obligate selenium accumulator plants are often found in shale rock formations which contain high levels of selenium.

Animals Affected

Cattle, goats, and sheep.



https://upload.wikimedia.org/wikipedia/commons/b/b8/Stanleya_pinnata_USDA.jpg

Poison hemlock



https://upload.wikimedia.org/wikipedia/commons/7/78/Conium_maculatum_s11.jpg

Poison hemlock

Description

Poison hemlock is a coarse, erect, 4-6 feet tall biennial or perennial plant. The smooth, branching stems are hollow, with purple spots especially near the base. The root is a simple carrot-like tap root. Leaves are alternate 3-4 times pinnately dissected, coarsely toothed with a fern-like appearance. The terminal inflorescence is a compound flat topped, loose umbel with multiple, small, white 5-petaled flowers. Fruits are grey-brown ovoid, ridged, and easily separated into two parts. The plant including the root has a strong pungent (likened to mouse urine) odor that makes it generally unpalatable.

Toxic Principle

The two predominant toxic alkaloids are coniine (mature plant and seeds), and gamma-coniceine (young growing plant). The mechanism of action of the Conium alkaloids is complex as they appear to have a profound effect in blocking spinal cord reflexes, and an initial stimulatory followed by depressant effect on the nervous system. Large doses of alkaloid cause skeletal muscle stimulation followed by neuromuscular blockade and paralysis. The effects of coniine are similar to those of nicotine both in the central and peripheral nervous system. In small doses, the alkaloids cause skeletal defects in the developing fetus. The leaves and stems are the most toxic part of the plant prior to the development of the fruits. The seeds are highly toxic and can be a source of livestock poisoning when they contaminate cereal grains fed to livestock. Plants growing in the warmer southern states appear to be more toxic than those in the northern areas. Drought stress increases the alkaloid content of the plant. The Conium alkaloids are detectable in the milk of cows and presumably in the milk of other lactating animals grazing the plant.

Gastrointestinal

Salivation, abdominal pain,

Musculoskeletal

Muscle tremors, and incoordination

Congenital Defects

Deformities of the legs, cleft palate, abnormal curvature of the spine (scoliosis) similar to those caused by lupine poisoning will occur in pregnant cows that eat poison hemlock in the first trimester of pregnancy.

Treatment

No specific treatment. Supportive therapy is indicated

Cardiovascular system

Rapid, weak pulse, cyanosis of the mucous membranes.

Respiratory System

Death from respiratory failure occurs in 2-3 hours

Nervous System

Respiratory paralysis, and coma without convulsions precede death.



<http://www.northfloridaequine.com/wp-content/uploads/2014/01/Equine-Health-Care-in-North-B-Gainesville-Alachua-Newberry-FL-DOC&SIB.jpg> http://4.bp.blogspot.com/_f3H4KkLd0TcBUNtw6K/AAAAAAAAE0/BzuUQj55Y/s600/poison-hemlock-danger.jpg

Ponderosa pine



https://cdn7.bigcommerce.com/s-f74ff/images/stencil/800x800/products/9631/24799/shutterstock_92441587_52714.1509232258.jpg?c=2

Ponderosa pine

Description

Tree 15-45 m. tall, often broad and round-topped with thick, brown bark which separates into cinnamon-brown scales or flakes. Needles are 8-25 cm long in 3's or 2's, yellowish green in color. The cones are sessile, ovoid in shape and 7-15 cm long. The thickened scales have a short, recurved prickle on the apex.

Toxic Principle

The toxic principle has been identified as isocupressic acid, a diterpene acid. Other diterpene acids, and lignols isolated from pine needles may also be involved in causing abortion. The toxins cause a marked decrease in blood flow to the uterus that results in death of the fetus. Cattle appear to eat the pine needles when stressed or when normal forage is scarce such as during winter snow storms. Green or dried needles, and the bark are toxic. Sheep, goats and bison are susceptible to isocupressic acid poisoning. Other species of *Pinus* that contain isocupressic acid with the potential to cause abortion include lodgepole pine, Jeffrey pine, Rocky Mountain juniper (*Juniperus scopulorum*), common juniper, and Monterey cypress (*Cupressus macrocarpa*).

Treatment

Treatment for retained fetal membranes may be necessary.

Renal System

Renal failure due to abietane resin acids in new growth pine needles occurs in cattle.

Reproductive System

Abortion. Cattle consuming pine needles in the last trimester of pregnancy will abort anywhere up to 2 weeks later. Cows develop edematous swelling of the vulva and udder prior to abortion. The fetus is usually autolyzed indicating it has been dead in utero for several days prior to abortion. The incidence of retained placentas following abortion is high. Sheep may have a high incidence of dead lambs after eating pine needles. Agalactia and retained fetal membranes are common in cows that abort.

Diagnosis

Late term abortions and evidence of pine needles being consumed.

Special Notes

Other species of pine tree, spruces, and firs have not been incriminated in causing abortions. Some cypress, and *Pinus radiata* contain isocupressic acid and therefore may cause abortion. The red pine (*P. resinosa*) has not been associated with abortion in cattle. Bald cypress (*Taxodium distichum*) is not known to be toxic.

Animals Affected

Cats, cattle, goats, and sheep.



https://c1.staticflickr.com/9/8519/8486758845_2f49ec67a9_b.jpg

https://upload.wikimedia.org/wikipedia/commons/thumb/8/84/Pinus_ponderosa_var_ponderosa_002_-_Matt_Lavin.jpg/1280px-Pinus_ponderosa_var_ponderosa_002_-_Matt_Lavin.jpg

Purple locoweed



<http://oldwestdailyreader.com/wp-content/uploads/2014/07/OWDR-Locoweed-Oxytropis-Lambertii-02.jpg>

Purple locoweed

Description

Perennial herbaceous plants with long tap root. Leaves are grouped basally 8-12 inches long, odd-pinnate compound and covered with silvery hairs. The flowers are borne on a leafless stalk in a raceme. The flower is white, pea-like, with purple-tipped, pointed keel. The seed pods are erect, stalkless, with a short beak that splits open to release numerous smooth brown seeds. Seeds may remain viable in the soil for 50 years or more. *Oxytropis lambertii*, purple locoweed, is very similar in its habitat and distribution to white locoweed. It differs from white locoweed in that it has purple flowers, generally fewer and smaller leaves and tends to flower immediately after white locoweed is finishing blooming.

Toxic Principle

Locoweed is poisonous at all times, even when dried. Swainsonine, an indolizide alkaloid found in all parts of the plant, inhibits the enzymes alpha-mannosidase I & II which are essential for normal carbohydrate and glycoprotein metabolism in cells. As a result, these carbohydrates (oligosaccharides) accumulate in the cells of the brain and most other organs with the result that normal cell function is impaired. Depending on the duration of locoweed consumption, the affected cells can be permanently damaged. Swainsonine is secreted in the milk of lactating animals and will therefore affect the young animal suckling its mother. Other *Astragalus* and *Oxytropis* Species Reported to Cause Locoism *Astragalus lentiginosus* (Spotted loco) *A. mollissimus* (Woolly, purple loco) *A. wootonii* (Wooton loco) *A. thurberi* (Thurbers loco) *A. nothoxys* (Sheep loco) *A. dyphysus* (Blue loco, rattlewood) *A. earlei* (Earle's loco) *A. argillophilus* (Halfmoon loco) *Oxytropis lambertii* (Purple Point loco) *O. bessyi* (Bessy point vetch) *O. condensata*. Current evidence indicates that swainsonine is in fact produced by one or more fungi that grow within the tissues (endophytes) of the locoweed. Locoweed that does not contain the endophyte *Undifilium oxytropis* (formerly *Embelisia*) does not produce the toxic alkaloid.

Gastrointestinal

Decreased appetites lead to weight loss. The effects of locoweed on the intestinal tract may lead to malabsorption of essential minerals and vitamins. Decreased growth rates resulting in lower weaning weights is a typical finding in calves exposed to locoweed. The decreased growth rate in locoed calves may also be due to the effect of swainsonine on the thyroid decreasing growth hormone production.

Congenital Defects

Calves, lambs, and foals may be born with deformed legs. Abortions and fetal death are common. Hydrops may develop in cows consuming locoweed. Some calves may be born weak and die shortly after birth.

Treatment

There is no effective treatment for locoweed poisoning. Animals should be moved from locoweed pastures. Recovery depends on the duration and severity of the lesions. Locoed horses should be considered permanently affected.

Cardiovascular system

Congestive heart failure (Brisket disease) occurs in cattle consuming locoweed growing at higher altitudes.

Nervous System

Abnormal behavior including sudden changes in temperament, aggressiveness, ataxia, falling over unexpectedly, violent reaction to routine management practices such as putting a halter on, and cattle refusing to go through a chute, are typical of locoed animals. Some horses become very depressed and sleepy. Horses often show more severe neurological effects of locoweed poisoning than cattle and sheep. The unpredictable behavior makes the animals dangerous to work around or ride.

Reproductive System

Decreased fertility in cattle characterized by decreased conception rates and lower calving percentages is the major problem encountered with locoweed poisoning. Semen fertility is decreased in bulls and rams consuming locoweed. Semen of affected bulls and rams may have increased numbers of sperm with proximal droplets, detached or bent tails, and poor motility.

Puncturevine



http://www.florafinder.com/LargePhotos/DI/Tribulus_terrestris-A511BA1401.jpg

Puncturevine

Description

A prostrate, annual weed with recumbent stems which are pubescent and branching occasionally up to 3 feet in length. Leaves are opposite and pinnately compound with leaflets occurring in 4 to 7 pairs, oblong, elliptical, and about 1/2 inch long. Flowers are solitary, occurring in the axils of the leaves with a corolla composed of 5 yellow petals. The fruit is a small, hard, capsule which breaks apart into 5 spiny sections, each having 2 prominent, sharp, woody spines, that resemble a goat head. Puncture vine is similar in appearance to hairy caltrop (*Kallstroemia hirsutissima*), differing in the very hairy leaves and stems of the latter.

Toxic Principle

A number of saponins have been found in the plant. In addition, a fungal toxin in the plant may be associated with hepatogenic photosensitivity in livestock. The development of photosensitivity appears to be secondary to obstruction of the biliary system with a crystalloid substance that causes the formation of microliths(stones). The formation of microliths in the bile ducts causes the retention of phylloerythrin and the development of photosensitivity.

Musculoskeletal

Lameness due to spiny burs.

Treatment

Provide shade and protection from the sun until photosensitization subsides. Mortality is often high.

Integumentary System

Photosensitization, Sheep may develop swelling of the head due to the photosensitization.

Hepatic System

Jaundice. Biliary stasis

Diagnosis

Photosensitivity secondary to cholecystitis.

Special Notes

Puncture vine is not a common problem to sheep unless other forages are scarce.

Animals Affected

Cattle and sheep.



<http://peanut.tamu.edu/files/2012/04/puncturevine-03.jpg>

Russian knapweed



https://upload.wikimedia.org/wikipedia/commons/thumb/4/4c/Rhaponticum_repens_3.jpg/470px-Rhaponticum_repens_3.jpg

Russian knapweed

Description

A creeping perennial with a black, horizontally spreading root system. It is an erect, rather stiff, branching plant ranging 2-3 feet in height. The new leaves and stems are covered with gray hairs (knap). The lower leaves are alternate with toothed margins, while the upper leaves are smaller and entire. The flowers are produced terminally and are typically thistle-like, being purple to white in color. The bracts are papery and spineless. The seeds are chalky white. Unlike Canada thistle for which it can be mistaken, Russian knapweed has no spines or prickles.

Toxic Principle

Recent evidence indicates that a complex compound isolated from yellow star thistle, and also probably present in Russian knapweed (2,3-dihydro-3,5-dihydroxy-6-(H) -pyran-4- (DDMP) is responsible for causing nigropallidal encephalomalacia. The compound inhibits the dopamine transporter system of the brain. The disease is unique to horses affecting very specific areas of the brain (globus pallidus, substantia nigra) that control the muscles of the lips, jaws and tongue. The muscles become hypertonic giving the horse a fixed or wooden appearing facial expression. The affected animal cannot bite-off and chew its food in a coordinated manner. Swallowing however, is unaffected. The toxic dose of green Russian knapweed is 1.8-2.6 kg/100 kg. body weight PER DAY eaten over a 28-35 day period.

Gastrointestinal

Affected horses are unable to prehend and chew their food. Attempts at doing so cause excessive salivation. Horses can swallow if food or water can be moved to the pharynx. Affected horses may learn to immerse their heads into water troughs to get water to the back of their mouth where they can swallow it. Death results ultimately from starvation.

Musculoskeletal

Facial muscles are hypertonic. Severe weight loss due to starvation.

Treatment

There is no known effective treatment for affected horses. Euthanasia is indicated to avoid the animal starving to death.

Respiratory System

Inhalation pneumonia may develop as a result of the animal's attempts at eating and drinking.

Nervous System


Chewing of food (cranial nerves, V, VII, IX) are affected causing hypertonicity of the facial muscles.

Diagnosis

Horses unable to prehend and chew their food are highly suggestive of Russian knapweed and yellow star thistle (*Centaurea solstitialis*) poisoning. Confirmation of the diagnosis is based upon the presence of typical brain lesions of nigropallidal encephalomalacia.

Special Notes

Horses, cattle, sheep and goats find the plant quite palatable. Sheep and goats are useful biological controls of Russian knapweed as they are unaffected by the plant. There is no evidence at this time to show that spotted or diffuse knapweed is toxic to horses.



http://www.whitmancounty.org/Weed/Index_Pages/Images/R.%20Knapweed/russianplant1.JPG<http://slvnoxiousweeds.org/wp-content/uploads/2014/05/russian-knapweed.png>

Russian thistle



© CA Clark

Russian thistle

Description

Annual, with many ascending branches, stems red or with red stripe, growing 2-3 feet in height. The leaves are alternate, fleshy and linear when young, becoming short and stiff, ending in a spine. Small greenish flowers are produced in the axils, with 2 bracts and 5 sepals, that become winged and cover the seed. The mature plant frequently breaks-off at ground level in the fall, and as the classical tumble weed is blown about effectively scattering seed.

Toxic Principle

Can accumulate significant levels of nitrate. In the rumen nitrate is rapidly converted to nitrite, which is absorbed and reacts with hemoglobin in red blood cells, oxidizing it to form methemoglobin which is incapable of transporting oxygen. When over 30-40% of hemoglobin is converted to methemoglobin clinical signs of poisoning become apparent. Death occurs as methemoglobin levels approach 80%. Drought conditions, acidic soils, and soils deficient in sulfur, phosphorous and molybdenum result in nitrate accumulation in plants. Cool, cloudy days enhance nitrate formation in plants.

Musculoskeletal

Staggering gait and recumbency

Treatment

Animals showing signs of nitrate poisoning should be handled carefully to avoid excitement. The preferred treatment for nitrate poisoning is methylene blue solution administered intravenously. The recommended dose range for methylene blue is from 4-15 mg/kg body weight administered as a 2-4% solution. A dose of 8 mg/kg body weight intravenously has been reported to be effective in cattle.

Cardiovascular system

Increased heart rate, brown colored mucous membranes.

Respiratory System

Increased respiratory rate and marked difficulty in breathing.

Reproductive System

Fetal death and abortion may occur at any stage of gestation as a result of the combined effects of decreased placental oxygen transport and the limited ability of the fetus to metabolize nitrite.

Diagnosis

Sudden death of cattle with brown colored mucous membranes and blood due to methemoglobinemia is diagnostic. Nitrate levels should be determined in both the forage and blood of the animal. Nitrate levels in aqueous of the eye of 20-40 ppm should be considered suspect, and over 40 ppm should be considered diagnostic of nitrate poisoning especially if there are corroborating clinical signs and evidence of high nitrate levels in the forage.

Special notes:

Plants or hay containing more than 1% nitrate (10,000 ppm) dry matter are potentially toxic and should be fed with caution. Forages containing more than 1% nitrate should only be fed if the total nitrate intake can be reduced to less than 1% by diluting the nitrate-forage with nitrate-free forages. As total nitrate intake determines the potential for poisoning, both forage and water nitrate levels should be taken into account. Water containing 100ppm or less of nitrate can be considered safe for all classes of livestock assuming that the animals are on a normal diet that does not have high levels of nitrate.

Animals Affected

Alpacas and cattle.

Salt brush



https://plants.usda.gov/gallery/pubs/atco_006.php.jpg

Salt brush

Description

A perennial shrub that is woody throughout, loosely branched, the bark gray, scaly and scurfy. The leaves are mostly alternate, often covered by a white powdery substance. The plants are dioecious with staminate flowers in terminal panicles without bracts. They have a three to five-parted perianth and 3-5 stamens. The pistillate flowers, produced in leaf axils, are subtended by 2 bracts, but are without a perianth. The fruits have 4 conspicuous wings.

Toxic Principle

Saltbush will accumulate high levels of selenium when growing in selenium-rich soils. Animals that eat it and other forages in the area have the potential of developing chronic selenium poisoning. Excess selenium in the diet causes abnormal hair and hoof formations as a result of selenium replacing sulfur in keratin, the primary protein in hair and hoof.

Musculoskeletal

Lameness due to hoof wall deformity and horizontal cracks in the hoof walls. All feet are usually affected.

Treatment

Affected animals should be removed from any food or water source containing more than 5 ppm. Diets containing adequate amounts of sulfur and copper have a protective effect against chronic selenium poisoning. Alfalfa has sulfur-containing amino acids and is a useful food source in areas where forages are high in selenium.

Integumentary System

Animals with chronic selenium poisoning have defective keratin formed in their hair and hooves with the result that the hair breaks off at the point where selenium is incorporated in the hair. The hoof walls have horizontal ridges form where selenium is incorporated in the keratin. These ridges form cracks in time that can cause severe lameness.

Diagnosis

A diagnosis of selenium chronic poisoning is best confirmed by submitting samples of hay or forages for analysis. Selenium levels greater than 5 ppm should be considered potentially toxic. Blood levels of 1-4 ppm are typical of chronic selenium poisoning, whereas serum levels up to 25 ppm have been reported in acute poisoning. Liver and kidney levels greater than 4 ppm are indicative of selenium toxicosis. Hoof wall containing 8-20 ppm is indicative of chronic selenium. Hair samples containing in excess of 10 ppm selenium indicate excessive selenium intake capable of causing toxicity.

Animals Affected

Cattle, horses, and sheep.



<https://delange.org/FourwingSaltbush/Dsc00197.jpg>

Service berry



<http://stevensonintermountainseed.com/wp-content/uploads/2012/07/Saskatoon-Serviceberry-Flc-crop.jpg>

Service berry

Description

Perennial, shrubs to small trees 3-12 feet tall. Leaves are alternate, longitudinally folded, apically rounded, sometimes serrate, deciduous. Flowers are produced in terminal, upright racemes often before the leaves. Flowers are white with 5 sepals and 5 petals. Fruits turn purple when ripe and are edible.

Toxic Principle

Cyanogenic glycosides which are readily hydrolysed by rumen bacteria to free hydrogen cyanide (HCN). All parts of the plant contain the cyanogenic glycosides except the ripe berries. The wilted leaves are more toxic than when fresh. The cyanide blocks the action of the cellular enzyme cytochrome oxidase thereby preventing hemoglobin from releasing oxygen to the tissues. Death results rapidly from anoxia.

Gastrointestinal

Excessive salivation

Treatment

Without stressing the animal, sodium thiosulfate and sodium nitrite should be given intravenously. A mixture of 1ml 20% sodium nitrite and 3ml of 20% sodium thiosulfate should be prepared and given at the rate of 4 ml of the mixture per 100lbs body weight. Sodium thiosulfate should be given orally via stomach using 30gm dissolved in a gallon of water.

Cardiovascular system

Mucous membranes appear pink and redder than normal. Venous blood is cherry-red in color. Stressing the animal rapidly leads to collapse and death.

Respiratory System

Sudden death. If observed early in the course of poisoning, affected animals show difficulty in breathing. Open mouth breathing is common as the animal becomes oxygen deprived.

Nervous System

Excitement and nervousness result from the animal's rapidly developing anoxia.

Reproductive System

Pregnant animals may abort if they survive the cyanide poisoning themselves.

Diagnosis

Rumen contents or plant material can be tested for cyanide using the sodium picrate test. Commercial test kits for cyanide are available.

Animals Affected

Cattle, goats, and sheep.



http://hgtvhome.sndimg.com/content/dam/images/grdn/fullset/2014/12/21/0/CI_8-bn-serviceberry.jpg.rend.hgtvcom.1280.853.jpeg <http://www.permacultureeden.com/wp-content/uploads/2014/11/AmelanchierOvalisFruit.jpg>

Snakeweed



<https://www.bamertseed.com/wp-content/uploads/2017/07/Broom-Snakeweed-00.jpg>

Snakeweed

Description

Perennial which is shrubby or woody only at the base, attaining 18-24 inches in height. The stems are branching, the leaves are linear and glabrous. The heads are many, usually in clusters at the ends of branches. A given head will have no more than 3-8 ray flowers and 3-8 disc flowers. The flowers are yellow with the disc flowers usually perfect. The corollas are 5-lobed and the pappus is composed of several to many oblong scales. Often forms dense stands especially in overgrazed rangeland.

Toxic Principle

Saponins are believed to be the toxic component of snakeweed. Both the green and dried plant are toxic, although there appears to be considerable variability in toxicity.

Gastrointestinal

Diarrhea followed by constipation.

Musculoskeletal

Loss of weight

Congenital Defects

Abortions. Calves may be born alive and weak, and may die after a few days.

Treatment

There is no specific treatment. Affected animals should be removed from the snakeweed and given supportive care.

Reproductive System

Abortions, retained fetal membranes. May also decrease male fertility.

Hepatic System

Liver necrosis and degeneration may be seen at post mortem examination.

Diagnosis

Abortions, liver necrosis, access to snakeweed.

Animals Affected

Horses, cattle, sheep, and goats.



<http://www.naturesongs.com/vvplants/broomsnakeweed6.jpg> <http://www.swcoloradowildflowers.com/Yellow%20Enlarged%20Photos/3gumi.jpg>

Woody aster



http://hasbrouck.asu.edu/imglib/seinet/Asteraceae/photos/Chaetopappa_ericoides_020207_3.jpg

Woody aster

Description

Erect perennials up to 2 feet in height, arising from a woody base and tough tap root. Leaves are hairy, linear-oblongate and tipped with a callus point. The ray flowers are white.

Toxic Principle

Woody aster will accumulate high levels of selenium. It is consequently seldom eaten by livestock. As an obligate selenium accumulator, its presence in the area is indicative of selenium-rich soils, and other plants in these soils will also contain selenium. Excess selenium in the diet causes abnormal hair and hoof formations as a result of selenium replacing sulfur in keratin, the primary protein in hair and hoof.

Musculoskeletal

Horses, in particular, may become severely lame. Initially circular ridges forms in all feet. As the hoof wall grows out, the ridges may crack and lames can be severe due to laminitis and even sloughing of the hoof.

Treatment

Affected animals should be removed from food or water sources containing more than 5 ppm. Diets containing adequate amounts of sulfur and copper have a protective effect against chronic selenium poisoning. Alfalfa has sulfur-containing amino acids and is a useful food source in areas where forages are high in selenium.

Integumentary System

Chronic selenium poisoning causes loss of the long hairs of the mane and tail.

Diagnosis

Samples of hay or forages containing selenium levels greater than 5 ppm. should be considered potentially toxic. Blood levels of 1-4 ppm are typical of chronic selenium poisoning, whereas serum levels up to 25 ppm have been reported in acute poisoning. Liver and kidney levels greater than 4 ppm. are indicative of selenium toxicosis.

Animals Affected

Cattle and horses.



<http://www.rockymountainsflora.com/details/White%20Simple/Porter%20Aster-83.JPG>

Yellowstarthistle



https://www.minnesotawildflowers.info/udata/r9ndp23q/contrib/centaurea-solstitialis_plant1_12094183085-hr.jpg

Yellow starthistle

Description

An annual herbaceous weed, branching from the base up to 3 feet tall. The branches are winged. Leaves are densely haired. The basal leaves are deeply lobed, while stem leaves are small and entire. The yellow disc flowers are surrounded by stiff spines 1-2cm long. The plant spreads via its seeds that are dispersed when the plant is incorporated in hay. The seeds may also pass through the intestinal tract of horses and remain viable in the manure.

Toxic Principle

Recent evidence indicates that a complex compound isolated from yellow star thistle, and also probably present in Russian knapweed (2,3-dihydro-3,5-dihydroxy-6-(H) -pyran-4- (DDMP) is responsible for causing nigropallidal encephalomalacia. The compound inhibits the dopamine transporter system of the brain, and uniquely affects horses. The toxin specifically acts on the dopaminergic nigrostriatal pathway that has a coordinating and inhibitory effect on the nerves affecting prehension and chewing of food (cranial nerves, V, VII, IX affected). The facial muscles become hypertonic giving the horse a fixed or wooden appearing facial expression. Affected horses cannot bite-off and chew their food in a coordinated manner. Swallowing however, is unaffected. The plant is toxic in the green, and dry state to horses only. The toxic dose of green plant is equivalent to the body weight of the horse eaten over a period of weeks. Thus horses can eat the plant without becoming poisoned as long as they do not consume the plant continuously. Horses however find the plant quite palatable.

Gastrointestinal

Often referred to as 'chewing disease' because affected horses try endlessly to bite-off, hold and chew food without success. The mouth may be held open and the tongue protrudes or is curled from side to side. Horses act as if they are 'choked'. Mouth abrasions and ulcers may also develop as a result of trauma to the gums and tongue. Weight loss can be severe.

Musculoskeletal

Hypertonicity of facial muscles affecting normal movement of the lips, cheeks and tongue. Weight loss is severe as the horse cannot eat. or drink.

Treatment

There is no known effective treatment. The brain lesions are permanent. Euthanasia is recommended to avoid the horse starving to death.

Respiratory System

Inhalation pneumonia may develop as a result of the animal's attempts at chewing and swallowing food.

Nervous System

Prehension and chewing of food (cranial nerves, V, VII, IX) are affected causing hypertonicity of the facial muscles.

Diagnosis

Horses unable to prehend and chew their food are highly suggestive of Russian knapweed and yellow star thistle poisoning. Confirmation of the diagnosis is based upon the presence of typical brain lesions of nigropallidal encephalomalacia.

Animals Affected

Cat, goats, and sheep.

Common burdock

Physically hazardous



http://courses.missouristate.edu/pbtrewatha/Common_Burdock4.JPG

Common burdock

Description

Burdock is a biennial, robust plant with stout taproot. Stems are erect, much branched, and reaching a height of 5-6 feet. Basal leaves are large (12 inches wide, 24 inches long), heart-shaped, with stout hollow stems. Upper leaves are progressively much smaller. Characteristic flowers are produced in clusters at the ends of branches, and have petals that are pink, purple or occasionally white. The fruit is covered by stiff, hooked spines.

Toxic Principle

Burdock is not toxic but because of its spiny burs it can become attached to animals fur and cause trauma. Burs attached to eye lashes in horses can cause corneal ulcers. Sheep with burs in the wool bring reduced value to their fleece at shearing.



<https://bybio.files.wordpress.com/2013/01/buck-2.jpg>



Foxtail



<https://static1.squarespace.com/static/57dcl17803596e07ba9b9bfb/58892513e58c62bad6cd4839/5889251317bffc4169a8f0de/1485385595886/Foxtail+barley+Phillips.jpg>

Foxtail

Description:

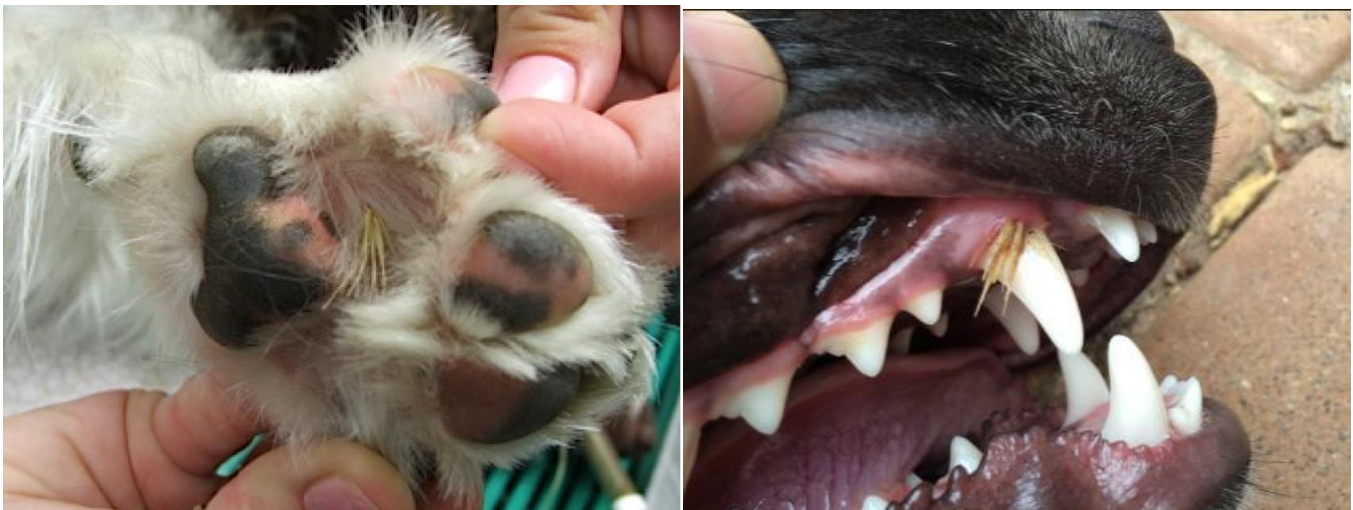Foxtail barley is a showy short-lived native perennial cool season bunchgrass that belongs to the grass tribe Triticeae. This plant ranges in height from one to three feet tall at maturity. It is often found in pastures, roadsides, meadows, alkaline/saline areas, moist soils and disturbed areas.

Foxtail barley seeds are arrow-shaped awns, made up of razor-sharp needles. Nature designed them this way so they can plant themselves in the ground and start burrowing beneath the surface to grow. Unfortunately, they do the same thing if they get on your dog's skin, or get snuffed up, ingested or land in his ears.

Foxtail Hazards:

- Foxtails inhaled through the nose can make their way into your dog's brain causing seizures or death.
- Foxtails picked up through the skin can make their way to vital organs, such as piercing their lungs.
- Swallowed Foxtails can get stuck in your dog's airway. They can puncture the throat or cause them to choke to death. They can cause pulmonary aspiration if they have bacteria on them and get into the lungs.
- Foxtails entering anywhere can cause infection from bacteria and even fungus that are on the Foxtail awn.
- Foxtails in the ears can rupture the eardrum, cause chronic ear infections and can require surgery.
- Foxtails in the eyes can cause blindness.
- Foxtails have even been found to introduce an infection of the spinal vertebra and discs (called Discospondylitis) to dogs.

Various other infections, inflammations and issues can be caused by foxtails. Autopsies on deceased dogs have found Foxtails in practically every vital organ including heart, brain, lungs, liver, and glands.



<http://www.viralandmore.com/wp-content/uploads/2016/05/Foxtail-6.png><http://gooddogcoaching.com/wp-content/uploads/2017/01/foxtail-7.jpg>

Downy brome (Cheatgrass)



<https://cheatgrass.byu.edu/portals/146/Images/cheatgrass.JPG?ver=2017-06-26-095837-817>

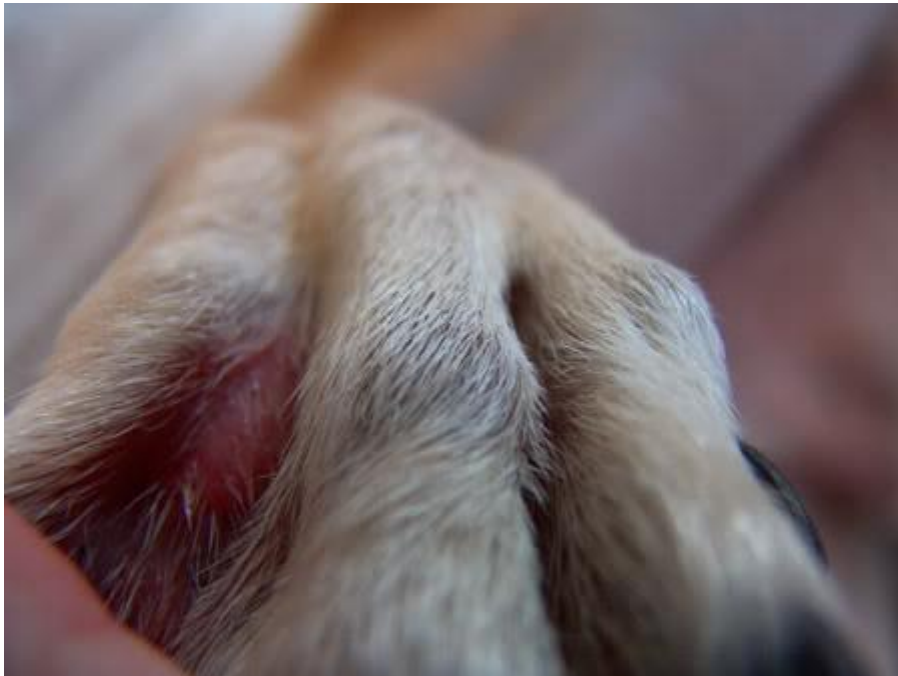Downy brome (Cheatgrass)

Description:

Downy brome or Cheatgrass is an annual or winter annual, native to the Mediterranean region. Cheatgrass ranges in height from 2 to 36 inches. Each plant contains multiple stems that are erect in nature. The inflorescences are born at the end of the stems, and are multi-branched. They appear in a slender, dense, and usually drooping manner. At maturity, they appear greenish purple in color. The spikelets are slender, 3/8 to 3/4 of an inch long and are nodding. The awns on the end of the spikelets are usually 3/8 to 5/8 of an inch long. The sheaths of the leaves are flat blades and densely covered in with soft hairs. Cheatgrass reproduces solely by seed. The root system is fibrous and fleshy.

Hazard:

These annoying and troublesome weeds have been found in the skin, between the toes (very common), and in the eyes, ears, mouth, and vulva—basically, anywhere on the body. They can even work their way through the skin to interior body cavities, such as lungs and abdomen, sometimes causing very serious infections as they migrate through, and get lodged in, body tissues. It is important not to underestimate the potential seriousness of this common problem.



http://s959.photobucket.com/user/Chelsea_shea/media/Baileyallergies046.jpg.html

Index

Arrow grass	Page 6, 7
Blake henbane	Page 8, 9
Bracken fern	Page 10, 11
Buffalo bur	Page 12, 13
Choke Cherry	Page 14, 15
Cocklebur	Page 16, 17
Curly dock	Page 18, 19
Curlycup gumweed	Page 20, 21
Dalmatian toadflax	Page 22, 23
Death camas	Page 24, 25
False hellbore	Page 26, 27
Flixweed	Page 28, 29
Foxglove	Page 30, 31
Gambel oak	Page 32, 33
Greasewood	Page 34, 35
Hairy vetch	Page 36, 37
Halogeton	Page 38, 39
Houndstongue	Page 40, 41
Smooth scouringrush	Page 42, 43
Indian hemp	Page 44, 45
Iris	Page 46, 47
Kochia	Page 48, 49
Lambs quarter	Page 50, 51
Larkspur	Page 52, 53
Leafy spurge	Page 54, 55
Lupine	Page 56, 57
Marijuana	Page 58, 59
Milkweeds	Page 60, 61

Nightshades	Page 62, 63
Pigweed	Page 64, 65
Prince's plume	Page 66, 67
Poison hemlock	Page 68, 69
Ponderosa pine	Page 70, 71
Purple locoweed	Page 72, 73
Puncturevine	Page 74, 75
Russian knapweed	Page 76, 77
Russian thistle	Page 78, 79
Salt brush	Page 80, 81
Service berry	Page 82, 83
Snakeweed	Page 84, 85
Woody aster	Page 86, 87
Yellow starthistle	Page 88, 89
Common burdock	Page 90, 91
Foxtail	Page 92, 93
Downy brome	Page 94, 95