



Histopathological Studies on Common Carp (*Cyprinus carpio* L.) Infected with *Saprolegnia* sp. and Treated With Virkon® S

Ahmad A. Ashour^{1*}; Sanaa A. Mustafa¹; Shaimaa N. Yassein²

¹ Pathology Department, College of Veterinary Medicine, University of Baghdad, Iraq

² Microbiology Department, College of Veterinary Medicine, University of Baghdad, Iraq

ARTICLE INFO

Received: 28.11.2016

Revised: 24.12.2016

Accepted: 28.12.2016

Publish online: 25.01.2017

*Corresponding author

contact Email address:

alfao8382@yahoo.com

Abstract

Fungal infections are the most common critical diseases responsible for mortality and several economic losses in fish aquarium culture industries. This study intends to investigate the effect of Virkon® S against *Saprolegnia* infection on commercially valuable freshwater fish (*Cyprinus carpio* L.). A total number of 100 fishes infected with skin white-grayish patches of cottony fungal growth, were

collected from aquaculture in Babel/Iraq. The fungal isolation was done from different parts of the body using the routine technique. *Saprolegneous* fungi (*Saprolegnia* sp.) was isolated from all collected specimens. Pathogenicity of the isolated fungi was tested on host fish with a concentration of 2×10^4 zoospores L-1 and the fishes were got the infection. Virkon® S (LC50=537.03mg/mL) at varying concentrations (75, 175, 375 mg/L and control) was used to control the experimental fungal infection in fish. In addition, formalin (0.15 ml/L) was used as a reference agent to test their potency in controlling the fungal infection. Tissue samples were collected from different treatment groups for histopathological studies. Varying degree of destruction in the tissue were seen in the treated and infected fishes. The skin of the infected fish showed loss of epidermis, necrotized hypodermis and penetration of hyphae in the underlying musculature. However, the treated fish with Virkon® S. Gills showed less severe changes in compare to control group. These changes were including degeneration of lamellae, telangiectasis, epithelial lifting, epithelial hyperplasia, hypertrophy, a fusion of the secondary lamellae, vasodilation with blood congestion of blood vessels and cellular necrosis with epithelium rupture. Quantitative analysis of Gill revealed that histopathological changes were significantly increased ($P < 0.05$) in fish treated with Virkon® S and formalin in compare with control and with infected fish group. In conclusion, this study approved the potency of the Virkon® S in controlling and preventing saprolegniasis in fish. The authors recommend a further future investigation to develop new alternative control strategies against *Saprolegnia* sp. in Iraq.

To cite this article: Ahmad A. Ashour; Sanaa A. Mustafa; Shaimaa N. Yassein. (2017). Histopathological Studies on Common Carp *Cyprinus carpio* L. Infected with *Saprolegnia* sp. and Treated With Virkon® S. MRVSA. 6 (1), 19-30.

DOI: [10.22428/mrvsa.2307-8073.2016.00613.x](https://doi.org/10.22428/mrvsa.2307-8073.2016.00613.x)

Key words: *Cyprinus carpio*, formalin, necrotized hypodermis, *Saprolegneous* fungi, Virkon® S,

Introduction

Fish aquaculture has evolved into the world's fastest growing food sector. With increasing fish production, the control and decrease of health problems in the production chain are supreme for the future success of the aquaculture intensity. It has been established that the greatest losses of fish are caused by infectious diseases (Hussein *et al.*, 2001). Fungal infections are one of the key factors responsible for mortality and several economic losses in fish culture industries (Bruno *et al.*, 2011). The most commonly identified fungal pathogen are water molds of *Saprolegnia* genus which considered as an agent of secondary infection arising from conditions such as bacterial infections, poor husbandry including poor water quality and adverse water temperature. All these factors increased the occurrence of *Saprolegnia* infections (Ruthing, 2009). Saprolegniosis are restricted to chronic stable losses (Bruno and Wood, 1999; Pickering and Willoughby, 1982). It causes 50% mortality in Salmon fish (Ali, 2009) and 50% losses in *Anguilla anguilla*. Besides, it is responsible for 50% losses in channel catfish in USA (Bruono and Wood,1999), and also affect other species of fish such as tilapia (*Oreochromis niloticus*) in hatchery and fingerlings stages (Easa and Amin,1987; Ogbonna,1989; Aly and El Ashram,2000).

Several medications have been used to diminish the economic losses and reduce the number of fish suffering from this disease. However, there is a critical requirement for new information and new treatment against saprolegniasis. Moreover, the understanding of pathogenicity, pathogenesis, and efficient testing methods are of vital importance when searching for new treatment. Malachite green and formalin are the most effective fish fungicides although they have an acute impact on the aquatic environment (Albert *et al.*, 2013). These include an immune suppression on frequently treated fish (Prost and Spinska, 1989), mutagenic and teratogenetic effects due to hazardous deposits in fish organs (Meyer and Jorgenson, 1983; Fitzpatrick *et al.*, 1995; Meinert *et al.*, 1995; Bruono and Wood, 1999).

Consequently, these reasons encourage several researchers to investigate the use of safer products that have no detrimental effect on fish or on environment (Hussein *et al.*, 2001). Review of literature revealed paucity in the information regarding fish saprolegniasis treatment in Iraq. Therefore, this study designed to emphasis on saprolegniasis as major fungal diseases affect freshwater fish (common carp) and also studying the histopathological alterations in selected organs. As well as, to determine the best preventive trial to control saprolegniasis using effective and less hazardous medication to both environment and personal such as Virkon® S.

Materials and Methods

Isolation and Identification of *Saprolegnia* sp. Isolation of *Saprolegnia* sp. from infected Fish

A total number of 100 infected *Cyprinus carpio* that showed external cotton wool like fungoid lesion and ulcerations on the body were collected from aquaculture in Babel/Iraq. These fish brought to the laboratory in sterilized polyethylene bags for

further examination. The infected collected fishes were kept separately in aquaria with continuous aeration. Later on, fish were inspected carefully for visible fungal lesions, and the lesions usually were observed as mycelia growth on the pectoral, caudal fins or skin (white cotton wool). The infected areas were excised and rinsed three times with sterilized distilled water. The infected areas were transferred to a sterile Petri dish containing 15 mL of a/c dH₂O. Later on, sterilized sesame seeds (*Sesamum indicum*) were added as a bait substrate. After that the plate incubated at 20°C and were colonized by spores or mycelia for 24 to 72 hours. Single colonized sesame seeds were aseptically transferred to a/c Sabouraud Dextrose agar (SDA). The medium was augmented with antibiotics [(Ab-SDA), (Chloramphenicol at concentration 0.05 g/L)] to prevent contamination and obtain a pure culture. After that, culture plates were incubated for 3-5 days at 20°C, before a transfer of a mycelia plug from the edge of the colony to a fresh Ab-SDA plate. These procedures were repeated at least three times to obtain a pure single culture isolate growing on SDA (Cayla, 2014).

Isolation of *Saprolegnia* sp. from Water Media

Water samples were collected from Tiger River of Baghdad/Iraq and using Baiting technique for isolation of aquatic fungi. About 15- 20 mL of river water was poured into a sterile petri dish containing Chloramphenicol. Then, Sesame seeds were added (5-7 seeds/ petri dish) (Muhsin, 1977). The petri dish incubated at 20 °C for 7 days and was examined every 24 h using a dissecting microscope to observe the Coenocytic hyphae. Slides were prepared from each colony by taking a small tuft of mycelium and stained with Lacto-phenol cotton blue. The slides were observed under a microscope. Identification of fungi was carried out according to a method by Willoughby, (1985).

Experimental Design of Artificial Infection.

A total number of 120 healthy *C. carpio* with an average weight (100 ± 5 g), were obtained from a commercial fish farm of Babel, Iraq. The fishes were dipping in the bath of NaCl 5% until the appearance of the stress on fish. After that, fish were acclimatized for two weeks prior in laboratory conditions. Later on, the fishes were randomly transferred to 12 plastic tanks (10 fish tank⁻¹) and subdivided into 6 treatment groups in duplicate (2 tanks treatment⁻¹). The treatment groups were as follow:

C1: control group/ The fish were kept in chlorine free tap water without exposed to *Saprolegnia*

C 2: The fish were kept in chlorine-free tap water and were injured manually in their skin using a sterile needle with exposure to 2x10⁴ zoospores L⁻¹ of *Saprolegnia*.

T1,T2,T3 and T4: The fish were exposed to 2x10⁴ zoospores L⁻¹.

The chemo-physical parameters of the water were measured during the experimental period (Table 1). Each of the six treatment groups was fed the formulated diets at a daily rate of (1%) body weight throughout the experiment. The experimental fish were preserved under (12 h) light/dark cycle. Every day after feeding (about one

hour) the tanks were cleaned, and the remnants were removed. Both infected and controlled groups were kept under observation for 4 days until the appearance of cotton wool like lesion over the bodies of fish. Consequently, the fishes were treated as follows:

C1: control healthy without treatment

C 2: control infected with *Saprolegnia* without treatment

T1 : fish were infected with *Saprolegnia* and treated with Virkon S 75 mg/ L for 10 min. for 5 successive days

T2: fish were infected with *Saprolegnia* and treated with Virkon S175 mg/L for 10 min. for 5 successive days

T3: fish were infected with *Saprolegnia* and treated with Virkon S 375 mg/ L for 10 min. for 5 successive days

T4: fish were infected with *Saprolegnia* and treated with formalin 0.15 ml/ L for 60 min for 5 successive days.

Then the samples were collected after 7 days from treatment.

Table 1. Shows the average data of physical-chemical parameters of water used during the experimental period.

Water quality parameter	Value (mean±SE)
Temperature	20±1.0 °C
DO	6.90± 1.0 mg l ⁻¹
PH	7.30±0.50
Ammonia	0.02±0.00 mg l ⁻¹
Hardness	210±3.50 mg l ⁻¹

Histopathological Studies

The histopathological examinations were carried out as described by Myers *et al.* (1998). Fish were removed from their tanks and dissected out (6 fish treatment-1). The infected tissue of liver, skin with muscles and gills, were immediately fixed in 10% formaldehyde solution for 48 -72 hours. The tissues were then processed

routinely and prepared into paraffin blocks. The blocks of the tissues were cut at 5-7 µm thickness and stained with Haematoxylin and Eosin (H&E). Some of the sections were stained with Periodic Acid Schiff (PAS) to show the hyphae. The tissue sections were examined by a light microscope and photographed using Optika Vision Microscopy Digital UBS camera. Detailed descriptions of pathology were done the according to Bernet *et al.*, (1999). For the gill tissues, histological features were recognized, measured when appropriate and the number of lamellae was counted. Only those secondary lamellae that were complete from base to tip, were considered for analysis according to Mustafa, (2012). A quantitative assessment of lesions in a histopathological investigation was done through practical statistics (ANOVA).

Results and Discussion

Saprolegnia sp. Isolation

The results of mycological isolation revealed 179 isolates out of 100 infected *Cyprinus carpio* samples of skin, gills, fins and liver. These isolates showed higher percentage from skin (42.45%), followed by fins (37.98%) and gills (18.55%). However, no growth was recovered from liver (Figure 1 A&B and Table.2). The colonies isolated from water media that provided with sesame seed were appeared after 3-5 days from culturing as small growth about (1-1.5 cm) in diameter and whitish in color. The positive colonies on (SDA) at 20°C for 24-48 h started with circular in shape with white cottony color and brownish in the center. Moreover, it was characterized by an extensive and dense mycelium (Figure. 1 C & D).

The asexual reproduction, of the current fungus isolate, was characterized by the presence of branched non-septate hyphae together with masses. These hyphae revealed different length and width, transparency and surrounded by the cell membrane. The zoosporangia were filled with large number of spores which separated from the basal somatic hyphae by (Saprolegnoid). These morphological findings were compatible with typical characteristic features of the *saprolegnia* species as shown in (Figure 1 E&F).

Table 2. Shows the incidence of *Saprolegnia* sp. isolated from different organs of *C. carpio*.

Fish species	organs	skin	fins	gills	liver	Total
100 infected <i>C. carpio</i>	No. of samples	100	100	100	100	400
	No. of isolates	76	68	34	0	179
	%	42.45	37.98	18.55	0	98.89

All isolated fungi from fish or water revealed its ability to infect the fish experimentally, and the results of the current study showed the pathogenicity of the isolates. The mycological examination of the isolated fungi revealed that *Saprolegnia* isolates were branched and non - septate. These results are in agreement with previous studies (Marzouk *et al.*, 2003) and Burno and Stamp, (1987), who observed that the shape of the colony was circular, whitish in color, 1-1.5 cm in diameter with brownish color in the center bezel to black.

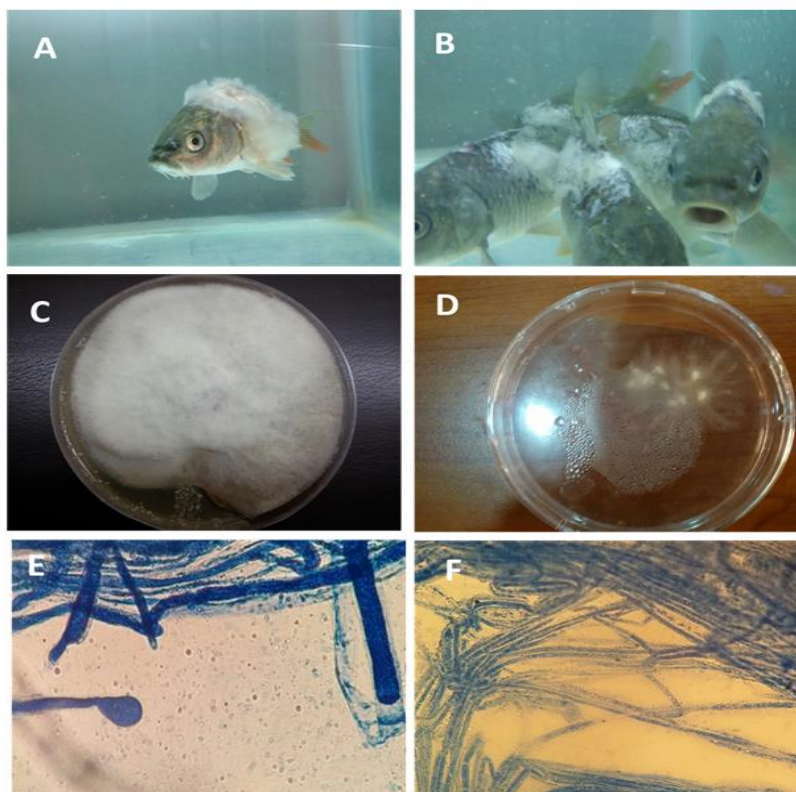


Figure.1:Shows: A& B: Cotton wool like lesion on pelvic, dorsal and caudal fins (tail) ; C: The positive colonies on (SDA) at 20°C for 3-4 days started circular of long hairs with white cottony color; D: Wet culture of developed *Saprolegnia* on sesame seed; E: part of sesame seed colony stained with lactophenol cotton blue showed masses of zoosporangia filled with large number of zoospores; F: the hyphae appeared abundantly split and were non septate, these morphological findings were characteristic of the *saprolegnia* species.

The growth of *Saprolegnia* isolates from water media with sesame seed, appeared as small growth after 3-5 day. It was about (1-1.5 cm) in diameter and whitish in color and increased in size after 1-2 days. These results are compatible with previous observations recorded by Muhsin, (1989) who, use sesame seed for the first time instead of *Cannabis sativa* L. (Coker, 1923; Seymoure, 1970) to grow *Saprolegnia*. Microscopically, hyphae appeared branched non-septate, together with masses, different in length and width, transparent and have cell membrane. All family of *Saprolegniaceae* revealed these characteristics features as explained by Coker, (1923). In this study, the isolated strain was classified as *Saprolegnia* sp. according to their morphological criteria including cenocytic hyphae, absence of oogonia and anethredia (sexual stage) and the presence of zoosporangia (Figure. 1 E), which is renewed by Saproleginoid. All these feature are in agreement with Seymour, (1970). Meanwhile, the isolates considered as *Achlya* genus, if the zoosporangia formed

beside the hyphae and the spores will kick off by *Achlyoid*. These observations are compatible with Coker (1923); Seymour (1970) and Muhsin, (1977).

Histopathological studies

Gill

The morphology of the gills of control group exhibited typical structures where epithelial cells were lined the lamellae (Figure 2.A). Identical lesions were appeared on all fish infected with *Saprolegniasis* and infected groups treated with Virkon S and formaldehyde solution. However, the extent of the gills damage was not severe in fish treated with Virkon S and formalin in compare to gill of infected group without treatment (Figure. 2 &3B-H). The quantitative analysis of gills revealed telangiectasis, epithelial lifting, epithelial hyperplasia, hypertrophy, a fusion of the secondary lamellae, and vasodilation with blood congestion of blood vessels and cellular necrosis with epithelium rupture. These histopathological alterations were significantly increased ($P < 0.05$) in groups (T1, T2, T3) and (T4) treated with Virkon S and formalin respectively (Table3; ANOVA; $P < 0.05$) in compare to the control groups (C1) and with infected group (C2). These histopathological changes might occur as a defense mechanism. Besides, these histopathological alterations are non-specific and common to different environmental stresses and a range of contaminants (Mallatt, 1985). These findings are justified by reports of Hussian *et al.*, (2013) and Refai *et al.*, (2010). Similar results were observed by El genaigy *et al.*, (2004) and El Ashram *et al.*, (2007). The results of the present study revealed a varying degree of histopathological changes and destructions. These results are compatible with previous histopathological manifestations that reported by other researchers due to mycotic infection (Chauhan *et al.*, 2014; Songe *et al.*, 2016).

Skin

Various types of destructions were seen in the *C. carpio* skin and muscles sections infected with *Saprolegnia*. Moreover, loss of epidermal layer with complete necrotizing of dermis and hypodermis also were seen. Muscle cells were completely lost their original appearance and hyphal granulomas were observed (Figure. 4 B-D). In addition, penetrating fungal hyphae were clearly observed in the skin layer (Figure 5E). The Skin of treated *C. carpio* groups both with Virkon S and formalin revealed an increase of mononuclear cells (MNCs) and slight sloughing of the most superficial layer of the epidermis, which indicating the disappearance of the causative agent (Figure. 4 F). These results are in agreement with observation reported previously by Amin *et al.*, (1985) and Ferguson, (1989). Moreover, these results are compatible with other researchers (Hatai and Hoshiai, 1994; Hussian *et al.*, 2013; Chauhan *et al.*, 2014).

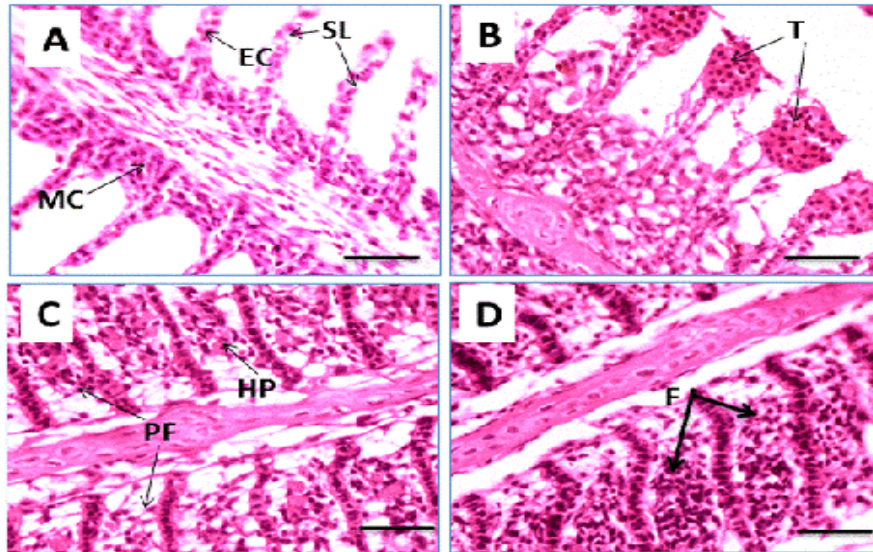


Figure.2. Shows the histology of gill of *C. carpio* L.[A] normal aspect showing secondary lamellae (SL) , epithelial cell (EC), mucous cell (MC) of the gill; B-D infected and treated groups. [B]revealing telangiectasis at the tips of the secondary lamellae (T); [C] partial fusion of the secondary lamellae (PF) with cellular hyperplasia (HP); [D] complete fusion of the secondary lamellae (F): (H&E at 5-8 μ m, Scale bars: 50 μ m).

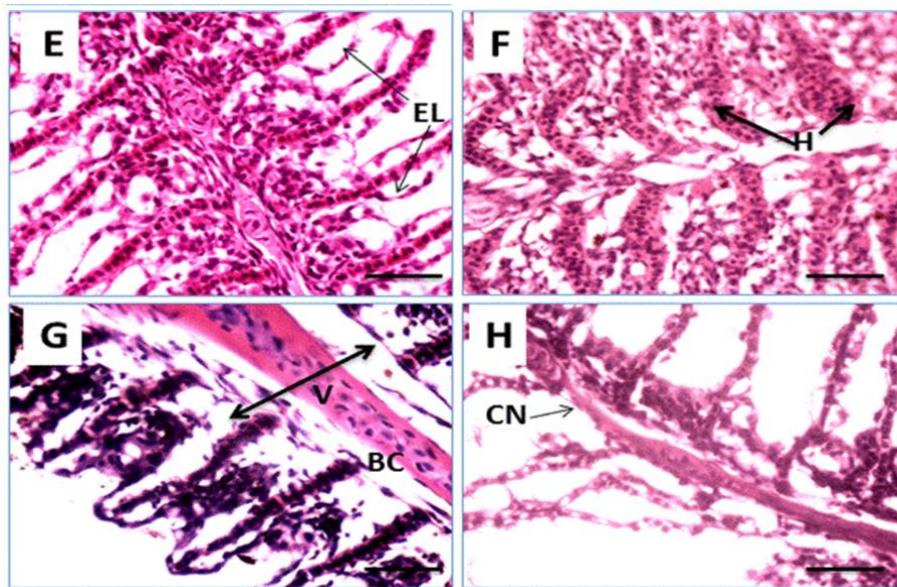


Figure.3: Shows the gill of *C. carpio* L. [E] the epithelial lifting (EL); [F] epithelial hypertrophy (H); [G] vasodilation (V) with blood congestion (BC) ; [H] cellular necrosis and epithelium rupture (CN). (H&E at 5-8 μ m, Scale bars: 50 μ m).

Table 3: Shows the histopathological changes presented as a percentage in the gills of *C. carpio L.* infected with *Saprolegnia* and treated with Virkon S and with formalin for 5 successive days.

Lesion (%)	C1	C2	T1	T2	T3	T4
Hyperplasia	3.40±1.35 ^a	15.00±2.05 ^b	30.00±4.00 ^c	36.00±4.05 ^c	42.00±1.05 ^d	39.00±6.09 ^d
Lifting epithelium	0.00±0.00 ^a	22.00±3.00 ^b	28.00±5.04 ^c	32.40±5.04 ^c	42.00±1.05 ^d	29.40±5.05 ^c
Fusion	01.00±0.05 ^a	16.00±1.00 ^b	22.00±3.50 ^c	27.40±4.09 ^c	37.00±5.08 ^d	35.00±6.50 ^d
Aneurism	2.00±0.04 ^a	12.00±3.05 ^b	8.40±3.05 ^c	11.00±3.00 ^b	12.40±4.05 ^a	14.00±3.05 ^b
Necrosis	0.00±0.00 ^a	11.00±1.00 ^b	2.40±0.06 ^c	2.00±0.55 ^c	2.00±1.00 ^c	6.40±1.07 ^d

Data are mean ± S.E. Groups with different alphabetic superscripts indicate significantly different at $P < 0.05$; (n=6). C1: control healthy without treatment; C2: control infected with *Saprolegnia* without treatment; T1: fish were infected with *Saprolegnia* and treated with Virkon S 1.5 g/20 L for 10 min; T2: fish were infected with *Saprolegnia* and treated with Virkon S 3.5 g/20 L for 10 min; T3: fish were infected with *Saprolegnia* and treated with Virkon S 7.5 g/20 L for 10 min; T4: fish were infected with *Saprolegnia* and treated with formalin 10-15 ml/100 L for 30 min.

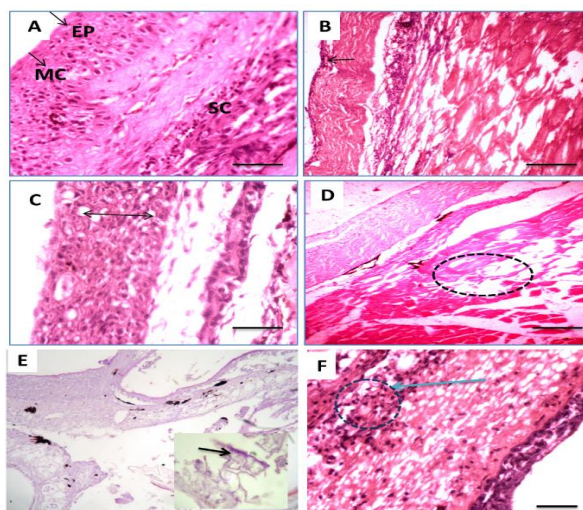


Figure.4: Photomicrograph of the skin of *C. carpio L.* [A] showing normal histology of the skin epidermis (EP), mucous cell (MC), stratum compactum (SC); [B] showing loss of epidermis, necrotized hypodermis; [C] increasing of mucous cells; [D] degenerated muscular layer and muscles completely lost their appearance; [E] Penetrating fungal hyphae were obviously observed in skin layer; [F] treated group with Virkon with formalin showed increase of mononuclear cells (MNCs) and slight sloughing of most superficial layer of epidermis: (stained with H&E at 5-7 μ m thickness. Scale bars: 50 μ m).

In conclusion, this study showed that Virkon S the most effective method for controlling and preventing saprolegniosis in fish ecosystem in a concentration of 75mg/L as observed through the results of histopathological studies. Moreover, the histopathological findings indicated that these fungi not only infect skin but also penetrate up to the internal organs (muscle, gills). The authors recommend another future study to develop a new alternative control strategies against *Saprolegnia sp.* in Iraq.

References

- Albert HV, Debbie M, Javier D, Pieter V.(2013).** The impact of the water moulds *Saprolegnia diclina* and *Saprolegnia parasitica* on natural ecosystems and the aquaculture industry. *Fungal Biology Reviews.* 27(2):33–42.
- Aly SM and EL Ashram AMM. (2000).** Some factors contributing to the development of Saprolegniosis in Nile tilapia (*Oreochromis niloticus*).*Alex. J. Vet. Science.*16 (1):165-174.
- Bernet D, Schmidt H, Meier W, Burkhardt-Holm P, Wahli T. (1999).** Histopathology in fish: proposal for a protocol to assess aquatic pollution. *Journal of Fish Diseases.* 22:25-34.
- Bruno DW, VanWest P, Beakes GW. (2011).** *Saprolegnia* and other *oomycetes*, In: Woo, P.T.K., Bruno, D.W. (Eds.) *Fish Diseases and Disorders: Volume 3: Viral, Bacterial and Fungal Infections*, 2nd Edition. CABI International, Wallingford, UK.669-720.
- Bruno DW and Wood BP. (1999).** *Saprolegnia* and other *Oomycetes*. In *Fish Disease and disorders, Volume 3, Viral, Bacterial and Fungal infections*. Edited by P. T. K. Woo and D. W. Bruno. CABI publishing, Walling ford, Oxon, UK.599-659.
- Bruno DW and Stamps DJ. (1987).** Saprolegniasis of Atlantic salmon, *Salmo salar* L., fry. *Journal of Fish Diseases* 10, 513 517.
- Cayla N. (2014).** Use of random amplified microsatellites (RAMS) to discern genotype of *Saprolegnia parasitica* isolation on the west of British Columbia. University of Victoria.
- Chauhan R, Beigh AH and Bhatt MH. (2014).** Histopathological manifestations in commercially important fish, *Clarias batrachus* (l.) found infected with *Saprolegnia diclina*. *Indo. Am. J. of Pharm. Res.* (4) 2:1168-1172.
- Coker WC. (1923).**The *saprolegniaseae*, with notes on other water molds. Chapel Hill: Univ. of North Carolina press.

Easa ME and Amin NE. (1987). Natural and experimental saprolegniosis of Tilapia (*Oreochromis niloticus*). Alex. J. Vet. Science. 2000, Vol.16 NO.1:1165-174.

El Ashram AMM, Abd El .Rhman AM. and Sakr SF. (2007). A contribution to saprolegniosis in cultured Nile tilapia (*Oreochromis niloticus*) with special reference to its control. Egypt. J. Aquat. Biol. & fish. 11(3):943-955. ISSN1110-1631.

El Genaidy Halam Zaki, Mona S and Aly SM. (2004). Pathological and biochemical studies in Catfish infected with *saprolegnia parasitica* and treated with Potassium permanganate. Egypt. J. Basic Appl. Physiol. 3(1), 201-212.

Fitzpatrick MS, Schreck CB and Chitwood RL. (1995). Evaluation of three candidate fungicides for treatment of adult spring chinook salmon. Prog. Fish-Cul. 57: 153-155.

Hussian MMA, Hassan WH and Mahmood MA. (2013). Pathogenicity of *Achlyaproliferoids* and *Saprolegnia diclina* (*Saprolegniaceae*) associated with saprolegniasis outbreaks in cultured Nile Tilapia (*Oreochromis niloticus*). World J of Fish and Marine Science. 5(2), 188-193.

Hussein MA, Hatai K, Nomura T. (2001) .Saprolegniasis in salmonids and their eggs in Japan. Journal of Wildlife Diseases. 37:204–207.

Hatai K and Hoshiai GI. (1994). Pathogenicity of *Saprolegnia parasitica coker*. In Salmon Saprolegniasis. Edited by G. J. Mueller. U.S. Department of Energy, Bonneville Power Administration, Portland, Oregon. pp. 87-98.

Marzouk MSM, Rezeki S Samira, and El Gamal M.H. (2003). Some mycological investigations on cultured tilapia in Kafr El Sheikh Governorate. Kafr El Sheikh Vet. Med. J. 1 (2): 97-114.

Meinertz JR, Stehly GR, Gingerich WH. and Allen JL. (1995). Residues of [14C] .Malachite green in eggs and fry of rainbow trout, *Oncorhynchus mykiss* [Walbaum], after treatment of eggs .J. Fish. Dis.18:239-247.

Muhsin TM. (1989). Polish Archive Hydrobiology. College of Sciences, Univ. of Basrah, Iraq.

Mallatt J (1985). Fish gill structural changes induced by toxicants and other irritants: a statistical review. Canadian Journal of Fisheries and Aquatic Sciences 42, 630–648.

- Mustafa SA (2012).** An integrated approach to assess impact of environmental stress in carp, *Cyprinus carpio L.*: Biochemical, genotoxic, histopathological and individual level effects. PhD Thesis. Plymouth University.
- Meyer FP and Jorgenson TA. (1983).**Teratological and other effects of malachite green on the development of rainbow trout and rabbits. *Trans. Am. Fish.Soc.* 112:818-824.
- Myers MS, Johnson LL, Hom T, Collier TK, Stein JE and Varanasi U. (1998).** Toxicopathic hepatic lesions in subadult English sole (*Pleuronectes vetulus*) from Puget Sound, Washington, USA: Relationships with other biomarkers of contaminant exposure. *Marine Environmental Research.* 45, 47-67.
- Ogbonna CIC. (1989).** Fungi associated with disease of freshwater fishes in Plateau state, Nigeria, *Journal of Aquatic Sciences.* 4:59-62.
- Refai MK, Laila A, Mohamed M K and Shimaa SMS. (2010).** The assessment of Mycotic settlement of freshwater fishes in Egypt. *J. Amer. Sci.* 6(11):595- 602.
- Prost H and Sopinska A. (1989).** Evaluation of the activity cellular protective process in carp with *Saprolegnia* infection and treatment with malachite green and immunostimulant. *Medycyna Weterynaryjna.* 45: 603-605.
- Ruthig GR. (2009).** Water molds of the genera *Saprolegnia* and *Leptolegnia* are pathogenic to the North American frogs *Rana catesbeiana* and *Pseudacris crucifer*, respectively. *Diseases of Aquatic Organisms.* 84;173e178.
- Songe MM, Willems A, Wiik-Nielsen J, Thoen E, Evensen Q, van West P and Skaar I. (2016).** *Saprolegnia diclina* IIIA and *S. parasitica* employ different infection strategies when colonizing eggs of Atlantic salmon, *Salmo salar L.* *Journal of Fish Diseases.* 39, 343–352.
- Seymour RL. (1970).** The genus *Saprolegnia.* *Nova Hedwigia,* 19: 1-124.
- Willoughby LG. (1985).** Rapid preliminary screening of saprolegnia to fish dis. (8): 473-476.