

Introduction

- Gallbladder hydrops, also known as gallbladder mucocele, is caused by prolonged blockage of the cystic duct.
- The most common cause is an impacted gallstone, but other etiologies include neoplasm, congenital strictures, extrinsic compression, and parasitic infection.
- In this case, we describe a rare case of gastric outlet obstruction (GOO) secondary to gallbladder hydrops.

Case Presentation

- A 60-year-old man with no known medical or surgical history presented with several months of intermittent abdominal pain, nausea, vomiting, and 30-lb unintentional weight loss.
- Physical exam was notable for a markedly distended abdomen with both tachycardia and hypotension.
- Labs revealed severe metabolic derangements consistent with history of vomiting, an elevated total bilirubin (10.1), alkaline phosphatase (519), and lactate (3.8).
- A markedly distended stomach compatible with gastric outlet obstruction, along with notable dilation of the gallbladder and intrahepatic ductal dilatation was found on CT of the abdomen (see Fig 1. & Fig 2.)
- Given the concern for obstruction secondary to underlying malignancy, patient underwent repeat EGD and EUS, which revealed ulcerated friable tissue extending from the prepyloric region to the duodenal bulb. ERCP could not be performed because tissue obstructed passage of the endoscope into the duodenum.
- Subsequently, an exploratory laparotomy was performed, and peritoneal and omental biopsies sent during the procedure revealed metastatic adenocarcinoma of likely pancreaticobiliary origin.
- A cholecystocolonic fistula was incidentally discovered while attempting to dissect the distended gallbladder, so the gallbladder was drained through the fistula. He received an additional palliative gastrojejunostomy.
- The patient was discharged home on hospice care with peritoneal and PTC drains postoperatively.

Figures

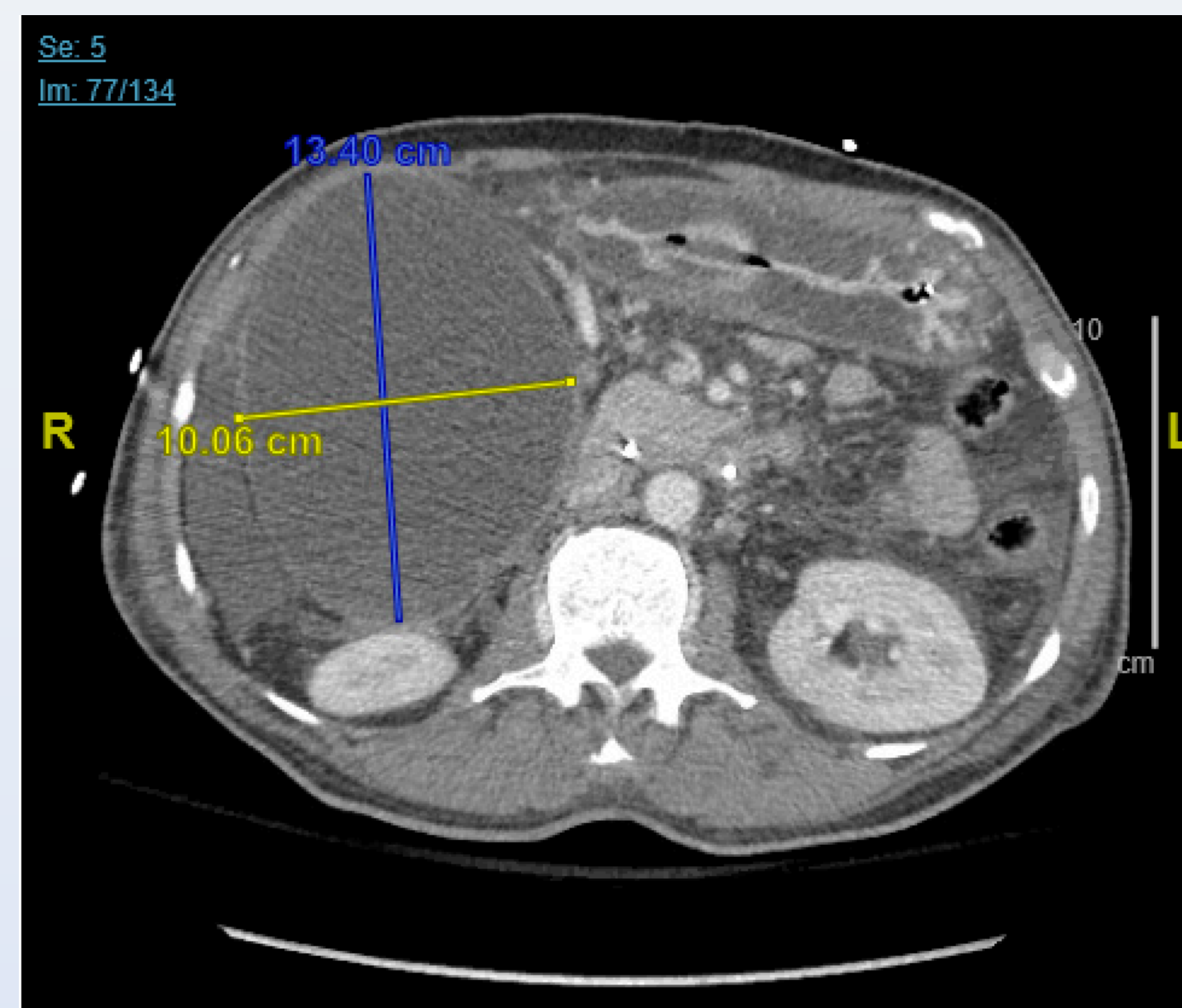


Fig 1. CT Abdomen (axial): Distended gallbladder mucocele measuring 13 x 10 cm compressing duodenum, small amount of ascites

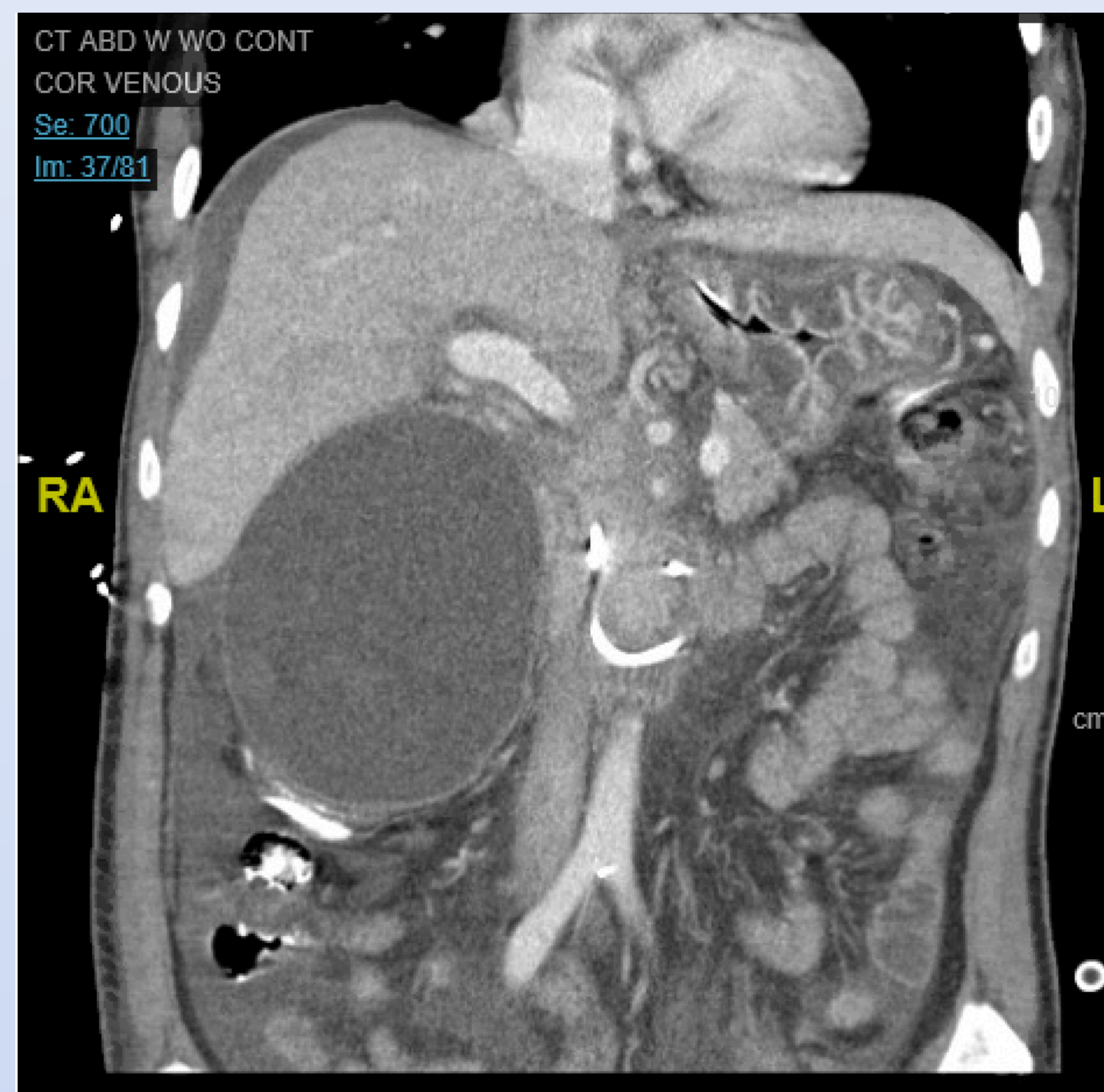


Fig 2. CT Abdomen (coronal)

Discussion

- The presentation of GOO due to extrinsic compression of the duodenum secondary to gallbladder hydrops is extremely rare, and there have only been a few cases reported worldwide.
- When an outlet obstruction is present, bile cannot exit the gallbladder via the cystic duct, and its buildup causes distension. Over time, bile salts are reabsorbed by the mucosa and replaced by clear, watery mucus. Since the gallbladder can hold up to 1.5L of fluid, the development of this mucocele can be progressive and subtle.
- However, its mass and size may eventually compress neighboring structures such as the pylorus and duodenal bulb, leading to GOO.
- In our patient, the gallbladder hydrops was caused by extrinsic compression of the cystic duct due to a pancreaticobiliary adenocarcinoma.
- While rare, it is important to consider gallbladder hydrops on the differential diagnosis for GOO, and if present, the different causes of gallbladder hydrops.
- Moreover, this case of gallbladder hydrops causing GOO highlights the importance of interdisciplinary management. Future cases of gallbladder hydrops and/or GOO may need to be co-managed by Gastroenterology, Surgery, and Interventional Radiology depending on the elucidated etiology.

References

- Khothsymuong RR, Kaminski J. Gallbladder Hydrops. *Journal of Diagnostic Medical Sonography*. 2004;20(4):256-259. doi:10.1177/8756479304266949
- Jones MW, Deppen JG. Gallbladder Mucocele. [Updated 2021 Feb 8]. In: StatPearls [Internet]. Treasure Island (FL): StatPearls Publishing; 2021 Jan-. Available from: <https://www.ncbi.nlm.nih.gov/books/NBK513282/>
- Loh WL, Ng NZP, Kabir T, Chan CY. Rare case of gallbladder mucocele causing gastric outlet obstruction treated with cholecystectomy. *Int J Surg Case Rep*. 2019;57:84-87. doi:10.1016/j.ijscr.2019.03.013