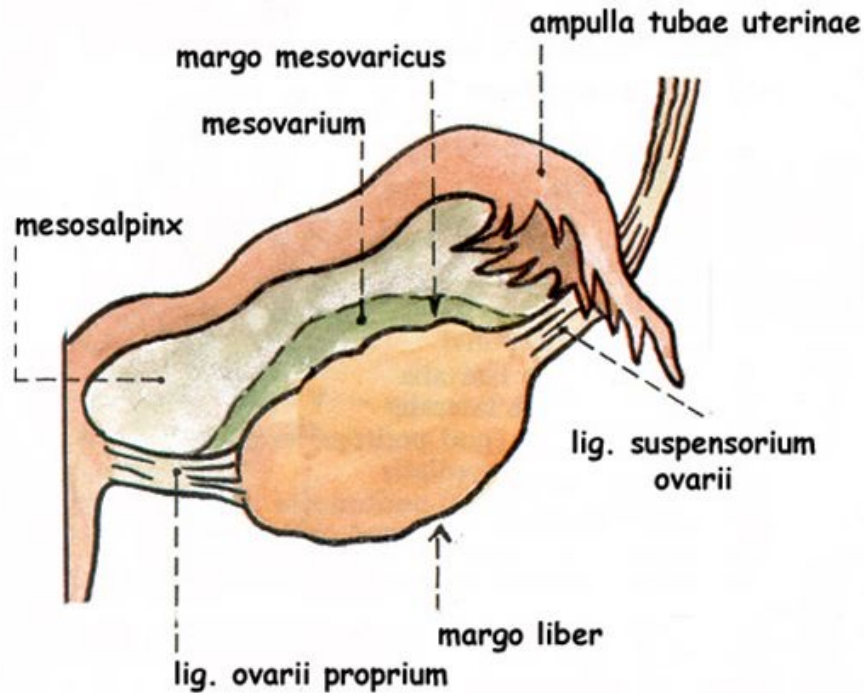


# Ovary – external structure

Surface - med. / lat

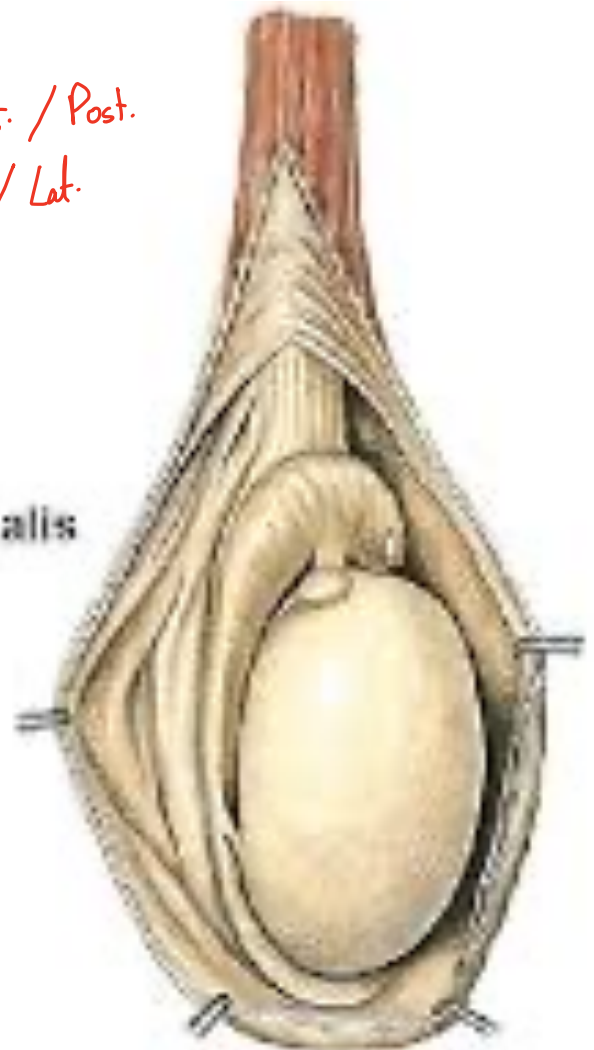
- extremitas tubaria ✓
- extremitas uterina ✓
- ✓ margo liber ✓
- margo mesovaricus ✓
- ✓ facies **medialis**
- ✓ facies **lateralis**
- hilum ovarii ✓



## TESTIS

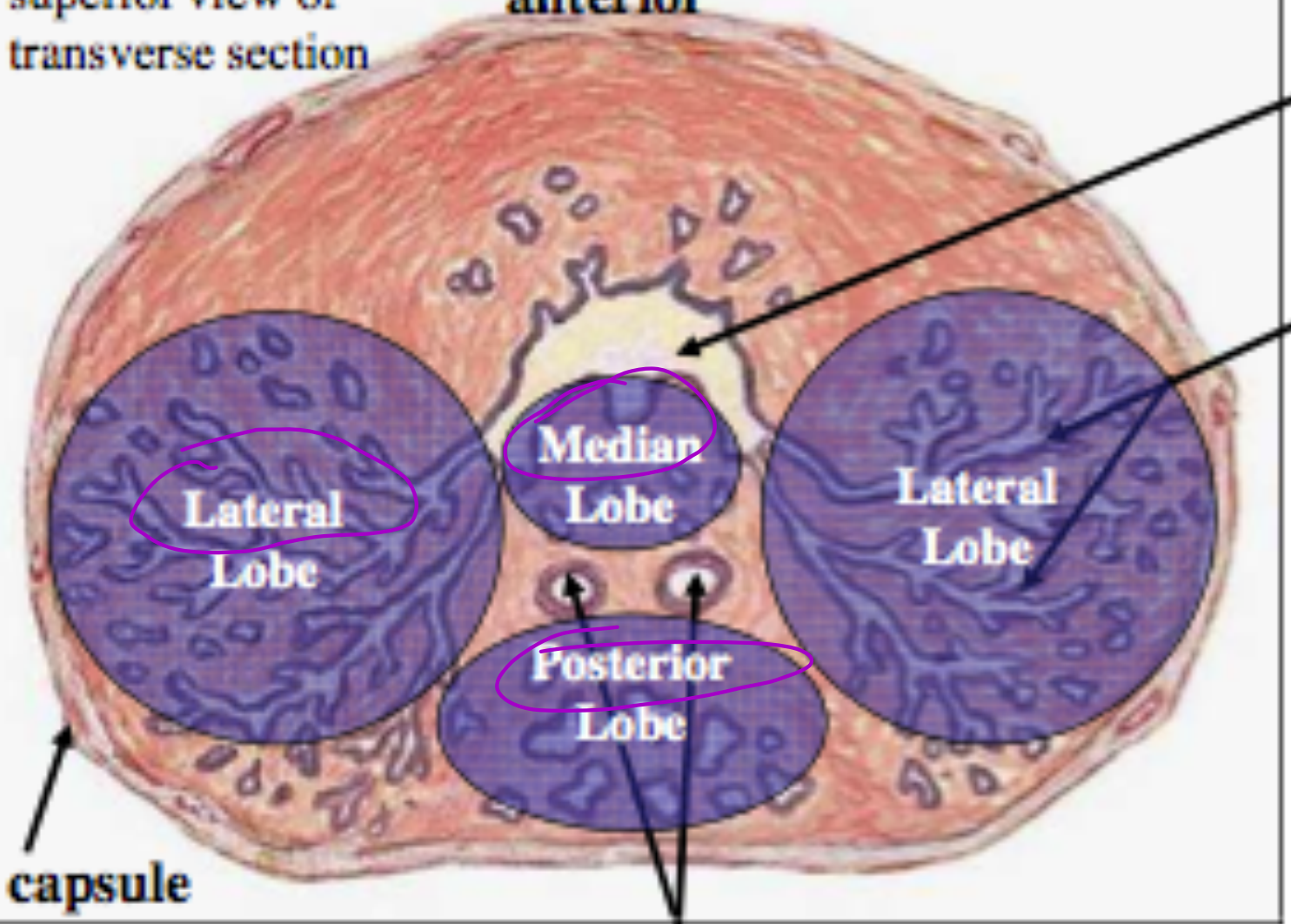
- Facies **medialis**
- Facies **lateralis**
- Extremitas **superior**
- Extremitas **inferior**
- Margo **anterior**
- Margo **posterior**
- Lamina visceralis tunicae vaginalis  
(Epiorchium) ✓

Border: Ant. / Post.  
Surface: Med. / Lat.



superior view of  
transverse section

anterior



Pr  
ur  
P  
&

capsule

ejaculatory duct

lobus sinister - left  
lobus dexter - right  
basis prostata - base