

General Disclaimer

One or more of the Following Statements may affect this Document

- This document has been reproduced from the best copy furnished by the organizational source. It is being released in the interest of making available as much information as possible.
- This document may contain data, which exceeds the sheet parameters. It was furnished in this condition by the organizational source and is the best copy available.
- This document may contain tone-on-tone or color graphs, charts and/or pictures, which have been reproduced in black and white.
- This document is paginated as submitted by the original source.
- Portions of this document are not fully legible due to the historical nature of some of the material. However, it is the best reproduction available from the original submission.

(NSA-CR-175837) HISTOLOGICAL AND
COMPOSITIONAL RESPONSES OF BONE TO
IMMOBILIZATION AND OTHER EXPERIMENTAL
CONDITIONS Semiannual Report, 1984 - 1985
(San Francisco Univ.) 30 p HC A03/MF A01

N85-27518

G3/52 Unclass
21376

SEMI-ANNUAL REPORT

HISTOLOGICAL AND COMPOSITIONAL RESPONSES OF BONE TO IMMOBILIZATION AND

OTHER EXPERIMENTAL CONDITIONS



Co-Operative Agreement: NCC 2-135

Period: 1984 through 1985

Principal Investigator: R. James Brown, Ph.D., Professor and Director
Institute of Chemical Biology
University of San Francisco
San Francisco, California 94117

Co-Investigator: Werner J. Niklowitz, Ph.D., Sen. Res. Assoc.
Institute of Chemical Biology
University of San Francisco
San Francisco, California 94117

ABSTRACT

Histological techniques were utilized for evaluating progressive changes in tibial compact bone in adult male monkeys (M. nemestrina) during chronic studies of immobilization-associated osteopenia. The animals were restrained in a semirecumbent position which reduces normally occurring stresses in the lower extremities and results in bone mass loss. The longest immobilization studies were of seven months duration. Losses of haversian bone tended to occur predominantly in the proximal tibia and were characterized by increased activation with excessive depth of penetration of osteoclastic activity. There was no apparent regulation of the size and orientation of resorption cavities. Rapid bone loss seen during 10 weeks of immobilization appeared to be due to unrestrained osteoclastic activity without controls and regulation which are characteristic of adaptive systems. The general pattern of loss persisted throughout 7 months of immobilization. Clear cut evidence of a formation phase in haversian bone was seen only after two months of reambulation. During this period, osteoblasts accumulated within resorption cavities and there was matrix apposition. Within 8 months of recovery, there was increased bone turnover and resorption cavities with diameters of 500-1500 μm were filled partially with new bone; the mean wall thickness of new bone is 2-3X larger than normal. In addition there were numerous remodeling sites which were more or less of normal size and orientation. Trabecular bone was also lost during immobilization, and it is probable that losses of large trabecular plates are not replaced and consequently original bone volume in the cross section is not recovered. In this immobilization model, we observe bone resorption occurring for long periods without apparent

interruption. In our view, immobilization gives rise to uncontrolled activation without coordination, balance or coupling to other remodeling parameters. Osteoblastic activity appears to be suppressed. Resorption cavities are not uniformly distributed and only a portion of the total cross section is involved. Recovery of cortical bone during reambulation is a repair and rejuvenation process characterized by refilling of resorption cavities as well as remodeling activities. The results are interpreted in terms of a cellular basis of bone remodeling.

KEY WORDS: immobilization-osteoporosis, cortical bone, primates

Chronic immobilization of adult male monkeys results in characteristic losses of vertebral (Kazarian and Von Gierke, 1969; Mack et al., 1968; Cann et al., 1980) and tibial cortical (Young et al., 1979; Young and Schneider, 1981) bone. Largely through the efforts of Kazarian, the immobilized primate has become a potentially useful model for studies of bone alteration in hypodynamic environments (Kazarian and Von Gierke, 1969). Our histological data (Young et al., 1983) in adult primates showed resorption cavities in the proximal tibiae within one month of immobilization; by two and a half months there were large resorption cavities subperiosteally, endosteally, and intracortically. Partial recovery of haversian bone was seen after fifteen months of reambulation, however, approximately forty months were required for restoration of the normal histologic appearance of the cortex. Bending stiffness of the tibiae, which is highly dependent upon the quality and quantity of cortical bone (Thompson et al., 1976; Orne 1974; Orne and Young, 1976), declined during immobilization, but returned to normal values after approximately eight and a half months of reambulation (Young et al., 1983).

Kazarian and Von Gierke (1969) using qualitative radiographic techniques, also demonstrated loss of cortical bone in the appendicular skeleton of young adult primates immobilized in whole body casts. But histological data reported by other investigators using young adult rhesus monkeys differ from our results: for example, evidence is cited (Schock et al., 1975, Wronski and Morey, 1983) that immobilization in body casts for two to eight weeks diminished bone apposition in the tibia. The haversian envelope of tibial cortical bone showed reduction of (a) formation rate, (b) percentage of labelled osteons in the perimeter,

and (c) a diminished ratio of cortical/total bone area (Schock et al., 1975). The latter finding implies a loss of bone, however no additional criteria of bone resorption were reported. Periosteal tibial bone (Schock et al., 1975) showed striking reductions in numbers of osteoid seams and apposition rate. Immobilization appeared to impair osteoblast-mediated activities. However, since there were no observed increases in percentage of resorbing surfaces, the authors concluded that there was no increase in remodeling rate.

In contrast, Jaworski et al., (Jaworski et al., 1980; Unthoff and Jaworski, 1979) described phasic changes in bone loss during long-term immobilization of canine forelimbs in plaster casts, and concluded that although rate and total amount of bone loss is age related, the mechanisms of bone loss in both young and old animals are associated with increased resorption surfaces but with unaltered rates of linear mineralization. The authors suggested that those observations implied significant changes in bone cell kinetics. Klein et al. (1982) studied limb immobilization by internal fixation in dogs pre-labeled with tetracycline. The increased losses of ^3H -tetracycline during immobilization demonstrated the increase of resorption rate. Significant amounts of released calcium were recycled and retained through the mechanisms of new bone formation. However, formation rate did not keep abreast of increased bone resorption, resulting in a net loss of bone. Those studies also suggest alterations in bone cell kinetics particularly in the recruitment and activation of osteoclasts.

Our earlier report (Young et al., 1983) was in general agreement with the conclusions drawn by Jaworski et al. (1980) and Klein et al. (1982) regarding the importance of bone resorption in immobilization-associated osteopenia. The demonstration of the recovery of mechanical

properties of tibial cortical bone (Young et al., 1983) however, was of greater significance and led us to believe that the middle-aged immobilized primate is a model for adult-acquired reversible osteopenia (AARO) (Young, 1984). Furthermore, we postulate that observed bone changes are (a) related principally to alterations of remodeling-type activity and events, but (b) may not be related significantly to changes or disturbances in bone growth functions as seen with pituitary disorder, nor in modeling functions such as those seen in osteogenesis imperfecta, nor in repair functions as seen in biological failures of bone union and wound disruption.

The present report is a qualitative assessment of histological changes in the tibiae of fifteen monkeys immobilized for periods up to seven months, and supports our hypothesis concerning AARO. We have focused principally upon changes in the cortex because of their impact on bending strength, and have expanded our evaluations of the osteoporotic process in the appendicular skeleton by use of microradiographic techniques as well as stained histologic sections.

MATERIALS AND METHODS

Immobilization studies were performed with 15 adults male pigtail monkeys (M. nemestrina). The studies were of 1-7 months duration. The animals were approximately 15 years of age. They were fed a commercial primate diet (Purina) throughout all phases of testing.

The animals were restrained in a semirecumbent position using the techniques of Howard et al. (1971). That procedure reduces normally occurring stresses in the lower extremities which results in an immobilization-associated osteopenia.

For histologic evaluation of the present series, the region below the tibial tuberosity was cut into 3-5 mm transverse slices and fixed in neutral formalin. They were subsequently decalcified in RDO* and 6-10 μ m frozen sections were prepared with a sliding microtome (AO) with a Super Histo-Freeze attachment. The tissues were embedded for cutting in O.C.T. compound (Tissue Tek). The sections were stained with H & E, Paragon, modified Masson, osteochrome Villanueva bone stain, and Weigert's iron hematoxylin with metachromic dyes. In addition, phase contrast microscopy was used to examine unstained, undecalcified bone sections.

For microradiography, sections were cut with a Buehler Isomet low speed saw from frozen untreated bone. For some specimens, 100-150 μ m sections were prepared. Bone marrow and other soft tissue was removed; the sections were then dehydrated in alcohol, rinsed with petroleum ether and dried in vacuo. In other samples the tissue was fixed in 75% ethanol, and then embedded in plastic and ground to a thickness of 100 μ m (Jee, 1959).

Control animals were given a total of 4 labels (Terramycin/Achromycin, i.v.) at 10 day intervals during the study in order to determine normal mineralization rate of cortical bone.

RESULTS

Three techniques (fluorescence microscopy, phase contrast microscopy, and microradiography) were used to visualize osteonal formation in the proximal tibia of control animals. Figure 1a shows the incorporation of four sequential tetracycline labels administered at 10 day intervals. Mineral appositional rate is 1.0-1.5 μm per day, but the frequency of events is low. Typically, only two or three labeled osteons are seen in the entire cross section. They are the young dark remodeling osteons seen in microradiography (Fig. 3). The pattern of tetracycline labeling in an osteon corresponds with the darker concentric lamellae seen in phase contrast microscopy of the same structure (Fig. 1b). Phase contrast shows the region of recent bone formation in relationship to the entire osteon. Microradiographs of this osteon (Fig. 1c) show another perspective. At this stage of development the remodeling osteon is less dense than the surrounding bone (18% less calcium as determined by electron microprobe analysis) (Niklowitz et al., 1983). The annular light lamellae density patterns in the microradiograph of the area adjacent to the haversian canal correspond to the dark annular patterns seen in phase microscopy as well as to the patterns of tetracycline labeling. Thus, these data are potentially useful for assessing the fractional area of individual osteons undergoing appositional bone formation in relationship to dimension of haversian canal, to radiographic density and to pattern of mineralization. We could not demonstrate satisfactory labeling with tetracycline in haversian bone during chronic immobilization, therefore quantitative comparisons of kinetic parameters were not possible.

Radiographic alterations that occur during immobilization are shown in Figure 2. Figure 2a, prior to immobilization, shows the solid

cortical bone below the tuberosity in the anterior proximal tibia. Figure 2b demonstrates the cancellation and osteopenia in cortical bone after 10 weeks of immobilization. There is surface erosion and thinning of the cortex, cortical striations, and a loss of definition of the endosteal margin.

Microradiographs of cross sections of the tibia (Fig. 3) show much of the normal haversian bone below the tuberosity delineated by an inner and outer circumferential layer of lamellar bone. There are few remodeling osteons. Trabecular bone is predominantly in the anterior tibia. Figure 4 shows the response to 10 weeks of immobilization. This section was also taken below the tuberosity. There are extensive resorption cavities subperiosteally and enlarged resorption cavities intracortically in the anterior tibia; there is also a thinning and loss of trabecular bone. Bone loss continues throughout seven months of immobilization. There are no dark (less dense) osteons^{to} indicate remodeling processes during immobilization. Figure 5 shows six months of recovery following 10 weeks of immobilization. These specimens show a dramatic increase in remodeling rate as shown by the larger number^{of} darker osteons (less mineralized bone) in the cortex as compared to control animals (Fig. 3). Most resorption cavities, 500 - 1500 μm in diameter, are partially filled with new and less dense bone and appear as unusually large osteons. The mean wall thickness of these units is 2 to 3 times larger than normal and at this stage the haversian canals are wide. During recovery, endosteal surfaces show bone apposition. But Figure 5 also shows endosteal areas without a covering of new bone which suggests either recent resorption or lack of apposition. It is possible that resorption and regional bone loss continue after immobilization is terminated. At 15 months of recovery, the wall thickness of newer osteons remains large and the haversian canal is somewhat larger than normal size (Fig. 6). Trabecular plates are not replaced.

Another pattern of recovery in the tibial cortex can be seen in Figure 7. There is extensive appositional formation of lamellar bone, subperiosteally. Several arrest lines delineate the areas of active formation. Remnants of arrest lines can also be seen within the cortical bone proper; the larger osteons extending into lamellar bone demonstrate states of transformation of lamellar to haversian bone.

Specific cells associated with bone loss were examined. During immobilization there is a characteristic recruitment of osteoclasts. Figure 8 shows effects of 10 weeks of restraint. There is an accumulation of multinucleated osteoclasts within resorption cavities in the cortex (Fig. 8a). Longitudinal sections contain osteoclasts at the leading edge of cutting cones (Fig. 8b). Figure 8c shows effects of seven months of immobilization. An osteoclast and Howship's lacuna can be seen on the irregular periosteal surface.

The large resorption cavities seen during immobilization have smooth surfaces and are lined with mononucleated cells (Fig. 9). The geometry of the cells suggests that they may be osteoblasts. But during immobilization we have not been able to demonstrate the presence of osteoid seams by selective staining techniques. However, within two months of recovery, extensive osteoid seams can be seen in proximity to morphologically similar cells (Fig. 10).

DISCUSSION

The present report is an extension of our studies of immobilization-associated osteoporosis. Ordinarily, the tibial cortex has a quiescent bone surface. There are few active remodeling sites. During immobilization this apparently inactive surface however, is capable of excessive metabolic activity. The pattern of bone resorption varies from cutting cones in single osteons to uncontrolled, chaotic, osteonal resorptive activities; that process prevails throughout at least seven months of continuous immobilization. Unlike remodeling which is a cyclical bone replacement mechanism (Parfitt, 1984), our samples show no apparent regulation of the size and orientation of resorption cavities. Thus the massive resorption of bone is considerably different from what might be expected with a normal activation frequency, and is associated with excessive depth of osteoclastic penetration. As in senescent changes (Jowsey, 1960; Martin et al., 1980), the increased cortical porosity in our model is not uniformly distributed; the most obvious changes were seen in the proximal anterior tibia.

During immobilization, cavities in the cortex with smooth surfaces are lined with mononuclear cells and appear to be in a reversal stage. Some of the mononuclear cells may be preosteoblasts or even osteoblasts. Nevertheless, the studies of others showing depressed osteoblastic activity (Schock et al., 1975; Wronski and Morey, 1983) as well as our own inability to demonstrate tetracycline labels in tibial haversian bone of immobilized primates (Young and Schneider, 1981) indicates an inhibition of new bone formation. Additional studies using histochemical techniques (acid and alkaline phosphatase distribution) are required for further attempts at identification of these cell populations. If

they are indeed osteoblasts derived from the marrow compartment, the possibility exists that there is an adequate stimulus for osteoblast recruitment but that specific cell function is inhibited, resulting in a long time delay in the reversal phase. Further studies are needed to elucidate this question.

We have seen clear cut evidence of a formation phase in haversian bone only after two months of reambulation. During this period, osteoblasts accumulate within the resorption cavity and there is matrix apposition. Thus a true reversal process occurs. After six months of recovery, refilling of cavities can be seen. Resorption cavities with diameters of 500-1500 μm are partially filled with new bone. The mean wall thickness is larger than normal. In addition, there is a significant increase of activation frequency; numerous remodeling sites which can be seen in the cross sections, are more or less of normal size and orientation. We have not excluded the possibility that bone loss may persist during the early phases of recovery.

Periosteal lamellar apposition is another pattern of recovery. The long parallel lamellar units of bone are stiffer and more rigid in all directions than is haversian bone (Katz et al., 1984). Thus at six months of recovery, the internal reconstruction of the cortex mediated by depth of deposition of new bone, remodeling events, as well as the formation of concentric lamellar structures improves bone quality. They can be expected to restore mechanical properties, especially bending stiffness (Young et al., 1983). Rejuvenation of matrix and crystal structure also improves the potential for homeostatic responses associated with calcium regulation.

There are obvious losses of trabecular bone in the tibia. Whereas a portion of the endosteal envelope may be restored by apposition, it

is doubtful that large trabecular plates are replaced. Consequently, original bone volume is probably not recovered. Bone surface to volume ratio at the endosteum is clearly altered.

Events occurring during immobilization cannot be understood in terms of only one cell population, therefore continuing studies in our laboratory are required to identify and better define the role of various cells in the overall process. But despite incomplete data, some tentative conclusions can be drawn from the observations in our model. Rapid bone loss in hypodynamic environments may not be a physiologic adaptive response. The loss appears to be due to unrestrained osteoclastic activity without controls and regulations which are characteristic of adaptive systems. The general pattern of loss persists throughout the longest immobilization studies we have conducted (7 months). The mechanisms giving rise to the loss of bone are unknown. There could be a hormonal basis for the bone loss. For example, we noted earlier (Howard et al., 1971) a 55% increase of fecal mass with constant food intake during immobilization which suggested altered intestinal absorption. Diminished calcium absorption can lead to a secondary hyperparathyroidism with direct effects of parathyroid hormone (PTH) on bone. Alternatively, the studies of Burkhart and Jowsey (1967) suggest increased sensitivity of immobilized bone to circulating levels of thyroid and parathyroid hormones. But the responses that we observe during immobilization do not fit the patterns in which bone is influenced by calcium regulating hormones. For example, patients suffering from primary hyperparathyroidism show a high bone turnover with increased formation and resorption surfaces, and a significantly increased bone apposition rate (Tam et al., 1982). Anabolic effects of PTH have also been shown in involutional osteoporosis

(Reeve et al., 1980). The stimulation of matrix synthesis by PTH appears to be cyclical (Parsons, 1976); an inhibitory effect is followed by a stimulatory response in which osteoblastic activity is increased (Raisz, 1984).

During reambulation there is ample evidence of increased bone turnover and filling of resorption cavities by anabolic processes. The repair and reconstruction of the cortex restores functional properties of the bone. Anabolic activity which occurs during this phase resembles some of the described effects of PTH or what might be expected from heightened sensitivity to PTH.

Glucocorticoids are also implicated in the osteopenia seen in immobilized primates. Glucocorticoids have been shown to reduce intestinal absorption of calcium (Harrison and Harrison, 1960), to reduce calcium binding protein in the intestine (Feher and Wasserman, 1979), and to lower plasma levels of 1,25 dihydroxyvitamin D3 (Chesney et al., 1978). In our studies there is a transitory rise in urine cortisol during the first five days of immobilization; baseline urinary cortisol excretion rates of 246 $\mu\text{g}/\text{day}$ increase to levels of 409 $\mu\text{g}/\text{day}$.) However, we have not yet established these transient alterations as a probable cause of altered intestinal calcium absorption or of altered bone formation parameters in our model. Further investigations are required in order to determine the modulating and permissive effect of calcemic hormones in the etiology of disuse osteoporosis.

In our model the extreme alterations in bone are obviously correlated with skeletal loading. Recent evidence of the strain environment in the tibia has been presented (Rubin, 1984). During vigorous physical activity the total strain in bone due to bending is 12-18x greater than is the strain associated with axial compressive loads. Our sample area of interest

is located in proximity to muscle and tendon insertions which ordinarily produce local high strain environments. Immobilization of primates may reduce mechanically induced deformations in the region of the tibial tuberosity by as much as 3000 microstrains. Thus we may be evaluating an especially load-sensitive area of bone. It has long been known that the stress history of bone influences its structural competence (Lanyon, 1984). The osteogenic response to increased physical activity although difficult to quantify, has been reasonably well-documented. Interactions of mechanical factors with hormones or local factors (Somjen et al., 1980) are thought to regulate remodeling and bone formation within the physiologic range. We have cited the evidence in primates which supports the concept of a reduction or perhaps cessation of new bone forming activities during immobilization. That lends further support to the attractive hypothesis concerning the stimulus provided by minimum effective strains on bone turnover. But a major effect of hypodynamic immobilization, beyond alteration of remodeling parameters, appears to be the loss of control and regulation of catabolic processes. We observe bone resorption occurring for long periods (7 months) without interruption; although we have interpreted that response in terms of a cellular basis of bone remodeling, we believe that it is more akin to a pathophysiologic process. Similarly, some changes seen during re-ambulation can be readily evaluated in terms of conventional remodeling concepts and effects of loading history. But the large increase in the mean wall thickness of new osteons is a new observation. Whether this should be classified properly as remodeling or modeling is unclear.

The evaluations support our premise of the occurrence of a modified type of adult-acquired reversible osteoporosis (AARO) in the cortex of weight-bearing bones. It is likely that replacement of the endosteal

envelope and trabecular bone is incomplete, so that repeated exposures to hypodynamic-hypogravic environments would probably lead to greater thinning of the cortex and reduction of bone volume as has been described in involutional bone loss. However, osteoporosis is traditionally attributed to bone cell senescence and relative insensitivity to signals and factors which ordinarily stimulate remodeling. In sharp contrast, our studies with cortical bone show the extremes of cellular activities. In our view, immobilization gives rise to uncontrolled activation without coordination, balance, or coupling to other remodeling parameters. Tunneling in bone due to focally excessive resorption as seen in our specimens was originally proposed by others evaluating irradiation-induced bone changes in man and dogs (Jee, 1962; Pool *et al.*, 1983) and also by Arnold (1966) in studies of senile osteoporosis. Only a portion (approximately 25%) of a representative cross section is involved. Recovery and rejuvenation of bone appears to be a reparative process. Approximately 30% of the cortical surface is affected by this activity. Cavities are filled and remodeling is stimulated. The mechanisms which stimulate these changes are at the present, obscure.

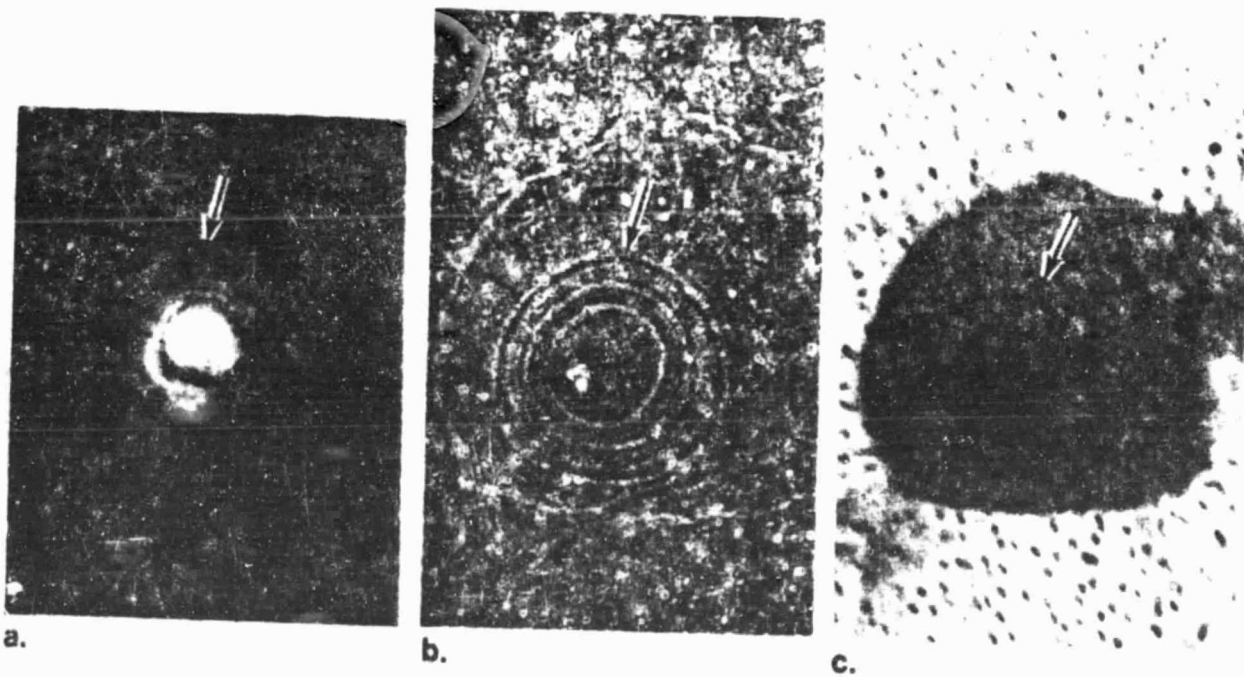
REFERENCES

- Arnold, J.S. and Bartley, M.H.: Skeletal changes in aging and disease. Clin. Orthop. 49:17-38, 1966.
- Burkhart, J.M. and Jowsey, J.: Parathyroid and thyroid hormones in the development of immobilization osteoporosis. Endocrinol. 81:1053-1062, 1967.
- Cann, C.E., Genant, H.K. and Young, D.R.: Comparison of vertebral and peripheral mineral losses in disuse osteoporosis in monkey. Radiology 134:525-529, 1980.
- Chesney, R., Mazess, R.B., Hamstra, R., De Luca, H.F., O'Reagan, S.: Reducation of serum 1,25-dihydroxyvitamin D in children receiving glucocorticoids. Lancet 2:1123-1125, 1978.
- Feher, J.J. and Wasserman, R.H.: Calcium binding protein, alkaline phosphatase, and calcium absorption in cortisol-treated chicks. Endocrinology 104:547-551, 1979.
- Harrison, H.E. and Harrison, H.C.: Transfer of Ca^{45} across intestinal wall in vitro in relation to action of vitamin D and cortisol. Am. J. Physiol. 199:265-271, 1960.
- Howard, W.H., Parcher, J/W. and Young, D.R.: Primate restraint system for studies of metabolic responses during recumbency. Lab Animal Science 21 (1):112-117, 1971.
- Jaworski, Z.F.G., Liskova-Kiar, M. and Uthoff, H.K.: Effect of long-term immobilization on the pattern of bone loss in older dogs. J. Bone Joint Surgery 62B:104-110, 1980.
- Jee, W.S.S.: Microradiographic and autoradiographic studies of bones containing radioisotopes. Anat. Rec. 133:395-396, 1959.
- Jee, W.S.S.: Histopathological endpoints in compact bones receiving alpha irradiation. In: Some Aspects of Internal Irradiation. Eds., T.F. Dougherty, W.S.S. Jee, C.W. Mays, B.J. Stover. pp. 95-116, Pergamon Press, Oxford, 1962.
- Jowsey, J.: Age changes in human bone. Clin. Orthop. 17:210-218, 1960.
- Katz, J.L., Yoon, H.S., Lipson, S., Maharidge, R., Meunier, A., and Christel, P.: The effects of remodeling on the elastic properties of bone. Calcif. Tissue Int. 26:S31-S36, 1984.
- Kazarian, L.E. and Von Gierke, H.E.: Bone loss as a result of immobilization and chelation: Preliminary results in Macaca mulatta. Clin. Orthop. 65:67-75, 1969.

- Klein, L., Player, J.S., Heiple, K.G., Bahniuk, E., and Goldberg, V.M.: Isotopic evidence for resorption of soft tissues and bone in immobilized dogs. J. Bone Joint Surgery 64A:225-230, 1982.
- Lanyon, L.E.: Functional strain as a determinant for bone remodeling. Calcif. Tissue Int. 36:S56-S61, 1984.
- Mack, P.B., Hoffman, R.A., and Al-Shawi, A.N.: Physiologic and metabolic changes in Macaca nemestrina on two types of diets during restraint and non-restraint. II. Bone density changes. Aerospace Med. 36:692-704, 1965
- Martin, R.B., Tackett, J.C., and Zinaich S.: Studies of skeletal remodeling in aging men. Clin. Orthop. 149:268-282, 1980.
- Niklowitz, W.J., Bunch, T.E., Young, D.R.: The effects of immobilization on cortical bone in monkeys (M. nemestrina). The Physiologist 26(6):S115-S116, 1983.
- Orne, D.: The in-vivo driving-point impedance of the human ulna: a viscoelastic beam model. J. Biomech. 7:249-259, 1974.
- Orne, D. and Young, D.R.: The effects of variable mass and geometry pretwist, shear deformation and rotatory inertia on the resonant frequencies of intact bone: a finite element model analysis. J. Biomech. 9:763-770, 1976.
- Parfitt, A.M.: The cellular basis of bone remodeling: The quantum concept reexamined in light of recent advances in the cell biology of bone. Calcif. Tissue Int. 36:S37-S45, 1984.
- Parsons, J.A.: Parathyroid physiology and the skeleton. In: The Biochemistry and Physiology of Bone. G.H. Bourne, Ed., Academic Press, New York, 1976, 2nd ed., volume 6, pp. 159-225.
- Pool, R.R., Morgan, J.P., and Parks, N.J.: Comparative pathogenesis of radium-induced intracortical bone lesions in humans and beagles. Health Physics 44 Suppl. 1:115-177, 1983.
- Raisz, L.G.: Studies of bone formation and resorption in vitro. Hormone Res. 20:22-27, 1984.
- Reeve, J., Meunier, P.J., and Parsons, J.A.: Anabolic effect of human parathyroid hormone fragment on trabecular bone in involutional osteoporosis: a multiple centre trial. Brit. Med. J. 280:1340-1344, 1980.
- Rubin, C.T.: Skeletal strain and the functional significance of bone architecture. Calcif. Tissue Int. 36:S11-S18, 1984.
- Schock, C.C., Noyes, F.R., Crouch, M.M., and Mathres, C.H.E.: The effects of immobility on long bone remodeling in the rhesus monkey. Henry Ford Hosp. Med. Journal 23 (3):107-115, 1975.

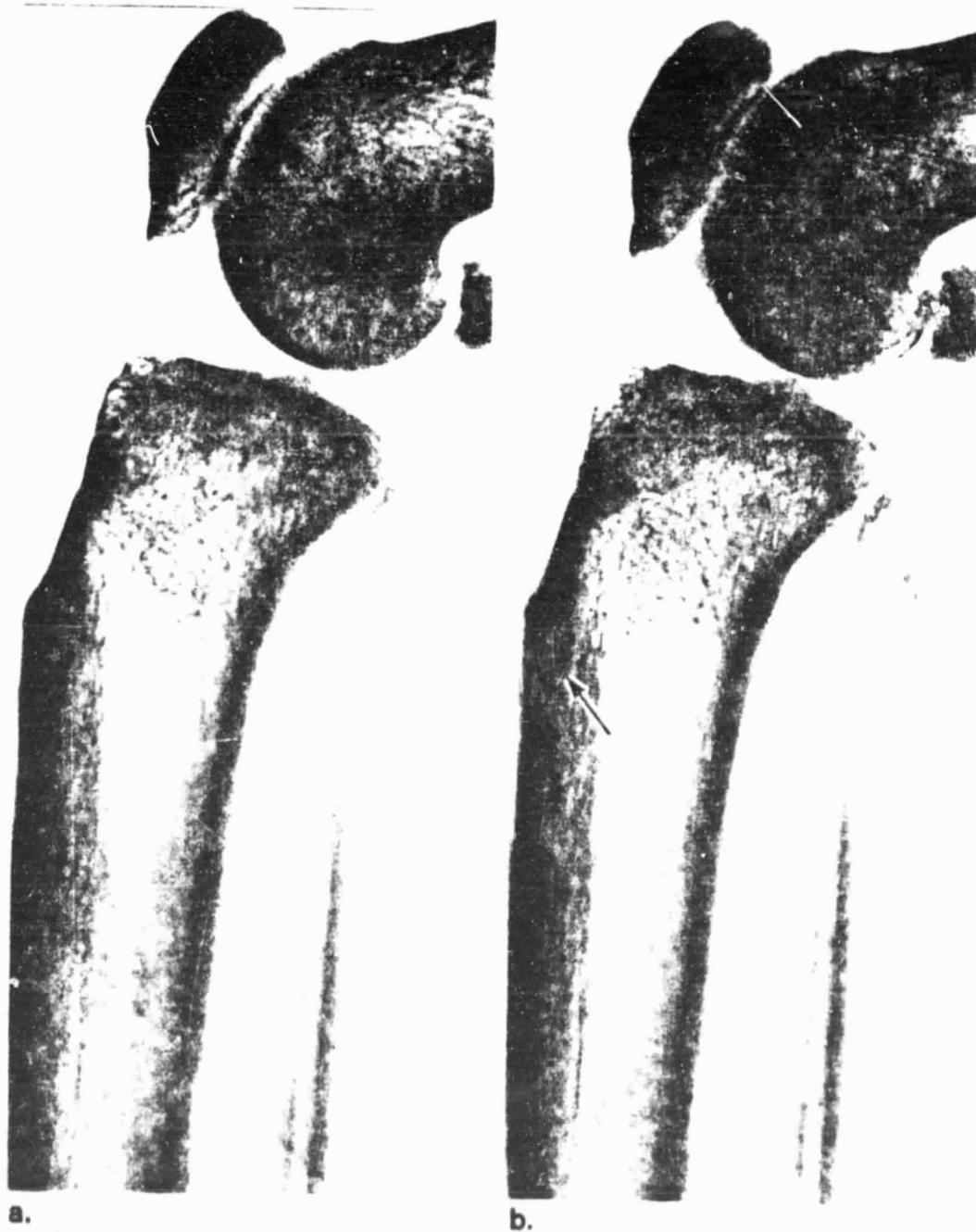
- Scnjen, D., Binderman, I., Berger, E., Harell, A.: Bone remodeling induced by physical stress in prostaglandin E₂ mediated. Biochem. Biophysics Acta 627:91-100, 1980.
- Tam, C.S., Bayley, A., Cross, E.G., Murray, T.M., and Harrison, J.E.: Increased bone apposition in primary hyperparathyroidism: measurements based on short interval tetracycline labeling of bone. Metabolism 31 (8):759-765, 1982.
- Thompson, G.A., Orne, D., and Young, D.R.: In-vivo determination of mechanical properties of the human ulna by means of mechanical impedance tests: experimental results and improved mathematical model. Med. Biol. Eng. 14:253-262, 1976.
- Uthoff, H.K. and Jaworski, Z.F.C.: Bone loss in response to long-term immobilization. J. Bone Joint Surgery 60B:420-429, 1978.
- Wronski, T.M. and Morey, E.R.: Inhibition of cortical and trabecular bone formation in the long bones of immobilized monkeys. Clin. Orthop. 181:269-276, 1983.
- Young, D.R.: Reversible osteoporosis in a primate model. In, Third International Symposium on Osteoporosis, Copenhagen, Denmark, pp. 475-479, June 3-8, 1984.
- ✓ Young, D.R., Howard, W.H., Cann, C., and Steel^e, C.R.: Non-invasive measure of bone bending rigidity in the monkey (M. nemestrina). Calcif. Tissue Int. 27:109-115, 1979.
- Young, D.R. and Schneider, V.S.: Radiographic evidence of disuse osteoporosis in the monkey (M. nemestrina). Calcif. Tissue Int. 33:631-639, 1981.
- Young, D.R., Niklowitz, W.J., and Steele, C.R.: Tibial changes in experimental disuse osteoporosis in the monkey. Calcif. Tissue Int. 35:304-308, 1983.

Fig. 1. Control. Proximal anterior tibia. Comparison of fluorescence (a), phase contrast (b), and microradiographic (c) images of the same osteon in process of remodeling. Arrow points to comparable region of recent bone formation in relationship to entire osteon. X180



ORIGINAL PAGE 15
OF POOR QUALITY

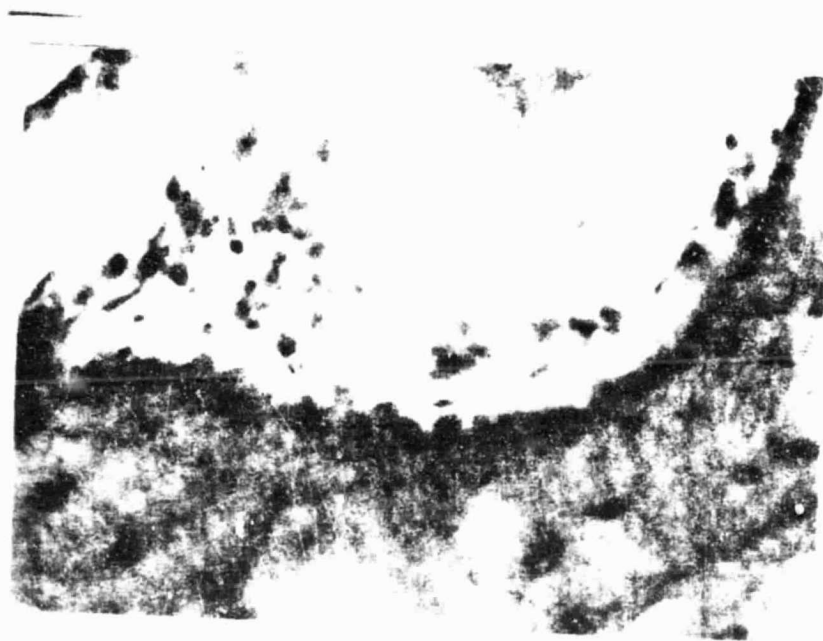
Fig. 2. Radiographs of the right tibia prior to restraint (a), and after 10 weeks of restraint (b). There is characteristic loss of bone in the anterior proximal tibia below the tuberosity. Arrow shows thinning of cortical bone, striations, and loss of definition of endosteal margin. X2



Legend for figure 9

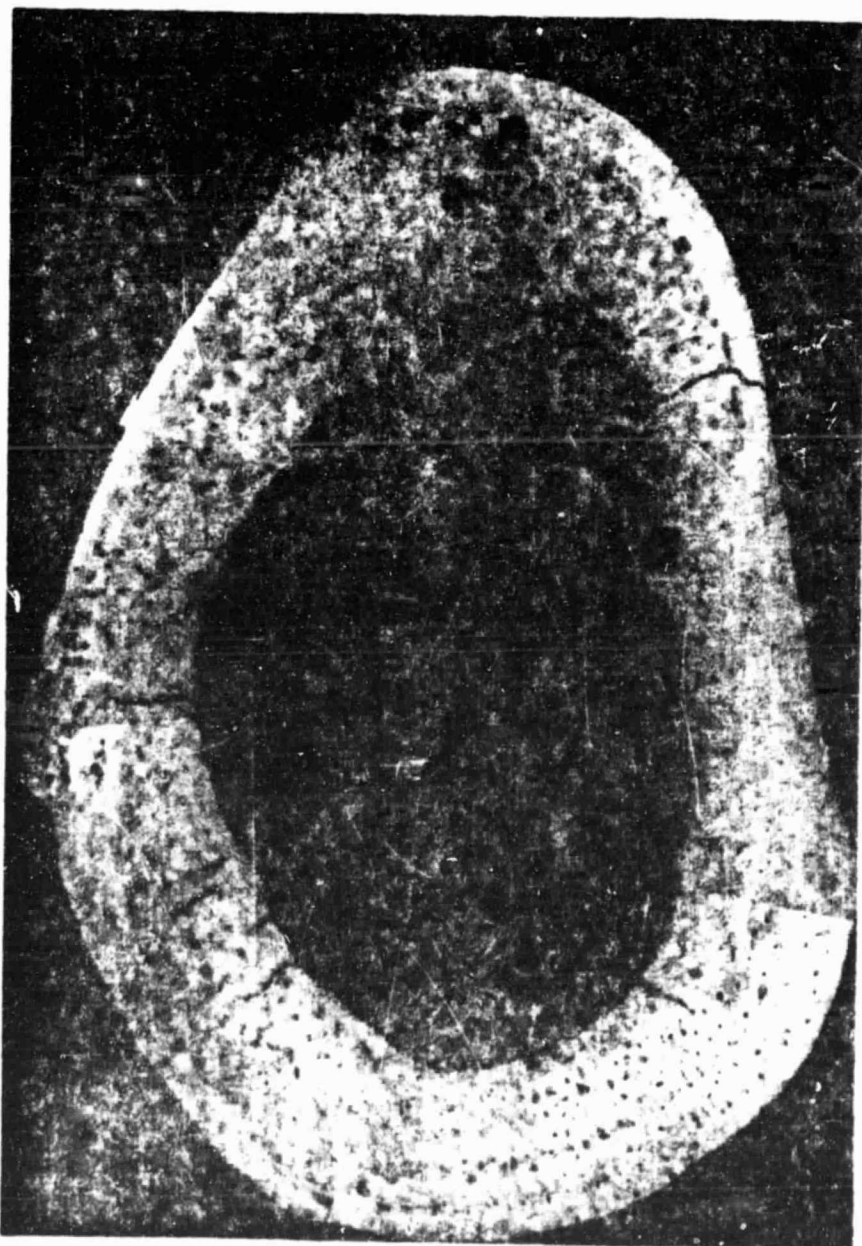
ORIGINAL PAGE IS
OF POOR QUALITY

Fig. 9. During restraint resorption cavity contains osteoblasts
or osteoblast-like cells. H&E. X420



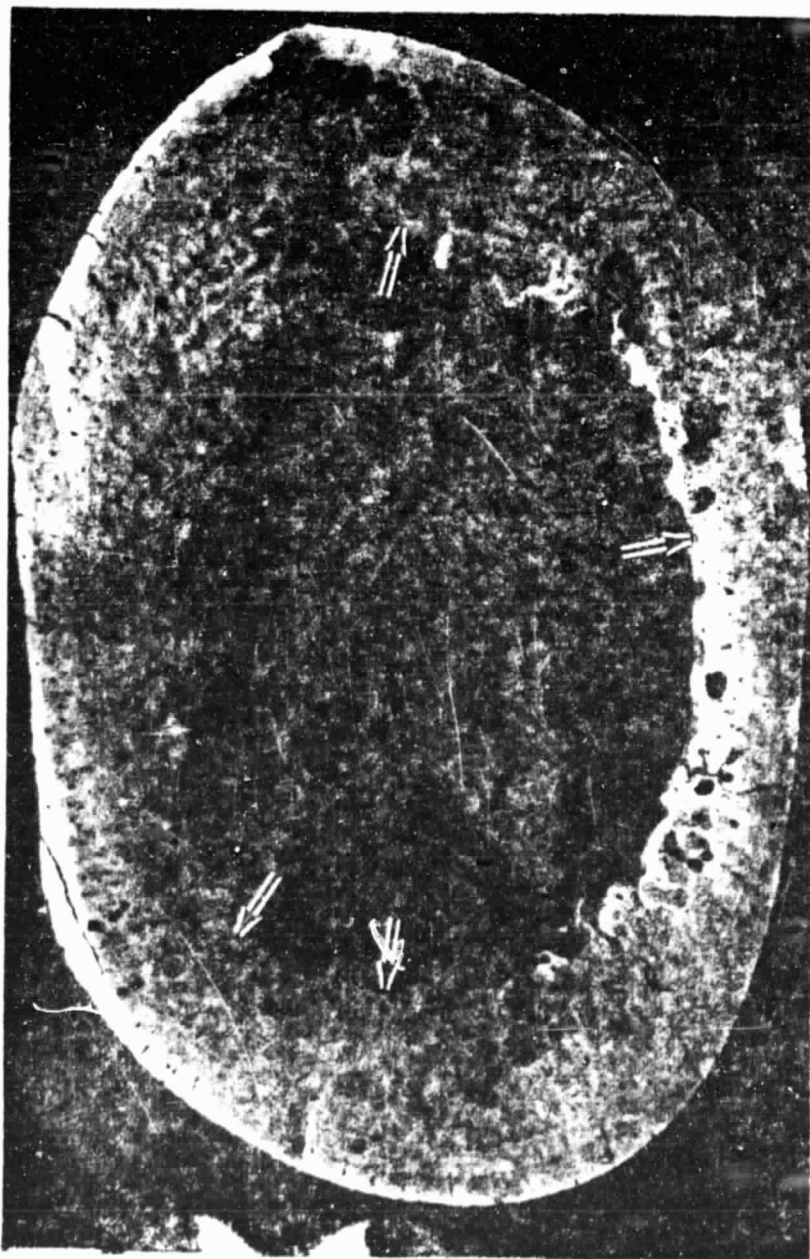
ORIGINAL PAGE IS
OF POOR QUALITY

Fig. 4. Microradiograph of a cross section through the proximal tibia of a 10 week restrained animal. There are no newly remodeled osteons, however, a larger number of resorption cavities can be seen in the anterior portion of the tibia, as well as loss (thinning and fewer trabeculi) of trabecular bone. X12



ORIGINAL PAGE IS
OF POOR QUALITY

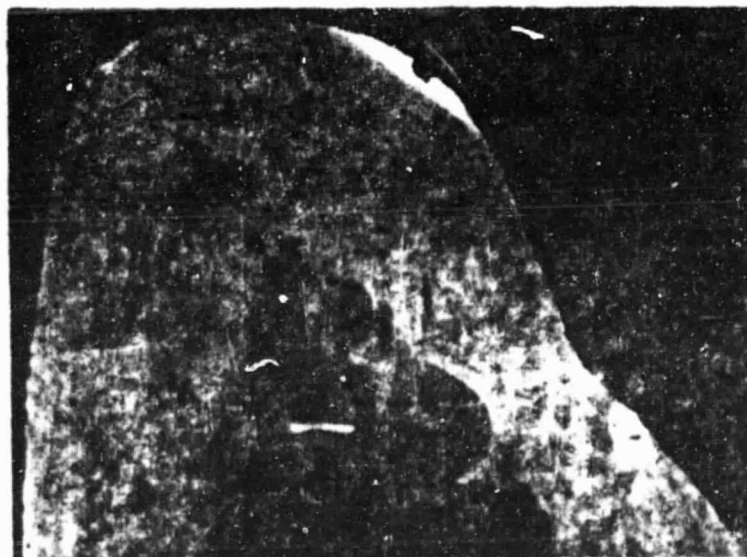Fig. 5. Microradiograph of a cross section through the proximal tibia of an animal after 6 months of recovery from 10 weeks of restraint. The resorption cavities are partially or completely filled with new bone, which in this state is still undermineralized. The posterior tibia shows increased remodeling. Regions of endosteal surface show bone apposition or resorption (+). X12



Legend for figure 6

ORIGINAL PAGE IS
OF POOR QUALITY

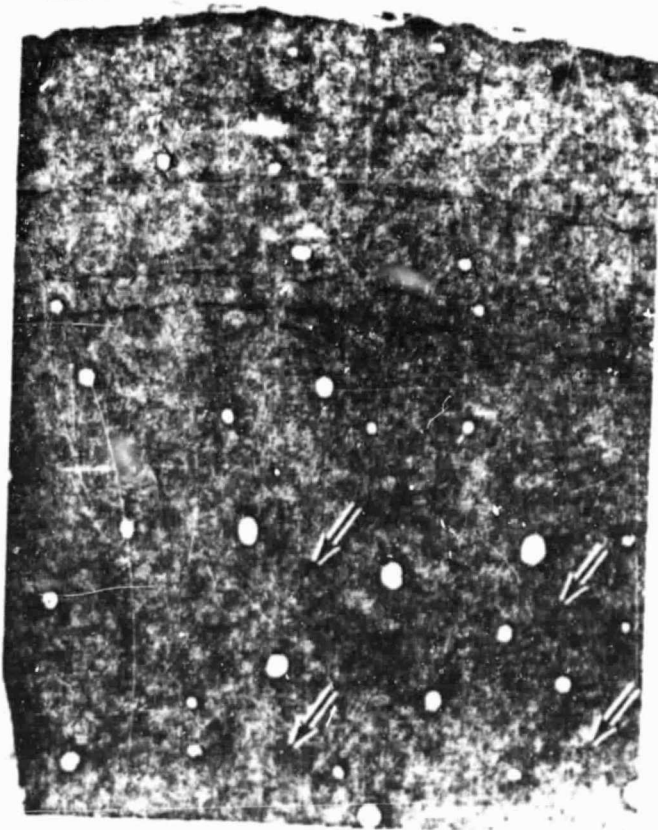Fig. 6. Microradiograph of the proximal tibia after 15 months of recovery from 6 months of restraint. Almost all of the former resorption cavities are completely filled with new bone and the haversian canal is of approximately normal size. The mean wall thickness of these osteons is larger than normal. Trabecular bone is not completely replaced. X12



Legend for figure 7

ORIGINAL PAGE IS
OF POOR QUALITY

Fig. 7. Partial cross section through the more lateral portion of the proximal tibia after 6 months of recovery from 10 weeks of restraint. This bone reveals extensive layers of lamellar bone delineated by several arrest lines. Remnants of arrest lines can be seen in cortical bone proper (+). H&E. X65

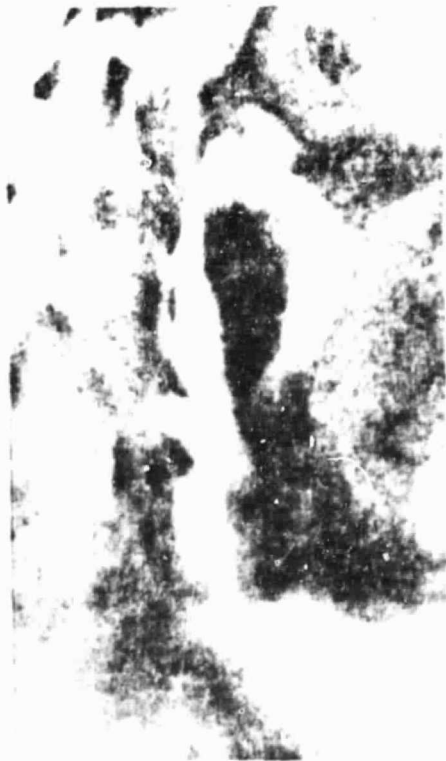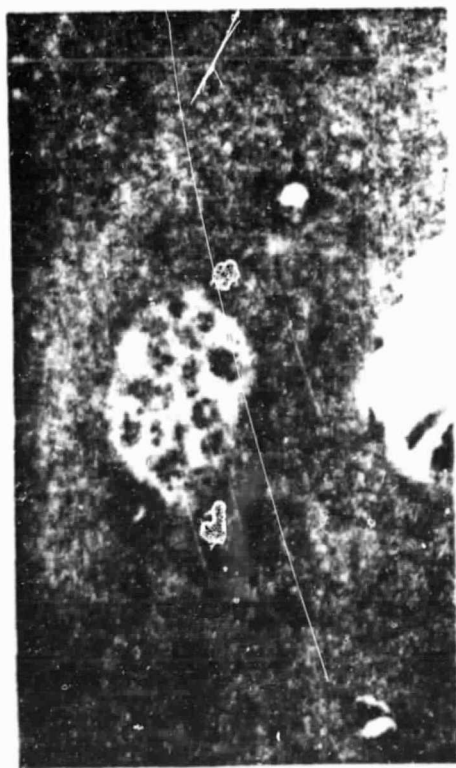


Legend for figure 8

ORIGINAL FIGURE
OF POOR QUALITY

Fig. 8. Osteoclasts during bone resorption.

- a. Resorption cavity located between the subperiosteal lamellar bone and haversian bone containing numerous osteoclasts. H&E. X240
- b. Longitudinal tibial bone section showing cutting cone with osteoclasts (+). H&E. X240
- c. Osteoclasts in Howship lacuna at periosteal surface. H&E. X1400



a

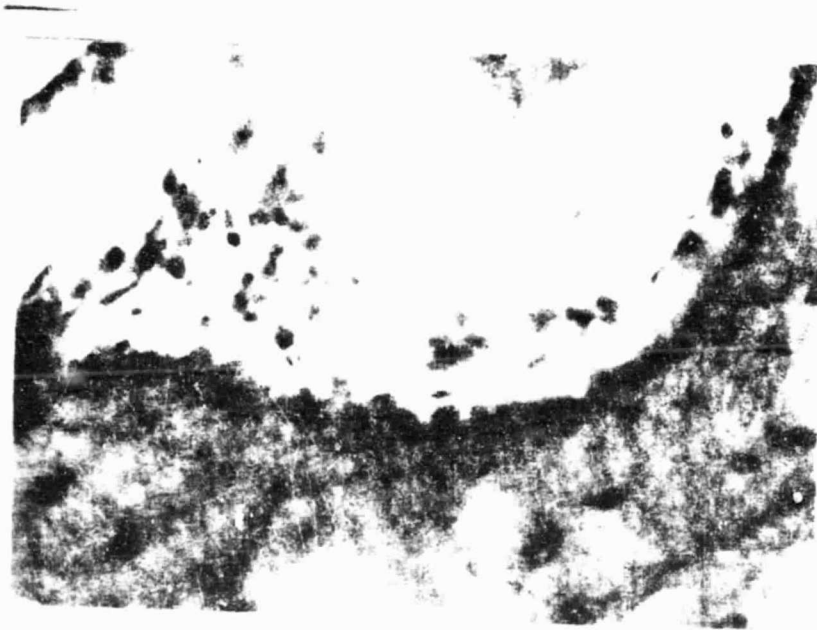
b

c

Legend for figure 9

ORIGINAL PAGE IS
OF POOR QUALITY

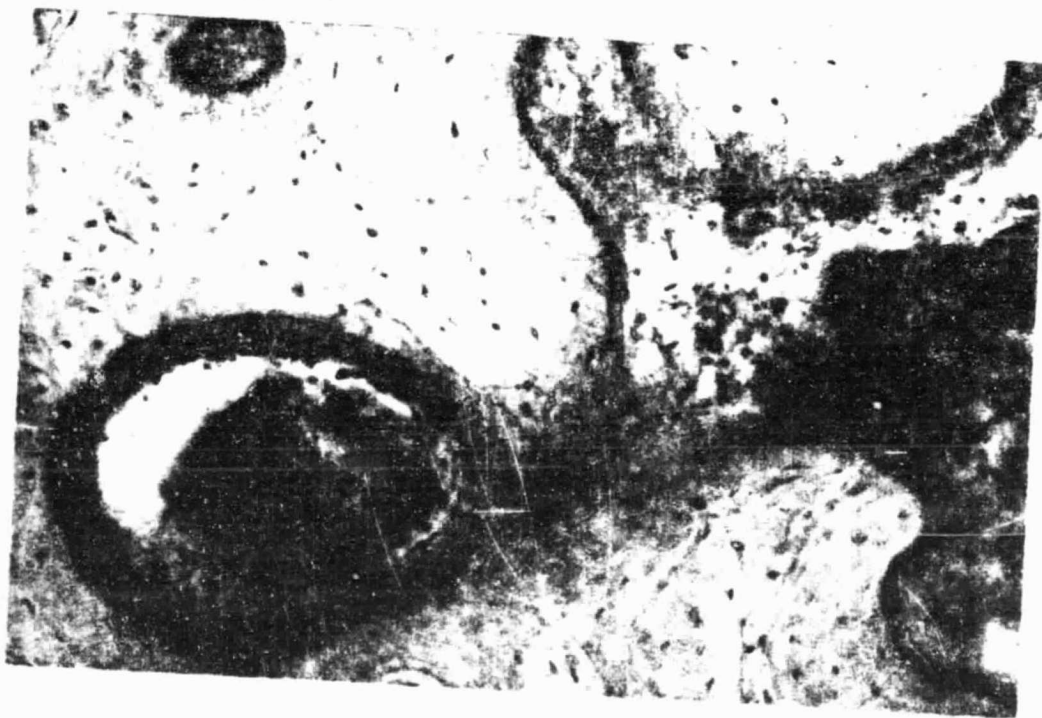Fig. 9. During restraint resorption cavity contains osteoblasts
or osteoblast-like cells. H&E. X420



Legend for figure 10

ORIGINAL PAGE IS
OF POOR QUALITY

Fig. 10. Resorption cavities after 2 months of recovery. Note the heavy layer of osteoid seam which is associated with cuboidal cells. Mod. Masson. X200



Acknowledgement. This study was supported in part by Grant No. NCC 2-125 with the University of San Francisco and Grant No. NAG 2-108 with the University of Utah.

Footnotes

Footnote to page 6

*Du Page Kinetic Laboratories, Inc., Downers Grove, IL 60515

Footnote to page 12

*Young, 1984, unpublished data.

ORIGINAL PAGE IS
OF POOR QUALITY