

Cricoid Pressure

Sharon Ann Van Wicklin, PhD, RN, CNOR, CRNFA(E), CPSN-R, PLNC, FAAN, ISPAN-F

Plastic and Aesthetic Nursing (PAN), the official journal of the International Society of Plastic and Aesthetic Nurses (ISPAN) publishes this column to provide accurate, evidence-based information about fundamental best practices for plastic and aesthetic nurses.

CRICOID PRESSURE

For more than 50 years, the *Sellick maneuver*, which is the application of *cricoid pressure* (Sellick, 1961), has been accepted as a standard component of general anesthesia (Dunn, 2022). Certified registered nurse anesthetists or anesthesiologists may ask plastic surgical nurses to apply cricoid pressure during the induction and intubation phases of general anesthesia if they anticipate a difficult intubation or if the patient presents with an increased risk for regurgitation (Dunn, 2022). Applying cricoid pressure prevents or reduces pulmonary aspiration of regurgitated gastric contents and air insufflation of the stomach (Sellick, 1961). Plastic surgical nurses should be knowledgeable of the relevant anatomy, understand the principles supporting its use, be able to identify the surface landmarks of the neck, and have the requisite skill to apply the Sellick maneuver correctly and safely.

ANATOMY

As shown in Figure 1, the larynx includes the thyroid and cricoid cartilages. The large, triangular-shaped *thyroid cartilage* is also known as the *Adam's apple* (Flanagan, 2019). The *cricoid cartilage*, located below the thyroid cartilage, is the only cartilage that completely encircles the trachea (Flanagan, 2019). These cartilages are easily palpable and

often visible on the neck. Pressure applied to the cricoid cartilage occludes the upper esophagus but allows the trachea to remain open (Sellick, 1961). Notably, excessive pressure can distort or deform this cartilage (Dunn, 2022).

The trachea is composed of 18–22 C- or U-shaped cartilaginous rings that easily collapse posteriorly in the areas where cartilage is absent, allowing the passage of food into the esophagus (Furlow & Mathisen, 2018). Because these rings do not completely surround the trachea, pressure applied to any location, other than the cricoid cartilage, does not occlude the esophagus and could result in regurgitation and pulmonary aspiration (Dunn, 2022).

APPLICATION

Cricoid pressure, applied correctly during general anesthesia induction and intubation, creates a physical barrier that prevents air from passing into the patient's stomach and prevents regurgitated stomach contents from passing into the airway (Sellick, 1961). To apply cricoid pressure effectively, the nurse should:

- Stand on the patient's right side, facing the patient.
- Place the fingers of the right hand either
 - slightly toward the posterior part of the patient's thyroid cartilage or
 - inferior to the patient's thyroid prominence.
- Press downward simultaneously using the thumb and index finger and gradually increase pressure using the index finger.
 - Apply pressure that is sufficient to occlude the esophagus, but not so forceful as to harm the surrounding tissues or cause airway obstruction.
 - To reduce movement of the cervical spine when there is a suspected cervical spine injury, simultaneously apply counterpressure to the back of the patient's neck.
- Not add, remove, or rearrange the fingers unless directed to do so by the anesthesia professional.
- Maintain cricoid pressure until the anesthesia professional requests that it be released (Dunn, 2022).

When performed incorrectly, the application of cricoid pressure can cause serious problems.

Incorrect finger positioning may increase the risk for aspiration, occlude or distort the anesthesia professional's view of the epiglottis, obstruct the airway, prevent the

Sharon Ann Van Wicklin, PhD, RN, CNOR, CRNFA(E), CPSN-R, PLNC, FAAN, ISPAN-F, is the Editor-in-Chief, *Plastic and Aesthetic Nursing*, and is a perioperative and legal nurse consultant, Aurora, CO.

The author reports no conflicts of interest.

Sharon Ann Van Wicklin is Editor-in-Chief of *Plastic and Aesthetic Nursing* and was excluded from the peer review process for this article.

Address correspondence to Sharon Ann Van Wicklin, PhD, RN, CNOR, CRNFA(E), CPSN-R, PLNC, FAAN, ISPAN-F, 8256 South Shawnee St, Aurora, CO 80016 (e-mail: sharonwvrn@ispan.org).

Copyright © 2022 International Society of Plastic and Aesthetic Nurses. All rights reserved.

DOI: 10.1097/PSN.0000000000000467

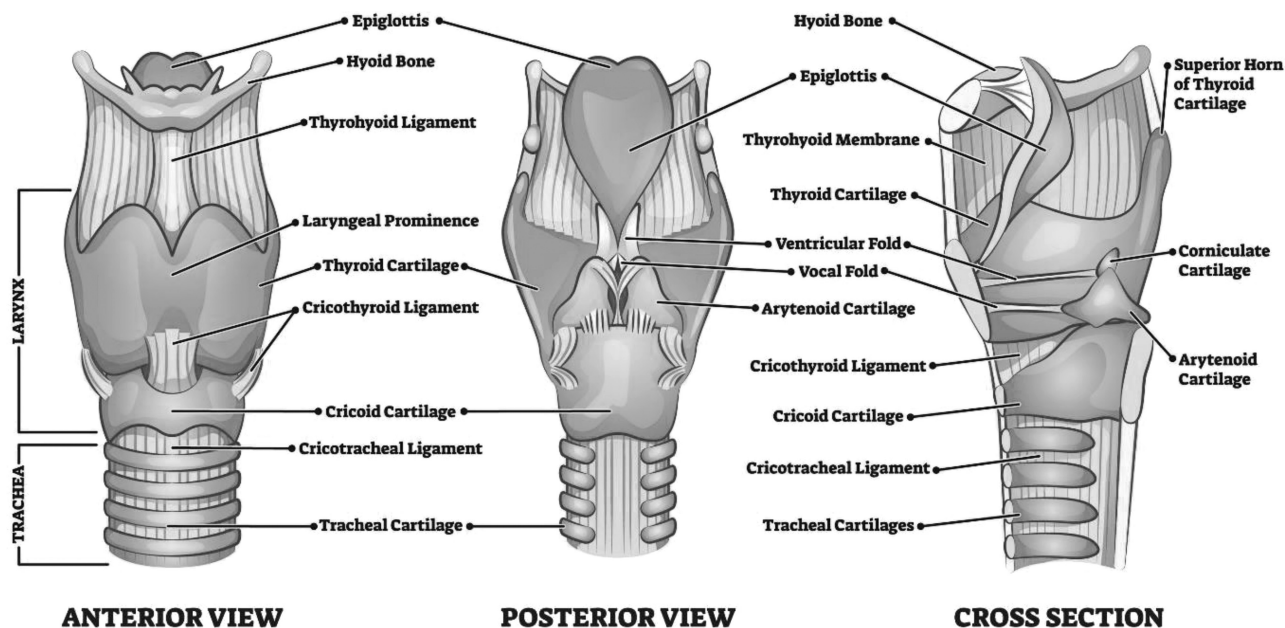


FIGURE 1. Anatomy of the larynx and trachea. From VectorMine/Shutterstock.com.

anesthesia professional from advancing the endotracheal tube, increase the difficulty of bag-mask ventilation, or cause thyroid bleeding.

Pressure is measured in newtons (N). The recommended amount of pressure that should be applied to an unconscious patient when performing the Sellick maneuver varies between 20 and 40 N, which is the equivalent of 2.08 kg (4.5 lb) to 4.08 kg (9.0 lb) of force (Ferk et al., 2015). Using insufficient force will fail to protect the airway; however, using excessive force can cause pain, dyspnea, coughing, gagging, retching, or vomiting and may also distort the anatomical view, obstruct the airway, or cause esophageal rupture or fracture of the cricoid cartilage (Dunn, 2022).

If the patient regurgitates while the nurse is applying cricoid pressure, the nurse should continue to maintain cricoid pressure to prevent pulmonary aspiration (Ferk et al., 2015). *Regurgitation* occurs when digestive fluids and undigested food rise from the esophagus into the mouth without abdominal contractions (Gottfried, 2022). Involuntary regurgitation is often a symptom of acid reflux.

If the patient vomits while the nurse is applying cricoid pressure, the nurse should immediately release the pressure to prevent esophageal rupture (Ferk et al., 2015). *Vomiting* is an active act resulting from high intragastric pressure that causes abdominal wall contractions to open the esophageal sphincter (Dunn, 2022).

CONTRAINDICATIONS

Performing cricoid pressure is contraindicated in patients with cervical spine trauma or fracture (actual or suspected),

cervical arthritis, laryngeal or tracheal injury or mass and in patients who are actively vomiting, may have a foreign body in the airways, or a history of difficult airway management (Dunn, 2022).

BENEFITS VERSUS HARMS

Controversy regarding the benefits of cricoid pressure has been ongoing for more than two decades. It is unclear whether the results of the studies demonstrating potential harms associated with the application of cricoid pressure are the result of the maneuver itself or the maneuver being performed incorrectly (Dunn, 2022). Some researchers have found that the application of cricoid pressure may

- Activate upper airway reflexes in semiconscious patients.
- Misalign the larynx and trachea and distort or obstruct the upper airway resulting in an inability to ventilate the patient.
- Interfere with direct laryngoscopy.
- Increase the risk for aspiration.
- Increase the difficulty of intubation (Dunn, 2022).

On the other hand, there is evidence to show that cricoid pressure prevents air from entering the stomach, which reduces the risk for aspiration (Avery et al., 2021).

Most health care providers and the organizations that develop guidelines for anesthesia support the use of cricoid pressure (Athanasoglou & Pandit, 2015; Ferk et al., 2015). Applying cricoid pressure is considered a low-risk maneuver to avoid a high-risk pulmonary aspiration event, and it is “unlikely that [health care providers] will ever

abandon its use because it makes intuitive sense” (Snider et al., 2005, p. 104). According to the American Society of PeriAnesthesia Nurses, “abandoning cricoid pressure in patients with known or suspected aspiration risk factors ... would be unethical. Until there is conclusive evidence to suggest otherwise, cricoid cartilage pressure should be used for at-risk patients” (Beavers et al., 2009, p. 94).

Although additional research is needed to determine morbidity and mortality rates based on the application of cricoid pressure, it is unlikely that any institutional review board would approve a clinical trial that involved withholding of the maneuver (Stewart et al., 2014).

EDUCATION AND TRAINING

Plastic surgical nurses and other health care professionals who may be called upon to provide cricoid pressure should undergo education and training (Dunn, 2022). *Education* includes receiving information relevant to performing the maneuver correctly (e.g., anatomy, procedural description, potential complications, and contraindications) (Dunn, 2022). *Training* includes mastering the steps and skills necessary to perform cricoid pressure correctly. Training is not particularly difficult or time consuming but does require practice to attain correct finger placement and apply pressure at the correct pressure ranges (Dunn, 2022).

If you are a plastic or aesthetic nurse and would like to write about an issue of fundamental importance to plastic or aesthetic nurses, or if you would like to see your issue presented in a future Fundamentals of Plastic and Aesthetic Nursing Practice column of PAN, please contact Sharon Ann Van Wicklin, Editor-in-Chief at sharonvwrn@ispan.org.

REFERENCES

- Athanassoglou, V., & Pandit, J. J. (2015). Cricoid pressure: The case in favour. *Trends in Anaesthesia Critical Care*, 5(2-3), 57-60. <https://doi.org/10.1016/j.tacc.2015.02.001>
- Avery, P., Morton, S., Raitt, J., Lossius, H. M., & Lockey, D. (2021). Rapid sequence induction: Where did the consensus go? *Scandinavian Journal of Trauma, Resuscitation and Emergency Medicine*, 29(1), 64. <https://doi.org/10.1186/s13049-021-00883-5>
- Beavers, R. A., Moos, D. D., & Cuddeford, J. D. (2009). Analysis of the application of cricoid pressure: Implications for the clinician. *Journal of Perianesthesia Nursing*, 24(2), 92-102. <https://doi.org/10.1016/j.jopan.2009.01.006>
- Dunn, D. (2022). Cricoid pressure: Contradictory evidence regarding a standard practice. *AORN Journal*, 115(5), 423-436. <https://doi.org/10.1002/aorn.13666>
- Flanagan, A. L. (2019). Otorhinolaryngologic surgery. In J. C., Rothrock & D. R. McEwen (Eds.), *Alexander's care of the patient in surgery* (16th ed., pp. 616-636). Elsevier.
- Frerk, C., Mitchell, V. S., McNarry, A. F., Mendonca, C., Bhagrath, R., Patel, A., O'Sullivan, E. P., Woodall, N. M., & Ahmad, I., & Difficult Airway Society Intubation Guidelines Working Group. (2015). Difficult Airway Society 2015 guidelines for management of unanticipated difficult intubation in adults. *British Journal of Anaesthesia*, 115(6), 827-848. <https://doi.org/10.1093/bja/aev371>
- Furlow, P. W., & Mathisen, D. J. (2018). Surgical anatomy of the trachea. *Annals of Cardiothoracic Surgery*, 7(2), 255-260. <https://doi.org/10/21037/acs.2018.03.01>
- Gotfried, J. (2022). Regurgitation and rumination. In *Merck Manual Consumer Version*. <https://www.merckmanuals.com/home/digestive-disorders/symptoms-of-digestive-disorders/regurgitation-and-rumination>
- Sellick, B. A. (1961). Cricoid pressure to control regurgitation of stomach contents during induction of anaesthesia. *Lancet*, 2(7199), 404-406. [https://doi.org/10.1016/s0140-6736\(61\)92485-0](https://doi.org/10.1016/s0140-6736(61)92485-0)
- Snider, D. D., Clarke, D., & Finucane, B. T. (2005). The “BURP” maneuver worsens the glottic view when applied in combination with cricoid pressure. *Canadian Journal of Anaesthesia*, 52(1), 100-104. <https://doi.org/10.1007/BF03018589>
- Stewart, J. C., Bhananker, S., & Ramaiah, R. (2014). Rapid-sequence intubation and cricoid pressure. *International Journal of Critical Illness and Injury Science*, 4(1), 42-49. <https://doi.org/10.4103/2229-5151.128012>

The test for this nursing continuing professional development activity can be taken at www.NursingCenter.com/CE/PSN.