

# Minimally Invasive Conjunctivodacryocystorhinostomy with Jones Tube

Martin H. Devoto, M.D.\*, Francesco P. Bernardini, M.D.†, and Carlo de Conciliis, M.D.‡

\*Consultores Oftalmologicos, Buenos Aires, Argentina; †Ospedale Evangelico Internazionale, Genova and Ospedale Evangelico Valdese, Torino, Italy; and ‡Ospedale S. Giuseppe, Milano, Italy.

---

**Purpose:** To describe a minimally invasive technique for conjunctivodacryocystorhinostomy with the Jones tube. This technique creates a direct communication between the conjunctiva and the middle meatus with the use of a 14-gauge angiocatheter. The glass tube is inserted under endoscopic or direct visualization.

**Methods:** A retrospective review of consecutive patients who underwent the minimally invasive technique for conjunctivodacryocystorhinostomy for complete bicanalicular lacrimal obstruction was performed. The surgical time, intraoperative and postoperative complications, length of the tubes, long-term patency, tube displacement, and need for secondary revision were evaluated.

**Results:** Fifty-five consecutive patients were included in the study. All surgical procedures were successfully performed without significant complications, in an operating time that averaged 16 minutes. In one early case, a patient had persistent postoperative bleeding that required cauterization of the middle turbinate. In 3 patients, late migration of the Jones tube into the nasal cavity required secondary intervention with successful Jones tube repositioning. Minor office tube cleaning was performed without removal of the tube. The patency of the Jones tube was regularly tested with demonstration of aspiration of 2% fluorescein solution from the tear meniscus in the tear lake opening of the tube at the slit lamp, the passage of the same solution in the nose with endoscopic view, and finally, with irrigation of saline solution in the tube.

**Conclusions:** The minimally invasive technique for conjunctivodacryocystorhinostomy with the Jones tube can be successfully performed with a simple “poke-through” technique from the conjunctiva to the nose with direct or endoscopic control. This technique has proved to be time-effective and well tolerated by patients.

---

Complete bicanalicular obstruction has been traditionally treated by a lacrimal bypass surgery described by Lester Jones.<sup>1</sup> This procedure consists of a skin incision, opening of the lacrimal sac with flaps, a large osteotomy, and the placement of a glass tube to ensure long-term patency of the path created between the conjunctiva and the nose. This operation may also be indicated for failed dacryocystorhinostomy (DCR)<sup>2,3</sup> and for lacrimal pump dysfunction.<sup>4</sup> This technique, although effective,<sup>5,6</sup> is time-consuming and technically difficult to perform. Recently, with the advent of endoscopic lacrimal surgery, a “closed” approach with no skin incision has been described, but a formal endonasal osteotomy is still performed.<sup>7,8</sup> We treated a group of patients with a minimally invasive conjunctivodacryocystorhinostomy (MICDCR), a straightforward technique that relies on a direct 3-mm communication between the

conjunctiva and the nose, without a skin incision, dissection of flaps, or a large osteotomy, which reduces intraoperative time and allows the use of local anesthesia.

## METHODS

A retrospective review of the charts of 55 consecutive patients who underwent primary MICDCR from 1997 to 2004 was performed. All patients underwent preoperative lacrimal probing and irrigation to confirm complete bicanalicular obstruction. Surgical times were obtained from the operative notes, intraoperative and postoperative complications were assessed, and length of the Jones tubes, long-term patency of the Jones tube, tube displacement, and need for secondary revision were evaluated.

**Surgical Technique.** Patients are given preoperative nasal packing with 4% lidocaine and 0.05% oxymetazoline nasal spray. The nasal mucosa is injected intranasally with 3 ml of 2% lidocaine with 1:100,000 epinephrine, using a 27-gauge spinal needle. The caruncle and inner canthal area are infiltrated with the same solution in patients undergoing the operation under general or local anesthesia to obtain hemostasis and anesthesia. The inferior third of the caruncle is excised. A 14-gauge intravenous catheter is inserted from the semilunar fold in the place where the caruncular excision was made, directed inferiorly and medially in the middle meatus through the thin lacrimal bone posterior to the anterior lacrimal crest, under

---

Accepted for publication January 27, 2006.

Presented as a free paper at the American Society of Ophthalmic Plastic and Reconstructive Surgeons Fall Meeting, Chicago, Illinois, U.S.A., October 2005.

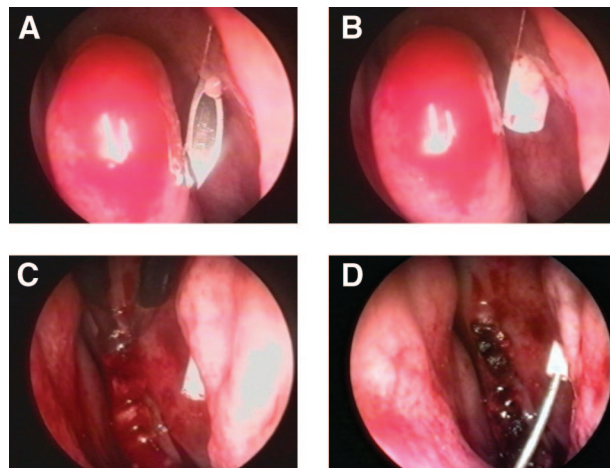
Address correspondence and reprint requests to Dr. Martín H. Devoto, Consultores Oftalmológicos, Montevideo 1410, 1018 Ciudad de Buenos Aires, Argentina. E-mail: info@martindevoto.com.

DOI: 10.1097/01.iop.0000226861.02781.af

endoscopic view, just anterior to the middle turbinate (Figure, A). This maneuver is performed by the surgeon while an assistant holds the endoscope, attached to a video monitor, placed in such a way as to allow the surgeon to shift his or her attention from the middle meatus to the endonasal view. The angiocatheter is very slowly advanced through the tissues until the bone is felt. At this point, the instrument is further advanced at the slowest possible pace to avoid injury to the septum or the middle turbinate as the bone is breached. When this operation is done without the endoscope, the angiocatheter is advanced until the bone is felt to break and then, a nasal speculum is placed to have direct vision of the catheter as it is further advanced. If the needle does not go through the bone, it is withdrawn a few millimeters and angled more posterior to go through thinner bone. Once the distal end of the angiocatheter is seen in the nose, the needle of the catheter is withdrawn, leaving the Teflon sheath in place (Figure, B). A guide wire is inserted through the sheath, and the latter is removed (Figure, C). A Jones tube (Weiss Scientific Glass Blowing Company, Portland, Ore, U.S.A.) is inserted, sliding it along the guide wire, under endoscopic or direct endonasal visualization. If the tube cannot be inserted, the track may be enlarged with a gold dilator. An anterior middle turbinectomy may be performed during the same procedure, if needed, to ensure a wide space at the nasal end of the Jones tube (Figure, D). The tube is checked for appropriate length and exchanged for a different one if needed, before removing the guide wire. The tube is then anchored in position with a double-armed, 5-0 nylon suture passed around the neck of the tube and then full thickness through the skin. It is removed 10 days after the procedure.

## RESULTS

Fifty-five consecutive patients underwent MICDCR between January 1997 and June 2005. Thirty-two were women and 23 were men. Patient age ranged from 22 to 92 years, with an average of 41 years. All surgical procedures were performed on an outpatient basis. Operative time averaged 16 minutes ( $\pm 6$ ). Thirteen patients underwent a bilateral procedure. Thirty-five cases were done under local anesthesia with intravenous sedation, and 20 were done under general anesthesia. All surgeries were performed without intraoperative complications. The average length of tube was 16 mm ( $\pm 4$ ). In none of the cases was there a need for removing more bone or enlarging the osteotomy. One patient had persistent bilateral nasal bleeding that required cauterization of turbinates. Seven patients had migration of the tube toward the nose, with successful repositioning in the office with topical anesthesia in 4 of them. The other 3 patients needed minor room revision under local anesthesia because the conjunctiva had closed the track. In all these cases, the tubes were repositioned. One patient had 4 events of tube migration, and the tube was changed for one with a 4.5-mm neck without further migrations, with a follow-up of 3 years. Four patients had pyogenic granulomas or redundant conjunctival folds that occluded the tube and needed excision. Of the 55 patients, 33 were followed for more than 3 years. Patients were seen every 6 months to check tube permeability and to perform tube cleaning. We have not seen acute dacryocystitis or lacrimal sac problems. All patients were satisfied with the procedure and had complete relief of tearing.



**A**, The angiocatheter is directed toward the nose under endoscopic control. **B**, The needle is withdrawn, leaving the Teflon sheath in position. **C**, A guide wire is passed through the Teflon sheath to help insert the Jones tube. **D**, A limited anterior turbinectomy is performed, and bipolar cautery is applied.

## DISCUSSION

Conjunctivorhinostomy with the Jones tube remains the mainstay of therapy for complete bicanalicular obstruction. The procedure relies on bypassing the normal lacrimal outflow with the help of a thin Pyrex tube. Traditionally, this technique has been performed with an external skin incision approach, opening the lacrimal sac, and creating flaps in a similar fashion as in external DCR.<sup>2-4,9</sup> A large bony opening is advocated to ensure the tube fixation by soft tissues.<sup>1,9,10</sup> It has been thought that the contact between the tube and bone increases the incidence of complications.<sup>10</sup> Other authors have shown that using a smaller osteotomy can result in satisfactory outcome.<sup>11</sup> The use of a holmium laser to perform the track has been associated with a high success rate and low morbidity.<sup>12</sup> However, the use of lasers increases the cost of the procedure.

MICDCR is performed under endoscopic or direct visualization. The use of the endoscope has helped to develop lacrimal surgery and has been previously reported as an aid in CDCR.<sup>7,8,12-16</sup> Direct endonasal DCR without the use of an endoscope has been reported as a very successful procedure.<sup>17</sup> We have also performed MICDCR with direct visualization by using surgical loupes and a fiberoptic headlight in several patients. This approach has the advantage of allowing the use of both hands during surgery. This is particularly useful in patients with increased bleeding, in whom a suction line may be held in the nondominant hand.

MICDCR is performed with a direct communication between the conjunctiva and the nose, passing through the lacrimal sac. Acute dacryocystitis has been reported<sup>18</sup> in patients with Jones tubes, but we have not encountered such complication in our series.

This "closed" technique for CDCR avoids the skin

incision used in the conventional approach. Although the appearance of the skin incision after external CDCR is acceptable,<sup>19</sup> young patients and the pigmented population may be at risk of a visible scar.

The MICDCR minimizes tissue trauma, but several patients needed an anterior middle turbinectomy for adequate space at the nasal end of the tube. Middle turbinectomy may lead to nasal adhesions and scarring,<sup>20</sup> but we have not found this problem in any of our patients. We believe that a middle turbinectomy that is limited to allow a wide space at the nasal end of the tube, performed with special care not to injure the septal mucosa, is safe and greatly improves the outcome of the operation, reducing the incidence of reoperations to change the length of the tube. When the Jones tube is inserted through a conventional approach, it is usually angled 10 to 20 degrees inferiorly, reaching a region in the nose where the septum and the lateral wall of the nose are closer together. This leads to less margin of error when choosing the appropriate length of the tube. Good hemostasis of the turbinate is needed to avoid postoperative bleeding, as happened in one of our early patients in whom only packing was used to minimize scarring.

Minor complications such as pyogenic granulomas, conjunctival occlusion of the tube, and excessive secretions needing tube cleaning are frequently observed after CDCR. In our series, the most prevalent complication was tube migration toward the nose. All our patients are instructed to return for an examination if they have sudden onset of tearing to avoid a permanent closure of the conjunctiva over the tube. Seven patients had tube migration, with successful repositioning in the office, under topical anesthesia in 4 of them. All these 4 patients were seen less than 5 days after new onset of tearing. The other 3 were seen after 1 week of tearing, and a permanent closure was diagnosed. These tubes were repositioned surgically with local anesthesia. One patient had 4 episodes of tube migration. A larger, 4.5-mm flange tube was inserted and prevented subsequent migrations. The use of a frosted tube<sup>21</sup> or a Gladstone-Putterman tube<sup>22</sup> may also help to prevent this complication.

Traditional CDCR usually has been performed under general anesthesia.<sup>6</sup> Most of our patients, particularly in the last 4 years, were operated on under local anesthesia with intravenous sedation. This was possible because this procedure is very fast, and there is minimal blood loss. This has allowed elderly patients to benefit from this operation. The average time of the procedure in our series was 16 minutes. Other authors comparing CDCR techniques have found an average operative time of 59 minutes for the endoscopic technique and 74 minutes for the external technique.<sup>7</sup>

The limitations of our study are that it is retrospective

and that longer follow-up may be needed to determine any long-term complications.<sup>23</sup>

In conclusion, MICDCR is a straightforward procedure that allows the insertion of a Jones tube in time-efficient manner, with endoscopic or direct intranasal control. This technique is performed in a "closed" fashion without a skin incision or a large bony osteotomy, using very simple instruments.

## REFERENCES

1. Jones LT. Conjunctivodacryocystorhinostomy. *Am J Ophthalmol* 1965;59:773-83.
2. Doucet TW, Hurwitz JJ. Canaliculodacryocystorhinostomy in the management of unsuccessful lacrimal surgery. *Arch Ophthalmol* 1982;100:619-21.
3. Welham RA, Guthoff R. The Lester-Jones tube: a 15-year follow-up. *Graefes Arch Clin Exp Ophthalmol* 1985;223:106-8.
4. Doucet TW, Hurwitz JJ. Canaliculodacryocystorhinostomy in the treatment of canalicular obstruction. *Arch Ophthalmol* 1982;100:306-9.
5. Lamping K, Levine MR. Jones tubes: how good are they? *Arch Ophthalmol* 1983;101:260-1.
6. Steinsapir KD, Glatt HJ, Putterman AM. A 16-year study of conjunctival dacryocystorhinostomy. *Am J Ophthalmol* 1990;109:387-93.
7. Trotter WL, Meyer DR. Endoscopic conjunctivodacryocystorhinostomy with Jones tube placement. *Ophthalmology* 2000;107:1206-9.
8. Boboridis K, Olver JM. Endoscopic endonasal assistance with Jones lacrimal bypass tubes. *Ophthalmic Surg Lasers* 2000;31:43-8.
9. Jones LT. Conjunctivodacryocystorhinostomy. *J All India Ophthalmol Soc* 1967;15:86-93.
10. Henderson PN. A modified trephining technique for the insertion of Jones tube. *Arch Ophthalmol* 1985;103:1582-5.
11. Lee JS, Jung G, Lee JE, et al. The treatment of lacrimal apparatus obstruction with the use of an inner canthal Jones tube insertion via a transcaruncular route. *Ophthalmic Surg Lasers* 2001;32:48-54.
12. Boboridis KG, Downes RN. Endoscopic placement of Jones lacrimal tubes with the assistance of holmium YAG laser. *Orbit* 2005;24:67-71.
13. Gonnering RS, Lyon DB, Fisher JC. Endoscopic laser-assisted lacrimal surgery. *Am J Ophthalmol* 1991;111:152-7.
14. Komínek P, Červenka S. Conjunctivodacryocystorhinostomy tube placement with a urologic catheter. *Ophthalm Plast Reconstr Surg* 2005;21:235-6.
15. Krishnan G, Prepageran N, Muthu K. Endonasal endoscopic dacryocystorhinostomy. *Med J Malaysia* 2002;57:404-7.
16. Leibovitch I, Sheikh I, Selva D, et al. Endonasal endoscopic assisted replacement of lacrimal drainage tubes. *Orbit* 2005;24:191-4.
17. Dolman PJ. Comparison of external dacryocystorhinostomy with nonlaser endonasal dacryocystorhinostomy. *Ophthalmology* 2003;110:78-84.
18. Schellini SA, Shiratori CA, Castilho EC, Nakanishi M. Pseudodacryocystitis: a complication related to a Lester-Jones tube. *Jpn J Ophthalmol* 2004;48:509-10.
19. Devoto MH, Zaffaroni MC, Bernardini FP, de Conciliis C. Postoperative evaluation of skin incision in external dacryocystorhinostomy. *Ophthalm Plast Reconstr Surg* 2004;20:358-61.
20. Gustafson RO, Bartley GB. A plea for preservation of the middle turbinate during dacryocystorhinostomy. *Ophthalm Plast Reconstr Surg* 1999;15:75-6.
21. Dailey RA, Tower RN. Frosted Jones Pyrex tubes. *Ophthalm Plast Reconstr Surg* 2005;21:185-7.
22. Gladstone GJ, Putterman AM. A modified glass tube for conjunctivodacryocystorhinostomy. *Arch Ophthalmol* 1985;103:1229-30.
23. Bartley GB, Gustafson RO. Complications of malpositioned Jones tubes. *Am J Ophthalmol* 1990;109:66-9.