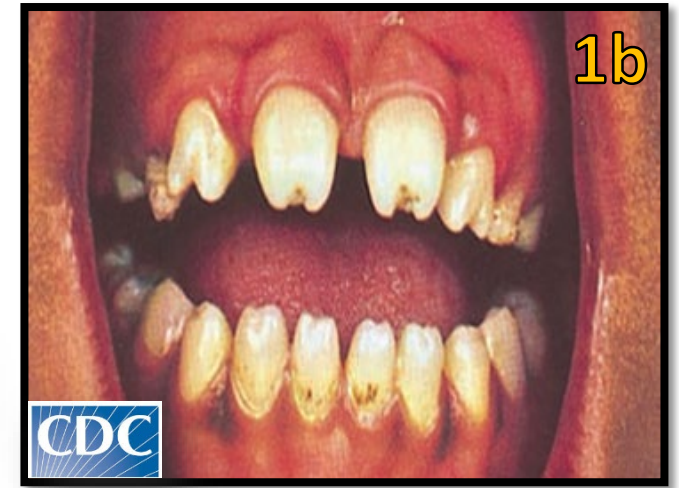
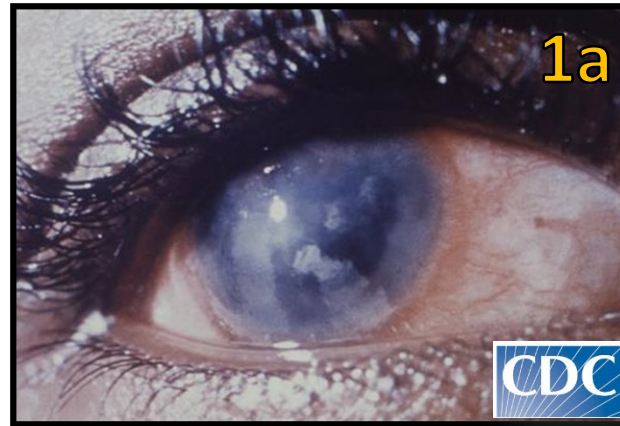
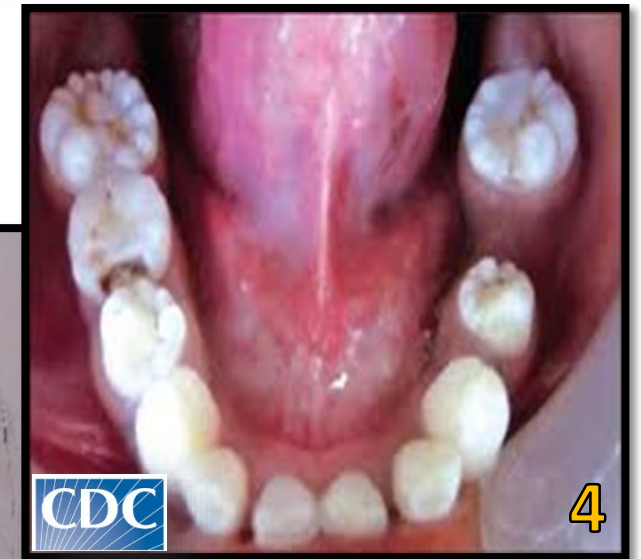
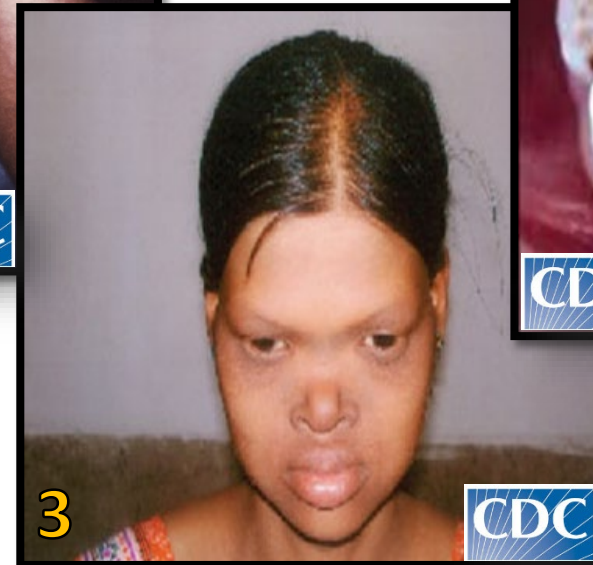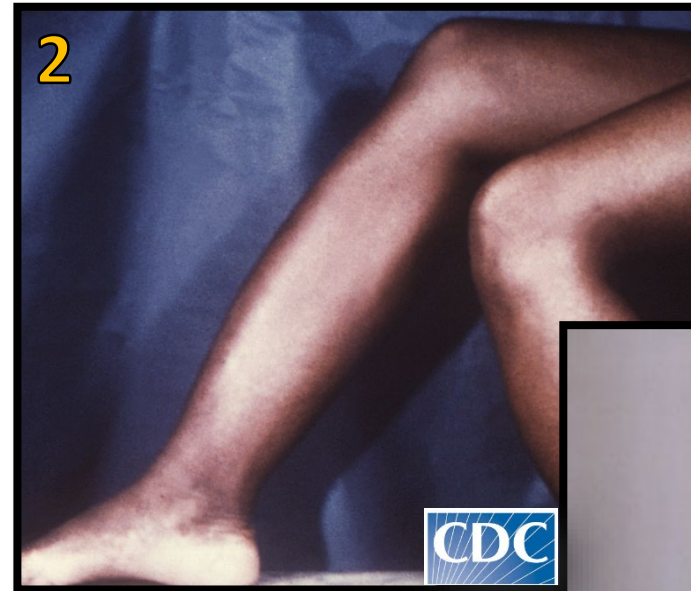Late Congenital Syphilis

- Typically manifests after two years of life



1. Hutchinson's Triad
 - a) Interstitial Keratitis
 - b) Hutchinson's Teeth
 - c) Deafness
2. Saber Shin
3. Frontal bossing & Saddle nose
4. Mulberry Molars
 - Anemia
 - Jaundice
 - Neurologic signs
 - Lymphadenopathy
 - Mucous patches
 - Placental abnormalities



Photos 1b,2-4
Courtesy of Dr. Stephanie Taylor
Centers for Disease Control &
Prevention (CDC)