

From Department of Clinical Science, Intervention and Technology
(CLINTEC), Division of Surgery
Karolinska Institutet, Stockholm, Sweden

THE PAPILLA OF VATER
ISSUES RELEVANT TO TRANSPAPILLARY CANNULATION AND
CLINICAL MANAGEMENT

Erik Haraldsson



**Karolinska
Institutet**

Stockholm 2020

All previously published papers were reproduced with permission from the publisher.

Published by Karolinska Institutet.

Cover image created by Erik Haraldsson

Printed by Eprint AB 2019

© Erik Haraldsson, 2020

ISBN 978-91-7831-633-5

The Papilla of Vater.
Issues relevant to transpapillary cannulation and clinical
management

THESIS FOR DOCTORAL DEGREE (Ph.D.)

will be publicly defended in the lecture room B64, at the Karolinska University Hospital,
Huddinge, Stockholm on

Friday the 31th of January 2020, at 13:00

By

Erik Haraldsson

Principal Supervisor:

Urban Arnelo, Assoc. Professor
Karolinska Institutet
Department of Clinical Science, Intervention and
Technology (CLINTEC)
Division of Surgery

Co-supervisor(s):

Matthias Löhr, Professor
Karolinska Institutet
Department of Clinical Science, Intervention and
Technology (CLINTEC)
Division of Surgery

Kjell-Arne Ung, Assoc. Professor
University of Gothenburg, Sahlgrenska Academy
Institute of Medicine
Department of Internal Medicine
and Clinical Nutrition

Opponent:

Colin McKay, Professor
University of Glasgow
Institute of Cancer Sciences

Examination Board:

Claes Jönsson, Assoc. Professor
University of Gothenburg, Sahlgrenska Academy
Institute of Clinical Sciences
Division of Surgery

Ib Rasmussen, Assoc. Professor
Uppsala University
Department of Surgical Sciences
Division of Upper Abdominal Surgery

Stefan Linder, Assoc. Professor
Karolinska Institutet
Department of Clinical Science, Intervention and
Technology (CLINTEC)
Division of Surgery

To Maria, Jonatan, David and Junis

“The seemingly impossible is possible”

Hans Rosling

*“It is not the path which is the difficulty;
rather, it is the difficulty which is the path”*

Søren Kirkegaard

*“But as long as a man has the strength to dream
He can redeem his soul and fly”*

Elvis Presley

ABSTRACT

Background: Many endoscopists have since the beginning of endoscopic retrograde cholangiopancreatography (ERCP) commented on the variation in the macroscopic appearance of the papilla of Vater. How the macroscopic appearance of the papilla influences the cannulation efforts during ERCP has been discussed but not previously investigated in-depth. The endoscopic appearance can also be distorted by neoplastic lesions that can develop into cancer if not treated in time. Endoscopic papillectomy has evolved as a treatment option to cure these lesions if detected at an early stage. This thesis focuses on the influence of the endoscopic appearance on transpapillary cannulation, also how to clinically manage early neoplastic lesions situated in the papilla of Vater.

Objectives: I), To introduce a new inter- and intraobserver validated classification of the endoscopic appearance of the papilla of Vater. II), Apply the classification to investigate if the endoscopic appearance influences transpapillary cannulation during ERCP. III), Evaluate the minimally invasive method of endoscopic papillectomy in the treatment of early neoplastic lesions in the papilla of Vater, including evaluating the significance of KRAS analysis on the resected specimen. IV), To investigate what symptoms and preinterventional findings that could be of value for clinical decision-making when choosing the best method to resect ampullary neoplastic lesions when an invasive malignancy is not clear.

Methods: I) Constructing a web-based survey where 18 endoscopists categorized photos of 50 different papillae from the suggested classification. II) A Nordic multi-center study, measuring bile duct cannulation in 1401 patients after the papillae have been categorized into one of the distinct papilla types from the proposed classification. Determination of the frequency of difficult cannulation among the papilla types. III) A case series including 36 patients treated with endoscopic papillectomy, evaluating the clinical outcome and safety. Also, determining the status in the resected specimen of mutated KRAS to evaluate if that could predict the clinical prognosis. IV) A descriptive analysis of all patients treated with endoscopic papillectomy and/or surgical resection for verified or suspected ampullary neoplasia from 2006 to June 2018, where no invasive lesion was seen at cross-sectional imaging. Analyzing the symptoms, the histopathological results, and other investigational findings, comparing these with the final diagnosis after resection.

Results: The classification consisting of four distinct types of papillae showed a substantial inter- ($\kappa=0.62$) and intraobserver ($\kappa=0.66$) agreement among beginners as well as experienced endoscopists and was therefore possible to use in study II. The second study showed that bile duct cannulation was significantly more often difficult in small papilla, Type 2 (52%, 95% CI 45-59%) and protruding or pendulous papilla, Type 3 (48%, 95% CI 42-53%) compared to regular, Type 1 papilla (36%, 95% CI 33-40%). Failure to cannulate were more frequent if an inexperienced endoscopist started cannulation attempts. In study III 50% of the patients were cured from adenomatous neoplasia with endoscopic papillectomy. A small number of patients had mild to moderate complications. The results from KRAS analysis were hard to interpret. The preinterventional diagnosis changed in many patients after the endoscopic resection, raising questions that will be addressed in study IV. In study IV, if a histological diagnosis of malignancy could not be made before surgical resection, there was a high frequency of patients with benign or early neoplastic lesions treated with major pancreatic surgery. If endoscopic forceps biopsies show adenoma, endoscopic papillectomy has a curative potential in 59% of the patients.

Conclusions: 1. The macroscopic appearance of the papilla of Vater influences bile duct cannulation during ERCP, both among experts and beginner endoscopists: 2. Endoscopic papillectomy is a reasonably safe procedure with the potential to cure early neoplastic lesions in the papilla of Vater, and if not curative, offer a comprehensive tissue diagnosis that can guide clinical management. 3. Before deciding on surgical resection of a suspected neoplastic ampullary lesion, efforts must be made to get a histological confirmation of malignancy. When biopsies show adenoma, endoscopic papillectomy should be considered to cure the patient or at any rate get a confirmation of malignant disease.

LIST OF SCIENTIFIC PAPERS

- I. *Haraldsson, E., Lundell, L., Swahn, F., Enochsson, L., Löhr, J., Arnelo, U.* (2016). **Endoscopic classification of the papilla of Vater. Results of an inter- and intraobserver agreement study**
United European Gastroenterology Journal 5(4), 504-510.
- II. *Haraldsson, E., Kylänpää, L., Grönroos, J., Saarela, A., Toth, E., Qvigstad, G., Hult, M., Lindström, O., Laine, S., Karjula, H., Hauge, T., Sadik, R., Arnelo, U.* (2019). **The macroscopic appearance of the major duodenal papilla influences bile duct cannulation: a prospective multicenter study by the Scandinavian Association for Digestive Endoscopy study group for ERCP**
Gastrointestinal Endoscopy 90(6), 957-963.
- III. *Haraldsson, E., Swahn, F., Verbeke, C., Mattsson, J., Enochsson, L., Ung, K., Lundell, L., Heuchel, R., Löhr, J., Arnelo, U.* (2015). **Endoscopic papillectomy and KRAS expression in the treatment of adenoma in the major duodenal papilla**
Scandinavian Journal of Gastroenterology 50(11), 1419-1427.
- IV. *Haraldsson, E., Halimi, A., Al-Saffar, H.A., Zarantonello, L., Rangelova, E., Löhr, J.M., Arnelo, U.* **Endoscopic and/or surgical resection for adenomatous neoplasia in the papilla of Vater. The Karolinska Experience 2006-2018**
In manuscript

Contents

1	Background.....	7
1.1	History	7
1.2	Eponyms and terminology.....	7
1.3	Anatomy of the ampullary region.....	9
1.3.1	The papilla of Vater	9
1.3.2	Ductal anatomy	10
1.3.3	The Sphincter of Oddi.....	10
1.4	Histology of the ampullary region.....	10
1.5	Endoscopic appearance of the papilla of Vater	12
1.5.1	Cannulation and the appearance of the papilla of Vater	12
1.5.2	Diseases affecting the appearance of the papilla of Vater	13
1.6	Adenomatous neoplasia of the ampullary region	14
1.6.1	Premalignant lesions in the ampullary region.....	14
1.6.2	Classification of ampullary neoplastic lesions.....	16
1.6.3	Histopathological staging of ampullary adenocarcinoma.....	17
1.6.4	Prognostic factors in ampullary adenocarcinoma.....	18
1.7	Endoscopic retrograde cholangiopancreatography.....	20
1.7.1	Cannulation during ERCP.....	20
1.7.2	Definitions of difficult cannulation.....	21
1.7.3	Acute post-ERCP pancreatitis (PEP).....	22
1.7.4	Other complications after ERCP.....	22
1.7.5	Risk factors for PEP.....	23
1.7.6	Methods to reduce the risk for post-ERCP pancreatitis.....	24
1.8	Evaluation of suspected neoplastic lesions in the papilla.....	25
1.8.1	Cross-sectional imaging of ampullary lesions.....	26
1.8.2	Endoscopic ultrasonography in ampullary neoplasia	26
1.8.3	Cytology of ampullary lesions	26
1.8.4	Endoscopic biopsies.....	27
1.9	Treating neoplastic lesions in the papilla of Vater	27
1.9.1	Pancreatoduodenectomy (PDE) (Whipple’s operation).....	27
1.9.2	Trans-duodenal ampullectomy (TA).....	28
1.9.3	Endoscopic papillectomy (EP).....	30
2	Aims.....	33
3	Methods	34
3.1	Paper I.....	34
3.1.1	Study design.....	34
3.1.2	Creation of the endoscopic classification	34
3.1.3	Inter- and intraobserver agreement study	34
3.1.4	Kappa statistics	35
3.2	Paper II.....	36
3.2.1	Study design.....	36
3.2.2	Patients.....	36
3.2.3	Outcome measures	36
3.2.4	The experience of the endoscopists	36
3.2.5	Statistical analysis.....	37
3.2.6	Ethical considerations	37

3.3	Paper III.....	37
3.3.1	Study design	37
3.3.2	Patients and data collection	37
3.3.3	Outcome measures after endoscopic papillectomy	37
3.3.4	Endoscopic papillectomy technique	38
3.3.5	KRAS analysis.....	38
3.3.6	Ethical considerations.....	38
3.4	Paper IV.....	38
3.4.1	Study design	38
3.4.2	Patients and data collection	38
3.4.3	Outcome measures.....	39
3.4.4	Ethical considerations.....	39
4	Results.....	41
4.1	Paper I	41
4.1.1	Interobserver agreement	41
4.1.2	Intraobserver agreement	41
4.1.3	Comments.....	41
4.2	Paper II	42
4.2.1	Patients and distribution of the papilla types.....	42
4.2.2	Frequency of difficult cannulation among the papilla types	42
4.2.3	Endoscopist experience and difficult cannulation	43
4.2.4	Cannulation technique and papilla type	44
4.2.5	Complications and the papilla types.....	45
4.2.6	Failed cannulation and the papilla types	46
4.3	Paper III.....	46
4.3.1	Procedures and complications	46
4.3.2	Histomorphology.....	46
4.3.3	KRAS analysis.....	47
4.3.4	Clinical follow-up.....	47
4.4	Paper IV.....	48
4.4.1	Patients	48
4.4.2	Cross-sectional imaging	48
4.4.3	The final histopathological diagnosis	49
4.4.4	Endoscopic biopsies and brush cytology.....	49
4.4.5	EUS and final diagnosis	49
4.4.6	Endoscopic papillectomy (EP)	50
4.4.7	Surgical resection	51
5	Discussion.....	54
5.1	The endoscopic appearance and bile duct cannulation	54
5.1.1	Interobserver agreement in classification studies been proven to	54
5.1.2	The endoscopic appearance and difficult cannulation.....	54
5.1.3	Endoscopic appearance and cannulation technique	55
5.1.4	Consequences for training in ERCP	56
5.1.5	Difficult cannulation frequency as a measure of proficiency.....	56
5.2	Endoscopic papillectomy	57
5.2.1	Clinical outcome after Endoscopic papillectomy.....	57
5.2.2	Complications after endoscopic papillectomy.....	57
5.3	Clinical management of ampullary neoplastic lesions	58
5.3.1	Early symptoms of an ampullary lesion	58

5.3.2	Imaging and ampullary neoplastic lesions.....	58
5.3.3	Endoscopic biopsies in ampullary neoplasia	59
5.3.4	Importance of KRAS mutational status	60
5.4	Endoscopic papillectomy or surgical resection	60
5.4.1	Can patients with adenocarcinoma be endoscopically cured?	60
5.4.2	How to avoid “unnecessary” surgery?	61
5.4.3	Suggested evaluation algorithm for suspected ampullary lesions	61
6	Conclusions.....	63
7	Proposals for further research.....	64
8	Populärvetenskaplig sammanfattning	65
9	Acknowledgements	69
10	References.....	72

LIST OF ABBREVIATIONS

ERCP	Endoscopic Retrograde Cholangio-Pancreatography
PEP	Post- ERCP pancreatitis
EP	Endoscopic papillectomy
EUS	Endoscopic ultrasonography
IDUS	Intra-ductal ultrasonography
PDE	Pancreatoduodenectomy (Whipple's operation)
TA	Transduodenal ampullectomy
HGD	High-grade Dysplasia
LGD	Low-grade Dysplasia
TNM	Tumor-Node-Metastasis classification of malignant tumors
AJCC	American Joint Committee on Cancer
ESGE	European Society of Gastrointestinal Endoscopy
SADE	Scandinavian Assiciation for Digestive Endoscopy
ASGE	American Society of Gastrointestinal Endoscopy
MDCT	Multi-detector computed tomography
CT	Computed Tomography
MRI	Magnetic resonance imaging
MRCP	Magnetic Resonance Cholangio-Pancreatography
IAPN	Intra-ampullary papillary-tubular neoplasia
KRAS	Kirsten rat sarcoma oncogen
AJCC	American Joint Committee on Cancer
UICC	Union for International Cancer Control

1 BACKGROUND

1.1 HISTORY

Abraham Vater (1684-1751) (Flati and Andrén-Sandberg 2002) presented in his anatomical dissertation at the University of Wittenberg (1720), a dilatation (diverticula) at the junction of the bile duct and the pancreatic duct before their joint opening into the duodenum, now days referred to as the Ampulla of Vater (Vater 1720). The name ampulla referring to an ancient Roman glass or earthenware flask with two handles and a globular body made to hold precious fluids (Gaspar and Shami 2015), Figure 1. Similarly, the ampulla of Vater “holds” two of the body’s most precious fluids, bile, and pancreatic juice.



Figure 1. “Ampulla” Coptic. Pilgrim Flask, 5th-7th century C.E. Terracotta
From Brooklyn Museum online collection. "Pilgrim Flask" is licensed under CC BY 3.0

Abraham Vater was not the first to describe the biliopancreatic ampulla or the junction of the bile duct and the main pancreatic duct (Wood 1979; Stern 1986). Already Vesalius, in 1543, described that the bile duct drains into the duodenum (Hand 1963) and later Wirsung, in 1642, when he described the main pancreatic duct noted that the orifice of the ducts emptied into the duodenum at the papilla. Santorini should probably have the honors for correctly describing the joint distal ends of the pancreatobiliary ducts. Mirilas et al. (2005) mean that what Abraham Vater described was a peri-vaterian diverticulum and not the anatomical ductal dilatation that now bears his name.

Abraham Vater died in 1751 after five days of jaundice (Lerch and Domschke 2000) but his name is forever ascribed to this anatomical structure. The name of Vater has also been given to the mucosal protrusion, bulging out from the medial duodenal wall referred to as the papilla of Vater. This nipple-like protrusion holds the orifice of the joint pancreatobiliary duct as it opens into the intestine, and was mentioned already by Vesalius and described in more detail by Samuel Collins in 1685 (Stern 1986), Figure 2.

1.2 EPONYMS AND TERMINOLOGY

The eponym’s papilla of Vater and ampulla of Vater should possibly be avoided to prevent mistakes and mix-ups between these two different, but closely related, anatomic structures (Mirilas et al. 2005). Naming the ampulla and the papilla with the same eponym can be confusing. It is suggested that the use of these eponyms should be abandoned and instead use the terms, major duodenal papilla and biliopancreatic ampulla (Mirilas et al. 2005). Nevertheless, the terms Papilla of Vater and Ampulla of Vater are widely used and are seen in many recent publications (Imamura et al 2019; Kim et al. 2019)

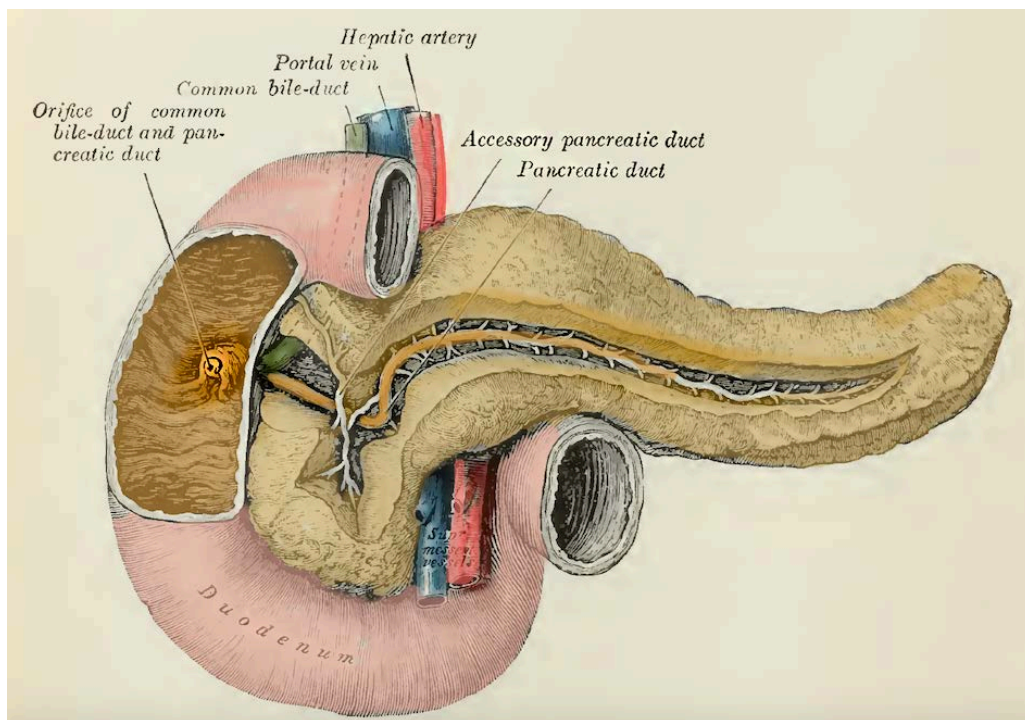


Figure 2. The Pancreas and Duodenum with the Papilla of Vater (highlighted)
 Henry Gray (1821–1865), *Anatomy of the Human Body*, 1918 (copyright expired).

Two other terms that also need some clarification are, the ampullary region, and the periampullary region. When discussing about tumors in the ampullary and periampullary regions, the terms are sometimes used in an unclear manner.

Periampullary carcinomas are often defined as all malignant tumors arising within 2 cm of the major duodenal papilla (Sarmiento et al. 2001), or all tumors that can be resected with a standard pancreatoduodenectomy (Whipple’s procedure) (He et al. 2014), Figure 3. The term “periampullary tumors” incorporate four different malignancies in the proximity of the ampulla: pancreatic cancer in the head of the pancreas, distal bile duct cancer, ampullary cancer, and duodenal cancer.

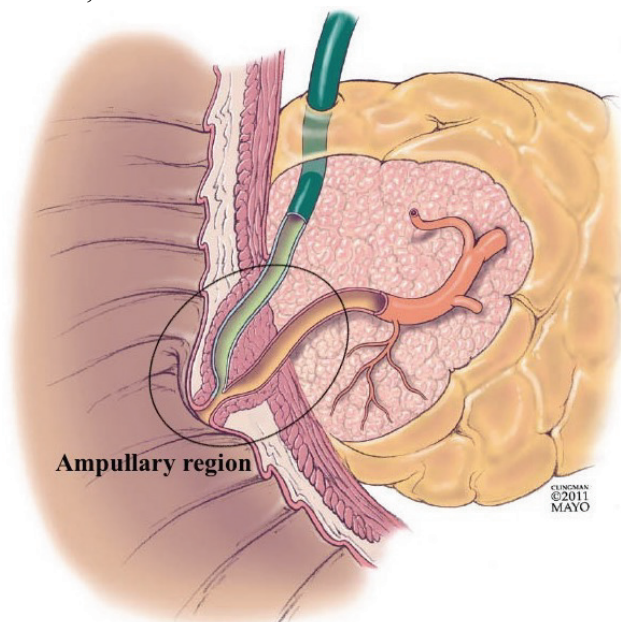


Figure 3. The periampullary region, with the ampullary region encircled. The ampullary region includes the ampulla, the papillary prominence, the sphincteric apparatus and the duodenal mucosal surface of the papilla.

Adopted from Davee, T. et al. (2012). *Percut sphincterotomy for selective biliary duct cannulation during endoscopic retrograde cholangiopancreatography. Annals of Gastroenterology* 25(4), 291-302.
<https://www.ncbi.nlm.nih.gov/pubmed/24714256>
 Licensed under CC-BY-NC SA 3.0

The ampullary region is the central part of the periampullary region and has four distinct parts centered around the opening of the biliopancreatic ductal systems into the intestine, Figure 3. First, the ampullary region includes the distal parts of the common bile duct and the pancreatic duct as they pass through the duodenal wall before opening into the duodenal lumen. The ducts either merge into a dilated common channel, the ampulla of Vater with a single ductal opening, or continue as two separate ducts thru the papilla. Secondly, there is the papilla of Vater, which is the duodenal protuberance in the second part of the duodenum, the nipple-like structure surrounding the ducts as they enter the intestine. The third part of the ampullary region is the duodenal intestinal mucosa (ampullary duodenum) covering the outside of the papilla. Finally, the complex of smooth muscles (sphincter of Oddi) together with the accessory pancreatobiliary ducts and the mucous glands around the ampulla also are part of the ampullary region (Dhall et al. 2015).

In some reports are the ampullary adenocarcinomas that originates from the duodenal surface, on the outside of the papilla (ampullary duodenum), called periampullary carcinomas. The use of the term periampullary tumors are therefore not clear and can be a source for confusion.

1.3 ANATOMY OF THE AMPULLARY REGION

1.3.1 The papilla of Vater

The papilla of Vater, or major duodenal papilla, is in most humans (82 %), located on the posteromedial wall of the second part of the duodenum, about 10.5 cm (range 7-13 cm) from the pylorus (Lindner et al. 1976; Flati et al. 1994), Figure 4. It can be found closer to the pylorus on rare occasions and even in the third part of the duodenum (Dowdy et al. 1962). Lindner et al. (1976) reported that intraoperative cholangiograms, in as much as 13% of the patients, revealed that the common bile duct ended distal to or at the lower angle of the duodenum.

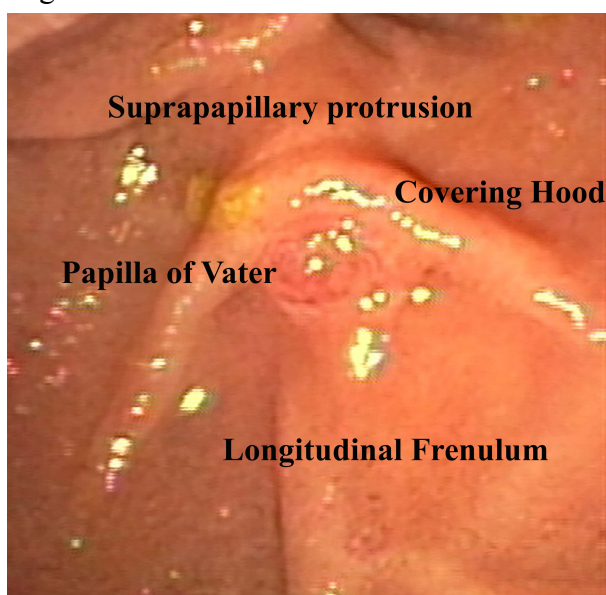


Figure 4. The anatomical landmarks of the Papilla of Vater.

The shape of the papilla is usually cylindrical-conic (78%) or hemispheric (14%) with a single ductal opening (94%) holding the orifice of the joint pancreatobiliary ductal systems (Flati et al. 1994; Horiguchi and Kamisawa 2010). Anatomical studies have described it as having a width of 5 mm (range 3-8 mm) and a protrusion of 7.7 mm (range 0-20mm) (Dowdy et al. 1962; Flati et al. 1994; Avisse et al. 2000; Skalicky 2011). The papilla, is in most patients (86%), partially or entirely, covered by a supra-papillary mucosal fold (hood)

and is in 76% of people associated with one or several caudally extending longitudinal folds (frenulum) of variable length (Avisse et al. 2000; Kim et al. 2008).

Endoscopists can use the frenulum, inferior of the papilla, as a guide when trying to locate the papilla during endoscopic examinations of the duodenum.

1.3.2 Ductal anatomy

Inside the papilla, there is considerable variability in the anatomy of the pancreatobiliary ductal system (Hand 1963), Figure 5. The junction of the bile duct and the main pancreatic duct can be classified into four types depending on how and if the ducts merge and in what way they merge inside the duodenal wall (Dowdy et al. 1962). The most frequent is the Y type (60%), with a common channel of more than 1.5 mm and a classic ampulla. The Y-type can be divided into a short (type a, 1.5-10 mm) or a long (type b, >10mm) type, depending on the length of the merged channel. In the U type (22%), the ducts are in parallel, with only an interductal septum separating the ducts all the way to the orifice. The ducts have separate openings on the papilla but in the same papilla. There are no muscle fibers separating the ducts in the U-type. Neither does the V type (14%), have the classic ampulla, instead, it has a short common channel, less than 1.5 mm long. The last type is the uncommon, II type with separate orifices in two separate papillae with separate sphincteric muscles (Dimagno et al. 1982; Wilasrusmee and Pongchairerks 1999, Kim et al. 2008).

If the common channel is even longer, >15 mm, or merge outside the duodenal wall, it is considered to be a congenital anomaly, pancreaticobiliary maljunction (Misra and Dwivedi 1990; Kamisawa et al. 2012, 2014). Pancreatobiliary maljunction is a risk factor for the development of bile duct carcinoma (Kamisawa et al. 2017; Hyvärinen et al. 2019), gallbladder carcinoma (Kamisawa et al. 2017b), or acute and chronic pancreatitis (Kamisawa et al. 2002; Löhr et al. 2012).

1.3.3 The Sphincter of Oddi

Underneath the mucosal surface, there is an intricate neuromuscular system with several sphincteric muscles that encircle the distal ends of the pancreatic and biliary ducts and the distal end of the common duct in the ampulla. This system of smooth muscular bundles is called the sphincter of Oddi (1887). The small sphincteric smooth muscles are regulated by several neurohormonal mediators, and they act separately from the musculature of the duodenal wall. The sphincteric apparatus acts to regulate the outflow of bile and pancreatic juice but also to obstruct duodenal content from entering the ducts (Staritz 1988; Kher and Guelrud 2004).

Dietary fat in the duodenal lumen, as well as acidic content, causes the sphincteric mechanism to relax (Kalloo and Pasricha 1995; Rosenblatt et al. 2001) opening up for the outflow of bile and pancreatic juice. These physiological functions of the sphincteric apparatus might ease cannulation during ERCP (Barrie et al. 2006; Fang et al. 2018). Several pharmaceutical substances have also been tested for both relaxation and contraction of the sphincteric mechanism and their potential effect on bile duct cannulation during ERCP (Thompson 2001; Woods and Saccone 2007).

1.4 HISTOLOGY OF THE AMPULLARY REGION

The ampullary region is a meeting point for several histologically different structures in a small area. The distal ends of the main pancreatic and common bile ducts; the intestinal mucosa on the duodenal outer surface of the ampulla; the ductules in the ampullary wall and the transitional zone of the papilla of Vater (Pant et al. 2018).

The outer surface of the major duodenal papilla, ampullary duodenum, is covered with intestinal simple columnar epithelium of small intestinal type, consisting of enterocytes, and with a higher frequency of interspersed goblet cells compared to further down in the

small intestine. On the papilla of Vater, the area of transition between the intestinal mucosa and the ductal epithelium, there is a mixture of foveolar-like cells and increased amounts of goblet cells. Inside the pancreatobiliary ducts or ampulla, the mucosa forms prominent papillary folds with a fibrovascular core, meant to minimize the reflux of duodenal content into the ductal system (de Sanctis and Tagliaferri 1968). In situations where there is no real ampulla, these extensive papillary folds instead fill out the distal part of the separate ducts. The extensive folds inside the ampullary lumen may play a part in difficulties during bile duct cannulation (Paulsen et al. 2002). The more proximal bile duct or pancreatic ducts are lined by cylindrical, monostratified, ductal epithelium with occasional goblet cells, but no absorptive-type cells (Frierson 1989).

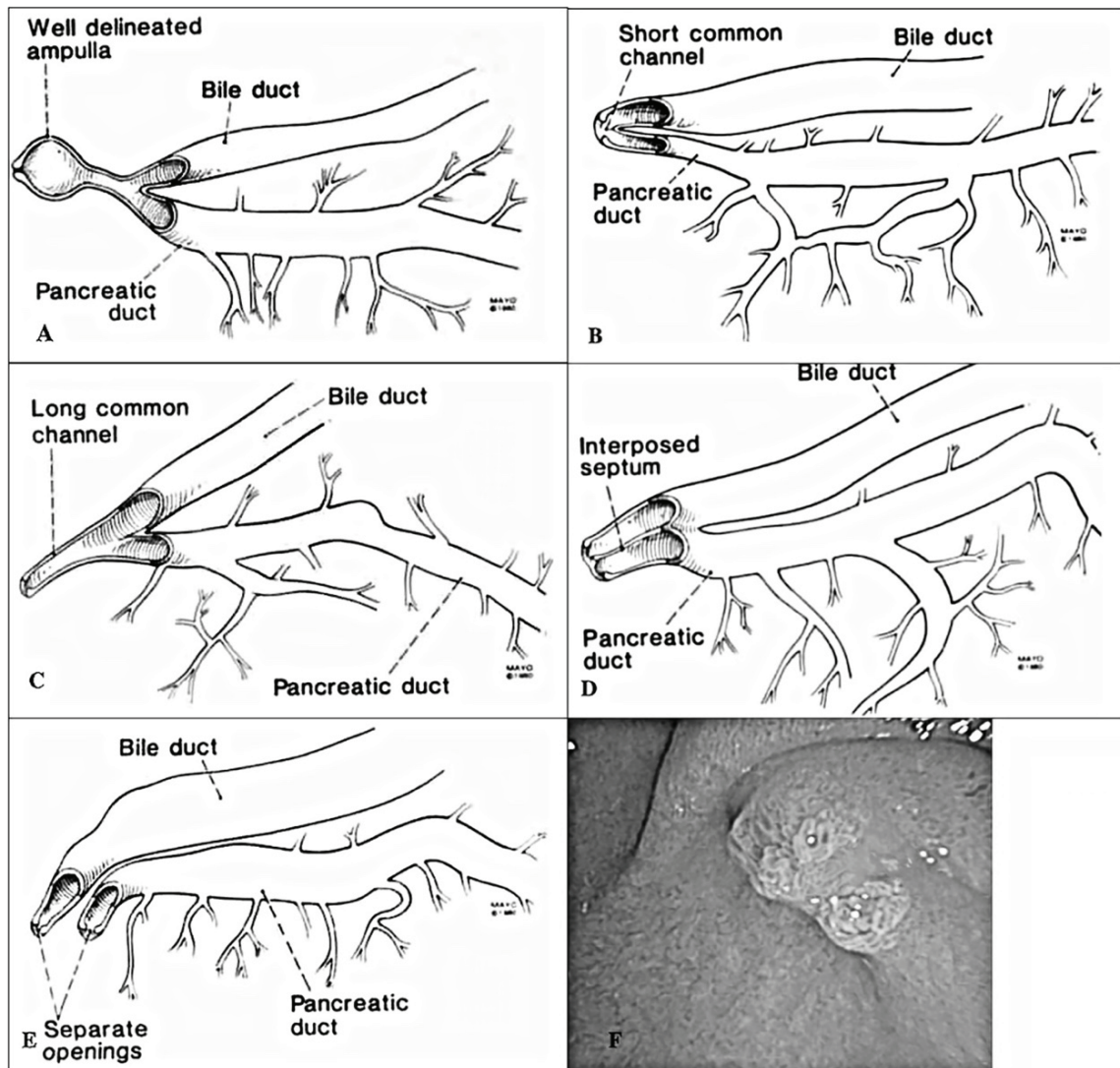


Figure 5. The different variants of ductal anatomy in the ampullary region. (A) Y-Type with developed ampulla. (B) V-Type, with very short (<1,5mm) common channel, (C) Y-Type with long common channel (> 10 mm), (D) U-Type, with a septum between the ducts all the way to the orifice. (E) II-Type, with two separate orifices and sometimes separate papillae. (F) Papilla with separate orifices.

From: Dimagno, E. et al., (1982) "Relationships between pancreatobiliary ductal anatomy and pancreatic ductal and parenchymal histology", *Cancer* 49(2), 361-368.

Reprinted with permission from John Wiley and Sons.

[https://doi.org/10.1002/1097-0142\(19820115\)49:2%3C361::AID-CNCR2820490225%3E3.0.CO;2-O](https://doi.org/10.1002/1097-0142(19820115)49:2%3C361::AID-CNCR2820490225%3E3.0.CO;2-O)

1.5 ENDOSCOPIC APPEARANCE OF THE PAPILLA OF VATER

Besides the anatomical characteristics of the major duodenal papilla, there are many variations in the endoscopic appearance, as seen at the time of endoscopic examination, Figure 6. The papilla may be large or small, swollen by diseases or hidden under the supra-papillary mucosal folds, and the amount of protrusion may also differ considerably (Silvis et al. 1983, Lee et al. 2014b). There has since the beginning of endoscopic bile duct cannulation been several authorities mentioning that the appearance of the papilla contributes to difficult or failed cannulation (Bourke et al. 2009; Swan et al. 2011; Bakman and Freeman 2013; Pan et al. 2015; Testoni et al. 2016). To date, there is no validated classification of the endoscopic appearance of the major duodenal papilla.

Horiuchi et al. (2007) presented a classification of the endoscopic appearance of the papilla, based on the amount of protrusion on the oral side of the papilla. In their classification there was no interobserver agreement validation made to see if different endoscopists had similar opinions of the types of papillae that they proposed. The classification included three types of papillae. Small type, with no oral protrusion, large type, with oral protrusion and the swollen type, with marked oral protrusion. These three different papilla types were applied to guide the endoscopists in selecting pre-cutting technique after they had failed with routine cannulation. In the classification, suggested by Horiuchi et al., there was no distinction between the different appearances of the papilla if there were no oral protrusion; instead, all papillae without protrusion were called small. Lee et al. (2011) expanded the classification proposed by Horiuchi et al. (2007), to include a “distorted type” ascribed to a papilla with unclassifiable characteristics. They measured successful cannulation between the different papilla types when using pre-cut fistulotomy technique after failed primary cannulation. They could not draw any conclusions about the different appearances of the papilla and the cannulation frequency.

1.5.1 Cannulation and the appearance of the papilla of Vater

Swan et al. (2011) proposed a list of risk factors that could cause failed cannulation, and among those factors were “a long and mobile intraduodenal part of the bile duct” or a “small papilla” mentioned. When discussing cannulation difficulties and the use of auxiliary techniques, it is suggested that endoscopists should use transpancreatic biliary sphincterotomy as the preferred pre-cut technique when having difficulties cannulating a small papilla (Katsinelos et al. 2012; Testoni et al. 2016), and the opposite approach, when cannulating a protuberant papilla, using either needle knife papillotomy or fistulotomy techniques instead (Katsinelos et al. 2015).

Another technical aspect mentioned when trying to cannulate a “small” papilla is to use a technique with the guidewire protruding 2-3 mm out of the sphincterotome (Reddy et al. 2017) to be more delicate when trying to find the correct duct. In a study about cannulation and ERCP-training, Pan et al (2015) found that an “abnormal papilla” was more difficult for a trainee to cannulate. The definition of an “abnormal papilla” was a “swollen, tiny, or hook-nose-shaped papilla”. The position of the papilla inside a diverticulum or “not in the second part of the duodenum” was also considered abnormal.

None of the above examples have made any definition of the variation in appearance between the different types of papillae, and there has not been any quantification to what extent the difficulties during cannulation of a certain type of papilla exists.

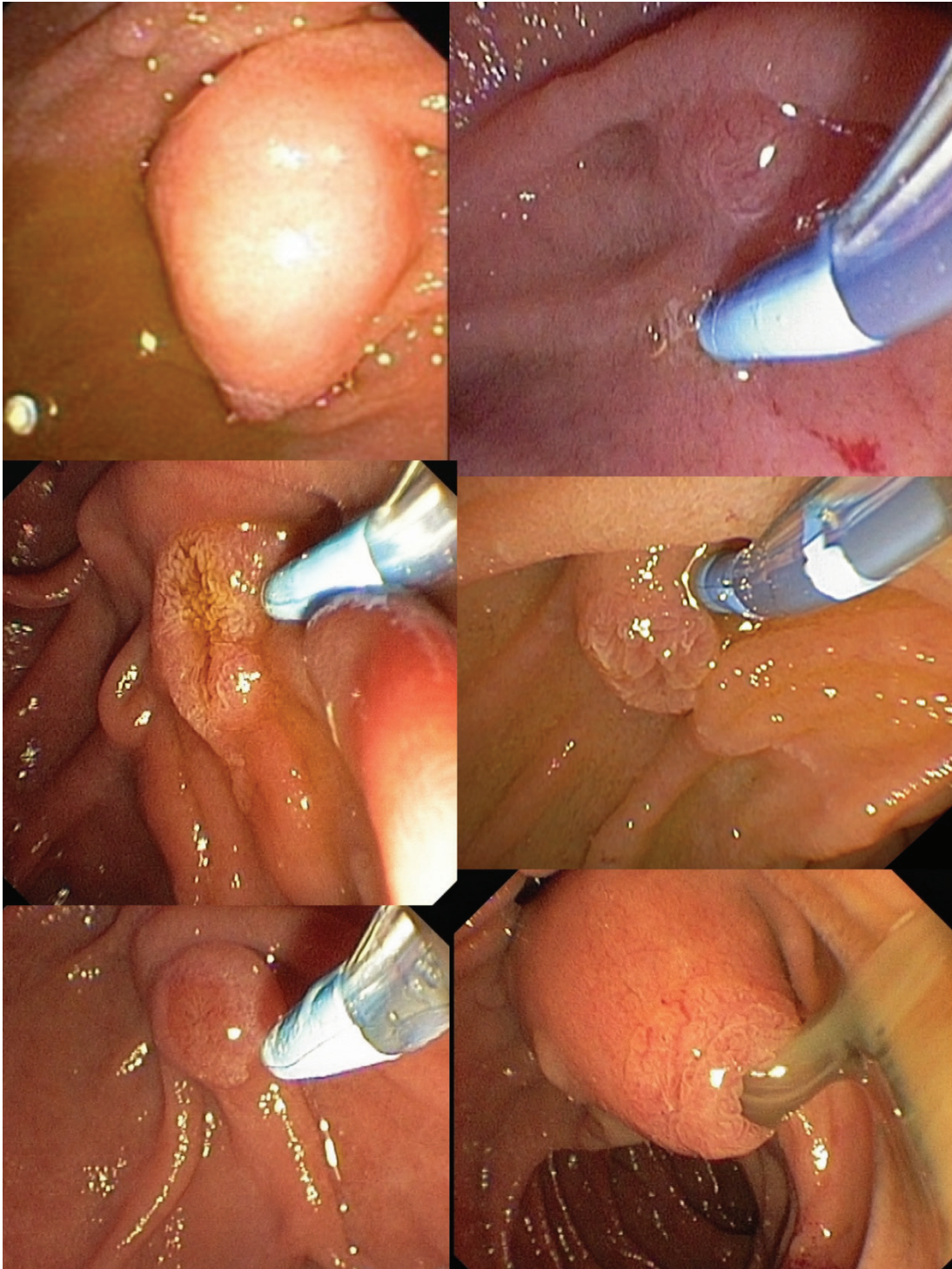

Figure 6. Examples of the various endoscopic appearances of the papilla of Vater.

1.5.2 Diseases affecting the appearance of the papilla of Vater

Already Leese et al (1986) described the difficulties in determining if the papilla was affected by neoplastic disease or inflammatory disease based only on the tumor-like endoscopic appearance of the papilla. Patients could have lesions that are inseparable on endoscopic inspection from those with malignancy, still, in 23 % of patients they turned out not to be malignant. Chang et al (1990) continued that discussion and noted that the presence of ulceration in a tumor-suspected lesion was more often a sign of underlying malignancy. Patients that proved to have a benign disease, even if the papilla had a malignant appearance, often had choledochal stones as the underlying explanation. Yamaguchi et al. (1990) described different endoscopic appearances of the papilla in patients with adenomas or carcinomas in the ampullary region. The papilla could be

protruding with intramural swelling caused by an underlying tumor, protruding with a visible tumor on the papilla surface, or having an ulcerating process. They reported that the ulcerating and the intramurally protruding appearances were in most patients malignant. The “exposed protruding” type could be either benign or malignant, and that the visual impression was of little use when faced with that type of endoscopic appearance.

Lee et al. (2014a) noted that the endoscopic appearance and forceps biopsies have equal sensitivity at determining if a lesion is benign or malignant. In the work by DeOliveria et al (2006) they concluded that the endoscopic appearance during duodenoscopy had a higher sensitivity (86%) and accuracy (83%) to correctly diagnose a neoplastic lesion as malignant, compared to endoscopic biopsies, sensitivity (65%) and accuracy (67%). It is an interesting result and must be repeated in a more extensive study to draw any confident conclusions and the visual impression has to be validated among multiple observers to be useful.

Kim et al (2008) reported that the bulging of the papilla, seen on MRI, but without a visible mucosal lesion could be caused by an ampullary tumor, impacted choledochal stones, secondary to a ductal mucin-producing tumor, or secondary to either cholangitis or pancreatitis.

Skalicky (2011) measured several papillae before and after cholecystectomy using EUS and noticed that the papilla increased in size during the first months after the operation. This effect was transient, and the size of the papilla, on repeated measures, went back to the preoperative size again after six months.

There are reports saying that a swollen papilla might also indicate that the patient has an autoimmune or sclerosing pancreatitis (Unno et al 2002). The swelling of the papilla attributed to autoimmune pancreatitis has been described as a severe swelling of the papilla itself and not of the supra papillary protrusion or the duodenal surroundings. This kind of swelling of the papilla corresponds to the swelling of the intraduodenal part of the biliopancreatic ducts (Kubota et al 2007). Combining the finding of a swollen papilla during endoscopic examination and biopsies of the papilla showing IgG4 positive plasma cells is, a clear sign of autoimmune pancreatitis (Kubota et al. 2007; Shimosegawa et al. 2011). Kubota et al. (2008) also report that in patients with primary sclerosing cholangitis, there was rarely a swelling of the papilla. Patients with primary sclerosing cholangitis had more often a small or retracted papilla instead, and this could help to differentiate between sclerosing cholangitis secondary to autoimmune pancreatitis and primary sclerosing cholangitis. Others have also noted that retraction of the papilla are a frequent finding in patients with extrahepatic primary sclerosing cholangitis (Parlak et al. 2007, 2015). How these kinds of endoscopic appearances of the papilla influences bile duct cannulation during ERCP, has not been studied.

1.6 ADENOMATOUS NEOPLASIA OF THE AMPULLARY REGION

1.6.1 Premalignant lesions in the ampullary region

Most ampullary adenocarcinomas originate from pre-neoplastic lesions, either intestinal adenomas or flat ductal lesions arising from different areas of the ampullary region (Esposito et al. 2001; Kaiser et al. 2002; Ruemmele et al. 2009; Stolte and Pscherer 2009). There are areas of residual adenoma in 30-90% of ampullary adenocarcinomas, indicating that there is an adenoma-carcinoma sequence involved in these neoplastic lesions (Kozuka et al. 1981; Fischer and Zhou 2004). The most commonly discovered premalignant lesions are adenomas of the intestinal type, which share traits with other intestinal adenomas in the large and small bowel. These are tubular, villous or tubulovillous adenomas. The natural history of ampullary adenomas have not been determined in detail, but there are apparent similarities to that of colorectal adenomas (Lieberman et al. 2012; Zauber et al. 2012) indicating a similar adenoma-carcinoma pattern (Baczako et al. 1985; Yamaguchi and

Enjoji 1991; Wittekind and Tannapfel 2001). The continuum from a premalignant lesion, which over time (years) develops into invasive carcinoma warrants that also these premalignant lesions have to be resected in a similar way like colorectal adenomas do (Heidecke et al. 2002; Chini and Draganov 2011),

Figure 7.

Neoplastic lesions are rare in the small intestine, but when present, they have a predilection to occur in the vicinity of the duodenal papilla (Wagner et al. 2008). As described above, the ampullary region is a complex anatomical and histological area where the intestinal mucosa meets pancreatobiliary epithelium, and neoplasia can originate from any of these locations. Ampullary adenocarcinoma accounts for 6% of all periampullary and pancreatic malignancies (Okano et al. 2014) and 0,5% of all gastrointestinal malignancies.

Depending on the origin and growth pattern of the tumors are ampullary adenocarcinomas, classically, subdivided into three categories depending on the origin of the lesion, (peri)ampullary, intra-ampullary or mixed (Cubilla and Fitzgerald 1980). The classical categories have in recent years, been remodeled to suit better the different premalignant lesions that originate from the various locations in the ampullary region. Adsay et al (2012), proposed a classification with four different categories instead, also including descriptions of the preinvasive lesions for each location, which can undergo malignant transformation, Figure 8. The classification proposed by Adsay et al. (2012) is adopted, with minor revision, in the latest version (4.0.0.0) of the College of American Pathologists (CAP) protocol to be used in the U.S., when examining resected ampullary lesions (Kakar et al. 2017).

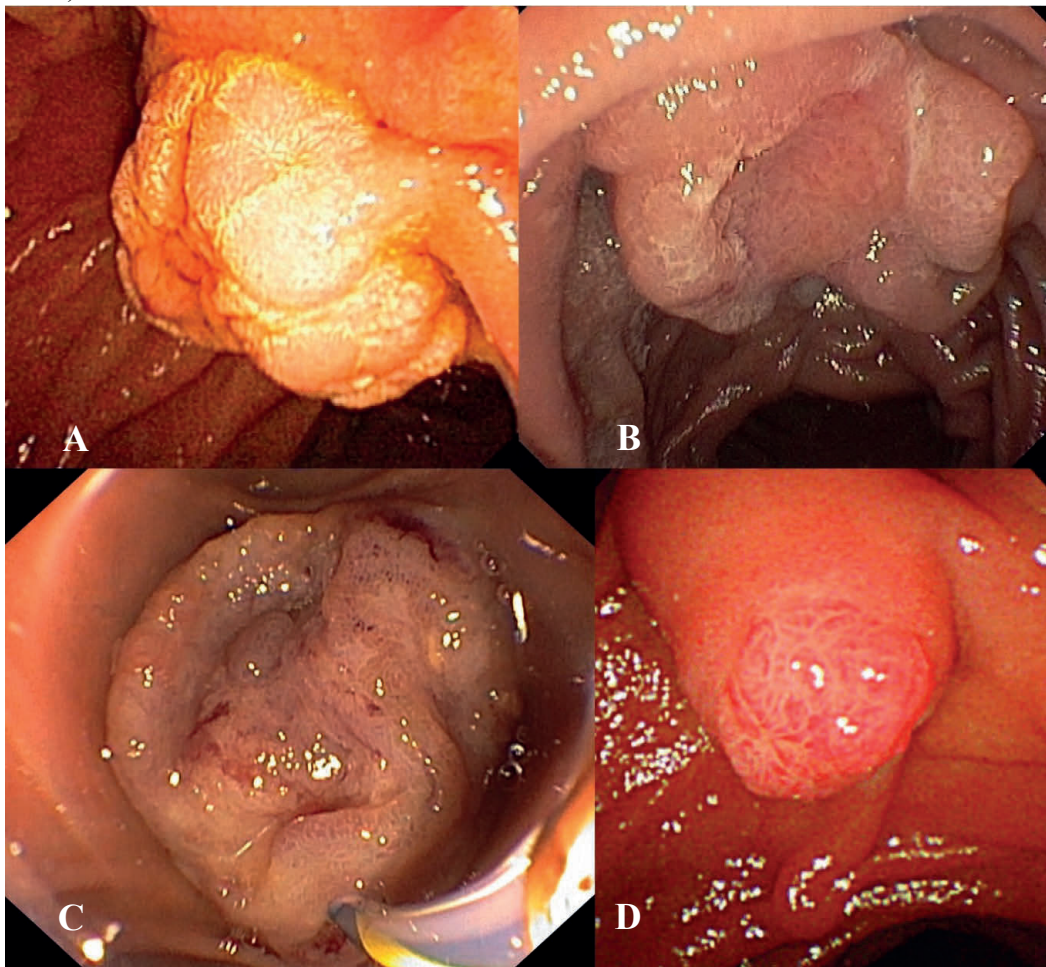


Figure 7. Examples of ampullary neoplasia at endoscopy. A and D Ampullary adenoma. B and C, Ampullary adenocarcinomas.

1.6.2 Classification of ampullary neoplastic lesions

1.6.2.1 Intra-ampullary papillary-tubular (IAPN) neoplasia or Intra-AMP

Intra-AMP tumors originate from mucosal components within the ampulla and can sometimes extend out through the patulous ductal opening into the duodenal lumen with friable tissue material. The lesions share many similarities with intraductal papillary mucinous neoplasm (IPMN) or intraductal tubulopapillary neoplasms (ITPN) of the pancreatic ducts and also intraductal papillary neoplasm (IPN) of the biliary tree (Ohike et al. 2010).

IAPN lesions can undergo malignant transformation in a similar way to IPMNs and progress with invasive growth (Adsay et al. 2016). The predominant cell types of the preinvasive lesions are either of intestinal, gastric, or pancreatobiliary differentiation (Pant et al. 2018). At endoscopic examinations, they might be hard to discern as they, in their non-invasive state, seldom grow out on the duodenal surface, and at least 75% of the lesions should be inside the ampulla to define them as an IAPN. Invasive malignancies that develop from IAPNs can either be of the intestinal or the pancreatobiliary type. IAPN lesions can correspond to the intramural protruding lesions described by Yamaguchi et al. (1990).

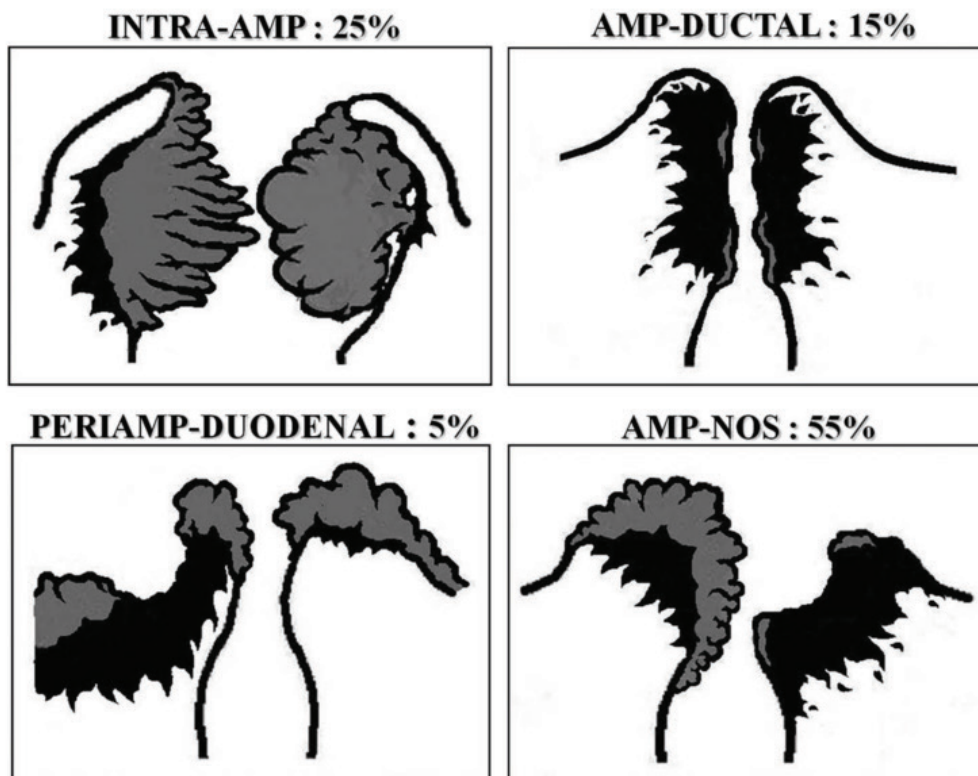


Figure 8. The four distinct types of ampullary region carcinomas. Discernable through the distribution of the preinvasive (grey areas) and invasive (black areas) components.

From: Adsay, V., Ohike, N., Tajiri, T., et al., (2012) Ampullary Region Carcinomas: Definition and Site Specific Classification With Delineation of Four Clinicopathologically and Prognostically Distinct Subsets in an Analysis of 249 Cases, the American Journal of Surgical Pathology, 36, 11, 1592-1608. <https://dx.doi.org/10.1097/pas.0b013e31826399d8>

Reprinted with permission from Wolters Kluwer Health Inc.

1.6.2.2 Ampullary-ductal lesions or AMP-ductal

Ampullary-ductal lesions are plaque-like thickenings of the wall inside the ampulla and might be mistaken for fibrosis but are scirrhous constrictive carcinomas. They have no distinct premalignant precursor lesion. Ampullary-ductal lesions are also difficult to notice

from the duodenal surface. They might just be a slightly elevated or small, retracting ulcerating at the papilla from the duodenal side. The tumors are pancreatobiliary type lesions and can be classified as T3b (or T4 in TNM ver.7) even though they are small due to the anatomical proximity to the peripancreatic soft tissues in the posterior wall of the ampulla (Adsay et al. 2012a). Ampullary-ductal lesions share characteristics with other flat lesions in the pancreatobiliary ducts such as PanIN and BilIN (Krishnamurthy and Sriganeshan 2019).

1.6.2.3 (Peri)Ampullary-duodenal lesions

Exophytic, classical, intestinal tumors, arising from the duodenal surface of the ampulla. They are in many ways like non-ampullary small intestinal adenomas and colonic adenomas. They are frequent in patients with familial adenomatous polyposis (FAP), and have, by definition, at least low-grade dysplasia (Dhall et al. 2015). Areas of ulceration are typically areas of invasiveness. They are of intestinal differentiation and endoscopically they correspond to the exposed protruding or ulcerating tumors described by Yamaguchi et al. (1990).

1.6.2.4 Ampullary NOS (not otherwise specified) lesions

Tumors found at the papilla of Vater, in-between the ampulla and the ampullary-duodenal areas in an unspecified manner. Ampullary-NOS is the most common location for ampullary neoplasia, according to Adsay et al. (2012a). The tumors can have an intestinal, pancreatobiliary, or a mixed type of histopathological differentiation and is endoscopically probably equivalent to the exposed protruding variant (Yamaguchi et al.1990).

1.6.3 Histopathological staging of ampullary adenocarcinoma

The AJCC/UICC TNM classification has recently been updated from version 7 (Edge et al. 2009) to version 8 (Amin et al. 2017) with several changes in the classification for ampullary cancer, Table 1. The seventh version of the classification was not so elaborate for ampullary cancer and had several weaknesses. One of the weaknesses was concerning the unprecise term “duodenal wall” used for T2 tumors. Tumors originating on the duodenal surface of the papilla, they should probably have been staged according to the TNM for small intestinal tumors, not as ampullary tumors (Adsay et al. 2012b). Invasive tumors that originate in the ampullary-duodenal area are, in the seventh TNM version, viewed as T2 regardless of how small they are as they invade the “duodenal wall“ per definition (You et al. 2014).

Whereas, an intra-ampullary tumor that grows from the inside out thru the duodenal wall also will be staged as a T2, but probably is a much larger tumor and a more aggressive tumor. Perhaps will the inclusion of several new T-stages, in the eight version, that resemble the TNM definitions for small intestinal tumors help in staging these tumors more correctly.

Furthermore, at histopathological examination is staging of ampullary malignancies not easy, regardless of the weaknesses of the tumor classification, due to the intricate anatomy of the ampullary region, with several epithelial surfaces and the variation in the underlying tissues next to the epithelial surfaces. Another example of a problem in the seventh version of the TNM classification is that in many patients are the posterior wall of the ampulla not covered by pancreatic parenchyma, making even small tumors, invading out through the ductal wall, to be classified as T4 , because they invade the peripancreatic soft tissues. This classifications does not mirror the prognosis of the lesion, and at the same time they could never be classified as a T3 tumors as there is no pancreas to invade in that direction (Adsay et al. 2012b).

The discussion regarding the staging system for ampullary adenocarcinomas continues as both Kim et al. (2018) and Imamura et al. (2019) have demonstrated weaknesses of the

eighth TNM version, with, in some instances, no difference of overall survival between neighboring T-stages.

In the seventh TNM version, there was a reversed survival between T1N0 and T2N0 cancers among the 4,328 patients with ampullary cancer in the AJCC database (Adsay et al. 2012b). Where 5-year survival of T1N0 was 39.7% and for T2N0 43.7%.

The problems with the TNM classification of ampullary tumors must be considered when comparing recent studies with older ones. In the US is the eighth edition mandatory from January 1, 2018 while other countries still use the seventh version.

Table 1. The development of the TNM-classification from version 7 to version 8.

T-category	Ampulla of Vater tumors T-criteria version 7	Small intestine /duodenal tumors T-criteria version 7	Ampulla of Vater tumors T-criteria version 8
T0	No evidence of primary tumor	No evidence of primary tumor	No evidence of primary tumor
Tis	Carcinoma in situ	Carcinoma in situ	Carcinoma in situ
T1	Tumor limited to ampulla of Vater or Sphincter of Oddi		
T1a		Tumor invades lamina propria	Tumor limited to ampulla of Vater or Sphincter of Oddi
T1b		Tumor invades the submucosa	Tumor invades beyond the sphincter of Oddi and /or into the duodenal submucosa
T2	Invades duodenal wall	Invades muscularis propria	Invades muscularis propria of duodenum
T3	Tumor invades pancreas	Tumor invades through the muscularis propria into the subserosa, or extends into nonperitonealized perimuscular tissue without serosal penetration	
T3a			Tumor directly invades the pancreas (up to 0.5 cm) or
T3b			Tumor extends more than 0.5 cm into the pancreas, or extends into peripancreatic or periduodenal tissue or duodenal serosa without involvement of the celiac axis or superior mesenteric artery
T4	Tumor invades peripancreatic soft tissues, or other adjacent organs or structures	Tumor perforates the visceral peritoneum or directly invades other organs or structures (for duodenum, invasion of the pancreas or bile duct)	Tumor involves the celiac axis, superior mesenteric artery, and/or common hepatic artery, irrespective of size

1.6.4 Prognostic factors in ampullary adenocarcinoma

Besides the AJCC/UICC stages of the tumors there are there several other important prognostic factor that influence the overall prognosis for the patients with ampullary adenocarcinoma.

1.6.4.1 Pancreatobiliary or Intestinal histopathological subtype

Tumors arising from in the ampullary region show differences in their histopathological phenotype and are classified as either of intestinal or pancreatobiliary subtype (Kimura et al. 1994). There is evidence that the differentiation of ampullary adenocarcinomas as either the intestinal or the pancreatobiliary type has an impact on prognosis, with the pancreatobiliary having a more dismal prognosis (Chang et al. 2013; Westgaard et al. 2013; Williams et al. 2016). A recent meta-analysis also confirmed that there is an inferior overall survival and disease-free survival if the lesion is of the pancreatobiliary type (Zhou et al. 2017). Additionally, there are data indicating that the different histopathological subtypes

have different sensitivity to oncologic therapy (Schiergens et al. 2015; Ramaswamy et al. 2019).

Although there is clearly a worse prognosis for pancreatobiliary type of tumors, for the pathologist it is sometimes difficult to distinguish between these two subtypes. In several reports, there are also a mixed or “other” subtype included when classifying ampullary tumors into the histopathological subtypes. There is also a considerable variation in the reported frequency of the different subtypes, sometimes with the pancreatobiliary being the most frequent and sometimes the intestinal (Perysinakis et al. 2014, Zhou et al. 2017). Furthermore, in a report by Reid et al. (2016) was the interobserver agreement only fair ($\kappa=0.39$) between different pathologists when determining the histological subtype. They also noted that many of the tumors had a mixed histological type that could be further subdivided into mixed-predominantly intestinal and mixed-predominantly pancreatobiliary, making the prognostic value difficult to interpret and also that different parts of the same tumor could display these different patterns.

All these issues have made immunohistochemical analysis even more interesting, to be able to separate the tumors into the different subtypes. The use of different palettes of tissue markers that can help in discerning the histopathological subtype (Ang et al. 2014) have been suggested. How to interpret these and to decide on which is the best tissue markers to use is still under debate (Kim et al. 2019). Perhaps even using mutational analysis to separate the tumors into the different histopathological subtypes (Chang et al 2013; Perkins et al. 2019; Harthimmer et al. 2019).

Considering these various aspects, it is hard to draw any firm conclusions on the importance of the histopathological subtype of ampullary adenocarcinoma and there are reports that state that there is no clear difference in prognosis (Lothe et al. 2019). Rather, different clinical scoring systems taking factors such as co-morbidity, age, TNM stage, tumor size and tumor differentiation into account also has been shown to have a prognostic value (Colussi et al. 2015; Li et al. 2019).

1.6.4.2 Lymph nodal metastasis

The presence of nodal metastasis after curative resection of ampullary adenocarcinoma portends a bad prognosis. In the eighth versions of TNM classification, is the nodal status divided into three levels instead of two, to better reflect the worsening prognosis of a more extensive lymph node involvement (Pomianowska et al. 2013; Kim et al. 2018). Not only the number of affected nodes is of importance but also the number of investigated nodes, the Lymph Node Ratio (LNR) (Roland et al. 2012; Doepker et al. 2016). The risk for lymph node metastasis is dependent on pathological differentiation of the tumor, T-stage, tumor size and histopathological subtype (Winter et al. 2010; Adsay et al. 2012a; Askew and Connor 2013; Okano et al. 2015; Moekotte et al. 2019). Due to the difficulties mentioned above, on T-staging in the ampullary region is the lymph node involvement already at T1 tumors, according to several reports, between 30-50% (Hornick et al. 2011; You et al. 2014; Amini et al. 2015).

1.6.4.3 Mutational status of KRAS in ampullary neoplasia

Mutations in the different RAS oncogenes, HRAS, KRAS, and NRAS are frequent in several malignancies, where KRAS is the most often mutated among them. RAS-genes influence a GDP-regulated system controlling the mitotic activity in cells (Jayaramayya et al. 2018; Waters and Der 2018).

In pancreatic cancer (PDAC), nearly all tumors express mutated KRAS, and it is an initiating mutation in the development of PDAC (Schönleben et al. 2009). In ampullary neoplasia is the situation more complicated. The frequency of mutated KRAS differs in but the overall frequency of mutated KRAS in ampullary carcinoma is between 30%-67% (Chung et al. 1996; Schultz et al. 2012; Valsangkar et al. 2015; Harthimmer et al. 2019),

and on par with the frequency of mutated KRAS in colorectal cancer (Arrington et al. 2012).

Over the last decade has an array of different immunohistochemical and molecular markers been assessed to characterize ampullary adenocarcinoma more closely. Among these is mutated KRAS a crucial genetic marker that is often associated with poor prognosis (Schultz et al. 2012; Mafficini et al. 2018) and also seems to occur at an early stage of tumor development as the frequency of mutated KRAS is independent of T-stage (Matsubayashi et al. 1999) and are even frequent, 54%, in adenomas adjacent to invasive carcinomas (Howe et al, 1997). The latter finding might say that evaluating mutational status of KRAS could be an early sign of poor prognosis and could serve as a useful tissue marker during the preinterventional investigations.

1.7 ENDOSCOPIC RETROGRADE CHOLANGIOPANCREATOGRAPHY

Endoscopic retrograde cholangiopancreatography or abbreviated ERCP, is an endoscopic interventional procedure in the biliary and pancreatic ductal system. ERCP is used to diagnose and treat many different diseases in the pancreatobiliary system.

Dr. William S. McCune was the first to perform what we now call ERCP. He was the first to cannulate the bile duct and with the use of a fiberoptic endoscope that had both frontal and side optics (McCune et al. 1968). A few years earlier, Dr Basil Hirschowitz (1961), was the first to visualize the duodenum through a fiberoptic endoscope as he presented his pioneering work with the first clinically useful flexible fiber-optic gastroscope. Later, Watson (1966), from the Glasgow Royal Infirmary, was the first to describe that he had visualized the papilla through an endoscope in five patients — confirming his findings by injecting secretin and witnessing the outflow of pancreatic juice and the movements of the sphincteric mechanism.

An explosive development of the fiberoptic duodenoscopes and ERCP techniques started and soon came the first larger patient series (Oi et al. 1969; Cotton 1972; Demling et al. 1972). Only a few years later, was the ERCP technique used for the first endoscopic interventional modality in the pancreatobiliary system, as the first endoscopic sphincterotomy and stone extraction was described simultaneously in Germany (Classen and Demling 1974) and Japan (Kawai et al. 1974).

Today, the ERCP technique has developed into a separate field of pancreatobiliary interventional endoscopy that in several respects, border to surgical interventions. The diagnostic part of ERCP has been replaced by more sophisticated, non-invasive imaging modalities such as magnetic resonance cholangiopancreatography (MRCP) and multidetector computed tomography (MDCT). During the ERCP procedure is it possible to diagnose and remove all kinds of ductal stones, drain obstructed ducts, perform intra-ductal investigations (Spyglass™), tumor resections, and ablations as well as extensive tissue sampling and more. Especially the single use cholangioscopy technique has revolutionized biliopancreatic diagnostics, opening up a new field of intra-ductal endoscopy (Arnelo et al. 2014; Tyberg et al. 2019).

1.7.1 Cannulation during ERCP

Since the beginning of ERCP, one of the significant difficulties to overcome has been the ability to manage transpapillary cannulation of the desired duct, most frequently the bile duct, safely and effectively (Cotton et al. 1972; Freeman and Guda 2005; Testoni et al. 2016; Hawes and Devière 2018; Berry et al. 2019). Bile duct cannulation can be a technical and time-consuming challenge that traumatize the papilla, a situation that is well known to increase the risk for complications (Testoni et al. 2011).

Somewhere between 5-20 % of biliary cannulations of a naïve papilla fail altogether, leaving the patient untreated and at increased risk for complications (Enochsson et al. 2010; Swan et al. 2011; Sheppard et al. 2015)

Several different chemical (Barrie et al. 2006; Fang et al. 2018), medical (Devereaux et al. 2002) and technical suggestions (Tse et al. 2012; Noel et al. 2013; Swahn et al. 2013; Huang et al. 2015) have been brought up, trying to facilitate biliary cannulation, and thereby decrease the risk for complications (Andriulli et al. 2007; Dumonceau et al. 2014).

1.7.2 Definitions of difficult cannulation

There are several studies and guidelines (Freeman et al. 1996; Dumonceau et al. 2014; Chandrasekhara et al. 2017) that emphasize that cannulation difficulties are among the leading risk factor for complications, and especially post- ERCP pancreatitis. Despite this fact, there has not been any standardized definition of difficult cannulation, until recently. Freeman et al (Freeman et al. 1996) suggested a grading system for cannulation difficulties based on the number of attempts made at cannulation. Easy cannulation defined as 1 to 5 attempts, moderate, 6 to 15 attempts, and difficult cannulation as more than 15 attempts. The proposed grading never received any broader recognition.

Table 2. Various definitions of difficult cannulation

	Definition of difficult cannulation (variables used)			Patients with difficult cannulation	
	Time (min)	Attempts	Times in PD	Study group (n)	Difficult cannulation (proc.)
Yoo et al. 2013	>10	>10		1394	7.4%
Mariani et al. 2016	>5		3	3940	31%
Swan et al. 2013	>10	>10	>4	464	15.7%
Zhou et al. 2006	>10		3	948	9.6%
Sugiyama et al. 2017	>15		>3	423	26%
Ismail et al. 2019	>5	>5	>1	821	37.9%
Watanabe et al. 2019		>5		589	41.8%

Testoni et al (Testoni et al. 2010) showed that ten attempts or more led to the highest odds ratio (OR 14.9, 95% CI 10.50-21.26) for PEP, among all the risk factors in their study. Zhou et al. concluded that five attempts also increased the risk for PEP significantly (Zhou et al. 2011). Several different definitions of difficult cannulation have been used over the years. Some of the more recently used can be seen in Table 2. Many of the definitions have been used in studies evaluating different cannulation techniques to be used after cannulation has become difficult.

The ERCP study group of the Scandinavian Association for Digestive Endoscopy (SADE), were the first to perform a more extensive multi-center study measuring bile duct cannulation and focusing on constructing a definition of difficult cannulation based on prospective data (Halttunen et al. 2014). Ten endoscopy units in the Nordic countries took part in the study. They evaluated bile duct cannulation on 907 patients with a naïve papilla, to determine a definition of difficult cannulation based on the factors: time, number of cannulation attempts, number of guidewire passages into PD and frequency of PEP. The definition of a cannulation attempt was, “the intentional, continuous contact with the papilla with a cannulation catheter or sphincterotome”. At the first intentional cannulation contact with the papilla, a stopwatch was started, and the time points when cannulation techniques changed and when bile duct cannulation was reached were recorded.

Halttunen et al. (2014) reported that the frequency of PEP after five attempts was 11.9% and when cannulation succeeded at the first attempt, the PEP frequency was only 0.6%. The longer the cannulation continued the higher the risk of PEP. If cannulation took less than 2 minutes, the PEP frequency was 1.6%, and it was over 15% if cannulation took between 6 to 10 minutes. The authors also set a cut-off time at 5 minutes that in their study corresponded to a PEP frequency of 2.6% if cannulation time was under 5 minutes to

11.8% if it was over 5 minutes. With two or more passages of the guidewire into the pancreatic duct, the frequency of PEP increased to over 13%. Therefore, the definition of difficult cannulation presented by the SADE group, using a PEP frequency of over 10% as the defining factor, is, after 5 minutes, after 5 attempts or at >1 passage of a guidewire into the pancreatic duct. The definition has since then been endorsed by the European Society of Gastrointestinal Endoscopy (ESGE) and is the one recommended to use when performing studies on cannulation difficulties (Dumonceau et al. 2014).

1.7.3 Acute post-ERCP pancreatitis (PEP)

Acute post-ERCP pancreatitis (PEP) is the most frequent post-interventional complication after ERCP. The incidence of PEP differs in large meta-analyses from 3.5 % (Andriulli et al. 2007) to 9.7% (Kochar et al. 2015).

The definition and severity grading of PEP used in the vast majority of reports are the definition put together during a consensus meeting by Cotton et al. (1991), “Clinical pancreatitis; amylase at least three times normal more than 24 hours after the procedure that requires hospital admission or prolongation of planned admission”. The term, clinical pancreatitis, is mostly interpreted as new or worsening of abdominal pain (Freeman et al. 2001), not to confound the complication registration with patients who either have no pain or have pancreatitis already before the ERCP. Hyperamylasemia can also be measured in up to 46% of the patients after ERCP, and it has been argued that the amylase level should be set higher, to 5 times the normal value, because of the hyperamylasemia that can continue even after 24 h in asymptomatic patients and some patients with three times normal values at 24 h does not have pancreatitis-like abdominal pain (Testoni et al. 1999, 2000).

Most patients who develops PEP have a mild to moderately difficult pancreatitis that subsides with supportive measures in a few days. Kochar et al found in their meta-analysis that the mortality after PEP was 0,7% when aggregating data from several randomized trials (Kochar et al. 2015).

The grading used in the consensus criteria (Cotton et al. 1991) to grade post-ERCP-pancreatitis' severity is not the same grading system as the most frequently used system for severity grading in other kinds of acute pancreatitis, the Atlanta criteria (Banks et al. 2013). The consensus criteria, used in ERCP studies, focus on the length of hospital stay, the Atlanta criteria, instead, are based on systemic or local complications to grade severity and predict overall outcome after pancreatitis. A recent study by Smeets et al (2019) evaluated 13384 patients after ERCP and graded severity of PEP according to both systems to determine their ability to predict mortality and PEP severity. They concluded that the Atlanta classification was superior in measuring PEP severity and predicting mortality, but the consensus criteria were better in diagnosing pancreatitis associated with ERCP.

Patients in Sweden, with ASA 1-2, treated because of common bile duct stones with ERCP have an all-cause mortality within 30 days of 0.2% to 0.7% after ERCP in a Swedish ERCP registry (Enochsson et al. 2010). Similar mortality numbers (0.33%, 95%CI 0.24-0.42%) was presented in a systematic review by Andriulli et al. (2007).

1.7.4 Other complications after ERCP

There are several other complications after ERCP, but none of them as frequent as PEP and not connected to cannulation difficulties in the same way. Post-interventional bleeding occurs in 0.9-1.3% of the patients (Andriulli et al. 2007; Enochsson et al. 2010) and infectious complications with either cholangitis or cholecystitis afflicts 1.4% (Andriulli et al. 2007). A serious but rare complication is perforation of the duodenum. The risk for perforation is highest during sphincterotomy or the dilatation of strictures. Duodenal perforation happens in 0,3-0,6% of the ERCPs (Kochar et al 2015; Enochsson et al. 2010). Berzin et al (2011) in their study on procedural sedation during ERCP, had remarkably high

(21%) frequency of sedation related adverse events. Desaturation was the most common complication.

1.7.5 Risk factors for PEP

Several different patient-related, endoscopist-related and procedure-related factors increase or decrease the risk of PEP, Table 3. Among the patient-related risk factors, recent systematic reviews conclude that female gender, previous acute pancreatitis, previous PEP as well as suspected sphincter Oddi dysfunction are to be considered definitive risk factors for PEP (Dumonceau et al. 2014; Ding et al. 2015; Chandrasekhara et al. 2017). There are also probable risk factors where the evidence is conflicting regarding what kind of influence they have on PEP frequency, such as younger age (Chen et al. 2014), non-dilated bile ducts (Nakeeb et al. 2016), absence of chronic pancreatitis (Freeman et al. 2001), normal serum bilirubin (Dumonceau et al. 2014).

Moreover, the influence of endoscopist experience and annual case volume on the risk of PEP is not entirely conclusive (Testoni et al. 2010). The success rate of the ERCP is dependent on experience, but experience seems not to affect complication rates (Cotton et al. 2009).

Table 3. Risk factors for post-ERCP pancreatitis

Definitive Patient-related risk factors	Odds Ratios (95% CI)		
	Chen et al 2014	Ding et al 2015	Dumonceau et al 2014
Suspected SOD	2.69 (2.14-3.37)	2.04 (1.78-2.33)	1.91 (1.37–2.65)
Female Gender	1.40 (1.24-1.59)	1.46 (1.30-1.64)	3.5 (1.1–10.6)
Previous Pancreatitis	1.66 (1.38-2.00)	2.90 (1.87-4.48)	2.46 (1.93–3.12)
Previous PEP	3.65 (2.76-4.82)	2.03 (1.31-3.14)	8.7 (3.2–23.86)
Suspected Patient-related risk factors			
Younger Age (<60)	2.14 (1.41-3.25)	1.22 (0.98-1.52)	
Absence of chronic pancreatitis			1.87 (1.00 – 3.48)
Normal serum bilirubin			1.89 (1.22 – 2.93)
Definitive Procedure-related risk factors			
Difficult cannulation (various definition)		3.49 (1.36-8.93)	1.76 (1.13 – 2.74)
Pancreatic guidewire passages >1			2.77 (1.79 – 4.30)
Pancreatic injection		1.62 (1.31-1.99)	2.2 (1.60 – 3.01)
Suspected Procedure-related risk factors			
Pre-cut sphincterotomy	2.11 (1.72-2.59)	2.30 (1.85-2.85)	2.3 (1.4 – 3.7)
Pancreatic sphincterotomy			3.07 (1.64 – 5.75)
Balloon dilatation of an intact papilla			4.51 (1.51 – 13.46)

There is a list of procedure-related risk factors as well, Table 3. The definite risk factors are, according to ESGE guidelines (Dumonceau et al. 2014) different aspects of difficulties during cannulation, such as long cannulation time (>10min or >5 min) (Halttunen et al. 2014), pancreatic guidewire passages >1 time and contrast-injection into the pancreatic duct. The probable technical risk factors are pre-cut sphincterotomy, pancreatic sphincterotomy and biliary balloon dilatation without prior sphincterotomy. Some reports state that cannulation using pre-cut technique is not a risk factor, perhaps even the opposite if done early in the cannulation process (Navaneethan et al. 2014; Sundaralingam et al. 2015; Takano et al. 2018)

The risk for PEP in a single patient, who has several risk factors for PEP is the sum of all the risk factors and can, therefore, become as high as 40% in extreme cases (Freeman et al. 2001).

There is also a long list of likely risk factors but there are conflicting results regarding those.

Several guidelines agree that difficult cannulation is a significant risk factor (Tenner et al. 2013; Dumonceau et al. 2014; Chandrasekhara et al. 2017).

1.7.6 Methods to reduce the risk for post-ERCP pancreatitis

1.7.6.1 NSAIDs during the procedure

During the last decade, several trials have investigated the effect of NSAIDs on the risk of developing PEP with sometimes conflicting results (Elmunzer et al. 2012; Lua et al. 2015; Leerhøy et al. 2016). But when combining data from several randomized controlled studies in meta-analyses the results clearly indicates that rectal administration of either indomethacin or diclofenac as a single dose at the time of ERCP can reduce the risk of developing PEP from 13% to 6.8% (Serrano et al. 2019) and the RR for developing PEP 0.52 (95% CI 0.43-0.64) (Yang et al. 2017; He et al. 2018). It is recommended to use NSAIDs to reduce the risk of PEP in several international guidelines (Tenner et al. 2013; Dumonceau et al. 2014; Chandrasekhara et al. 2017).

1.7.6.2 Guidewire cannulation technique

Transpapillary cannulation can be done without a guidewire, using a catheter and contrast injections to guide cannulation, or with a guidewire to lead the way during cannulation, Figure 9. A meta-analysis including 12 randomized trials with a total of 3450 patients, showed a decrease in PEP rate (RR 0.51; 95% CI, 0.32-0.82) and a higher cannulation success rate (RR 1.07; 95% CI, 1.00-1.15) (Tse et al. 2012). There are also indications that if the endoscopist controls the guidewire themselves, instead of the assistant, is the risk for inadvertent guidewire passage into the pancreatic duct diminished (Buxbaum et al. 2016). Although guidewire led cannulation now dominates among cannulation techniques (Adler 2018) it is an ongoing discussion if guidewire passages into the pancreatic duct might even lead to a higher risk for PEP than what the injection of contrast medium into the pancreatic duct does (Mariani et al. 2012; Srinivasan and Freeman 2016).

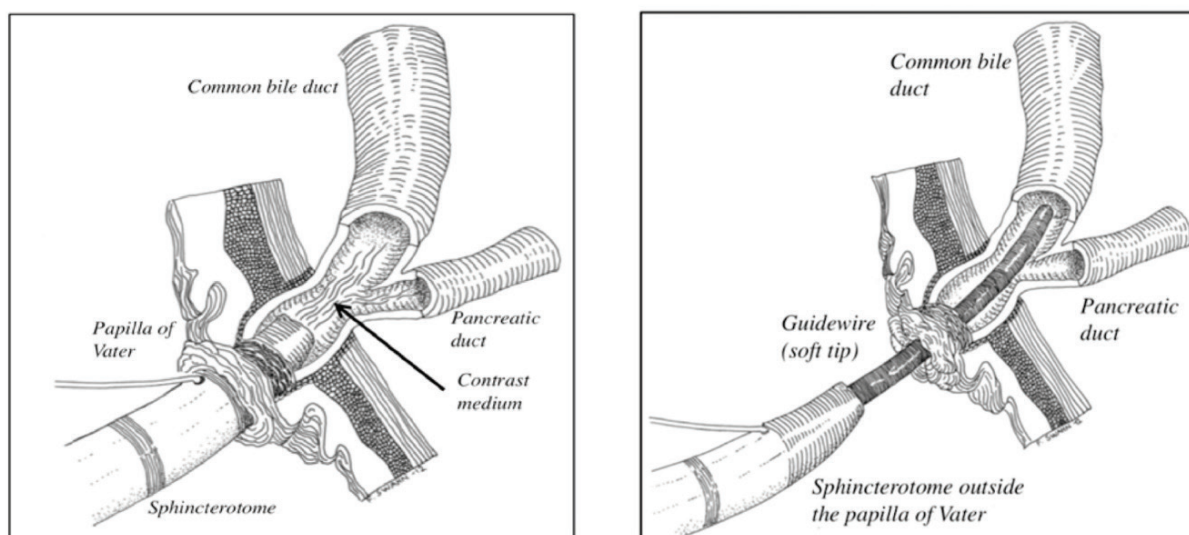


Figure 9. Contrast guided cannulation and guidewire guided cannulation.

From: Löhr, J., Aabakken, L., Arnelo, U., et al. (2012). How to cannulate? A survey of the Scandinavian Association for Digestive Endoscopy (SADE) in 141 endoscopists. *Scandinavian journal of gastroenterology* 47(7), 861-9. <https://dx.doi.org/10.3109/00365521.2012.672588>

Reprinted by permission of Taylor & Francis

Artist, Dr Fredrik Swahn

1.7.6.3 Prophylactic pancreatic duct stenting

Several meta-analyses have shown a clear reduction in PEP rate with prophylactic pancreatic stenting (OR, 0.22 to 0.39), particularly when faced with a patient at an elevated risk for PEP (Mazaki et al. 2010; Sugimoto et al. 2019). Prophylactic pancreatic duct stenting is recommended in cannulation situations when the guidewire has been inside the pancreatic duct. The diameter of the stent should be 5 Fr and not 3 Fr (Afghani et al. 2014) and be left in place after the procedure for at 7 to 10 days (Cha et al. 2013). If the endoscopist chooses to use pancreatic stents without internal flanges, the recommendation is to perform an X-ray within two weeks to confirm the dislodgement of the stent and diminish the risk for stent induced complications (Bakman et al. 2009). However, there are indications that the risk for complications is not increased with a slightly longer interval than two weeks before the removal of retained stents (Dultz et al. 2018). In a Japanese randomized controlled study, where they used 5 Fr, 3 cm straight stents with no internal flanges, they noted that 96% of the stents had dislodged in a mean time of 2 days and also that there was a 3.2 % PEP frequency in the stent group compared to 13.6% in the non-stent group (Sofuni et al. 2007).

1.7.6.4 Rendez-vous cannulation

In order to facilitate bile duct cannulation, the assistance of a guidewire, placed in an antegrade direction out through the papilla into the duodenum, has proven to be a useful technique (Tse et al. 2012; Noel et al. 2013; Swahn et al. 2013a; Huang et al. 2015). The guidewire can be placed either during a concomitant laparoscopic cholecystectomy (Deslandres et al. 1993; Noel et al. 2013), percutaneously (Dowsett et al. 1989) or using EUS to puncture the bile duct (Iwashita et al. 2011; Bill et al. 2016) After that catching the guidewire with a snare, pulling it out of the endoscope and threading on the sphincterotome for an unproblematic cannulation.

1.7.6.5 Other prophylactic measures against PEP

There is a lengthy list of different substances and treatment alternatives that have been used trying to prevent PEP in some cases with interesting results and in others more uncertain findings. Protease inhibitors might be useful (nafamostat) (Ohuchida et al. 2015), topical epinephrine spray in combination with Indometacin showed no difference (Kamal et al. 2019), heparin injections given in 3 doses at the time for ERCP and the day after showed a biochemical effect on amylase levels (Ung et al. 2011), somatostatin injection can be useful for high-risk patients (Wang et al. 2018), glyceryl trinitrate sublingually or sprayed topically in the duodenum can have some effect on PEP frequency (Ding et al. 2013), and aggressive hydration during and after the ERCP might be the most exciting suggestion and has promise to be a useful method, at least in high-risk patients (Radadiya et al. 2019).

1.8 EVALUATION OF SUSPECTED NEOPLASTIC LESIONS IN THE PAPILLA

The preinterventional staging of a suspected ampullary neoplastic lesion is not easy (Askew and Connor 2013). However, with the possibility of an endoscopic resection, avoiding major surgery, has the importance of a correct staging of small, non-invasive lesions been emphasized (Zbar et al. 2012; Alvarez-Sánchez and Napoleon 2016). There are several diagnostic modalities to choose from, all with their strengths and weaknesses.

Transabdominal ultrasound is in many patients with jaundice the first examination, but it is of limited use when it comes to investigating ampullary lesions, with an accuracy of as low as 12% (Chen et al. 2009; Jones and Necas 2018). The vital distinction to determine in the preinterventional investigations are if the lesion is benign or malignant. As malignant lesions needs to be surgically resected to be cured.

1.8.1 Cross-sectional imaging of ampullary lesions

Advanced multidetector computed tomography (MDCT) is in most patients the first investigation for biliary tract obstruction not caused by gallstone disease. MDCT is used in many different investigational schemes for suspected abdominal disease, and sometimes even used as a screening tool in search for a diagnosis in unclear cases. Because of the wide indications for MDCT, has the investigation, compared with other investigational methods used in this context, the advantage to be able to discover signs of ampullary disease in asymptomatic patients or as an incidental finding (Alessandrino et al. 2015). Visualizing a non-invasive lesion in the ampullary region is difficult, and the differentiation between benign and malignant lesions is even more difficult in the ampullary region than at other levels of the biliary tree (Nikolaidis et al. 2014).

Magnetic resonance imaging (MRI) is complementary to MDCT regarding the search for metastasis and distant lymph node metastasis, but has a better accuracy in discerning if a periampullary lesion is malignant or benign compared with MDCT, due to the use of the MR cholangiopancreatography (MRCP) technique (Andersson et al. 2004). It is unclear if this is true for purely ampullary lesions as the ampullary region is more challenging to evaluate with MRCP as it often holds lesser amounts of fluid because of the natural narrowing of the lumina (Geier et al. 2000). Both MRI and MDCT image quality and diagnostic value is highly dependent on the protocol used during the examination and the measures taken to distend the duodenal lumen to delineate the papilla more clearly (Alessandrino et al. 2015).

1.8.2 Endoscopic ultrasonography in ampullary neoplasia

Endoscopic ultrasonography (EUS) is used, to assess locoregional status in ampullary disease (Peng et al. 2019). Although there are some conflicting results, a meta-analysis concludes that EUS has a moderate sensitivity for T- and N-stage and concluded that EUS is inadequate as a single investigation to select patients for surgery or endoscopic resection (Triksudanathan et al. 2014), but in many instances useful in the local staging. Regarding the evaluation of the intraductal extension of an adenomatous neoplastic lesion, has ERCP and EUS similar sensitivity (Ridtitid et al. 2015). ERCP having the downside of being invasive, and EUS the advantage to determine the T-stage of the lesions makes the choice of performing EUS on many of these patients straight forward (Gaspar and Shami 2015). One disadvantage being that both EUS and ERCP is dependent on skilled endoscopists to give the best evaluations.

Larger size of the lesion (>20 mm) is often a sign of malignancy, and lesions smaller than 6,5 mm are rarely malignant (Patel et al. 2016). EUS is definitively better than MDCT in determining the grade of local invasiveness and local nodal status and MDCT is not particularly useful in deciding local tumor status (Artifon et al. 2015).

The best modality, for local staging, and to decide between invasive or non-invasive tumor, is intra-ductal ultrasound (IDUS) (Ito et al. 2007; Okano et al. 2013). The negative aspect of IDUS is that the technique is invasive and dependent on skilled operators in this unusual patient group (Menzel et al. 1999a).

1.8.3 Cytology of ampullary lesions

The use of brush cytology is the basis for tissue diagnosis of bile duct strictures and is the most used tissue sampling method in the investigation of bile duct strictures. Brush cytology is done because of the ease of taking the samples during ERCP and the low costs. The sensitivity is in most series low (6-64%) while the specificity is close to 100% for diagnosing malignancy in bile duct strictures (Hacihanoglu et al. 2018).

To improve the sensitivity on brush cytology different methods have been tried, and the one that is used in routine clinical praxis is fluorescence in situ hybridization (FISH) analysis, that in unclear cases can increase the diagnostic yield (Kushnir et al. 2019).

Studies concerning the utility of brush cytology has primarily focused on biliary and pancreatic malignancies and not on ampullary adenocarcinomas and especially not adenomas in the ampulla, where only small case reports exist (Mantoo et al. 2017). The tissue diagnosis of ampullary lesions is to a considerable extent based on the acquisition of forceps biopsies not on brush cytology (Jailwala et al. 2000). Furthermore, is the differentiation between HGD and adenocarcinoma on brush cytology almost impossible.

1.8.4 Endoscopic biopsies

Histopathological evaluation of endoscopic biopsies of ampullary neoplastic lesions is not easy (Elek et al. 2003). The tissue samples are small and only represent a tiny fraction of a suspected lesion, and several factors (e.g. stents, sphincterotomy, inflammation) can influence the diagnostic yield making the assessment of the tissue sample even more challenging. It has been known that endoscopic biopsies of ampullary lesions have a low sensitivity to correctly diagnose malignancy (Yamaguchi et al. 1990). Furthermore, the inter-and intraobserver agreement, when evaluating endoscopic biopsies, is moderately good between different assessors to diagnose reactive atypia from lesions with low-grade dysplasia (Allard et al. 2018).

There is a recommendation to take at least six biopsies (Espinel 2015) to get a higher diagnostic yield. Should biopsies be taken before or after sphincterotomy? The answer is not clear, and it is probably best to take biopsies early during the endoscopic examination not to get reactive changes (Bourgeois et al. 1984, Menzel et al 1999b). But at the same time can increase diagnostic yield in cases of intra-ampullary lesions (Elek et al 2003). There has been a concern that taking biopsies from the papilla could increase the risk for pancreatitis after the biopsies. In a recent matched-pairs controlled study there was a non-significant difference in complication frequency between ordinary ERCP and ERCP with biopsies. It is difficult to draw any clear conclusions from the study as it is probably underpowered with only 54 patients in each arm (Dacha et al. 2017).

DeOliveira et al. (2006) as well as Lee et al. (2014a) noted that the endoscopic appearance and forceps biopsies have similar accuracy at determining if a lesion is benign or malignant, and that both aspects are important when evaluating ampullary neoplastic lesions.

1.9 TREATING NEOPLASTIC LESIONS IN THE PAPILLA OF VATER

To resect and cure sporadic neoplastic lesion in the papilla of Vater there are three different treatment options to choose from, pancreatoduodenectomy, transduodenal ampullectomy or endoscopic papillectomy. A fourth possibility is the pancreas-preserving duodenectomy, a surgical operation usually reserved for patients with hereditary polyposis diseases (de Castro et al. 2008).

1.9.1 Pancreatoduodenectomy (PDE) (Whipple's operation)

1.9.1.1 History/Development

Pancreatoduodenectomy or Whipple's operation was presented for the first time in 1935 (Whipple et al. 1935), Figure 10. Only limited numbers of procedures were performed during the early years due to the extremely high in-hospital mortality of up to 25% (Mongé et al. 1964). However, during the last two decades has the improvements of surgical and perioperative treatments lowered both morbidity and mortality to between 2-4 % in expert centers. Because of these progresses have the indications for PDE expanded, now treating even patients with premalignant diseases (Cameron and He 2015; Hata et al. 2016; Tingstedt et al. 2018).

1.9.1.2 Indications

The indications for PDE are many and incorporates the curative treatment of all kinds of periampullary malignancies and nowadays even premalignant conditions not amendable for local resections. Even in rare instances have benign diseases such as chronic pancreatitis been treated with PDE. It is the golden standard against which all the other treatment options compare. In recent years has the indications for resection widened due to the introduction of neoadjuvant chemotherapy and vascular resections (Tingstedt et al. 2018; Roessel et al. 2018).

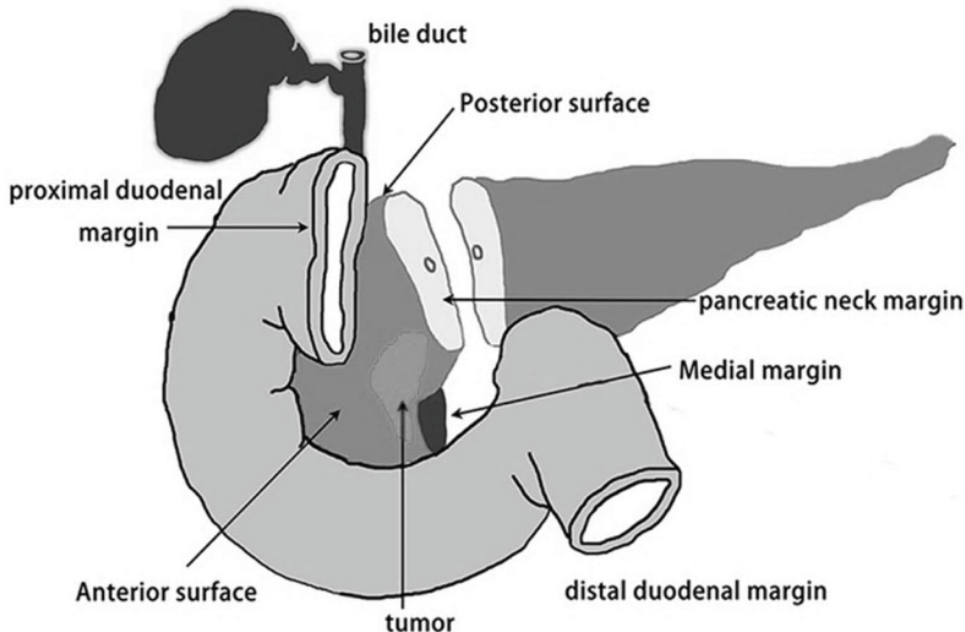


Figure 10. Pancreatoduodenectomy. Resection of the head of the pancreas, duodenum and the extrahepatic biliary tree.

From: Xu, J., et al. (2017). Identifying the neck margin status of ductal adenocarcinoma in the pancreatic head by multiphoton microscopy. *Scientific Reports* 7(1), 4586. <https://dx.doi.org/10.1038/s41598-017-04771-w>
Reprinted according to CC-BY-4.0

1.9.1.3 Postoperative complications

PDE is one of the most complex gastrointestinal surgical resections (Hata et al. 2016), with complication rates as high as 43-90% of the patients and with severe complications (Clavien grade 3 or higher) in at least 30% of the patients (Clavien and Strasberg 2009; Sánchez-Velázquez et al. 2019). PDE is a major surgical resection essential for the long-term survival of patients with periampullary malignancies. As many radical surgical resections there is also some long-term morbidity for the survivors (Chen et al. 2015).

1.9.2 Trans-duodenal ampullectomy (TA)

1.9.2.1 History

Halsted (1899) was the first to describe a local resection of an ampullary tumor when he resected a tumor in the pancreatic head as a two-stage operation. The patient survived for nine months before dying of metastatic disease. Before the development of flexible endoscopy, it was uncommon to diagnose ampullary neoplasia that was suitable for local resection (Rock and Fisher 1959; Barber et al. 1960).

1.9.2.2 Indication

The indication for transduodenal ampullectomy is somewhere between that of endoscopic papillectomy and pancreatoduodenectomy. TA offers a deeper resection than EP but without the lymph node resection that is done during PDE, with in addition, the need for

continued endoscopic surveillance, Figure 11 (Line A).

There are no universal indications accepted for TA, and Beger et al (1999) suggest that adenomas and superficial malignancies (pTis and pT1) that have a highly differentiated growth patterns are a suitable patient group (Schoenberg et al. 1998). In a more recent patient series, the same indications were used but restricted to patients unsuitable for endoscopic resection, or after failed endoscopic resection where no invasive lesion could be seen (Nappo et al. 2019). TA can still have a place in the treatment of ampullary neoplasia as a rescue after failed endoscopic resection (Schneider et al. 2016). Nevertheless, caution is called for in patients with malignancies > 1 cm due to the substantial risk of recurrent disease (Yoon et al. 2005). Yoon et al. also conclude that TA is not right for patients that are fit for PDE, at least not if the tumor is bigger than 1 cm.

In the retrospective patient-series by Ceppa et al. (2013) comparing outcome from a single-center between endoscopic resection and TA they concluded that endoscopic resection was equally effective to resect neoplasia but with fewer adverse events (Ceppa et al. 2013). Perhaps can technical developments with minimally invasive or robot-assisted surgical procedures change the indications for transduodenal ampullectomy in the future (Downs-Canner et al. 2015; Chapman et al. 2018; Hong et al. 2018; Lee et al. 2019b), but at present has TA very few indications.

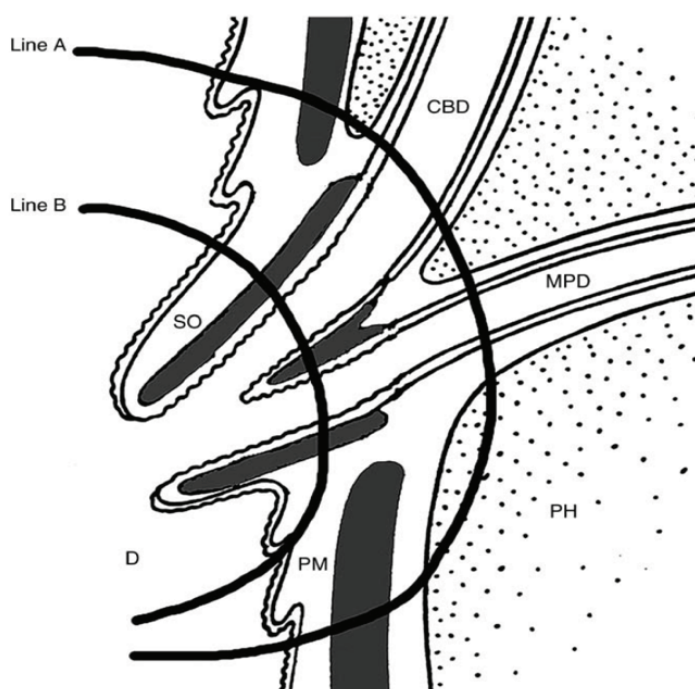


Figure 11. The depth of resection during transduodenal ampullectomy (Line A) and endoscopic papillectomy (Line B). CBD, Common bile duct. PH, pancreatic head. MPD, main pancreatic duct. PM, proper muscle layer. SO sphincter Oddi. D, Duodenal lumen.

Reprinted from Gastrointestinal Endoscopy Han, J., Kim, M. Endoscopic papillectomy for adenomas of the major duodenal papilla (with video) 63(2), 292-301, Copyright (2006). With permission from Elsevier Inc. <https://dx.doi.org/10.1016/j.gie.2005.07.022>

1.9.2.3 Results

In a meta-analysis including in total 382 patients, had 93% microscopically free resection margins, but had 18% of the patients had a recurrent disease. A neoplastic lesion that recurs after TA must be considered for further surgery with PDE. Complication frequency was 27% and mortality 0.26%, according to the meta-analysis (Papoulas et al. 2017).

1.9.3 Endoscopic papillectomy (EP)

1.9.3.1 Background

Endoscopic resection of intestinal adenomas has been a frequent phenomenon since the beginning of colonoscopy (Winawer et al. 1993). Before the development of flexible endoscopy were benign tumors in the papilla anecdotal findings (Barber et al. 1960). During the development of ERCP in the 1970s and '80s there were several documented findings of adenomas in the papilla of Vater (Bourgeois et al. 1984). The knowledge that local transduodenal resection of small neoplastic adenomatous lesions in the ampullary region could be a successful treatment, combined with the intense development in endoscopic technique, gave birth to endoscopic treatments of ampullary lesions in the 1980s (Suzuki et al. 1983; Lambert et al. 1988; Ponchon et al. 1989). However, it was not until the 1990's that the development of the technique of EP started to progress, after the landmark series by Binmoeller et al. (Binmoeller et al. 1993). Since then, EP has developed into being considered the first-line treatment of small ampullary adenomatous lesions (Irani et al. 2009; Laleman et al. 2013; Onkendi et al. 2014; Ridditid et al. 2014; Klein et al. 2017; Sahar et al. 2019).

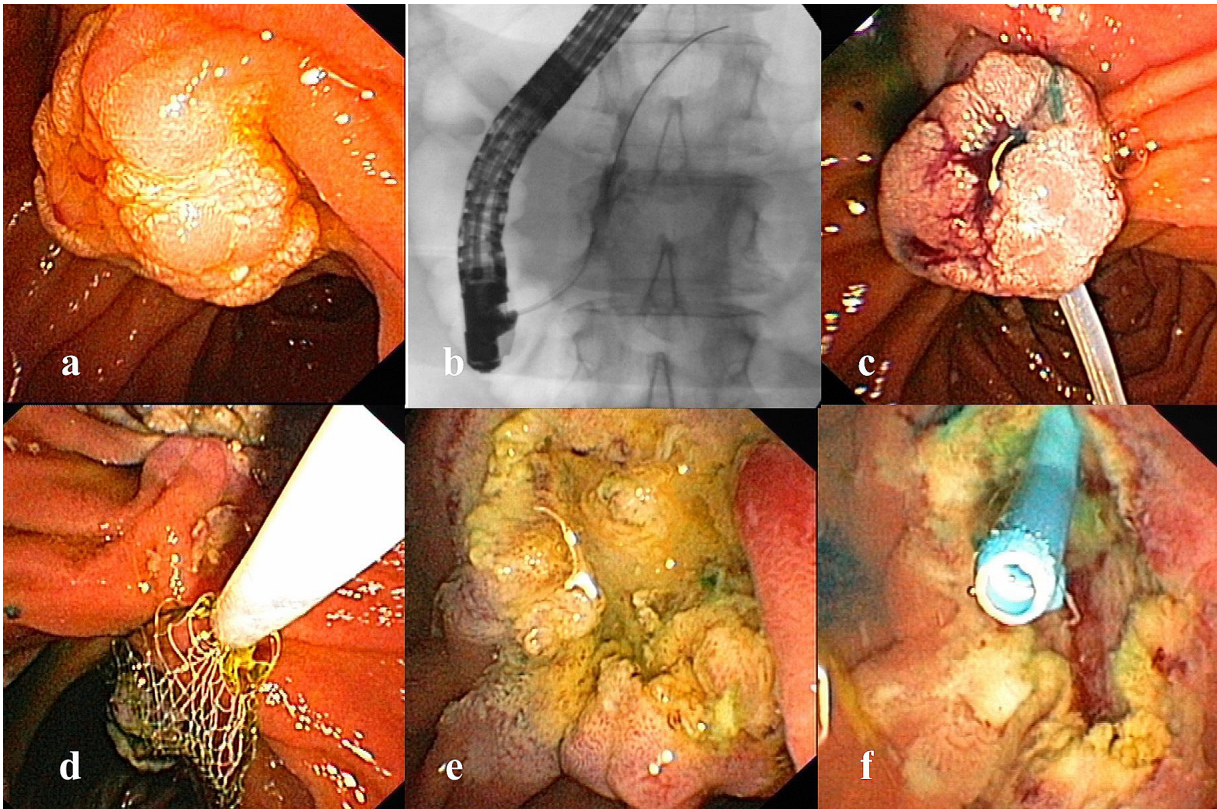


Figure 12. The technique of endoscopic papillectomy. a/identifying the lesion. b/cannulation of the pancreatic duct for methylene-blue injection. c/ Resection with snare and diathermy d/ Retrieval of the resected specimen. e/ Inspection of the resected area for signs of residual adenoma or signs of complications. f/ Prophylactic pancreatic stenting.

Images with permission from Dr Urban Arnelo.

1.9.3.2 Techniques in Endoscopic papillectomy

The technique of EP is in many respects similar to that of other endoscopic snare resections throughout the intestine, with some technical exceptions (Palma 2014; Kandler and Neuhaus 2018), Figure 12. Before resection starts, attempts are made to cannulate both ductal systems. Primarily, cannulation of the pancreatic duct is vital to inject methylene blue (Poincloux et al. 2014), to ease the post-resectional placement of a PEP prophylactic

pancreatic stent. The bile duct can be cannulated to evaluate if there are any signs of intra-ductal extension of the adenoma up in the ducts (Ridtitid et al. 2015). Resection is performed without submucosal injection if there is no lateral spreading of the tumor (Hyun et al. 2017). A polypectomy snare coupled with blended diathermy current is used to perform an en-bloc resection of the lesion.

After retrieval of the resected specimen and hemostasis, the pancreatic duct is prophylactically stented (Harewood et al. 2005). The bile duct is stented in case of poor outflow of bile after the resection at the discretion of the endoscopist. Small islands of residual adenoma can be ablated with argon-plasma coagulation, and at the same time, treating minor bleeding spots (Nam et al 2018).

The depth of resection at EP is, in theory, not as deep going as with TA, Figure 11. EP can resect lesions corresponding to line A while TA can get a bit deeper but with the need to reconstruct the continuity between the ductal and the intestinal mucosa with a sutured anastomosis. The deeper resection plays a part in the higher frequency of complications after TA (Nam et al. 2018).

1.9.3.3 Indication for EP

There are no universal indications for EP in the literature. One obvious contra-indication for curative EP is definite signs of invasive tumor on imaging. The ASGE guidelines from 2015, states that ampullary lesions above four cm in size, endoscopic biopsies that show malignancy, an endoscopic appearance that indicates malignancy, or lesions with an intra-ductal extension above 1 cm it is not recommended to perform EP in routine management (Chathadi et al. 2015). The indication for EP proposed by the ASGE is almost the same as what Binmoeller et al. (1993) used in the first patient series regarding EP.

The boundary for EP has in several reports over the years been pushed further, and it has been shown that it is possible to even treat superficial malignant lesions with acceptable results (Woo et al. 2009; Yamamoto et al. 2019) or intraductal extension above 1 cm (Pérez-Cuadrado-Robles et al. 2018). Although these new indications must be considered experimental as the results are conflicting (Amini et al. 2015) and EP is not free from complications. More importantly, not withholding almost certain curative treatment with PDE in patients with small adenocarcinomas. Staging of ampullary lesions is complicated not only clinically but also at histopathological examination. EP has been used as a “total biopsy” (Ogawa et al. 2012) when the biopsies are not convincing for malignancy and the lesion seems to be resectable.

With no universal and precise, indication for EP, the results from the different patient series that exist are conflicting, Table 4.

Table 4. Endoscopic papillectomy, results from large patient series

	Patients		Cured		Complications		Recurrence		Need for surgery	
	n	n	Proc.	n	Proc	n	Proc	n	Proc	
Binmoeller et al. 1993	25	23	92%	5	20%	6	24%	3	12%	
Catalano et al. 2004	103	83	81%	10	10%	10	10%	16	16%	
Bohnacker et al. 2005	106	73	69%	16	15%	15	14%	19	18%	
Laleman et al. 2013	91	71	78%	23	25%	13	16%	14	15%	
Ridtitid et al. 2014	182	134	74%	34	19%	16	9%	NA		
Napoleon et al. 2014	93	84	90%	39	42%	5	5%	NA		
Onkendi et al. 2014	139	82	59%	38	27%	44	32%	9	6%	
Klein et al. 2018	125	122	98%	31	25%	3	2.4%	3	2.4%	
Li et al. 2019b	110	86	78%	46	42%	13	12%	11	12%	
Sahar et al. 2019	128	106	83%	23	18%	8	6%	11	8.5%	
Total	1204	950	79%	286	22%	133	12%	102	11%	

1.9.3.4 Results of the endoscopic resection

With no universal and precise, indication for EP, are the results from different patient series a bit difficult to interpret as the patient selection for the intervention is not entirely clear. Furthermore, there is no consensus on what is to be considered a treatment success. The most frequently used definition is the one stated by Catalano et al. (2004); “complete excision of the lesion without regard to the number of sessions required and the absence of recurrence or recurrence during long-term follow-up that was easily treated endoscopically.” This relatively broad definition of treatment success has often been narrowed down to define recurrence as new neoplastic lesion occurring after a 3-6 months interval of being neoplasia free at endoscopic examination (Palma 2014).

With these implications in mind, the frequency of curative treatment after EP is between 46-92%, with recurrence during follow-up of between 0-33%. (Ardengh et al. 2015; Chathadi et al. 2015). Examples from the larger patient series is displayed in Table 4. Between 2.4% and 18% of the patients are after EP referred for surgical resection, due to either intraductal extension or to discovering malignant transformation.

1.9.3.5 Complications

EP has, compared to other endoscopic interventions, a high frequency of adverse events, with a scenario more of that of a surgical resection. The most common complications are bleeding (2-16%), and acute pancreatitis (5-15%). The overall frequency of adverse events is around 25%, but most of the complications are mild to moderate and with a mortality of <0.3% (Espinel 2015; Chathadi et al. 2015).

1.9.3.6 Future for EP

There have been several attempts at expanding the indications for EP to include patients with superficial malignancies (Alvarez-Sanchez et al. 2017) and intra-ductal extension. One treatment possibility could be to manage intra-ductal extension with radiofrequency (RF) ablation (Valente et al. 2015; Rustagi et al. 2017). A few patient series have been published with promising results. Although, the treatment with RF at present is to be considered an adjunct to palliative treatment, but might, with more conclusive data in the future be considered a part of curative treatment. One prospective study with 20 patients had, after one year of follow-up, 70% of the patients no signs of residual adenoma (Camus et al. 2018).

2 AIMS

- I. To design an endoscopic classification of the endoscopic appearance of the papilla of Vater and to determine the inter- and intra-observer agreement among experts as well as non-expert endoscopists when assessing the different papillae types of the classification.
- II. Determine if the endoscopic appearance of the papilla of Vater influences transpapillary bile duct cannulation during endoscopic retrograde cholangiopancreatography (ERCP)
- III. To evaluate if endoscopic papillectomy can be performed as a safe diagnostic and/or therapeutic procedure in biopsy-verified or suspected ampullary adenoma at the Karolinska University hospital and to evaluate if the expression of mutated KRAS in endoscopically resected tissue predicts long-term outcome.
- IV. To investigate what symptoms and/or findings that could be of value in the clinical decision-making and in choosing the most appropriate method to resect an ampullary neoplastic lesion when invasive malignancy is not evident.

3 METHODS

3.1 PAPER I

3.1.1 Study design

The study is design as an inter- and intra-observer agreement study to validate a suggested new classification of the endoscopic appearance of the papilla of Vater among endoscopists with different levels of experience.

3.1.2 Creation of the endoscopic classification

To create the classification of the endoscopic appearance of the papilla of Vater, photos of 140 different papillae were captured during ERCP examinations of naïve, previously untouched, papillae. The endoscopist took a minimum of 4 photos from 4 predefined positions. The first photo was captured, at full inflation, of the papilla and the surrounding duodenal wall from two different angles, to get a sense of the 3-dimensional arrangement. Followed by a close-up of the papilla and finally one frontal image with a standard cannulation catheter or sphincterotome positioned beside the papilla, for size reference. A group of expert endoscopists analyzed all the 140 sets of photographs of the different papillae and after discussion, agreed upon the proposed classification, of the endoscopic appearance of the papilla of Vater, Table 5 and Figure 13.

Table 5. The endoscopic classification of the papilla of Vater

Type 1	Regular Papilla, with no distinctive features, i.e., “classic appearance”.
Type 2	Small Papilla, often flat, with a diameter not bigger than 3 mm (approx. 9 Fr).
Type 3	Protruding or Pendulous Papilla. A papilla that is standing out protruding or bulging into the duodenal lumen or sometimes hanging down, pendulous with the orifice oriented caudally.
Type 4	Creased or Ridged Papilla, where the ductal mucosa seems to extend distally, rather out of the papillary orifice, either on a ridge or in a crease.

3.1.3 Inter- and intraobserver agreement study

An inter- and intra-observer agreement study was constructed to validate the proposed endoscopic classification. The aim was to determine if the different papilla types were possible for both expert and non-expert endoscopists to agree with the proposed classification also to evaluate if their opinion was consistent over time.

A web-based survey consisting of 50 different papillae, chosen from the original 140 papillae used when constructing the classification. The picture-set of the individual papillae consisted of up to 4 photographs from the same papilla. The invitation to take part in the survey was sent out via e-mail to all 18 endoscopists in the Nordic countries. The web format was chosen to ease the distribution of the survey and to standardize the image quality. Also, to have a convenient interface for the respondents and the possibility for reminders and data collection. The option, in the web-survey, to randomly change the order of the multiple-choice answers as well as the order of different photo sets of the papillae was used. The survey started with a brief introduction to get the respondent acquainted with the classification and the papilla types before the proper survey started. The invitation e-mail also included a separate document with background information on the classification together with image examples of the different papilla types.

Three months later, the same endoscopists were approached to respond once more to a similar survey, now containing a stratified random sample of 20 different papilla photo sets (5 each of the four different types of papillae) from the first survey, allowing for an assessment of intraobserver agreement.

3.1.4 Kappa statistics

Since the presentation of Cohen in 1960 (Cohen 1960), the use of kappa statistics has dominated in interobserver agreement studies. Kappa statistics consider the possibility of a chance agreement occurring between different observers and not just the rate of agreement per se. To calculate interobserver agreement, was the respondents' answers to the different sets of papilla photos compared to the type of papilla defined for each set of photos when the classification was created. The analysis was performed on all respondents as a group compared to the correct answers, as well as the expert group, the non-expert group, and the individual endoscopists' answers separately against the correct answers.

Likewise, was the intraobserver agreement calculated, comparing the individual endoscopists answers against their earlier answers on the same of papilla from the first survey.

Table 6. Interpretation of the kappa value

<i>Kappa Statistic</i>	<i>Strength of Agreement</i>
<0.00	Poor
0.00-0.20	Slight
0.21-0.40	Fair
0.41-0.60	Moderate
0.61-0.80	Substantial
0.81-1.00	Almost perfect

To control for the situation that the endoscopists made the same mistake at both surveys, the answers from the second survey were also compared with the original, correct, answer again. The 95% confidence interval (CI) was calculated to measure the level of precision of the respective kappa values. The kappa value was interpreted according to Landis et al. (Landis and Koch 1977), Table 6.

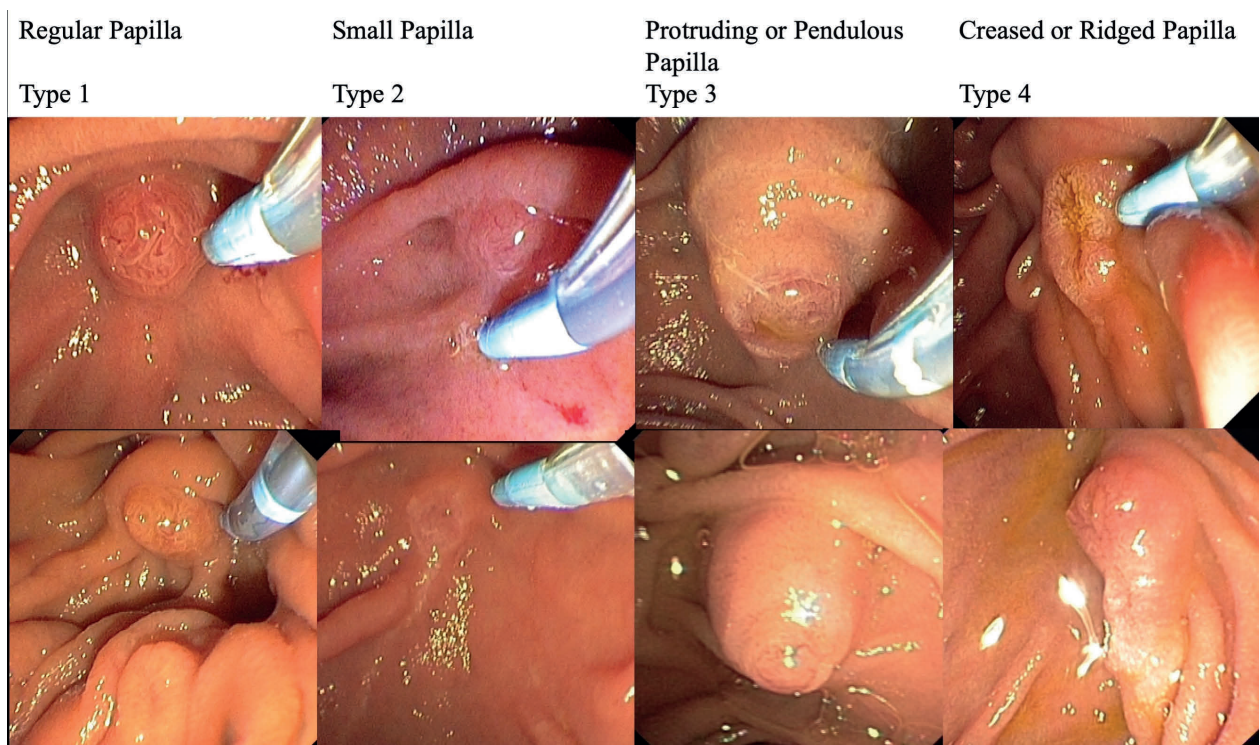

Figure 13. The endoscopic classification of the Papilla of Vater

3.2 PAPER II

3.2.1 Study design

This study is a non-randomized clinical trial to determine the influence the different papilla types, from the endoscopic classification, has on transpapillary bile duct cannulation during ERCP. The study group consisted of patients scheduled for ERCP with an untouched, naïve papilla, where bile duct cannulation was intended. The exposure was the difference in papilla type and the primary outcome measure was frequency of difficult cannulation.

3.2.2 Patients

Patients were prospectively included from nine participating centers in the Nordic countries. The patients had to be over 18 years old, scheduled for a clinically indicated ERCP, have an intact, naïve, major duodenal papilla, where the desired duct to cannulate was the common bile duct.

Exclusion criteria were a papilla hidden inside a large diverticulum, a bulky tumor distorting the ampullary region, or patients with surgically altered anatomy. Earlier ERCP with stenting, sphincterotomy or patients with retrograde guidewires placed, were also exclusion criteria.

3.2.3 Outcome measures

The primary outcome measure was differences in the frequency of difficult cannulation distributed between the different papilla types of the newly validated classification. The definition of difficult bile duct cannulation used in the study was the one proposed by Halttunen et al, the 5-5-2 definition (Halttunen et al. 2014).

Secondary outcome measures were cannulation failure and complications that occurred during the first 24 hours, or before discharge. Complications were defined according to the consensus criteria (Cotton et al. 1991), but the severity was not graded or complications that occurred after 24 hours.

Several patient and procedure-related variables were documented. In addition to documenting the papilla type and the outcome measures, were data regarding the indication for the ERCP, the endoscopists' experience, patient demographics, methods used during cannulation, and measures taken to avoid post ERCP pancreatitis (NSAIDs and/or protective pancreatic endoprosthesis insertion) recorded.

3.2.4 The experience of the endoscopists

Intuitively, there ought to be a distinct difference in frequency of difficult cannulation between expert endoscopists and beginners, "fellows". To investigate the influence of experience on difficult cannulation and to quantify the difference, the endoscopists performing the cannulation was divided into three levels of experience depending on their lifetime accumulated number of performed ERCPS.

Fellow endoscopists were defined as having performed less than 200 ERCPS (Jowell et al. 1996; Faulx et al. 2017) experts were defined as having done over 1000 ERCPS and intermediate endoscopists 200-1000 lifetime ERCPS. To evaluate the difficulties during bile duct cannulation facing inexperienced endoscopists, fellows, and at the same time not to jeopardize patient safety, a defined time limit for the fellow endoscopists' cannulation attempts had to be determined in the study protocol. The time to fulfill the definition of difficult cannulation was 5 minutes; therefore, this time limit was chosen for the fellow endoscopists to perform cannulation on their own before a more experienced colleague had to take over to continue the procedure.

3.2.5 Statistical analysis

Power calculations were not possible in this study since the distribution of the different papilla types was previously unknown, as was the overall frequency of difficult cannulation using the ESGE approved definition. The 5-5-2 definition constructed in the report by the SADE study group of ERCP (Halttunen et al. 2014) consisted of expert endoscopists and have not previously been tested in an everyday clinical setting with endoscopists of different levels of experience.

All statistical calculations were made with SPSS version 25. Chi-square test or Fisher exact test were used for categorical data as appropriate, as well as odds ratio calculation. Mann-Whitney U-test was used for non-normally distributed continuous data.

3.2.6 Ethical considerations

The study was approved by the Ethical review board at the Karolinska Institutet. Included patients received no extra treatment or risk compared to standard examination. They were recruited because they had a clinical indication for ERCP. No extra follow-up was made besides controlling the medical reports for signs of complication.

3.3 PAPER III

3.3.1 Study design

This study is a patient series of prospectively included patients on which EP had been performed at the Karolinska University hospital between 2005 and 2014. The aim was to evaluate the clinical outcome following endoscopic papillectomy and to incorporate an oncogenic evaluation of the mutational status of KRAS in the endoscopically resected specimen from the papilla of Vater.

3.3.2 Patients and data collection

All patients treated with endoscopic papillectomy, with curative intent, were included. The indication for resection were, if endoscopic biopsies showed adenoma or if the patient had an endoscopic appearance of the papilla suspicious for adenoma. Signs of invasive malignancy were assessed with either computed tomography (CT) or magnetic resonance imaging (MRI) prior to resection. Data about patient demographics, pre-interventional investigations, medical history, interventional techniques used, complications, the histopathological outcome, as well as the clinical outcome were collected and analyzed from the medical charts. Paraffin-embedded tissue samples from the endoscopic papillectomy were analyzed to determine KRAS mutational status.

3.3.3 Outcome measures after endoscopic papillectomy

Outcome measures for the endoscopic papillectomies were endoscopic success and post-interventional complications. In this study, we chose the most often used definition for endoscopic success, proposed by Catalano et al. (2004), with minor modification. The definition used in the present study was that; endoscopic success was defined as complete excision without regard to the number of endoscopic sessions required and that the patient was adenoma free at two consecutive surveillance endoscopies, over a minimum period of 6 months without recurrence during long-term follow-up.

In contrast to Catalano et al (2004), we also included in the definition a timeframe stating that two consecutive, adenoma-free, follow-up endoscopies with a minimum time of 6 months between the endoscopies had to be made to be considered cured. The use of the timeframe of 6 months was to clarify, more precisely, the borderline between cure and recurrence.

Treatment failure was determined as an intra-ductal extension of adenoma or malignant transformation discovered during follow-up. A finding of neoplasia after being defined as

cured of adenoma was considered a recurrent disease. Postprocedural complications were defined according to the consensus criteria (Cotton et al. 1991).

3.3.4 Endoscopic papillectomy technique

All resections were performed under general anesthesia with the patient in a supine position. Experienced endoscopists performed all the EPs. Cannulation of both pancreatic and biliary ducts were tried before resection to delineate signs of intraductal extension of adenoma, and to install methylene blue in the pancreatic duct to ease post-resectional recannulation and prophylactic pancreatic stenting (Harewood et al. 2005).

No submucosal injection to lift the lesions were made. A braided snare, coupled with monopolar diathermy, was used to excise the papilla in an oral to distal direction. All resected tissue samples were retrieved for histopathological analysis.

Clinical follow-up was scheduled at 1, 3, 6, and 12 months, then annually, to find and treat any residual adenomatous tissue or signs of recurrent neoplasia.

3.3.5 KRAS analysis

To determine the mutational status of the KRAS oncogene in the specimen resected at EP, DNA was extracted from paraffin-embedded tissue samples. In this study, we used the commercially available QIAamp DNA mini kit™ (Qiagen inc.) according to the manufacturer's instructions. Measurements to confirm sufficient DNA concentrations was made. The samples were PCR amplified and the PCR product for the different samples were then subject to pyrosequencing analysis to measure the mutational status of KRAS codon 12, 13 and 61 (Richman et al. 2009). The results were described as either mutated-KRAS regardless of what codon involved or kind of mutation, or as wild-type (normal) KRAS.

3.3.6 Ethical considerations

The patients were informed about the treatment that was conducted on clinical grounds in all patients. The histopathological evaluation was conducted primarily as a part of the clinical evaluation but was, in this study reanalyzed in retrospect as was the KRAS analysis. The study design was approved by the Ethical review board at the Karolinska Institutet.

3.4 PAPER IV

3.4.1 Study design

This study was designed as a retrospective patient series to describe and detect clinical factors that could influence how decisions were made when choosing between either endoscopic or surgical resection of ampullary adenomatous neoplastic lesions.

3.4.2 Patients and data collection

All patients treated with surgical or endoscopic resection, between January 2006 and July 2018 at the Karolinska University Hospital, for verified or suspected adenomatous neoplastic lesions where no invasive, malignant lesion could be identified on cross-sectional imaging were included.

A comprehensive list of exclusion criteria was applied to select the small patient group with neoplastic ampullary adenomatous lesions that are on the borderline between endoscopic or surgical resection, Table 7.

The patients' medical journals were reviewed, to obtain data regarding different aspects of the initial symptoms, investigations, and findings, leading up to the decision for either surgical or endoscopic resection, Table 8.

3.4.3 Outcome measures

Several different measures are of interest when trying to depict and evaluate the decision-making in this complicated clinical context.

The final histopathological result after surgical resection was regarded as the final and correct diagnosis or if only treated with endoscopic resection, then the histopathological result after endoscopic papillectomy was considered as the final diagnosis.

The final diagnosis was then compared with the initial symptoms, cross-sectional imaging results, endoscopic biopsies, post-papillectomy histopathology, treatment decisions made, and other findings during the pre-interventional investigations to discern if these findings could have aided or altered decision-making when the correct diagnosis was clear after resection. Post-interventional complications were also registered, to get a perspective of what the clinician chooses between when deciding for either surgery or endoscopy.

Complications and the grading of severity of complications were done according to Cotton et al. (1991) for the EP and Clavien et al. (2009) for the surgical resections.

3.4.4 Ethical considerations

The study was performed entirely in retrospect, with no added tests or discomforts for the included patients. The data was extracted from the patients' medical records. The study was approved by the Swedish Ethical Review Authority.

Table 7. Exclusion criteria

-
- Neoplasia not originating in the ampulla/papilla on postoperative/post papillectomy pathology report (e.g. pancreatic cancer, IPMN, cholangiocarcinoma, duodenal adenoma and adenocarcinoma)
 - Non-ampullary adenomatous neoplastic lesion in the duodenum evident at the time of intended endoscopic resection.
 - Clearly invasive malignancy described as such in the original radiology report or after second opinion from an expert radiologist during multi-disciplinary tumor board (MDT).
 - Patients where the indication for surgery was chronic pancreatitis.
 - Familiar adenomatous polyposis or other hereditary polyposis diseases, due to the special considerations surrounding surveillance and when choosing surgical resection or not.
 - Neuroendocrine tumors (NET)
-

Table 8. Definitions of the information extracted from the patient journals

		Definitions	Notes
Patient demographics	Age Gender	Years Man / Woman	
Dominant initial symptom/finding	Jaundice Pancreatitis Bile duct dilatation Incidental finding Abdominal pain Other	-Clinically evident -Acute or Chronic -Asymptomatic, Seen on imaging -During endoscopy for other reasons, e.g., “dysphagia”, “ulcer control” -Unspecific, reason for imaging e.g., Anemia, GI Bleeding	As reported in the patient journal including radiology report or the referral documentation from other hospitals
Radiological findings (CT/MRI)	Visible non-invasive lesion? Bile duct dilatation? Main pancreatic duct dilatation?	e.g. “Suspicious lesion”, “Swollen papilla”, “non-invasive” e.g., “Dilated”, “widened” “Double duct sign”	As written in the original radiology report or MDT opinion if changed
Endoscopic cell/tissue samples	Forceps biopsy? Brush cytology?	e.g. “adenoma”, “suspicion of invasive malignancy”, “Adenocarcinoma” Grade of dysplasia? “Atypic cells”, “Normal Cells” “Malignant cells” “Unclear”	As written in the original pathology or cytology report
EUS finding	Invasive tumor? Non-invasive tumor Ductal dilatation?	As stated in the original EUS report	
Treatment decision	Multi-disciplinary tumor board Treatment decision	Yes/no e.g. “malignancy cannot be excluded”, “Ampullary cancer” “Recommends endoscopic resection “	
Endoscopic papillectomy	Curative resection/ endoscopically cured Recurrent disease? Complications Histopathological result	Complete excision without regard to the number of endoscopic sessions required and that the patient was adenoma free at two consecutive surveillance endoscopies, over a minimum time of 6 months ¹² Return of adenoma after being "cured." According to consensus criteria ³⁹ See “Forceps biopsy” above	
Surgical resection	Histopathological result Complications	See “Forceps biopsy” above According to Clavien/Dindo ⁴⁰	

EUS – Endoscopic Ultrasonography, MDT- Multi-disciplinary tumor board, CT- Computer Tomography, MRI- Magnetic resonance imaging

4 RESULTS

4.1 PAPER I

Endoscopists from the Nordic countries, nine experts and nine non-experts, responded to the two web-based surveys consisting of picture sets showing different papillae taken from the proposed classification of the endoscopic appearance of the papilla.

4.1.1 Interobserver agreement

In the first survey, the endoscopists were requested to answer what type of papilla, out of the four predefined types, that they thought the individual sets of photographs represented. The correct answer for each set of photos had been decided by the expert group when they created the classification. The endoscopists' answers were correct, as a group, in 72% (range 58%-82%) of the sets of photos, Table 9.

The interobserver agreement was substantial for the entire group of endoscopists $\kappa=0.62$ (95% CI 0.59-0.66) with comparable results for both experts $\kappa=0.63$ and non-experts $\kappa=0.61$. The level of agreement among the individual endoscopists against the predefined classification ranged from moderate $\kappa=0.44$ to substantial $\kappa=0.76$.

Table 9. Inter- and intraobserver agreement.

	Observed agreement	Kappa (95% CI)	Agreement
Interobserver agreement			
All respondents	0.72	0.62 (0.59-0.66)	Substantial
Expert endoscopists	0.72	0.63 (0.57-0.69)	Substantial
Non-experts endoscopists	0.72	0.61 (0.56-0.67)	Substantial
Intraobserver agreement			
All respondents	0.75	0.66 (0.59-0.72)	Substantial
Expert endoscopists	0.77	0.68 (0.60-0.76)	Substantial
Non-experts endoscopists	0.73	0.62 (0.53-0.72)	Substantial

4.1.2 Intraobserver agreement

The intraobserver agreement, showed some variation between the individual endoscopists, from moderate, $\kappa=0.50$, to almost perfect, $\kappa=0.86$. The level of intraobserver agreement among the endoscopists as a group indicated a substantial agreement $\kappa=0.66$ (95%CI 0.59-0.72).

The results among experts $\kappa=0.68$ (95%CI 0.60–0.76) and non-experts $\kappa=0.62$ (95%CI 0.53–0.72) were again similar.

4.1.3 Comments

Both inter- and intraobserver agreement was substantial for the endoscopists as a group, as well as for experts and non-experts. Furthermore, as individuals did, the all endoscopists have at least a moderate level of agreement or better on both surveys.

The proposed classification of the endoscopic appearance of the papilla of Vater is validated with substantial agreement between both expert and beginner endoscopists.

4.2 PAPER II

4.2.1 Patients and distribution of the papilla types

In total, 1401 patients were included in the study. The mean age of the patients was 66 years (range 18-101 years), and 52% were female. The most common indications for ERCP were common bile duct stones 44%, followed by periampullary tumor and jaundice, see Table 10. Classification of the papilla into the predefined types was possible in 98% of the patients. In 2% (n=24) of the patients, the endoscopist was unable to select an appropriate papilla type. The most common papilla type was regular papilla, Type 1 in 56% of the patients, followed by Type 3, protruding, or pendulous papilla occurring in 23%. Small, type 2 was seen in 13% and type 4 Creased or Ridged papilla was seen in 8% of the patients.

Table 10. Patient characteristics

No of patients (n)	1401
Female	52%
Age, years, mean (SD)	66 (16)
Indication for ERCP	
Common bile duct stones	44%
Periampullary tumor	15%
Jaundice	13%
Stricture	9%
Primary sclerosing cholangitis	7%
Bile Leak	4%
Other	8%

There were no significant differences regarding age, sex, previous cholecystectomy rate, NSAID use, use of protective pancreatic stent, or indications for ERCP between the different papilla types, except for patients with creased or ridged papilla, Type 4. Compared with Type 1 papilla, patients with Type 4 papilla were, on average, younger (mean 59 years vs. 66 years, $p<0.0001$) and had more often primary sclerosing cholangitis as indication for ERCP (18.7% vs. 5.7%, $p<0.0001$). Furthermore, in patients with Type 3 papilla, periampullary diverticulum was not as frequent as in Type 1 papilla (6% vs. 13%, $p=0.001$). The level of endoscopist experience was evenly distributed among the different papilla types, with only minor, nonsignificant differences.

4.2.2 Frequency of difficult cannulation among the papilla types

The overall frequency of difficult cannulation, regardless of papilla type, was 42% (95% CI 39-44%). Among the different papilla types, difficult cannulation varied, as shown in Figure 14. Small papilla, Type 2 (52%, 95% CI 45-59%) and protruding or pendulous papilla, Type 3 (48%, 95% CI 42-53%) were significantly more often difficult to cannulate compared to regular, Type 1 papilla (36%, 95% CI 33-40%). There was, accordingly, an increased odds ratio (OR) for difficult cannulation for both small papilla (OR=1.89, 95% CI 1.37-2.62) and protruding or pendulous Type 3 papilla (OR=1.61, 95% CI 1.24-2.10) compared with regular, Type 1 papilla. Creased or ridged, Type 4 papilla (43%, 95% CI 34-52%) did not show any significant difference from regular Type 1 papilla in the frequency of difficult cannulation.

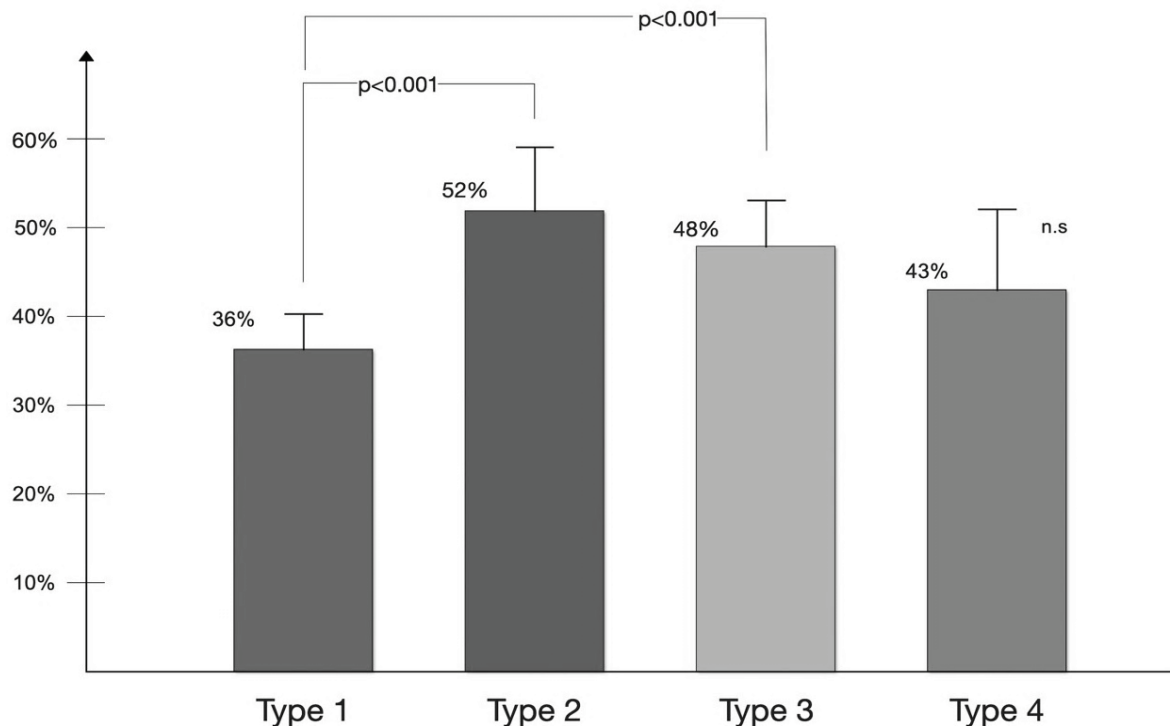


Figure 14. Frequency of difficult cannulation distributed between the papilla types.

4.2.3 Endoscopist experience and difficult cannulation

An expert endoscopist started the bile duct cannulation in 62% (n=870) of the patients, and an endoscopist in the intermediate category started in 17% (n=240). In 291 cases (21%), a fellow endoscopist started the cannulation attempts. There was an equal distribution of the various levels of endoscopist experience between the different papilla types, with only non-significant differences.

Cannulation difficulties were more frequent when endoscopists with less experience attempted bile duct cannulation, Table 11. Regardless of papilla type, bile duct cannulation was more often difficult when a fellow started (69%, 95% CI 64-74%) as well as when an endoscopist from the intermediate category started (49%, 95% CI 42-55%) compared when an expert started (30%, 95% CI 27-34%, both p-values <0.0001). Figure 15 also displays the frequency of difficult cannulation for endoscopists with varying degrees of experience.

Table 11. Frequency of difficult cannulation, depending on experience and papilla type

Papilla type	Experience of the endoscopists		
	Expert	Intermediate	Fellow
Type 1, regular papilla	25%	45%*	66%*
Type 2, small papilla	43%	49% [⊕]	83%*
Type 3, protruding or pendulous papilla	36%	63%*	69%*
Type 4, creased or ridged papilla	32%	44% [⊕]	73%*
Overall	30%	49%*	69%*

*Significant difference (p<0.05) compared to Expert, [⊕] non-significant compared to Expert

When only Expert endoscopists performing bile duct cannulation on their own were analyzed, the result was similar to that of the entire study population: a significantly higher frequency of difficult cannulation when cannulating small papilla, Type 2 (43%, 95% CI 34-53%, $p=0.0002$) or protruding or pendulous papilla, Type 3 (36%, 95% CI 29-43%, $p=0.0075$) was seen, compared to regular papilla, Type 1 (25%, 95% CI 21-29%). There was no difference when comparing creased or ridged papilla, Type 4 (32%, 95% CI 21-45%, $p=0.22$) with Type 1.

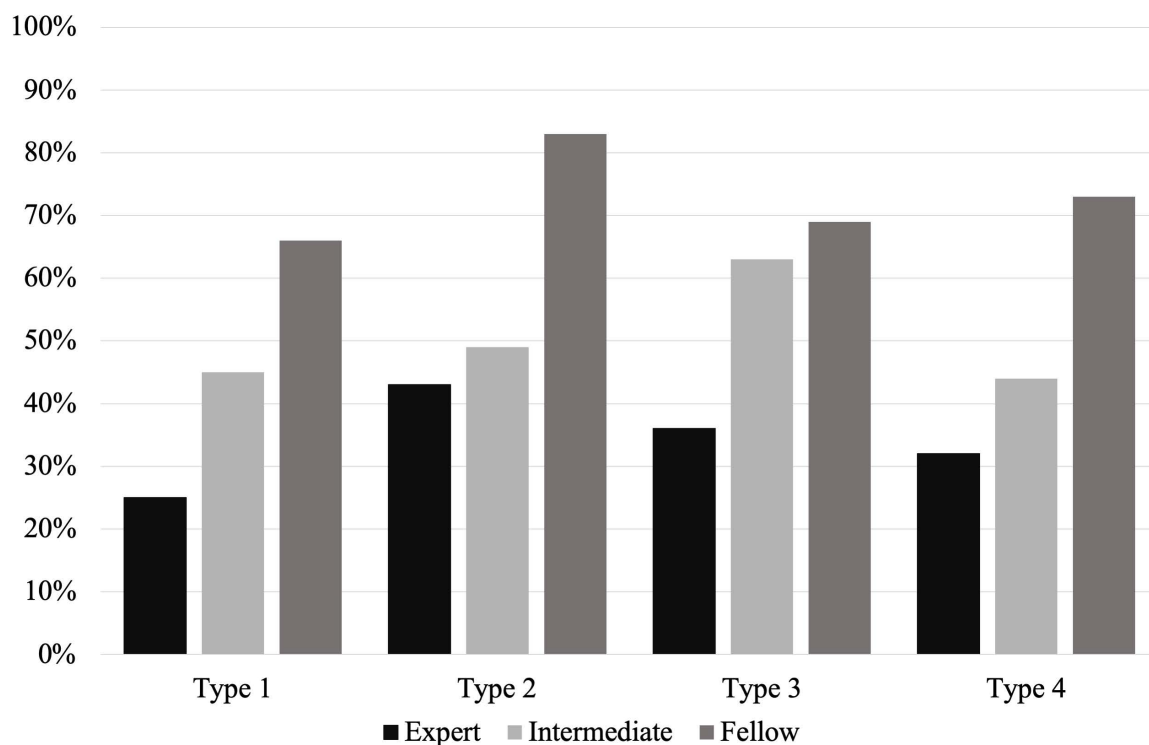


Figure 15. Frequency of difficult cannulation between the different papilla types and the experience of the endoscopist

4.2.4 Cannulation technique and papilla type

There was information about the use of auxiliary cannulation methods recorded in 1355 patients. In 99% of the ERCs, the endoscopists began cannulation with guidewire assisted cannulation. If cannulation became difficult, 50% of the endoscopists continued with guidewire cannulation until cannulation succeeded or failed. Different auxiliary cannulation techniques were applied in the remaining patients when cannulation became difficult. Standard pre-cut technique as the only auxiliary method was used in 9% of the patients, transpancreatic septotomy in 16%, double wire technique in 15%, and a combination of transpancreatic septotomy and double guidewire techniques in the remaining 10%. There was no significant difference in the choice of auxiliary techniques between the different papilla types, Figure 16.

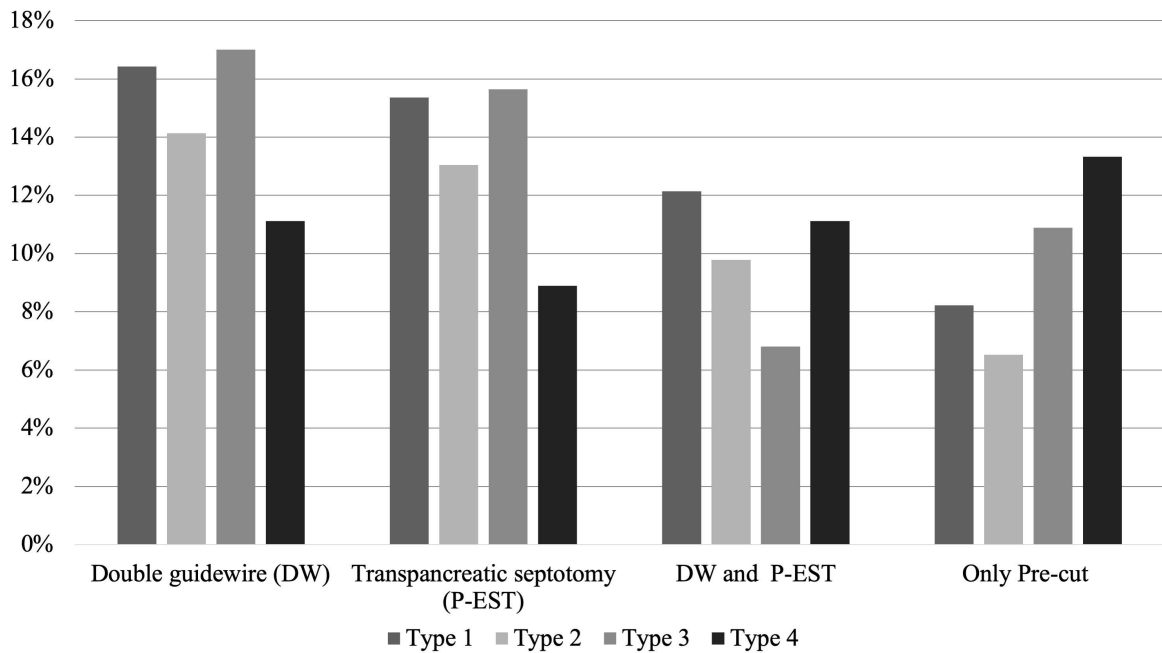


Figure 16. Auxiliary cannulation techniques used when cannulation became difficult, distributed among the different papilla types

4.2.5 Complications and the papilla types

The overall post ERCP pancreatitis (PEP) frequency, regardless of papilla type, was 6.7% (95%CI 5.5-8.2%). When there was difficult cannulation, the frequency of PEP increased to 8.9% compared to 5.1% ($p=0.006$) when cannulation was not difficult. There was also a variation in the frequency of PEP between the different papilla types, but none of the differences were statistically significant. Regular, Type 1 papilla had a PEP frequency of 6.1% (95%CI 4.6-8.0%) whereas small, Type 2 papilla had 9.4% (95%CI 5.9-14.6%), protruding or pendulous, Type 3 papilla 6.4% (95%CI 4.1-9.7%) and creased or ridged, Type 4 had 7.5% (95%CI, 3.6-14.3%). There was an overall low frequency of other complications, such as post-interventional bleeding (0.2%) and cholangitis (0.6%), and there were no significant differences between the papilla types, Figure 17.

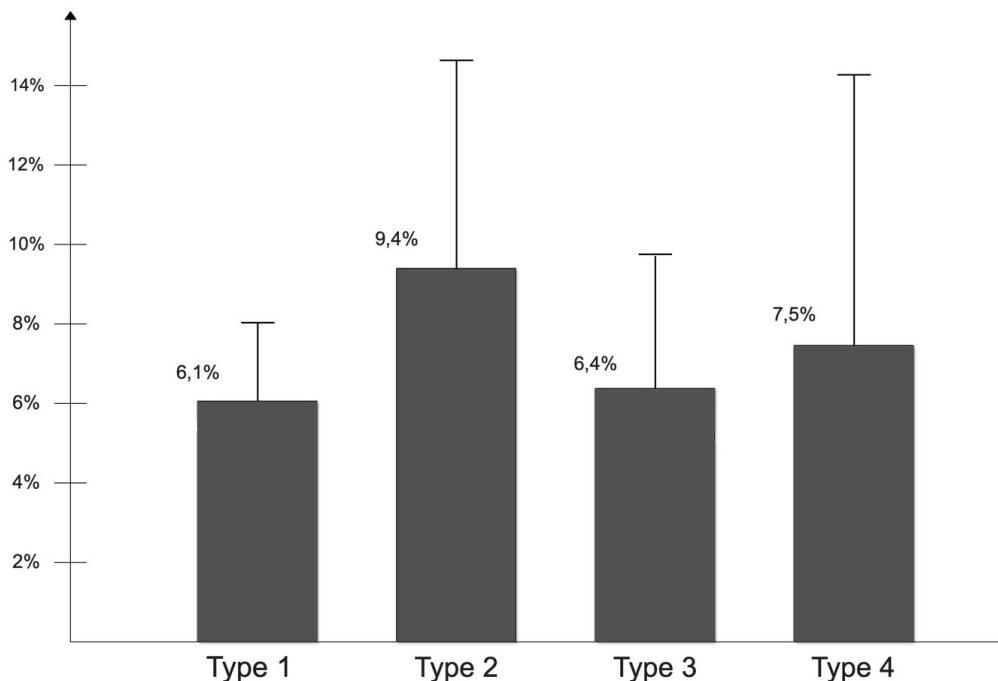


Figure 17. Frequency of post-ERCP pancreatitis among the different papilla types

4.2.6 Failed cannulation and the papilla types

The overall frequency of failed cannulation was low (2.8%, 95% CI 2.1-3.9%), with only non-significant differences between the different papilla types. However, the frequency of failed cannulation regardless of papilla type increased from 1.9% to 6.3% ($p < 0.0001$) if a fellow started cannulation attempts compared to an expert, even though they had to turn the endoscope over to a more senior colleague after 5 min. If a fellow started on a small, Type 2 papilla, there was an overall 14% failed cannulation frequency, compared to 2.7% ($p = 0.018$) when an expert performed the cannulation single-handedly. The OR, regardless of papilla type, for failed cannulation when a fellow started to cannulate compared to when an expert endoscopist started was 4.0 (95% CI, 2.0-8.2, $p = 0.0001$). When a fellow started the OR for failed cannulation on a small papilla was 6.1 (95% CI 1.4-27, $p = 0.017$) and on a protruding or pendulous papilla 5.2 (95% CI 1.3-21, $p = 0.022$) compared to when an expert started.

4.3 PAPER III

4.3.1 Procedures and complications

Between November 2005 and June 2014 were 36 patients treated for verified or suspected adenoma in the papilla of Vater with endoscopic papillectomy (EP) at the Karolinska University Hospital, Stockholm. Endoscopic biopsies taken before EP showed ampullary adenoma in 29 of the patients; in the remaining patients ($n = 7$), resection was due to macroscopic suspicion of adenoma. Endoscopic ultrasonography (EUS) was used in 25 (69%) patients to exclude local signs of invasive growth. Before completion of the procedure was a protective pancreatic stent placed in 26 patients (72%).

Eight patients (22%) had mild to moderate post-procedural complications, two patients developed pancreatitis, two with conservatively treated periampullary perforation, two with minor post interventional bleeding, and finally two with cholangitis. Obstructive jaundice at presentation increased the risk of finding an invasive ampullary adenocarcinoma or a concomitant pancreatic adenocarcinoma during endoscopic papillectomy (RR=3.98 CI 95% 1.46-10.85 $p = 0.007$). Moreover, jaundice at presentation, was associated with an increased risk of death due to malignancy during the follow-up period (RR= 3.4 CI 95% 1.2-9.7 $p = 0.02$).

4.3.2 Histomorphology

The development of the histomorphological findings from the endoscopic biopsies to the findings in the post papillectomy specimens can be seen in, Figure 18. Among the 29 patients that had adenoma in the endoscopic biopsies had 28 an adenomatous neoplasia in the papillectomy specimens. The grade of dysplasia and invasiveness after assessment of the resected specimen differed when compared with the results from the biopsies. Fourteen (48%) of the 29 cases with prior endoscopic biopsies, displayed the same histopathological grading in the resected specimens after EP. Five patients (17%) with adenoma on biopsies had an unknown ampullary adenocarcinoma revealed after EP. No remaining adenomatous tissue, only nonspecific inflammation, was the only finding in one patient where biopsies prior to EP had shown adenoma with high-grade dysplasia (HGD). Among the seven patients without proven neoplasia ahead of EP only two patients did have adenoma while 5 had non-neoplastic tissue in the post EP resected ampullary specimen; three of them had undiagnosed underlying pancreatic cancer.

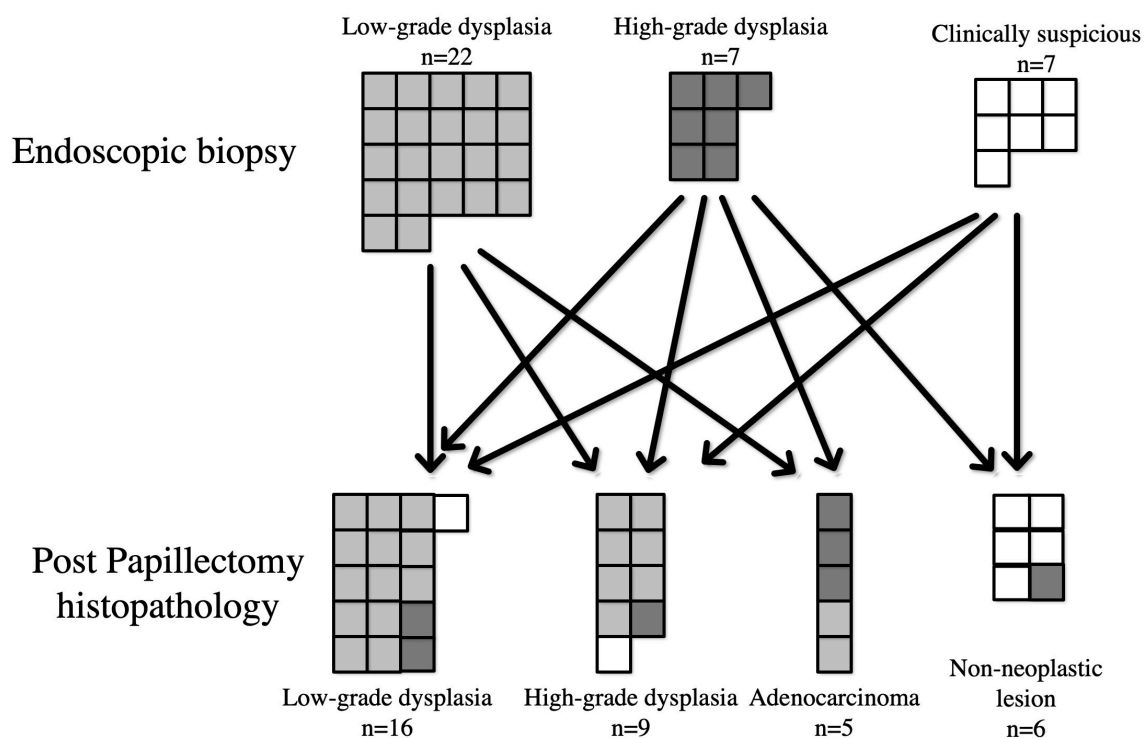


Figure 18. Histopathological development from biopsies to post- endoscopic papillectomy

Malignant tumors were significantly larger than adenomas (mean 31 mm vs. 14 mm, $p=0.001$), and all adenocarcinomas were greater than 20 mm in diameter. Endoscopic en-bloc resection was carried out in 22 patients (61%), while a piecemeal technique had to be used in the remaining 14 patients.

4.3.3 KRAS analysis

Nine, out of the 36 patients, had mutated KRAS shown in the resected specimen. The mutations were in codon 12 (n=5), codon 13 (n=2), or codon 61 (n=2). Mutated KRAS was found in 4 (80%) of the five patients with ampullary adenocarcinoma and in 4 (20%) of the 16 adenomas with LGD and in 1 (11%) of 9 with HGD. But the clinical impact was difficult to interpret. The clinical outcome for patients who expressed mutated KRAS was varied as 4 of the patients with mutated KRAS were cured endoscopically and 5 could not be cured endoscopically. The lesions with mutated KRAS tended to be larger than those expressing wild-type KRAS (mean 21 mm vs. 14.9 mm, $p=n.s$).

4.3.4 Clinical follow-up

After the index EP, either adenocarcinoma (n=5), adenoma (n=25), or non-neoplastic lesions (n=6) were found in the histopathological examination. Two of the patients with ampullary malignancy were referred for surgical resection after EP, and three continued with further endoscopic follow-up. One patient had only a carcinoma in situ tumor and two patients that were considered not fit for surgery. Also, two patients with signs of intraductal extension of adenoma and one with concurrent pancreatic adenocarcinoma were referred for surgical resection without any further endoscopic follow-up. The remaining 25 patients continued with endoscopic follow-up. During endoscopic follow-up, five more patients developed signs of extension of adenoma or malignant transformation. Three were sent for surgical resection, and two were treated with palliative measures. Unrelated disease or death hit two patients in between follow-up endoscopies, and they dropped out of the study.

Eighteen (50%) out of 36 patients scheduled for endoscopic papillectomy were endoscopically cured after a mean follow-up time of 47 months (range 16-92). Among the patients with confirmed adenoma after EP were 16 (73%) endoscopically cured. Eradication of adenomatous tissue required only one endoscopic resection in 11 cases (61%), the seven remaining patients required between 2 and 7 sessions to be cleared of all adenomatous tissue. One patient with ampullary adenocarcinoma who was not fit for surgery was treated seven times with endoscopic procedures to clear all adenomatous tissue; she was recurrence-free at the end of follow-up and is still alive, eleven years after the endoscopic papillectomy.

4.4 PAPER IV

4.4.1 Patients

During the study period from January 2006 to July 2018 was 1426 patients treated with either surgical or endoscopically resection for presumed or verified periampullary tumor at the Karolinska University Hospital. 172 patients fulfilled the inclusion criteria, while the remaining (n=1254) were excluded on various grounds, Table 12.

Table 12. List of excluded patients

<i>Exclusion criteria</i>	<i>n</i>
Non-ampullary neoplastic lesions	1004
Pancreatic cancer	639
Duodenal neoplastic lesions	102
Cholangiocarcinoma	56
Neuroendocrine tumor	67
IPMN or pancreatic cystic tumors	140
Invasive ampullary adenocarcinoma on imaging	85
Familial adenomatous polyposis	52
Miscellaneous indications (e.g. metastasis, chronic pancreatitis)	111
Missing Data	2
Total	1254

In the study population, there was an equal gender distribution (women n=86, male n=86) with a mean age of 66 years (range 33-85). Abdominal pain was more frequent as the dominating symptom among women than among men (22% vs. 6%, p=0.004), while jaundice was more frequent among men (29% vs. 49%, p=0.01).

Jaundice at presentation was more common in patients with adenocarcinoma, as the final diagnosis than among patients with adenoma (65% vs. 9%, p<0.0001). Among the patients with adenoma as the final diagnosis were abdominal pain a frequent initial symptom (20%), as well as previous, or recurrent pancreatitis (14%). In 27% of the patients with adenoma as the final diagnosis were the lesion discovered incidentally during upper gastrointestinal endoscopy for other reasons.

4.4.2 Cross-sectional imaging

All patients were examined with CT (n=164), both CT and MRI (n=39), or only MRI (n=8), at some time-point during the pre-interventional investigations.

In 45 patients there was a suspicion of a lesion in the ampullary area mentioned in the radiology report, but no apparent signs of an invasive, malignant, lesion. The suspicion of a lesion, was in this narrowly selected patient group, not more common if the final diagnosis were adenocarcinoma compared to if it was a benign diagnosis (31% vs. 21%, p=0.12). Bile duct dilation was seen in 140 patients (81%) and pancreatic ductal dilation was seen in 79 (46%) of the patients. Both ducts were dilated in 75 patients (45%), the so-called

“double duct sign”. Double duct sign was more frequent among patients with adenocarcinoma compared to when they had adenoma as the final diagnosis (60% vs. 26%, $p < 0.0001$). All patients with adenocarcinoma ($n=82$) had dilated bile ducts.

4.4.3 The final histopathological diagnosis

The final diagnoses in the entire study population was that 48% ($n=82$) had ampullary adenocarcinoma (AA), 15% ($n=25$), adenoma with high-grade dysplasia (HGD), 24% ($n=41$), adenoma with low-grade dysplasia (LGD) and, 14% ($n=24$) with non-neoplastic lesions. The non-neoplastic lesions consisted of findings such as unspecific inflammation, with or without pancreatitis, fibrosis of the papilla, gallstone disease, or periampullary diverticulum.

4.4.4 Endoscopic biopsies and brush cytology

Endoscopic biopsies were taken before deciding on EP or surgical resection in 80% ($n=137$) of the patients. The overall concordance between endoscopic biopsies and the final diagnosis is displayed in Table 13.

The sensitivity for endoscopic biopsies to correctly diagnose adenocarcinoma was 58% (95% CI, 45-70%) with a specificity of 97% (95 CI, 90-100%), and the diagnostic accuracy was 79% with a positive predictive value 95% (95% CI, 82-99%). In patients where endoscopic biopsies had shown adenoma had 94% ($n=77$ out of 82) a neoplastic lesion of some kind as the final diagnosis. Adenocarcinoma was revealed in 27% ($n=22$) of the patients with adenoma on the endoscopic biopsies.

Table 13. Endoscopic biopsies and the histopathological final diagnosis

Endoscopic biopsies	Final histopathological diagnosis				SUM
	Adenocarcinoma	Adenoma HGD	Adenoma LGD	Non-Neoplastic	
Adenocarcinoma	37		1	1	22
Adenoma HGD	11	13	2	3	29
Adenoma LGD	11	10	30	2	53
Non-neoplastic lesion	5	1		10	16
SUM	64	24	33	16	137

Brush cytology was taken during ERCP in 69 of the patients. Eight patients had malignant cells or atypia with suspicion of malignancy written in the cytology report. Six out of these had adenocarcinoma as the final diagnosis. The sensitivity in diagnosing malignancy was 25% (95%CI 10%-47%), and the specificity was 96% (95% CI 85%-100%). If also including patients with unspecific atypia in the brush cytology as a sign of malignancy, then the sensitivity became 54% and the specificity 64%. Therefore, when finding malignant cells on brush cytology, the cancer diagnosis is most likely correct, however an uncertain finding, with lower grades of atypia, gave no decisive information in this patient group.

4.4.5 EUS and final diagnosis

At the beginning of the study-period was EUS not often used at our hospital but has over the years been implemented more regularly. In Sweden, EUS is still under development and has not been implemented outside expert centers. EUS was performed on 36% ($n=62$) out of all the patients ($n=172$) and in many instances before EP ($n=26$), or at the same endoscopic session as the EP ($n=17$). The results from the EUS examinations were, 48% ($n=30$) in agreement with the patients' final diagnosis. In 34% ($n=21$) of the patients did the EUS examination under-stage the lesion, and in 4 patients were the lesions over-staged. Seven patients had an inconclusive examination due to technical problems. If the EUS

examiner stated that the patient had a malignant lesion (n=3), this was, in all cases, correct compared with the final diagnosis.

4.4.6 Endoscopic papillectomy (EP)

Endoscopic papillectomy (EP) was the initial treatment for 76 patients, see Figure 19. Endoscopic biopsies were in 82% (n=62) of the patients taken before EP. In 14 patients no biopsies were taken before EP, instead was the ampullary lesion discovered incidentally during a clinically indicated ERCP and the EP performed at the discretion of the endoscopist. Adenoma on biopsies, with various degrees of dysplasia, was the indication for the EP in 78% (n=59) of the patients. Three patients had biopsies with only non-neoplastic findings prior to EP, and all three did not have any signs of neoplasia after EP either.

4.4.6.1 Endoscopic papillectomy and the final diagnosis

The 76 patients resected with EP had in 89% (n=68) an adenomatous neoplastic lesion as the final diagnosis. For those who had an adenomatous neoplastic lesion as the final diagnosis was EP curative for 59% (n=40), Figure 19. The final diagnosis among the endoscopically cured were adenoma with LGD in 83% (n=33), adenoma with HGD in 15% (n=6), and one patient had a small adenocarcinoma with no sign of recurrence during long-term follow-up.

Eight patients had a non-neoplastic final diagnosis even though 4 of them had biopsies showing adenoma. One patient with non-neoplastic findings at EP had clinical suspicion of neoplasia and underwent surgical resection.

Twenty-one (28%), out of the 76 patients treated with EP, were referred for surgical resection due to either adenocarcinoma (n=8) on post-EP histopathology or adenoma with signs of intraductal extension (n=13). Additionally, six patients treated with EP had malignancy or advanced adenoma discovered at EP. They were not fit for surgery, and therefore treated with palliative measures.

4.4.6.2 Endoscopic papillectomy among patient with biopsy-proven adenoma

Of the 59 patients with biopsy-proven adenoma prior to EP, was 58% (n=34) cured of the neoplastic lesions with endoscopic resection. In 7% (n=4) of the patients, there were only non-neoplastic findings, diagnosed after EP, with no signs of residual adenoma.

Adenocarcinoma was revealed in 14% (n=8) of the patients where biopsies had shown adenoma, while 47 patients still had adenoma in the post EP tissue samples.

4.4.6.3 Complications after endoscopic papillectomy

The 76 patients treated with EP had in 79% (n=60) an uneventful intervention and were in most cases, sent home the day after the intervention. However, in 21% (n=16) of the patients, a post-EP complication occurred. The most severe complication was one patient who died 111 days post-EP due to severe post-procedural pancreatitis. The patient was examined with other invasive endoscopic techniques such as per-oral pancreatoscopy and EUS with biopsies, during the same endoscopic intervention as the EP, due to suspicion of a pancreatic lesion that could not be verified. Two patients with perforation were treated successfully with conservative measures and could be sent home on day 6, respectively day 9 postoperatively. The most common complications after EP were bleeding (8%), that needed transfusions or endoscopic intervention, and pancreatitis (7%), which were mild and self-limiting in many cases. One patient with pancreatitis developed multi-organ failure but recovered and one patient with severe bleeding needed to be treated with angiography and coiling.

One of the patients treated with surgical resection after not being cured with EP had a mild self-limiting pancreatitis after the EP that did not delay surgery.

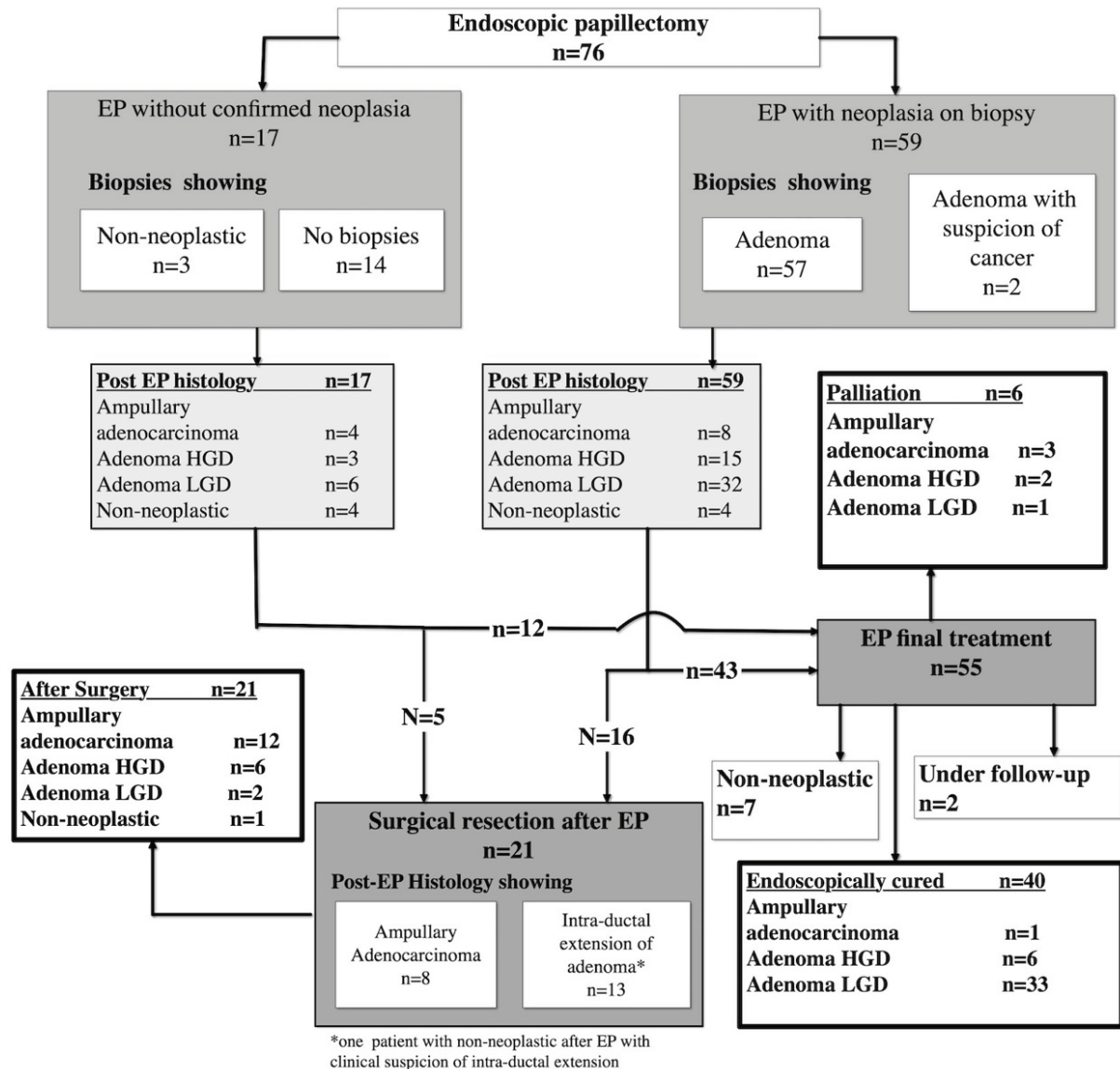


Figure 19. Clinical and histopathological development for patients treated with endoscopic papillectomy

4.4.7 Surgical resection

A multidisciplinary tumor board (MDT) evaluated the preinterventional investigations and made the treatment decisions for all patients treated with surgical resection (n=117), the majority of whom were treated with PDE (n=113). Three patients were operated with pancreas-preserving duodenectomy, and one patient had a transduodenal ampullectomy. The results from these four patients are included in the surgical resection group.

The decision to choose surgical resection were based on only imaging and no biopsies in 21 patients. The majority (n=75) had endoscopic examination with biopsies together with imaging as the basis for deciding for surgery and 21 patients were surgically resected after EP, Figure 20.

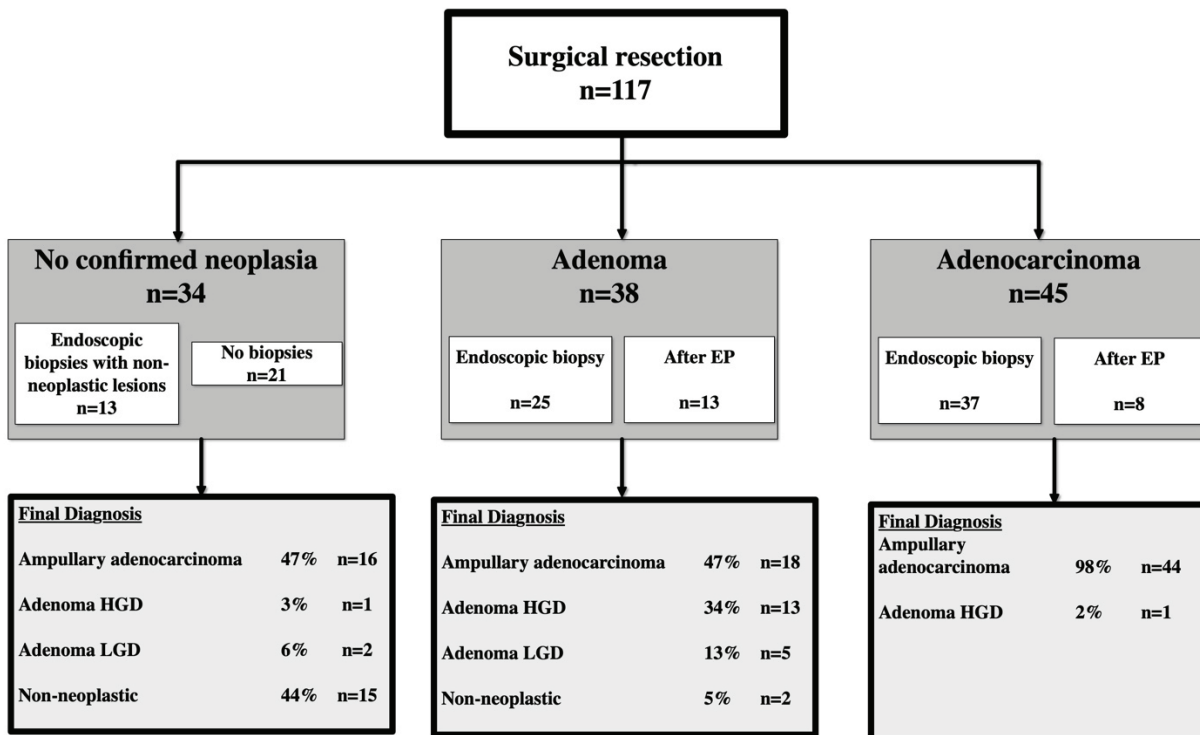


Figure 20. Histological development among the surgically resected patients

4.4.7.1 Surgical resection after endoscopic examination with biopsies.

In all the patients with endoscopic biopsies (n=75) taken prior to surgical resection did 73% (n=55) have adenocarcinoma, 12% (n=9) adenoma with HGD, 4% (n=3) adenoma with LGD and 11% (n=8) had non-neoplastic findings as their final diagnosis.

Among the 37 patients that had adenocarcinoma or adenoma with suspected invasive adenocarcinoma on biopsies, all had ampullary adenocarcinoma as the final diagnosis. Additionally, 25 patients were surgically operated, where endoscopic biopsies had shown either, adenoma with HGD (n=15), or adenoma with LGD (n=10). In this group had 52% (n=13) adenocarcinoma, and 12 still had adenoma while 1 had only a non-neoplastic lesion. Finally, among the patients were biopsies could not confirm neoplasia (n=13) had five patients ampullary adenocarcinoma, one adenoma with HGD and seven patients (54%) still had non-neoplastic lesions after surgery.

4.4.7.2 Surgical resection without endoscopic biopsies

Among the 21 patients that were surgically resected, without prior endoscopic biopsies had 52% (n=11) ampullary adenocarcinoma as their final diagnosis. However, 38% (n=8) had non-neoplastic findings, and 10% (n=2) had small adenomas (3-4 mm) with LGD combined with suspected gallstone disease, as the final diagnoses after surgery.

4.4.7.3 Surgical resection after endoscopic papillectomy

Twenty-one patients were operated with PDE after EP. Seven out of the eight patients with adenocarcinoma after EP, had adenocarcinoma as well in the final surgically resected specimen; one had only residual adenoma with HGD.

The 13 patients with intra-ductal extension of adenoma had in 5 patients invasive adenocarcinoma, while seven still had adenomas with intra-ductal invasion. One had on signs of remaining neoplastic tissue in the postoperative histopathology.

4.4.7.4 *Complications after surgical resection*

Pancreatic surgery is a major surgical resection and as such, have a high frequency of postoperative morbidity. In this study, 67% (n=78) of the surgically resected patients (n=117) had postoperative complications, that were in 34% (n=40) of the patients mild and not requiring any advanced interventions (Clavien 1-2).

Two (1.7%) patients died due to postoperative complications (Clavien 5), and 7,5% (n=9) of the patients needed treatment in the intensive care unit for multi- or single organ failure (Clavien 4a and b). The remaining 23% (n=27) had an intermediate degree of complications (Clavien 3a and b), that were treated with endoscopic, surgical, or radiologic interventions to drain collections, stop bleedings, reoperation with rescue pancreatectomy, or ductal drainage due to anastomotic leakage.

Operated patients with adenocarcinoma as their final diagnosis had significant complications (Clavien 3a-5) in 27% (n=21/78), and patients with benign final diagnosis had in 45% (n=17/38) significant complications, but the difference was not statistically significant (p=0.09).

5 DISCUSSION

This thesis focuses on a few issues concerning the papilla of Vater, or major duodenal papilla. The attention has been on two different clinical problems. First, in Paper I and Paper II the focus is on the endoscopic appearance of the papilla and to answer the question, if the appearance of the papilla influences transpapillary cannulation during ERCP.

Paper III and Paper IV deal with various aspects surrounding the clinical management of early ampullary neoplastic tumors in the papilla of Vater.

Paper III shows that endoscopic papillectomy is a safe and potentially curative treatment possibility for early neoplastic lesions in the papilla of Vater. While Paper IV sheds light upon the various difficulties surrounding clinical management of early ampullary neoplastic lesions in the papilla of Vater. We are evaluating decision-making and investigations prior to curative, either endoscopic or surgical, resection.

5.1 THE ENDOSCOPIC APPEARANCE AND BILE DUCT CANNULATION

In this thesis is an inter- and intraobserver validated classification of the endoscopic appearance of the papilla of Vater presented. Furthermore, the proposed classification is put to the test, measuring circumstances surrounding bile duct cannulation and especially the frequency of difficult cannulation, to evaluate its clinical use.

5.1.1 Interobserver agreement in classification studies been proven to

To evaluate a diagnostic or clinical method that involves subjective interpretation, there must be an evaluation of the degree of agreement between the different interpreters to make the method valid. There have been several studies performed evaluating various aspects of image interpretation in the field of gastrointestinal endoscopy (Armstrong et al. 1996; Asfeldt et al. 2009; Silva et al. 2011; Hirano et al. 2013). In Paper I, concerning the endoscopic classification of the macroscopic appearance of the papilla of Vater, there is a substantial agreement among endoscopists of different degrees of experience and the predefined classification. The level of agreement is at a similar level to other studies in the field of endoscopic image interpretation, used in clinical practice today, such as the LA classification concerning the degree of reflux esophagitis (Lundell et al. 1999). The proposed classification of the endoscopic appearance of the papilla of Vater is the only classification of the endoscopic appearance of the papilla that has undergone any interobserver agreement evaluation by multiple observers and from several centers.

In our papilla image study, we choose to use endoscopic images for the intra- and interobserver evaluation. It can be argued, however, that the use of endoscopic video sequences could have been better than using endoscopic images when performing this kind of validation studies. There are some reports have used video sequences (Bendtsen et al. 1990) in a similar setting like this and others that have used still images (Curvers et al. 2008) instead. No comparison between the different methods have been made, and photographic images are still the standard way of documenting endoscopic findings.

5.1.2 The endoscopic appearance and difficult cannulation

The endoscopic appearance of the papilla of Vater has consistently been claimed to influence bile duct cannulation during ERCP (Lee et al. 2014b; Testoni et al. 2016; Berry et al. 2019). Earlier statements about cannulation difficulties and endoscopic appearance have concluded, without any clear definition, that small and protruding papilla are more often difficult to cannulate and therefore also have a higher risk for PEP (Swan et al. 2011; Katsinelos et al. 2012; Bakman and Freeman 2013). Not until the present study has the influence of the different appearances of the papilla on bile duct cannulation been quantified, and prospectively determined. With the use of the validated classification of the endoscopic appearance and the definition promoted by the ESGE for difficult cannulation,

we have shown that cannulation is more frequently difficult for Type 2, Small papillae and Type 3, Protruding or Pendulous papillae than for Type 1, Regular papilla, Figure 13. The overall frequency of difficult cannulation, in the present study, regardless of papilla type, was 42% using the 5-5-2 definition and this is on par with what Ismael et al (2019) have found. In their patient series they had 37.9 % frequency of difficult cannulation when consecutively measuring bile duct cannulation using the 5-5-2 definition in an everyday clinical setting. Their results also confirm that there is a higher frequency of PEP if the cannulation becomes difficult compared to when it is easy (2.2% vs. 7.1%, $p=0.001$). Watanabe et al. (2019) constructed a classification of the endoscopic appearance where three expert endoscopists classified endoscopic pictures into the different papilla types and reviewed cannulation data in retrospect. They suggested two different aspects of the endoscopic appearance for their classification; first the amount of supra-papillary protrusion of the intraduodenal portion of the ducts, separated into three different grades; second five different surface patterns of the papilla itself. Watanabe et al. decided on five attempts as their definition of difficult cannulation with no time-limit. With their definition of difficult cannulation, they had an overall frequency of difficult cannulation of 41.8%. They concluded that the papilla type of Papilla-L (Large protrusion) had a higher OR for difficult cannulation compared to the average level of difficult cannulation, but if this applied to all the different surface patterns was not clear. The classification constructed by Watanabe et al. (2019) is complicated, with 3x5 potential types of papillae, and all the patients were classified in retrospect by three senior endoscopists.

When a new classification is constructed, there must be a compromise between usefulness and precision. Our classification, based on four different types, is inter-observer validated among both experts and beginner endoscopists, to a similar degree, making the classification recognizable, easy to use and to generalize. The classification could have been more elaborate, including several subclasses of papillae, but then it would have been more difficult to use in the daily clinical praxis.

5.1.3 Endoscopic appearance and cannulation technique

In earlier studies, where the influence of the endoscopic appearance were discussed, has the focus been the variation in the degree of supra-papillary protrusion, and how that influences when choosing pre-cut technique, see section 1.5.

Wen et al. (2018) compared the transpancreatic septotomy technique against needle-knife fistulotomy technique where the choice of technique was dependent on the morphology of the papilla. They separated the papillae into either “small”, with no supra-papillary protrusion, or a “protuberant” papilla, with a visible supra-papillary bulge. Transpancreatic septotomy was the preferred technique used when the papilla was “small” and a guidewire had been placed in the pancreatic duct, otherwise was the needle-knife fistulotomy technique be used. However, they could not show any differences between the two techniques on cannulation success or complications. Their study was retrospective and with a major difference in the number of patients in the two treatment arms. The “small” papilla group had three times as many subjects as the protruding type group. Probably are the “small” papillae in Wen et al comparable to Type 1, 2 and 4 in our proposed classification. In our data, there was no indication that the endoscopists had any preference for a specific type of auxiliary cannulation technique, depending on the endoscopic appearance. Several previous studies have argued that needle-knife fistulotomy technique is the preferred technique when the papilla is similar to the Type 3, Protruding or Pendulous type, thereby also avoiding the papillary orifice and perhaps even have a lower frequency of PEP (Mavrogiannis et al. 1999).

Perhaps can future studies focusing on the cannulation techniques used when cannulating the different types of papillae shed some light on these questions.

5.1.4 Consequences for training in ERCP

In the present study we found that the experience of the endoscopist influenced the frequency of difficult cannulation for all the papilla types. That experience influences bile duct cannulation is not a surprising finding, but it has previously not been quantified using the ESGE promoted definition (5-5-2) and it is one of the few prospective studies that have the frequency of difficult cannulation as the primary endpoint. Because difficult cannulation is one of the acknowledged risk factors for PEP (Dumonceau et al. 2014), the question regarding the high frequency of difficult cannulation among beginners learning ERCP has to be addressed. The aim of our study was not primarily to investigate the PEP frequency, but the influence the different papilla types have on bile duct cannulation. The possibility of an increased risk for PEP when a trainee is making the initial attempts at cannulation has been discussed previously. Some report an increased risk for PEP (Cheng et al. 2006) while others have not seen any increase in the risk for PEP (Elmunzer et al. 2012; Lua et al. 2015; Leerhøy et al. 2016)

Lee et al (2019a) in a very recent study from South Korea measured post ERCP complications among patients undergoing ERCP with a naïve papilla, and recorded the level of experience among the endoscopists. They report that the least experienced (<200 lifetime ERCPS) endoscopists have a higher frequency of PEP (12% vs 6.8%) compared with more experienced endoscopists. In that study, they defined difficult cannulation as any of the criteria, >10 attempts, one guidewire passage into the MPD, or >5 minutes. Using this definition, they could show a clear difference between experts and less experienced in the frequency of difficult cannulation (49.7% vs 37.3%, $p < 0.001$). At multivariate analysis, taking the frequency of difficult cannulation into the analysis, they showed a higher OR for PEP among inexperienced endoscopists, OR 1.63 (95%CI 1.05-2.53).

The higher frequency of difficult cannulation among inexperienced endoscopists were an expected finding, but in what way does the higher frequency of difficult cannulation among beginners influences the risk of PEP. Future studies with a clear definition of trainee participation measuring the cannulation process and complications might answer the question.

Failure to cannulate occurred more frequently if a fellow (<200 lifetime ERCPS) started cannulation attempts, even though a more senior colleague took over cannulation after 5 minutes, compared to when an expert performed cannulation on their own. The higher failure frequency was especially noticeable when a fellow was faced with a Type 2, small papilla. This finding, if confirmed, must have consequences on how future training in ERCP is conducted. It may suggest that if a fellow sees a small, Type 2 or perhaps even a protruding or pendulous, Type 3 papilla, they probably should withhold from cannulation attempts, not to jeopardize further cannulation success.

In previous reports, there are conflicting conclusions concerning these matters, where some studies indicate a higher cannulation failure rate (Williams et al. 2012; Peng et al. 2013) while others have found no difference (Voiosu et al. 2019) or some even showed better procedural success with trainee participation (Ekkelenkamp et al. 2015). There is no universal definition for “trainee participation” among the different studies, and with conflicting results, the question is still unanswered.

5.1.5 Difficult cannulation frequency as a measure of proficiency

The self-evident finding that the frequency of difficult cannulation is lower among experts than among beginners might be used when evaluating education or monitored as a quality measure. The frequency of successful cannulation of the desired duct is the most frequently used intraprocedural quality measure (Domagk et al, 2018; Adler et al, 2015), where the goal is >98% cannulation success or at least above 80-85% to be regarded as having completed basic training. Failed cannulation is of course an important variable, but it does

not measure the ability of the endoscopist in all the ERCPs where cannulation succeeds. In addition, by measuring the rate of difficult cannulation, is the entire process of cannulation also evaluated, with a variable that has a clear correlation to PEP frequency (Ismail et al. 2019). The added benefit could also be that keeping track of both cannulation time and attempts could help in making a timely shift to auxiliary cannulation techniques, as proposed in several meta-analyses (Sundaralingam et al. 2015; Chen et al. 2018; Tang et al. 2018).

Further studies about the use of difficult cannulation frequency as a quality measure, might determine a benchmark for what frequency of difficult cannulation one should achieve and maintain to be considered a qualified ERCP endoscopist.

5.2 ENDOSCOPIC PAPILLECTOMY

Endoscopic papillectomy (EP) has, since the beginning of the study period in 2005, been proven to be a safe and effective first-line treatment when resecting adenomas in the ampullary region in several studies and guidelines (Chathadi et al. 2015). With the improvements in cross-sectional image diagnostics and the increasing availability of endoscopic examinations it is likely that discovering asymptomatic, suspicious lesions in the ampullary region suitable for endoscopic resection will increase.

Although EP is a comparatively lenient treatment if all goes well, there are potentially disastrous complications if not performed with care and with a great deal of experience in complex endoscopic procedures.

5.2.1 Clinical outcome after Endoscopic papillectomy

Both Paper III and Paper IV shows that EP is a useful intervention with curative potential for patients with ampullary adenomas. If EP cannot offer a curative resection it can serve as a macro biopsy to aid in decision-making prior to surgery.

Among the patients scheduled for EP was 50-59% of the patients in our studies cured with the endoscopic resection. In a recent meta-analysis, they concluded that the overall curative resection frequency was 87.1%, with recurrence in 11.8% of the patients (Spadaccini et al. 2019). In this meta-analysis, they also conclude that it is difficult to compare the oncological results between patient series, because the indications for EP, the investigations leading up to EP and the definition of treatment success is not standardized between the different patient series. It is therefore difficult to put our results into perspective, but our frequency of curative resections is on the lower end of what other studies have presented (Laleman et al. 2013; Klein et al. 2018), Table 4. One could guess that the reasons for the relatively low curative rate in our studies is that surgeons performing these resections are, perhaps, presented to a different case-mix, and maybe a lower threshold to turn to surgical resection.

There are several factors, in our data, that influenced treatment success. The size of the lesion (>20 mm) as well as jaundice at diagnosis increased the likelihood of finding an undiagnosed malignancy after EP. The size of the lesion as a risk factor for malignancy is emphasized in several reports (Patel et al. 2016; Kandler and Neuhaus 2018).

5.2.2 Complications after endoscopic papillectomy

There is a high post-interventional complication frequency after EP compared with other endoscopic interventions. The complications are mild to moderate in most patients, and with the same kinds of complications that occur after ERCP, but with a slightly higher frequency. In a recent meta-analysis, including, 1751 patients Spadaccini et al. (2019) report a 24.9% overall complication frequency, with pancreatitis in 11.9% and bleeding in 10.6% of the patients. Perforations were at 2.7%, which is considerably higher than in ordinary ERCP patients (0.1-0.6%) (Andersson et al. 2012).

In our studies, the complication frequencies were at 21% and 22% of the patients, respectively.

5.3 CLINICAL MANAGEMENT OF AMPULLARY NEOPLASTIC LESIONS

5.3.1 Early symptoms of an ampullary lesion

Among the patients included in Paper IV were obstructive jaundice (39%) the most frequent symptom at presentation, followed by unspecific bile duct dilatation (15%). Irani et al., (2009) in their study on endoscopic papillectomy, had 48% (72 out of 150) of the patients cholestasis as the initial symptom. In a recent study, by (Li et al. 2019b) the frequency of jaundice at presentation was significantly higher for patients with adenocarcinoma compared to patients with adenoma as the final diagnosis (47.8% vs 13.8%, $p=0.001$) as was also the frequency of bile duct dilatation (34.8% vs. 9.2%, $p=0.001$). Ridditid et al. (2014) concluded that jaundice at presentation was more common in patients with incomplete EP.

Jaundice at presentation was also in our data linked to a higher frequency of adenocarcinoma, compared to the patients that had adenoma as the final diagnosis (65% vs. 9%, $p<0.0001$). Probably are the patients without jaundice at presentation the once where EP has the best chance to offer a curative resection. Abdominal pain as the initial symptom or an incidental finding of an ampullary lesion might also indicate a benign disease (Irani et al. 2009). Sahar et al. (2019) reported that in their patient series had 72% of the patients with adenomas no symptoms prior to diagnosis and only 8% of the patients had jaundice or biliary obstruction.

Although ampullary neoplastic tumors are rare lesions among patients with abdominal pain, it is a differential diagnosis to have in mind, especially when performing upper gastrointestinal endoscopy or in patients with biliary type of pain.

5.3.2 Imaging and ampullary neoplastic lesions

The investigational methods used in the preoperative evaluation of a suspected ampullary neoplastic lesion are duodenoscopy with biopsies, ERCP, EUS, IDUS, MDCT, and MRI with MRCP. All have their strengths and weaknesses in confirming the correct diagnosis. IDUS is the most accurate investigational method for local staging of ampullary lesions but it is technically complex, invasive, and has few other investigational applications, making it rarely used in clinical praxis (Ito et al. 2007).

5.3.2.1 Pre-interventional imaging

MDCT is widely used in many different clinical situations and is good at finding indirect signs of suspected ampullary lesions such as dilated ducts and protrusion of the papilla, as well as evaluating the presence of distant metastasis (Nikolaidis et al. 2014).

In our data we excluded patients with a clearly invasive lesion, seen on imaging. The frequency, in our data, of patients where imaging showed a suspected, non-invasive lesion was similar regardless whether the final diagnosis was adenoma or adenocarcinoma. In a recent study by Anghong et al., (2018) had 41.9% of the patient with confirmed ampullary adenocarcinoma no visible ampullary mass that could be seen on MDCT. These findings implicate that MDCT has no, or at best moderate, ability to differentiate malignant from benign ampullary lesion (Lee et al. 2011b). Zbar et al. (2012) report that MDCT have a sensitivity between 19% to 67% in correctly diagnosing the T-stage of an ampullary lesion. Chen et al (2009) report that MRI has an accuracy 54% in correctly diagnosing the T-stage. In both of our studies the exact T-stage of the lesions was not possible to evaluate from the retrospective analysis of the EUS reports. The endoscopist only stated if the lesions were invasive, malignant or suitable for endoscopic resection. The quality of the EUS examinations varied a lot during the study period at our hospital and should be

implemented more often in this patient group. In published studies has EUS a high accuracy (63-90%) to correctly evaluate the T-stage of an ampullary lesion (Ito et al. 2010; Okano et al. 2013) and is better than MRI and MDCT.

To evaluate the amount of intraductal extension and not T-stage has ERCP similar accuracy as EUS according to Ridditid et al. (2015). Both methods have a sensitivity of 80% or more and a specificity of 93% to determine intraductal extension correctly when comparing with the final result after surgery.

To determine the N-stage of the lesion is probably MRI better than EUS but there is only one study directly comparing these modalities (Chen et al 2009)

5.3.2.2 Ductal dilatation and final diagnosis

The finding of dilated pancreatobiliary ducts, double duct sign, on imaging is an ominous sign for a malignant disease in the periampullary region. Sinha et al. (2015) showed in a retrospective study on MRCP investigations, where 81 patients with double duct sign were evaluated to determine the underlying reason for the ductal dilation, that the most common reason for double duct sign was choledochal stones. They also report that the patients with jaundice and double duct sign had 48% a malignant disease. In our data were the double duct sign significantly more frequent among patients with malignant disease than among those with a benign final diagnosis (60% vs 26%, $p < 0.0001$).

Among patients with an unclear bile duct dilation are the underlying explanations for the bile duct dilation in many instances not found. Smith et al (2015) conducted a systematic review of the currently available studies on dilated bile ducts and concluded that the data is insufficient to make any clear recommendations about how to handle patients with unexplained bile duct dilation. However, they also conclude that a small fraction of the patients, preferably the ones with symptoms or raised liver function tests, must be further evaluated, as a fraction of them have an underlying malignant diagnosis.

When evaluating 68 patients with double duct sign without jaundice and no visible lesion on MDCT with EUS, had 42 of the patients no detectable reason for the dilation. Six of the patients had a periampullary neoplasia that had not been seen on MDCT (Cohen et al. 2014).

The dilation of the pancreatic duct is a more worrisome sign than the dilation of the bile duct, especially when there is a pancreatic lesion responsible (Oppong et al. 2014; Chiaro et al. 2019). In Del Chiaro et al. (2019), the main pancreatic duct dilatation was the only variable associated with an increased probability of underlying malignancy or HGD when evaluating intraductal papillary mucinous neoplasms (IPMN) of the pancreas.

5.3.3 Endoscopic biopsies in ampullary neoplasia

Evaluating endoscopic biopsies is not easy. In paper III the endoscopic biopsies were in concordance with the post-EP resected specimen in only 48% of the patients, and in paper IV the endoscopic biopsies were in concordance with the final diagnosis in 66% of the patients. The reason for the higher concordance in paper IV is probably because of the higher frequency of patients in paper IV with adenocarcinoma as the final diagnosis. In paper IV the sensitivity was 58% (95% CI, 45-70%) and the specificity was 97% (95% CI, 90-100%) for endoscopic biopsies to correctly diagnose adenocarcinoma and it is similar to what other studies previously have shown (Elek et al. 2003).

One other important aspect of endoscopic biopsies is that if biopsies show adenoma then there is nearly always adenoma or adenocarcinoma in the final diagnosis. This results indicates that biopsies showing adenoma must lead, at least, to further investigations and deciding upon resectional therapy.

Lee et al. (2014a) tried to both take the endoscopic appearance of the papilla and the results from the biopsies and combine those to guide in decision-making. They concluded that biopsies and the visual impression of the papilla was equally important, and that biopsies

had a tendency to under-stage the lesions and the visual impression tended to over-stage the lesions.

A way to improve tissue diagnosis from endoscopic biopsies might be to analyze the DNA content, as shown by Wen et al (2019). They concluded that tissue samples from endoscopic biopsies presenting abnormal DNA content were more common in biopsies showing HGD. In patients where biopsies showed a non-dysplastic mucosa there were no abnormal DNA. Even more interesting was that they found that in the small group of patients with LGD on histopathological examination and abnormal DNA content developed 86% HGD or adenocarcinoma within 2 years. Those with normal DNA content and LGD developed HGD or adenocarcinoma in 10% of the patients within 7 years. These findings must be repeated in a larger study to evaluate the clinical use of the method.

5.3.4 Importance of KRAS mutational status

Earlier studies have reported a varied expression of mutated KRAS in surgical specimens from ampullary adenocarcinomas and that the presence of mutated KRAS influences long term prognosis (Mafficini et al. 2018). The frequency of mutated KRAS also seems to be more common in the pancreatobiliary subtype (Perkins et al. 2019). Our study is the first to investigate the presence of mutated KRAS in tissue of endoscopically resected specimen collected at papillectomy. Mutated KRAS was present in 80% of the ampullary adenocarcinomas, but it was also present in several (25%) of the adenomas with low-grade dysplasia, making it hard to draw any conclusions on the long-term prognosis in these patient groups.

Exploration of biomarkers that can be analyzed from endoscopic biopsies or cytology specimen is clinically relevant, and one of the investigated candidates is mutated KRAS (Kipp et al. 2010; Layfield et al. 2014). Perhaps, with DNA analysis and molecular profiling can future generations of oncological treatment be tailored from small biopsies or even cytology (Dreyer et al. 2019).

5.4 ENDOSCOPIC PAPILLECTOMY OR SURGICAL RESECTION

5.4.1 Can patients with adenocarcinoma be endoscopically cured?

The recommendation that patients with a malignant ampullary tumor should be referred to curative surgical resection has been challenged over the years (Pérez-Cuadrado-Robles et al. 2018). It has previously been concluded, from studies on the surgically resected specimen, that even small ampullary malignancies can spread along the biliopancreatic ducts or set of lymph node metastasis therefore being impossible to resect radically with either TA or EP (Yoon et al. 2005; Lee et al. 2006). Perhaps in mucosal (Tis) tumors possible to resect or even T1 tumors if the lesions are of the intestinal subtype, without signs of lymphovascular invasion (Woo et al. 2009; Alvarez-Sanchez et al. 2017). The trouble is to be sure that the lesion is Tis ahead of EP, and that no part of the lesion has any lymphovascular invasion. In a small prospective case series on patients treated with EP, that had an adenocarcinoma smaller than 2 cm. The study showed that 57% of patients that were considered not fit for surgery or that did not accept surgery could be cured with endoscopic resection (Petroni et al. 2013). This result, of course, must be compared with the expected 5-year survival for stage Ia ampullary adenocarcinoma of at least 80% after surgery (Stiles et al. 2018).

EUS, or better IDUS, have been shown to have a high accuracy in determining the T-stage of ampullary lesions, in expert settings. The best use of EUS is to determine if a lesion is invasive or not, in patients where endoscopic biopsies have not confirmed malignancy. Unfortunately, are EUS dependent, to a high degree, on the endoscopists that performs the examinations, and most published results are from expert centers. How the high performance of EUS will stand in everyday clinical praxis is difficult to know.

5.4.2 How to avoid “unnecessary” surgery?

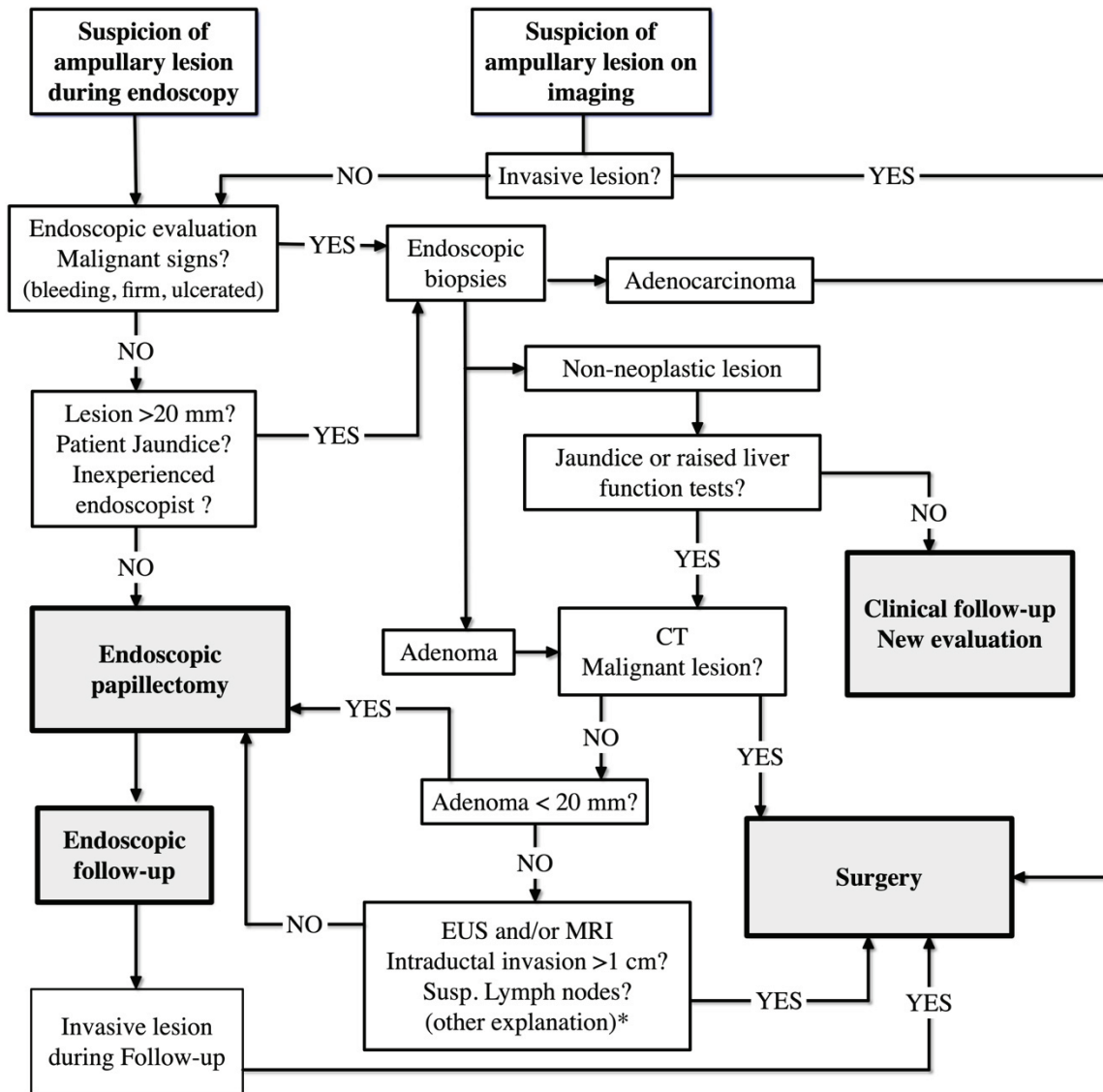
The preoperative diagnostic evaluation of lesions in the periampullary region is not easy. In paper IV are the frequency of surgical resections with a non-neoplastic lesion as final diagnosis high. The difficulties in evaluating an early malignancy, can sometimes lead to that surgical resections are performed on benign lesions, due to the overlap in symptoms and diagnostic findings (Birnbaum et al. 2017). In a consensus statement from the International Study group of Pancreatic Cancer Surgery it is stated that in 5-13% of the patients resected with pancreatoduodenectomy for presumed periampullary cancer is the final diagnosis benign. On the other hand, 5-9% of the patients operated because of chronic pancreatitis have an undiscovered malignancy (Asbun et al. 2014). In the consensus statement, it was concluded that no tissue diagnosis was needed before surgery in cases where a solid mass, suspicious for malignancy, can be seen on MDCT. However, the consensus statement does not include any discussion about the indications for PDE among patients with ampullary adenocarcinoma. Perhaps has the knowledge that pancreatic cancer does not need any histological confirmation prior to surgery influenced the treatment decisions concerning patients with ampullary cancer. In paper IV, 38% of the patients that went straight to surgery without any preoperative efforts to get an endoscopic biopsy had a non-neoplastic final diagnosis (see section 4.4.7.2.).

5.4.3 Suggested evaluation algorithm for suspected ampullary lesions

To avoid unnecessary surgical resections on patients with suspected ampullary neoplastic lesions should all patients without obvious invasive signs on MDCT undergo endoscopic evaluation with duodenoscopy, for visual examination, and biopsies, see Figure 21 Patients with confirmed malignancy, that are capable of handling major surgery should not undergo EP and take the risk of complications prior to curative resection. This because of the difficulties to make certain that the lesion is only a Tis tumor and that it has no lymph node involvement prior to resection. Among elderly patients and those not fit for major surgery can EP be a curative possibility if they have a small adenocarcinoma (<2cm) (Petroni et al. 2013).

If biopsies reveal adenoma regardless of grading of dysplasia there is a need for further investigations with MRI, or EUS if the right expert is available. Small adenomas (<2cm) might be resected with EP without further investigations or even without biopsies if there are no malignant signs, the patient is not jaundiced (Kandler and Neuhaus 2018), and that the endoscopist has the proper experience of EP. If MRI or EUS cannot find any signs of invasive lesion in the patient with adenoma, they should be considered for an EP with a curative intent.

After the EP there is a risk that an undiagnosed adenocarcinoma is revealed. The patient should then be referred for curative surgical resection or palliative endoscopic treatment. Patients with intra-ductal extension, but no proven adenocarcinoma, should be evaluated for surgical resection or intra-ductal radio-frequency ablation within a structured, prospective study protocol.



*Clinical follow-up or treatment as needed

Figure 21. Suggested investigational algorithm for suspected ampullary neoplastic lesion

6 CONCLUSIONS

The present studies present data to support the following conclusions:

- I. The proposed endoscopic classification of the endoscopic appearance of the papilla of Vater has shown substantial inter- and intraobserver agreement for the four different papilla types among both beginners as well as experienced endoscopists, making it useful in further studies regarding issues concerning cannulation and clinical management.

- II. The macroscopic appearance of the papilla of Vater influences bile duct cannulation during ERCP, where Type 2, Small papillae and Type 3, Protruding or Pendulous papillae are more frequently difficult to cannulate than Type 1, Regular papilla.
 - The frequency of difficult cannulation decreases with higher degrees of experience.
 - The frequency of failed cannulation rises if a fellow endoscopist starts cannulation attempts, even though a more senior endoscopist takes over cannulation after 5 minutes.

Taken together these findings need to be considered in ERCP teaching and when comparing cannulation studies.

- III. Endoscopic papillectomy is an important treatment option in evaluating and curatively resecting adenomatous neoplastic lesions in the papilla of Vater. The use of KRAS analysis of EP tissue samples needs further investigation.

- IV. Preinterventional evaluation of early ampullary neoplastic lesions is difficult and complex. If no obvious, invasive malignancy is seen on imaging, in order to avoid unnecessary major pancreatic resections:
 - patients with a suspicious ampullary neoplastic lesion should undergo endoscopic examination done with duodenoscopy and tissue samples prior to deciding the definitive treatment strategy.
 - If biopsies show ampullary adenoma, regardless of the grading of dysplasia, patients, ought to be considered for endoscopic papillectomy.
 - Patients where tissue samples show adenocarcinoma should be sent for surgical resection, not to delay definitive treatment or to risk leaving lymph node metastasis behind

7 PROPOSALS FOR FURTHER RESEARCH

- At what level of difficult cannulation is an endoscopist considered proficient? Evaluate the definition of DC in an educational setting. Follow trainees and evaluate the development of the frequency of DC during their training, comparing with a group of expert endoscopists as a reference.
- What auxiliary cannulation techniques are the most appropriate for the different types of papillae? Probably needs to be within a Nation-wide registry to be possible to evaluate.
- Is the endoscopic appearance of the papillae *per se*, an independent risk factor for PEP irrespective of cannulation difficulties? Is there an equal risk for PEP at the same frequency of difficult cannulation among the different papilla types?
- Is cannulation failure more frequent if a fellow endoscopist starts cannulation attempts? Might be possible to answer with a registry-based trial, where the participation of the fellow is defined to make comparisons possible.
- A large multi-center (registry based again) study evaluating the diagnostic accuracy of EUS outside of expert centres.
- A randomized controlled study on the outcome of treatment of intra-ductal extension of adenoma. Radio-frequency ablation compared with PDE. A difficult study that has to be done over a multitude of centers and also carefully considering the ethical aspects.

8 POPULÄRVETENSKAPLIG SAMMANFATTNING

För precis 300 år sedan, år 1720, presenterade Abraham Vater sin avhandling vid Universitetet i Wittenberg rörande gallgångens anatomi, med betoning på den allra sista delen innan gallgången mynnar till tolvfingertarmen. Han beskriver det vidgade parti som oftast finns efter att gallgång och bukspottskörtelgången smält ihop till en gemensam utförsgång precis innanför mynningen till tarmen. Denna del bär hans namn sedan dess, ampulla Vaterii eller Vater's ampull. Ampulla är ett antikt förvaringskärl tillverkat för att förvara olika vätskor, oftast med ett handtag på vardera sida. Vid passagen till tolvfingertarmen befinner sig ampulla Vaterii omsluten av en knopp-liknande bildning som syns från insidan av tarmen och som, till olika grad, buktar ut i tarmen. Denna bildning eller knopp kallad för Papilla Vaterii, "the papilla of Vater" eller "papillen" som man säger i "branschen". Papillen beskrevs inte av Abraham Vater men bär ändå hans namn av lite oklar anledning.

Gallgången och bukspottskörtelgången mynnar vid denna gemensamma öppning till tolvfingertarmen. Dessa gångsystem ska hantera, dels alla leverns utsöndringar, så kallad galla, samt alla de olika kraftfulla matspjälkningsenzym, nödvändiga för näringsupptaget, som utsöndras i bukspottet. Dessa, två av de viktigaste vätskorna för att magtarmkanalen, och därmed kroppen, ska kunna sköta sina funktioner samlade i en mynning. Galla innehåller även olika ämnen som levern renat blodet ifrån och som kroppen behöver göra sig av med. Det för med sig att hinder i gallgången leder snabbt till mycket allvarliga sjukdomstillstånd.

Det finns flera olika sjukdomstillstånd som kan orsaka hinder i utflödet av galla eller bukspott. Det vanligaste är gallstenar, men även olika tumörsjukdomar eller kroniska inflammationer kan också orsaka hinder i gallflödet. Det tydligaste symtomet på hinder i gallflödet är, gulsot, även kallat ikterus. Det finns många olika anledningar till ikterus men bland de vanligare är hinder i gallvägarna.

Genom åren har olika tekniker utvecklats för att diagnosticera och åtgärda hinder i gallvägarna. Från början handlade det mest om olika kirurgiska operationer, men med tiden har titthålsteknik eller endoskopiska tekniker tagit över mer och mer.

Endoskopi är ett samlingsbegrepp för olika metoder för att med böjliga och styrbara slanglika instrument ta sig in genom olika kroppsöppningar och med en kamera i toppen av instrumenten undersöka eller åtgärda olika tillstånd inuti kroppen, exempelvis i magtarmkanalen. En vanlig sådan är endoskopiskt instrument är ett gastroskop.

Sedan den första endoskopiska undersökningen av gallgången, 1968, har den endoskopiska tekniken utvecklats till att bli en helt egen disciplin inom medicinen med fler och fler användningsområden.

Endoskopisk retrograd kolangiopankreatografi, förkortat ERCP, kallas den endoskopiska teknik som kan diagnosticera men framförallt behandla sjukdomstillstånd i gallgång och bukspottskörtelgången. ERCP går till så att man med hjälp av ett specialendoskop, med kamera som ser åt sidan, tar sig förbi magsäcken, ut i tolvfingertarmen ned till i nivå med papillen. Väl på plats vid papillen är nästa steg att försöka föra in olika katetrar med ledare in i den gång man vill behandla, vilket vanligen är gallgången. Att få in katetrarna i rätt gång, så kallad kanylering, kan vara en tekniskt svår manöver, men samtidigt helt nödvändig för att kunna genomföra ERCPn. Manipulationen av papillen och den gemensamma öppningen för gallgång och bukspottskörtelgången i samband med ERCP är inte riskfritt. Bukspottskörteln är ett lättretat organ som innehåller kraftfulla enzymen och det finns en risk att man startar en bukspottskörtelinflammation, en pankreatit, i samband med ERCPn. Pankreatiter är, i detta sammanhang, oftast lindrigt och kräver några dagars extra sjukhusvård, men kan i enstaka fall bli mycket svår och till och med ha dödlig utgång. Det är känt sedan länge att svårigheter vid kanylering av papillen, såsom lång kanyleringstid, många manipulationer med katetrarna på papillen (attempts) och att man

kommer in i bukspottskörtelsgången av misstag med ledare eller kateter, ökar risken för akut bukspottskörtelinflammation, post-ERCP pankreatit (PEP).

I denna avhandling utreds två olika aspekter av förhållanden centrerade kring papilla Vaterii. De första två delarbetena handlar om hur det varierande utseendet hos papilla Vaterii skulle kunna påverka hur svårt det är att genomföra kanylering vid ERCP.

För att sedan i de två sista delarbetena, dels utvärdera endoskopisk operation av tumörer i papilla Vaterii; tumörer som kan vara förstadier till cancer. För att till sist utvärdera den komplicerade utredningen som föregår beslut om antingen kirurgisk operation eller endoskopisk operation av både förstadier till cancer och små concertumörer utgående från ”papillen”.

Utseendet av papillen och gallgångskanylering

Sedan man startade med ERCP i slutet av 1960-talet har det varit diskussion kring hur man ska göra för att kanylera gallgången på bästa vis för att, om möjligt, undvika att patienten får pankreatit. Mängder med olika aspekter har belyst, samt både medicinska och tekniska åtgärder testats med varierande framgång. I beskrivningar av ERCP teknik framhålls ofta att utseendet hos själva papillen, den knopp där gången mynnar, har betydelse för hur svårt det kan vara att kanylera. Det finns dock ingen som har mätt hur svårt, eller ens om det stämmer att det är svårare att kanylera. Det finns heller inte någon standard eller överenskommelse för hur papillen utseende varierar och vilka olika typer av utseende som man kan tänkas vara intressanta.

För att utreda frågan om hur papillens utseende påverkar svårigheter vid gallgångskanylering behövs flera olika pusselbitar. Först behöver man avgöra vad som är att betrakta en svår kanylering, sedan måste man skapa ett ramverk, en klassifikation, för vilka utseenden av papillen som är aktuella. När dessa båda delar är på plats, kan man börja mäta hur kanyleringen fungerar när man som undersökare ställs inför en papill av en speciell typ, med ett speciellt utseende.

Genom ett nordiskt forskningssamarbete inom den skandinaviska endoskopiföreningen (SADE), skapades, 2014, en definition för ”svår kanylering” (difficult cannulation) av gallgången. Resultatet av studien blev, att definitionen för svår kanylering uppfylls om något av dessa tre kriterier uppfylls, om man försöker komma in i gallgången i mer än 5 minuter, manipulerar papillen med katetrar mer än 5 gånger (attempts) eller hamnar med ledare eller kateter i bukspottskörtelsgången mer än 1 gång.

Nästa steg för att besvara frågan om utseendet av papillen påverkar svårigheter vid gallgångskanylering, var att skapa en klassifikation av det endoskopiska utseendet av papillen, som är det första delarbetet i denna avhandling. Viktigt i samband med skapandet av klassifikationer som bygger på olika bedömares åsikter, är att de olika bedömarna är rimligt överens om hur de bedömer det hela. I den första studien skapades först en klassifikation bestående av fyra olika typer av papillutseenden. Vanlig papill, Typ 1, Liten papill, Typ 2, Utbuktande eller nedhängande papill, typ 3 samt Veckad eller fårad papill, typ 4. Dessa skapades utifrån, dels analys av flertalet fotografier av papiller, men även utifrån erfarenhet hos experter inom ERCP.

För att mäta hur väl olika endoskopister, både experter och nybörjare, var överens om vilken typ av papill de såg och kunna avgöra till vilken av de olika typerna som papillen tillhörde, skapades en internetbaserad enkät. I enkäten var det 50 olika papiller, tillhörande de fyra olika fördefinierade typerna, avbildade med fotografier. Enkäten besvarades av 18 olika endoskopister från hela Norden, för att värdera att de var rimligt överens. För att se att de även var överens med sig själva fick det besvara enkäten ytterligare en gång efter 3

månader. Resultatet genomgick statistisk analys och det visade på ”ansenlig” överenskommelse både mot den föreslagna klassifikationen och att endoskopisterna svarade liknande bägge gånger. Därmed var den föreslagna klassifikationen färdig att tas i bruk.

För att mäta i vilken omfattning som det blev ”svår kanylering” för de olika typerna av papillutseende planerades en studie med deltagande kliniker från hela Norden. Studien gick ut på att mäta gallgångskanyleringen (tiden för kanylering, antal försök, och om kateterna kom in i bukspottskörtelgången) samt att i samband med detta avgöra vilken typ av papillutseende som patienten hade. Gallgångskanyleringen mättes på 1401 patienter vid 11 olika sjukhus i Sverige, Finland och Norge. Studien visade att gallgångskanylering oftare blev svår om papillen är Liten eller platt (typ 2) eller Utbuktande eller nedåthängande (typ 3) jämfört med det Vanliga papillutseendet (typ 1). Hur ofta kanyleringen blev svår berodde också på hur erfaren endoskopisten var, samt att om en oerfaren starta att kanylera fanns lite ökad risk att man misslyckades helt med kanyleringen.

Därmed kunde slutsatsen dras att det endoskopiska utseendet av papilla vaterii påverkar hur ofta gallgångskanyleringen blir svår.

Endoskopisk utredning och behandling av tidiga tumörer i papilla vaterii.

En ovanlig orsak till hinder av gallvägarna är tumörer som utgår ifrån själva papillen. Innan det fanns endoskopi upptäcktes dessa nästan aldrig innan de blivit så stora att det inte gick att klargöra var de kom från, men med ökande användning av endoskopi och förbättrad röntgendiagnostik har gjort att det upptäcks små tumörer, och även förstadier till cancer, i papillen. Om det redan är cancer opereras patienterna med en stor operation där halva bukspottskörteln, gallgången och gallblåsa, hela tolvfingertarmen och del av magsäcken tas bort. För att undvika det, har en endoskopisk metod att ta bort förstadier till cancer, så kallade adenom, papilladenom, utvecklats.

I den tredje studien i denna avhandling, utvärderas resultaten av endoskopisk operation (endoskopisk papillektomi, EP) av papilladenom under nästan en 10 års period. Då adenom i papillen är ovanligt, handlar det om få patienter som är aktuella för behandling. I studien inkluderades 36 patienter som genomgick EP för att bli botad från förmodat eller verifierat adenom. EP går till så att man i samband med ERCP, med hjälp av en metalsnara, bränner av själva papillen med tillhörande adenom.

Resultaten från studien visar att metoden är relativt säker, med något fler komplikationer än vid vanlig ERCP, samt att i minst 50% av patienterna kan man undvika stor kirurgisk operation och att de botas med ingreppet. Bland de som inte botas bidrar EP med att säkerställa diagnos på tumören innan operation, då vanliga, små vävnadsprover visade sig ha mycket svårt att avgöra om adenomet redan blivit en cancer. Det visade sig också att flera av de fall som man tolkade som ”snälla” adenom innehöll cancer även om vävnadsprover inför den endoskopiska operationen inte kunde visa på det.

För att gå vidare med den frågan beslutade vi att undersöka samtliga som genomgått både endoskopisk operation (EP) samt den klassiska kirurgiska operationen på grund av tumör i papillen under åren 2006–2018. Det var för att bedöma dels hur utredningen av dessa lite ovanliga patienter gått till samt om man kunde dra några lärdomar utifrån det.

Efter en del letande kunde till sist alla 172 patienter identifieras som kirurgiskt eller endoskopiskt opererats på grund av tumör i papillen där man inte redan såg en stor tumör på röntgen.

Efter att alla journaler och undersökningssvar var genomgångna kunde man identifiera ett par problem som man behöver ta hänsyn till vid utredning av dessa patienter. Det fanns en grupp av patienter som opererades med kirurgisk operation utan att man hade tagit vävnadsprov inför operationen, trots att man inte var helt säker på att det fanns en tumör på

röntgen. Hälften av patienterna hade trots det en cancer men i nästan hälften visade sig att blivit opererade i onödan.

Det fanns även en grupp patienter som gick till kirurgisk operation där vävnadsprover i samband med endoskopisk undersökning visade adenom, ett förstadium till cancer, men ingen säker cancer. Även bland dessa hade cirka hälften cancer efter operationen medans resterande fortsatt hade adenom. De med adenom kunde möjligen ha botats med en endoskopisk operation istället. Av dessa kan man inte säga att de opererades i onödan utan möjligen att de opererades för mycket, men det kan man inte veta säkert i efterhand.

De patienter som opererats där vävnadsprover visat cancer innan hade 44 av 45 cancer. Den sista patienten hade ett stort adenom, förstadium till cancer.

I studien fanns också 76 patienter som opererats med endoskopisk operation, på samma vis som i den förra studien, och utav dessa blev över hälften botade från adenom med hjälp av den endoskopiska operationen. De som inte botades fick en säkerställd diagnos och de som visade sig ha cancer kunde senare opereras men vetskap om att det var rätt att operera dem. Slutsatserna blev att om man misstänker en tumör i papillen bör man försöka ta vävnadsprover innan man beslutar om operation. Visar vävnadsproverna förstadier till cancer, adenom, bör man fundera på om inte försök med endoskopisk operation är det bästa för patienten. Visar vävnadsproverna cancer ska patienten genomgå kirurgisk operation.

9 ACKNOWLEDGEMENTS

To Dr **Urban Arnelo**, my principal supervisor, friend and inspirational guide in so many aspects of life and career. No word can express the impact you had on the way things have turned out over the years. Without your friendship, energy, stamina, guidance, knowledge, tutorship, optimism and always being at the other end of the telephone line this would never had come true and I would not have grown in the way that this journey has made me. Forever grateful.

I also want to thank **Catarina Arnelo** for the positive energy that you have and the welcoming atmosphere that you always spread and for letting me lend Urban all these years.

To my co-supervisor, Prof. **Matthias Löhr**, for making research sound like the most natural thing in the world, always with innovative ideas and wise council.

To my co-supervisor Dr **Kjell-Arne Ung**, for inspiring me that research is a possibility even for a “Country surgeon” and that endoscopy is the most fascinating thing in the world.

Prof. **Lars Lundell**, for friendship, inspiration, assistance, manuscript support and most of all the convincing guidance when all hope had faded, that I could ever finish my PhD.

Dr **Magnus Olsson**, long-time friend, colleague, and now boss. For the never-ending energy to face new challenges with a constructive and positive mind. At the same time always having the time to lend an ear or for an adventure in the forest.

Dr **Bengt Orrenius**, long-time friend and colleague. Your considerate friendship, supportive energy and commitment are always inspirational and heart-warming.

My first mentor Dr **Stefan Modin**, for encouraging me that work as a surgeon was the thing for me and introducing me to much of what I know in both upper GI surgery, endoscopy and life as a surgeon.

Thank you, Dr **Lars Rydberg**, my first ERCP mentor, for introducing the fascinating secrets of ERCP, and showing that friendliness and humor is the strongest force.

Dr **Anders Kylebäck**, Dr **Tomas Manke** and Dr **Åsa Fredriksson**, my ERCP brothers and sister in Skövde. Thank you for always being positive to my sometimes-optimistic ideas and for covering up for me while in have been away.

Also, to Dr **Anna Elmered**, Dr **Christian Kirnö** and Dr **Claes Håkansson** making the Upper GI team in Skövde, a great lineup to be part of.

To Dr **Björn Frisk** for long-time friendship, always having something supportive to say I miss you in the office.

Many thanks to the rest of my **colleagues at the Department of Surgery**, Skaraborg Hospital.

To **Ann-Louise**, **Ulrika**, **Louise** and **Maria** at the endoscopy unit in Skövde. Thank you for always being positive to new ideas and never giving up.

I also wish to thank **Monica Nielsen** and **Annelie Andersson** at the Operation Ward in Skövde, for always helping out and solving all the problems I throw at them, never saying it is impossible.

Andreas Lindgren, my own Medical Engineer. Thank you for all the hours spent with cables and converters to arrange for the possibility to take images for the papilla classification and to have video guidance with Karolinska.

Dr **Rozh Noel**, former research brother. Thank you for all the inspiration and interesting discussions. Now we can start our own projects!

Thank you, Dr **Fredrik Swahn**, for friendship, inspiration and support during the ERCP-fellowship and beyond. I crossed the Atlantic! And for the fantastic drawings.

Leena Kylänpää, friend and inspirational icon. The Nordic Queen of ERCP, among the brightest, still always so kind and welcoming.

To the rest of the SADE research group of ERCP for the patience, friendship, and for being so supportive with the cannulation study. Prof **Juha Grönroos**, Dr **Arto Saarela**, Dr **Truls Hauge**, Dr **Gunnar Qvigstad**, Dr **Ervin Toth**, Dr **Per Ejstrud**

And, also to Dr **Riadh Sadik** for your friendship and kind help including patients in the cannulation study.

Dr **Mari Hult**, Dr **Roberto Valente**, Dr **Per Bergenzaum** and Dr **Niklas Fagerström** for letting me be a small part of the endosurgical team at Karolinska.

To **Inger and the team at the ERCP unit** Karolinska for being so supportive over the years taking care of the “Erik Studien” and my when I make my visits.

To **Caroline Verbeke**, for working on the histopathological diagnostics of the papillectomy specimen in Paper I.

Annika Wagman and Dr **Reiner Heuchler** for your kind patience during my stumbling work in the Lab trying to get the hang of DNA extraction and KRAS analysis.

To the **Research and Development unit at Skaraborg Hospital** for all the endless support during all these years. Thank you!

Thank you, **Hélène Jansson** for all the help over the years and especially during the last months, getting all the paperwork and arrangements in order.

To **Christina Gustafsson**, for always being a lifeline to hold on to when in need of administrative support, advice and desperate proof-reading.

I also want to thank **Christel Nilsson**, my former lifeline at K42, Karolinska. I haven't forgotten!

Dr **Asif Halimi**, Dr **Elena Rangelova**, Dr **Hasan Ahmad Al-Saffar** and Dr **Laura Zarantonello** at Karolinska Huddinge, for help with constructive input and lots of data to Paper IV.

But above of all;

I want to thank **Lars and Irene Haraldsson**, my beloved parents, for always being supportive and caring. Never doubting that I made the right choices in life and always there when you need them.

A special thank you to **Emil Haraldsson** my dear brother, and also my major sponsor. Together with **Lill**, letting me occupy your home during my fellowship and all the long years of PhD studies. Always welcoming and considerate. Without your unending support this journey had never even begun. A special thanks to **Hampus, Melker and Selma** for making the evenings at your house full of life and necessary distraction.

To **Jonatan, David and Junis**, my not so small children. My everything in this world. It is a privilege to be part of your life. I love You All!

Finally, to **Maria** my beautiful wife. Enormous amounts of gratitude and unending love! Without your patience, love and infinite support, I would have been a lesser man.
I Love You!

10 REFERENCES

- Adler DG (2018) Guidewire cannulation in ERCP: from zero to hero! *Gastrointest Endosc* 87:202–204.
- Adsay V, Mino-Kenudson M, Furukawa T, et al (2016) Pathologic Evaluation and Reporting of Intraductal Papillary Mucinous Neoplasms of the Pancreas and Other Tumoral Intraepithelial Neoplasms of Pancreatobiliary Tract. *Ann Surg* 263:162–177.
- Adsay V, Ohike N, Tajiri T, et al (2012a) Ampullary Region Carcinomas. *Am J Surg Pathol* 36:1592–1608.
- Adsay VN, Bagci P, Tajiri T, et al (2012b) Pathologic staging of pancreatic, ampullary, biliary, and gallbladder cancers: pitfalls and practical limitations of the current AJCC/UICC TNM staging system and opportunities for improvement. *Semin Diagn Pathol* 29:127–141.
- Afghani E, Akshintala VS, Khashab MA, et al (2014) 5-Fr vs. 3-Fr pancreatic stents for the prevention of post-ERCP pancreatitis in high-risk patients: a systematic review and network meta-analysis. *Endoscopy* 46:573–80.
- Alessandrino F, Ivanovic AM, Yee EU, et al (2015) MDCT and MRI of the ampulla of Vater (part I): technique optimization, normal anatomy, and epithelial neoplasms. *Abdom Imaging* 40:3274–3291.
- Allard FD, Goldsmith JD, Ayata G, et al (2018) Intraobserver and Interobserver Variability in the Assessment of Dysplasia in Ampullary Mucosal Biopsies. *Am J Surg Pathol* 42:1095–1100.
- Alvarez-Sánchez M-V, Napoleon B (2016) EUS and ampullary adenoma: Why? When? *Endosc Int Open* 4:E1319–E1321.
- Alvarez-Sanchez M-V, Oria I, Luna OB, et al (2017) Can endoscopic papillectomy be curative for early ampullary adenocarcinoma of the ampulla of Vater? *Surg Endosc* 31(4):1564-1572
- Amin M.B., Edge S.B., Greene F.L., et al. (2017) *AJCC Cancer Staging Manual* (8th ed.), Springer, New York
- Amiri A, Miura JT, Jayakrishnan TT, et al (2015) Is local resection adequate for T1 stage ampullary cancer? *HPB(Oxford)* 17:66–71.
- Andersson M, Kostic S, Johansson M, et al (2004) MRI combined with MR cholangiopancreatography versus helical CT in the evaluation of patients with suspected periampullary tumors: a prospective comparative study. *Acta Radiol* 46:16–27.
- Anderson MA, Fisher L, Jain R, et al. (2012) Complications of ERCP. *Gastrointest Endosc* 75:467–473.
- Andriulli A, Loperfido S, Napolitano G, et al (2007) Incidence Rates of Post-ERCP Complications: A Systematic Survey of Prospective Studies. *Am J Gastroenterol* 102(8):1781-88
- Ang DC, Shia J, Tang LH, et al (2014) The Utility of Immunohistochemistry in Subtyping Adenocarcinoma of the Ampulla of Vater. *Am J Surg Pathol* 38(10):1371–1379.
- Anghong W, Jiarakoo K, Tangtiang K (2018) Differentiation of benign and malignant ampullary obstruction by multi-row detector CT. *Jpn J Radiol* 36:477–488.
- Ardengh J, Kemp R, Lima-Filho É, dos Santos J (2015) Endoscopic papillectomy: The limits of the indication, technique and results. *World J Gastrointest Endosc* 7:987–994.
- Armstrong D, Bennett J, Blum A, et al (1996) The endoscopic assessment of esophagitis: A progress report on observer agreement. *Gastroenterology* 111:85–92.
- Arnelo U, Siiki A, Swahn F, et al (2014) Single-operator pancreatoscopy is helpful in the evaluation of suspected intraductal papillary mucinous neoplasms (IPMN). *Pancreatology* 14:510–514.
- Arrington AK, Heinrich EL, Lee W, et al (2012) Prognostic and Predictive Roles of KRAS Mutation in Colorectal Cancer. *Int J Mol Sci* 13:12153–68.
- Artifon E, Marson FP, Gaidhane M, et al (2015) Hepaticogastrostomy or choledochoduodenostomy for distal malignant biliary obstruction after failed ERCP: Is there any difference? *Gastrointest Endosc* 81:950–959.
- Asfeldt A, Straume B, Paulssen EJ (2009) Impact of observer variability on the usefulness of endoscopic images for the documentation of upper gastrointestinal endoscopy. *Scand J Gastroentero* 42:1106–1112.

- Asbun H., Conlon, K., Fernandez-Cruz, L et al. (2014). When to perform a pancreatoduodenectomy in the absence of positive histology? A consensus statement by the International Study Group of Pancreatic Surgery. *Surgery* 155(5), 887-892.
- Askew J, Connor S (2013) Review of the investigation and surgical management of resectable ampullary adenocarcinoma. *HPB(Oxford)* 15(11):829–838.
- Avisse C, Flament J-B, Delattre J-F (2000) Ampulla of Vater. Anatomic, Embryologic, and Surgical Aspects. *Surg Clin N Am* 80:201–212.
- Baczako K, Büchler M, Beger H-G, et al (1985) Morphogenesis and possible precursor lesions of invasive carcinoma of the papilla of Vater: Epithelial dysplasia and adenoma. *Hum Pathol* 16:305–310.
- Bakman Y, Safdar K, Freeman M (2009) Significant clinical implications of prophylactic pancreatic stent placement in previously normal pancreatic ducts. *Endoscopy* 41:1095–1098.
- Bakman YG, Freeman ML (2013) Difficult Biliary Access at ERCP. *Gastrointest Endosc Clin North Am* 23:219–236.
- Banks PA, Bollen TL, Dervenis C, et al (2013) Classification of acute pancreatitis—2012: revision of the Atlanta classification and definitions by international consensus. *Gut* 62(1):102-11.
- Barber KW, ReMine WH, Harrison EG, Priestley J (1960) Benign Neoplasms of Extrahepatic Bile Ducts, Including Papilla of Vater. *Arch Surg* 81:479–484.
- Barrie M, Klein S, Brown C, et al (2006) Endoscopic Retrograde Cholangiopancreatography after a Liquid Fatty Meal: Effect on Deep Common Bile Duct Cannulation Time. *Endoscopy* 38:241–248.
- Beger HG, Treitschke F, Gansauge F, et al (1999) Tumor of the Ampulla of Vater: Experience With Local or Radical Resection in 171 Consecutively Treated Patients. *Arch Surg* 134:526–532.
- Bendtsen F, Skovgaard L, Sørensen TI, Matzen P (1990) Agreement among multiple observers on endoscopic diagnosis of esophageal varices before bleeding. *Hepatology* 11:341–347.
- Berry R, Han JY, Tabibian JH (2019) Difficult biliary cannulation: Historical perspective, practical updates, and guide for the endoscopist. *World J Gastrointest Endosc* 11:5–21.
- Berzin TM, Sanaka S, Barnett SR, et al (2011) A prospective assessment of sedation-related adverse events and patient and endoscopist satisfaction in ERCP with anesthesiologist-administered sedation. *Gastrointest Endosc* 73:710–717.
- Bill JG, Darcy M, Fujii-Lau LL, et al (2016) A comparison between endoscopic ultrasound-guided rendezvous and percutaneous biliary drainage after failed ERCP for malignant distal biliary obstruction. *Endosc Int Open* 4:E980-5.
- Binmoeller KF, Boaventura S, Ramsperger K, Soehendra N (1993) Endoscopic snare excision of benign adenomas of the papilla of Vater. *Gastrointest Endosc* 39:127–131.
- Birnbaum D, Gaujoux S, Berbis J, et al (2017) Surgery for pancreatic neoplasms: How accurate are our surgical indications? *Surgery* 162:112–119.
- Bohnacker, S., Seitz, U., Nguyen, D., et al. (2005). Endoscopic resection of benign tumors of the duodenal papilla without and with intraductal growth. *Gastrointest Endosc* 62(4), 551-560.
- Bourgeois N, Dunham F, Verhest A (1984) Endoscopic biopsies of the papilla of Vater at the time of endoscopic sphincterotomy: difficulties in interpretation. *Gastrointest Endosc* 30:163–166.
- Bourke M, Costamagna G, Freeman M (2009) Biliary cannulation during endoscopic retrograde cholangiopancreatography: core technique and recent innovations. *Endoscopy* 41:612–617.
- Buxbaum J, Leonor P, Tung J, et al (2016) Randomized Trial of Endoscopist-Controlled vs. Assistant-Controlled Wire-Guided Cannulation of the Bile Duct. *Am J Gastroenterology* 111:1841.
- Cameron JL, He J (2015) Two Thousand Consecutive Pancreaticoduodenectomies. *J Am Coll Surgeons* 220:530–536.
- Camus M, Napoléon B, Vienne A, et al (2018) Efficacy and safety of endobiliary radiofrequency ablation for the eradication of residual neoplasia after endoscopic papillectomy : a multicenter prospective study. *Gastrointest Endosc* 88:511–518.
- Catalano MF, Linder JD, Chak A, et al (2004) Endoscopic management of adenoma of the major duodenal papilla. *Gastrointest Endosc* 59:225–232.
- Ceppa EP, Burbridge RA, Rialon KL, et al (2013) Endoscopic Versus Surgical Ampullectomy. *Ann Surg* 257:315–322.

- Cha S-W, Leung WD, Lehman GA, et al (2013) Does leaving a main pancreatic duct stent in place reduce the incidence of precut biliary sphincterotomy-associated pancreatitis? A randomized, prospective study. *Gastrointest Endosc* 77:209–216.
- Chandrasekhara V, Khashab MA, Muthusamy R, et al (2017) Adverse events associated with ERCP. *Gastrointest Endosc* 85:32–47.
- Chang CP, Ng WW, Tsay SH, et al (1990) Differential diagnosis of tumor-like appearance of the papilla of Vater. *Gastrointest Endosc* 36:635–636
- Chang DK, Jamieson NB, Johns AL, et al (2013) Histomolecular Phenotypes and Outcome in Adenocarcinoma of the Ampulla of Vater. *J Clin Oncol* 31:1348–1356.
- Chapman BC, Gleisner A, Ibrahim-Zada I, et al (2018) Laparoscopic pancreaticoduodenectomy: changing the management of ampullary neoplasms. *Surgical Endoscopy* 32:915–922.
- Chathadi KV, Khashab MA, Acosta D, et al (2015) The role of endoscopy in ampullary and duodenal adenomas. *Gastrointest Endosc* 82:773–781.
- Chen C, Yang C, Yeh Y, et al (2009) Reappraisal of endosonography of ampullary tumors: Correlation with transabdominal sonography, CT, and MRI. *J Clin Ultrasound* 37:18–25.
- Chen J, Wan J, Wu D, et al (2018) Assessing Quality of Precut Sphincterotomy in Patients With Difficult Biliary Access. *J Clin Gastroenterol* 52:573–578.
- Chen J-J, Wang X-M, Liu X-Q, et al (2014) Risk factors for post-ERCP pancreatitis: a systematic review of clinical trials with a large sample size in the past 10 years. *Eur J Med Res* 19:26.
- Chen KT, Devarajan K, Hoffman JP (2015) Morbidity Among Long-Term Survivors After Pancreatoduodenectomy for Pancreatic Adenocarcinoma. *Ann Surg Oncol* 22:1185–1189.
- Cheng C-L, Sherman S, Watkins JL, et al (2006) Risk Factors for Post-ERCP Pancreatitis: A Prospective Multicenter Study. *Am J Gastroenterol* 101:139–147.
- del Chiaro M, Beckman R, Ateeb Z, et al (2019) Main Duct Dilatation Is the Best Predictor of High-grade Dysplasia or Invasion in Intraductal Papillary Mucinous Neoplasms of the Pancreas. *Ann Surg*. (Jan 18, 2019 Epub ahead of print)
- Chini P, Draganov PV (2011) Diagnosis and management of ampullary adenoma: The expanding role of endoscopy. *World J Gastrointest Endosc* 3:241–247.
- Chung C, Wilentz R, Polak M, et al (1996) Clinical significance of K-ras oncogene activation in ampullary neoplasms. *J Clin Pathol* 49:460–464.
- Classen M, Demling L (1974) Endoskopische Sphinkterotomie der Papilla Vateri und Steinextraktion aus dem Ductus choledochus. *Dtsch Med Wochenschr* 99(11):496–497.
- Clavien PA, Strasberg SM (2009) Severity Grading of Surgical Complications. *Ann Surg* 250:197–198.
- Cohen J (1960) A Coefficient of Agreement for Nominal Scales. *Educ Psychol Meas* 20:37–46.
- Cohen J, Sawhney MS, Pleskow DK, et al (2014) Double-Duct Sign in the Era of Endoscopic Ultrasound: The Prevalence of Occult Pancreaticobiliary Malignancy. *Digest Dis Sci* 59:2280–2285.
- Colussi O, Voron T, Pozet A, et al (2015) Prognostic score for recurrence after Whipple’s pancreaticoduodenectomy for ampullary carcinomas; results of an AGEO retrospective multicenter cohort. *European J Surg Oncol* 41:520–526.
- Cotton P, Blumgart L, Davies G, et al (1972) Cannulation of papilla of vater via fiber-duodenoscope. Assessment of retrograde cholangiopancreatography in 60 patients. *Lancet* 1(7741):53–8
- Cotton PB (1972) Cannulation of the papilla of Vater by endoscopy and retrograde cholangiopancreatography (ERCP). *Gut* 13:1014–1025.
- Cotton PB, Garrow DA, Gallagher J, et al.(2009) Risk factors for complications after ERCP: a multivariate analysis of 11,497 procedures over 12 years. *Gastrointest Endosc* 70:80–88.
- Cotton PB, Lehman G, Vennes J, et al (1991) Endoscopic sphincterotomy complications and their management: an attempt at consensus. *Gastrointest Endosc* 37:383–393.
- Cubilla A, Fitzgerald P (1980) Surgical pathology aspects of cancer of the ampulla-head-of-pancreas region. *Monogr Pathology* 21:67–81
- Curvers W, Bohmer C, Mallant-Hent R, et al (2008) Mucosal morphology in Barrett’s esophagus: interobserver agreement and role of narrow band imaging. *Endoscopy* 40:799–805.
- Dacha S, Chawla S, Lee J, et al (2017) Endoscopic retrograde cholangiopancreatography with ampullary biopsy vs ERCP alone: a matched-pairs controlled evaluation of outcomes and complications. *Gastroenterol Rep*. 5(4):277-281.

- de Castro S, van Eijck C, Rutten J, et al (2008) Pancreas-preserving total duodenectomy versus standard pancreatoduodenectomy for patients with familial adenomatous polyposis and polyps in the duodenum. *Brit J Surg* 95:1380–1386.
- de Sanctis C, Tagliaferri G (1968) Ampullary biopsy. A critical appraisal based on a histological study of the normal papilla of Vater. *Brit J Surg* 55:250–255.
- Demling L, Classen M, Koch H (1972) [Enteroscopy with retrograde demonstration of the pancreatic and biliary ducts]. *Dtsch Z Verdau Stoffwechselkr* 32(1):149–52
- Devereaux B, Lehman GA, Fein S, et al (2002) Facilitation of pancreatic duct cannulation using a new synthetic porcine secretin. *Am J Gastroenterology* 97:2279–81.
- DeOliveira ML, Triviño T, de Filho GJL (2006) Carcinoma of the Papilla of Vater: Are Endoscopic Appearance and Endoscopic Biopsy Discordant? *J Gastrointest Surg* 10:1140–1143.
- Deslandres E, Gagner M, Pomp A, et al (1993) Intraoperative endoscopic sphincterotomy for common bile duct stones during laparoscopic cholecystectomy. *Gastrointest Endosc* 39:54–58.
- Dhall D, Guindi M, Mertens R, Chopra S (2015) Early neoplasms of the ampulla and intrapancreatic biliary tract. *Diagn Histopathol* 21:332–339.
- Dimagno EP, Shorter RG, Taylor WF, Go VW (1982) Relationships between pancreaticobiliary ductal anatomy and pancreatic ductal and parenchymal histology. *Cancer* 49(2):361–368.
- Ding J, Jin X, Pan Y, et al (2013) Glyceryl Trinitrate for Prevention of Post-ERCP Pancreatitis and Improve the Rate of Cannulation: A Meta-Analysis of Prospective, Randomized, Controlled Trials. *Plos One.* ;8(10):e75645
- Ding X, Zhang F, Wang Y (2015) Risk factors for post-ERCP pancreatitis: A systematic review and meta-analysis. *Surg* 13:218–229.
- Doepker MP, Thompson ZJ, Centeno BA, et al (2016) Clinicopathologic and survival analysis of resected ampullary adenocarcinoma. *J Surg Oncol* 114:170–175.
- Dowdy GS, Waldron GW, Brown WG (1962) Surgical Anatomy of the Pancreatobiliary Ductal System: Observations. *Arch Surg-Chicago* 84:229–246.
- Downs-Canner S, der Vliet WJ, Thoolen SJ, et al (2015) Robotic Surgery for Benign Duodenal Tumors. *J Gastrointest Surg* 19:306–312.
- Dowsett JF, Vaira D, Hatfield ARW, et al (1989) Endoscopic biliary therapy using the combined percutaneous and endoscopic technique. *Gastroenterology* 96:1180–1186.
- Dreyer SB, Jamieson NB, Evers L, et al (2019) Feasibility and clinical utility of endoscopic ultrasound guided biopsy of pancreatic cancer for next-generation molecular profiling. *Chin Clin Oncol* 8(2):16.
- Dultz G, Gerber L, Zeuzem S, et al (2018) Prolonged retention of prophylactic pancreatic stents is not associated with increased complications. *Pancreatology* 19:39–43.
- Dumonceau J-M, Andriulli A, Elmunzer JB, et al (2014) Prophylaxis of post-ERCP pancreatitis: European Society of Gastrointestinal Endoscopy (ESGE) Guideline – Updated June 2014. *Endoscopy* 46:799–815.
- Edge S.B., Byrd D.R., Compton C.C., et al (2009) *AJCC Cancer Staging Manual (7th ed.)*, Springer, New York, NY
- Ekkelenkamp V, de Man R, ter Borg F, et al (2015) Prospective evaluation of ERCP performance: results of a nationwide quality registry. *Endoscopy* 47:503–507.
- Elek G, Gyôri S, Tóth B, Pap Á (2003) Histological evaluation of preoperative biopsies from ampulla Vateri. *Pathology Oncol Res* 9:32–41.
- Elmunzer JB, Scheiman J, Lehman GA, et al (2012) A Randomized Trial of Rectal Indomethacin to Prevent Post-ERCP Pancreatitis. *New Engl J Medicine* 366:1414–1422.
- Enochsson L, Swahn F, Arnelo U, et al (2010) Nationwide, population-based data from 11,074 ERCP procedures from the Swedish Registry for Gallstone Surgery and ERCP. *Gastrointest Endosc* 72:1175-1184.
- Espinel J (2015) Endoscopic management of adenomatous ampullary lesions. *World Journal of Methodology* 26;5(3): 127–35.
- Esposito I, Friess H, Büchler MW (2001) Carcinogenesis of cancer of the papilla and ampulla: pathophysiological facts and molecular biological mechanisms. *Langenbeck's Archives Surg* 386:163–171.
- Fang J, Wang S, Zhao S, et al (2018) Impact of intraduodenal acetic acid infusion on pancreatic duct cannulation during endoscopic retrograde cholangiopancreatography: A double-blind, randomized controlled trial. *J Gastroenterol Hepatol* 33:1804–1810.

- Faulx AL, Lightdale JR, Acosta D, et al (2017) Guidelines for privileging, credentialing, and proctoring to perform GI endoscopy. *Gastrointest Endosc* 85:273–281.
- Fischer H-P, Zhou H (2004) Pathogenesis of carcinoma of the papilla of Vater. *J Hepatobiliary Pancreat Surg* 11(5):301–309.
- Flati G, Andrén-Sandberg Å (2002) Wirsung and Santorini: the men behind the ducts. *Pancreatology* 2:4–11
- Flati G, Flati D, Porowska B, et al (1994) Surgical anatomy of the papilla of Vater and biliopancreatic ducts. *Am Surg* 60:712–718
- Freeman M, Nelson D, Sherman S, et al (1996) Complications of endoscopic biliary sphincterotomy. *The New England journal of medicine* 335:909–18.
- Freeman ML, DiSario JA, Nelson DB, et al (2001) Risk factors for post-ERCP pancreatitis: A prospective, multicenter study. *Gastrointest Endosc* 54:425–434.
- Freeman ML, Guda NM (2005) ERCP cannulation: a review of reported techniques. *Gastrointest Endosc* 61:112–125
- Frierson HF (1989) The Gross Anatomy and Histology of the Gallbladder, Extrahepatic Bile Ducts, Vaterian System, and Minor Papilla. *Am J Surg Pathology* 13:146–162.
- Gaspar J, Shami VM (2015) The role of EUS in ampullary lesions: Is the answer black and white? *Gastrointest Endosc* 81:389–390.
- Geier A, Nguyen H, Gartung C, Matern S (2000) MRCP and ERCP to detect small ampullary carcinoma. *Lancet* 356:1607–1608.
- Hacihanoglu E, Memis B, Pehlivanoglu B, et al (2018) Factors Impacting the Performance Characteristics of Bile Duct Brushings: A Clinico-Cytopathologic Analysis of 253 Patients. *Archives of Pathology & Laboratory Medicine*.
- Halsted W (1899) Contributions to the Surgery of the Bile Passages, Especially of the Common Bile-Duct. *New Engl J Medicine* 141:645–654.
- Halttunen J, Meisner S, Aabakken L, et al (2014) Difficult cannulation as defined by a prospective study of the Scandinavian Association for Digestive Endoscopy (SADE) in 907 ERCPs. *Scand J gastroenterol* 49:752–758.
- Hand B (1963) An anatomical study of the choledochoduodenal area. *Brit J Surg* 50:486–494.
- Harewood GC, Pochron NL, Gostout CJ (2005) Prospective, randomized, controlled trial of prophylactic pancreatic stent placement for endoscopic snare excision of the duodenal ampulla. *Gastrointest Endosc* 62:367–370.
- Harthimmer, M., Stolborg, U., Pfeiffer, P. et al. (2019). Mutational profiling and immunohistochemical analysis of a surgical series of ampullary carcinomas. *Journal of Clinical Pathology* 72(11), 762.
- Hata T, Motoi F, Ishida M, et al (2016) Effect of Hospital Volume on Surgical Outcomes After Pancreaticoduodenectomy. *Ann Surg* 263:664–672.
- Hawes RH, Devière J (2018) How I cannulate the bile duct. *Gastrointest Endosc* 87:1–3.
- He J, Ahuja N, Makary MA, et al (2014) 2564 resected periampullary adenocarcinomas at a single institution: trends over three decades. *HPB(Oxford)* 16(1):83–90.
- He X, Zheng W, Ding Y, et al (2018) Rectal Indomethacin Is Protective against Pancreatitis after Endoscopic Retrograde Cholangiopancreatography: Systematic Review and Meta-Analysis. *Gastroent Res Pract* 2018:9784841.
- Heidecke C-D, Robert R, Bauer M, et al (2002) Impact of grade of dysplasia in villous adenomas of Vater’s papilla. *World J Surg* 26:709–714.
- Hirano I, Moy N, Heckman MG, et al (2013) Endoscopic assessment of the oesophageal features of eosinophilic oesophagitis: validation of a novel classification and grading system. *Gut* 62:489–495.
- Hirschowitz B (1961) Endoscopic examination of the stomach and duodenal cap with the fiberscope. *Lancet* 277:1074–1078.
- Hong S, Song K, Lee Y-J, et al (2018) Transduodenal ampullectomy for ampullary tumors – single center experience of consecutive 26 patients. *Ann Surg Treat Res* 95:22–28.
- Horiguchi S, Kamisawa T (2010) Major Duodenal Papilla and Its Normal Anatomy. *Digest Surg* 27:90–93.
- Horiuchi A, Nakayama Y, Kajiyama M, Tanaka N (2007) Effect of Precut Sphincterotomy on Biliary Cannulation Based on the Characteristics of the Major Duodenal Papilla. *Clin Gastroenterol Hepatol* 5(9):1113–1118.

- Hornick JR, Johnston FM, Simon PO, et al (2011) A single-institution review of 157 patients presenting with benign and malignant tumors of the ampulla of Vater: Management and outcomes. *Surgery* 150:169–176.
- Huang L, Yu Q, Zhang Q, et al (2015) Double-guidewire technique. *Digest Endosc* 27:381–387.
- Hyun J, Lee T, Park J-S, et al (2017) A prospective multicenter study of submucosal injection to improve endoscopic snare papillectomy for ampullary adenoma. *Gastrointest Endosc* 85:746–755.
- Hyvärinen I, Hukkinen M, Kivisaari R, et al (2019) Increased Prevalence of Pancreaticobiliary Maljunction in Biliary Malignancies. *Scand J Surg*. 108(4):285-290
- Imamura T, Yamamoto Y, Sugiura T, et al (2019) The Prognostic Relevance of the New 8th Edition of the Union for International Cancer Control Classification of TNM Staging for Ampulla of Vater Carcinoma. *Ann Surg Oncol* 26:1639–1648.
- Irani S, Arai A, Ayub K, et al (2009) Papillectomy for ampullary neoplasm: results of a single referral center over a 10-year period. *Gastrointest Endosc* 70:923–932.
- Ismail S, Udd M, Lindström O, et al (2019) Criteria for difficult biliary cannulation: start to count. *Eur J Gastroenterol Hepatol* 31(10):1200-1205
- Ito K, Fujita N, Noda Y, et al (2007) Preoperative evaluation of ampullary neoplasm with EUS and transpapillary intraductal US: a prospective and histopathologically controlled study. *Gastrointest Endosc* 66:740–747.
- Ito K, Fujita N, Noda Y, et al (2010) Diagnosis of Ampullary Cancer. *Digest Surg* 27:115–118.
- Iwashita T, Lee J, Shinoura S, et al (2011) Endoscopic ultrasound-guided rendezvous for biliary access after failed cannulation. *Endoscopy* 44:60–65.
- Jailwala J, Fogel EL, Sherman S, et al (2000) Triple-tissue sampling at ERCP in malignant biliary obstruction. *Gastrointest Endosc* 51:383–390.
- Jones M, Necas M (2018) The performance of ultrasound in determining the cause of biliary dilation. *Sonogr* 5:174–180.
- Jowell P, Baillie J, Branch M, et al (1996) Quantitative Assessment of Procedural Competence: A Prospective Study of Training in Endoscopic Retrograde Cholangiopancreatography. *Ann Intern Med* 125:983–989
- Jayaramayya, K., Balachandar, V., Santhy, K. (2018). Ampullary carcinoma-A genetic perspective. *Mutat Res* 776:10-22.
- Kaiser A, Jurowich C, Schönekäs H, et al (2002) The Adenoma-Carcinoma Sequence Applies to Epithelial Tumours of the Papilla of Vater. *Zeitschrift Für Gastroenterologie* 40:913–920.
- Kakar S., Shi C., Adsay V., et al. (2017). Protocol for the Examination of Specimens From Patients With Carcinoma of the Ampulla of Vater In: Cancer Protocol Templates. College of American Pathologists (CAP). Available at: <https://documents.cap.org/protocols/cp-ampulla-17protocol-4000.pdf> Accessed Nov 28 2019
- Kalloor AN, Pasricha PJ (1995) Effect of gastric distension and duodenal fat infusion on biliary sphincter of Oddi motility in healthy volunteers. *Digest Dis Sci* 40:745–748.
- Kamal A, Akshintala VS, Talukdar R, et al (2019) A Randomized Trial of Topical Epinephrine and Rectal Indomethacin for Preventing Post-Endoscopic Retrograde Cholangiopancreatography Pancreatitis in High-Risk Patients. *Am J Gastroenterology* 114:339–347.
- Kamisawa T, Amemiya K, Tu Y, et al (2002) Clinical Significance of a Long Common Channel. *Pancreatology* 2:122–128.
- Kamisawa T, Ando H, Hamada Y, et al (2014) Diagnostic criteria for pancreaticobiliary maljunction 2013. *J Hepatobiliary Pancreat Sci* 21(3):159–161.
- Kamisawa T, Ando H, Suyama M, et al (2012) Japanese clinical practice guidelines for pancreaticobiliary maljunction. *J Gastroenterol* 47:731–759.
- Kamisawa T, Kaneko K, Itoi T, Ando H (2017a) Pancreaticobiliary maljunction and congenital biliary dilatation. *Lancet Gastroenterology Hepatology* 2:610–618.
- Kamisawa T, Kuruma S, Chiba K, et al (2017b) Biliary carcinogenesis in pancreaticobiliary maljunction. *J Gastroenterol* 52:158–163.
- Kamisawa T, Kuruma S, Tabata T, et al (2015) Pancreaticobiliary maljunction and biliary cancer. *J Gastroenterol* 50:273–279.
- Kandler J, Neuhaus H (2018) How to Approach a Patient with Ampullary Lesion. *Gastroenterology* 155:1670–1676.

- Katsinelos P, Gkagkalis S, Chatzimavroudis G, et al (2012) Comparison of Three Types of Precut Technique to Achieve Common Bile Duct Cannulation: A Retrospective Analysis of 274 Cases. *Digestive Dis Sci* 57(12):3286–3292.
- Katsinelos P, Lazaraki G, Chatzimavroudis G, et al (2015) The endoscopic morphology of major papillae influences the selected precut technique for biliary access. *Gastrointest Endosc* 81:1056.
- Kawai K, Akasaka Y, Murakami K, et al (1974) Endoscopic sphincterotomy of the ampulla of Vater. *Gastrointest Endosc* 20:148–151.
- Kher K, Guelrud M (2004) Normal sphincter of Oddi motor function. *Curr Gastroenterol Rep* 6:163–168.
- Kim, M., Jang, M., Kim, H., et al. (2019). Distinct immunological properties of the two histological subtypes of adenocarcinoma of the ampulla of Vater. *Cancer Immunol, Immunother* 68(3), 443-454.
- Kim S, An S, Kang H, et al (2018) Validation of the eighth edition of the American Joint Committee on Cancer staging system for ampulla of Vater cancer. *Surgery* 163:1071–1079.
- Kim T, Kim S, Lee J, et al (2008) Ampulla of Vater: Comprehensive anatomy, MR imaging of pathologic conditions, and correlation with endoscopy. *European Journal of Radiology* 66:48–64.
- Kimura W, Futakawa N, Yamagata S, et al (1994) Different Clinicopathologic Findings in Two Histologic Types of Carcinoma of Papilla of Vater. *Jpn J Cancer Res* 85:161–166.
- Kipp BR, Fritcher EG, Clayton AC, et al (2010) Comparison of KRAS Mutation Analysis and FISH for Detecting Pancreatobiliary Tract Cancer in Cytology Specimens Collected During Endoscopic Retrograde Cholangiopancreatography. *J Mol Diagnostics* 12:780–786.
- Klein A, Ahlenstiel G, Tate DJ, et al (2017) Endoscopic resection of large duodenal and papillary lateral spreading lesions is clinically and economically advantageous compared with surgery. *Endoscopy* 49:659–667
- Klein A, Qi Z, Bahin FF, et al (2018) Outcomes after endoscopic resection of large laterally spreading lesions of the papilla and conventional ampullary adenomas are equivalent. *Endoscopy* 50:972–983.
- Kochar B, Akshintala VS, Afghani E, et al (2015) Incidence, severity, and mortality of post-ERCP pancreatitis: a systematic review by using randomized, controlled trials. *Gastrointest Endosc* 81:143-149.e9.
- Kozuka S, Tsubone M, Yamaguchi A, Hachisuka K (1981) Adenomatous residue in cancerous papilla of Vater. *Gut* 22:1031.
- Krishnamurthy K, Sriganeshan V (2019) Pancreatic Intraepithelial Neoplasia (PanIN) as a Morphologic Marker of Pancreatobiliary Type of Ampullary Carcinoma. *Pathol Oncol Res* (Oct 22 2019, epub ahead of print)
- Kubota K, Iida H, Fujisawa T, et al (2007) Clinical Significance of Swollen Duodenal Papilla in Autoimmune Pancreatitis. *Pancreas* 35:e51–e60.
- Kubota K, Kato S, Akiyama T, et al (2008) Differentiating sclerosing cholangitis caused by autoimmune pancreatitis and primary sclerosing cholangitis according to endoscopic duodenal papillary features. *Gastrointest Endosc* 68:1204–1208.
- Kushnir, V., Mullady, D., Das, K., et al. (2019). The Diagnostic Yield of Malignancy Comparing Cytology, FISH, and Molecular Analysis of Cell Free Cytology Brush Supernatant in Patients With Biliary Strictures Undergoing Endoscopic Retrograde Cholangiography (ERC): A Prospective Study. *J Clin Gastroenterol* 53(9), 686-692.
- Laleman W, Verreth A, Topal B, et al (2013) Endoscopic resection of ampullary lesions: a single-center 8-year retrospective cohort study of 91 patients with long-term follow-up. *Surg Endosc* 27:3865–3876.
- Lambert R, Ponchon T, Chavaillon A, Berger F (1988) Laser Treatment of Tumors of the Papilla of Vater. *Endoscopy* 20:227–231.
- Landis J, Koch G (1977) The Measurement of Observer Agreement for Categorical Data. *Biometrics* 33:159–174.
- Layfield LJ, Ehya H, Filie AC, et al (2014) Utilization of ancillary studies in the cytologic diagnosis of biliary and pancreatic lesions: The Papanicolaou Society of Cytopathology guidelines for pancreatobiliary cytology. *Diagnostic Cytopathology* 42:351–362.
- Lee H, Cho C-M, Heo J, et al (2019a) Impact of Hospital Volume and the Experience of the Endoscopist on Adverse Events Related to Endoscopic Retrograde Cholangiopancreatography: A Prospective Observational Study. *Gut Liver* (May 3 2019, epub ahead of print).
- Lee H, Jang J, Lee S, et al (2014a) Diagnostic Accuracy of the Initial Endoscopy for Ampullary Tumors. *Clinical Endoscopy* 48:239–8.

- Lee J, Choi S, Chon H, et al (2019b) Robotic transduodenal ampullectomy: A novel minimally invasive approach for ampullary neoplasms. *Int J Med Robot* 15(3):e1979.
- Lee M, Kim M-J, Park M-S, et al (2011a) Using multi-detector-row CT to diagnose ampullary adenoma or adenocarcinoma in situ. *Eur J Radiol* 80:e340–e345.
- Lee S-Y, Jang K-T, Lee K, et al (2006) Can endoscopic resection be applied for early stage ampulla of Vater cancer? *Gastrointest Endosc* 63:783–788.
- Lee T, Hwang S, Choi H, et al (2014b) Sequential algorithm analysis to facilitate selective biliary access for difficult biliary cannulation in ERCP: a prospective clinical study. *BMC Gastroenterol* 14:30.
- Lee TH, Bang BW, Park S-H, et al (2011b) Precut Fistulotomy for Difficult Biliary Cannulation: Is It a Risky Preference in Relation to the Experience of an Endoscopist? *Digest Dis Sci* 56:1896–1903.
- Leerhøy B, Nordholm-Carstensen A, an Novovic, et al (2016) Effect of body weight on fixed dose of diclofenac for the prevention of post-endoscopic retrograde cholangiopancreatography pancreatitis. *Scand J Gastroentero* 51:1007–1012.
- Leese T, Neoptolemos J, West K, et al (1986) Tumours and pseudotumours of the region of the ampulla of Vater: an endoscopic, clinical and pathological study. *Gut* 27(19):1186-92.
- Lerch, M., Domschke, W. (2000). Abraham Vater of the Ampulla (Papilla) of Vater. *Gastroenterology* 118(2), 379.
- Li H, Zhao F, Zhou J (2019a) Prognostic Nomogram for Disease-Specific Survival in Patients with Non-metastatic Ampullary Carcinoma After Surgery. *Ann Surg Oncol* 26:1079–1085.
- Li S, Wang Z, Cai F, et al (2019b) New experience of endoscopic papillectomy for ampullary neoplasms. *Surg Endosc* 33:612–619.
- Lieberman DA, Rex DK, Winawer SJ, et al (2012) Guidelines for Colonoscopy Surveillance After Screening and Polypectomy: A Consensus Update by the US Multi-Society Task Force on Colorectal Cancer. *Gastroenterology* 143:844
- Lindner HH, Pena VA, Ruggeri RA (1976) A Clinical and Anatomical Study of Anomalous Terminations of the Common Bile Duct Into the Duodenum. *Ann Surg* 184:626–632.
- Löhr MJ, Schneider A, Diehl SJ, Witt H (2012) Opie’s hypothesis revisited: Acute pancreatitis due to bile reflux into the pancreas. *Pancreatology* 12:39–40.
- Lothe I, Kleive D, Pomianowska E, et al (2019) Clinical relevance of pancreatobiliary and intestinal subtypes of ampullary and duodenal adenocarcinoma: Pattern of recurrence, chemotherapy, and survival after pancreatoduodenectomy. *Pancreatology* 19:316–324.
- Lua G, Muthukaruppan R, Menon J (2015) Can Rectal Diclofenac Prevent Post Endoscopic Retrograde Cholangiopancreatography Pancreatitis? *Digest Dis Sci* 60:3118–3123.
- Lundell L, Dent J, Bennett J, et al (1999) Endoscopic assessment of oesophagitis: clinical and functional correlates and further validation of the Los Angeles classification. *Gut* 45:172–180.
- Mafficini A, Amato E, Cataldo I, et al (2018) Ampulla of Vater Carcinoma. *Ann Surg* 267:149–156.
- Mantoo S, Sanaka MR, Chute DJ (2017) Cytologic features of tubular adenoma of ampulla causing distal common bile duct stricture: A case report and review of the literature. *Cytojournal* 14:19.
- Mariani A, Giussani A, Leo M, et al (2012) Guidewire biliary cannulation does not reduce post-ERCP pancreatitis compared with the contrast injection technique in low-risk and high-risk patients. *Gastrointest Endosc* 75:339–346.
- Mariani, A., Leo, M., Giardullo, et al. (2016). Early precut sphincterotomy for difficult biliary access to reduce post-ERCP pancreatitis: a randomized trial *Endoscopy* 48(06), 530-535.
- Matsubayashi H, Watanabe H, Yamaguchi T, et al (1999) Differences in mucus and K-ras mutation in relation to phenotypes of tumors of the papilla of Vater. *Cancer* 86:596–607.
- Mavrogiannis C, Liatsos C, Romanos A, et al (1999) Needle-knife fistulotomy versus needle-knife precut papillotomy for the treatment of common bile duct stones. *Gastrointest Endosc* 50:334–339.
- Mazaki T, Masuda H, Takayama T (2010) Prophylactic pancreatic stent placement and post-ERCP pancreatitis: a systematic review and meta-analysis. *Endoscopy* 42:842–853.
- McCune WS, Shorb PE, Moscovitz H (1968) Endoscopic Cannulation of the Ampulla of Vater. *Ann Surg* 167:752–756.

- Menzel J, Hoepffner N, Sulkowski U, et al (1999a) Polypoid tumors of the major duodenal papilla: preoperative staging with intraductal US, EUS, and CT — a prospective, histopathologically controlled study. *Gastrointest Endosc* 49:349–357.
- Menzel, J., Poremba, C., Dietl, K., et al. (1999b). Tumors of the papilla of Vater – inadequate diagnostic impact of endoscopic forceps biopsies taken prior to and following sphincterotomy *Annals of Oncology* 10(10), 1227-1231.
- Mirilas P, Colborn GL, Skandalakis LJ, et al (2005) Benign anatomical mistakes: “ampulla of Vater” and “papilla of Vater”. *The American surgeon* 71:269–74
- Misra, S., Dwivedi, M. (1990). Pancreaticobiliary ductal union. *Gut* 31(10), 1144-1149.
- Moekotte, A., Lof, S., Roessel, S. et al. (2019). Histopathologic Predictors of Survival and Recurrence in Resected Ampullary Adenocarcinoma: International Multicenter Cohort Study. *Annals of Surgery* (Jan 7, 2019 Epub ahead of print)
- Mongé JJ, Judd ES, Gage RP (1964) Radical Pancreatoduodenectomy. *Ann Surg* 160:711–722.
- Nakeeb A, Hanafy E, Salah T, et al (2016) Post-endoscopic retrograde cholangiopancreatography pancreatitis: Risk factors and predictors of severity. *World J Gastrointest Endosc* 8:709–715.
- Napoleon, B., Gincul, R., Ponchon, T., et al. (2014). Endoscopic papillectomy for early ampullary tumors: long-term results from a large multicenter prospective study *Endoscopy* 46(02), 127-134.
- Nam K, Song T, Kim RE, et al (2018) Usefulness of argon plasma coagulation ablation subsequent to endoscopic snare papillectomy for ampullary adenoma. *Digest Endosc* 30:485–492.
- Nappo G, Gentile D, Galvanin J, et al (2019) Trans-duodenal ampullectomy for ampullary neoplasms: early and long-term outcomes in 36 consecutive patients. *Surg Endosc.*(23 Oct 2019 epub ahead of print)
- Navaneethan U, Konjeti R, Venkatesh PG, et al (2014) Early precut sphincterotomy and the risk of endoscopic retrograde cholangiopancreatography related complications: An updated meta-analysis. *World J Gastrointest Endosc* 6:200–208.
- Nikolaidis P, Hammond NA, Day K, et al (2014) Imaging Features of Benign and Malignant Ampullary and Periampullary Lesions. *Radiographics* 34:624–41.
- Noel R, Enochsson L, Swahn F, et al (2013) A 10-year study of rendezvous intraoperative endoscopic retrograde cholangiography during cholecystectomy and the risk of post-ERCP pancreatitis. *Surg Endosc* 27:2498–2503.
- Oddi R., (1887): D’une disposition a sphincter speciale de l’ouverture du canal choledoche. *Arch Ital Biol* 8:317-322.
- Ogawa T, Ito K, Fujita N, et al (2012) Endoscopic papillectomy as a method of total biopsy for possible early ampullary cancer. *Digest Endosc* 24:291–291.
- Ohike N, Kim GE, Tajiri T, et al (2010) Intra-ampullary Papillary-Tubular Neoplasm (IAPN). *Am J Surg Pathology* 34:1731–1748.
- Ohuchida J, Chijiwa K, Imamura N, et al (2015) Randomized Controlled Trial for Efficacy of Nafamostat Mesilate in Preventing Post-Endoscopic Retrograde Cholangiopancreatography Pancreatitis. *Pancreas* 44:415–421.
- Oi I, Takemoto T, Kondo T (1969) Fiberduodenoscope: Direct Observation of the Papilla of Vater. *Endoscopy* 1:101–103.
- Okano K, Oshima M, Yachida S, et al (2014) Factors predicting survival and pathological subtype in patients with ampullary adenocarcinoma. *J Surg Oncol* 110:156–162.
- Okano K, Asano E, Kushida Y, et al (2015) Factors Influencing Lymph Node Metastasis in Patients with Ampullary Adenocarcinoma. *Digest Surg* 31:459–467.
- Okano N, Igarashi Y, Hara S, et al (2013) Endosonographic Preoperative Evaluation for Tumors of the Ampulla of Vater Using Endoscopic Ultrasonography and Intraductal Ultrasonography. *Clin Endosc* 47:174–177.
- Onkendi EO, Naik ND, Rosedahl JK, et al (2014) Adenomas of the Ampulla of Vater: A comparison of Outcomes of Operative and Endoscopic Resections. *J Gastrointest Surg* 18:1588–1596.
- Oppong KW, Mitra V, Scott J, et al (2014) Endoscopic ultrasound in patients with normal liver blood tests and unexplained dilatation of common bile duct and or pancreatic duct. *Scandinavian Journal of Gastroenterology* 49:473–480.
- Palma GD (2014) Endoscopic papillectomy: Indications, techniques, and results. *World J Gastroentero* 20:1537–1543.
- Pan Y, Zhao L, Leung J, et al (2015) Appropriate time for selective biliary cannulation by trainees during ERCP--a randomized trial. *Endoscopy* 47:688–695.

- Pant M, Pehlivanoglu B, Erbarut-Seven I, Adsay VN (2018) Intra-Ampullary Papillary-Tubular Neoplasm. *AJSP: Rev Reports* 23:38–43.
- Papoulas M, Pucher P, Pinsker N, et al (2017) Transduodenal ampullectomy for ampullary neoplasms - a systematic review and meta-analysis. *HPB, Suppl* 19:S98–S100.
- Parlak E, Çiçek B, Dişibeyaz S, et al (2007) An endoscopic finding in patients with primary sclerosing cholangitis: retraction of the main duodenal papilla into the duodenum wall. *Gastrointest Endosc* 65:532–536.
- Parlak E, Koksal A, Disibeyaz S, et al (2015) Retraction of the main papilla toward the biliary system in patients with primary sclerosing cholangitis. *Turkish J Gastroenterology* 25:203–205.
- Patel V, Jowell P, Obando J, et al (2016) Does ampullary adenoma size predict invasion on EUS? Does invasion on EUS predict presence of malignancy? *Endosc Int Open* 04:E1313–E1318.
- Paulsen FP, Bobka T, Tsokos M, et al (2002) Functional anatomy of the papilla Vateri. *Surg Endosc* 16:296–301.
- Peng C, Lv Y, Shen S, et al (2019) The impact of endoscopic ultrasound in preoperative evaluation for ampullary adenomas. *J Digest Dis* 20:248–255.
- Pérez-Cuadrado-Robles E, Piessevaux H, Moreels TG, et al (2018) Combined excision and ablation of ampullary tumors with biliary or pancreatic intraductal extension is effective even in malignant neoplasms. *United Eur Gastroent* 7:369–376.
- Perkins G, Svrcek M, Bouchet-Doumenq C, et al (2019) Can we classify ampullary tumours better? Clinical, pathological and molecular features. Results of an AGEO study. *British Journal of Cancer* 120:697–702.
- Perysinakis I, Margaris I, Kouraklis G (2014) Ampullary cancer – a separate clinical entity? *Histopathology* 64:759–768.
- Petrone G, Ricci R, Familiari P, et al (2013) Endoscopic snare papillectomy: a possible radical treatment for a subgroup of T1 ampullary adenocarcinomas. *Endoscopy* 45:401–404.
- Poincloux L, Scanzi J, Goutte M, et al (2014) Pancreatic intubation facilitated by methylene blue injection decreases the risk for postpapillectomy acute pancreatitis. *Eur J Gastroen Hepat* 26:990–995.
- Pomianowska E, Westgaard A, Mathisen Ø, et al (2013) Prognostic Relevance of Number and Ratio of Metastatic Lymph Nodes in Resected Pancreatic, Ampullary, and Distal Bile Duct Carcinomas. *Ann Surg Oncol* 20:233–241.
- Ponchon T, Berger F, Chavaillon A, et al (1989) Contribution of endoscopy to diagnosis and treatment of tumors of the ampulla of Vater. *Cancer* 64:161–167.
- Radadiya D, Devani K, Arora S, et al (2019) Peri-procedural aggressive hydration for Post Endoscopic retrograde pancreatocholangiography (ERCP) pancreatitis prophylaxis: Meta-analysis of randomized controlled trials. *Pancreatology* 19(6):819–827
- Ramaswamy A, Bhandare M, Bal M, et al (2019) Clinico-pathological correlates and survival outcomes in 214 resected ampullary adenocarcinomas – are outcomes different in intestinal and pancreatobiliary subtypes with adjuvant gemcitabine? *HPB* (Aug 9, 2019). Epub ahead of print
- Reddy ND, Nabi Z, Lakhtakia S (2017) How to Improve Cannulation Rates During Endoscopic Retrograde Cholangiopancreatography. *Gastroenterology* 152:1275–1279.
- Reid MD, Balci S, Ohike N, et al (2016) Ampullary carcinoma is often of mixed or hybrid histologic type: an analysis of reproducibility and clinical relevance of classification as pancreatobiliary versus intestinal in 232 cases. *Modern Pathol* 29:1575–1585.
- Ricci C, Pagano N, Taffurelli G, et al (2018) Comparison of Efficacy and Safety of 4 Combinations of Laparoscopic and Intraoperative Techniques for Management of Gallstone Disease With Biliary Duct Calculi: A Systematic Review and Network Meta-analysis. *Jama Surg* 153(7):e181167.
- Richman SD, Seymour MT, Chambers P, et al (2009) KRAS and BRAF Mutations in Advanced Colorectal Cancer Are Associated With Poor Prognosis but Do Not Preclude Benefit From Oxaliplatin or Irinotecan: Results From the MRC FOCUS Trial. *J Clin Oncol* 27:5931–5937.
- Riditid W, Schmidt SE, Al-Haddad MA, et al (2015) Performance characteristics of EUS for locoregional evaluation of ampullary lesions. *Gastrointest Endosc* 81:380–388.
- Riditid W, Tan D, Schmidt SE, et al (2014) Endoscopic papillectomy: risk factors for incomplete resection and recurrence during long-term follow-up. *Gastrointest Endosc* 79:289–296.

- Rock J, Fischer ER (1959) Papillary Adenoma of the Ampulla of Vater. *M Archives Surg* 79:163–166.
- Roessel van, S., Mackay, T., Tol J., et al. (2018). Impact of expanding indications on surgical and oncological outcome in 1434 consecutive pancreatoduodenectomies. *HPB* 21(7):865-875.
- Roland CL, Katz MH, Gonzalez GM, et al (2012) A High Positive Lymph Node Ratio is Associated with Distant Recurrence after Surgical Resection of Ampullary Carcinoma. *J Gastrointest Surg* 16:2056–2063.
- Rosenblatt ML, Catalano MF, Alcocer E, Geenen JE (2001) Comparison of sphincter of Oddi manometry, fatty meal sonography, and hepatobiliary scintigraphy in the diagnosis of sphincter of Oddi dysfunction. *Gastrointest Endosc* 54:697–704.
- Ruemmele P, Dietmaier W, Terracciano L, et al (2009) Histopathologic Features and Microsatellite Instability of Cancers of the Papilla of Vater and Their Precursor Lesions. *Am J Surg Pathology* 33:691–704.
- Rustagi T, Irani S, Reddy ND, et al (2017) Radiofrequency ablation for intraductal extension of ampullary neoplasms. *Gastrointest Endosc* 86:170–176.
- Sahar N, Krishnamoorthi R, Kozarek RA, et al (2019) Long-Term Outcomes of Endoscopic Papillectomy for Ampullary Adenomas. *Digest Dis Sci.* (Aug 28 2019, Epub ahead of print)
- Sánchez-Velázquez, P., Muller, X., Malleo, G., et al. (2019). Benchmarks in Pancreatic Surgery: A Novel Tool for Unbiased Outcome Comparisons. *Ann surg* 270(2):211-218.
- Sarmiento JM, Nagorney DM, Sarr MG, Farnell MB (2001) Periampullary cancers. Are there differences? *Surg Clin N Am* 81:543–555.
- Schiergens TS, Reu S, Neumann J, et al (2015) Histomorphologic and molecular phenotypes predict gemcitabine response and overall survival in adenocarcinoma of the ampulla of Vater. *Surgery* 158(1):151–161.
- Schneider L, Contin P, Fritz S, et al (2016) Surgical ampullectomy: an underestimated operation in the era of endoscopy. *HPB* 18(1):65–71.
- Schoenberg MH, Treitschke F, Harada N, Beger HG (1998) Benign tumour of the ampulla of vater: surgical treatment and prognosis. *Eur J Surg* 164:765–770.
- Schönleben F, Qiu W, Allendorf JD, et al (2009) Molecular Analysis of PIK3CA, BRAF, and RAS Oncogenes in Periampullary and Ampullary Adenomas and Carcinomas. *J Gastrointest Surg* 13(8):1510–1516
- Schultz N, Roslind A, Christensen IJ, et al (2012) Frequencies and Prognostic Role of KRAS and BRAF Mutations in Patients With Localized Pancreatic and Ampullary Adenocarcinomas. *Pancreas* 41(5):759–766.
- Serrano J, de Moura D, Bernardo W, et al (2019) Nonsteroidal anti-inflammatory drugs versus placebo for post-endoscopic retrograde cholangiopancreatography pancreatitis: a systematic review and meta-analysis. *Endosc Int Open* 7(4):E477–E486.
- Sheppard D, Craddock S, Warner B, Wilkinson M (2015) ERCP cannulation success benchmarking: implications for certification and validation. *Frontline Gastroenterology* 6(2):141-146.
- Shimosegawa, T., Chari, S., Frulloni, L., et al. (2011). International Consensus Diagnostic Criteria for Autoimmune Pancreatitis. *Pancreas* 40(3), 352-358.
- Silva F, Dinis-Ribeiro M, Vieth M, et al (2011) Endoscopic assessment and grading of Barrett's esophagus using magnification endoscopy and narrow-band imaging: accuracy and interobserver agreement of different classification systems (with videos). *Gastrointest Endosc* 73(1):7–14.
- Silvis S, Vennes J, Dreyer M (1983) Variations in the normal duodenal papilla. *Gastrointest Endosc* 29(2):132–133.
- Sinha R, Gardner T, Padala K, et al (2015) Double-Duct Sign in the Clinical Context. *Pancreas* 44(6):967–970.
- Skalicky (2011) The Size of the Papilla of Vater and Its Relation to Its Height in Comparison with the Visibility of the Sphincter of Oddi before and after Cholecystectomy. *J Int Med Res* 39(3):1039–50.
- Smeets X, Bouhouch N, Buxbaum J, et al (2019) The revised Atlanta criteria more accurately reflect severity of post-ERCP pancreatitis compared to the consensus criteria. *United Eur Gastroent* 7(4):557–564.
- Smith I, Monkemuller K, Wilcox MC (2015) Incidentally Identified Common Bile Duct Dilatation. *J Clin Gastroenterol* 49(10):810–815.

- Sofuni A, Maguchi H, Itoi T, et al (2007)
Prophylaxis of Post-Endoscopic Retrograde Cholangiopancreatography Pancreatitis by an Endoscopic Pancreatic Spontaneous Dislodgement Stent. *Clin Gastroenterol Hepatol* 5(11):1339–1346.
- Spadaccini M, Fugazza A, Frazzoni L, et al (2019)
Endoscopic papillectomy for neoplastic ampullary lesions: A systematic review with pooled analysis. *United Eur Gastroent.* (July 30, 2019 epub ahead of print)
- Srinivasan I, Freeman ML (2016) Editorial:
Guidewire trauma: a key component of post-ERCP pancreatitis that is best controlled by the endoscopist. *Am J Gastroenterol* 111(12):1848-1850.
- Staritz (1988) Pharmacology of the Sphincter of Oddi. *Endoscopy* 20 Suppl 1:171–174.
- Stern C (1986) A historical perspective on the discovery of the accessory duct of the pancreas, the ampulla “of Vater” and pancreas divisum. *Gut* 27(2):203-12.
- Stiles, Z., Behrman, S., Deneve, J., et al. (2018).
Ampullary adenocarcinoma: Defining predictors of survival and the impact of adjuvant therapy following surgical resection for stage I disease *Journal of Surgical Oncology* 117(7):1500-1508.
- Stolte M, Pscherer C (2009) Adenoma—Carcinoma Sequence in the Papilla of Vater. *Scand J Gastroenterol* 31(4):376–382.
- Sugimoto M, Takagi T, Suzuki R, et al (2019)
Pancreatic stents to prevent post-endoscopic retrograde cholangiopancreatography pancreatitis: A meta-analysis. *World J Meta-anal* 7(5):249–258.
- Sugiyama H, Tsuyuguchi T, Sakai Y, et al (2017)
Transpancreatic precut papillotomy versus double-guidewire technique in difficult biliary cannulation: prospective randomized study. *Endoscopy* 50:33–39.
- Sundaralingam P, Masson P, Bourke MJ (2015)
Early Precut Sphincterotomy Does Not Increase Risk During Endoscopic Retrograde Cholangiopancreatography in Patients With Difficult Biliary Access: A Meta-analysis of Randomized Controlled Trials. *Clin Gastroenterol Hepatol* 13(10):1722-1729.e2.
- Suzuki K, Kantou U, Murakami Y. Two cases with ampullary cancer who underwent endoscopic excision. *Prog Dig Endosc* 1983; 23: 236-239
- Swahn F, Nilsson M, Arnelo U, et al (2013a)
Rendezvous Cannulation Technique Reduces Post-ERCP Pancreatitis: A Prospective Nationwide Study of 12,718 ERCP Procedures. *Am J Gastroenterol* 108:552-559.
- Swahn F, Regner S, Enochsson L, et al (2013b)
Endoscopic retrograde cholangiopancreatography with rendezvous cannulation reduces pancreatic injury. *World J Gastroenterol* 19:6026–6034.
- Swan MP, Alexander S, Moss A, et al (2013)
Needle knife sphincterotomy does not increase the risk of pancreatitis in patients with difficult biliary cannulation. *Clinical Gastroenterology and Hepatology* 11:430-436.e1.
- Swan MP, Bourke MJ, Williams SJ, et al (2011)
Failed biliary cannulation: clinical and technical outcomes after tertiary referral endoscopic retrograde cholangiopancreatography. *World J Gastroenterol* 17:4993–4998.
- Takano Y, Nagahama M, Niiya F, et al (2018)
Optimal timing for precutting in cases with difficult biliary cannulation. *Endosc Int Open* 06:E1015–
- Tang, Z., Yang, Y., Yang, Z., et al. (2018).
Early precut sphincterotomy does not increase the risk of adverse events for patients with difficult biliary access *Medicine* 97(36), e12213.
- Tenner, S., Baillie, J., DeWitt, J., et al. (2013).
American College of Gastroenterology Guideline: Management of Acute Pancreatitis. *Am J Gastroenterol* 108(9), 1400-1415.
- Testoni P, Caporuscio S, Bagnolo F, Lella F (1999)
Twenty-Four-Hour Serum Amylase Predicting Pancreatic Reaction After Endoscopic Sphincterotomy. *Endoscopy* 31:131–136.
- Testoni P, Mariani A, Giussani A, et al (2010)
Risk factors for post-ERCP pancreatitis in high- and low-volume centers and among expert and non-expert operators: a prospective multicenter study. *Am J Gastroenterol* 105:1753–61.
- Testoni P, Testoni S, Giussani A (2011)
Difficult biliary cannulation during ERCP: How to facilitate biliary access and minimize the risk of post-ERCP pancreatitis. *Digest Liver Dis* 43:596–603.
- Testoni PA, Bagnolo F, Natale C, Primignani M (2000)
Incidence of post-endoscopic retrograde-cholangiopancreatography/sphincterotomy pancreatitis depends upon definition criteria. *Digest Liver Dis* 32:412–418.
- Testoni PA, Mariani A, Aabakken L, et al (2016)
Papillary cannulation and sphincterotomy techniques at ERCP: European Society of Gastrointestinal Endoscopy (ESGE) Clinical Guideline. *Endoscopy* 48:657–83.
- Thompson DR (2001)
Narcotic analgesic effects on the sphincter of Oddi: a review of the data and therapeutic implications in treating pancreatitis. *Am J Gastroenterol* 96(4):1266-72.

- Tingstedt B., Andersson, B., Jönsson, C., et al. (2019). First results from the Swedish National Pancreatic and Periampullary Cancer Registry HPB 21(1):34-42.
- Trikudanathan G, Njei B, Attam R, et al (2014) Staging accuracy of ampullary tumors by endoscopic ultrasound: meta-analysis and systematic review. *Digestive endoscopy* 26:617–626.
- Tse F, Yuan Y, Moayyedi P, Leontiadis GI (2012) Guidewire-assisted cannulation of the common bile duct for the prevention of post-endoscopic retrograde cholangiopancreatography (ERCP) pancreatitis. *Cochrane Db Syst Rev.* 12;12:CD009662
- Tyberg A, Raijman I, Siddiqui A, et al (2019) Digital Pancreaticocholangioscopy for Mapping of Pancreaticobiliary Neoplasia: Can We Alter the Surgical Resection Margin? *J Clin Gastroenterol* 53:71–75.
- Ung K-A, Rydberg L, Modin S, et al (2011) A preventive effect of unfractionated heparin on post-ERCP pancreatitis is suggested by positive effects on laboratory markers. *Hepato-gastroenterol* 58:168–73
- Unno H, Saegusa H, Fukushima M, Hamano H (2002) Usefulness of endoscopic observation of the main duodenal papilla in the diagnosis of sclerosing pancreatitis. *Gastrointest Endosc* 56:880–884.
- Valente R, Urban O, Chiaro M, et al. (2015) ERCP-directed radiofrequency ablation of ampullary adenomas: a knife-sparing alternative in patients unfit for surgery. *Endoscopy* 47:E515–E516.
- Valsangkar NP, Ingkakul T, Correa-Gallego C, et al. (2015) Survival in ampullary cancer: Potential role of different KRAS mutations. *Surgery* 157:260–268.
- Vater A (1720) *Dissertatio anatomica quo novum bilis dicetilicum circa orificum ductus choledochi ut et valvulosam colli vesicæ felleæ constructionem ad disceptandum proponit.* University of Wittenberg ;1720
- Voiosu T, Boskoski I, Voiosu A, et al (2019) Impact of trainee involvement on the outcome of ERCP procedures: results of a prospective multicenter observational trial. *Endoscopy.* (25 Nov 2019 epub ahead of print)
- Wagner, P., Chen, Y., Yantiss, R. (2008). Immunohistochemical and Molecular Features of Sporadic and FAP-associated Duodenal Adenomas of the Ampullary and Nonampullary Mucosa *The Am J Surg Pathol* 32(9):1388-1395.
- Wang G, Xiao G, Xu L, et al (2018) Effect of somatostatin on prevention of post-endoscopic retrograde cholangiopancreatography pancreatitis and hyperamylasemia: A systematic review and meta-analysis. *Pancreatology* 18:370–378.
- Watanabe M, Okuwaki K, Kida M, et al (2019) Transpapillary Biliary Cannulation is Difficult in Cases with Large Oral Protrusion of the Duodenal Papilla. *Digest Dis Sci* 64:2291–2299.
- Waters, A., Der, C. (2018). KRAS: The Critical Driver and Therapeutic Target for Pancreatic Cancer. *Cold Spring Harbor perspectives in medicine* 8(9), a031435.
- Watson WC (1966) Direct vision of the ampulla of Vater. Through the gastroduodenal fiberscope. *Lancet* 287:902–903.
- Wen, J., Li, T., Lu, Y., (2018) Comparison of efficacy and safety of transpancreatic septotomy, needle-knife fistulotomy or both based on biliary cannulation unintentional pancreatic access and papillary morphology. *Hepatobiliary & pancreatic diseases international : HBPDI* 18(1):73-78.
- Wen K, Kim GE, Rabinovitch PS, et al (2019) Diagnosis, risk stratification, and management of ampullary dysplasia by DNA flow cytometric analysis of paraffin-embedded tissue. *Modern Pathol* 32:1291–1302
- Westgaard A, Pomianowska E, Clausen OF, Gladhaug IP (2013) Intestinal-type and Pancreaticobiliary-type Adenocarcinomas: How Does Ampullary Carcinoma Differ from Other Periampullary Malignancies? *Ann Surg Oncol* 20:430–439
- Whipple A, Parsons W, Mullins C (1935) Treatment of carcinoma of the ampulla of Vater. *Ann Surg* 102:763–779.
- Wilasrusmee C, Pongchairerks P (1999) Pancreaticobiliary ductal anatomy in Thai People. *J Hepatobiliary Pancreat Surg* 6:79–85. 7
- Williams JL, Chan CK, Toste PA, et al (2016) Association of Histopathologic Phenotype of Periampullary Adenocarcinomas With Survival. *Jama Surg* 152(1):82-88.
- Winawer SJ, Zauber AG, Ho M, et al (1993) Prevention of Colorectal Cancer by Colonoscopic Polypectomy. *New Engl J Medicine* 329:1977–1981.
- Winder JS, Juza RM, Alli VV, et al (2019) Concomitant laparoscopic cholecystectomy and antegrade wire, rendezvous cannulation of the biliary tree may reduce post-ERCP pancreatitis events. *Surg Endosc* (Sept 5, 2019 epub ahead of print).

- Winter JM, Cameron JL, Olino K, et al (2010) Clinicopathologic Analysis of Ampullary Neoplasms in 450 Patients: Implications for Surgical Strategy and Long-Term Prognosis. *J Gastrointest Surg* 14:379–387
- Wittekind C, Tannapfel A (2001) Adenoma of the papilla and ampulla – premalignant lesions? *Langenbeck's Archives Surg* 386:172–175.
- Woo S, Ryu J, Lee S, et al (2009) Feasibility of endoscopic papillectomy in early stage ampulla of Vater cancer. *J Gastroen Hepatol* 24:120–124.
- Wood M (1979) Eponyms in biliary tract surgery. *Am J Surg* 138:746–754.
- Woods CM, Saccone G (2007) Neurohormonal regulation of the sphincter of oddi. *Curr Gastroenterology Reports* 9:165–170.
- Yamaguchi K, Enjoji M (1991) Adenoma of the ampulla of Vater: putative precancerous lesion. *Gut* 32:1558-61
- Yamaguchi K, Enjoji M, Kitamura K (1990) Endoscopic biopsy has limited accuracy in diagnosis of ampullary tumors. *Gastrointest Endosc* 36:588–592.
- Yamamoto K, Itoi T, Sofuni A, et al (2019) Expanding the indication of endoscopic papillectomy for T1a ampullary carcinoma. *Digest Endosc* 31:188–196
- Yang C, Zhao Y, Li W, et al (2017) Rectal nonsteroidal anti-inflammatory drugs administration is effective for the prevention of post-ERCP pancreatitis: An updated meta-analysis of randomized controlled trials. *Pancreatology* 17:681–688.
- Yoo Y, Cha S-W, Lee W, et al (2013) Double guidewire technique vs transpancreatic precut sphincterotomy in difficult biliary cannulation. *World J Gastroentero* 19:108–114.
- Yoon Y-S, Kim S-W, Park S, et al (2005) Clinicopathologic Analysis of Early Ampullary Cancers With a Focus on the Feasibility of Ampullectomy. *Ann Surg* 242:92–100.
- You D, Heo J, Choi S, et al (2014) Pathologic T1 Subclassification of Ampullary Carcinoma With Perisphincteric or Duodenal Submucosal Invasion: Is It T1b? *Arch Pathol Lab Med* 138:1072–6.
- Zauber AG, Winawer SJ, O'Brien MJ, et al (2012) Colonoscopic polypectomy and long-term prevention of colorectal-cancer deaths. *The New England journal of medicine* 366:687–96.
- Zbar AP, Maor Y, Czerniak A (2012) Imaging tumours of the ampulla of Vater. *Surg Oncol* 21:293–298
- Zhou P-H, Yao L-Q, Xu M-D, et al (2006) Application of needle-knife in difficult biliary cannulation for endoscopic retrograde cholangiopancreatography. *Hepatobiliary Pancreat Dis Int Hbpd Int* 5:590–4
- Zhou W, Li Y, Zhang Q, et al (2011) Risk Factors for Postendoscopic Retrograde Cholangiopancreatography Pancreatitis: A Retrospective Analysis of 7,168 Cases. *Pancreatology* 11:399–405.
- Zhou Y, Li D, Wu L, Si X (2017) The histopathologic type predicts survival of patients with ampullary carcinoma after resection: A meta-analysis. *Pancreatology* 17:273–278.