

## Case Report

# Human Tail in a New Born: A Case Report

Tewodros Deneke, MD<sup>\*</sup>; Birtukan Ewunetu, MD

Department of Pathology, Jimma University Medical Center, Jimma, Ethiopia

<sup>\*</sup>Corresponding author

Tewodros Deneke, MD

Assistant Professor, Department of Pathology, Jimma University Medical Center, Jimma, Ethiopia; E-mail: [Tednew09@gmail.com](mailto:Tednew09@gmail.com)

### Article information

Received: September 29<sup>th</sup>, 2022; Revised: October 26<sup>th</sup> 2022; Accepted: October 26<sup>th</sup>, 2022; Published: October 31<sup>st</sup>, 2022

### Cite this article

Deneke T, Ewunetu B. Human tail in a new born: A case report. *Pediatr Neonatal Nurs Open J.* 2022; 8(2): 48-50. doi: [10.17140/PNNOJ-8-139](https://doi.org/10.17140/PNNOJ-8-139)

## ABSTRACT

### Background

Human tails are rare congenital anomalies protruding from midline of the lumbosacral region covered by skin. Human tails are classified as true tail and pseudo tail. True tails, also known as vestigial tails are caudal, midline protrusion capable of spontaneous or reflex motion, consisting of skin covering with a combination of striated muscle, adipose and connective tissue, normal blood vessels and nerves.

### Case Presentation

A 47-days-old-female infant born from 28-years old prime parous women present with cutaneous appendage arising from the sacrococcygeal region, in the midline, above the intergluteal cleft. The tail-like structure was 9 cm in length, with a diameter between 3 cm and 2 cm in all its length, cylindrical, and pointy towards the end. The structure was soft, covered in skin, it shows spontaneous movement. The magnetic resonance imaging (MRI) report shows S1-S2 level spinal bifida.

### Conclusion

This is a rare case of vestigial human tail with spinal bifida on 47-days old female infant born from prime parous mother through spontaneous vaginal delivery diagnosed by histopathologic examination.

### Keywords

Human tail; Vestigial tail; Pseudo-tail; Spinal bifida.

## INTRODUCTION

Human tails are rare congenital anomalies protruding from midline of the lumbosacral region covered by skin.<sup>1,2</sup> The birth of a baby with a tail can cause psychological disturbance to the parents and, in some cases, a feeling of stigma and shame.<sup>3,4</sup>

Human tails are classified as true tail and pseudo tail. True tails, also known as vestigial tails are caudal, midline protrusion capable of spontaneous or reflex motion, consisting of skin covering with a combination of striated muscle, adipose and connective tissue, normal blood vessels and nerves. Pseudo tail is a secondary protrusion caused by various anomalies or neoplasms such as, anomalous prolongations of coccygeal vertebrae, occult spinal dysraphism, lipoma, teratoma, a parasitic fetus, fibro lipoma.<sup>4,6</sup> Unlike the tail of other vertebrates, human tails do not contain vertebral structures.<sup>3,4</sup>

Human tail can be associated with congenital anomalies such as spinal dysraphism, which should be intentionally assessed

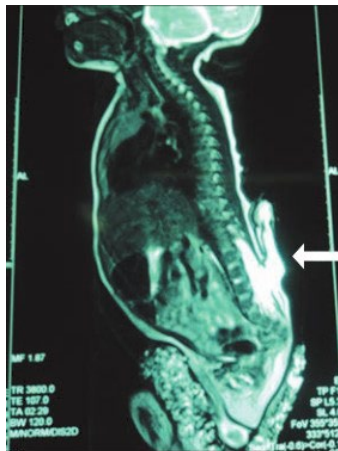
before any extirpation attempt.<sup>5</sup> Thorough neurological examination and imaging studies of the vertebral column are recommended to exclude this possibility. Spina bifida to be the most frequent coexisting anomaly with both true tail and pseudo tail.<sup>7,8</sup>

## CASE PRESENTATION

A 47-days-old-female infant born from 28-years old prime parous women having regular antenatal follow-up, with spontaneous vaginal delivery and no history of radiation or chemical exposure during the pregnancy, was referred to Jimma University Medical Center (JUMC) with referral diagnosis of vestigial human tail.

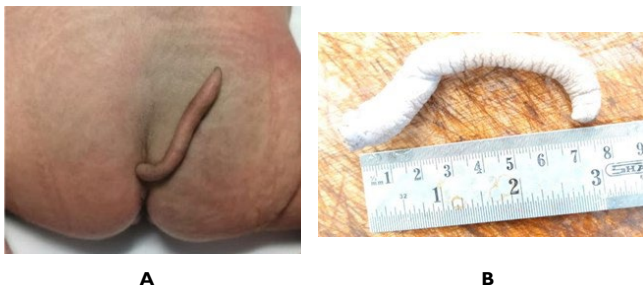Upon examination a cutaneous appendage was found, arising from the sacrococcygeal region, in the midline, above the intergluteal cleft. The tail-like structure was 9 cm in length, with a diameter between 3 cm and 2 cm in all its length, cylindrical, and pointy towards the end. The structure was soft, covered in skin, and shows spontaneous movement. The magnetic resonance imaging (MRI) report shows S1-S2 level spinal bifida (Figure 1).

**Figure 1.** MRI of the Vertebral Bone Showing the Defect, Spinal Bifida



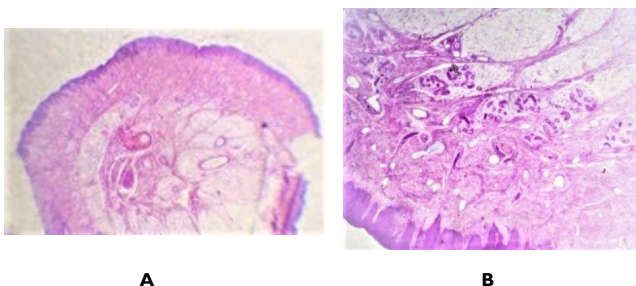
Surgery was done with removal of the whole structure and sent to pathology department. The gross structure shows tail-like structure was 9 cm in length, with a diameter between 3 cm and 2 cm in all its length, cylindrical, and pointy towards the end (Figure 2).

**Figure 2.** Showing the Vestigial Tail (A, before Surgery; B, after Surgical Removed)

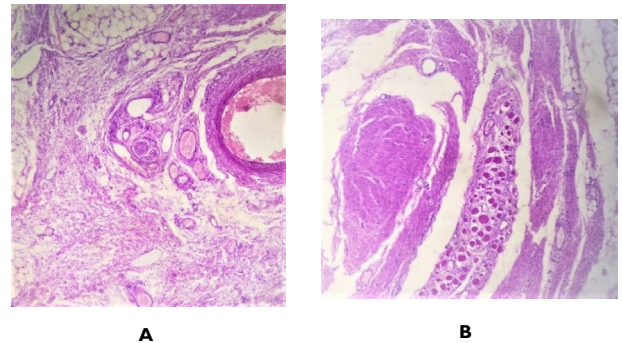


On microscopy it shows keratinized stratified squamous epithelium containing the underlining sweat gland hair follicles and other dermal structure, skeletal muscle, smooth muscles, nerve bundles, adipose tissue, blood vessels and fibrous mesenchymal tissue (Figures 3 and 4).

**Figure 3.** Dermal Components, Fat Tissue and Blood Vessels (H&E; A=4X; B=10X)



**Figure 4.** Smooth Muscle, Skeletal Muscle, Nerves and Other Mesenchymal Components (A,B=40X)



## DISCUSSION

True human tail results from incomplete regression of the most distal end of the normal embryonic tail found in the developing human fetus.<sup>9</sup> During the 5<sup>th</sup> to 6<sup>th</sup> week of intrauterine life, the human embryo has a tail with 10-12 vertebrae. By 8-weeks, the human tail disappears. True human tail arises from the most distal remnant of the embryonic tail.<sup>3</sup> Mutations resulting in increased up regulation of the *WNT3A* gene may result in retention of the embryonic tail in humans. However, further genetic studies are necessary.<sup>10</sup>

A true tail is a dermal appendage mostly located in the sacrococcygeal region and affects all races.<sup>7</sup> True human tails are not inherited, but familial cases have been reported and in one case, three female generations in the same family were born with true human tail.<sup>9</sup> Our patient has no family history.

Vestigial (True) tails were described as resembling a penis, finger, sausage, stump and often covered by pigmented hairy skin. It can occur twice in males than females. Unlike the tail of other vertebrates, human tails do not contain vertebral structures.<sup>3,4</sup> The length ranged from 3 to 13 cm with a diameter of 0.7 to 3 cm.<sup>4</sup> In our case, the vestigial tail measures 9 cm length and 3 cm to 2 cm diameter. It shows spontaneous movement.

Histologically, vestigial tails are characterized by mature adipose tissue, connective tissue, small blood vessels and nerve fibers with central bundles of striated muscle which enable it to move. The surface is covered by skin with normal hair follicles and sweat glands. The dermis usually is thicker than normal.<sup>3,4</sup> Our case has all histologic features of vestigial tails.

Pseudo tails are lumbosacral protrusion with superficial resemblance to true tails. They present as anomalous extension of the coccygeal vertebrae elongation teratomatous elements, adipose tissue, cartilage and as associated with additional lesions such as lipoma, teratoma chondrodystrophy or parasitic fetus.<sup>1,4,6</sup> It is the most human tail type associated with abnormalities of the spine and spinal cord.<sup>1</sup>

Both true tail and pseudo tail can be associated with congenital anomalies like spina bifida, brain and craniofacial disorders, congenital heart disease, anal and vaginal atresia, horse shoe kidney, cleft palate, club foot and syndactyl.<sup>4,5,7</sup>

Before management in addition to physical examination imaging is very important. MRI is best choice, as it has good specificity in defining anatomy and location, in addition to ruling out other pathologies like tethered chord syndrome, occult spina bifida, hypoplasia of vertebral arches, myelomeningocele or meningocele.<sup>4,5</sup>

Treatment for human tails needs clinical and radiological evaluation followed by Simple excision or both removal and correction of the underlying lesion if it is associated with congenital anomalies.<sup>11</sup> To rule out teratomatous growth and other associated neoplasms, histopathological examination required.<sup>1</sup>

Post-operatively, long-term follow-up is necessary to rule out possible complications after surgery especially in cases associated with spinal dysraphism.<sup>1,11</sup>

## CONCLUSION

This is a rare case of vestigial human tail with spina bifida on 47-days-old-female infant born from prime parous mother through spontaneous vaginal delivery. Before surgical management, imaging is necessary to rule out underlying anomalies followed by histopathologic examination to differentiate true tail from pseudo tail.

## ETHICAL CONSIDERATION

Ethical clearance was obtained from Institutional Review Board (IRB) of Jimma University and was submitted to the responsible authorities of JUMC Department of Pathology and the parents of the neonate before collecting the data of the case. All the information collected from the case report was handled confidentially.

## ACKNOWLEDGMENT

We would like to thank our patient who consented to participate in this case report.

## CONFLICT OF INTEREST

The authors declare that they have no conflicts of interest.

## REFERENCES

1. Forte H, Soares CEL, de Holanda Góes Bezerra MM, de Araujo

Verdiano V, Honorio RS, das Chagas Barros Brilhante F. A true human tail in neonate. *Journal of Pediatric Surgery Case Reports*. 2021; 66. doi: 10.1016/j.epsc.2021.101801

2. Sarmast AH, Showkat HI, Mir SF, Ahmad SR, Bhat AR, Kirmani AR. Human born with a tail: A case report. *S. Afr. J. Child Health*. 2013; 7(1): 38-39. doi: 10.7196/SAJCH.456

3. Mukhopadhyay B, Shukla R, Mukhopadhyay M, Mandal K, Haladar P, Benare A. Spectrum of human tails: A report of six cases. *J Indian Assoc Pediatr Surg*. 2012; 17(1): 23-25. doi: 10.4103/0971-9261.91082

4. Dao AH, Netsky MG. Human tails and pseudotails. *Hum Pathol*. 1984; 15(5): 449-453. doi: 10.1016/S0046-8177(84)80079-9

5. Rueda J, Gutierrez J, Facio J, et al. Human tail in a newborn. *Journal of Pediatric Surgery Case Reports*. 2022; 76: 102098. doi: 10.1016/j.epsc.2021.102098

6. Kang HK, Lee SR, Park DW, Hahm CK. Human tail: A case report. *J Korean Radiol Soc*. 2002; 47(4): 419-421. doi: 10.3348/jkrs.2002.47.4.419

7. Chauhan SPS, Gopal NN, Jain M, Gupta A. Human tail with spina bifida. *Br J Neurosurg*. 2009; 23(6): 634-635. doi: 10.3109/02688690902912933

8. Joel Belzberg A, Myles ST, Trevenen CL. The human tail and spinal dysraphism. *J Pediatr Surg*. 1991; 26(10): 1243-1245. doi: 10.1016/0022-3468(91)90343-R

9. Daib A, Saadi C, Ben Abdallah RR, et al. A rare case of lumbosacrococcygeal mass in newborn: A human tail. *J Surg Case Rep*. 2020; 2020(11): rjaa426. doi: 10.1093/jscr/rjaa426

10. Greco TL, Takada S, Newhouse MM, McMahon JA, McMahon AP, Camper SA. Analysis of the vestigial tail mutation demonstrates that Wnt-3a gene dosage regulates mouse axial development. *Genes Dev*. 1996; 10(3): 313-324. doi: 10.1101/gad.10.3.313

11. Ahmad A. Human tail- a rare anatomical mystery: A case report. *J Pediatr Adolesc Surg*. 2020; 1(1): 44-46. doi: 10.46831/jpas.v1i1.3