

Pigmented Lesions of the Oral Cavity: Review, Differential Diagnosis, and Case Presentations

- Adel Kauzman, BDS, DMD, MSc •
- Marisa Pavone, DDS •
- Nick Blanas, BSc, DDS, FRCD(C) •
- Grace Bradley, DDS, MSc, FRCD(C) •

A b s t r a c t

Pigmented lesions are commonly found in the mouth. Such lesions represent a variety of clinical entities, ranging from physiologic changes to manifestations of systemic illnesses and malignant neoplasms. Evaluation of a patient presenting with a pigmented lesion should include a full medical and dental history, extraoral and intraoral examinations and, in some cases, biopsy and laboratory investigations. In this paper, an algorithm is proposed for the assessment of pigmented lesions of the oral cavity, and 3 patients with such lesions are described.

MeSH Key Words: *diagnosis, differential; mouth mucosa/pathology; pigmentation disorders/diagnosis*

© J Can Dent Assoc 2004; 70(10):682-3
This article has been peer reviewed.

Pigmented lesions are commonly found in the mouth. Such lesions represent a variety of clinical entities, ranging from physiologic changes (e.g., racial pigmentation) to manifestations of systemic illnesses (e.g., Addison's disease) and malignant neoplasms (e.g., melanoma and Kaposi's sarcoma). Therefore, an understanding of the causes of mucosal pigmentation and appropriate evaluation of the patient are essential.

Oral pigmentation may be exogenous or endogenous in origin. Exogenous pigmentation is commonly due to foreign-body implantation in the oral mucosa. Endogenous pigments include melanin, hemoglobin, hemosiderin and carotene. Melanin is produced by melanocytes in the basal layer of the epithelium and is transferred to adjacent keratinocytes via membrane-bound organelles called melanosomes. Melanin is also synthesized by nevus cells, which are derived from the neural crest and are found in the skin and mucosa. Pigmented lesions caused by increased melanin deposition may be brown, blue, grey or black, depending on the amount and location of melanin in the tissues.¹

Differential Diagnosis of Oral Pigmented Lesions

Evaluation of a patient presenting with a pigmented lesion should include a full medical and dental history,

extraoral and intraoral examinations, and laboratory tests.² The history should include the onset and duration of the lesion, the presence of associated skin hyperpigmentation, the presence of systemic signs and symptoms (e.g., malaise, fatigue, weight loss), use of prescription and nonprescription medications, and smoking habits. Pigmented lesions on the face, perioral skin and lips should be noted. The number, distribution, size, shape and colour of intraoral pigmented lesions should be assessed. In general, benign pigmented lesions show regular borders and are small, symmetric and uniform in colour. They may be either flat or slightly elevated. In contrast, irregular borders, colour variation, and surface ulceration suggest malignancy.

Clinical tests such as diascopy and radiography and laboratory investigations such as blood tests can be used to confirm a clinical impression and reach a definitive diagnosis. However, because it is not always possible to distinguish between a benign pigmented lesion and an early melanoma on the basis of clinical features alone, biopsy is usually recommended for focal oral pigmented lesions that cannot be explained by local factors. In this paper, we present an algorithm to guide the assessment of pigmented lesions of the oral cavity on the basis of history, clinical examination and laboratory investigations (Fig. 1). The algorithm is based on the typical or predominant clinical presentation of

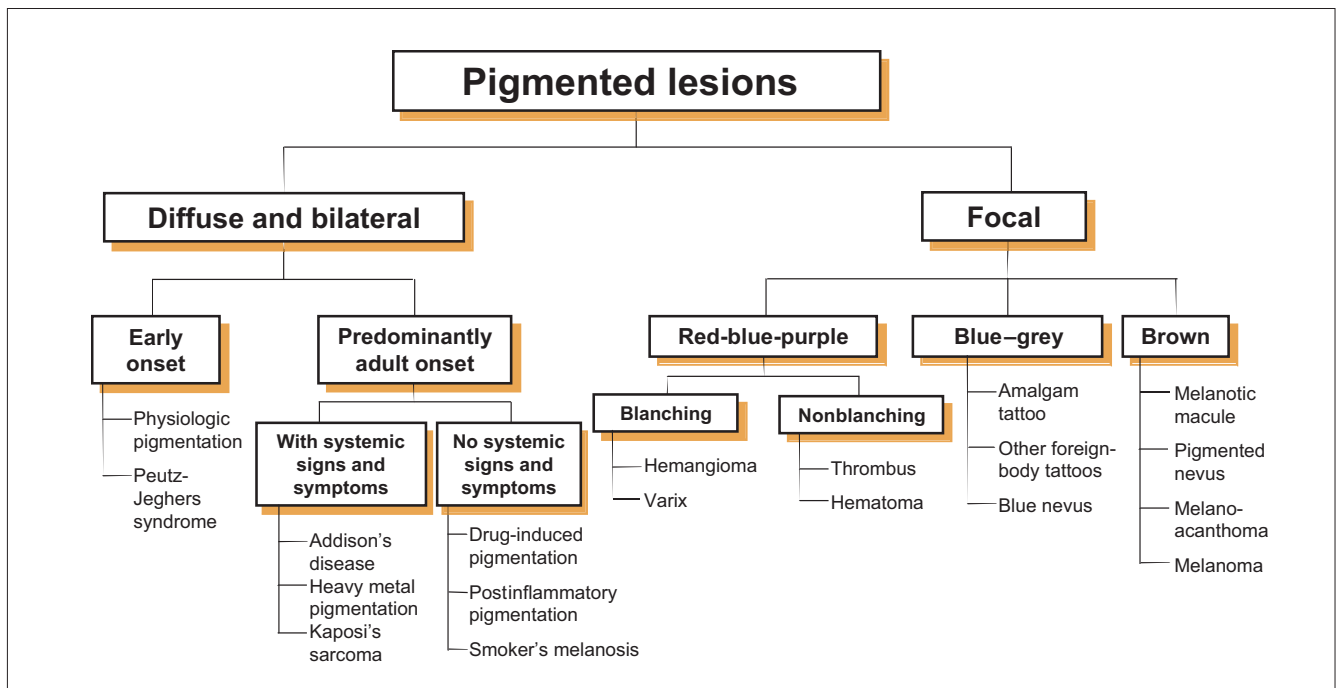


Figure 1: An algorithm for evaluation of pigmented lesions of the oral cavity.

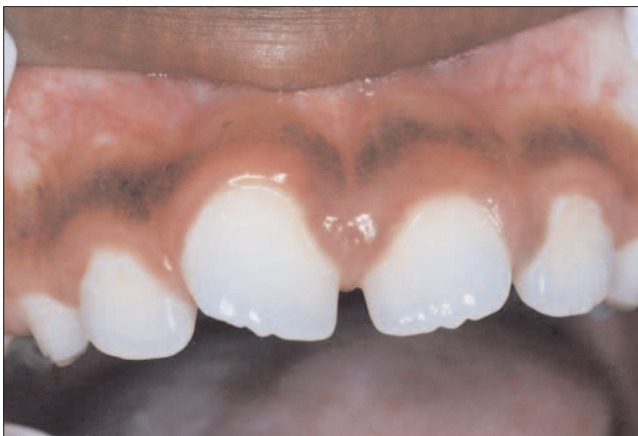

Figure 2: Physiologic (racial) pigmentation in an African boy presenting as a well-demarcated dark brown band on the attached gingiva. The marginal gingiva is unaffected.

the various lesions and should not be taken as absolute indicator of diagnosis. Moreover, although differences in colour can help to differentiate among pigmented lesions, the interpretation of colour can be subjective and is influenced by the amount and location of the pigment within the mucosa.

Diffuse and Bilateral Pigmentation

Physiologic (Racial) Pigmentation

Physiologic pigmentation, which is common in African, Asian and Mediterranean populations,³ is due to greater melanocyte activity rather than a greater number of melanocytes. Physiologic pigmentation develops during the

first 2 decades of life but may not come to the patient's attention until later. The colour ranges from light to dark brown. The attached gingiva is the most common intraoral site of such pigmentation, where it appears as a bilateral, well-demarcated, ribbon-like, dark brown band that usually spares the marginal gingiva¹ (Fig. 2). Pigmentation of the buccal mucosa, hard palate, lips and tongue may also be seen as brown patches with less well-defined borders. The pigmentation is asymptomatic, and no treatment is required.

Peutz-Jeghers Syndrome

Peutz-Jeghers syndrome is a rare genetic disorder associated with mutation of the *LKB1* gene on chromosome 19.^{4,5} It is characterized by pigmented mucocutaneous macules, intestinal hamartomatous polyposis and an increased risk of cancer in many organs, including the small intestine, colon, stomach, pancreas, breast and genital tract.⁶ The melanotic spots of Peutz-Jeghers syndrome are characteristically small and multiple, and are very obvious around the lips. Pigmented spots also occur inside the mouth, in the mucosa of the nose, conjunctiva and rectum, and on the skin of the extremities.⁷ The melanotic spots do not require treatment and are not associated with increased risk of melanoma. However, the patient should be monitored for the development of internal malignancies.

Addison's Disease

Addison's disease, or primary hypoadrenalism, is due to progressive bilateral destruction of the adrenal cortex by autoimmune disease, infection or malignancy.⁸ The lack of adrenocortical hormones in the blood stimulates

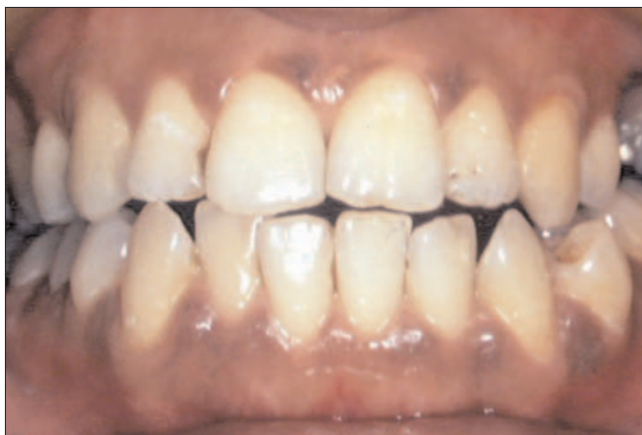

Figure 3: Diffuse macular pigmentation of the gingiva in a patient with Addison's disease. Pigmented lesions were also present on the buccal and labial mucosa (not shown). In contrast to the situation for physiologic pigmentation (Fig. 2), the marginal gingiva is involved in this case.

production of adrenocorticotrophic hormone (ACTH) by the anterior pituitary gland. The increased production of ACTH induces melanocyte-stimulating hormone, which results in diffuse pigmentation of the skin and oral mucosa. Oral involvement presents as diffuse brown patches on the gingiva, buccal mucosa, palate and tongue, which may resemble physiologic pigmentation⁹ (Fig. 3). However, oral mucosal pigmentation associated with Addison's disease develops and progresses during adult life and is usually accompanied by systemic manifestations including weakness, nausea and vomiting, abdominal pain, constipation or diarrhea, weight loss and hypotension. Patients presenting with these features should be sent for medical evaluation and laboratory tests to assess levels of ACTH, plasma cortisol and serum electrolytes. Addison's disease can be fatal if left untreated. Management involves treatment of the underlying cause and corticosteroid replacement therapy.

Heavy Metal Pigmentation

Increased levels of heavy metals (e.g., lead, bismuth, mercury, silver, arsenic and gold) in the blood represent a known cause of oral mucosal discolouration. In adults, the most common cause for such increased levels is occupational exposure to heavy metal vapours. Treatment with drugs containing heavy metals, such as arsenicals for syphilis, was a common cause in the past. In children, possible sources of exposure include lead-contaminated water or paint and mercury- or silver-containing drugs.⁹ The pigmentation appears as a blue-black line along the gingival margin and seems to be proportional to the amount of gingival inflammation.¹⁰ Other oral mucosal sites may also be involved.

Depending on the type of metal implicated, a number of systemic signs and symptoms may be associated with chronic exposure.⁹ The importance of oral mucosal pigmentation associated with heavy metals lies primarily in

Table 1 Drugs associated with oral mucosal pigmentation^{9,10}

Antimalarials: quinacrine, chloroquine, hydroxychloroquine
Quinidine
Zidovudine (AZT)
Tetracycline
Minocycline
Chlorpromazine
Oral contraceptives
Clofazimine
Ketoconazole
Amiodarone
Busulfan
Doxorubicin
Bleomycin
Cyclophosphamide
5-Fluorouracil

the recognition and treatment of the underlying cause to avoid severe systemic toxic effects.

Kaposi's Sarcoma

Kaposi's sarcoma (KS) is a multifocal vascular malignancy seen predominantly in HIV-infected individuals. The development of this tumour is considered diagnostic of AIDS progression. A human herpesvirus (HHV-8, also called Kaposi's sarcoma-associated herpesvirus) has been implicated as the cause. KS in the oral mucosa most commonly affects the hard palate, gingiva and tongue. Early lesions appear as flat or slightly elevated brown to purple lesions that are often bilateral. Advanced lesions appear as dark red to purple plaques or nodules that may exhibit ulceration, bleeding and necrosis. Definitive diagnosis requires biopsy, which shows a proliferation of spindle-shaped cells surrounding poorly formed vascular spaces or slits with numerous extravasated red blood cells.^{9,10}

Drug-Induced Pigmentation

A number of medications may cause oral mucosal pigmentation (Table 1). The pathogenesis of drug-induced pigmentation varies, depending on the causative drug. It can involve accumulation of melanin, deposits of the drug or one of its metabolites, synthesis of pigments under the influence of the drug or deposition of iron after damage to the dermal vessels.¹¹ Chloroquine and other quinine derivatives are used in the treatment of malaria, cardiac arrhythmia and a variety of immunologic diseases including systemic and discoid lupus erythematosus and rheumatoid arthritis. Mucosal discolouration associated with this group of drugs is described as blue-grey or blue-black, and in most cases only the hard palate is involved.^{2,12,13} Laboratory studies have shown that these drugs may produce a direct stimulatory effect on the melanocytes.¹⁴ However, the reason why this effect is limited to the palatal mucosa is not understood.

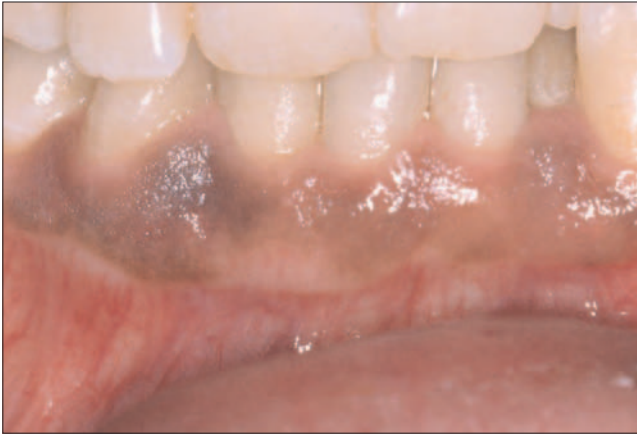

Figure 4: Heavy pigmentation of the attached gingiva in the region of the right lower canine in a smoker. The cigarette was usually held on the right side.

Minocycline is a synthetic tetracycline used in the long-term treatment of refractory acne vulgaris. It can cause pigmentation of the alveolar bone, which can be seen through the thin overlying oral mucosa (especially the maxillary anterior alveolar mucosa) as a grey discoloration.¹⁵ Minocycline has also been reported to cause pigmentation of the tongue mucosa.¹⁶

Postinflammatory Pigmentation

Long-standing inflammatory mucosal diseases, particularly lichen planus, can cause mucosal pigmentation.¹ This is seen more frequently in dark-skinned individuals. Clinically, multiple brown–black pigmented areas are noted adjacent to reticular or erosive lesions of lichen planus. The pathogenesis of postinflammatory pigmentation remains unclear.¹⁷ Histologically, there is increased production of melanin by the melanocytes and accumulation of melanin-laden macrophages in the superficial connective tissue.

Smoker's Melanosis

Smoking may cause oral pigmentation in light-skinned individuals and accentuate the pigmentation of dark-skinned patients.¹⁸ There is increased production of melanin, which may provide a biologic defence against the noxious agents present in tobacco smoke.¹⁹ Smoker's melanosis occurs in up to 21.5% of smokers.²⁰ The intensity of the pigmentation is related to the duration and amount of smoking.^{20,21} Women are more commonly affected than men, which suggests a possible synergistic effect between the female sex hormones and smoking.²⁰ The brown–black lesions most often involve the anterior labial gingiva (Fig. 4), followed by the buccal mucosa.²⁰ Smoker's melanosis usually disappears within 3 years of smoking cessation. Biopsy should be performed if there is surface elevation or increased pigment intensity or if the pigmentation is in an unexpected site.⁹

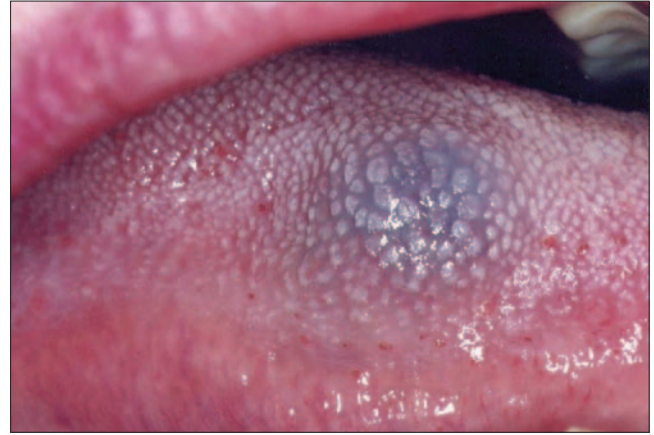

Figure 5: Hemangioma on the right side of the tongue in a young patient presented as an asymptomatic reddish blue lesion that blanched on pressure.

Focal Pigmentation

Hemangioma and Vascular Malformation

Hemangioma is a benign proliferation of the endothelial cells that line vascular channels. Vascular malformation is a structural anomaly of blood vessels without endothelial proliferation. Both lesions are developmental abnormalities, characterized by onset during infancy. Hemangioma regresses as the patient ages, but vascular malformation persists throughout life.⁹ In the mouth, the tongue is the most common site of occurrence, and the clinical features are similar for hemangioma and vascular malformation (Fig. 5). The lesion may be flat or slightly raised and varies in colour from red to bluish purple depending on the type of vessels involved (capillaries, veins or arteries) and the depth of the lesion in the tissues.²² Diascopy usually shows blanching on pressure. This procedure is performed by pressing gently on the lesion with a glass slide or a glass test tube. A positive diascopy result (blanching) generally indicates that the blood is within vascular spaces and is displaced out of the lesion by pressure.²² However, lack of blanching does not exclude the possibility of a vascular lesion.

Varix and Thrombus

Varices are abnormally dilated veins, seen mostly in patients older than 60 years of age. The most common intraoral location is the ventral surface of the tongue, where varices appear as multiple bluish purple, irregular, soft elevations that blanch on pressure (Fig. 6). If the varix contains a thrombus, it presents as a firm bluish purple nodule that does not blanch on pressure. Thrombi are more common on the lower lip and buccal mucosa.⁹

Hematoma and Other Hemorrhagic Lesions

Hematomas, petechiae, purpurae and ecchymoses are caused by extravasation of blood into the soft tissues. They appear as nonblanching flat or elevated pigmented lesions. They may occur spontaneously in certain systemic

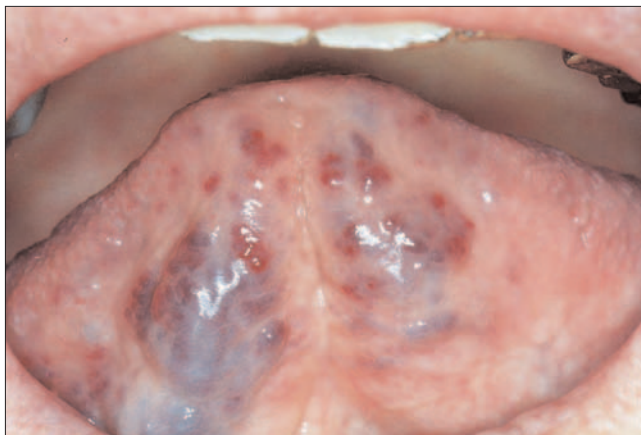


Figure 6: A typical example of sublingual varices in an elderly patient. The dilated vessels were soft to palpation and blanched on pressure.

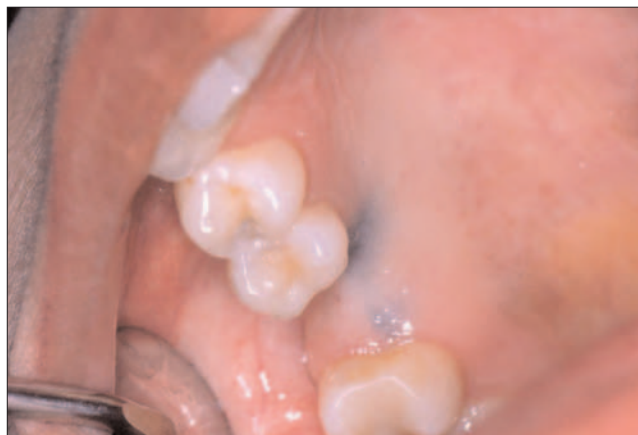

Figure 7: Amalgam tattoo on the right maxillary ridge at an extraction site. The extracted tooth had a large amalgam filling. The lesion was asymptomatic. A periapical radiograph failed to show amalgam particles, and a biopsy was performed (see Fig. 8).

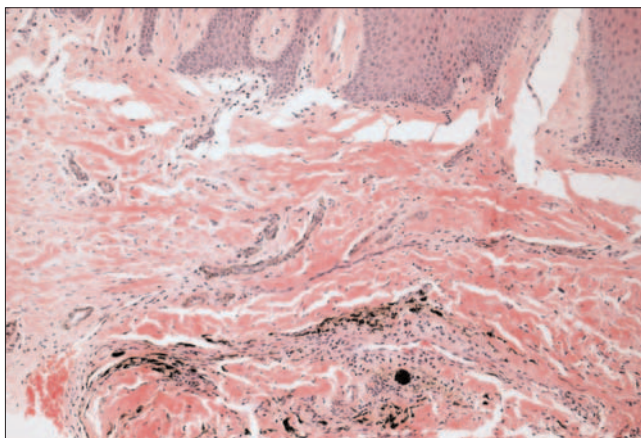


Figure 8: Photomicrograph of the lesion depicted in Fig. 7 showing fine particulate black pigment that demonstrates a marked affinity for collagen fibrils (hematoxylin and eosin, $\times 100$).

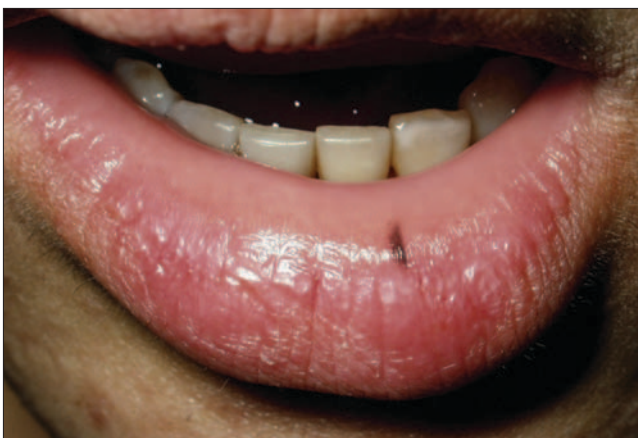

Figure 9: A small, flat brown lesion of the lower lip, which was diagnosed as an oral melanotic macule on the basis of biopsy results. (Photo courtesy of Dr. C. Kilmartin, faculty of dentistry, University of Toronto.)

conditions such as idiopathic thrombocytopenic purpura, or they may result from trauma.²² The colour, produced by the degradation of hemoglobin to bilirubin and biliverdin, varies among red, purple, blue and bluish black depending on the length of time the blood has been present in the extravascular spaces. The colour gradually returns to normal, but this can take up to 2 weeks. If hemorrhagic lesions occur in the absence of recent trauma, the patient should be investigated for platelet disorders and coagulopathies.

Amalgam Tattoo and Other Foreign-Body Pigmentation

Amalgam tattoo is one of the most common causes of intraoral pigmentation.²³ It presents clinically as a localized flat, blue-grey lesion of variable dimensions. The gingiva and alveolar mucosa are the most common sites of involvement, but these lesions may also involve the floor of the mouth and the buccal mucosa (Fig. 7). No signs of inflammation are present at the periphery of the lesion, and the

results of diascopy should be negative. In some cases, especially when the amalgam particles are large enough, they can be seen in intraoral radiographs as fine radiopaque granules.⁹ In these circumstances, the diagnosis of amalgam tattoo can be made on the basis of the clinical and radiographic findings. In case of doubt, a biopsy should be performed to demonstrate the presence of amalgam particles in the connective tissue (Fig. 8).

Graphite may be introduced into the oral mucosa through accidental injury with a graphite pencil. The lesion occurs most frequently in the anterior palate of young children, appearing as an irregular grey to black macule. A history of injury confirms the diagnosis; otherwise, a biopsy should be performed to exclude the possibility of melanoma.⁹

Melanotic Macules

The labial melanotic macule is a benign pigmented lesion that is common on the lower lip,²⁴ (Fig. 9) and the

oral melanotic macule is the same lesion seen inside the oral cavity, most commonly on the gingiva, buccal mucosa and palate.²⁵ Both are caused by increased melanin production with no increase in the number of melanocytes. Melanotic macules are usually smaller than 1 cm in diameter and show a well-demarcated smooth border. They usually occur as single lesions, but multiple lesions are sometimes seen. The colour may be light or dark brown and is homogeneous within each lesion. Melanotic macules are more common in women^{26,27} and young adults. Melanotic macules are benign and are not known to transform into melanoma.²⁷ Biopsy is usually required to establish the diagnosis and to rule out melanoma, especially for lesions involving the palate, where malignant melanoma is most prevalent. No further treatment is required once the diagnosis has been established.

Pigmented Nevi

Pigmented nevi are rare causes of focal oral pigmentation. They present as either brown or blue lesions. Histologically, nevi are composed of an accumulation of nevus cells in the basal epithelial layers, the connective tissue or both. As such, they are classified as junctional, intradermal or intramucosal, and compound nevi. Junctional nevi are flat and dark brown in colour because the nevus cells proliferate at the tips of the rete pegs close to the surface. Intramucosal and compound nevi are typically light brown, dome-shaped lesions. Blue nevi are characterized by proliferation of dermal melanocytes within the deep connective tissue at some distance from the surface epithelium, which accounts for the blue colour. The intramucosal nevus is the most common type and is seen most frequently on the buccal mucosa.²⁸ The blue nevus is the second most common type, occurring most commonly in the palate.²⁸ The mean age at excision is 35 years.

It may be difficult to differentiate clinically between a nevus and an early lesion of mucosal melanoma, especially in the palate, the most common site for both lesions. Although transformation of oral pigmented nevi to melanoma has not been well documented, it is believed that nevi may represent precursor lesions to oral mucosal melanoma.²⁹ It is therefore recommended that these lesions be excised and submitted for histopathologic examination.

Oral Melanoacanthoma

Oral melanoacanthoma is an uncommon benign pigmented lesion of the oral mucosa characterized by proliferation of dendritic melanocytes scattered throughout the thickness of an acanthotic and hyperkeratotic surface epithelium.^{9,30} Clinically, the lesion appears flat or slightly raised and is hyperpigmented, the colour ranging from dark brown to black. This lesion, in contrast to most of the benign pigmented lesions discussed above, has a tendency to enlarge rapidly, which raises the possibility of a

malignant process in the clinical differential diagnosis.³¹ However, its tendency to occur in young black females distinguishes it from melanoma, which is uncommon in this age and racial group. The buccal mucosa is the most common site of occurrence, which may be related to greater frequency of trauma in this area.³⁰ Oral melanoacanthoma appears to be a reactive lesion with no malignant potential. In some cases, the lesion disappears after incisional biopsy or removal of the offending stimulus.³⁰

Oral Melanoma

Oral mucosal melanoma is rare, accounting for less than 1% of all oral malignancies. It is characterized by proliferation of malignant melanocytes along the junction between the epithelial and connective tissues, as well as within the connective tissue. The most common site is the palate, which accounts for about 40% of cases, followed by the gingiva, which accounts for one third of cases.²⁹ Other oral mucosal sites may also be affected. Oral melanoma is generally encountered between the fourth and seventh decades of life, with a greater incidence in men than in women.³² Clinically, oral melanoma may present as an asymptomatic, slow-growing brown or black patch with asymmetric and irregular borders or as a rapidly enlarging mass associated with ulceration, bleeding, pain and bone destruction. Some oral melanomas are nonpigmented (amelanotic).

Although oral mucosal melanomas are rare, they represent a serious and often fatal disease. They tend to be more aggressive than their cutaneous counterparts and present at a later stage of the disease. Treatment involves radical surgical excision with clear margins. This may be difficult to accomplish because of anatomic constraints and proximity to vital structures. Radiation and chemotherapy are ineffective, which adds to the difficulties associated with management of this malignancy. The prognosis for patients with oral melanoma is much worse than for those with cutaneous lesions, and the overall 5-year survival rate is 15%. The best way to improve prognosis is early detection.^{29,33}

Case Reports

Case 1

A 28-year-old East Indian man presented with a pigmented lesion on the buccal mucosa that had been present for many years with no change in size. There was no history of trauma to the area. The patient was in good health and was not taking any medications. Intraoral examination showed a well-demarcated, smooth, dome-shaped lesion on the right buccal mucosa, measuring 7 mm in diameter. The lesion was dark brown with an unpigmented halo at the base (**Fig. 10**). There were no other pigmented lesions on the oral mucosa or the lips.

The differential diagnosis of this focal, raised brown lesion included pigmented nevus, melanoacanthoma and melanoma. Oral melanotic macule was less likely because

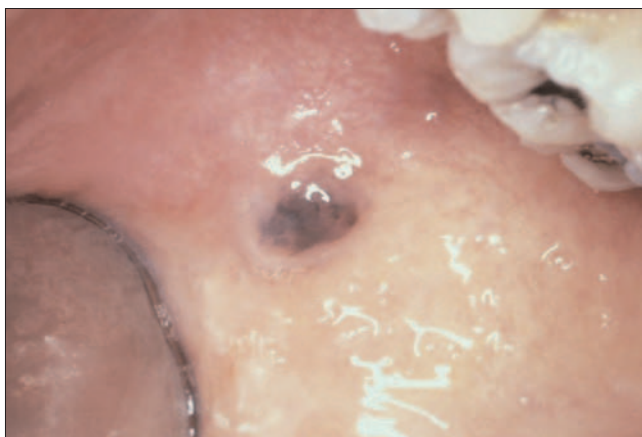


Figure 10: A well-demarcated, smooth, dome-shaped, dark brown lesion on the right buccal mucosa with an unpigmented halo at the base. No other pigmented lesions were observed on the oral mucosa. Biopsy (see **Fig. 11**) revealed a compound nevus.

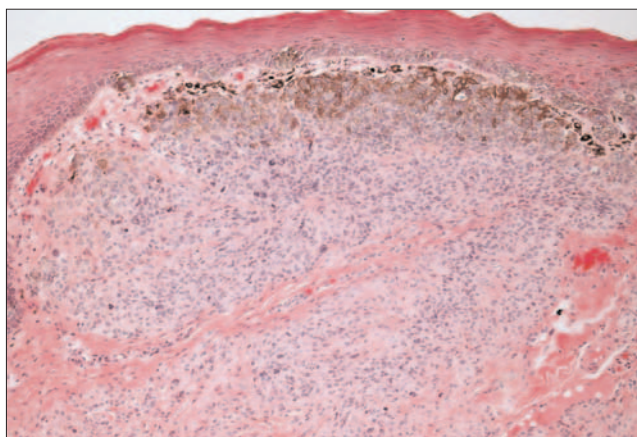


Figure 11: Photomicrograph of the lesion depicted in **Fig. 10** shows a proliferation of pigmented nevus cells forming nests in the superficial connective tissue and at the junction between the epithelial and connective tissues. Melanin pigment was characteristically more abundant in the superficial part of the nevus. (Hematoxylin and eosin, $\times 100$.)

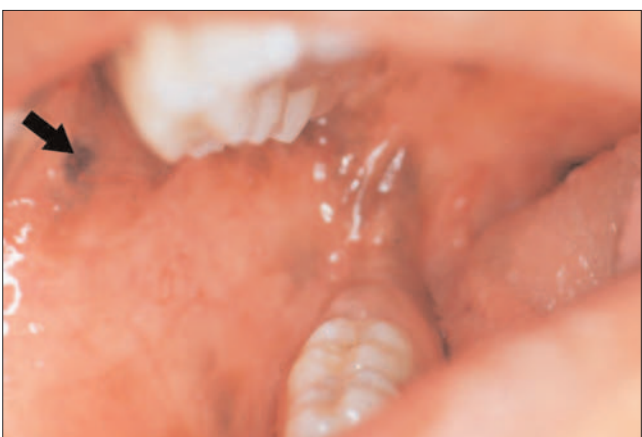

Figure 12: Multiple brown-black patches on the buccal mucosa of a patient who also had pigmented patches on the labial mucosa and tonsillar pillars. The heavily pigmented lesion indicated by the arrow was selected for biopsy (see **Fig. 13**)

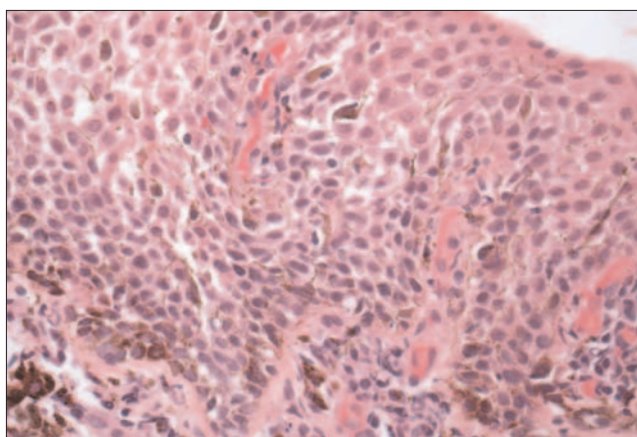


Figure 13: Histologic examination of the lesion depicted in **Fig. 12** showed acanthotic stratified squamous epithelium containing numerous dendritic melanocytes with abundant melanin granules in the cytoplasm. The superficial connective tissue contained a dense chronic inflammatory infiltrate. (Hematoxylin and eosin, $\times 200$.)

the lesion was raised. The colour of the lesion was not consistent with amalgam tattoo or a vascular lesion. The long duration without change in size favoured pigmented nevus over melanoacanthoma and melanoma. Excisional biopsy showed a nodule of oral mucosa with a proliferation of cuboidal and ovoid cells that formed nests in the superficial connective tissue and at the junction between the epithelial and connective tissues. Cells in the most superficially located nests contained abundant melanin in their cytoplasm. The more deeply situated lesional cells were more elongated in shape and grew singly rather than as compact nests. There was no cellular atypia, and no mitotic figures were seen (**Fig. 11**). The diagnosis was compound nevus. By the time of the post-biopsy visit, the biopsy site had healed completely with no evidence of recurrence.

Case 2

A 13-year-old East Indian male presented with pigmented patches on both buccal mucosa that had first been noticed 8 months previously, after a severe allergic reaction to soy, which had resulted in lip and throat swelling. The allergic reaction was successfully treated with antihistamines, but the oral pigmentation increased over the ensuing months. The patient was in good health otherwise and was not taking any other medications. Examination showed multiple brown-black macules and patches on the maxillary and mandibular labial mucosa, the right and left buccal mucosa, and the anterior tonsillar pillars.

The differential diagnosis of multiple pigmented macules and patches in the labial and buccal mucosa of an adolescent, dark-skinned individual included racial

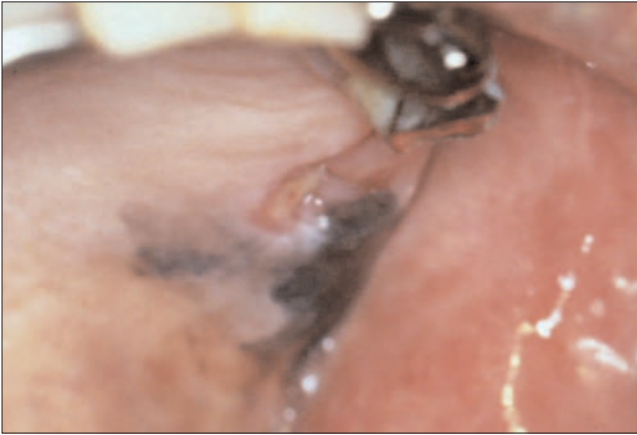

Figure 14: Photograph taken 1 week after extraction of a loose left maxillary molar shows an irregular greyish black patch on the maxillary alveolar ridge, distal and buccal to the extraction socket of the molar. Smaller satellite lesions were present on the palatal mucosa. An incisional biopsy was performed (see Fig. 15).

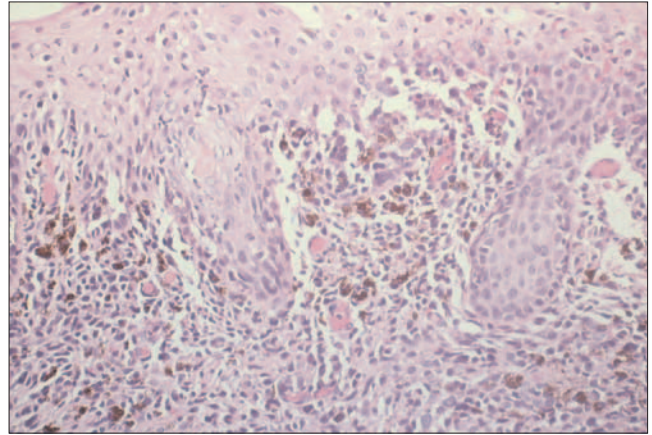


Figure 15: Histologic examination of the lesion depicted in Fig. 14 showed malignant melanocytes invading the superficial connective tissue and the overlying epithelium. Note the cellular pleomorphism and nuclear hyperchromatism. (Hematoxylin and eosin, $\times 125$.)

(physiologic) pigmentation, Addison's disease, postinflammatory pigmentation and drug-induced pigmentation. Physiologic pigmentation was considered most likely, although the relatively rapid onset and the location of the pigmentation were unusual. The patient did not have signs and symptoms suggestive of Addison's disease, was not taking any medications that commonly cause oral pigmentation and did not have a chronic mucosal inflammatory disease that would typically be associated with postinflammatory pigmentation. Biopsy of a dark brown lesion on the right buccal mucosa (Fig. 12) showed oral mucosa covered by acanthotic stratified squamous nonkeratinized epithelium and numerous dendritic melanocytes, with cytoplasmic melanin throughout the epithelium (Fig. 13). The superficial connective tissue contained a dense, chronic inflammatory infiltrate, composed predominantly of plasma cells and eosinophils. There was no cellular atypia to suggest melanoma. The histologic appearance was characteristic of melanoacanthoma. This patient's clinical lesions were unusually extensive for melanoacanthoma, although the condition has been reported to present bilaterally and as pigmented areas several centimetres in diameter.³⁰ No further treatment was indicated, and the patient will be followed clinically to monitor the lesions.

Case 3

A 77-year-old Asian man complained of a loose left maxillary molar. The tooth was heavily restored with a stainless steel crown that had been repaired with an amalgam filling. An irregular greyish black patch was present on the buccal and distal gingiva, with smaller "satellite" lesions on the palatal aspect of the tooth.

The differential diagnosis was a large amalgam tattoo (or similar foreign-body implantation) and melanoma. The tooth was extracted, and an incisional biopsy was taken from the gingiva. Once the tooth had been removed, it

became apparent that the pigmented lesion was larger than had previously been appreciated (Fig. 14). Histologic examination showed oral mucosa in which the lamina propria was infiltrated by pleomorphic cells, some with melanin pigment in the cytoplasm (Fig. 15). Abnormal melanin-containing cells were also present within the stratified squamous epithelium. The diagnosis was malignant melanoma, and the patient was referred to the Head and Neck Oncology Clinic for treatment. ♦



Dr. Kawzman is associate professor, department of stomatology, faculty of dentistry, University of Montreal, Montreal, Quebec.

Dr. Pavone is staff dentist, department of dentistry, Sunnybrook and Women's College Health Science Centre, University of Toronto, Toronto, Ontario.



Dr. Blanas is staff oral and maxillofacial surgeon, department of dentistry, Sunnybrook and Women's College Health Science Centre, University of Toronto, Toronto, Ontario.

Dr. Bradley is associate professor, oral pathology and oral medicine, faculty of dentistry, and Sunnybrook and Women's College Health Science Centre, University of Toronto, Toronto, Ontario.

Correspondence to: Dr. Grace Bradley, Faculty of Dentistry, University of Toronto, 124 Edward St., Toronto, ON M5G 1G6. E-mail: grace.bradley@utoronto.ca.

The authors have no declared financial interests.

References

1. Eisen D. Disorders of pigmentation in the oral cavity. *Clin Dermatol* 2000; 18(5):579–87.
2. Kleinegger CL, Hammond HL, Finkelstein MW. Oral mucosal hyperpigmentation secondary to antimicrobial drug therapy. *Oral Surg Oral Med Oral Pathol Oral Radiol Endod* 2000; 90(2):189–94.
3. Gaeta GM, Satriano RA, Baroni A. Oral pigmented lesions. *Clin Dermatol* 2002; 20(3):286–8.

4. Hemminki A, Markie D, Tomlinson I, Avizienyte E, Roth S, Loukola A, and others. A serine/threonine kinase gene defective in Peutz-Jeghers syndrome. *Nature* 1998; 391(6663):184–7.
5. Hemminki A, Tomlinson I, Markie D, Jarvinen H, Sistonen P, Bjorkqvist AM, and others. Localization of a susceptibility locus for Peutz-Jeghers syndrome to 19p using comparative genomic hybridization and targeted linkage analysis. *Nat Genet* 1997; 15(1):87–90.
6. Hemminki A. The molecular basis and clinical aspects of Peutz-Jeghers syndrome. *Cell Mol Life Sci* 1999; 55(5):735–50.
7. McGrath DR, Spigelman AD. Preventive measures in Peutz-Jeghers syndrome. *Fam Cancer* 2001; 1(2):121–5.
8. Kim HW. Generalized oral and cutaneous hyperpigmentation in Addison's disease. *Odontostomatol Trop* 1988; 11(3):87–90.
9. Neville BW, Damm DD, Allen CM, Bouquot JE, editors. Oral and maxillofacial pathology. 2nd ed. Toronto (ON): W.B. Saunders Company; 2002.
10. Regezi JA, Sciubba JJ, Jordan RC, editors. Oral pathology. Clinical pathologic correlations. 4th ed. Philadelphia: W.B. Saunders; 2003.
11. Dereure O. Drug-induced skin pigmentation. Epidemiology, diagnosis and treatment. *Am J Clin Dermatol* 2001; 2(4):253–62.
12. Birek C, Main JH. Two cases of oral pigmentation associated with quinidine therapy. *Oral Surg Oral Med Oral Pathol* 1988; 66(1):59–61.
13. McAllan LH, Adkins KF. Drug-induced palatal pigmentation. *Aust Dent J* 1986; 31(1):1–4.
14. Savage NW, Barber MT, Adkins KF. Pigmentary changes in rat oral mucosa following antimalarial therapy. *J Oral Pathol* 1986; 15(9):468–71.
15. Westbury LW, Najera A. Minocycline-induced intraoral pharmacogenic pigmentation: case reports and review of the literature. *J Periodontol* 1997; 68(1):84–91.
16. Meyerson MA, Cohen PR, Hymes SR. Lingual hyperpigmentation associated with minocycline therapy. *Oral Surg Oral Med Oral Pathol Oral Radiol Endod* 1995; 79(2):180–4.
17. Halder RM, Nootheti PK. Ethnic skin disorders overview. *J Am Acad Dermatol* 2003; 48(6 Suppl):S143–8.
18. Hedin CA, Axell T. Oral melanin pigmentation in 467 Thai and Malaysian people with special emphasis on smoker's melanosis. *J Oral Pathol Med* 1991; 20(1):8–12.
19. Hedin C, Pindborg JJ, Daftary DK, Mehta FS. Melanin depigmentation of the palatal mucosa in reverse smokers: a preliminary study. *J Oral Pathol Med* 1992; 21(10):440–4.
20. Axell T, Hedin CA. Epidemiologic study of excessive oral melanin pigmentation with special reference to the influence of tobacco habits. *Scand J Dent Res* 1982; 90(6):434–42.
21. Araki S, Murata K, Ushio K, Sakai R. Dose-response relationship between tobacco consumption and melanin pigmentation in the attached gingiva. *Arch Environ Health* 1983; 38(6):375–8.
22. Carpenter WM, Rudd M. Focal, flat pigmentations of the oral mucosa: a clinical approach to the differential diagnosis. *J Calif Dent Assoc* 2000; 28(12):949–54.
23. Perusse R, Blackburn E. Differential diagnosis of pigmented lesions of the oral cavity. *J Can Dent Assoc* 1984; 50(10):783–7.
24. Weathers DR, Corio RL, Crawford BE, Giansanti JS, Page LR. The labial melanotic macule. *Oral Surg Oral Med Oral Pathol* 1976; 42(2):196–205.
25. Page LR, Corio RL, Crawford BE, Giansanti JS, Weathers DR. The oral melanotic macule. *Oral Surg Oral Med Oral Pathol* 1977; 44(2):219–26.
26. Buchner A, Hansen LS. Melanotic macule of the oral mucosa. A clinicopathologic study of 105 cases. *Oral Surg Oral Med Oral Pathol* 1979; 48(3):244–9.
27. Gupta G, Williams RE, Mackie RM. The labial melanotic macule: a review of 79 cases. *Br J Dermatol* 1997; 136(5):772–5.
28. Buchner A, Hansen LS. Pigmented nevi of the oral mucosa: a clinicopathologic study of 36 new cases and review of 155 cases from the literature. Part II: analysis of 191 cases. *Oral Surg Oral Med Oral Pathol* 1987; 63(6):676–82.
29. Hicks MJ, Flaitz CM. Oral mucosal melanoma: epidemiology and pathobiology. *Oral Oncol* 2000; 36(2):152–69.
30. Goode RK, Crawford BE, Callihan MD, Neville BW. Oral melanoacanthoma. Review of the literature and report of ten cases. *Oral Surg Oral Med Oral Pathol* 1983; 56(6):622–8.
31. Whitt JC, Jennings DR, Arendt DM, Vinton JR. Rapidly expanding pigmented lesion of the buccal mucosa. *J Am Dent Assoc* 1988; 117(5):620–2.
32. Barker BF, Carpenter WM, Daniels TE, Kahn MA, Leider AS, Lozada-Nur F, and others. Oral mucosal melanomas: the WESTOP Banff workshop proceedings. Western Society of Teachers of Oral Pathology. *Oral Surg Oral Med Oral Pathol Oral Radiol Endod* 1997; 83(6):672–9.
33. Gorsky M, Epstein JB. Melanoma arising from the mucosal surfaces of the head and neck. *Oral Surg Oral Med Oral Pathol Oral Radiol Endod* 1998; 86(6):715–9.