

Unravelling white patches of the mouth

EDUCATION

AUTHOR

Dr Mark Watts

Oral & Maxillofacial Surgery Unit,
Royal Devon & Exeter Hospital

Dr Zarina Shaikh

Oral & Maxillofacial Surgery Unit,
Royal Cornwall Hospital

Address for Correspondence:

Dr Mark Watts
Department of Oral & Maxillofacial
Surgery
The Royal Devon & Exeter Hospital
Barrack Road
Exeter EX2 5DW
United Kingdom

Email: mw9773@my.bristol.ac.uk

ORCID ID: 0000-0003-4615-0314

No conflicts of interest to declare.

Accepted for publication: 25.07.21

ABSTRACT

Summary

This article aims to provide a guide for medical students and junior doctors on how to carry out a focused clerking of patients that present with intra-oral white lesions. In addition, it summarises the most common diagnoses as well as their management. Advice is given on how to quickly identify which lesions are likely to be malignant and how to manage such patients safely. 'Best of five' multiple-choice questions are provided to help with application and consolidation of knowledge.

Relevance and Take-Home Messages

Doctors and medical students need not panic when presented with a patient that has intra-oral white patches. This step-by-step guide will allow them to clerk these patients with more precision and confidence. It provides a deeper insight into which lesions are more likely to be dysplastic or in-situ carcinomas as well as how to safely manage and make onward referrals to the relevant specialty.

INTRODUCTION

White patches of the oral cavity are common and diverse, and although the majority represent benign disease, some are malignant. Establishing the correct diagnosis early on is key. Clinicians have a responsibility to be aware of them and minimise the potentially detrimental consequences of delayed diagnosis and treatment. This article aims to provide a simple way of systematically examining these lesions. Examination of the mouth can be overlooked when a patient is admitted into hospital for other problems, however, it is important for this to be done as part of a primary clerking so that the appropriate action, such as a specialist referral if indicated, can be taken.

It is not uncommon for white patches in the mouth to be asymptomatic and these cases are often picked up as a result of the diligence of dental or medical practitioners who have noticed the lesions as part of a thorough examination. (1-3)

Presenting Complaint & History

A patient may be referred by a doctor, dentist or present acutely in the emergency department. A structured history is essential for establishing a differential diagnosis.

Important questions to ask the patient are:

- Where is the white patch and how long has it been there?
- Is there one isolated lesion or are there multiple?
- If multiple, are they unilateral or bilateral?
- Is it soft or firm?
- Is it changing?
- Did it suddenly appear?
- Is it growing or shrinking?
- Does it come and go?
- Does it change location in the mouth?
- Does it change in colour?
- Are there any associated or relieving factors?
- Do hot & spicy foods, or toothpaste make it worse?
- Are any sharp teeth or dentures rubbing against the lesion?
- Pain? – Site, onset, character, radiation, relieving or exacerbating factors, severity (scale of 1 to 10)
- Does it bleed?
- Is it ulcerated? (1)

Relevant medical and social history

The oral cavity is bathed in saliva. Saliva has an immunological and protective role to maintain a healthy oral flora and dentition and further assists in healing and cellular turnover.

Reduction in the volume or quality of saliva can have significant repercussions for the balance of this dynamic environment. In addition, the mucosal lining of the mouth has a rapid turnover in response to the repeated trauma of daily use. Some medical conditions and medication can upset this balance giving rise to intra-oral white patches. These include:

- Dermatological disease (e.g. lichen planus or lupus erythematosus)
- Haematological disease (e.g. associated with anaemia)
- Immunosuppressed states (uncontrolled diabetes, HIV), immunosuppressant medication including corticosteroids (systemic and inhaled), immunomodulators and chemotherapy (2,3)
- Iatrogenic (e.g. through the use of broad-spectrum antibiotics giving rise to opportunistic infections and steroid inhalers giving rise to candida infections which often present at the junction of the hard and soft palate)

Tobacco and alcohol habits are strongly related to many pre-malignant intra-oral white patches and their synergistic effect compounds their malignant potential. (4) Other recreational drugs such as betel nut and paan are implicated, specifically in sub-mucous fibrosis. Patients with psychological illness may inflict artefactual trauma to their mouths resulting in the formation of characteristic marks or patterns. (2,3)

See Table 1. for detail relating to specific white patches.

Examination

An extra-oral examination should be carried out first to check for signs of systemic disease, such as nail bed changes, pigmented or scaly lesions, rashes and papules on the arms, legs and genitals and palpable cervical lymph nodes (see Table 1. for relevance). The mouth should be examined in a systematic manner so as to avoid missing a lesion. Start at the front and work backwards.

A. Soft tissues:

Lips (including commissures) →labial mucosa (including sulci) →buccal mucosa (including sulci) →gingiva around all teeth, labial, buccal, lingual surfaces and behind the last standing molar teeth, including the retromolar trigone region →floor of the mouth (anterior, posterior, lingual gutter) →tongue (ventral, lateral and dorsal surfaces, you can use gauze to gently hold and pull the tongue out to gain a proper view), posterior tongue and oropharynx →hard, soft palate, uvula and tonsils.

B. Hard tissues:

Palpation of teeth and bone. Gentle tapping of teeth to check if any teeth are tender to tap, which would raise your suspicion of an associated dental infection. If patients are wearing dentures, check the

soft and hard tissues under the dentures. Check for poorly fitting dentures, sharp teeth or cheek biting trauma.

The clinical photographs in Figure 1. can be used as a guide.

A good torch and a dental mirror will aid your assessment. If a dental mirror isn't available, a tongue depressor will suffice. Be aware that lesions located in the depths of the patients' sulci and under the tongue and retro-molar area are often missed.

Describe any lesions found as follows:

- site
- size (in mm or cm)
- shape
- outline (regular or irregular)
- colour (it may be a mixed red and white lesion which is more concerning)
- texture (e.g. smooth, speckled, striated)

Asking the patient to take their own photographs at home can help with monitoring or diagnosis of lesions if they wax and wane. Clinical photography with appropriate patient consent is also good practice.

Red Flags

- Does the lesion look ulcerated with raised/rolled margins?
- Is the lesion rapidly growing?
- Is it a mixed red and white patch? (erythroleukoplakia)
- Is the lesion rough, tender & friable?
- Is the base granular? (i.e. does it feel rough and appear bumpy, 'cobblestone' like, rather than smooth and homogeneous)
- Any evidence of induration? (Fixed to underlying tissues)
- Any unexplained looseness of teeth specifically associated to the lesion?
- Does the lesion bleed to the touch?
- Is there any facial numbness or weakness? e.g. lips, cheeks
- Is there any unexplained loss of weight?
- Is there any ear pain? (otalgia) - ask in particular for unilateral otalgia
- Pain on swallowing? (odynophagia)
- Difficulty swallowing? (dysphagia)
- Change in voice? (dysphonia)

These signs should raise your suspicion of malignancy, particularly if it is an isolated, ulcerated lesion that has been present for more than three weeks. The position of the lesion can also be a prognostic indicator: White patches that are found to be squamous cell carcinomas are generally more likely to metastasise to regional lymph nodes if found in the posterior part of the oral cavity. (5) The floor of the mouth is also high risk as chemicals collect there and it is often missed. (5)

Investigations

These may include blood tests (e.g. full blood count, haematinics), viral, bacterial, fungal swabs and concentrated oral rinse cultures (CRCs) for fungus.

An incisional or excisional biopsy may be required. If an intra-oral white patch requires a biopsy, for the vast majority of cases an incisional biopsy is preferred. This involves taking a sample of tissue at the margin of the abnormal site including a margin of adjacent normal tissue. An excisional biopsy or an excision is usually only taken when the clinician is more certain of the diagnosis. If the lesion is highly suspicious, additional imaging may also be required following discussion and assessment by the maxillofacial team. See Table 1. for special investigations required for the diagnosis you are suspecting.

Diagnosis

Using all the information you have gathered so far, a working diagnosis for the intra-oral white patch, or patches, can be made (see Table 1.).

Management

The specific management of white patches can vary considerably depending on the patient history, clinical appearance, changes in appearance and the differential or definitive diagnosis. Generally, the precipitating causes are corrected first. Treatment may include:

- Counselling or referral for cessation of smoking and reduction of alcohol consumption (especially for malignant and pre-malignant lesions)
- Management of associated comorbidities and correction of associated haematological abnormalities (such as deficiencies of vitamin B12, iron and folate)
- Trauma reduction - consider referral to a dentist to smooth sharp teeth or denture edges. Address any self-inflicted harm. Many of these lesions will resolve spontaneously after removal of the cause. Protective bite guards can also be helpful.
- Symptomatic relief such as use of chlorhexidine mouthwash, steroid mouthwashes and sprays. Systemic medication may be required in refractory cases.

White patches may be super-infected with fungus such as candida which should be treated if detected. The same goes for any virus or potentially causal non-commensal or pathogenic bacteria which may be isolated on an oral swab or rinse. Using a spacer cone for steroid inhaler use and rinsing the mouth with water after use can reduce opportunistic fungal infections. Topical anti-fungal medication can be used, progressing to systemic if unresponsive. Where

possible, avoid prescribing multiple courses of broad-spectrum antimicrobials, instruct patients on maintaining good oral and denture hygiene and manage xerostomia with continuous hydration and saliva substitutes (pastilles, drops or gels). This will help to better manage and reduce the risk of oral candidiasis.

Monitoring of white patches is essential and is more frequent for dysplastic lesions, diagrams can be drawn, patients can be educated and clinical photographs can be a helpful adjuvant. (2,3)

When to Biopsy

If the intra-oral white patch is associated with any of the red flags, consider an urgent incisional biopsy within two weeks to rule out a malignancy (see Table 1). If the white patch does not appear to be associated with any of the aforementioned red flags and is clearly associated with a reversible cause only, the cause should be addressed and the patient should be reviewed after a few weeks to assess the effects of your measures and to see if they have adhered to advice such as smoking and alcohol cessation. If there is no improvement or worsening in the symptoms or appearance of the lesion, consideration should then be given for an incisional biopsy.

Biopsy-proven mildly dysplastic white patches can be reviewed by the patient's dentist on a three- to six-monthly basis with continued efforts for smoking and alcohol cessation and a healthier diet plan as appropriate. Re-referral to Oral & Maxillofacial Surgery (OMFS) can be made if the lesion changes. White patches with moderate or severe dysplasia are usually excised before they can develop into carcinomas. (2,3)

How do I make sure I am safe and how do I refer a patient with a white patch?

There are two arms on the pathway for these referrals, one is to the patient's dentist and the other is to the Oral & Maxillofacial Surgery (OMFS) Department.

Some white patches are pre-malignant and therefore if there is any uncertainty regarding the diagnosis of malignancy, or degree of dysplasia, an urgent two-week wait referral should be made to the OMFS team. The national guidance below can be used. A referral can be done by letter or via an electronic referral system if one is available. If a lesion is found not to be malignant but needs symptomatic relief or monitoring, it can be referred to, or reviewed by a dentist. Ensure the patient is registered with a dentist. If access to dental care is poor, referrals with clinical photographs including patients' own mobile phone photographs attached to referrals can help streamline referrals. Ensure any photographs used are managed in line with information governance policy for the region that you work in.

What are the national guidelines for referral?

The most recognised referral guideline is the Head and Neck Cancer Guideline published by the National Institute for Health and Care Excellence (NICE).

Regarding white patches, it states: "Consider an urgent referral (for an appointment within two weeks) for assessment for possible oral cancer by a dentist in people who have a red or red and white patch in the oral cavity consistent with erythroplakia or erythroleukoplakia." (6)

The guidance states that if the above lesion is detected by a dentist, that an onward "cancer pathway" referral should be considered by that dentist i.e. to be seen by the OMFS team within two weeks. However, if you are highly suspicious that the oral lesion is cancer, please refer to OMFS, not the patient's dentist, as a delay such as this can result in a delay to the patient's diagnosis and a worse prognosis.

The NICE guidance also states that if the white patch is associated with an ulcer lasting more than three weeks or a persistent and unexplained lump in the neck, an urgent cancer pathway referral (to be seen in two weeks by OMFS) should be considered. (6)

How to document and pass the information to the next team

Documentation, even if it is brief, should be in the format of a history as described above, including relevant findings of an examination and previous treatment given. If the patient is systemically unwell with the lesion, contact the on-call clinician in OMFS via bleep or hospital switchboard. Otherwise, the patient can be referred to the OMFS team via the pathway described above.

What's new on this topic?

Research is being conducted into aiding early detection and diagnosis of dysplastic intra-oral white patches. For example, use of chemiluminescence which involves the use of incandescent light and toluidine blue dye to identify the lesions. A recent study has suggested a high specificity and sensitivity for diagnosis with this technique. Although it does not replace the gold standard of histopathological diagnosis, it can help to identify the extent of the lesions on examination. (7)

DISCUSSION

Oral white lesions are varied and at times complex to diagnose. Using a systematic and thorough approach to history-taking and examination, makes establishing the correct diagnosis and instigation of successful management more likely. The integration of multidisciplinary care both in the community and through hospital referral is something that every doctor should be aware of and use where indicated to optimise the care delivered. Although often inadequately covered in medical training, the hope is that students and doctors will use this guide and further reading to ensure that all patients being admitted into hospital have an assessment of their mouth to screen for concerning lesions as part of their initial clerking. With experience, the clinician can diagnose many systemic conditions from lesions in the mouth. To further knowledge and experience in oral medicine, the authors recommend that junior doctors and medical students consider organising a period of observation with their local oral medicine or OMFS department.

Table 1. INTRA-ORAL WHITE PATCHES – SPOT DIAGNOSIS		
BENIGN	Key clinical features	Relevant special investigations
Linea alba	Distinct white line (not always straight) in the cheeks, usually next to where the teeth meet	Nil
Fordyce spots	Represent ectopic sebaceous glands – small, usually multiple spots measuring 1-2mm in the mouth; commonly buccal mucosae; yellow/white	Nil
Chemical burns	White friable slough, often easily removed to leave a bed of redness and ulceration (commonly due to incorrect use of aspirin as topical pain relief)	Nil
Leukoedema	Whitish-grey filmy appearance of mucosa, common in buccal mucosae – disappears on stretching of the mucosa.	Nil
White sponge naevus	Asymptomatic white lesions in several mucosal sites – particularly buccal mucosa, also affects mucosa of vagina, vulva, anus and oesophagus. Commonly affects other family members, developmental but often only noticed in second decade of life. Mutations in gene coding for keratin.	Nil
Coated tongue	Whiteness or other discolouration of the tongue when there is a failure of exfoliation of surface epithelial cells – often occurs in patients with febrile illnesses who are not eating much or who are on a soft diet – can also be orange or brown depending on external factors such as tea/coffee and smoking.	Oral fungal swab or rinse
Frictional keratosis	Corrugated or thickened white patch, commonly lips, lateral tongue and buccal mucosa along the line of teeth biting	Nil – sometimes requires fungal swab /biopsy
Geographic tongue	Irregular de-papillated red areas on the tongue surrounded by pale white well demarcated margins – mostly occurs on the dorsum and lateral borders of the tongue, appear and disappear over a period of a few days (sometimes longer) and move around different areas of the tongue/mouth – some people complain of discomfort on eating, especially hot and spicy foods.	Full blood count, haematinics (Zinc if no other cause identified)
Pseudomembranous candidiasis	Common in the immunocompromised, elderly and infants. Soft creamy-yellow white patches, can affect large areas, can be wiped off. Local causes: courses of antibiotics, steroids (systemic and inhalers), smoking, under un-clean dentures/wearing dentures at night. Systemic causes: HIV, Blood dyscrasias, uncontrolled diabetes, transplant patients.	Oral fungal swab or rinse
Nicotinic stomatitis (Smoker's keratosis)	Heat and chemicals from tobacco produces whiteness with "punctate" red dots marking out minor salivary glands, most commonly on the hard palate, although can affect other areas. If a denture is worn, it will form around it. If on the palate, very low risk of malignant transformation.	Nil, incisional biopsy if looks sinister
Hairy leukoplakia	Asymptomatic, corrugated white lesion along lateral tongue border only, commonly associated with Epstein-Barr virus (EBV) – common in the immunocompromised e.g. HIV, immunosuppression after organ transplantation	Full blood count, fungal swab, HIV test
Lupus erythematosus (discoid vs systemic)	Can look like lichen planus in the mouth (striated keratotic, can be red) discoid version often has raised, red scaly patches on sun exposed skin. Systemic version has multi-system organ involvement resulting in kidney, pulmonary, cardiac & joint disease. May have a butterfly rash on the skin of the face (commonly zygomatic processes of the maxilla). May have dry mouth and eyes with Sjogren's syndrome.	Incisional biopsy Anti-nuclear anti-bodies Rheumatoid factor, SSA & SSB antigen
Pyostomatitis vegetans	Common in patients with inflammatory bowel disease (e.g. Crohn's, ulcerative colitis) – redness anywhere in the mouth leading to 2-3mm yellow pustules which can progress to larger vegetating lesions of the oral mucosa.	May require biopsy if unsure, full blood count, C-reactive protein (CRP)
Graft-versus-host disease (GVHD)	Usually in the chronic form i.e. more than 100 days after a bone marrow transplant – mimics forms of auto-immune disease. In the mouth there may be white reticular lesions that resemble erosive lichen planus. Patients may complain of burning secondary to candidiasis or dry mouth	Nil – biopsy if looks sinister

Table 1: This has been created by the authors to summarise features of intra-oral white patches to help with differential diagnosis. (1) (2) (3) (8)

Please note that this is not an exhaustive list and in particular does not include some rare hereditary conditions. It is also important to note that other lesions in the mouth may present as white patches at some stage if they have been traumatised.

Table 1: INTRA-ORAL WHITE PATCHES – SPOT DIAGNOSIS		
MALIGNANT & PRE-MALIGNANT	Key Clinical Features	Relevant special investigations
Squamous cell carcinoma (SCC)	Alcohol, tobacco and paan chewing are common contributing factors, sun exposure common for lip. Can take many forms, however as a white patch it is often painless to palpation in the early stages with irregular margins and induration. Often associated with local soft tissue trauma (e.g. sharp tooth). Can arise anywhere in the mouth, although most common under the tongue and behind the lower molar teeth.	Incisional biopsy; staging scans as necessary (MRI, CT)
Lichen planus	Variable appearance – reticular “fisherman’s net” appearance or papular, plaque-like, atrophic or erosive types. Patients experience oral soreness or burning over the lesions, often to hot, spicy or acidic foods. It can affect all oral mucosa, commonly the buccal mucosa and gingiva. Initially patients may also have purple pruritic papules on flexor surfaces of their arms, legs and genitals. Low risk of malignant transformation.	Incisional biopsy May require a full blood count and anti-nuclear antibodies
Lichenoid reaction	Similar appearance to Lichen planus but often presents next to metal fillings (e.g. amalgam), metal tooth crowns, and rarely white fillings. Some contributory medication e.g. hypoglycaemics, antihypertensives and NSAIDS. Low risk of malignant transformation.	Incisional biopsy
Chronic hyperplastic candidiasis (CHC)	Similar causes to pseudomembranous candidiasis – commonly associated with heavy smoking and alcohol habit. White patch in the buccal mucosa (corner of the mouth close to the lip commissure) or tongue. Can vary from a faint white patch to an indurated ulcer with a white/yellow slough. Does not rub off. High risk of malignant transformation.	Incisional biopsy Oral fungal swab and rinse
Leukoplakia	A white patch or plaque on the oral mucosa that cannot be rubbed off or characterised clinically as any specific disease i.e. diagnosis of exclusion. Can be mixed red and white “speckled” and thickened leathery appearances which are the most concerning, tongue and floor of mouth are higher risk sites for malignancy. Other appearances include flat white patches and wart-like lesions. Tobacco and alcohol habit common. Low to moderate risk of malignant transformation.	Incisional biopsy May require haematinics and full blood count Fungal swab if suspected overlying candida
Submucous fibrosis	Most commonly present as fibrous bands that can be palpated in the buccal mucosae or palate – chewing betel nut (areca) is the primary cause, patients will often deny usage or be chewing a product with betel nut in with a different brand name. Chillies in the diet and haematinic deficiencies can worsen the condition. Moderate to high risk of malignant transformation.	Incisional biopsy May require haematinics

Table 1 continued: This has been created by the authors to summarise features of intra-oral white patches to help with differential diagnosis. (1) (2) (3) (8)

Please note that this is not an exhaustive list and in particular does not include some rare hereditary conditions. It is also important to note that other lesions in the mouth may present as white patches at some stage if they have been traumatised.

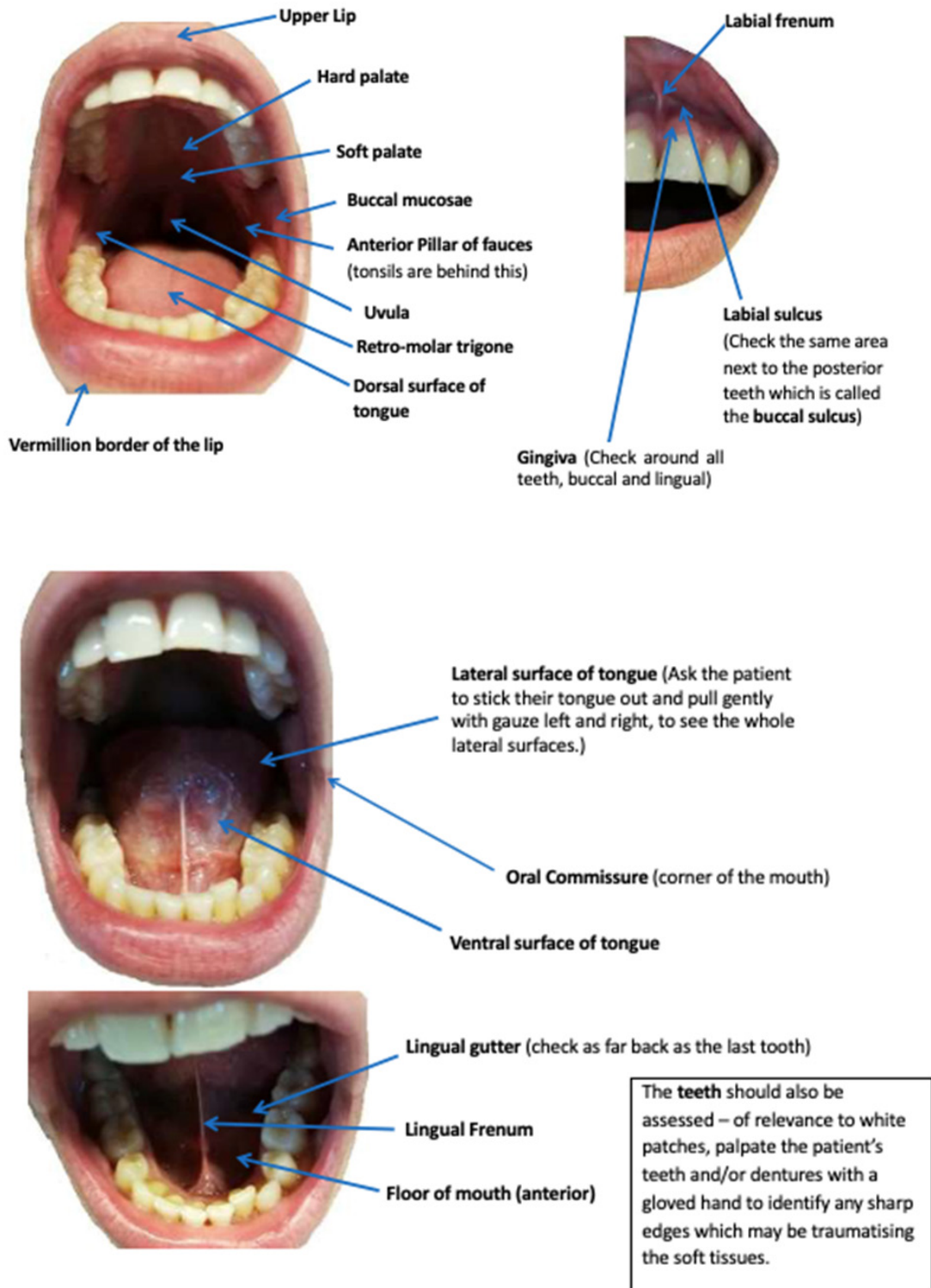


Figure 1: Clinical photographs of normal clinical anatomy. Photographs owned by the authors.

Multiple-Choice Questions (MCQs)*Best of five – select the single best answer.***1.) A white patch occurring in which area of the mouth has the highest malignant potential out of the following options?**

- a. lip
- b. palate
- c. buccal mucosa (BM)
- d. floor of mouth (FOM)
- e. gingiva

2.) Which of the following appearances of a white patch in the mouth is most concerning?

- a. white friable slough
- b. mixed red and white patch, indurated
- c. corrugated, rough
- d. faint white lines, fisherman's net appearance
- e. multiple white/yellow 2–3mm spots

3.) You are working as a ward doctor in cardiology. A nurse asks you to review a 92 year-old gentleman that they notice has a large white patch in the left cheek. You notice that the white patch is in the cheek next to where the teeth bite, it is a diffuse white patch, striated and is not sore to palpation. The patient informs you that it was a little sore after drinking orange juice. What is the most likely diagnosis?

- a. frictional keratosis
- b. leukoplakia
- c. lichen planus
- d. linea alba
- e. pseudomembranous candidiasis

4.) You are working as a ward doctor in haematology. A nurse asks you to review a 50 year-old female patient with acute myeloid leukaemia who has had a bone marrow transplant. They inform you that the patient is complaining of a growth on her tongue. On examination, there are a few smooth red areas on the front of the tongue surrounded by flat white ring-like patches. There is no growth, swelling or roughness and it is not particularly sore to touch. The patient reported that she only noticed it yesterday and that last week there was a similar lesion on the back of her tongue which has now disappeared. What is the most likely diagnosis?

- a. oral hairy leukoplakia
- b. squamous cell carcinoma (SCC)
- c. related to graft-versus-host disease (GVHD)
- d. geographic tongue
- e. coated tongue

5.) Which intra-oral white patch is the most urgent to carry out an incisional biopsy on?

- a. lichenoid reaction
- b. pyostomatitis vegetans
- c. frictional keratosis
- d. leukoedema
- e. chronic hyperplastic candidiasis (CHC)

MCQ answers

- 1.) The answer is *d. floor of mouth*. This area is often missed on examination under the tongue.
- 2.) The answer is *b. mixed red and white patch*, indurated, as these clinical signs make the lesion more likely to be dysplastic or an in-situ carcinoma. (a. is most likely to be frictional keratosis, c. leukoplakia, d. lichen planus and e. Fordyce spots).
- 3.) The answer is *c. lichen planus* – the key clues here were the striated appearance and soreness on drinking orange juice. Frictional keratosis usually presents as a lesion that is rough and sore to palpation. Pseudomembranous candidiasis would wipe off, sometimes leaving an area of redness.
- 4.) The answer is *d. geographic tongue*, given the classically described clinical appearance and the intermittent nature of the lesions. You would think about graft-versus-host disease given the patient's history, however its appearance is usually more severe than described and would not be intermittent.
- 5.) The answer is *e. chronic hyperplastic candidiasis (CHC)* as it has the highest risk of malignant transformation compared to the rest of the options. Leukoedema and pyostomatitis vegetans have no potential for malignant transformation.

REFERENCES

1. Odell EW. *Cawson's Essentials of Oral Pathology & Oral Medicine*. 9th Edition. London: Elsevier Publishing; 2017.
2. Scully C, Felix D. Oral Medicine — Update for the dental practitioner: Oral white patches. *Br Dent J*. 2005; 199:565–572.
doi: 10.1038/sj.bdj.4812901
PMID: 16288249
3. Lewis M, Jordan R. *Oral Medicine, Second Edition (A Colour Handbook)*. London: Manson Publishing Ltd; 2012.
4. Mello FW, Melo G, Pasetto JJ, Silva CAB, Warnakulasuriya S, Rivero ERC. The synergistic effect of tobacco and alcohol consumption in oral squamous cell carcinoma: a systematic review and meta-analysis. *Clin Oral Investig*. 2019; 23:2849–2859.
doi: 10.1007/s00784-019-02958-1
5. Feller L, Lemmer J. Oral Squamous Cell Carcinoma: Epidemiology, Clinical Presentation and Treatment. *Journal of Cancer Therapy*. 2012; 3:263–268.
doi: 10.4236/jct.2012.34037.
6. National Institute of Health & Care Excellence. Head and neck cancers – recognition and referral (Last revised in February 2021). Available from: <https://cks.nice.org.uk/head-and-neck-cancers-recognition-and-referral#!topicsummary> [accessed 21st April 2021].
7. Jain N, Nagarajappa AK, Bhasin M, Pandya D, Tripathi KP. Role of chemiluminescence examination as non-invasive diagnostic tool in early detection of leukoplakia. *J Oral Biol Craniofac Res*. 2018;8:177–181.
doi: 10.1016/j.jobcr.2017.04.004
8. Warnakulasuriya S, Johnson W, Van Der Waal I. Nomenclature and classification of potentially malignant disorders of the oral mucosa. *J Oral Pathol Med*. 2007; 36:575–580. Available from:
doi: 10.1111/j.1600-0714.2007.00582.x



The **British Student Doctor** is an open access journal, which means that all content is available without charge to the user or his/her institution. You are allowed to read, download, copy, distribute, print, search, or link to the full texts of the articles in this journal without asking prior permission from either the publisher or the author.

bsdj.org.uk



[/thebsdj](https://www.facebook.com/thebsdj)



[@thebsdj](https://twitter.com/thebsdj)



[@thebsdj](https://www.instagram.com/thebsdj)

Journal DOI

[10.18573/issn.2514-3174](https://doi.org/10.18573/issn.2514-3174)

Issue DOI

[10.18573/bsdj.v5i3](https://doi.org/10.18573/bsdj.v5i3)



The **British Student Doctor** is published by **The Foundation for Medical Publishing**, a charitable incorporated organisation registered in England and Wales (Charity No. 1189006), and a subsidiary of **The Academy of Medical Educators**.

This journal is licensed under a Creative Commons Attribution-NonCommercial-NoDerivatives 4.0 International License. The copyright of all articles belongs to **The Foundation for Medical Publishing**, and a citation should be made when any article is quoted, used or referred to in another work.



Cardiff University Press
Gwasg Prifysgol Caerdydd

The **British Student Doctor** is an imprint of Cardiff University Press, an innovative open-access publisher of academic research, where 'open-access' means free for both readers and writers.

cardiffuniversitypress.org