

FOOT AND ANKLE

Anatomy.....	111	Accessory Navicular Bone.....	120
Mechanics.....	113	Flatfoot.....	121
Tripod.....	113	Skewfoot.....	123
Acetabulum Pedis.....	113	Calcaneovalgus.....	123
Evaluation.....	113	Hindfoot.....	123
History.....	113	Clubfoot.....	123
Physical Examination.....	113	Pathomechanics.....	124
Imaging.....	114	Vertical Talus.....	127
Toe Disorders.....	115	Tarsal Coalition.....	128
Syndactyly.....	115	Ankle.....	129
Polydactyly.....	115	Toe Walking.....	129
Curly Toe.....	115	Ball and Socket Ankle.....	129
Claw Toe.....	115	Tarsal Tunnel Syndrome.....	129
Hammer Toe.....	116	Os Trigonum.....	130
Mallet Toe.....	116	Osteochondrosis.....	130
Overlapping Toe.....	116	Sever.....	130
Bunion.....	116	Köhler.....	130
Bunionette.....	117	Freiberg Infraction.....	131
Dorsal Bunion.....	117	Tumors.....	131
Hallux Rigidus.....	117	Soft Tissue.....	131
Hallux Varus.....	117	Bone.....	131
Macroductyly.....	117	Infection.....	132
Forefoot.....	118	Puncture Wounds.....	132
Metatarsus Adductus.....	118	Paronychia.....	132
Brachymetatarsia.....	118		
Midfoot.....	118		
Cavus.....	118		

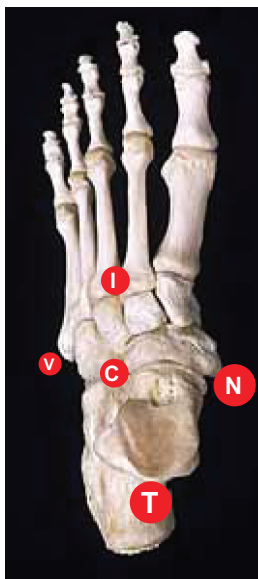
ANATOMY

Greek *πους* (root *ποδ-*) is Latin *pes* (root *ped-*): “foot”, which gives the root *-ped-* in English. Do not confuse Greek *παις* (root *παιδ-*): “child”, which is represented in American usage as *-ped-* after the custom of simplifying diphthongs, as in *Pediatrics*. The only exception in American usage is the term *Orthopædic*, which retains the diphthong to avoid limitation of scope to the foot.

The foot may be divided into hindfoot, midfoot, and forefoot [A]. The hindfoot consists of the talus and calcaneus. Latin *talus* is Greek *αστραγαλος*: *astragalus*. The midfoot is made up of cuboid bone, navicular bone, and the three cuneiform bones (medial, intermediate, and lateral, or numbered). Latin *navicula* is Greek *σκαφη*: “small boat, *skiff*,” to describe the bone’s shape; hence the distinction “tarsal navicular or scaphoid.” The forefoot includes metatarsal bones and phalanges. Hindfoot and midfoot correspond to the galenic concept of *ταρσος*: “*tarsus*,” as the equivalent in the foot of *καρπος*: “*carpus*” in the hand. The mid- or transverse tarsal joint, through which the French surgeon François Chopart (1743–1795) recommended amputation, consists of talonavicular and calcaneocuboid articulations. The French surgeon Jacques Lisfranc de St. Martin (1790–1847) favored amputation at the junction of tarsus and metatarsus, from Greek *μετα-*: “next”.

A Nomenclature for normal function and disease The two entities are named independently.

Site	Motion	Deformity
Ankle	Plantar flexion (extension)	Equinus
	Dorsiflexion (flexion)	Calcaneus
Subtalar joint	Inversion	Varus
	Eversion	Valgus
Heel	Dorsad <i>pitch</i> at rest	↑ Calcaneus
		↓ Equinus
Midfoot	Coronal plane	Adductus Abductus
	Sagittal plane	Cavus Planus
Forefoot	Axial plane	Pronation Supination
Toes	Distal interphalangeal flexion	Mallet
	Intermediate phalangeal flexion	Hammer
	Interphalangeal flexion + metatarsophalangeal extension	Claw
Hallux	Adduction	Valgus
	Abduction	Varus



B Accessoria of the foot T: os trigonum (15%). N: naviculare accessorium (15%). C: calcaneus secundarius (5%). I: os intermetatarsium (5%). V: os vesalianum (rare).

Distinguish normal motion from morbid deformity [A]. This resembles the distinction of version (normal “turning” of a part of a long bone) from torsion (abnormal or “excessive”) for long bones of the lower limb. When ankle plantar flexion exceeds the normal range or is fixed (eliminating dorsiflexion) due to disease, this is known as equinus, from Latin *equus*: “horse,” after the posture of a horse’s foot. The opposite is known as calcaneus, after the bone that is most distinctive in the deformity. The midfoot and forefoot do not move actively but may be deformed. Adductus describes “direction toward” and abductus “direction away” from the midaxis of the foot. Cavus describes a medial plantar longitudinal arch that is “scooped out” higher than normal, whereas in planus, the arch is “flat.” In pronation, the forefoot appears rotated toward the midline due to flexion or depression of the first ray; elevation or extension of the first ray rotates the forefoot away from the midline into supination. Toe deformities are distinguished according to the joint affected. Flexion of the distal interphalangeal joint likens the toe to a diminutive mallet on account of a smaller distal skeletal element than is presented with flexion of the intermediate interphalangeal joint, which is likened to a hammer. Interphalangeal flexion with metatarsophalangeal extension gives the toe a claw appearance.

Anatomists and surgeons differ at the ankle. The former group’s flexion, following the convention that applies this term to reduction of angle in the direction of motion at a joint, is the latter’s dorsiflexion. The opposite motion is termed extension by the anatomist and plantar flexion by the surgeon.

Anatomists and surgeons also differ at the foot (and the hand). Normal motion is described relative to the foot, whereas the midaxis of the body is used to define deformity. *Valgus* refers to pointing of the hallux (the distal skeletal element) “away” from the body midaxis at the metatarsophalangeal joint. The equivalent active motion is under the action of *adductor hallucis* muscle, which pulls the great toe away from the midaxis of the body but “toward” the midline of the foot.

The foot may be divided into columns. Medial includes the talus and first ray. Lateral includes the calcaneus and fifth ray. This concept is fundamental to an understanding of foot mechanics (*q.v.*).

The foot is replete with accessory ossicles [B]. Some have fanciful names, such as os vesalianum at the base of the 5th metatarsal bone, after the Barbantian “Father of Anatomy” Andreas Vesalius (1514–1564). Others may be sufficiently common and sufficiently noisome to be worthy of a classification (*cf.* Accessory Navicular Bone). The malleoli may present separate ossification centers, of which appearance peaks between 6 and 9 years and which fuse with remainder of bone 1 to 2 years later. Distinguish these normal variants from avulsion fracture or other disease.

MECHANICS

Two models aid understanding of normal function and disease of the foot.

Tripod

This highlights the interconnectedness of the foot in bearing weight [C]. The legs of the tripod are the first and fifth rays, as well as the calcaneus. In a supinated forefoot with a hypermobile first ray, the calcaneus tips into valgus at the subtalar joint as the medial longitudinal arch reduces to produce a flatfoot. Correction of a flatfoot by calcaneal lengthening without correction of forefoot supination will fail as the first ray returns to the ground by hindfoot eversion

Acetabulum Pedis

Calcaneus and navicular bone (with remainder of foot) form a cup that rotates around a ball formed by the head of the talus [D]. In clubfoot, the acetabulum is displaced plantar and medialward, such that navicular bone abuts tibial malleolus and the head of the talus becomes palpable at lateral proximal dorsum of the foot. The acetabulum moves in an opposite direction in flatfoot. This concept underpins casting for clubfoot, which is rotated out of adductus and varus *via* the acetabulum. In flatfoot, cutting the calcaneus and lengthening the lateral column swings the foot around the head of the talus to reduce hindfoot valgus and restore normal alignment of the first ray with the talus.

EVALUATION

History

The foot has been a source of complaint and concern in every culture and in every age. A dichotomy may exist between child and parent, and between parent and physician. A parent may regard flexible flatfoot as an abnormality worthy of treatment when the child has no concerns and to the surgeon it is a normal variant. The foot may be the focus of a remote condition, either benign such as in-toeing due to tibial torsion or grave such as cavus as a sign of neural disease.

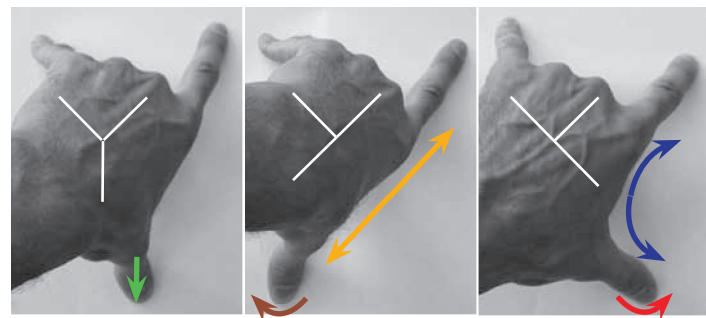
Physical Examination

Global Perform a complete assessment. The foot may manifest a sign of primary neural disease, such as dysrrhaphism, or hereditary motor and sensory neuropathy. Ask the patient to walk and run. Which way do the feet point? Do they appear symmetric, or does asymmetry betray a problem remote from the feet such as at the hip? Is there a normal progression of heel–flat-toe in stance and ankle flexion in swing?

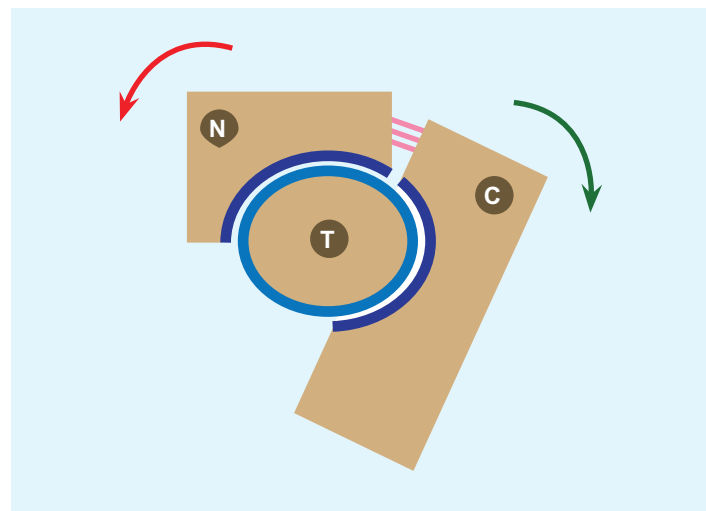
Focal The foot is a dynamic structure [E]. Start viewing the foot from the back. What is the position of the hindfoot standing and when the patient is up on the metatarsal heads? Add a block to support the lateral border of the foot: does the hindfoot evert as the medial front leg of the tripod sinks to the floor? These are tests of flexibility of the subtalar joint. Are “too many toes” visible beyond either malleolus in the standing position? How much space is there under the medial longitudinal arch in the lateral position? Evaluate the foot in weight-bearing and unloaded positions. Does the arch shape vary between the two?

Evaluate the skin, which tells a story. Callus is a response to abnormal pressure, which provides a functional outcome of deformity. Ulcer may have an exogenous cause, such as constrictive shoe wear, or endogenous cause, such as sensory loss. A single deep furrow is a sign of reduced skin motion over a joint with fixed deformity, such as posterior to an equinus ankle in structural clubfoot. A primary physician may rely on the observation that multiple fine creases suggest stretching and relaxation of skin over a mobile ankle to distinguish metatarsus adductus, a benign condition, from clubfoot.

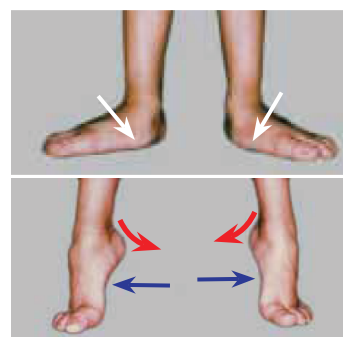
Pain varies according to age [F]. Most disorders and complaints concentrate around the turn of the decade. Palpate for tenderness: the foot is geographic and will reveal the source of pain [G].



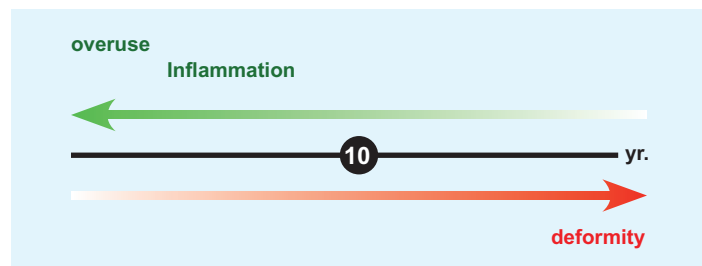
C The foot as tripod Thumb represents calcaneus. As a neutral calcaneus (green) rotates into valgus (brown), the medial longitudinal arch diminishes (orange) to keep ground contact with the first ray, which is relatively extended bringing the forefoot into supination. By contrast, when the calcaneus assumes a varus inclination (red), the arch elevates (blue) and the forefoot pronates as the first ray flexes to maintain contact with the ground.



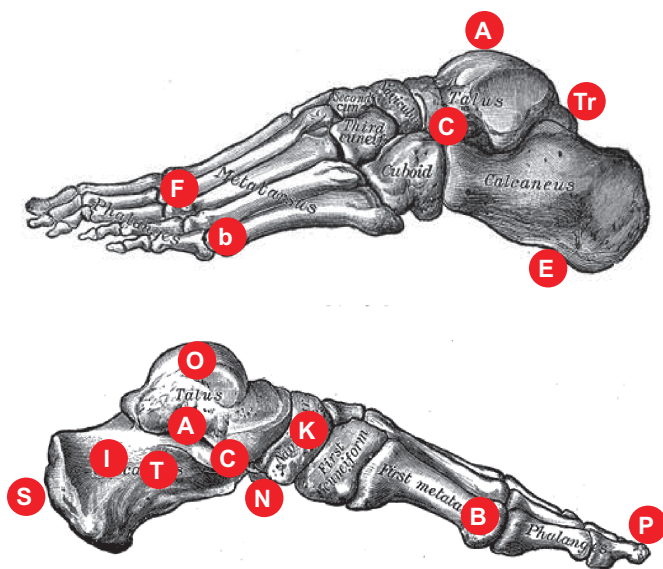
D Acetabulum pedis Calcaneus (C) and navicular bone (N), with intervening ligaments (pink), may rotate around talus (T) plantar and medialward (red), for example, in clubfoot, or lateralward and dorsal (green), for example, in flatfoot.



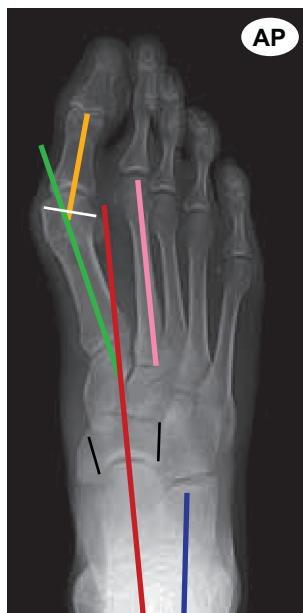E Dynamic examination of the foot In standing, weight-bearing position, the foot is flat (white). Upon standing on the metatarsal heads, the hindfoot inverts (red) and the medial longitudinal arch reconstitutes (blue), demonstrating that the deformity is flexible.



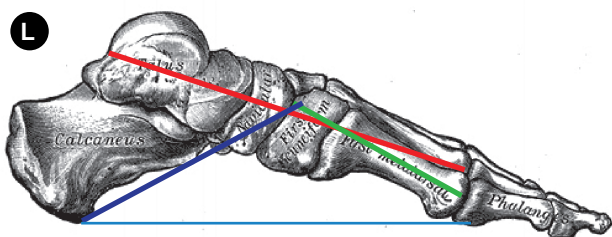
F Foot pain Foot pain varies according to age.



G Foot pain Foot pain is geographic. A: arthritis. B: bunion. b: bunionette. C: coalition. E: enthesitis. F: Freiberg infraction. I: osteomyelitis. K: Köhler condition. N: accessory navicular. O: osteochondritis dissecans. P: paronychia. S: Sever apophysitis. T: trauma. Tr: os trigonum.



H Radiographic examination of the foot Measure relationships in anteroposterior (AP) and lateral (L) projections between the talus (red), calcaneus (blue), first metatarsal bone (green), navicular bone (black), proximal phalanx of hallux (orange), and second metatarsal bone (pink). Some relationships vary with age, such as the talocalcaneal angle, which declines from 30 to 50 degrees at birth to 15 to 30 degrees by age 5 years. Other angles are stable, such as the pitch of the calcaneus at 20 to 30 degrees. *Subtalar joint incompetence, such as after overcorrection of clubfoot, may allow the calcaneus to slide lateralward from under the talus to produce hindfoot valgus while maintaining parallelism of the bones and thereby a reduced talocalcaneal angle.



Uncouple ankle and subtalar joints when determining motion. Invert the hindfoot to bring calcaneus directly under talus and thereby lock the subtalar joint before flexing the ankle. Patients with contracture of triceps surae will compensate for limited ankle flexion by swiveling through subtalar joint to place the foot flat on the ground. Flex and extend knee joint to isolate gastrocnemius muscle from soleus muscle. Ankle flexion >30 degrees is one criterion of ligamentous laxity. Flexibility of subtalar joint impacts deformity reconstruction. Deformity correction in the setting of a rigid joint is addressed by a compensating osteotomy or transarticularly by arthrodesis.

Imaging

While the foot lends itself to (hyper) analysis radiographically, there remains debate regarding applicability of metrics to functional outcome.

Röntgenogramme This is the mainstay [H]. Obtain views of weight bearing, because this is the functional position of the foot and foot shape varies significantly according to loading. There will be imprecision when drawing the longitudinal axis of irregular bones, such as the talus and calcaneus, and during growth with incomplete ossification.

Distinguish lateral view of the foot from lateral view of the ankle, which differs in the setting of deformity. Mortise view of the ankle delineates trochlea of the talus. Special views include oblique of the foot to view sinus tarsi and calcaneonavicular relationship and Harris view, which projects along the posterior facet of subtalar joint orthogonal to long axis of the calcaneus. Stress views may be useful in deformity, such as to distinguish oblique from vertical talus, and in trauma, such as Lisfranc injury.

Measurement	Normal	Abnormal
Talus–calcaneus	AP: 15–30 degrees	▼ Varus
	L: 15–30 degrees	▲ Valgus*
Talus–1st metatarsal (Méary)	AP: 0 degrees	Medial: metatarsus adductus
	L: 5 degrees	Lateral: abductus ▲ Flatfoot ▼ Cavus
Talus–navicular	joint neutral	Medial: clubfoot Lateral: flatfoot
Talus inclination	10–35 degrees	▼ Cavus
		▲ Flatfoot
Calcaneus (Campbell)	L: 20–30 degrees	▼ Equinus
		▲ Calcaneus
Calcaneus–1st metatarsal (Hibbs)	L: 120–150 degrees	> 150 degrees: flatfoot
		< 120 degrees: cavus
Intermetatarsal	< 10 degrees	> 15 degrees: Bunion
Hallux valgus	< 15 degrees	> 30 degrees: Bunion

Other modalities Scintigramme reveals occult bone lesions, as in early osteomyelitis. Ultrasonography is useful for foreign body that may be radiolucent, such as glass, or operatively to aid and limit dissection. Computed tomography (CT) gives the finest bone detail, as in determining location and extent of tarsal coalition, and aids surgical planning, in particular with three-dimensional reconstruction. Magnetic resonance imaging (MRI) provides the best view of soft tissue, as in tumor; can expose osseous reaction to disease; and aids in the evaluation of mixed lesions, such as osteochondritis dissecans.

TOE DISORDERS

Toe anomaly may be isolated or part of a generalized disorder [A]. They hurt, can be unsightly, and interfere with shoe wear.

Syndactyly

This affects the 2nd to 3rd more than the 4th to 5th toes and often is bilateral. The skin bridge may be complete, involving the nails, or incomplete, receding variably from the nails. Isolated toe syndactyly is benign: it is asymptomatic and poses no dysfunction. Educate parents that release to improve appearance is outweighed by surgical risk and scar. The condition may be part of polydactyly.

Polydactyly

This is summarized in [B]. Familial form follows autosomal dominant inheritance with variable penetrance.

Postaxial polydactyly is subclassified into type A, in which a well-formed extra digit articulates with the 5th or a 6th metacarpal, and type B, characterized a rudimentary extra digit (pedunculated postminimi). A heterozygous mutation in the *GLI3* gene on 7p14.1 has been found in both type A and type B. Autosomal dominant inheritance type A has been mapped to 7q22, 13q21, and 19p13. An autosomal recessive type A has been mapped to 13q13. Postaxial polydactyly is a feature of three-fourths of patients with trisomy 13.

In preaxial polydactyly, the metatarsal bone may be duplicated or widened to present a partial or separate condyle for the supernumerary digit. Mutation of the binding sites for transcription factors *SOX9* and *PAX3* in the *LMBR1* gene (sonic hedgehog family) on 7q36.3 has been found in preaxial polydactyly. Preaxial hallucal polydactyly is a feature of diabetic embryopathy.

Operation is indicated toward the end of the first year, as a balance between osseous development and independent walking. Excise the less developed supernumerary digit, which may be determined by the nail, overall toe size, or radiographic appearance. Include partial or complete metatarsal resection to avoid prominence laterally or a wide web space centrally. The latter also may be ameliorated by reconstruction of the intermetatarsal ligament. Plan flap(s) or skin graft for associated syndactyly.

Bracket epiphysis This represents medial extension of the physis of hallux phalanx or metatarsal to give origin to a preaxial polydactyly [C]. Growth of the epiphysis results in a broad-based bone that resembles a “triangle,” hence the original name “delta phalanx,” after the Greek letter Δ.

The epiphysis and physis are radiolucent but may be seen on MRI. Excision includes proximal extension to resect the physis bracket, along with release and reconstruction of remaining hallux to avoid varus deformity.

Curly Toe

The toe is flexed and rotated along its longitudinal axis under the next medial toe due to flexor contracture. This affects the lesser toes and often is bilateral. Half resolve spontaneously with walking. Deformity persistent beyond age 4 years is treated by flexor tenotomy at proximal cutaneous crease.

Presentation in the second decade may require complex reconstruction due to secondary contracture, including capsulotomy without or with flexor to extensor transfer. In the Girdlestone-Taylor procedure, the flexor is harvested *via* distal and proximal interphalangeal incisions, retrieved through a dorsal incision, through which a capsulotomy may be performed and where the tendon is sewn to the extensor.

Claw Toe

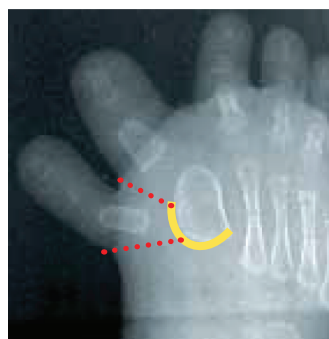
This is defined as metatarsophalangeal hyperextension with interphalangeal flexion [D]. It is a feature of extensor recruitment alone or in the setting of neural disease, where flexors are unopposed. Evaluation and management do not occur in isolation but are directed at the primary cause, such as cavovarus foot.

Toe Deformity	Disorders
Polydactyly	Bardet-Biedl syndrome Chondroectodermal dysplasia Carpenter syndrome Cephalopolysyndactyly syndrome (Greig) Femoral-facial syndrome
Syndactyly	Apert syndrome Oculodentodigital syndrome Pterygium syndrome
Metatarsal dysplasia	Achondrogenesis Brachydactyly syndrome Otopalatodigital syndrome
Broad toe	Acromesomelic dysplasia Rubinstein-Taybi syndrome
Macroductyly	Proteus syndrome Neurofibromatosis Vascular malformation
Deficiency or absence	Amniotic band syndrome (Streeter)

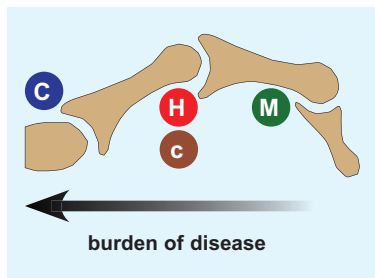
A Select syndromes associated with toe deformities.

Feature	Rate
Axis	Pre- 15%
	Post- 85%
Familial	30%
Blacks	10 X Whites
Syndactyly	10%
Hand	30%
Generalized disorder	Pre- 20%
	Post- 10%
Genetics	Pre-: <i>LMBR1</i> mutation on 7q36.3
	Post- <i>GLI3</i> mutation on 7p14.1. 7q22, 13q13, 13q21, 19p13 trisomy 13

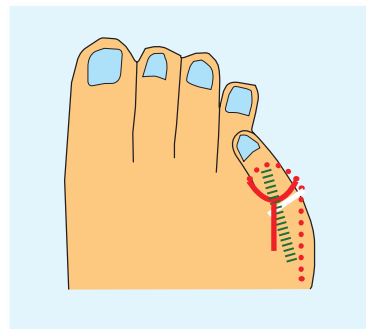
B Polydactyly Features that distinguish polydactyly include genetic mapping.



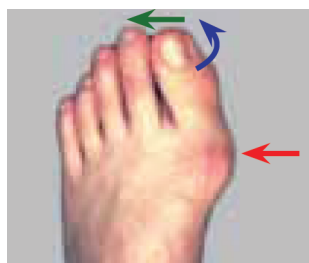C Bracket epiphysis This rare form of preaxial polydactyly requires recognition, complete resection (*red*) to include part of the U-shaped physis and epiphysis (*yellow*), and reconstruction to avoid hallux varus.



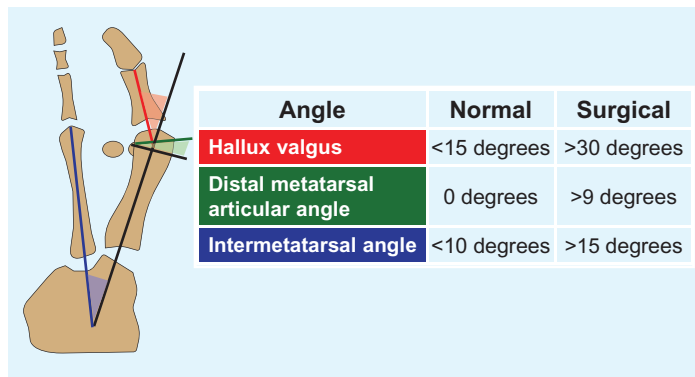
D Defining deformity
C: claw. H: hammer. c: curly. M: mallet. Note that a curly toe, in addition to interphalangeal flexion like a hammer toe, adds an axial deformity.



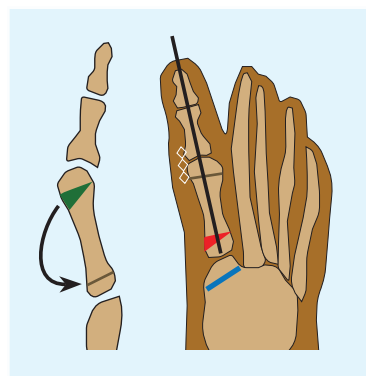
E Butler procedure Incision (red) allows for derotation and plantar displacement of the toe. Extensor tendon (green) is sectioned, as is the dorsal MP capsule (white).



F Bunion Hallux is deviated away from midline (green) and rotated (blue) against the second toe. The metatarsal head is prominent, and overlying soft tissues are reactive (red).



G Radiographic assessment of bunion Note obliquity of metatarsocuneiform articulation.



H Osteotomies for bunion Distal osteotomy to correct DMAA is combined with medial soft tissue reconstruction. Opening wedge proximal osteotomy addresses increased IMA. While the distal excised bone (green) may be transferred as shown on left, allograft (red) is more stable and can be tailored given that distal and proximal deformities rarely are equivalent. Alternatively, the proximal osteotomy may be made in the medial cuneiform (blue) if this is trapezoidal and the metatarsocuneiform articulation

is inclined. The correction is fixed with a medullary wire that may be supplemented with a crossed wire for rotational control.

Hammer Toe

This is defined as flexion deformity of the proximal interphalangeal joint (PIP). Metatarsophalangeal and distal interphalangeal (DIP) joints are obligatorily extended to contact the ground. Second toe is most affected. Presentation includes callus over dorsum of PIP joint and tends to be delayed into the second decade, when rigid deformity necessitates Girdlestone-Taylor procedure or PIP arthrodesis.

Mallet Toe

The essential lesion is fixed flexion deformity of the DIP joint. Presentation and treatment are similar to those of hammer toe

Overlapping Toe

Overlapping of the 2nd to 4th toes are benign and resolve spontaneously in infancy.

Digitus minimus varus Proximal and dorsal migration, with adduction and rotation to present the nail lateralward, of the 5th toe to overlap with the 4th typically is fixed. Operative correction (Butler) includes the following [E]:

- Circumferential incision (be careful of neurovascular bundles!) at base of toe with dorsal limb centered on metatarsal and longer plantar limb at border of glabrous skin
- Section of extensor tendon
- Section dorsal metatarsophalangeal capsule
- Rotation of cutaneous flaps to reinforce and maintain reduction of the toe

Bunion

Greek βουντιον: “small hill, tumulus,” whence “bunny,” describes the prominence of the head of metatarsal bone [F]. Childhood bunion represents a primary growth disturbance of the hallux metatarsal, reflected in the appellation metatarsus primus varus. This may be quantified by the distal metatarsal articular angle (DMAA) and further revealed by trapezoidal deformity of the medial cuneiform. In neuromuscular patients, bunion may result from imbalance of muscle forces. In adult bunion, exogenous factors conspire to deform and destabilize the static and dynamic metatarsophalangeal soft tissues.

Evaluation The ratio of girls:boys is 5:1. A family history in half of patients suggests mendelian inheritance with variable penetrance. The hallux deviates away from midline and rotates such that the nail inclines medialward, eventually lying under or over the second toe. Soft tissue over the exposed and prominent head of metatarsal is callused, red, and sore. Pain also may be felt over displaced plantar sesamoids. Assess hypermobility of the first ray at the metatarsocuneiform articulation. Patients may present in the absence of pain or dysfunction due to cultural disapprobation.

Röntgenogrammes quantify deformity, form the basis for surgical indications, and guide operation [G].

Management Education is fundamental, including wearing of shoes with a sufficiently wide toe box and minimizing heel height. Orthotics do not provide a durable result.

Surgical treatment may be divided into four according to site and aspect of deformity corrected. There are numerous techniques and combinations, which betrays the facts that bunion is not homogeneous and that no single procedure is universally effective [H].

- Soft tissue. This includes plication of medial capsule and release of adductor hallucis laterally. The former may be performed through drill holes for security. Beware of the first dorsal metatarsal artery, which enters the head on the lateral side. Following the principle that soft tissue reconstruction will fail in the setting of osseous deformity, combine this with osteotomy.
- Osteotomy—distal. This is indicated when there is no proximal deformity. It corrects the DMAA and hallux valgus when the intermetatarsal angle (IMA) is normal.

- Osteotomy—proximal. Indication is abnormal IMA. Opening wedge adds length to a short 1st metatarsal.

Base of metatarsal to medial cuneiform arthrodesis. This allows plantar flexion (in addition to coronal correction) of the metatarsal to address hypermobility of the first ray, in order to stabilize the medial limb of the tripod in flatfoot.

The principal complications are avascular necrosis of the head of metatarsal and over-/undercorrection. The former is related to lateral dissection. The latter are related to maturity in the uninvolved child, in whom operation should be delayed until physial closure. In neuromuscular disease, metatarsophalangeal arthrodesis balances control of correction against reduced physical demand.

Bunionette

This also is known as tailor's bunion, after repetitive pressure and rubbing at the dorsal aspect of the 5th metatarsal head in the cross-legged position on an unyielding surface. The deformities mirror bunion on the opposite side of the foot. The disorder is less common and less troubling than is bunion in children. As a result, it rarely comes to surgery, which consists of the 5th metatarsal osteotomy to reduce prominence of the head.

Dorsal Bunion

The head of the 1st metatarsal is prominent at the dorsum, with associated flexion contracture of the metatarsophalangeal joint. An imbalance between a stronger tibialis anterior muscle than peroneus longus muscle lifts the 1st metatarsal. It may be a consequence of operative release of clubfoot, in which tibialis anterior may be hyperactive and a weakened triceps surae is compensated for by flexor recruitment. Surgical management includes the following:

- Flexion osteotomy of the 1st metatarsal or medial cuneiform, to correct deformity
- Plantar metatarsophalangeal joint capsular release
- Transfer of flexor hallucis longus to the neck of the 1st metatarsal (reverse Jones), to support correction and to reduce metatarsophalangeal joint flexion
- Transfer of tibialis anterior to lateral cuneiform bone

Hallux Rigidus

The hallux does not move due to arthritis of the metatarsophalangeal joint. Dorsiflexion is lost first. Presentation is in the second decade. Repetitive trauma, osteochondritis dissecans (OCD), and hypermobile first ray may have been implicated. Pain may be elicited with motion under resistance, in particular during standing on the metatarsal heads. Röntgenogrammes show signs of degeneration, including reduction in joint width, osteophyte, and possible OCD of the metatarsal head.

Initial treatment is supportive, including stiff shank or insert to limit metatarsophalangeal joint motion. Surgical options include the following:

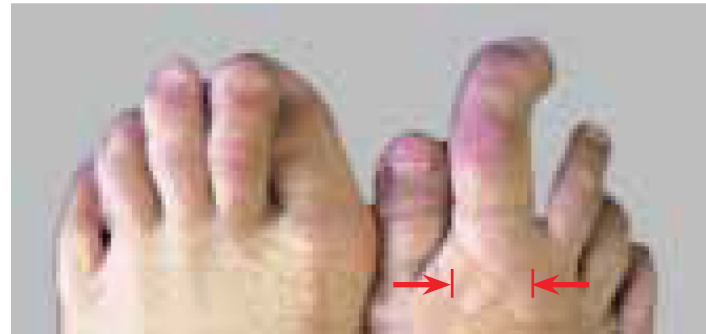- Joint débridement, including cheilectomy, to alleviate pain and improve motion.
- Metatarsophalangeal arthrodesis. This eliminates pain, is durable, and allows a high level of function in an active adolescent.

Hallux Varus

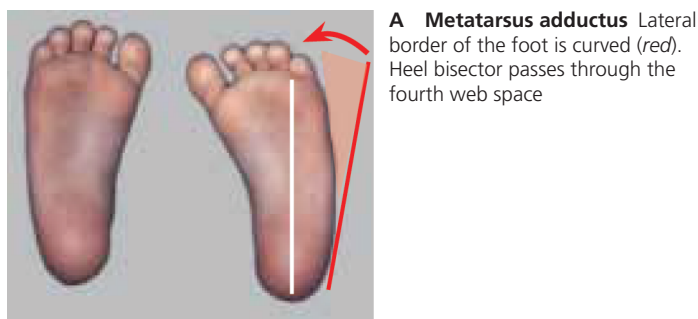
The hallux points medialward. Acquired deformity results from overcorrection of bunion. Congenital hallux varus may be dynamic or static. The former is due to overactivity of abductor hallucis muscle and is self-limited in infancy. In the latter, a palpable contracture of the muscle may become visible under the medial skin with abduction of the forefoot (Lichtblau test). Surgical release of abductor hallucis may be reinforced by lateral transfer of extensor brevis tendon.

Macroductyly

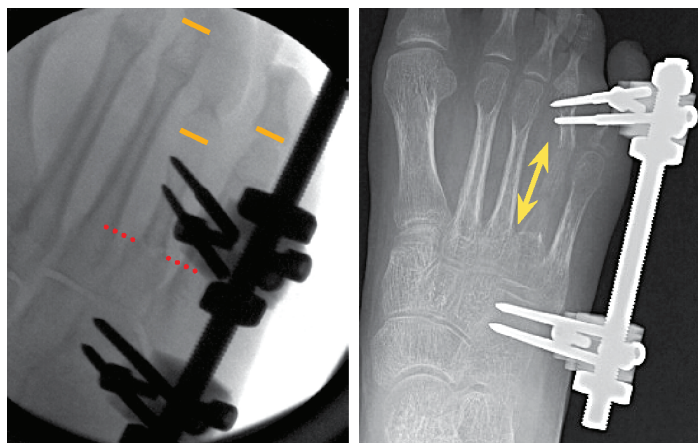
This may be isolated [1] or associated with other condition, including Proteus syndrome, neurofibromatosis, or vascular malformation. It interferes with shoe wear, is readily traumatized, and is unsightly. Accommodate by modifying shoe wear. Physiodesis has limited utility, for example, it limits length but does not address width. Debulking is ineffective. Consider amputation of metatarsal as well as affected toe, in order to avoid a wide web space for adjacent toes to incline toward and create secondary deformity.



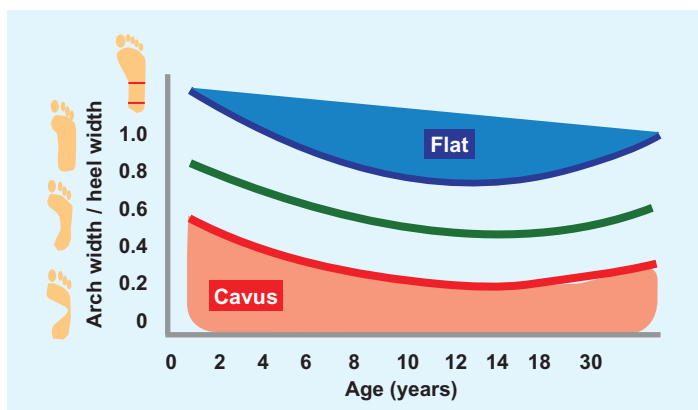
1 Macroductyly There is hypertrophy of the entire second ray (red), which should be included in a resection.



A Metatarsus adductus Lateral border of the foot is curved (red). Heel bisector passes through the fourth web space



B Lengthening of brachymetatarsia The 4th metatarsal is short (orange). An external fixator is placed, the bone is cut at proximal metaphysis (red), and lengthened (yellow) with intervening callus.



A Midfoot:heel contact area Ratio of the arch width to the heel width varies with age. Normal mean is 0.5, and range is 0.25 to 0.75. Below this range is cavus (red). Above this range is flat (blue).

Type	Hindfoot	Cause
Physiologic	Normal	Idiopathic
	Cavovarus	Neural—central e.g., Friedreich ataxia Neural—peripheral e.g., Charcot-Marie-Tooth Muscular e.g., Duchenne
Pathologic	Calcaneocavus	Spinal cord disease e.g., poliomyelitis

B Classification of cavus This classification includes the majority of causes of cavus feet. Pathologic cavus is often associated with neurologic disorders.

FOREFOOT

Metatarsus Adductus

The metatarsus is “directed” (Latin *ducere* “to(ward)” (Latin *ad-*) the midline. This is one cause of in-toeing. It may be a “packaging sign” of uterine crowding, in association with plagiocephaly, torticollis, and hip dysplasia.

Evaluation The lateral border of the foot is curved [A]. The heel bisector, which normally passes through the second toe, is displaced lateralward with increasing severity. The deformity may be flexible or rigid, which some distinguished by the appellation *metatarsus varus*. Flexible metatarsus adductus is divided into active, which corrects with stimulation of the foot, and passive, in which the lateral border may be straightened and made concave by displacing the forefoot lateralward with one hand while securing the heel in the other hand. The hindfoot and ankle are supple.

The natural history is spontaneous resolution in > 90%. Rigid or persistent metatarsus adductus may interfere with shoe wear.

Management Education about the benignity of the condition is the cornerstone. Modalities such as stretching exercises in the first year and reversing shoes after walking age do not adversely impact the child and give parents some agency.

Rigid deformity is treated according to age.

- Under 5 years, serial casting. A sequela is recurrence.
- After 5 years, opening wedge cuneiform osteotomy with structural allograft and closing wedge cuboid osteotomy (bone is too cancellous to be structurally effective) with internal fixation. Tarsometatarsal capsulotomies with metatarsal osteotomies (Heyman-Herndon) is an unnecessarily complex procedure fraught with complications.

Brachymetatarsia

This may affect the hallux metatarsal, as an atavic trait representing regression from a structure adapted for terrestrial erect weight bearing and locomotion to one adapted for arboreal life, in which the hallux more closely resembles an opposable thumb in relative size, position, and mobility (Morton foot).

Lesser brachymetatarsia typically affects the 4th toe, which is displaced proximalward and dorsad, furrowing the web space. Severe deformity is characterized by transfer metatarsalgia and pressure against the upper toe box. Two surgical techniques have been advocated:

- Osteotomy and acute lengthening over a medullary wire, with intercalary bone graft. Autograft necessitates a second incision; allograft may not unite. Length is limited by soft tissue envelope, including toe ischaemia.
- Osteotomy and callus distraction by external fixator [B]. This carries pin-site risks but, because it is gradual, it is more potent and less threatening to the adjacent neurovascular structures.

MIDFOOT

Cavus

Latin *cavus* describes a medial longitudinal arch that is “hollowed out,” as a “cave” is in the earth. While arch height is difficult to measure, the reduction in contact area that follows may be measured in the ratio of midfoot width:heel width [A]. Cavus may be divided into physiologic and pathologic. Physiologic is an isolated finding at one end or 2.5% above the Gaussian distribution for the general population. Pathologic is neuromuscular or syndromic [B].

Evaluation The essential problem in cavus is reduction of contact area (A), which increases pressure (P) for the same force (F) of body weight after the formula $P = F/A$. The foot hurts and reacts by forming calluses to increase the contact area [C].

In isolated cavus, the hindfoot is uninvolved. Determine flexibility of cavus, toes, subtalar, and ankle joints. Triceps surae contracture may result in recruitment of the long digital extensors, which are visible under the dorsal skin, leading to flexible claw toes. Hindfoot varus displaces callus lateralward. It also stresses the ankle, including episodes of instability. Callus also appears over the dorsa of the clawed toes. Severe and rigid deformity is difficult to shoe.

Rule out other disease. The history may be obvious in an established diagnosis such as cerebral palsy. A family history may reveal a peripheral neuropathy. The child should be undressed and in a gown. Examine all systems, in particular the rest of the skeleton (e.g., other deformity), nervous (e.g., diminished deep tendon reflexes in peripheral neuropathy), muscular (e.g., weakness or wasting), and cutaneous (e.g., sign of dysrrhaphism). Unilateral deformity and hindfoot deformity are abnormal. Clawing of the toes may be a sign of intrinsic muscle disease.

Röntgenogrammes aid the determination of site(s) and severity of deformity, and operative planning. Consider other testing based upon index of suspicion. MRI may reveal a spinal cord tumor. Electrodiagnostic and gene testing are indicated for Charcot-Marie-Tooth diseases and muscular dystrophies (*cf.* Neuromuscular Diseases). Appropriate referral, for example, to a neurologist, completes the evaluation.

Management Arch supports increase contact area, thereby reducing pressure. Orthotic for the hindfoot restores normal distribution of force at subtalar and ankle joints. Ankle-foot orthotics may aid clearance of the floor during swing phase of gait.

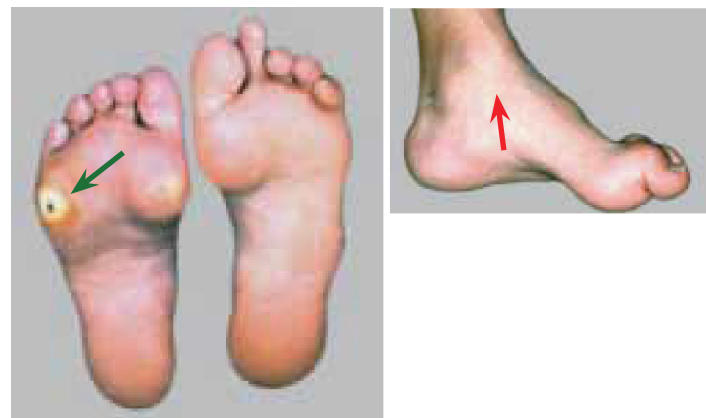Because the natural history of significant deformity is poor, surgical treatment is common. The causes and presentations are diverse. Learn principles and tailor methods.

- Timing balances size of the foot—to allow for sufficient ossification—versus joint motion—which declines with age and as such will limit surgical options [D].
- Determine whether deformity is flexible or rigid [E]. Flexibility allows correction *via* joint motion rather than by excision and fusion: this will preserve function and improve outcomes. Casting is non-operative soft tissue release. Osteotomy for the rigid foot creates a secondary osseous deformity to compensate for the primary articular deformity.
- Examine every muscle for strength and contracture [F]. Transfer strong muscles to recover motion lost to neural imbalance or myopathy. Split transfers guard against opposite deformity in unpredictable disease. Avoid transfer of weak muscles or muscles out of phase, except in a supportive rôle. Lengthen contracted muscles to reduce their deforming force.

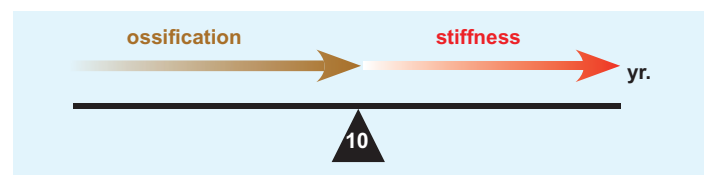
Surgery may be divided into several components.

SOFT TISSUE Plantar release may be isolated or inclusive. The former is performed at the medial midfoot, where the edge of plantar aponeurosis is readily palpable. The latter (Steindler) is performed through a medial approach to the hindfoot, which allows identification of neurovascular structures and section (or “stripping”) of plantar aponeurosis and deep muscles of the foot off the tuber of calcaneus, as well as the talonavicular capsule. The first two address cavus, while the third component aids hindfoot correction *via* the acetabulum pedis.

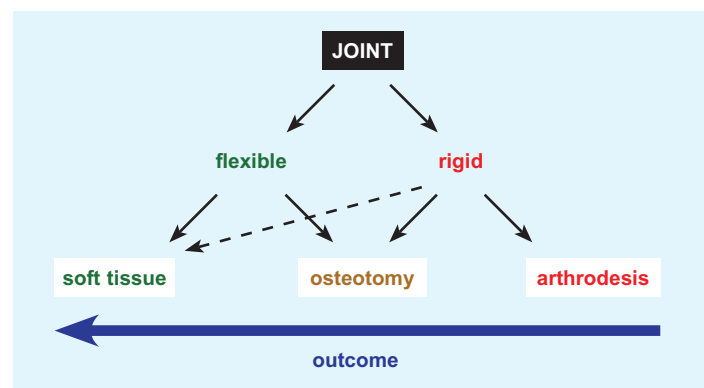
Plantar release usually is the first stage of care. Casting may correct remaining, more global contracture, preparing the flexible foot for second stage surgery, which will include muscle work. Cast until a plateau is reached, which determines whether osteotomy will be necessary if deformity remains.



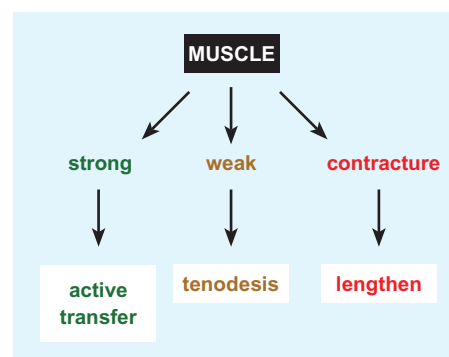
C Physical examination of cavus The deformity increases load on the metatarsal heads. If sensation is poor, for example, spina bifida, skin breakdown (*green*) is not uncommon. The arch points to the locus of disease (*red*), in this case, the spine.



D Timing of operation Balance ossification against stiffness.



E Surgical principles: joint Joint integrity influences type of procedure.



F Surgical principles: muscle Muscle strength and excursion influence type of procedure.

Transfer	Lengthening	Effect
Tendo Achillis or gastrocnemius		▼ equinus
Peroneus longus		▼ cavus
		▲ eversion
Extensor digitorum longus		▼ clawing
		▲ ankle flexion
Extensor hallucis longus		▼ clawing
		▲ extension 1st metatarsal
Flexor digitorum		▼ clawing
Tibialis posterior		▼ varus
		▲ ankle flexion
		▲ eversion

G Muscle surgery for cavus Lengthening or transfer reduces deforming forces and augments motion.

MUSCLE TRANSFER OR LENGTHENING Triceps surae release is postponed until after casting [G]. Gastrocnemius recession is indicated when Silfverskiöld sign is present: ankle flexion improves sufficiently with knee flexion, when the gastrocnemius is relaxed. Tendo Achillis lengthening may be percutaneous or open: the former is less invasive, the latter more controlled.

The goal of muscle transfer is balanced function after, not to effect, deformity correction.

Peroneus longus flexes the first ray. Releasing this muscle removes its deforming force. Transferring the muscle to peroneus brevis, which everts the hindfoot, allows it to counteract varus.

The digital extensors, recruited against overpowering posterior crural muscles, exacerbate claw deformity. Their power of ankle flexion is dissipated at the metatarsophalangeal joints. Transfer removes a deforming force and enables the muscles to be more effective. Extensor hallucis longus may be transferred to the neck of the 1st metatarsal, to aid its extension. Extensor digitorum longus may be transferred to lateral cuneiform, to augment ankle flexion, or to cuboid (peroneus tertius, if present, may be a more secure anchor point) to add eversion.

Lengthening of the plantar aspect of the foot, along with improved ankle flexion, stretches the digital flexors, which are unopposed after extensor transfer. This may be addressed by percutaneous flexor release at the proximal cutaneous crease of the toes, which is simpler than multiple phalangeal arthrodeses.

Tibialis posterior, the principal agent of varus, may be lengthened above the tibial malleolus, where the tendinous fraction is sectioned, or by a Z-manner in the midfoot during plantar release. The tendon may be transferred to aid ankle flexion or eversion, but this takes the muscle out of phase and is reserved for the neuromuscular, paralytic foot, where it acts as a passive transfer. It may be rerouted *in toto* through the interosseous membrane to the lateral cuneiform, or it be split behind the foot to the peroneus brevis.

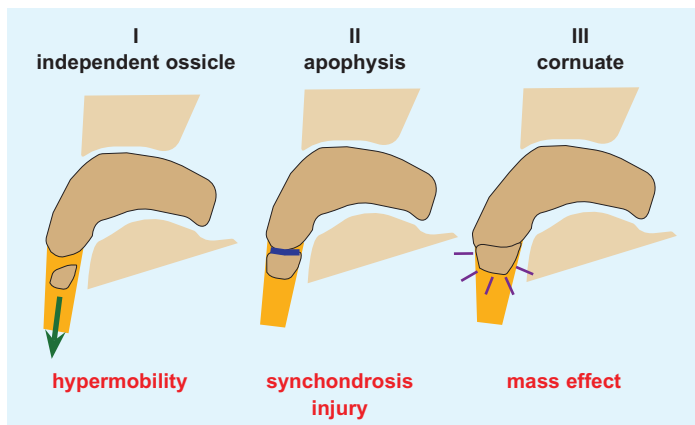
OSTEOTOMY The forefoot may be elevated by midfoot osteotomy. Mildest is medial cuneiform osteotomy to elevate the 1st metatarsal. Osteotomy proceeds lateralward with increasing deformity. Osteotomy may be opening of closing wedge: the former lengthens a short foot, while the latter is less resisted by overall contracture and thereby may afford greater correction. Translational osteotomies, which correct cavus by dorsad displacement of the distal foot, are more limited and create a secondary deformity. Midfoot osteotomies are fixed with wires.

Osteotomy of the calcaneus may compensate for rigid hindfoot varus. Valgus osteotomy resects a lateral closing wedge. Because the center of deformity is the subtalar joint, lateral displacement of the calcaneus fragment is necessary to bring the tuber in line with the mechanical axis. Superior displacement of the calcaneus fragment is indicated when pitch is increased, as in calcaneocavus. Screw fixation is more stable.

ARTHRODESIS This is indicated for deformity that is rigid—when the foot cannot be corrected by harnessing joint motion—and severe—when compensating osteotomy is insufficient. A dorsal wedge resected through the transverse tarsal joint corrects cavus. A lateral wedge resected through the subtalar joint corrects varus. Fix with staples or plates.

Accessory Navicular Bone

This accessorium also is known as os tibiale externum or os naviculare secundarium. It represents a “secondary” center of ossification that is lodged as a sesamoid in the tibialis posterior tendon. It affects 15% of the population. Three types are distinguished [H]. The cornuate type has fused late to elongate the navicular like a “horn” (Latin *cornu*).



H Classification of accessory navicular Pain (red) is most associated with type II, where the synchondrosis (blue) is stressed repeatedly by the pull of the tibialis posterior tendon (orange).

Evaluation Presentation is toward the inflection of the decades. Chronic inflammation from repetitive stress, microfracture of synchondrosis, and/or direct trauma to an osseous prominence conspires to produce pain that is focal and reproducible by palpation. The navicular is prominent. Overlying skin is reactive, typically red and thick.

Röntgenogrammes are the standard and sufficient in the classic presentation. While it may be visible on anteroposterior and lateral projection, an external oblique projection is tangent to the navicular and remainder of the foot, thereby exposing the accessorium *en profil*. Although the navicular ossifies by 5 years, the accessorium ossifies later. Other imaging modalities are reserved for special circumstances. Scintigramme may focus vague foot pain. MRI gives detail of the tibialis posterior tendon, before and after operation.

Management Initial treatment is symptomatic and supportive. Modify shoe wear to decompress the accessorium. University of California Biomechanics Laboratory orthotic inverts a valgus hindfoot to reduce pressure on the navicular. Rest the foot in a cast. Persistent pain may be addressed by patience for fusion with the main bone, or simple excision [I]. Make a linear incision centered on the bone. Divide tibialis posterior sharply in line with its fibers. Identify the gap, synchondrosis, or scar between the two bones, through which the accessorium may be shelled out least traumatically. Blunt remaining prominence or edge. Do not defy Ockham's razor: broad excision and advancement of tibialis posterior (Kidner procedure) lest the it be attenuated by the accessorium and in order to support the medial longitudinal arch is unnecessarily complicated and risks the tendon's function.

Flatfoot

The condition is discussed here even though the principal problem is proximal to the midfoot because the name describes the medial longitudinal arch. This also is known in Latin as *pes planovalgus*, to encompass deformity of the hindfoot.

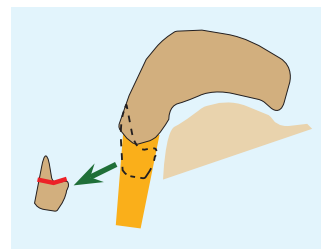
There are three types of flatfoot [J]. The components of flexibility are change of shape of the medial longitudinal arch with loading and supple subtalar joint motion. Flexible flatfoot may be divided into without and with triceps suræ contracture. The former is a normal variant and accounts for no symptoms or dysfunction. The latter may cause pain as decreased excursion of the calcaneus, tethered by the heel cord, restricts ankle motion and transfers force to the subtalar joint, at which the calcaneus swivels out leaving the head of the talus unsupported to drop to the ground. Rigid flatfoot has an immutable shape and a stiff subtalar joint: the foot hurts, interferes with shoe wear, and often requires treatment. It is typified by tarsal coalition and vertical talus (*q.v.*).

The essential pathomechanical features of flexible flatfoot are as follows [K]:

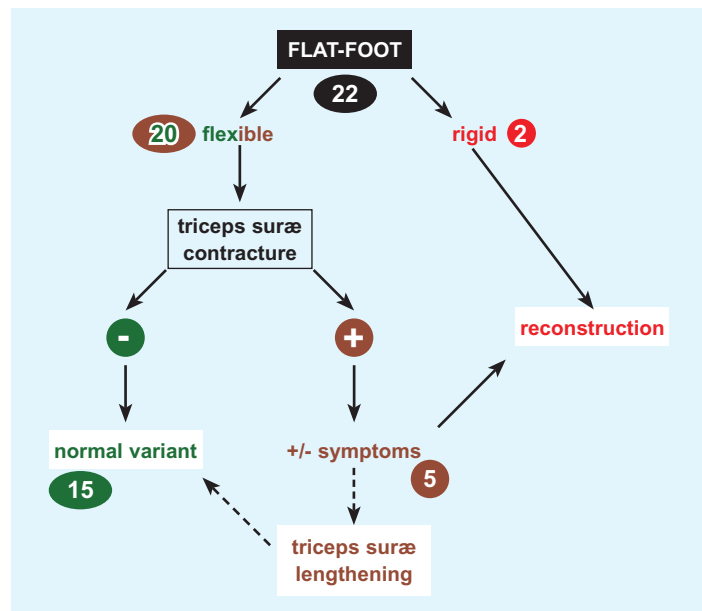
- Calcaneus may be equinus or plantar flexed relative to the tibia.
- Calcaneus rotates lateralward at subtalar joint into the valgus.
- Talus falls into equinus, plantar flexed relative to the tibia and calcaneus.
- Navicular is abducted and dorsiflexed relative to the talus.
- The 1st metatarsal is extended, supinating the forefoot.

Flexible flatfoot distributes Force of weight bearing over a large surface Area, reducing Pressure after the formula $P = F/A$ (*cf.* Cavus). This is advantageous, as manifest by reduced stress fractures in the flatfooted. An unyielding foot (tight heel cord or rigid) concentrates force over a small area (e.g., head of the talus) [L].

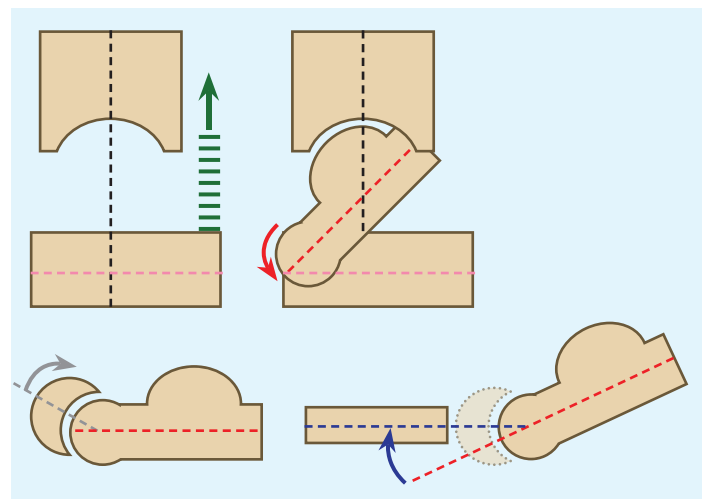
Secondary deformities may be divided into osseous and soft tissue. The lateral column is relatively short. The tibialis posterior tendon is attenuated. The plantar and medial talonavicular joint capsule is lax.



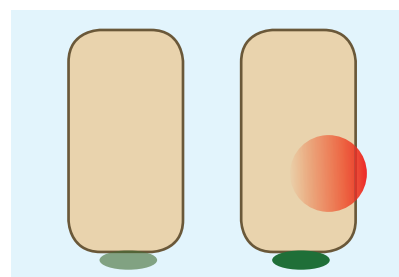
I Excision of accessory navicular Shell the accessorium sharply out of the tibialis posterior tendon. Blunt remaining prominence or edge.



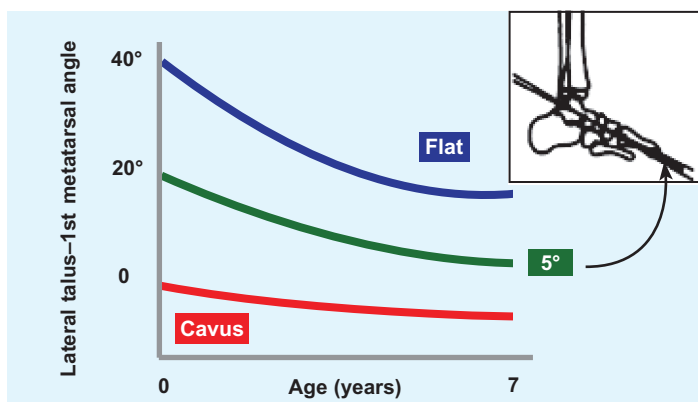
J Algorithm for flatfoot Numbers represent % of white population affected.



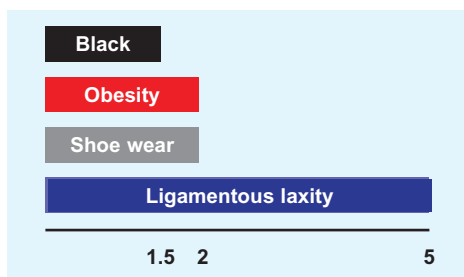
K Pathomechanics of flatfoot.



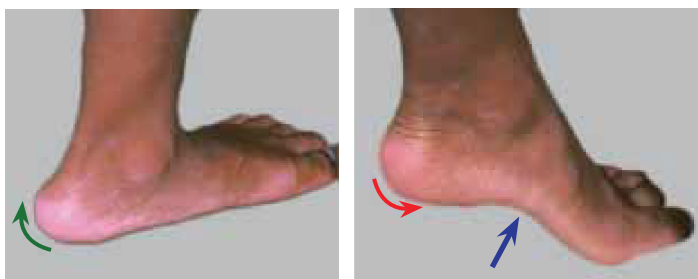L Stiffness concentrates force A flexible flatfoot without tether distributes force over a large surface area. Tight heel cord (*dark green*) prevents the head of the talus (*red*) from accommodating during weight bearing, thereby concentrating force.



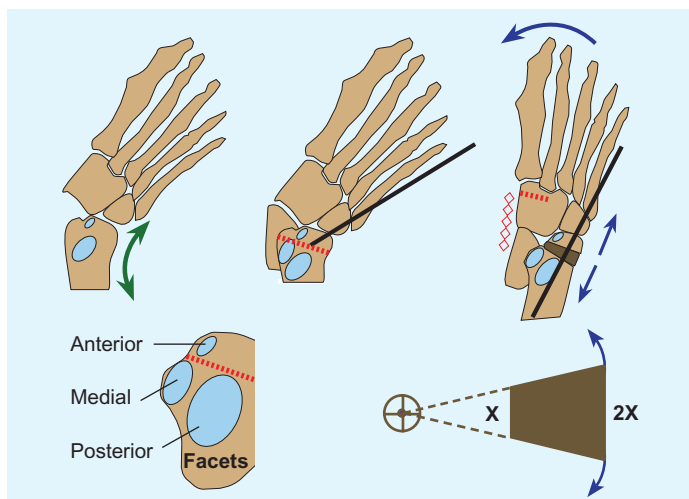
M Development of the medial longitudinal arch The arch stabilizes at mean slight plantar sag (green) by age 7 years.



N Associations with flatfoot Numbers represent multiples of the general population. Obesity suggests a mechanical factor, as does exogenous force from shoes. Laxity points to ligament and not muscle as primary tissue site.



O Shape of flexible flatfoot changes with weight bearing Heel moves from valgus (green) to varus (red), no arch to arch (blue).



P Lateral column lengthening Lateral column is short (green). Wire (black) stabilizes calcaneocuboid joint, graft, and osteotomy (red). Osteotomy is extra-articular between calcaneal facets. Trapezoid graft for medial center of rotation (brown).

Evaluation Flexible flatfoot is normal in infancy (“fat foot”) and reduces with growth [M]. Several characteristics are associated with flexible flatfoot [N]. While flatfoot and bunion are independent, the two conditions are influenced by shoe wear. Is there a toe-toe gait, suggesting triceps surae contracture? Examine the foot standing flat, standing on the metatarsal heads and unweighted. Does extension of the hallux restore an arch by tightening the plantar aponeurosis *via* a windlass mechanism (Jack)? Determine subtalar flexibility, and whether the medial longitudinal arch reconstitutes [O]. Examine the skin for signs of decompensation, such as callus or sore, which reflect force concentration. Move the subtalar joint and flex the ankle, with the knee extended and flexed, to determine whether the tendo Achillis is tight or whether there is an isolated contracture of the gastrocnemius muscle. Is there tenderness, such as over a prominent head of the talus, along tibialis posterior tendon or peroneal tendons, or at the insertion of tendo Achillis? Distinguish hindfoot valgus from ankle valgus, which may be seen in neuromuscular disease such as spina bifida.

IMAGING Röntgenogrammes are the standard and sufficient. Evaluate relationship of the talus and calcaneus in the anteroposterior projection: divergence with overlap suggests a competent subtalar joint; lateral displacement of the calcaneus without concomitant divergence suggests joint incompetence, as after excessive clubfoot release. The lateral projection exposes extent of equinus. The metatarsals are evaluated for overlap or divergence, to aid assessment of forefoot supination. Röntgenogrammes may reveal other cause of flatfoot, such as tarsal coalition.

Management Perhaps the most important component of management is education. Flexible flatfoot is normal. Orthotics are unnecessary. They do not alter foot shape. That an “arch support” can harm the foot is a paradox to many patients: there is no room, and jamming something against the medial foot hurts. Do not underestimate cost, including of “custom” fabrication and psychic for the child.

Address a tight heel cord either by compensating for it, for example, with a heel lift, or by stretching it, with exercises. The latter is ambitious for a small muscle group, because it requires isolating the ankle joint by locking the subtalar joint (with which the public is unfamiliar), and in a child who may be otherwise distracted.

OPERATION Lengthen the triceps surae, either at tendo Achillis or at gastrocnemius muscle, to decompress the subtalar joint. Because surgical intervention is reserved for significant primary deformity that typically presents in company of secondary deformities, this usually is combined with reconstruction.

Arthroereisis (Greek ερεσις: “pushing against”), in which a block to subtalar eversion is inserted into the calcaneus at the sinus tarsi to actively or passively counteract hindfoot valgus, may improve foot posture early but will degrade the subtalar joint long term.

Lateral column lengthening is indicated for a reducible and competent subtalar joint [P, Q]. This is anatomic, harnessing the acetabulum pedis and addressing secondary deformity, and physiologic, avoiding arthrodesis.

- Lengthen the heel cord or the triceps aponeurosis, depending upon the site of contracture.
- Oblique incision in lines of von Langer over sinus tarsi.
- Expose dorsal distal calcaneus preserving calcaneocuboid joint.
- Lengthen peroneus brevis and cut aponeurosis of abductor digital minimi, which become contracted in a short lateral column.
- Identify site of osteotomy between anterior and middle facets of calcaneus. Some patients have no distinction between these, in which case select 10 to 15 mm proximal to calcaneocuboid joint.
- Expose plantar surface of calcaneus and divide periosteum and lateral plantar aponeurosis.
- Cut the calcaneus with osteotome or saw.
- Drive a smooth wire retrograde across the calcaneocuboid joint (to stabilize it) into the osteotomy.

- Prepare a trapezoid allograft or autogenous corticocancellous graft from the ilium. Lateral side is 2× medial side of graft. This accounts for the center of rotation of acetabulum pedis remote at the center of the head of the talus.
- Distract osteotomy and place graft, securing both by advancing wire retrograde.
- By a medial longitudinal incision, expose and plicate the talonavicular joint and tibialis posterior tendon.
- Flex the ankle and evaluate metatarsal heads. If supination, perform a closing wedge osteotomy of the medial cuneiform. Leaving a supinated forefoot risks recurrence as the medial limb of tripod ultimately will reach the ground by driving the hindfoot back into the valgus.

Medial displacement osteotomy of the calcaneus is indicated for lateral translation of the calcaneus and remainder of the foot at an incompetent subtalar joint, or when subtalar joint is stiff such that acetabulum pedis cannot be reduced around the head of the talus. It is a compensating osteotomy that brings ground contact point in line with mechanical axis (*cf.* Cavus).

Skewfoot

This also is known as Z-foot, which describes the appearance of the three parts of the foot as limbs of the letter [R]. It is a combination of metatarsus adductus and flatfoot, with hindfoot valgus and midfoot adductus, and should be managed according to the same principles.

Surgical correction includes *both* medial column lengthening and lateral column lengthening. These do not counteract each other, but rather address the two deformities at different sites in the foot: midfoot where there is adductus, and hindfoot where there is valgus.

Calcaneovalgus

This is a benign condition produced by uterine crowding [A]. It is striking to parents and primary physicians. The natural history is spontaneous resolution without sequelae over the first few months of life. There is no association with long-term deformity.

Evaluation The ankle is hyperflexed, and the hindfoot is in valgus, plastering the foot against the anterior distal leg, which may be indented. Distinguish flexibility of talonavicular joint and dorsiflexion of calcaneus from vertical talus, in which the former is stiff and the calcaneus is in equinus. Palpate the subcutaneous border of the tibia and malleoli to rule out posteromedial bowing (*q.v.*). Look for other packaging signs, such as plagiocephaly, torticollis, and hip dysplasia.

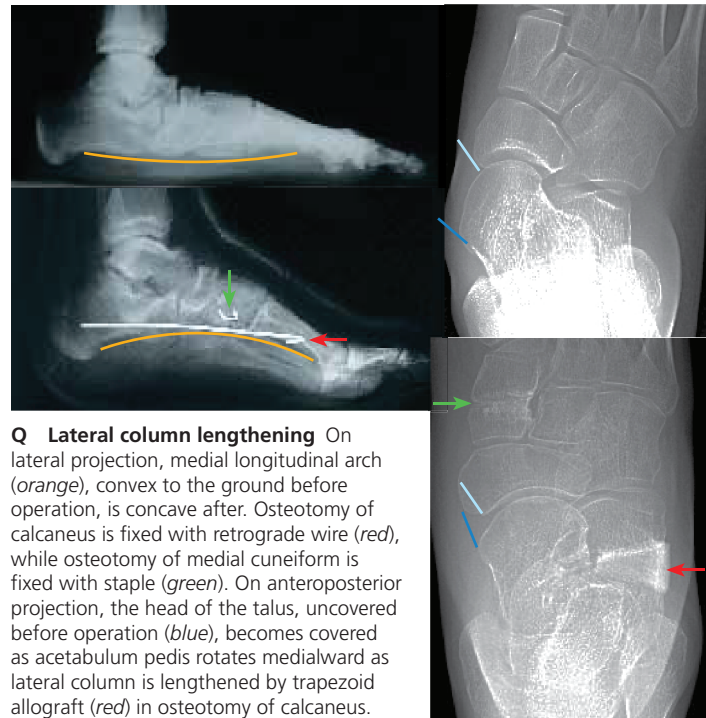Management Stretching by parents does not harm the child and gives them agency.

HINDFOOT

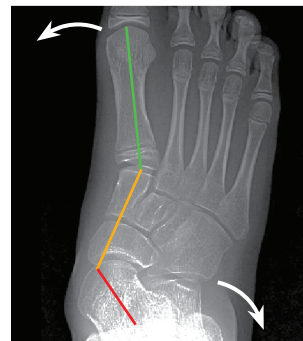
Clubfoot

This also is known as Latin *tali-pes equino-cavo-varus*, a term that describes the “talus” serving as “foot” to be walked on in the severe untreated form, and the deformities of the ankle, midfoot, and hindfoot. The name does not include the leg, which also is involved. It has been recognized since ancient times. Hephæstus, god of blacksmiths, fire, and volcanoes (Roman Vulcan), was called “lame” due to deformity of the feet [A]. The Hippocratic Corpus discusses the condition at length, including manipulative correction.

Clubfoot may be divided postural, which is extrinsic related to *in utero* position and resolves spontaneously, and structural, which is an intrinsic defect [B]. Structural clubfoot may be divided into idiopathic and associated with generalized condition, which includes neuromuscular disease (e.g., spina bifida) and syndromes (e.g., arthrogryposis). Idiopathic clubfoot is bilateral in half the cases and affects boys more. The cause is unknown and multifactorial, including genetics (it is familial) and encompassing all tissues (soft and hard) [C]. A base substitution in the highly conserved homeodomain of paired-like homeodomain transcription factor



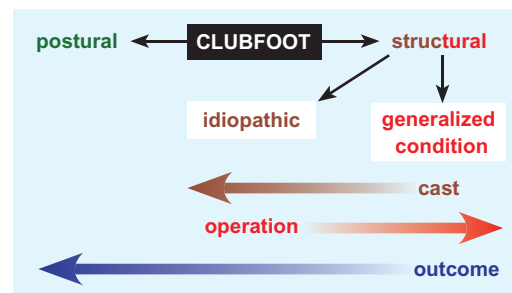
Q Lateral column lengthening On lateral projection, medial longitudinal arch (*orange*), convex to the ground before operation, is concave after. Osteotomy of calcaneus is fixed with retrograde wire (*red*), while osteotomy of medial cuneiform is fixed with staple (*green*). On anteroposterior projection, the head of the talus, uncovered before operation (*blue*), becomes covered as acetabulum pedis rotates medialward as lateral column is lengthened by trapezoid allograft (*red*) in osteotomy of calcaneus.



R Skewfoot The first metatarsal (*green*) and forefoot are adducted relative to midfoot (*orange*). The hindfoot is valgus, with an exposed head of talus (*red*) as navicular is abducted.



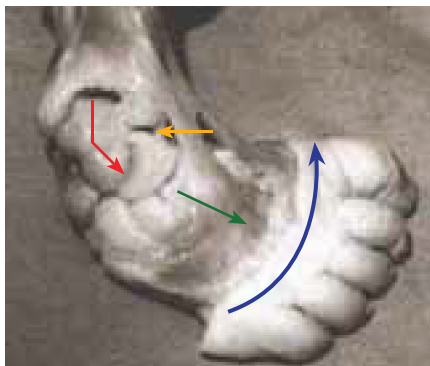
A Clubfoot is ancient Hephæstus, with clubfeet (*white*), led to Olympus by Dionysus (chalice).



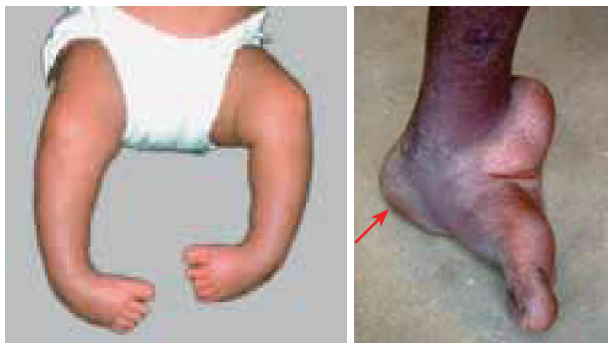B Algorithm for clubfoot Treatment and outcome vary according to subtype.

Cause	Finding
Genetic	Mutation in PITX1 gene (5q31.1). Pairwise concordance in twins.
Bone	Medial and plantar declination of neck of talus. Delayed ossification of talus.
Capsule/ligament	Contracture of plantar aponeurosis, tibionavicular ligament.
Muscle	Shortening of myotendinous junctions in tibialis posterior, triceps suræ, digital flexors.
Vascular	Hypoplasia of tibialis anterior, peroneal arteries.
Nerve	Feature of neural diseases

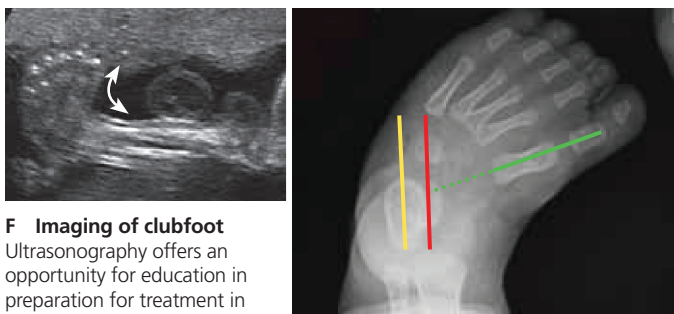
C Cause of clubfoot is multifactorial.



D Pathomechanics Neck of the talus is declined plantar and medialward (red). Acetabulum pedis swings around the head of the talus (blue). Navicular is apposed to malleolus of the tibia (orange). Forefoot is adducted (green).

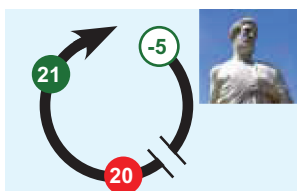


E Natural history of clubfoot Left will progress to right. Note heel pad over the head of the talus (red).



F Imaging of clubfoot

Ultrasonography offers an opportunity for education in preparation for treatment in the immediate neonatal period (white). Röntgenogrammes show parallelism of the talus (red) and calcaneus (yellow), a sign of hindfoot varus, and adductus of forefoot (green).



G Evolution of treatment The dominance of operation (20th century) has ceded to manipulation (21st), returning to what was advocated by Hippocrates (5th BC).

1 (Pitx1) has been found in affected members of a five-generation family. Pitx1 has been found to direct hindlimb morphology and can effect forelimb to hindlimb transformation. In a mouse model, PITX1 deletion results in clubfoot, peroneal artery hypoplasia, and spatially corresponding muscle hypoplasia. PITX1 haploinsufficiency may cause a developmental field defect of the leg, of which clubfoot is the most striking feature.

Pathomechanics

There are several components of clubfoot deformity [D].

- Ankle is *equinus*.
- Neck of the talus is short, plantar flexed and rotated medialward, down to 90 degree (normal 150 degrees).
- Acetabulum pedis is plantar flexed and rotated medialward into hind-foot *varus*, while the trochlea of the talus is retained in ankle mortise. This brings calcaneus parallel to the talus in both sagittal and coronal planes. It swings navicular to appose malleolus of the tibia.
- The forefoot is flexed, producing *cavus*, and deviates medialward into *adductus*.
- Hypoplasia of the limb distal to the knee produces a thin calf and a small foot.

Natural history Untreated disability results from functional reduction of the foot to a single bone [E]. Treatment improves outcome but not always. Casting may lead to no or incomplete correction, and surgery may lead to a stiff foot or an overcorrected foot.

Evaluation Postural clubfoot is supple, and the skin has multiple creases. Exclude other conditions by taking a complete history and examining the entire child. In metatarsal adductus, the heel can be placed into valgus and the ankle has unrestricted motion.

There are many clinical classifications based upon multiple components with variable reproducibility and prognostic utility. Their principal benefit is to focus the physical examination.

- Equinus
- Varus
- Cavus
- Adductus
- Flexibility
- Head of the talus, which is exposed dorsolateral
- Cutaneous creases, posterior and medial
- Stigmata of decompensation, such as callus
- Foot size and stiffness, which are proportional to severity

IMAGING Clubfoot may be diagnosed *in utero* starting at 12 weeks [F]. The finding should persist over time and despite movement. Three-dimensional ultrasonography does not add value. Complete survey for fetal compression (e.g., fibroids) and for other anomalies: false-positive rate is up to 40%. While deformity may be seen on röntgenogrammes [F], because management begins soon postpartum, and because radiographic correlations with outcomes are unclear, this modality is reserved for the older child, in particular as part of operative preparation.

Management The clubfoot is intrinsically diseased and never will be normal. The calf always will be thin, the foot always small and different in appearance. Management has evolved in a circle [G]. The goals of treatment are to do no harm and to achieve normal function [H].

CASTING (PONSETI) This is effective for >90% of cases begun in the first few weeks of life. It also is effective, or at least an aid, for patients in the first few years of life. Fundamental is an understanding of the acetabulum pedis.

- An above-knee cast is applied every week for 6 weeks.
- The deformity is approached sequentially according to the acronym CAVE (Cavus, Adductus, Varus, Equinus).
- The first cast pushes up against the first ray to reduce cavus, supinating the forefoot and exaggerating the deformity.

- The forefoot is pushed to swing the acetabulum pedis around the head of the talus.
- Counterpressure is applied against the head of the talus or against the malleolus of the fibula [I]. The former is more effective by being at the center of rotation but risks pressure phenomenon where the skin is thinnest. The latter relies on securing the talus in ankle mortise, which is supported against lateral distortion.
- Do not address equinus until other components of deformity are corrected. The tendo Achillis is the tether, securing the ankle, against which the subtalar joint is manipulated.

TENDO ACHILLIS SECTION This is indicated for equinus, in 90% of case. Zealous ankle flexion against an unyielding tendo Achillis risks dorsiflexion at the midfoot, creating a rocker-bottom deformity.

- A percutaneous heel cord tenotomy is performed in office or in operating room.
- Topical cream provides only cutaneous anaesthesia. Injection of anaesthetic may distort anatomy and risk posteromedial neurovascular bundle.
- Insert scalpel parallel to medial border of tendo Achillis 1 cm proximal to calcaneus.
- Advance blade into space anterior to tendon (which may be developed by a clamp), turn 90 degree, and cut posteriorward.
- Apply final cast in hypercorrected position.

BRACING This is indicated for all patients (J).

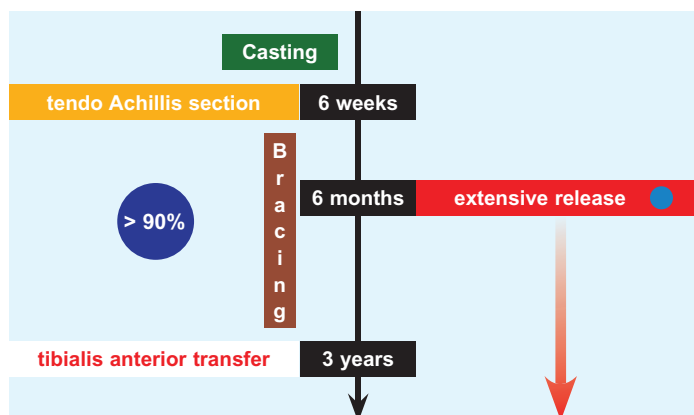
- The brace consists of firm above-ankle boots connected by a metal bar, set at shoulder width. A pad above the heel prevents the foot from slipping out of the shoe. There have been multiple modifications.
- The original concept was “to control the position of one foot by means of the other” (Browne). Extension of one limb during spontaneous kicking drives the subtalar joint of the flexed limb into eversion.
- The brace is worn full time until standing, after which it is applied during sleep until 3 years of age.
- Recurrence is indirectly proportional to compliance with bracing. While the design is simple, application can be challenging over time and as the child becomes older.

TIBIALIS ANTERIOR TRANSFER After 3 years of age, this is indicated for residual dynamic supination. Perform after structural (static) deformity, which a tendon transfer cannot overcome, has been corrected. The tendon is moved *in toto* (not split as in neuromuscular disease) to lateral cuneiform [K].

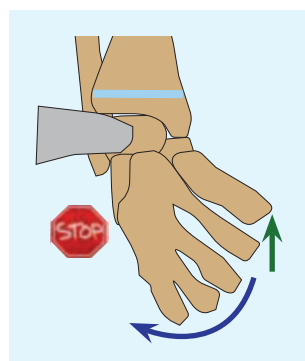
For idiopathic clubfoot resistant to the above approach, or in clubfoot associated with other condition, a formal surgical correction may be indicated, starting at 6 months of age. Do not offer a “blue plate special” to every patient; rather, follow an “a la carte” approach according to location and severity of deformity [L].

POSTERIOR RELEASE

- Prone position is easier because the limb needs no manipulation but less familiar.
- A variety of incisions have been advocated, including circumferential (Cincinnati) from base of 1st metatarsal medial passing 1 cm proximal to posterior ankle crease to tip of fibular malleolus lateral.
- Mobilize neurovascular bundle.
- Z-lengthen tendo Achillis, starting medial at calcaneus.
- Trace flexor hallucis longus, which has a distal muscle belly, to the posterior capsule of the subtalar joint, which is opened circumferentially. Preserve the talocalcaneal and deep deltoid ligaments.
- Section calcaneofibular ligament deep to peroneal tendons.



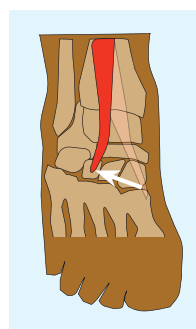
H Algorithm for treatment of clubfoot.



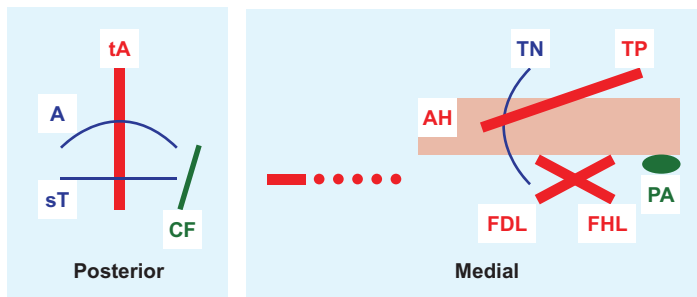
I Casting technique (Ponseti) Start by elevating the first ray to correct cavus (green). Swing acetabulum pedis (blue) around the talus, which is stabilized by pressure at the exposed head (grey) or at malleolus of fibula. Do not correct the midfoot and forefoot distal to acetabulum pedis (STOP), for example, about a fulcrum at calcaneocuboid joint (Kite).



J Browne brace Firm ankle boots are screwed to a metal bar at shoulder width in abduction that may be bent for eversion.



K Tibialis anterior transfer The tendon is moved *in toto* to lateral cuneiform.



L Components of surgical release for clubfoot tA: tendo Achillis. A: ankle joint. sT: subtalar joint. CF: calcaneofibular ligament. AH: abductor hallucis. PA: plantar aponeurosis. TP: tibialis posterior. TN: talonavicular joint. FHL: flexor hallucis longus. FDL: flexor digitorum longus. The flexors may be distally at the toes (*dotted*).



M Ilizarov frame Complex procedure for complex deformity.

MEDIAL RELEASE

- Release the three origins of the abductor hallucis muscle distal, between medial and lateral plantar nerves, and proximal at tuber of calcaneus, thereby opening the “door to the cage” (Henry)
- Perform a plantar release (*cf.* Cavus)
- Z-lengthen tibialis posterior tendon
- Perform a capsulotomy of talonavicular joint

DIVISION OF TOE FLEXORS

- This may be performed through the medial approach or fractionally posterior to the tibial malleolus.
- Alternatively, it may be performed distally. With dorsiflexion tension applied to the ankle, insert a scalpel in the midline of the base of the each toe, cutting flexor tendon by a narrow arc windshield wiper action. Division at this level preserves the tendon sheath, allowing rapid tendon regeneration without adhesion formation.

OSTEOTOMY This is indicated as a supplement to soft tissue work, or in case of undercorrection. Persistent deformity impairs outcome.

- Persistent adductus interferes with shoe wear. This may be addressed by medial column lengthening through medial cuneiform, or lateral column shortening. The former may be more effective as it is accommodating to overall contracture rather than pushing against it. Partial resection of cuboid is joint sparing compared with calcaneocuboid arthrodesis (Evans) or arthroplasty (Lichtblau).
- Persistent varus leads to excessive plantar pressure over the lateral border of the foot. It may be improved by lateral displacement of calcaneus. Wedge osteotomies stretch the medial soft tissues if open and may result in lateral impingement if closing.

EXTERNAL FIXATION Advanced deformity in older children may be managed with an Ilizarov frame [M], which allows gradual stretch of severe contracture and when extensive scarring precludes internal reconstruction. Orthotic support after removal of frame guards against recurrence of deformity.

SALVAGE For uncorrectable clubfoot, talectomy provides enough room in the ankle to position the foot plantigrade. The same may be achieved by wide resection and arthrodesis. These procedures are appropriate for patients with limited physical demand.

Complications

RECURRENCE This is most common. It is inversely proportional to compliance with nonoperative management, including bracing. Manage with education, repeat casting, and bracing.

STIFFNESS This may result from excessive articular pressure during casting, compartment syndrome complicating surgery, avascular necrosis of the talus, and operative scarring.

OVERCORRECTION This includes opposite deformity and weakness. Excessive hindfoot valgus from enthusiastic release, in particular of talocalcaneal and deltoid ligaments, results in incompetence of subtalar joint. Calcaneus and remainder of foot displace lateralward out from under talus. Triceps surae may be weakened by overlengthening or repeated lengthenings. Flexor recruitment in this setting, exacerbated by hyperactive tibialis anterior, may lead to dorsal bunion (*q.v.*). Unlike casting, where overcorrection is the goal, err on the side of undercorrection at surgery. Overcorrection is difficult to rectify.

Vertical Talus

While it may be regarded as the most severe rigid flatfoot, it also is known as rocker-bottom foot, for the convexity of the plantar surface [N]. Half of cases are bilateral. It is distinguished by its rigidity from *oblique talus*, which is abnormally plantar flexed but which may be reduced manually and on stress röntgenogrammes.

Cause More than half of cases are associated with other conditions, which may be divided into central nervous system (e.g., spina bifida), neuromuscular (e.g., arthrogryposis), and syndromes (e.g., Costello, deBarys). Fifteen percent of cases have a family history. A mutation in HOXD10 gene (2q31.1) has been implicated, which also is associated with foot deformity typical of Charcot-Marie-Tooth disease. HOX gene mutations have been found in radioulnar synostosis and hand-foot-genital syndrome.

Pathomechanics

- The essential lesion is in the midfoot: talonavicular dislocation. This displaces the remainder of the distal foot toward dorsad and lateralward, where a soft tissue contracture develops, including the tendons of the anterior and lateral crural compartment muscles.
- In the hindfoot, the calcaneus is plantar flexed into equinus and rotated lateralward, with concomitant contracture of triceps suræ.
- In severe cases, subluxation of tibialis posterior–anterior to tibial malleolus and peroneals over the fibular malleolus converts these into dorsiflexors, exacerbating deformity.

Evaluation Even more importantly than clubfoot, exclude other condition by taking a complete history and examining the entire child. Head of the talus projects into the plantar aspect of the foot, producing a convex sole. Hindfoot is in equinus and valgus, which aids distinction from calcaneovalgus. The forefoot is dorsiflexed and abducted. There are simultaneous contractures of dorsiflexors and plantar flexors. There is a deep dorsal cutaneous crease, in which a gap is noted where the head of the talus is absent.

IMAGING Lateral projection röntgenogramme demonstrates a talus that is vertical, in line with the tibia [O]. Dorsiflexion and plantar flexion stress views show no change in orientation of the talus and no change in its relationship with navicular or the 1st metatarsal (if navicular is not ossified in the infant), suggesting fixed dislocation of talonavicular joint [P]. The calcaneus is plantar flexed into equinus.

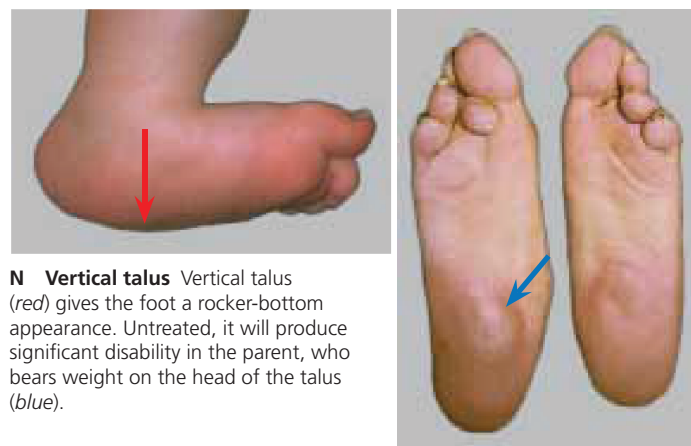
Management Akin to clubfoot, surgical management of vertical talus has evolved from extensive and complex to directed and less invasive.

CASTING Six serial weekly casts are applied as the forefoot is manipulated into plantar flexion and inversion against counterpressure applied to the head of the talus. Confirm talonavicular reduction by röntgenogramme. The foot now resembles a clubfoot in equinus.

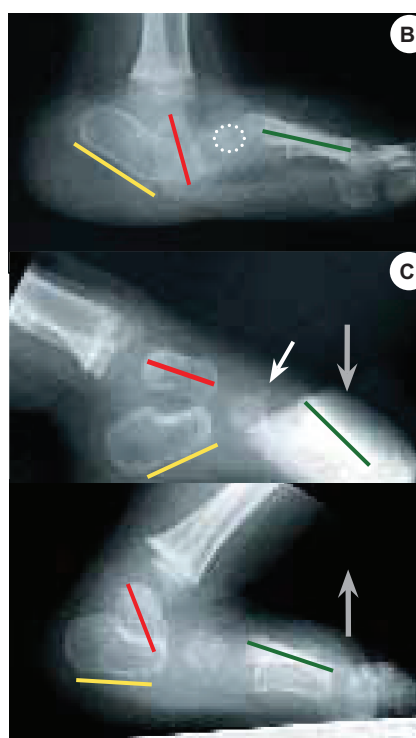
TENDO ACHILLIS SECTION This is performed like clubfoot.

DORSAL WITHOUT OR WITH POSTERIOR RELEASE Indication is failure of talonavicular reduction by casting.

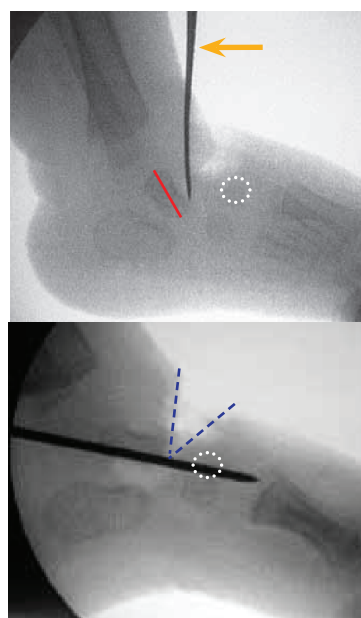
- A transverse incision is made over talonavicular joint. Extensor tendons are fractionally lengthened in the distal leg. Perform capsulotomies of the ankle, talonavicular, and calcaneocuboid joints. Use a blunt elevator as a shoehorn to reduce talonavicular joint, which is held with a wire.
- Perform a percutaneous tendo Achillis section to correct equinus.
- In an older patient, consider open Z-lengthening of tendo Achillis, as well as ankle and subtalar capsulotomies.



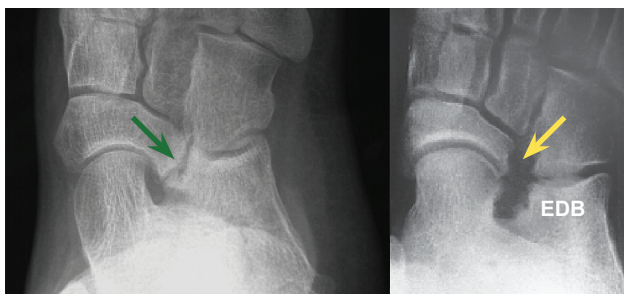
N Vertical talus Vertical talus (red) gives the foot a rocker-bottom appearance. Untreated, it will produce significant disability in the parent, who bears weight on the head of the talus (blue).



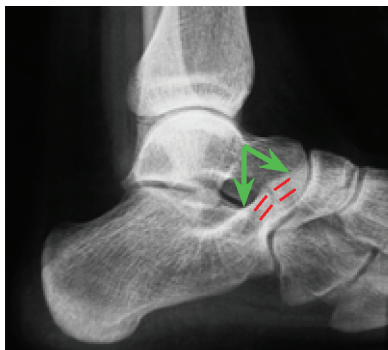O, P Imaging Vertical talus (red) is plantar flexed vertical, calcaneus is plantar flexed into equinus (yellow), navicular (white) is dislocated dorsad on the talus, and talo–first metatarsal relationship shows increased angulation and dorsad displacement. An oblique talus, the talus moves from vertical position, calcaneus from equinus, navicular from a reduced position, and the 1st metatarsal from alignment with the talus in plantar flexion stress view to oblique position, normal pitch, and dorsad displacement of navicular and 1st metatarsal, respectively, under dorsiflexion stress.



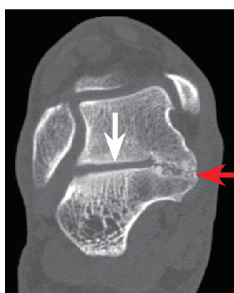
Q Operation for vertical talus Dislocation of navicular (white) on the talus is approached directly via a dorsal incision (blue), through which soft tissue contractures also may be addressed. It is reduced (orange) and fixed with a wire.



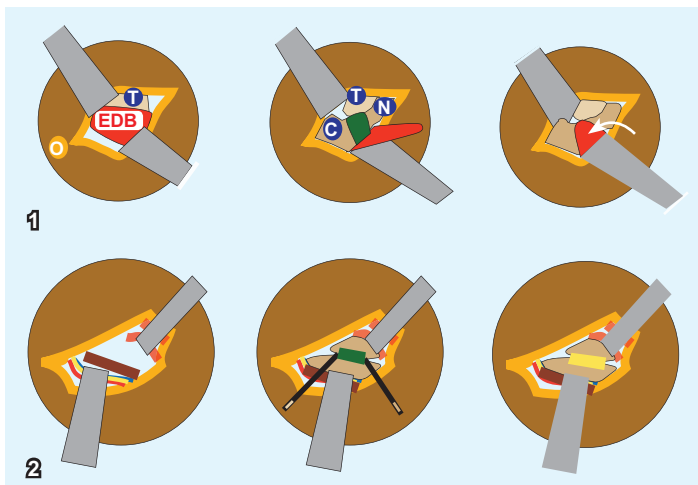
R Calcaneonavicular coalition A nonossified coalition (green) is resected to talonavicular and calcaneocuboid margins, leaving a gap (yellow), which may be filled with extensor digitorum brevis (EDB) or fat.



S Anteater sign Anterior process of calcaneus is long, gracile, and curved (green) as it extends into navicular, with which it forms a coalition (red). The dorsal margin of the talus does not show beaking, which in children is a traction phenomenon secondary to stress transfer, while in adults, it may be a degenerative sign.



T Talocalcaneal coalition CT axial view shows the middle facet compartment is irregular (red), while the posterior is preserved (white). This is definitive and quantifiable.



U Excision of calcaneonavicular (1) and talocalcaneal (2) coalitions
1. T: talus. EDB: extensor digitorum brevis. C: calcaneus. N: navicular. O: Ollier.
2. Neurovascular bundle and flexor hallucis longus retracted plantarward. Keith needles (black) delimit coalition. Fat graft (yellow).

Tarsal Coalition

The term may be misleading: this is not an active process of coalescence but a failure of segmentation. Two types represent the majority: talocalcaneal and calcaneonavicular. They may be familial, bilateral, and multiple. One percent incidence suggests that most coalitions are silent. However, coalition reduces motion, may produce a rigid deformity of the foot, and imposes increased stress on adjacent joints, which may elicit pain, muscle spasm, and risks degenerative arthritis. Coalitions may be present in other disorders, such as clubfoot and limb deficiency, in which there also may be a ball and socket ankle.

Evaluation Presentation is early second decade. Obtain a family history: autosomal dominant inheritance has been demonstrated. This is the most common cause of rigid flatfoot, although half of coalitions do not produce this deformity. Rule out other cause of restricted joint motion in the foot, such as juvenile idiopathic arthritis. Coalitions may be fibrous or cartilaginous, which manifest as irregular narrowing on imaging, or osseous, which accounts for the greatest stiffness but may be least symptomatic because of their stability. Röntgenogrammes usually suffice for diagnosis. CT defines anatomy for operative planning and screens for other coalition. CT and MRI aid mapping of articular coalitions; the latter also evaluates soft tissues for other lesion. Scintigraphy may illuminate an atypical clinical presentation.

Management Initial management is symptomatic and supportive, including with orthotic or 6-week cast. Operative treatment is indicated for persistent unacceptable pain and significant foot deformity [Q].

Calcaneonavicular Coalition This is extra-articular: as such, there is less stiffness and deformity, and outcomes of resection are better. Locus of pain is sinus tarsi. It is seen *en profil* by oblique projection röntgenogramme [R]. Lateral projection may show extension of anterior process of calcaneus to navicular, resembling the snout of an anteater [S].

Resection is performed through an oblique incision over sinus tarsi [U]. Extensor digitorum brevis (EDB) is elevated from its origin at the anterior calcaneus. The coalition is resected to the borders of talonavicular and calcaneocuboid joints. The resultant gap may be filled with EDB, pulled in by sutures drawn through the sole and tied over a button, or with fat harvested from the area of the natal crease, which by sparing EDB does not distort the dorsal contour of the foot.

Talocalcaneal Coalition This is articular: it tends to create more stiffness and deformity and to have poorer outcomes. Locus of pain is medial hindfoot. The coalition begins at the middle facet, from which it may reach into the posterior facet. It is seen best on a Harris axial view: the middle facet joint is irregular, fused or invisible, or it may be inclined >20 degrees. Other signs, such as C margin of the talus on lateral projection, are debatable. CT [T] and MRI are essential to map the extent of articular involvement: any significant invasion of the posterior facet precludes resection.

Surgery must address both coalition, as source of pain, and deformity, against worsening of which the coalition may be a final tether. A calcaneus in valgus (>15 degrees) may be liberated to decline further by resection of a medial coalition. Such operation should include resection of coalition and lateral column lengthening. Approach coalition *via* a linear incision from anterior margin of tendo Achillis to navicular. Take down abductor hallucis, retract neurovascular bundle, and develop interval between flexor digitorum longus and flexor hallucis longus, which courses under sustentaculum tali. Identify normal posterior and anterior subtalar compartments to delimit the middle facet coalition. Define the plane of nonosseous coalition bluntly to guide excision, which continues until normal cartilage surfaces are visible and there is unrestricted subtalar motion. Repair the flexor retinaculum to retain the fat graft.

Consider talocalcaneal arthrodesis for coalition of $>50\%$ of total subtalar surface area, as excision leaves insufficient articular surface for reasonable joint function. Correct deformity by appropriate angulation of joint resection and fusion planes.

ANKLE

Toe Walking

This may be idiopathic or associated with other condition, including clubfoot, cerebral palsy, spina bifida, muscular dystrophy, arthrogryposis [A]. Contracture may involve a short triceps surae *in toto*, gastrocnemius muscle, or accessory soleus muscle. In the uninvolved child, it may be an atavistic trait.

Natural history Most idiopathic toe walking resolves in the first few years, though residual triceps surae may persist. Morbid toe walking does not improve.

Evaluation Exclude other disease by taking a complete history and examining the entire child [B]. Is gait equinus, flatfoot, or normal hell-toe? Is the shape of the foot triangular, reflecting osseous reaction to differential force? Are the toes splayed? Check the skin for callus, suggesting decompensation. Determine site of contracture by performing Silfverskiöld test: lock subtalar joint by inverting the heel, and flex the ankle with knee flexed and knee extended [C]. Significant difference in ankle motion suggests selective contracture of gastrocnemius muscle.

Management There are no long-term functional outcome studies. Toe walking is unsightly for many. It interferes with shoe wear. Shifting force distal in the foot theoretically risks deformity, pain, and overuse injury such as stress fracture.

Stretching, including with a physiotherapist, is difficult in this age group. Serial casting takes control but may not provide a durable result. Orthotics, such as an articulated ankle-foot having a plantar flexion block, with no end point may be a greater treatment burden than surgery.

Because most improve spontaneously, and because recurrence is greater before 4 years, do not operate before that age. For persistent toe walking, surgical lengthening is low morbidity and effective.

GASTROCNEMIUS RESECTION This is indicated in the presence of a Silfverskiöld sign. The incision is linear at the myotendinous junction midline or along medial border of gastrocnemius. Sural nerve may enter surgical field, often heralded by accompanying vein. Divide plantaris. Separate widely gastrocnemius aponeurosis from that of subjacent soleus: this allows selective section of the former and free retraction of its edges with ankle flexion in knee extension. The aponeurotomy may be chevron (Vulpinus), tongue-in-groove (Baker), or transverse (Strayer). While there is no risk of overcorrection, undercorrection is possible: preoperative ankle flexion must be >10 degrees with the knee flexed, which simulates operative result.

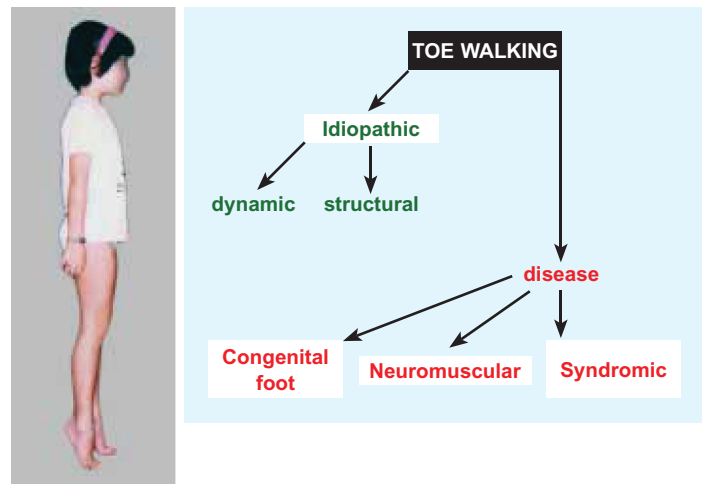
HEEL CORD LENGTHENING Indication is triceps surae contracture, or insufficient ankle flexion (<10 degrees) with the knee flexed. This may be percutaneous or open. The former may be two anatomic cuts (*white*), rotated 45 degrees to account for the normal rotation of the tendo Achillis fibers [D]. Alternatively, three cuts (Hoke) may be performed in the same plane, to cut enough fibers to effect a lengthening. Open Z-lengthening, *via* a linear incision parallel but off the medial margin of the tendon, leaves a visible scar but offers more control. Repair the tendon under moderate tension in neutral ankle position to avoid excessive lengthening, which will lead to weak push-off and is difficult to salvage.

Ball and Socket Ankle

This is an acquired deformity secondary to extensive osseous tarsal coalition, which is congenital [E], in particular in association with limb deficiency. The ankle is molded into a socket that allows inversion–eversion in addition to flexion–extension, to compensate for loss of subtalar motion. The tarsal coalition is too extensive to take down: it may be completed if symptomatic. Ball and socket is not addressed *per se*; rather, treatment focuses on limb deficiency.

Tarsal Tunnel Syndrome

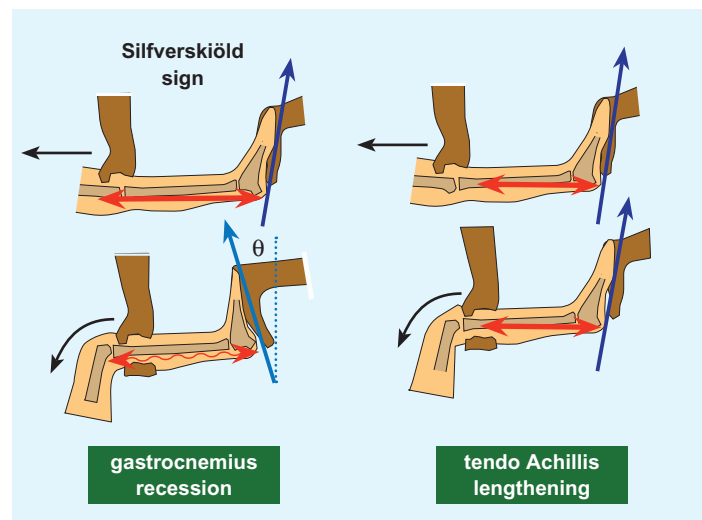
The passage of tibial nerve, posterior tibial artery, tibialis posterior, and long digital flexor tendons from the leg into foot is converted into



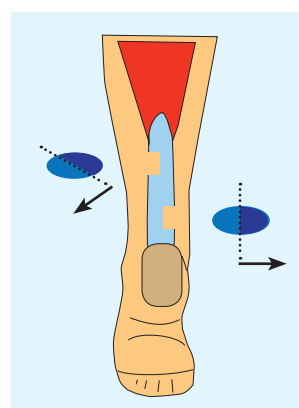
A Algorithm for toe walking.

Feature	Idiopathic	Disease
Geography	Localized	General
	Bilateral	Bilateral
Development	Normal mile-stones	Delayed, including walking > 18 months
Timing	Walking age	Independent
Natural history	Most improve	Static or progressive

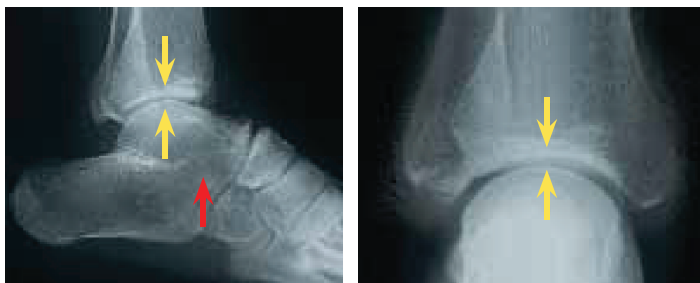B Features of idiopathic versus morbid toe walking.



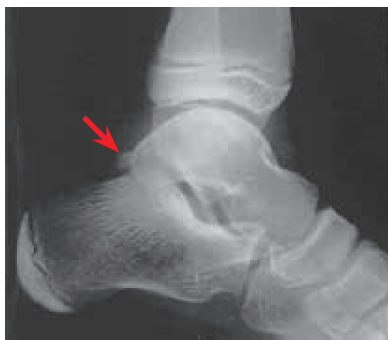C Locus of contracture This influences operation. Perform a tendo Achillis lengthening if $\theta < 10$ degrees.



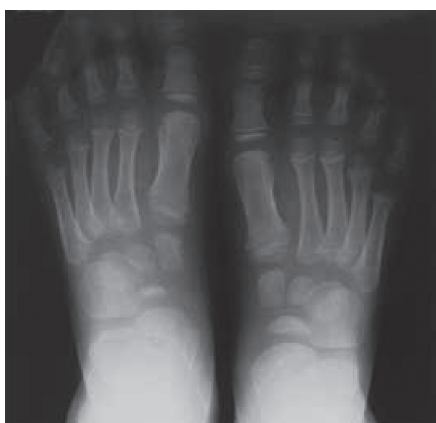D Tendo Achillis lengthening The anatomic percutaneous technique adjusts the angle of two step-cuts according to the normal rotation of the tendon's fibers.



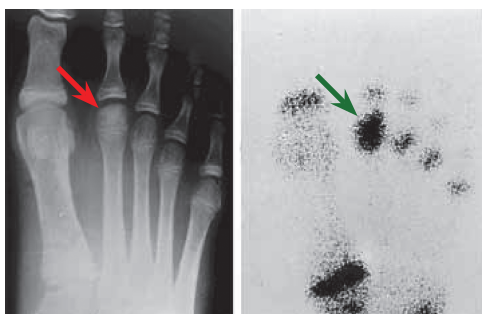
E Ball and socket ankle There is an extensive talocalcaneal coalition (red) subjacent to a spherical talar trochlea articulating with a spherical ankle socket, rounded in orthogonal planes (yellow).



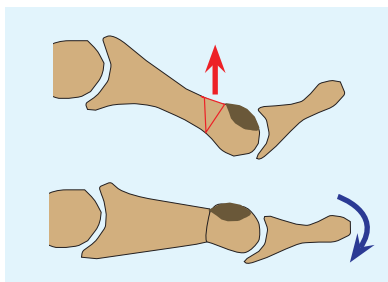
F Os trigonum Incidental finding of a secondary ossification center separate from the talus. The regular appearance is consistent with an accessory ossicle in an asymptomatic child.



G Köhler disease The navicular is small, collapsed and hyperdense (red), and the site of tenderness.



H Freiberg infraction The 2nd metatarsal head shows sclerosis but no collapse or other irregularity (red). Scintigramme shows increased uptake (green).



I Metatarsal osteotomy for Freiberg infraction Realignment of the avascular segment (brown).

the tarsal tunnel extension of the flexor retinaculum (lacinate ligament) from malleolus of the tibia to calcaneus and plantar aponeurosis.

Evaluation Rarity in children results in delayed diagnosis. Insidious onset medial ankle pain, including at night, together with plantar dysaesthesia in adolescent girls more than boys. Tinel sign is pathognomonic on physical examination, which also reveals inversion of the hindfoot to relax tibial nerve such that the patient walks on the lateral border of the foot. Dorsiflexion–eversion is a provocative test to stretch tibial nerve. Delayed tibial nerve conduction confirms the diagnosis. A local anaesthetic block aids prediction of operative result.

Management Rest the ankle by modifying activity and with an orthotic as necessary. Decompression of the tarsal tunnel is indicated for persistent symptoms and disability. Include the flexor retinaculum, and the origins of abductor hallucis muscle from calcaneus and plantar aponeurosis proximally as well as from between medial and lateral plantar nerves.

Os Trigonum

This secondary ossification center may remain separate from the posterior lateral rim of the talus as a silent accessorium [F]. Such an ossicle has smooth borders without sclerosis. If the bone is fractured off the talus during forced ankle extension under load, such as *en pointe*, it will hurt and will continue to do when this action is repeated.

Evaluation Dancers are most affected. Pain is localized to the posterior ankle with stress manoeuvre. Röntgenogrammes show the bone, which may move on flexion and extension lateral views of the ankle. Scintigraphy shows focal increased uptake. MRI will show inflammatory changes in the bone and surrounding soft tissue, including flexor hallucis longus tenosynovitis.

Management Symptom control and activity modification may not be practicable in an active child, such as a ballerina. If unacceptable pain persists, excise the ossicle and decompress the flexor hallucis longus *via* an incision off the lateral border of tendo Achillis or with the assistance of an endoscope.

Osteochondrosis

Sever and Köhler conditions (not “diseases,” not “syndromes”) are relatively common and benign, having a natural history characterized by spontaneous resolution with supportive care for pain. Freiberg infraction is rare and obscure, with grave potential.

Sever

This represents apophysitis of the calcaneus. Traction by the tendo Achillis, developmentally short or tightened by growth acceleration, results in micromotion between apophysis and remainder of bone.

Evaluation Presentation is at the turn of the decades. There is tenderness over the apophysis. There is contracture of triceps surae, which reproduces the pain upon stretching and may elicit posterior knee pain at the origin of gastrocnemius. Imaging is negative; in fact, röntgenogrammes may raise unnecessary concern about the normal fragmented and sclerotic appearance of the apophysis.

Management Address the tight triceps surae either by compensating for it, for example, with a heel lift, or by stretching it, with exercises. Educate the patient and family that this will resolve but may take months.

Köhler

Collapse, sclerosis, and fragmentation of the navicular [G]. A propensity for boys, in whom the bone ossifies 1 to 2 years later (by 5 years of age) and therefore may be mechanically vulnerable to repetitive injury, the radiographic appearance, and histologic studies showing necrotic bone suggest a vascular insult. This insult is transient and reversible, because the bone recovers completely.

Evaluation Presentation is in the middle of the 1st decade. There is focal tenderness at navicular, which may be prominent and red due to inflammation. Röntgenogrammes confirm the diagnosis and alarm the parents; they also demonstrate reconstitution over 1 to 3 years.

Management Educate parents that this looks worse than it is, including a > 30-year follow-up study showing no sequelæ in adulthood. Modify activity. For significant pain, for example, limp, unable to play, or participate in sports, apply a below-knee walking cast for 6 weeks.

Freiberg Infraction

Infraction reflects avascular necrosis, affecting the 2nd metatarsal head. Implicated causative factors include repetitive trauma, tenuity of blood supply, and abnormal loading of a prolonged 2nd metatarsal.

Evaluation Presentation is in the second decade, more often in girls. There is focal tenderness, limp, and poor push-off. Röntgenogrammes show collapse and irregularity of the 2nd metatarsal head. Scintigraphy may establish the diagnosis before radiographic change [H].

Management Educate the patient and parents that this may not resolve completely. Administer anti-inflammatory agents for a scheduled short course or *pro re nata*. Rest the foot in a cast for 6 weeks and follow with a custom orthotic to unload the 2nd metatarsal head or a firm sole shoe. Modify activity to minimize foot trauma.

Operative treatment is indicated for residual articular incongruity and overgrowth leading to persistent pain and degenerative changes.

- Joint débridement alleviates pain but may not be durable.
- Excisional arthroplasty of the proximal 2nd phalanx with interposition of the tendon of extensor digitorum longus decompresses the 2nd metatarsal head.
- Dorsiflexion osteotomy of the 2nd metatarsal may redirect a geographic lesion away from the weight bearing or joint loading [I].

TUMORS

The foot makes up 3% of body mass but 6% of musculoskeletal tumors. Weight bearing and exposure of the foot accelerate diagnosis. Indistinct fascial boundaries in mid- and hindfoot do not permit radical resection, by contrast with the forefoot, where ray resection permits salvage. Prosthetic replacement is compatible with good function.

Soft Tissue

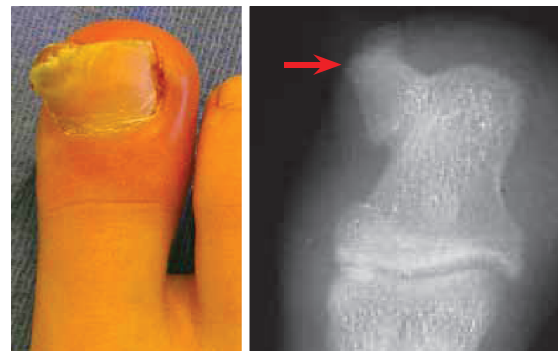
Ganglion (Greek γαγγλιον: “knot, tumor, cyst”) is most common and most benign. It is associated with joint or tendon and may be mistaken for an osseous excrescence, which may be ruled out by röntgenogramme. Treat symptomatically and accommodate to it, including by shoe and activity modification. Lesions responsible for unacceptable pain or dysfunction may be excised. Remain extracapsular to trace the stalk to its origin. Perform a capsulectomy to prevent reaccumulation by a one-way valve mechanism.

The benign tumors plantar fibromatosis and pigmented villonodular synovitis, as well as the malignant synovial cell sarcoma, are discussed in Tumors (*q.v.*).

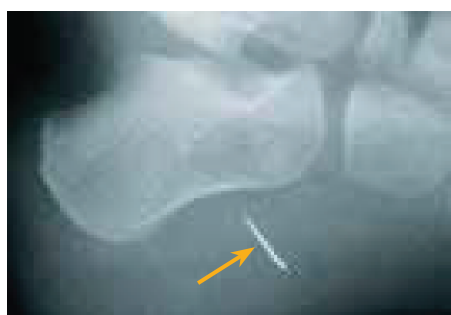Bone

Subungual exostosis arises frequently from the hallux [A]. The tumor displaces and distorts the nail plate and wall. As a result, it often is misdiagnosed as an infection or soft tissue excrescence and treated by other health care providers as such. Lack of success ultimately prompts referral or röntgenogrammes, which reveal the osseous lesion arising from the distal phalanx. Excise the lateral border of the nail plate for exposure. Sharply dissect the disrupted matrix to allow the most anatomic repair. Resect the entire osteochondroma flush with normal phalangeal cortex. Sew wall to plate to close the space.

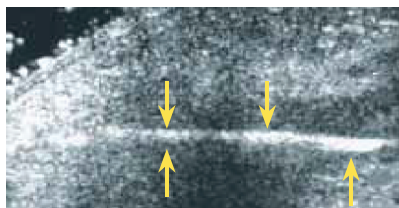
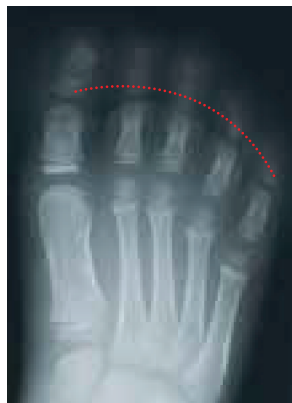The benign tumor cysts and chondroblastoma, as well as the malignant osteosarcoma, are discussed in Tumors (*q.v.*).



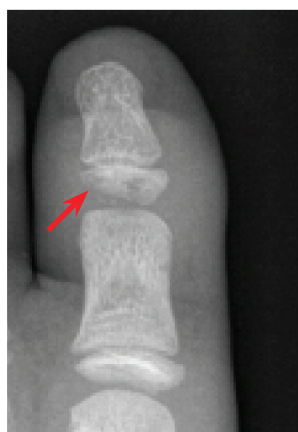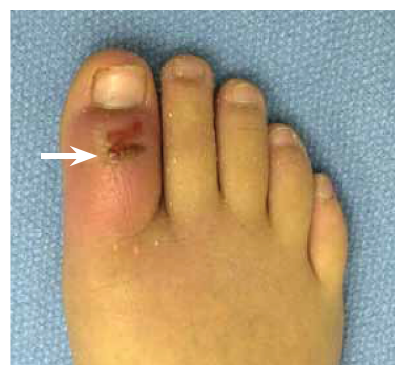A Subungual exostosis This may be mistaken for infection or soft tissue excrescence. Röntgenogrammes confirm the diagnosis (*red*).



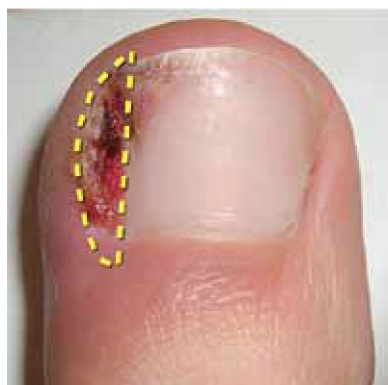A Needle penetration into heel Site of entry and surrounding inflammation (red) correspond with röntgenogrammes showing a broken tip (orange).



B Wood puncture The foot is swollen (red). Ultrasonogramme reveals a wood fragment (yellow) when röntgenogrammes show no foreign body.



C Pseudomonas infection Delayed presentation of redness and swelling around a puncture wound (white) correlated with epiphysial erosion (red) suggestive of interphalangeal pyarthrits.



D Winograd operation for infected ingrown toenail Excises granulation tissue, lateral margin of plate, and germinal as well as sterile matrices (yellow).

INFECTION

Puncture Wounds

Most are plantar. Most infections are by *Staphylococcus aureus*. In shoes, *Pseudomonas aeruginosa* becomes a significant though still secondary agent.

Evaluation Rule out retained foreign body. Röntgenogrammes show metal [A] and some glass according to lead content. They also show soft tissue swelling, obscuration of fascial planes, gas, and osteomyelitis. Ultrasonography is useful for wood and other radiolucent material [B]. Time to presentation of associated infection suggests the organism: 1 to 3 days *S. aureus*, 7 to 10 days *P. aeruginosa*. Site also is suggestive: *P. aeruginosa* is unlikely remote from a joint, such as the heel pad. Delayed presentation of redness and swelling is typical of pyarthrits by *P. aeruginosa*, which is chondrophilic and slow growing [C].

Management Update tetanus immunization. Wound exploration in the emergency setting is too much for the child and often for the surgeon: do this in the operating room, where a thorough irrigation can be performed. For clean wounds, administer an antibiotic *per venam* to cover gram-positive organisms and follow within the week. Operative treatment is indicated for a dirty contamination, such as from a farm, together with expanded coverage for gram-negative and anaerobic organisms. Educate parents to return for any sign of delayed infection, including pain, redness, swelling, and fever over the subsequent 7 to 10 days, the temporal window for *Pseudomonas* pyarthrits. This is a surgical emergency.

Paronychia

Infected ingrown toenails [D] result from anatomical predisposition, improper nail trimming, and repetitive trauma in a shoe. There is a greater lateral curvature of the nail plate into the nail wall. Nails are trimmed too proximal, such that during growth, the corner of the plate drives into rather than clear of the distal extension of the nail wall. Shoe preference is tight with a narrow toe box. The most common pathogen is *S. aureus*.

Evaluation Granulation tissue overlies the junction of the nail plate and wall, which is swollen and tender.

Management Educate the patient on proper nail trimming, which includes leaving the corners of the plate clear of the walls rather than continuing in a smooth round contour. Institute warm dilute soap water soaks twice daily. Insert a cotton wisp under corner of plate twice daily to provide a ramp that separates the plate from the wall during growth. Antibiotics accelerate recovery.

For persistent or recurrent infection, matricectomy is indicated (C). Débride granulation tissue gently, in order not to damage nail wall for later repair. Excise the lateral edge of the nail plate. Curette away subjacent germinal and sterile matrices to bone of phalanx. Repair of wall to remaining plate narrows the nail.

TOE DEFORMITY

- Aikin OF. The treatment of hallux valgus: a new operative procedure and its results. *Med. Sentinel* 33:678–679, 1925.
- Albuisson J, Isidor B, Giraud M, Pichon O, Marsaud T, David A, Le Caignec C, Bezieau S. Identification of two novel mutations in Shh long-range regulator associated with familial pre-axial polydactyly. *Clin. Genet.* 79(4):371–377, 2011.
- Chang CH, Kumar SJ, Riddle EC, Glutting J. Macroductyly of the foot. *J. Bone Joint Surg.* 84-A:1189–1194, 2002.
- Cockin J. Butler's operation for an over-riding fifth toe. *J. Bone Joint Surg.* 50-B(1):78–81, 1968.
- Furniss D, Critchley P, Giele H, Wilkie AOM. Non-sense-mediated decay and the molecular pathogenesis of mutations in SALL1 and GLI3. *Am. J. Med. Genet.* 143A(24):3150–3160, 2007.
- Girdlestone GR. *J. Chartered Soc. Physiotherapy* 32:167, 1947.
- Lichtblau S. Section of the abductor hallucis tendon for correction of metatarsus adductus varus deformity. *Clin. Orthop.* 110:227–232, 1975.
- M^cBride ED. A conservative approach to bunions. *J. Bone Joint Surg.* 10:735–739, 1928.
- Peterson HA, Newman SR. Adolescent bunion deformity treated with double osteotomy and longitudinal pin fixation of the first ray. *J. Pediatr. Orthop.* 13(1):80–84, 1993.
- Radhakrishna U, Blouin J-L, Mehenni H, Patel UC, Patel MN, Solanki JV, Antonarakis SE. Mapping one form of autosomal dominant postaxial polydactyly type A to chromosome 7p15-q11.23 by linkage analysis. *Am. J. Hum. Genet.* 60(3):597–604, 1997.
- Shea KG, Mubarak SJ, Alamin T. Preossified longitudinal epiphyseal bracket of the foot: treatment by partial bracket excision before ossification. *J. Pediatr. Orthop.* 21(3):360–365, 2001.
- Taylor RG. The treatment of claw toes by multiple transfers of flexor into extensor tendons. *J. Bone Joint Surg.* 33-B(4):539–542, 1951.
- Umm-e-Kalsoom BS, Kamran-ul-Hassan NS, Ansar M, Ahmad W. Genetic mapping of an autosomal recessive postaxial polydactyly type A to chromosome 13q13.3-q21.2 and screening of the candidate genes. *Hum. Genet.* 131(3):415–422, 2012.

FOREFOOT

- Kite JH. Congenital metatarsus varus: report of 300 cases. *J. Bone Joint Surg.* 32(3)-A:500–506, 1950.

HINDFOOT

- Alvarado DM, M^cCall K, Aferol H, Silva MJ, Garbow JR, Spees WM, Patel T, Siegel M, Dobbs MB, Gurnett CA. Ptx1 haploinsufficiency causes clubfoot in humans and a clubfoot-like phenotype in mice. *Hum. Mol. Genet.* 20(20):3943–3952, 2011.
- Anderson RJ. The presence of an astragaloschaphoid bone in man. *J. Anat. Physiol.* 14:452–455, 1879.
- Browne D. Modern methods of treatment of club-foot. *Br. Med. J.* Sep:570–572, 1937.
- Cowell HR. Extensor brevis arthroplasty. *J. Bone Joint Surg.* 52-A:820, 1970.
- Crim J, Kjeldsberg K. Radiographic diagnosis of tarsal coalition. *Am. J. Roentgenol.* 182(2):323–328, 2004.
- Evans D. Relapsed clubfoot. *J. Bone Joint Surg.* 43-B:722–733, 1961.
- Ezra E, Hayek S, Gilai AN, Khermosh O, Wientroub S. Tibialis anterior tendon transfer for residual dynamic

- supination deformity in treated club feet. *J. Pediatr. Orthop.* 9(3)-B:207–211, 2000.
- Giannini S, Ceccarelli F, Vannini F, Baldi E. Operative treatment of flatfoot with talocalcaneal coalition. *Clin. Orthop.* 411:178–187, 2003.
- Grogan DP, Gasser SI, Ogden JA. The painful accessory navicular: a clinical and histopathological study. *Foot Ankle* 10(3):164–169, 1989.
- Kite JH. *The Clubfoot*. New York, NY: Grune & Stratton; 1964.
- Leonard MA. The inheritance of tarsal coalition and its relationship to spastic flat foot. *J. Bone Joint Surg.* 56(3)-B:520–526, 1974.
- Lichtblau S. A medial and lateral release operation for clubfoot: a preliminary report. *J. Bone Joint Surg.* 55(7)-A:1377–1384, 1973.
- M^cKay DW. New concept of and approach to clubfoot treatment. Section II. Correction of the clubfoot. *J. Pediatr. Orthop.* 3(1):10–21, 1983.
- Ponseti IV. Congenital club foot: the results of treatment. *J. Bone Joint Surg.* 45(2)-A:261–344, 1963.
- Raikin S, Cooperman DR, Thompson GH. Interposition of the split flexor hallucis longus tendon after resection of a coalition of the middle facet of the talocalcaneal joint. *J. Bone Joint Surg.* 81(1)-A:11–19, 1999.
- Swiontkowski MF, Scranton PE, Hansen S. Tarsal coalitions: long-term results of surgical treatment. *J. Pediatr. Orthop.* 3(3):287–292, 1983.
- Turco VJ. Surgical correction of the resistant clubfoot: one stage posteromedial release with internal fixation. *J. Bone Joint Surg.* 53(3)-A:477–497, 1971.
- Wilde PH, Torode IP, Dickens DR, Cole WG. Resection for symptomatic talocalcaneal coalition. *J. Bone Joint Surg.* 76(5)-B:797–801, 1994.
- Zadek J, Gold AM. The accessory tarsal scaphoid. *J. Bone Joint Surg.* 30(4)-A:957–968, 1948.

MIDFOOT

- Dwyer FC. Osteotomy of the calcaneus for pes cavus. *J. Bone Joint Surg.* 41-B:80–86, 1959.
- Echarri JJ, Forriol F. The development in footprint morphology in 1851 Congolese children from urban and rural areas, and the relationship between this and wearing shoes. *J. Pediatr. Orthop.* 12(2)-B:141–146, 2003.
- Harris RI, Beath T. Etiology of peroneal spastic flat foot. *J. Bone Joint Surg.* 30(4)-B:624–634, 1948.
- Harris RI, Beath T. Hypermobile flat-foot with short tendo achillis. *J. Bone Joint Surg.* 30(1)-A:116–140, 1948.
- Hibbs RA. An operation for "clawfoot". *JAMA* 73:1583–1585, 1919.
- Jahss MH. Tarsometatarsal truncated-wedge arthrodesis for pes cavus and equinovarus deformity of the fore part of the foot. *J. Bone Joint Surg.* 62(5)-A:713–722, 1980.
- Japas LM. Surgical treatment of pes cavus by V-osteotomy: preliminary report. *J. Bone Joint Surg.* 50(5)-A:927–944, 1968.
- Lamy L, Weissman L. Congenital convex pes planus. *J. Bone Joint Surg.* 21(1):79–91, 1939.
- Mazzocca AD, Thomson JD, Deluca PA, Romness MJ. Comparison of the posterior approach versus the dorsal approach in the treatment of congenital vertical talus. *J. Pediatr. Orthop.* 21(2):212–217, 2001.
- Méary R. Symposium sur le pied creux essentiel. *Rev. Chir. Orthop.* 53:390–466, 1967.
- Mosca VS. Calcaneal lengthening for valgus deformity of the hindfoot. Results in children who had severe,

- symptomatic flatfoot and skewfoot. *J. Bone Joint Surg.* 77(4)-A:500–512, 1995.
- Peterson HA. Skewfoot (forefoot adduction with heel valgus). *J. Pediatr. Orthop.* 6(1):24–30, 1986.
- Ragab AA, Stewart SL, Cooperman DR. Implications of subtalar joint anatomic variation in calcaneal lengthening osteotomy. *J. Pediatr. Orthop.* 23(1):79–83, 2003.
- Staheli LT, Chew DE, Corbett M. The longitudinal arch: A survey of eight hundred and eighty-two feet in normal children and adults. *J. Bone Joint Surg.* 69(3)-A:426–428, 1987.
- Steindler A. Stripping of the os calcis. *J. Orthop. Surg.* 2(1):8–12, 1920.
- van der Wilde R, Staheli LT, Chew DE, Malagon V. Measurements on radiographs of the foot in normal infants and children. *J. Bone Joint Surg.* 70(3)-A:407–415, 1988.
- Ward CM, Dolan LA, Bennett DL, Morcuende JA, Cooper RR. Long-term results of reconstruction for treatment of a flexible cavovarus foot in Charcot-Marie-Tooth disease. *J. Bone Joint Surg.* 90(12)-A:2631–2642, 2008.
- Wenger DR, Leach J. Corrective shoes and inserts as treatment for flexible flatfoot in infants and children. *J. Bone Joint Surg.* 71(6)-A:800–810, 1989.

ANKLE

- Alberktsson B, Rydholm A, Rydholm U. The tarsal tunnel syndrome in children. *J. Bone Joint Surg.* 64(2)-B:215–217, 1982.
- Grogan DP, Walling AK, Ogden JA. Anatomy of the os trigonum. *J. Pediatr. Orthop.* 10(5):618–622, 1990.
- Lamb D. The ball and socket ankle joint; a congenital abnormality. *J. Bone Joint Surg.* 40(2)-B:240–243, 1958.
- Silfverskiöld N. Reduction of the uncrossed two-joints muscles of the leg to one-joint muscles in spastic conditions. *Acta Chir. Scand.* 56:315–330, 1924.
- Strayer LM. Recession of the gastrocnemius; an operation to relieve spastic contracture of the calf muscles. *J. Bone Joint Surg.* 32(3)-A:671–676, 1950.

OSTEOCHONDROSIS

- Borges JL, Guille JT, Bowen JR. Köhler's bone disease of the tarsal navicular. *J. Pediatr. Orthop.* 15(5):596–598, 1995.
- Freiberg AH. Infraction of the second metatarsal bone. A typical injury. *Surg. Gynecol. Obstetr.* 19:191–193, 1914.
- Köhler A. Über eine häufige bisher anscheinend unbekanntere Erkrankung einzelner kindlicher Knochen. *München Med. Wochenschr.* 55:1923, 1908.
- Sever JW. Apophysitis of the os calcis. *NY State J. Med.* 95:1025–1029, 1912.
- Waugh W. The ossification and vascularization of the tarsal navicular and their relation to Köhler's disease. *J. Bone Joint Surg.* 40(4)-B:765–777, 1958.

TUMOR

- Landon GC, Johnson KA, Dahlin DC. Subungual exostosis. *J. Bone Joint Surg.* 61(2)-A:256–259, 1979.

INFECTIO

- Jacobs RF, M^cCarthy RE, Elser JM. Pseudomonas osteochondritis complicating puncture wounds of the foot in children: a 10-year evaluation. *J. Infect. Dis.* 160(4):657–661, 1989.
- Winograd AM. Modification in the technic of operation for ingrown toe-nail. *JAMA* 92:229–230, 1929.