

# TUMORS

Evaluation.....	199	Enchondroma.....	209
History.....	199	Chondromyxoid Fibroma.....	209
Physical Examination.....	200	Chondroblastoma.....	209
Imaging.....	200	Benign Bone Tumors.....	210
Laboratory Analysis.....	202	Osteoid Osteoma and Osteoblastoma.....	210
Staging.....	202	Eosinophilic Granuloma.....	211
Biopsy.....	203	Giant Cell Tumors.....	211
Differential Diagnosis.....	203	Other Benign Tumors.....	212
Bone Cyst.....	204	Hæmangioma.....	212
Unicameral Bone Cyst.....	204	Pigmented Villonodular Synovitis.....	212
Aneurysmal Bone Cyst.....	205	Malignant Soft Tissue Tumors.....	213
Benign Fibrous Tumors.....	206	Rhabdomyosarcoma.....	213
Nonosteogenic Fibroma.....	206	Synovial Sarcoma.....	213
Fibrous Dysplasia.....	206	Malignant Bone Tumors.....	214
Desmoid Tumor.....	207	Osteosarcoma.....	214
Focal Fibrocartilaginous Dysplasia.....	208	Ewing Sarcoma.....	214
Benign Cartilage Tumors.....	208	Leukæmia.....	215
Osteochondroma.....	208	Metastasis.....	215

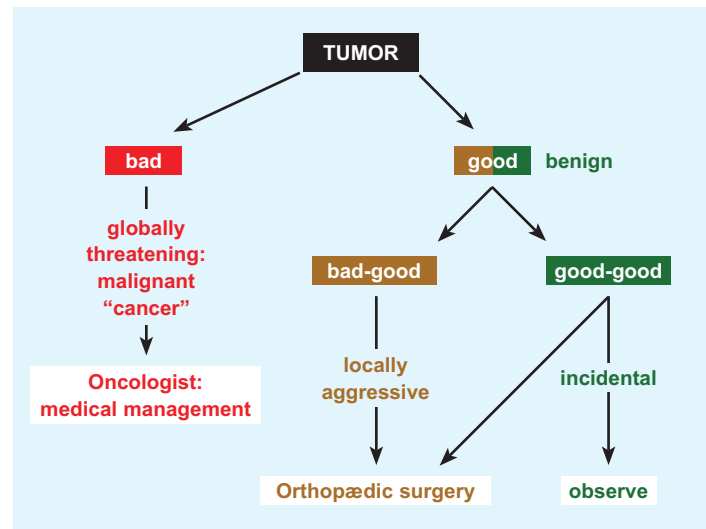
**M**alignant tumors of the musculoskeletal system constitute 10% of new cancers in children, numbering approximately 1,000 cases in the United States *per annum*. Benign tumors are 10 times the rate. We are presently on an exponential curve for advancement in oncology, for example, overall 5-year survival has risen from 10% to 20% in 1970 to better than 70% today. The most common pædiatric tumor is the benign fibrous cortical defect. The most common malignant tumor is osteosarcoma of bone and rhabdomyosarcoma of soft tissue; Ewing sarcoma traverses tissue types. This chapter focuses on common diagnoses.

## EVALUATION

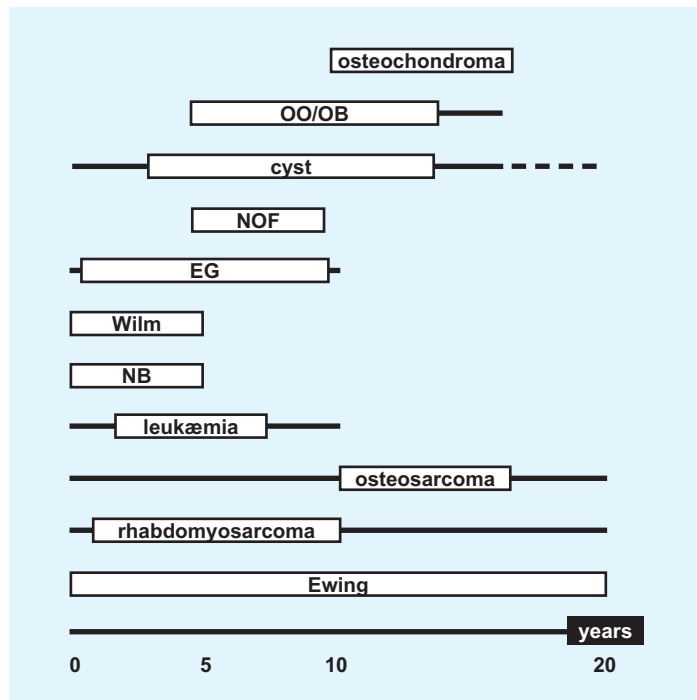
Because the word “tumor” may have sinister connotations, consider classifying tumors in simple terms for patients [A]. Most tumors are not life threatening. They may threaten local tissues, for example, risk of morbid fracture, and thus require surgical management. They may be stable, amenable to conservative measures, or incidental findings, which are left alone.

### History

Duration may be difficult to determine. The tumor requires time to grow sufficiently to disturb function or to be physically apparent or visible. Hence the poorer prognosis for axial tumors compared with appendicular lesions. Age is the universal discriminator of disease, for example, 2/3 of rhabdomyosarcomas occur in the first decade, while osteosarcoma peaks at puberty [B]. Refine the presentation of pain [C]. Abrupt pain may indicate morbid fracture. Beware of being distracted by a sporting or other benign injury. Not all malignant or aggressive tumors elicit pain: rhabdomyosarcoma typically does not hurt. Race may be helpful, for example, Ewing sarcoma is less common in blacks than whites.



**A Classification of tumors** This simple approach provides clarity and perspective for patients.



**B Age distribution of some tumors** NB, neuroblastoma; EG, eosinophilic granuloma; NOF, nonossifying fibroma; OO, osteoid osteoma; OB, osteoblastoma.

PAIN	
Low	High
Type	
Mechanical	Constant
Nocturnal	
Delays sleep	Awakens from sleep
Functional	
Symptom	Sign: stops sports, limp
Timing	
Gradual	Abrupt onset: fracture?

**C Pain** Characteristics of pain may be of low or high concern.

**Physical Examination**

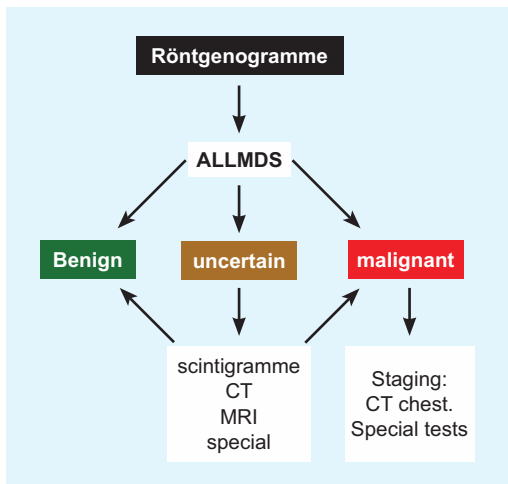
Take the temperature. Ewing sarcoma may be mistaken for osteomyelitis at first. Observe gait for alteration due to pain or other interference with function. Does the child look ill, as if overcome by pain or a generalized process? Are the complaints focal or diffuse? Are there “hard” objective signs? Are the soft tissues reactive, as evidenced by swelling, redness, induration, and adhesion? Is there articular stiffness to suggest guarding? Is there atrophy of disuse or other asymmetry? If a mass is detectable, is it tender? Is it soft, firm, or hard? How large is it? Greater than 5 cm is ominous for soft tissue sarcoma.

**Imaging**

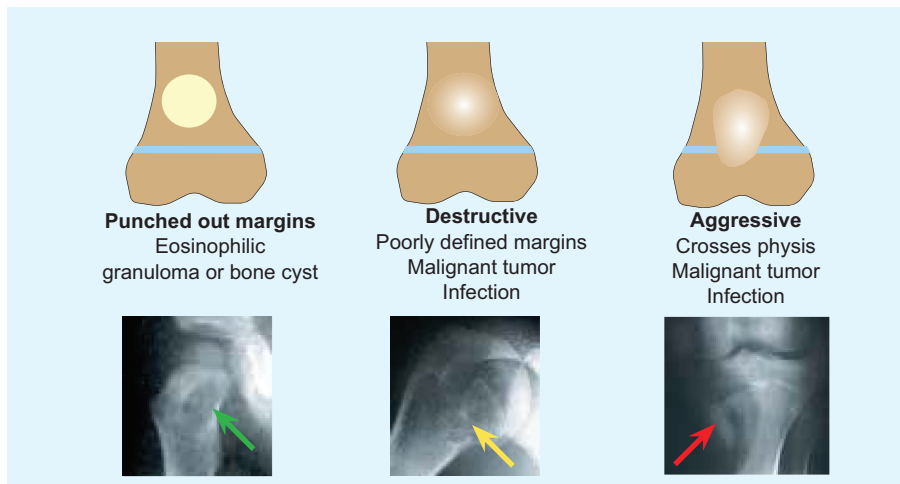
Develop a method that is clear, standard, efficient, and reproducible.

*Röntgenogrammes* The acronym ALLMDS facilitates communication [D]:

- A: Age.
- L: “Looks like.” This admits descriptives such as “sunburst,” “moth eaten,” scalloped,” and “expansile” [E].
- L: Location. Where within the bone, for example, metaphysis, diaphysis, or epiphysis [F], or what bone, for example, long bone such as the femur, irregular bone such as the spine, or flat bone such as the pelvis [G].
- M: Margins. These are divided into distinct, called “geographic,” or nondistinct, called “nongeographic.” The latter is more ominous, as it is a sign of rapid tumor growth and failure of bone to react and delimit this growth.
- D: Density. Lesions may be lytic, which are radiolucent; blastic, which are radiodense; or mixed, which are heterogeneous. This aids local assessment of bone but is not prognostic. Lytic lesions erode the integrity of bone and risk morbid fracture, influencing decision on internal fixation. On the other hand, while blastic lesions may be more stable, they may represent a high-grade osteosarcoma.
- S: Soft tissue. This may be reactive, such as elevation of periosteum, or a mass, for example, Ewing sarcoma.

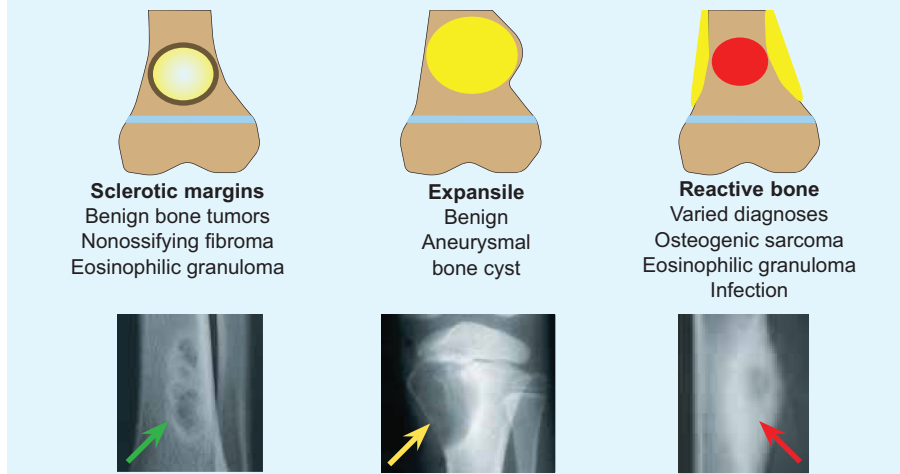


D Imaging for bone tumor Simple algorithm.



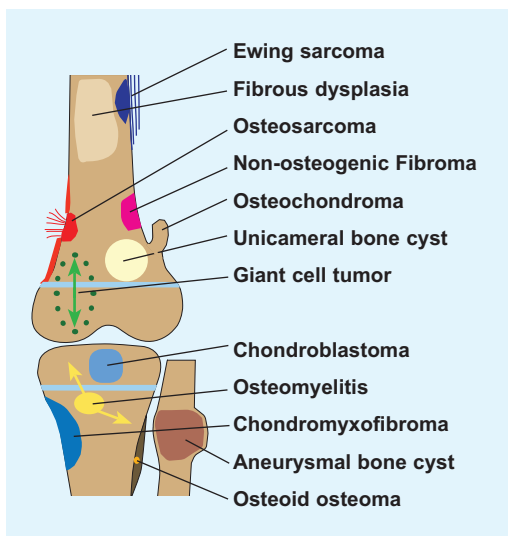
**Effect of lesion on bone**

Lytic eosinophilic granuloma (green), heterogeneous osteogenic sarcoma (yellow), and aggressive osteogenic sarcoma traversing the physis (red).

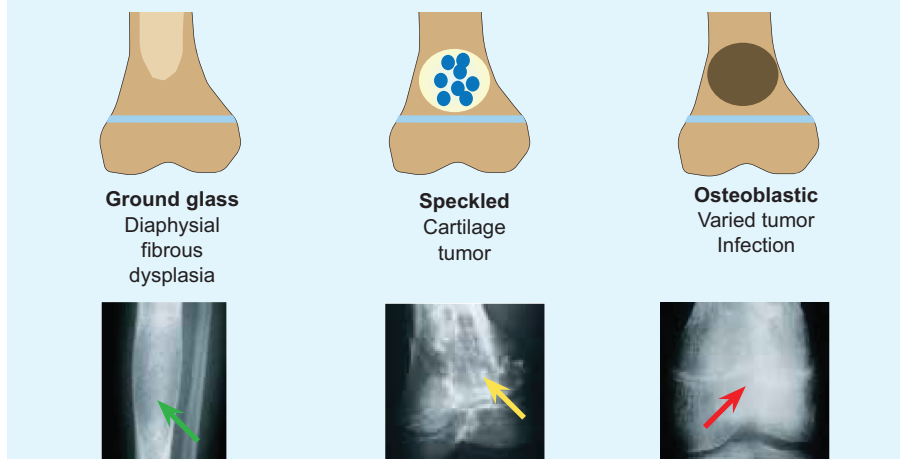


**Effect of lesion on normal adjacent tissue**

Scalloping in nonossifying fibroma (green), expanded cortex in aneurysmal bone cyst (yellow), and vigorous osseous reaction in osteoid osteoma (red).



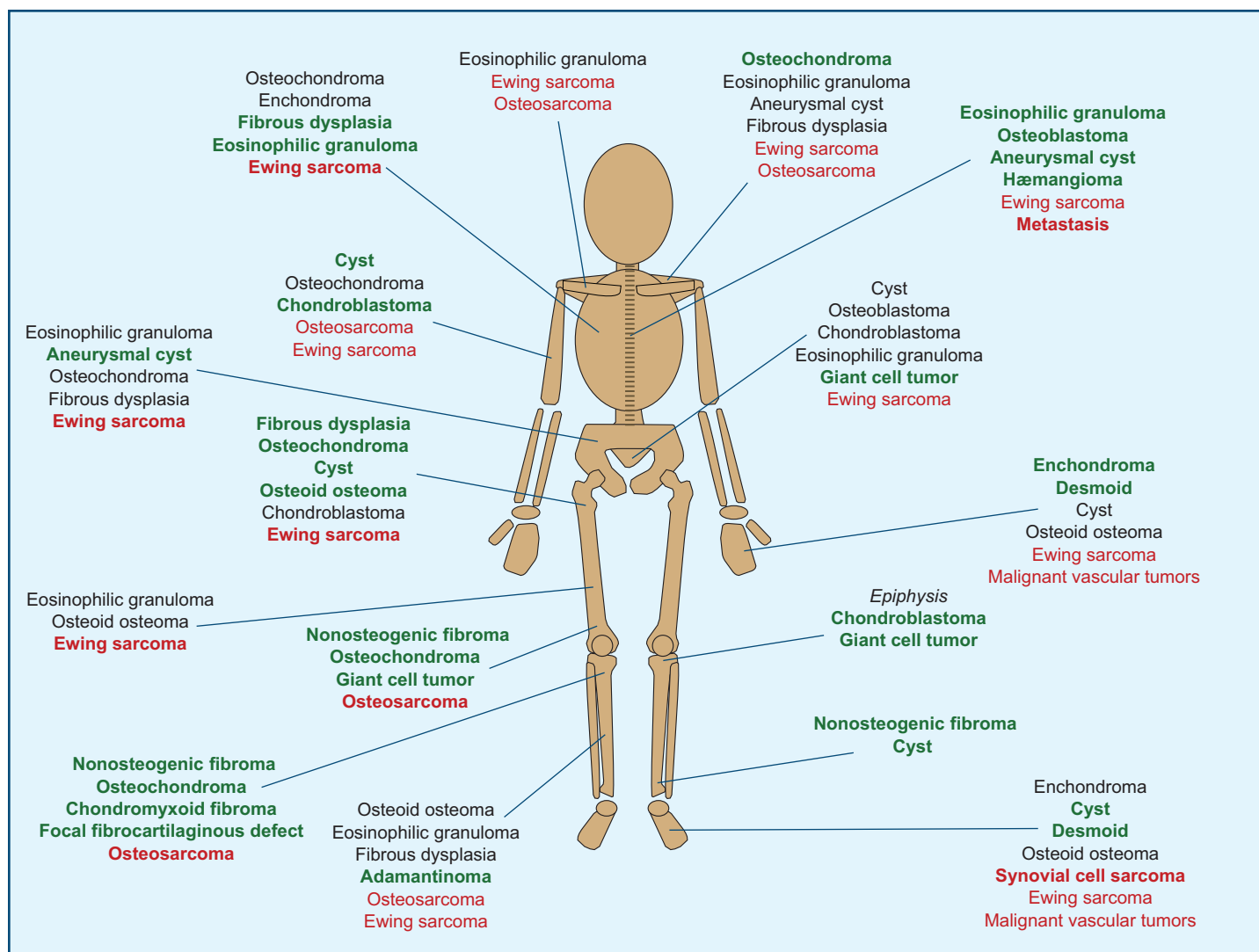
F Location of tumors within a long bone.



**Special diagnostic features.**

Ground glass appearance of fibrous dysplasia (green), speckled calcification in a cartilage tumor (yellow), and osteoblastic features of an osteogenic sarcoma (red).

E Some diagnostic features by röntgenogramme.



**G Tumor types by skeletal site** Common location of benign tumors in *green*. Malignant tumors in *red*, and common sites indicated in *bold*.

**Ultrasonography** This is indicated for a soft tissue mass when there is a low index of suspicion for malignancy. It may be used as a guide to aspiration or needle biopsy. It is simple to perform in an awake child without a special facility or medication.

**Scintigraphy** This is a measure of bone turnover and activity of a lesion. It may discern between a benign lesion that is incidental and not the explanation for regional pain and one that has a microfracture, thereby guiding treatment. It surveys the skeleton for other sites of disease. It has a high negative predictive value for malignant disease. Overlap between benign and malignant disease reduces the positive predictive value.

**CT** This is essential to staging as a survey of the chest and abdomen. Its fine bone detail aids operative decision making.

**MRI** Like CT, MRI is essential to staging. It is indicated for soft tissue tumors and bone tumors with a significant soft tissue component. It is supplanting CT for bone, for example, osteoid osteoma of a long bone. It has high sensitivity but specificity declines in differentiation of tumor from infection. The principal disadvantage is the requirement for sedation in the young child.

**PET** Detects gamma rays from the positron-emitting radioactive isotope fluorine-18 substituted for a hydroxyl group on glucose (fluorodeoxyglucose). The glucose analogue is taken up by actively dividing cells, where it is trapped but not metabolized, resulting in concentration of radioactive signal in tissue with high glucose uptake. This modality may

enhance CT and surveys for metastases and is useful to follow response to treatment.

#### Laboratory Analysis

A peripheral blood smear is useful in leukæmia. White blood cell count may be difficult to interpret, for example, it may be reduced due to chronic disease. Inflammatory markers may be increased in tumor, for example, Ewing sarcoma, or in infection. Elevation of alkaline phosphatase may be sensitive though nonspecific, for example, in the active phase of fibrous dysplasia. It may serve as a marker of response to medical treatment, such as with bisphosphonates. Blood cultures distinguish infection. Special tests may be indicated, such as urinary catecholamines and metabolites, which are elevated in neuroblastoma.

#### Staging

There are three stages of benign tumor.

- **Latent.** These may be asymptomatic and incidentally found. They show little or no growth and do not disturb or escape the compartment.
- **Active.** There is growth of tumor, as well as destruction, remodeling, and possible fracture of bone, limited to the confines of the compartment.
- **Aggressive.** Tumor grows rapidly; destroys, distorts, and fractures bone; and escapes the compartment into surrounding soft tissue, including rare metastasis (e.g., giant cell tumor).

Staging of malignant tumors is complex and disease specific. It is essential to management and prognosis of malignant tumors. Several factors contribute to stage [H]. Surgical staging (Enneking) emphasizes pathologic grade and the compartmental nature of a lesion: fascia, joint, and bone define a compartment [I]. Broadly, stage 0 may be considered precancerous. For stage I, surgical treatment is sufficient. Surgery for stage IV is prophylactic or palliative, for example, for impending or actual morbid fracture. Stages II and III combine medical and surgical management.

**Biopsy**

This may be percutaneous or open. Percutaneous may be of bone marrow from the iliac crest, for example, in leukæmia or Ewing sarcoma, or with image guidance when open access is morbid, for example, in the spine, or when there remains uncertainty about the diagnosis of tumor. Plan a large and wide enough specimen from multiple locations to be definitive. Biopsy may be incisional for diagnosis, excisional when geographic and localized, or compartmental when margins are indistinct but there is no regional or distant spread [J]. The principles of open biopsy are well established, founded on the spirit that this must be undertaken with the same level of preparation as the definitive procedure.

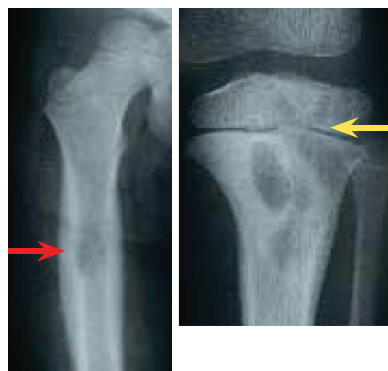
- Plan for future reconstruction when selecting incision, which should be as small as possible and extensile.
- Perform a transmuscular approach to limit contamination within that compartment.
- Avoid major neurovascular structures. Unlike muscle, these are not expendable in the event of future resection.
- Include the margin of a lesion, where growth and atypia tend to be greatest.
- Strict hæmostasis reduces contamination.
- Intraoperative frozen section confirms that enough tissue has been obtained to establish diagnosis or that a lesion is benign before proceeding with definitive care.
- Consider referral before biopsy if the surgeon, pathologist, and institution are not equipped to manage the case regardless of diagnosis.

**Differential Diagnosis**

The adage “culture tumor, biopsy infection” was conceived in the diagnostic dilemma each can pose the other. Consider fever, systemic signs, age, location, and elevation of inflammatory markers. Presence or absence of a mass and appearance on imaging sharpen the diagnosis [K]. Biopsy may be necessary for certainty.

Distinguish osteosarcoma from myositis ossificans by zone reversal. The latter is characterized by central proliferating cells surrounded by a margin of ossification. In osteosarcoma, the rapidly growing periphery has not yet ossified.

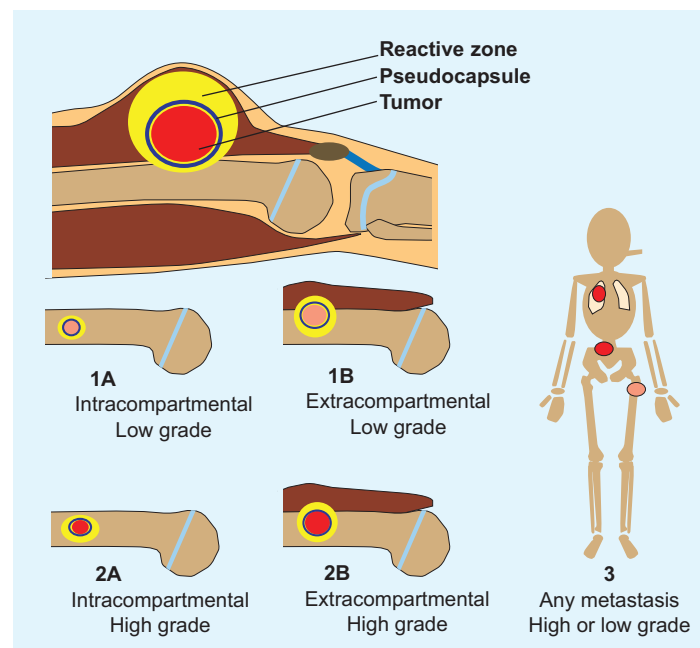
Differentiate fractures by history, for example, trauma or repetitive stress, and empirically by treating with rest and immobilization. Distinguish anxiety time from biologic time: 4 to 6 weeks will not alter tumor prognosis. Laboratory analysis is normal. Advanced imaging may be necessary, such as MRI showing no soft tissue extension or mass. Resist biopsy.



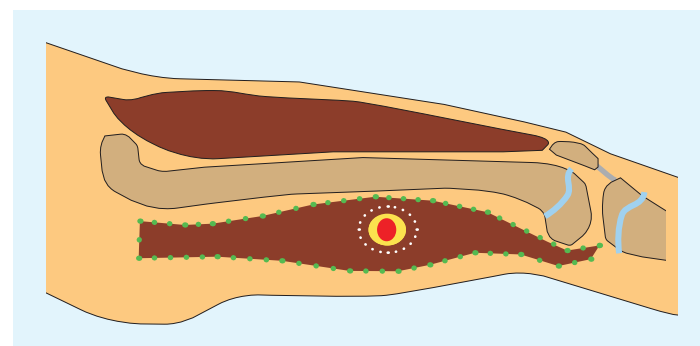
**K Infection, not tumor** Atypical features of infection include periosteal reaction and diaphyseal location (red) and extension from metaphysis transphysis to epiphysis (yellow).

Factor	Comment
Tumor	1: confined to site of origin 2: outside the site of origin
Nodal involvement	0: none 1: local 2: regional 3: distant
Metastasis	0: absent 1: present
Grade	1: low 4: high
Serum markers	Elevation
Resection	Measure of free or contaminated margins
Vascular	Invasion of vasculature
Lymphatic	Invasion of lymphatic system
Response	To chemotherapy, based upon % necrosis in surgical specimen
Imaging	e.g., MRI

**H Some factors considered for staging of tumors** These may vary according to disease type.



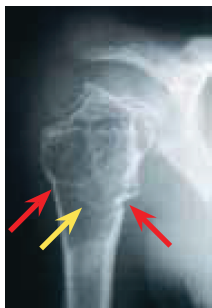
**I Staging of musculoskeletal tumors** Surgical staging is determined by grade and physical extent of lesion.



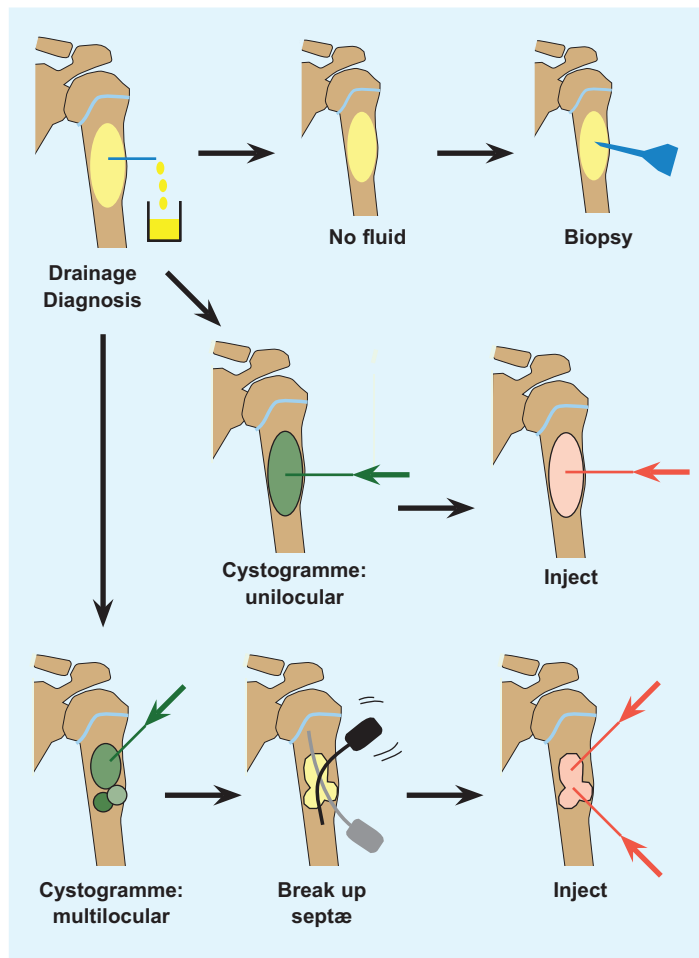
**J Biopsy of tumor** This may be incisional, within the tumor (red), excisional (white dots), or compartmental (green dots).

	1	2	3
<b>Pain</b>	Mild	Moderate	Functional
<b>Location</b>	Upper limb	Lower limb	Proximal femur
<b>Size</b>	< 1/3	1/3-2/3	> 2/3
<b>Density</b>	Blastic	Mixed	Lytic

**A Assessing risk for morbid fracture of hole in bone** 3 points are given for pain that is sufficiently severe to disturb function. A critical value is 9, which represents the beginning of the exponential part of the fracture curve (>1/3 will fracture). This system is a guide: it was developed for bone metastases in adults (Mirels).



**B Active unicameral bone cyst** There is a fracture fragment floating inside the cyst like a "fallen leaf" (yellow). The fracture takes up the entire width of the bone and has eroded the cortex to the point of fracture (red).



**C Aspiration and injection of a bone cyst** Injection may be of steroid, bone marrow aspirate, or other adjuvant.

## BONE CYST

### Unicameral Bone Cyst

The name implies a "single chamber" (Latin *camera* = Greek *καμρα*: "vaulted chamber") without loculation, although some have septæ. This most commonly occurs in the humerus and femur. Cause is unknown. The cysts are filled with yellow fluid and lined with a fibrous capsule.

**Evaluation** These may be incidental or may present with pain. They are metaphyseal and travel toward the diaphysis with growth. Incidental findings are assessed for fracture risk [A]. Pain indicates bending under load or fracture and may be severe enough to interfere with function. Lesions in the proximal femur are high risk because of concentration of the force of weight bearing and the grave anatomic consequences of fracture in this region.

**RÖNTGENOGRAMME** The lesion is central, nonexpansile, geographic with a sclerotic margin, and lytic. It may have septæ and an osseous fragment may float in its midst, known as "fallen leaf sign."

**Management** The natural history is spontaneous resolution of cysts by maturity in most cases. Latent cysts may be observed. Active cysts, which abut the physis, grow inexorably, and may fracture, tend to be treated surgically. Age, location, and fracture risk and consequences guide treatment.

**LOW RISK EXCEPT FEMUR** Observe. A humeral cyst that is small, asymptomatic, or acceptably painful may be managed conservatively, such as activity modification and nonnarcotic analgesics, and may resolve with maturity.

**LOW RISK PROXIMAL FEMUR** Observe or treat surgically because of concerns regarding load at, and fracture of, the hip.

**HIGH RISK** Observe if patient is very young and humerus is involved, or treat surgically. The proximal femur trumps age: consider fixation even in the very young.

**FRACTURE EXCEPT FEMUR** Treat by closed methods as long as alignment is acceptable. Healing of the fracture may partially heal cyst, potentially converting a cyst that is high risk by size into one that is low risk due to filling in with new bone.

**FRACTURE FEMUR** Treat surgically. Immobilization, for example, in hip spica cast, is associated with residual deformity, in particular coxa vara, due to intrinsic instability of the fracture and incomplete healing. For the proximal femur, improved alignment with surgical fixation may reduce complications of fracture such as malunion and osteonecrosis.

Surgical treatment may be divided into cases.

**PERCUTANEOUS WITHOUT FIXATION** This began as injection of steroid (Scaglietti), for its angiostatic and fibroblastic inhibitory effects. The method has evolved in multiple directions such that there is no consensus on best practice. It is preferred for the upper limb and lower risk lower limb lesions.

- The cyst is drained. If it is solid, reconsider diagnosis and perform an incisional biopsy.
- A cystogramme determines whether the cyst is uni- or multilocular. If the former, inject with steroid or other adjuvant. Bone marrow aspirate may bring mesenchymal stem cells that will promote bone ingrowth and healing. Calcitonin inhibits osteoclasts. Calcium sulfate cement is osteoconductive. Proprietary fibrosing agents have been promoted.
- If the latter, break up septæ to form a unilocular cyst. In the process, perforate the cyst to create channels of communication with the medulla, based upon the rationale that altered hæmodynamics with venous obstruction may be a causative factor, and to allow access to the cyst by bone stem cells.
- Repeat for recurrence.

**OPEN WITH FIXATION** This is indicated for high-risk lesions, such as proximal femur [D], or where open access is simple, for example, calcaneus.

- Create an ovoid window to avoid stress concentration at an angle. The cyst may dictate location of this at the eroded cortex.
- Débride the wall to remove all cells, manually or with power.
- Consider adjuvant intralesional therapy to kill residual cells, for example, liquid nitrogen (freezing), phenol (chemical), argon laser (coagulation), or hydrogen peroxide. For liquid nitrogen, leave in cavity until it evaporates; for other chemicals, let sit for 2 to 3 minutes. Cycle thrice. Reduce application hazard by controlling the agent within the osseous cavity in order to minimize injury to surrounding soft tissue. These augment but do not substitute for complete débridement.
- Pack the cyst with graft, allogeneous or autogeneous, or with a substitute. There are no robust data suggesting anything is better than bone, and allogeneous bone avoids the morbidity of harvesting bone, in particular because much may be needed to fully fill a large cyst.
- If the bone is stable, apply a cast. If internal fixation is indicated, for example, proximal femur, medullary implants will load share and thereby be more durable in the event of recurrence. In the immature child, elastic medullary nails may be inserted antegradely or retrogradely. They provide stability even in proximal lesions because they may be anchored in the unaffected and hard proximal epiphysis: no physal arrest will occur given their smooth surface and small fractional cross-sectional area [E].

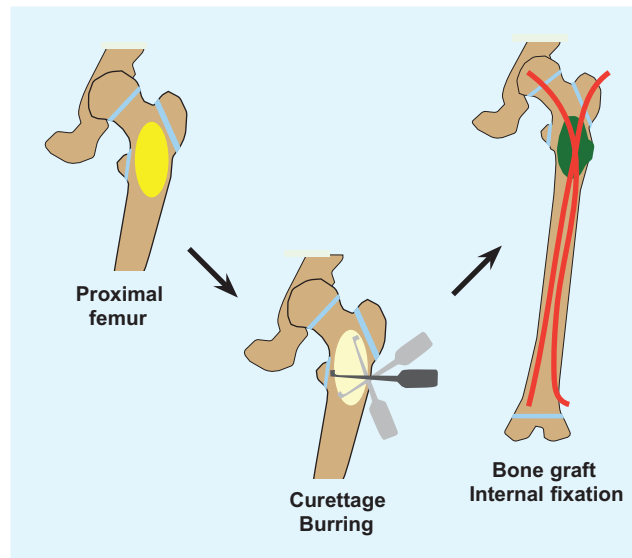
**Complications** While bone cyst is a benign or “good” tumor, it is a “bad–good” tumor because outcomes can be vexing.

- Recurrence. Some factors cannot be controlled, such as abutment against a physis. The principal factor that is controllable is débridement; hence the recommendation to use a burr, to be methodical, to proceed until healthy bleeding bone, and to leave only periosteum in places (so long as the bone is not unreasonably destabilized or resected).
- Growth disturbance. This may be iatrogenic or related to activity of cyst. The former may be minimized by avoiding physis during operation. The latter is a reflection of duration and aggressiveness of cyst.
- Malunion. This is most common in the proximal femur. Likelihood increases with closed management.

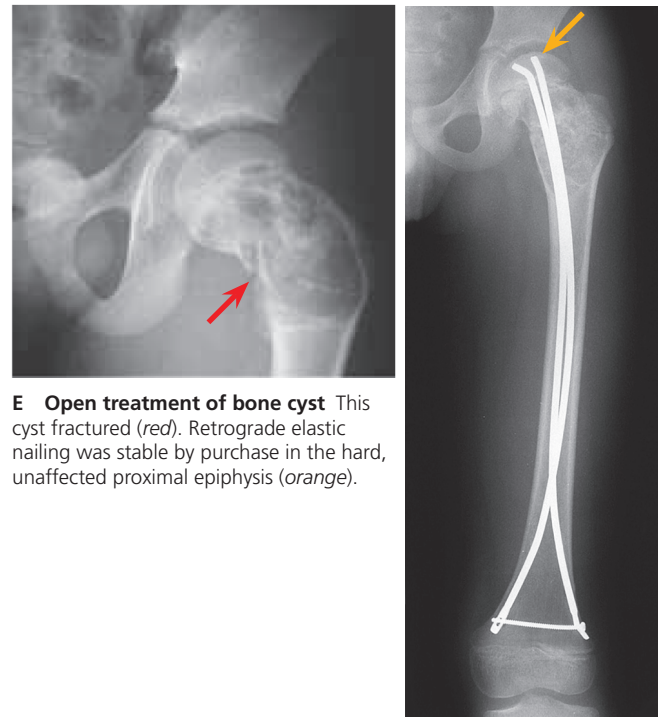
**Aneurysmal Bone Cyst**

As the name implies, this is vascular and expansile. Cause is unknown, although vascular malformation is most subject to speculation. Evaluation and management principles overlap with unicameral cyst, with key distinctions. Aneurysmal cyst is more aggressive:

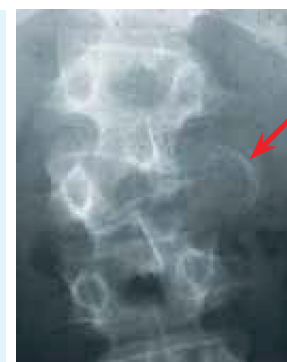
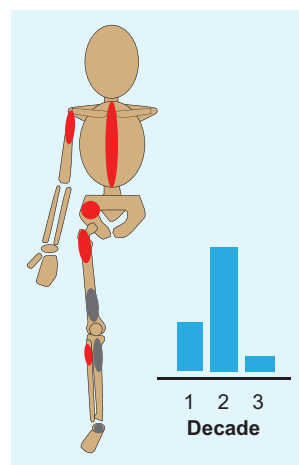
- Location. 1/4 arise in the axial skeleton, including posterior elements of the spine and the periacetabular region of the pelvis [F]. Consequences are greater morbidity of disease, for example, neural compromise, and of treatment, including more invasive dissection and more complex reconstruction.
- Recurrence. Correct surgical technique has reduced a formerly universal rate. Recurrence occurs within 2 years of operation, although children must be followed until maturity.
- Association with other tumors, including giant cell and osteosarcoma, in which it may represent the cystic component of a primary tumor.



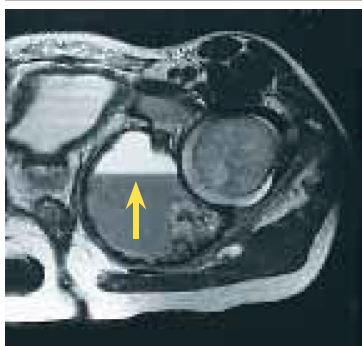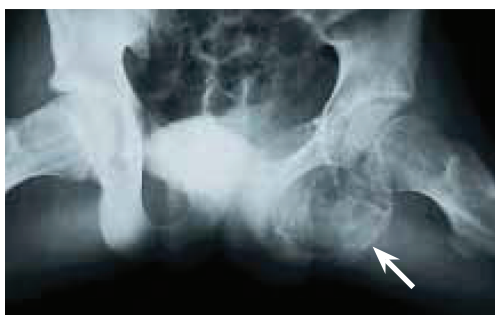**D Open treatment of bone cyst** The cyst is débrided and bone grafted (green), after which the femur is stabilized with elastic medullary nails (red).



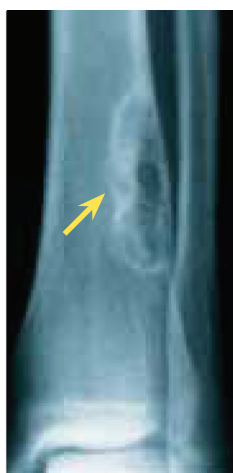
**E Open treatment of bone cyst** This cyst fractured (red). Retrograde elastic nailing was stable by purchase in the hard, unaffected proximal epiphysis (orange).



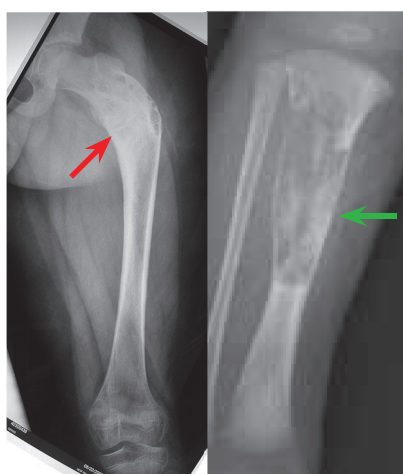

**F Distribution of aneurysmal cyst** The axial skeleton, including the spine (red) and the pelvis (white), makes advanced imaging and open treatment more typical.



**G Aneurysmal cyst of the pelvis** The expansile and otherwise aggressive appearance on röntgenogramme led to MRI, which shows a characteristic blood–fluid level (yellow).



**A Nonosteogenic fibroma** It peaks in adolescence and commonly affects the tibia. It is eccentric, loculated with a scalloped margin (yellow).



**B Fibrous dysplasia** The femur is distorted to resemble a “shepherd’s crook” (red). Note the thick periosteal healing response. Appearance may be so varied, including provoking concern (green), that further imaging often is necessary.

**Evaluation** On röntgenogramme, it is eccentrically expansile, lytic, and multiloculated, giving a “soap-bubble” appearance. The thin margin has been likened to an “eggshell.” The radiographic appearance may raise concern and prompt further imaging. Scintigramme may show a “halo” of increased uptake surrounding a central cold region. MRI will show blood–fluid levels [G] and define soft tissue extension.

**Management** This tends to be open and has the additional considerations:

- Preoperative angiography and selective embolization before surgical treatment of large lesions, in particular in the pelvis, will decrease haemorrhage and may shrink the lesion to decrease recurrence where complete resection is unrealistic.
- Entry into a cyst will return blood. Include soft tissue within, or the lining of, the cyst for biopsy, which will show proliferative fibroblasts, spindle cells, osteoid, and multinucleated giant cells.
- Break up all septae to define the entire cyst wall, which may be interrupted.
- Consider an *en bloc* resection with reconstruction where feasible to reduce recurrence.
- In the spine, excision may result in instability necessitating reconstruction, including bone grafting, fusion, and internal fixation.

## BENIGN FIBROUS TUMORS

### Nonosteogenic Fibroma

Originally reported as a cyst of bone (Pheemister), this was named separately as nonosteogenic (Jaffe) and nonossifying fibroma. The appellation fibrous cortical defect is reserved for small lesions confined to the cortex without medullary extension.

This is the most common benign lesion of bone in children, peaking in adolescence [A]. Cause is unknown, although it has been related to physis and traction by tendon or ligament, for example, at origin of the gastrocnemius from the distal femur.

**Evaluation** Most are incidental findings on röntgenogramme obtained for injury followed by pain.

**RÖNTGENOGRAMME** The lesion is metaphyseal, eccentric, geographic with a “scalloped” margin, and lytic with one or more loculations [A]. A large lesion may show a cortical breach.

**SCINTIGRAMME** This is indicated when there is uncertainty whether the lesion is a source of pain, suggesting structural failure, or when the lesion risks morbid fracture, such as in the proximal femur or >50% diameter of the bone. Fracture will demonstrate increased signal.

**Management** The natural history is spontaneous resolution by maturity. Observe incidental findings and follow clinically based upon symptoms. For fracture through a lesion, immobilize and observe for (partial) healing. If the fracture cannot be immobilized effectively, or for lesions with significant risk of morbid fracture, treat like a unicameral cyst (*q.v.*).

### Fibrous Dysplasia

Neoplastic fibrosis replaces and weakens bone, causing microfractures that hurt and lead to progressive deformity. It may arise in any bone, though the ribs and the proximal femur [B], as well as maxilla, are distinctive sites. Two types are distinguished: monostotic (80%) or polyostotic. The latter subtype is more severe and occurs in conjunction with café au lait spots and precocious puberty as part of McCune-Albright syndrome (*cf.* Syndromes chapter) and in conjunction with soft tissue myxomata in Mazabraud syndrome. Polyostotic fibrous dysplasia is caused by an activating gain of function mutation in the *GNAS1* gene located on chromosome 20q13.2. This results in abnormal synthesis of both organic and inorganic components of the extracellular matrix, thereby compromising the structural integrity of bone.

**Evaluation** Pain is the most common presentation. Other signs include deformity and limb length discrepancy.



**IMAGING** This tumor is one of the grand mimics. The classic appearance on röntgenogramme is the “shepherd’s crook” deformity of the femur, which is slowly eroded and deformed progressively by sub-clinical microfractures. At the other extreme is the simple geographic lucent lesion, surrounded by a “rind” of sclerotic bone and producing no deformity. Opacity, resembling “ground glass,” correlates with woven bone, with fibrous tissue being the principal tissue in lucent lesions.

The radiographic range is so broad that it often prompts further imaging. Scintigramme surveys the skeleton and may expose a fracture. CT is useful for complex lesions, in particular in the spine and craniofacial skeleton. MRI distinguishes this from malignancy and defines the extent of disease in bone and soft tissue.

#### Management

**MEDICAL** Bisphosphonates alleviate pain in polyostotic disease.

**SURGICAL** At biopsy, there is yellow-gray, gritty fibrous tissue with occasional cartilage foci forming a circumscribed mass that readily falls away from surrounding bone. Microscopically, a fibrous stroma is punctuated by “Chinese characters” or an “alphabet soup” of immature woven bone populated by some osteoblasts but many osteoclasts.

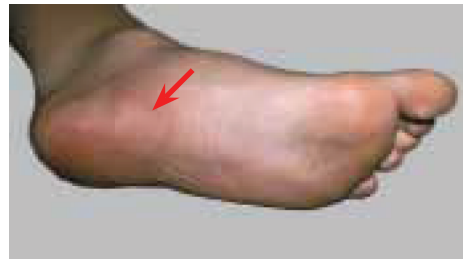Indications for operation follow general principles, including pain, which is evidence of bone instability from microfracture, deformity interfering with function, or clinical fracture. Educate parents that operation may be the first stage before definitive management at maturity, when lesions stabilize. Medullary fixation is preferable because lesions progress during childhood and because recurrence is high. Follow meticulous technique for the cavity remaining after removal of the mass (*cf.* Cyst). Allograft bone will be resorbed partially by the neoplastic process.

#### Desmoid Tumor

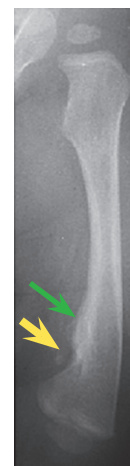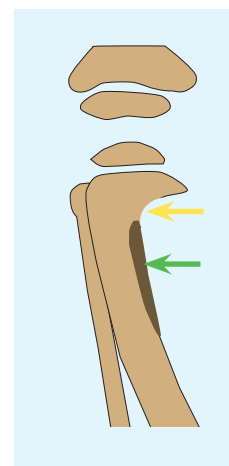
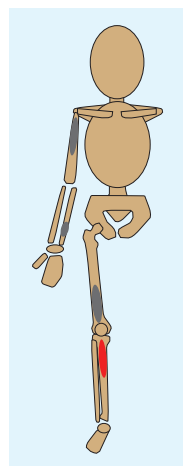
Greek δεσμός = Latin *fibra*, which describes a tumor of fibrous tissue. It also is known as fibromatosis, reflecting an infiltrative and locally aggressive nature. This is a broad spectrum that encompasses Dupuytren contracture of the hand and Ledderhose disease of the foot.

**Evaluation** Firm smooth mass anchored to deep fascia but sparing overlying skin. In the limbs, 1/4 of cases are bilateral. An extraintestinal abdominal form of the disease affects 10% of patients with familial adenomatous polyposis (Gardner syndrome): both disorders are caused by mutation in the adenomatous polyposis coli gene on 5q22.2. Desmoid tumor may represent an error in response to injury, including a surgical incision. MRI demonstrates the nongeographic nature of the tumor and aids determination of extent of soft tissue infiltration. Biopsy shows a dense collagen matrix populated by myofibroblasts expressing platelet-derived growth factor- $\beta$  proto-oncogene, which encodes the mitogenic  $\beta$ -chain of PDGF-B.

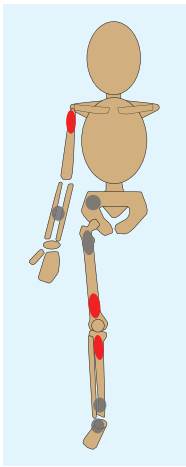
**Management** Because it is infiltrative and recurrence is high, nonoperative management is preferable. Because the injury of surgery may aggravate the tumor, plan to perform a wide excisional biopsy and confirm clear margins by intraoperative frozen section. Recurrence is high, and secondary operation is difficult in the setting of iatrogenic scarring. Collagenase, cryotherapy, and steroid injection may be helpful adjuncts. Radiation therapy for a benign condition raises concerns of physical arrest and tumorigenesis in a child.



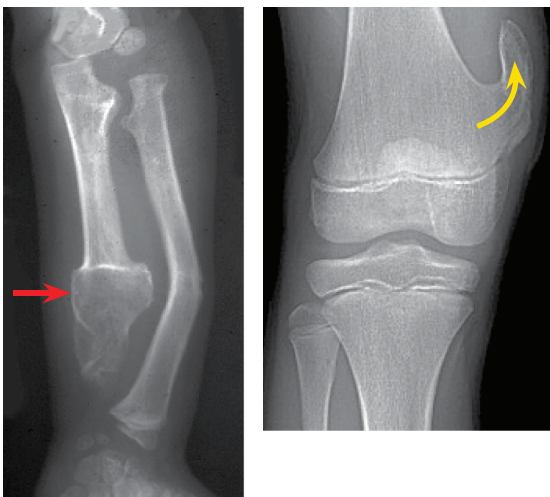
**C Plantar fibromatosis** Firm smooth mass associated with plantar aponeurosis.



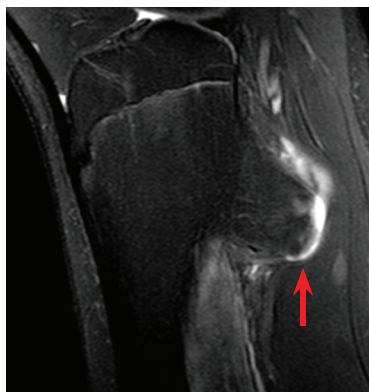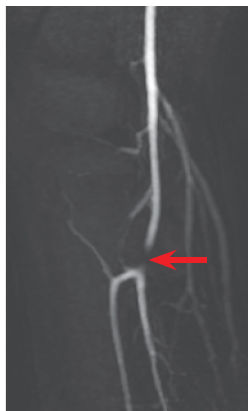
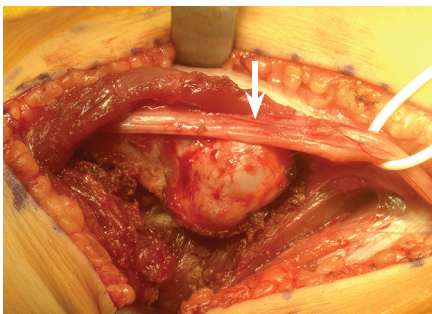
**D Focal fibrocartilagenous dysplasia** A lucent corticometaphyseal lesion (*yellow*) adjacent to the insertion of pes anserinus or hip adductors is interposed between proximal physis and a region of sclerotic reactive bone (*green*).



**A Distribution of solitary osteochondroma** The knee and proximal arm are most commonly affected. Multiple hereditary exostosis, which is more akin to a skeletal dysplasia, may affect the entire skeleton, except for relative sparing of the spine.



**B Röntgenogramme of osteochondroma** In multiple hereditary exostosis, the lesions deform affected bones and do not stand out alone (red). The presentation of solitary osteochondromata is classic, either sessile or pedunculated (yellow).



**C Complicated osteochondroma** Proximal fibula lesion may impinge upon the common fibular nerve, held by a silastic loop (white). A lesion arising from the posterior proximal tibia may obstruct the popliteal artery, before it bifurcates (red).

### Focal Fibrocartilagenous Dysplasia

The name (Bell) reflects the tissue of which the tumor is composed. Cause is unknown. Trauma, including abnormal periosteal traction, for example, by pes anserinus at the proximal tibia or hip adductors at the distal femur, has been proposed.

**Evaluation** Onset is infancy in the lower limb and later in childhood for upper limb lesions. The most affected is the tibia [D]. It may be mistaken for pseudarthrosis of the tibia, which is bowed with a region of lucency, representing the lesion, adjacent to sclerosis produced by the osseous reaction [D].

**Management** Spontaneous resolution is possible, representing perhaps rupture of the periosteal tether. The rarity of the condition makes nonoperative guidelines, for example, bracing, impossible. Tibial lesions correct most predictably, in particular if deformity is <25 degrees. Persistent significant deformity, for example, genu varum, is treated with osteotomy and lengthening as indicated.

In the forearm, deformity and growth retardation may have deleterious effects on the uninvolved bone, such as ulnar tethering of the radius with radiocapitular instability. Early excision may allow restoration of growth and mitigate dysfunction.

## BENIGN CARTILAGE TUMORS

### Osteochondroma

The name describes a stem of “bone” capped by “cartilage.” This also is known as exostosis, after the appearance of bone growing “away” from the main body. It is distinguished as such under the nail (*cf.* Foot chapter). It may arise from any bone [A]. Like fibrous dysplasia, osteochondroma may be solitary or multiple. The latter is a skeletal dysplasia having a genetic basis that is deforming [B] and associated with considerable morbidity, including malignant potential (*cf.* Syndromes chapter). Injury to the peripheral physis, followed by slow growth away with retention of physical cartilage as a cap, may explain the pathogenesis.

**Evaluation** Pain and a mass are typical of the presentation. Prominence may take the mass vulnerable to physical trauma. The mass may hurt or limit motion if it interferes with muscle movement. In a critical location, or if sufficiently large, an osteochondroma may produce neurovascular compromise [C].

**IMAGING** Röntgenogrammes usually suffice. Solitary osteochondroma may be sessile, characterized by a smooth rounded lesion with a wide “base,” or pedunculated, which is narrow and elongated like a “stalk” or finger [B]. It arises juxtaphysal out of the metaphysis, from which it is directed and grows away. Medullary and cortical continuity between the main bone and osteochondroma gives rise to the description “acalasis” (Greek κλαω: “to break, interrupt”). For complex lesions in complex locations, MRI will show the structure of the lesion and the surrounding structures impacted by it to aid operative planning. Integrated PET/CT aids in identifying conversion of osteochondroma to chondrosarcoma in the multiple form of the disease.

**Management** Observe osteochondromata unless they significantly disturb a patient: there is no rôle for prophylactic removal. The natural history is unpredictable growth during childhood and stabilization after maturity. Follow clinically for unacceptable symptoms or signs. Indications for operation are pain; significant prominence, for example, at the medial condyle of the tibia, which is exposed during sports and where there is thin soft tissue coverage; dysfunction such as of joint or muscle; and neurovascular compromise.

### Enchondroma

The name suggests a tumor of cartilage “inside” a long bone (medulla). However, it may occur in or on the cortex. It shows a predilection for the appendicular skeleton, where half occur in the hands and feet [D]. The tumor may be solitary or multiple (*cf.* Syndromes chapter), without (Ollier) or with h amangiomata (Maffucci). Pathogenesis is an ectopic remnant of physial cartilage. Macroscopically, lobules give the blue-gray hue of cartilage punctuated by yellow-white mineralized foci. Immunohistochemistry shows S100-positive chondrocytes.

**Evaluation** Solitary lesions typically are incidental findings. Pain may be a presenting sign of fracture. Lower limb length discrepancy may result, in particular for lesions about the knee.

**R NTGENOGRAMME** Lytic, lobulated lesion with scalloped margins and speckled mineralization is a manifestation of endochondral ossification that accompanies these tumors.

**Management** For intractable pain, d bride the cavity and bone graft. Add fixation as indicated. Lengthen a short limb, with deformity correction as indicated. Recurrence is rare (<5%).

### Chondromyxoid Fibroma

The tumor is composed of lobular myxoid and chondroid tissue with occasional multinucleated giant cells and foci of calcification. It has been linked to mutation on 6q, in the region that includes the gene encoding the  $\alpha$ -1 chain of collagen type XII.

**Evaluation** The majority (>80%) occur in long bones in the lower limb, most commonly about the knee. The tumor is associated with secondary aneurysmal bone cyst.

**R NTGENOGRAMME** The eccentric, geographic, lytic, ovoid metaphyseal lesion looks like a “bite” out of the cortex [E]. It may extend to, but never is solely in, the epiphysis.

**Management** Manage according to general principles for hole in bone. *En bloc* resection, feasible for an eccentric lesion, reduces recurrence (25%). Reports of malignant transformation probably represent misdiagnosis of chondrosarcoma.


### Chondroblastoma

This tumor is distinguished by the epiphysis or apophysis as the primary site [F]. It also is known as Codman tumor, after the original report of “chondromatous giant cell tumors” in the proximal humerus.

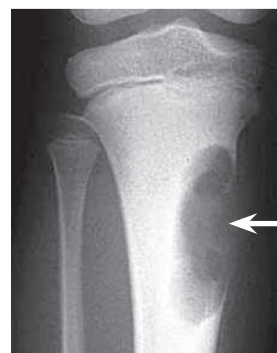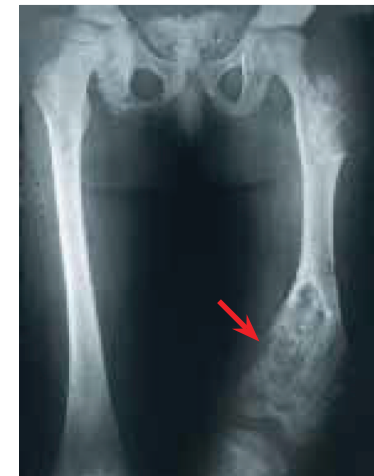**Evaluation** Pain may be associated with joint swelling for epiphysial lesions. Absence of systemic involvement excludes other disease. Microscopically, chondroblastoma resembles giant cell tumor of the tendon sheath and pigmented villonodular synovitis. Chondroblastoma is S100 and vimentin positive. Metastasis has been reported, calling into question the appellation “benign” or the initial diagnosis.

**R NTGENOGRAMME** The lesion is geographic, lytic, solely epiphysial, or apophysial, with erosion into metaphysis.

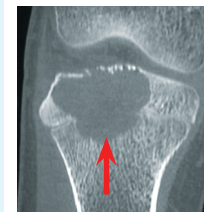
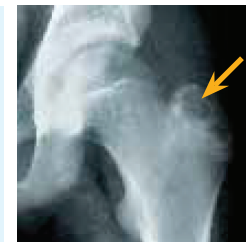**Management** Percutaneous radiofrequency ablation may be effective for small lesions and avoids articular dissection. Large lesions are at risk for articular collapse, which is an indication for open d bridement and bone grafting. For the epiphysis, intralesional adjuvant risks injury to the physis and articular surface, which additionally limits surgical access on either side of the tumor. Epiphysial lesions have poorer outcomes due to incomplete excision, which leads to a high recurrence rate (30%), as well as to physial and articular injury, which may be due to disease or iatrogenicity.



**D Enchondroma** The hands and feet are most affected. In the distal femur, growth disturbance may result in shortening and deformity (*red*).



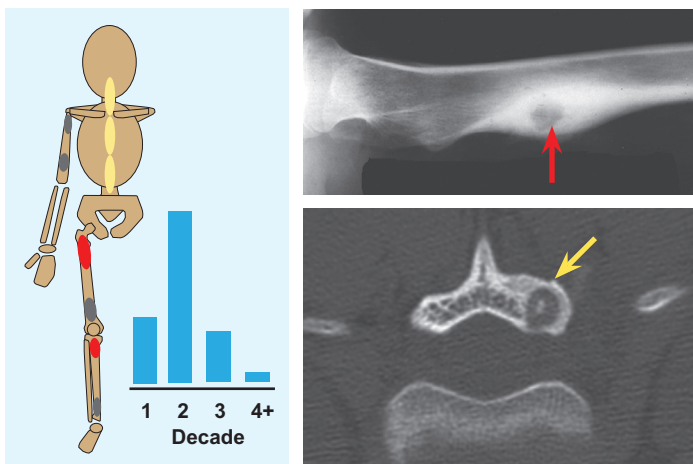
**E Chondromyxoid fibroma** A “bite” out of the cortex (*white*).



**F Chondroblastoma** The original report was in the proximal humerus. The lesion may be apophysial, for example, trochanter major (*orange*), in addition to being epiphysial (*red*). Epiphysial lesions undermine the articular surface and may erode through the physis into the metaphysis.

	Osteoid Osteoma	Osteoblastoma
<b>Size</b>	≤ 2 cm	
<b>Location</b>	90% long bone	1/3 spine: 1/3 cervical 1/3 thoracic 1/3 lumbar
<b>Symptoms</b>	Intense, night pain	Less pain Less responsive to NSAIA
<b>Sign</b>	Swelling	Deformity

**A Differences between osteoid osteoma and osteoblastoma** NSAIA: nonsteroidal anti-inflammatory agent.



**B Osteoid osteoma and osteoblastoma** Osteoid osteoma most frequently occurs in the femur (red). The posterior elements of the vertebrae are the exclusive domain of osteoblastoma (yellow).

Letterer-Siwe	Hand-Schüller-Christian	Eosinophilic granuloma
Multifocal multisystem	Multifocal unisystem	Unifocal
Infant	1st decade	Skeletal only
Diffuse disease	Triad:	Monostotic
Low survival	Exophthalmos Diabetes insipidus Osteolysis (skull)	Polyostotic

**C Forms of Langerhans cell histiocytosis.**

## BENIGN BONE TUMORS

### Osteoid Osteoma and Osteoblastoma

Osteoid osteoma is a benign, bone-producing, highly vascular tumor that induces an intense reaction and a characteristic pain pattern. Several features distinguish this from osteoblastoma [A].

**Evaluation** The clinical course of osteoid osteoma consists of an acute phase lasting 1 to 3 years followed by a recovery phase characterized by healing of the lesion with maturity. Pain is intense, focal, and worst at night. Pain results from secretion by the central nidus (Latin “nest”) of prostaglandins (in particular E<sub>2</sub> and I<sub>2</sub> or prostacyclin), inflammatory mediators that elicit a hypervascular response similar to that of injury. Pain is relieved by nonsteroidal anti-inflammatory agents, which block prostaglandin synthesis and are used as diagnostic and therapeutic tools. Osteoblastoma in the thoracolumbar spine presents with pain often associated with scoliosis (75%). In the cervical spine, it is one cause of torticollis.

**IMAGING** Röntgenogrammes show dense eccentric sclerosis without or with a radiolucent center. There may be surrounding osteopenia as a sign of disuse. Scintigramme shows focal increased uptake with 100% sensitivity, including early in cases when röntgenogrammes are negative, thereby accelerating diagnosis. CT reveals that the sclerosis forms an envelope surrounding a central nidus, likened to a “target.” In the spine, osteoblastoma affects the posterior elements, with sparing of the vertebral bodies. CT is essential to operative treatment, localizing lesions for complete resection and demonstrating extent of disease for planning of reconstruction. MRI tracks CT, but the inflammatory nature of the tumor reduces accuracy.

**DIFFERENTIAL DIAGNOSIS** Signs such as swelling in a subcutaneous bone, for example, tibia, as well as the nidus surrounded by a sclerotic rim, raise the specter of infection. The periosteal reaction may be mistaken for stress fracture. Increased uptake in posterior elements of the spine on scintigramme raises the question of spondylolysis. The two may be distinguished by the fact that osteoblastoma will show uptake in the immediate or flow phase (seconds) when increased signal in spondylolysis is delayed until the second or blood pool phase (minutes). A herniated intervertebral disc may be suspected in an adolescent with sudden-onset back pain and deformity. The length and breadth of the differential list account for a characteristic delay in diagnosis (1 to 3 years).

**Management** The natural history is resolution with maturity in most children.

**MEDICAL** Nonsteroidal anti-inflammatory agents help but rarely are sufficient due to the intensity and duration of pain.

**PERCUTANEOUS** The rationale is limitation of morbidity, including dissection and bone compromise, which ease convalescence and reduce complications such as fracture. CT guides localization. Options include radiofrequency or laser coagulative (50°C to 90°C) necrosis. Repeat cycles for lesions >1 cm. The principal disadvantage is lack of immediate confirmation of tumor removal. A hybrid approach is percutaneous cannulated drilling with CT guidance until complete resection. The disadvantages are drill control and fracture risk.

**OPEN EXCISION** This may be intralesional débridement, with identification of the nidus, without or with bone grafting, or *en bloc* excision for noncritical bone to reduce recurrence. The nidus appears deep red, reflecting a microscopic architecture of osteoid within a highly vascular stroma. Intraoperative CT with navigation aids localization and resection and confirms completeness. Add fixation as indicated for stability. Advantages of open treatment are direct visualization to ensure sufficient resection, no size limitation, and ability to stabilize a critical site. Recurrence correlates inversely with aggressiveness of resection.

Spontaneous resolution of spine deformity after excision is more likely in younger patients with short duration of disease (<1 year).

Overall recurrence or persistence of pain regardless of percutaneous or open method is 10%.

### Eosinophilic Granuloma

This is the most benign form of Langerhans cell histiocytosis [A], limited to the skeleton, most often as a solitary lesion. Langerhans cells are antigen-presenting immune cells, distinguished by Birbeck granules and populating skin and mucosa. Like fibrous dysplasia, eosinophilic granuloma imitates other disease. The two tumors also share a predilection for the craniofacial skeleton and ribs [B].

**Evaluation** Onset peaks in infancy. Pain may be associated with low-grade fever, which, together with elevated inflammatory markers and the radiographic appearance, makes differentiation from infection difficult. Skull lesions may resemble disorders of the central nervous system, such as arachnoid granulation (Pacchioni).

One-sixth of cases involve the spine, of which 1/2 have multilevel disease, 1/3 affect the cervical spine, and 1/6 will be deforming. Back pain is a universal finding. Deformity and soft tissue mass may encroach upon vertebral canal and intervertebral foramina to compromise the neural elements.

**RÖNTGENOGRAMME** Expansile, lytic lesions without or with periosteal reaction suggest aggressive destruction and simulate malignancy. Skull lesions may show “hole in hole” due to asymmetric erosion of the inner and outer tables. *Vertebra plana* (Calvé disease) describes “flattening” of the body, which collapses from a rectangle to a wedge or a line in anteroposterior and lateral projections. Image the entire spine.

**OTHER IMAGING** Scintigramme, which surveys the skeleton for polyostotic disease, may be cold in 1/3 of cases. CT provides best osseous detail, which is of particular importance for skull and spine lesions. MRI, enhanced with gadolinium, shows an associated soft tissue component.

**Management** While skull involvement and *vertebra plana* focus the differential, biopsy often is necessary for confidence in the diagnosis. Long bone lesions are treated according to principles of hole in bone (*cf.* Cyst). Operative indications for spine lesions are neural compromise and evidence of instability, including progressive deformity. Otherwise, support with a spinal orthotic primarily to control pain, with the secondary goal to protect alignment. The majority of cases (>90%) reconstitute without significant residual deformity. There is no consensus on chemotherapy. Do not irradiate children for this condition.

### Giant Cell Tumors

While it peaks around the age of 30, 10% occur in children. 50% occur in the knee; it also has a predilection for the sacrum [F]. Measures of the aggressiveness of this benign tumor include the following:

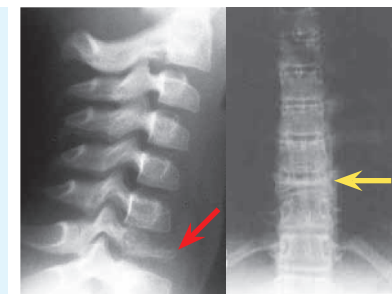
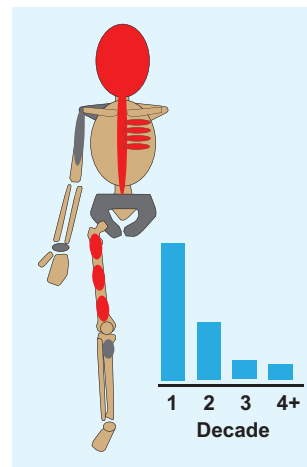
- It traverses the physis between metaphysis and epiphysis, eroding to the articular surface.
- 3% metastasize to the lungs.
- 25% fracture.
- 25% recur.

It is more often solitary than polyostotic, which behaves more aggressively. It is characterized by giant cells with multiple central nuclei as opposed to the peripheral nuclei of Langerhans cells.

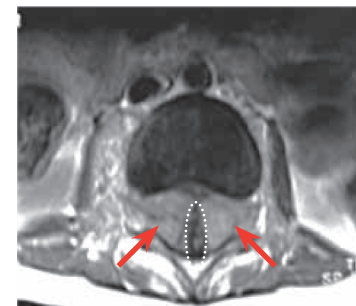
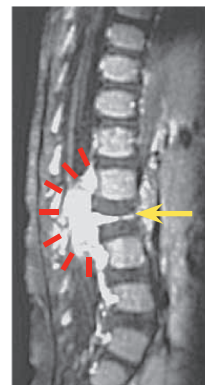
**Evaluation** Patients present with pain and swelling.

**RÖNTGENOGRAMME** Expansile and lytic lesion, erosive of bone yet eliciting little reaction, with soft tissue component. MRI aids determination of the extent of bone involvement and soft tissue extension.

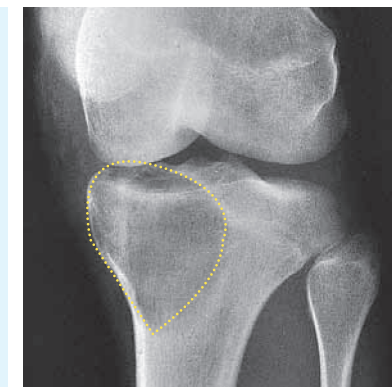
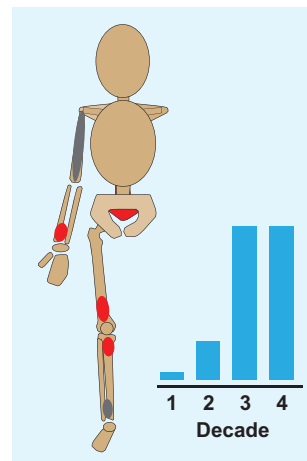
**Management** Treat according to principles of hole in bone (*cf.* Cyst). Complications relate to involvement of the physis and erosion of subchondral bone, which lead to growth disturbance and arthritis. As for aneurysmal cyst and other high recurrence benign tumors, *en bloc* resection is preferable; however, this may not be feasible given proximity to joint. Like chondroblastoma, intralesional adjuvant risks iatrogenic injury to the physis and articular surface.



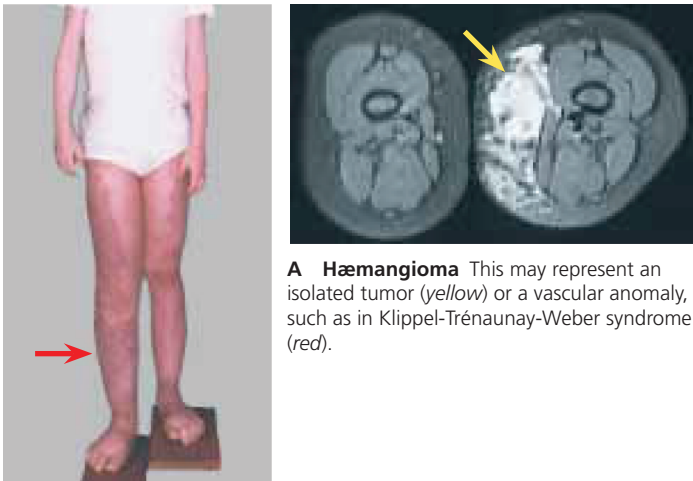
**D Eosinophilic granuloma** Vertebra plana may be seen on lateral projection in the cervical spine (red) and anteroposterior projection in the thoracic spine (yellow). Despite collapse, there is neither kyphosis nor scoliosis.



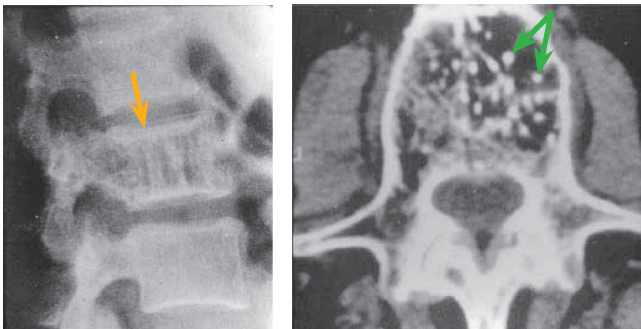
**E Eosinophilic granuloma of the spine** This lesion has eroded the vertebral body (yellow) and is associated with a large soft tissue mass (red), which occupies most of the spinal canal (red). The neural elements are outlined in white dots.



**F Giant cell tumor** It may extend between metaphysis and epiphysis, eroding the physis and subchondral bone (yellow).



**A Hæmangioma** This may represent an isolated tumor (*yellow*) or a vascular anomaly, such as in Klippel-Trénaunay-Weber syndrome (*red*).



**B Hæmangioma of bone** Radiodense longitudinal stripes reflecting osseous deposition along vascular channels give the appearance of a "jailhouse" or "corduroy" (*orange*) and appear as "polka dots" in transverse plane on CT (*green*). These findings contrast with thicker transverse striations parallel to end plates, as seen in the rachitic spine, which are likened to a "rugger jersey."

## OTHER BENIGN TUMORS

### Hæmangioma

Hæmangioma may be isolated, when it is regarded as a tumor, or part of a systemic condition, where it is an anomaly [A]. The tumors may be capillary, involving small vessels, or cavernous, involving large vessels. They may be distinguished according to tissue distribution.

**Muscular** Most tumors occur in the lower limb, the majority in the thigh. Unlike vascular anomaly syndromes, skin is unaffected. Presentation includes pain without or with swelling, which may increase with dependent position of the limb or with activity. Röntgenogrammes show soft tissue swelling. MRI with gadolinium enhancement shows serpentine infiltration of muscle in early disease.

The natural history is spontaneous involution. Indications for surgical removal are unacceptable pain or dysfunction. Preoperative embolization may reduce hæmorrhage. Recurrence is associated with lesions having less defined margins and those that are in critical locations, for example, forearm, where wide margins may impair function.

**Synovial** This may affect joint (mostly knee) or tendon sheath. Articular involvement is characterized by pain, hæmarthrosis, stiffness, and mechanical symptoms. Effusion should serve as an alert for further workup. Mechanical symptoms have been attributed to more innocent causes of internal derangement, thereby delaying diagnosis.

Treat arthroscopically for central lesions, or open for a peripheral lesion, where any capsule may be identified for a complete extralesional excision.

**Osseous** Two-thirds occur in the craniofacial skeleton and spine [B], where the tumor affects the anterior column. Hæmangioma is the most common benign tumor of the vertebrae (10% of autopsies). Tumor may involve a single bone, adjacent bones, or separate sites. Osseous hæmangioma also includes massive osteolytic hæmangiomatosis (Gorham), where increased blood supply is stimulatory of osteoclasts more than osteoblasts, tipping the normal state toward resorption.

Most are asymptomatic. Consider embolization for pain that is not alleviated by conservative methods. Vertebroplasty alleviates pain and stabilizes deformity. Spinal canal decompression and reconstruction are indicated for neural compromise.

### Pigmented Villonodular Synovitis

This disorder affects synovial joints, most frequently the knee, and tendon sheaths, most frequently in the hand, where it is known as giant cell tumor of the tendon sheath. Fusion transcripts of the gene encoding  $\alpha$ -1 chain of collagen type VI and colony-stimulating factor-1 have been found, although causation has not been established.

**Evaluation** Patients present with pain, swelling, and stiffness. There are two types: diffuse and focal. Röntgenogrammes show shadow of soft tissue swelling and may show saucerized erosions on both sides of the joint in advanced disease. MRI with gadolinium enhancement reveals hyperplastic and hypervascular synovial membrane, hæmosiderin deposition, and hæmorrhagic effusion. Histologic analysis shows synovial cell proliferation and multinucleated giant cells.

**Management** Definitive treatment consists of complete synovectomy, arthroscopically or open, and with radiation if necessary. The articular location and infiltrative nature of this tumor raises recurrence.

## MALIGNANT SOFT TISSUE TUMORS

These tumors account for about 7% of malignant tumors of childhood. They may be divided into five general categories [A].

### Rhabdomyosarcoma

This is a sarcoma of the skeletal muscle and constitutes more than half of malignant soft tissue tumors in children. It is the most common paediatric soft tissue sarcoma [B].

**Evaluation** Two-thirds occur in the first decade. Blacks and Asians are affected less commonly than Whites. Rhabdomyosarcoma may occur anywhere, and presentation varies accordingly [C]. One-quarter occur in the head and neck and 1/4 in the limbs. In a limb, it typically manifests as a firm, painless mass, without or with nodal involvement. Nodal extension is predictive of metastasis. By contrast with muscle, osseous lesions are painful. In the orbit, it produces proptosis. In the bladder or prostate, it produces urinary tract obstruction or haematuria, which may be gross or detected by urinalysis. In the chest, abdomen, or pelvis, it may grow large before manifestation.

There are 2 principal histologic types of rhabdomyosarcoma: embryonal (80%) and alveolar (20%), which have 2/3 the survival rate. Tumors arising in sites other than the limbs typically are embryonal, whereas limb tumors are alveolar, hence the poorer prognosis.

Embryonal rhabdomyosarcoma may be caused by somatic mutation in the SLC22A18 gene on chromosome 11p15.5, resulting in loss of heterozygosity of a tumor suppressor gene. Alveolar rhabdomyosarcoma results from fusion of the PAX3 gene on chromosome 2 with the FKHR gene on chromosome 13 as a result of a translocation t(2;13), or from fusion of the PAX7 gene on chromosome 1 with the FKHR gene as a result of a translocation t(1;13). Such translocations produce hybrid molecules that serve as potent transcription activators, deactivating myoblast proliferation. These mutations may be detected by fluorescent *in situ* hybridization (FISH) and reverse transcriptase–polymerase chain reaction (RT-PCR) testing of a biopsy specimen.

**Management** Survival for solitary lesions is >70%, which declines to the historical level <30% for metastatic disease. Operative treatment includes resection with a wide margin (>2 cm) and sampling of local lymph nodes.

### Synovial Sarcoma

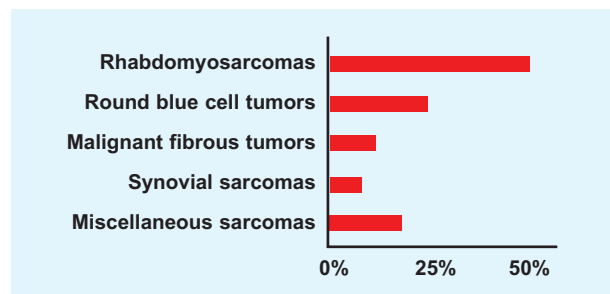
This occurs most frequently in the lower limbs, around the knee. It is the most common malignant soft tissue tumor of the foot. It is caused by the chromosomal translocation t(X;18)(p11;q11), leading to fusion of the SYT gene (18) with the SSX gene (X). The fusion proteins may function as aberrant transcriptional regulators to activate proto-oncogenes or inhibit tumor suppressor genes.

**Evaluation** Delay in diagnosis is characteristic, often >12 months. This is due to varied presentation, including latency, which gives the impression of benignity but which may be followed by rapid growth. The tumor is associated with deep fascia, manifesting as a deep, tender mass. Intralesional calcification (“snowstorm”) on röntgenogramme is pathognomonic though infrequent. MRI is the imaging modality of choice for diagnosis and surgical staging. Cytogenic analysis (FISH, RT-PCR) confirms diagnosis.

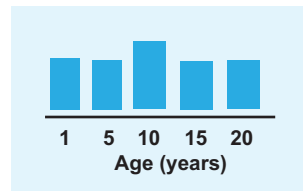
Several factors influence survival [C].

**Management** Adjuvant monoclonal antibody against a cell surface receptor (FZD10) unique to synovial cell sarcoma cells may improve outcomes, including need for amputation and survival.

Wide resection (2-cm margin) limits recurrence. Location in the knee may involve popliteal artery and tibial nerve, which may preclude limb salvage.



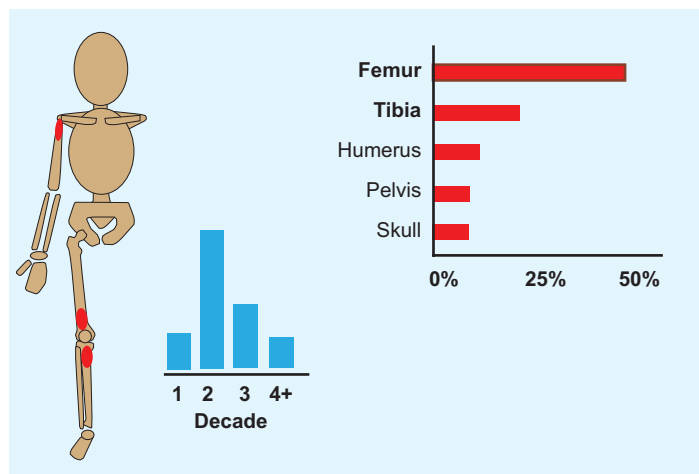
**A** Types of soft tissue sarcomas.



**B** Rhabdomyosarcoma age distribution 2/3 occur in the first decade.

Size	Histology	Location
< 5cm	Biphasic: synovial cells in glandular architecture	Distal limb
5-10 cm	Monophasic: spindle + round cells	Proximal limb
> 10 cm	Poorly differentiated	Central

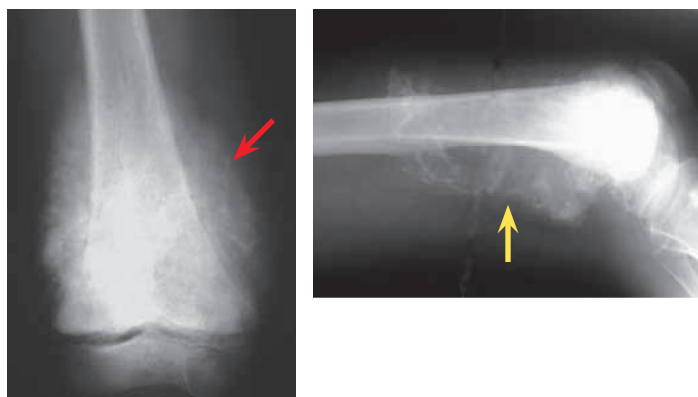
**C** Prognosis for synovial cell sarcoma For good prognostic factors (green), survival rate is >80%. This declines to <20% for poor prognostic factors. Distal limb signifies hand and foot. Central location is the trunk, head, and neck.



**A Geographic and age distributions of osteosarcoma** Growth influences distribution, both geographic (knee) and temporal (adolescence).

Factor	Prognosis
Grade	Low: favorable
Location	Distal limb (best) - proximal limb - axial skeleton (worst)
Metastasis	Absence better than presence
Response to neo-adjuvant chemotherapy	Increasing tumor cell kill improves prognosis
Resectability	Complete primary resection improves prognosis
Alkaline phosphatase Lactate dehydrogenase	Elevation unfavorable
Clinical subtype	Parosteal and peri-osteal favorable
Relapse	Poor prognosis

**B Prognostic factors.**



**C Radiographic appearance of osteosarcoma** Osteogenesis look like a "sunburst" (red) or resemble "cotton wool" (yellow).

Estimated lower limb length discrepancy >8 cm in immature child
Poor response to neo-adjuvant chemotherapy
Tumor contamination beyond compartment, e.g., after biopsy or due to hæmatoma after morbid fracture
Major infection
Unresectable lesion, e.g., due to extensive soft tissue involvement, such as penetration of neurovascular structures.

**D Contraindications to limb salvage.**

**MALIGNANT BONE TUMORS**

**Osteosarcoma**

Osteosarcoma is third in frequency to blood and brain cancers in childhood. It is the most common malignant tumor of bone. It is related to rapid growth, as evidenced by geographic distribution in the knee (more than half of cases) and the proximal humerus, as well as peak incidence during adolescence [A].

Loss of heterozygosity and tumor suppressor allelic inactivation at chromosome 3q13.31 have been found in osteosarcoma. A genetic predisposition is suggested by association of osteosarcoma with retinoblastoma (mutation in the RB1 gene on 13q14), Paget disease of bone (mutation in the TNFRSF11A gene on 18q22), Li-Fraumeni syndrome-1 (mutation in the TP53 gene on 17p13), Li-Fraumeni syndrome-2 (mutation in the CHEK2 gene on 22q12), and Rothmund-Thomson syndrome.

**Evaluation** Pain, limp, stiffness, inflammatory swelling, and focal mass are characteristic. Systemic presentation is uncharacteristic, except in metastasis. There is no gender or race predilection. Several factors are critical to prognosis [B].

**LABORATORY** Alkaline phosphatase elevation correlates with risk of metastasis. Elevation of lactate dehydrogenase bears a worse prognosis. Histologic analysis shows osteoid and cells that may be distinguished as osteoblastic, fibroblastic, chondroblastic, and telangiectatic, which contain loculi of blood. The tissue distinctions do not correlate with prognosis. Two clinical subtypes, parosteal, which is intracortical, and periosteal, which is low grade and encircles (Greek περί: "around") the bone, have a favorable prognosis.

**RÖNTGENOGRAMME** One-half of cases are blastic, including osteogenesis in a radiating "sunburst" or "cotton wool" pattern [C], 1/3 are lytic, and others are mixed. Repeated periosteal elevation and reaction results in lamellar bone deposition likened to "onion skin." The telangiectatic type may resemble aneurysmal bone cyst.

**SCINTIGRAMME** Survey the skeleton for metastasis, within both the same osseous compartment and extracompartmental.

**CT** CT of the chest is essential to staging. Of the site, it is essential to operative planning.

**MRI** This best visualizes medullary disease and soft tissue involvement.

**PET** This may detect disease missed by other modalities, predict response to chemotherapy, and aid in determination of response after treatment.

**Management** Neoadjuvant chemotherapy aids prognostication and improves surgical outcomes, including limb salvage, by shrinking the tumor. Osteosarcoma is radioresistant, leaving surgical as the only treatment for local control.

Operation for cure may include wide margins (> 5 cm); radical margins, defined as the entire osseous compartment from joint to joint; or amputation. Limb salvage is the first goal in a child, but is not always feasible [D]. For every patient, balance the functional benefits, including appearance, and the morbidity, physical and psychic, of limb salvage and reconstruction against early amputation and prosthetic fitting: there is no universal approach.

**Ewing Sarcoma**

Ewing sarcoma is part of a family of small, round, blue cell tumors that includes peripheral primitive neuroectodermal tumor and neuroepithelioma. The family shares the same reciprocal translocation of the EWS gene on chromosome 22q12 with various members of the ETS family of transcription factors on 11q24. The fusion protein is a target of current molecular treatment modalities (e.g., YK-4-279). Ewing sarcoma is the second most common malignant bone tumor of childhood. It may be osseous, medullary, or soft tissue.



**Evaluation** It peaks in the second decade [E]. In contrast with osteosarcoma, Ewing sarcoma occurs with equal frequency in flat bones, such as the pelvis, and long bones, where it may arise in the diaphysis. It also may arise in soft tissues. Whites are affected onefold more than blacks. Focal osseous symptoms and signs include pain, limp, stiffness, inflammatory swelling, and mass, while petechiae and other signs of blood dyscrasia are medullary manifestations and fever is systemic. Back pain may be spinal, retroperitoneal, or pelvic in origin. Most important determinants of prognosis are metastasis [F], followed by location (*cf.* Osteosarcoma).

**LABORATORY** Findings include abnormal blood cell count such as thrombocytopenia, and elevated inflammatory markers, including CRP and ESR. Histology shows characteristic small, round cells of which the glycogen-rich cytoplasm stains blue with hematoxylin and eosin. Immunohistochemical marker MIC2 antigen (CD99) stains the cell membrane. Cytogenetic studies of tissue specimen confirm the t(11;22) translocation.

**RÖNTGENOGRAMME** This is one of the diaphysial lesions. It is permeative (wide zone of transition between disease and normal), destructive of bone, and eliciting a periosteal reaction.

**MRI** This tumor is characterized by a soft tissue mass, which is best visualized by MRI. MRI also reveals medullary extent.

**PET** This is sensitive for metastasis, though scintigramme and whole-body MRI may substitute.

**Management** Principles resemble those for osteosarcoma. A difference is the use of radiation therapy to augment surgery for local control of disease. A cost is radiation-induced sarcoma, in particular leukæmia.

**Leukæmia**

This is the most common cancer of childhood. The most common subtype is acute lymphoblastic.

**Evaluation** This peaks early in the first decade. Patients with chromosomal anomalies (e.g., trisomy 21) are at increased risk for leukæmia. 20% of children with leukæmia present with bone pain, of which the characteristic is a migratory pattern, and 10% present with a limp. An orthopædic surgeon or rheumatologist may be the first medical consultant. Keys to the diagnosis include physical evidence of systemic disease, such as fever, malaise, lymphadenopathy, hepatosplenomegaly, and signs of myelophthisis, such as easy bruising and bleeding, infection, and pallor of mucous membranes.

**LABORATORY** Abnormal blood counts and peripheral smear, for example, leukocytosis (hence the name of the disease by Virchow), are diagnostic.

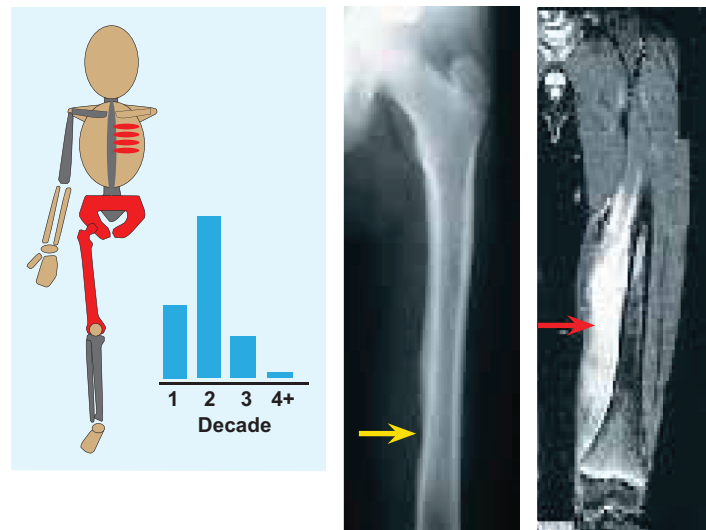
**RÖNTGENOGRAMME** “Leukæmic lines,” transverse radiolucent metaphyseal bands, are rare though pathognomonic. More common is periosteal new bone formation in a background of disuse osteopenia and, in severe cases, geographic osteolysis.

**Management** The essential component for the surgeon is recognition. Bone marrow aspiration establishes the diagnosis.

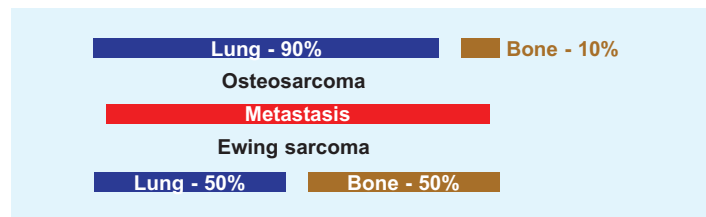
**Metastasis**

The spine is third in frequency after the lung and liver as a destination for metastasis [G]. Most patients are symptomatic and half have multiple level involvement, hence the importance of survey imaging such as scintigramme or PET. Greater than 90% of lesions are vertebral or epidural, with <10% intradural. Most metastasis represents vascular seeding, including *via* Batson plexus, a network of valveless veins that drain the body cavities to the vertebral veins.

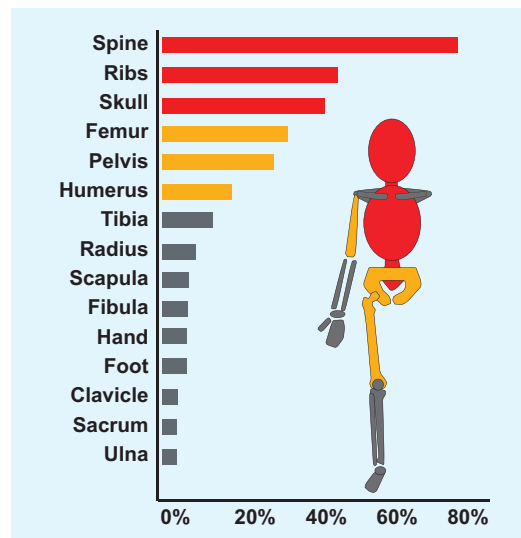
The tumor that most frequently metastasizes to bone is neuroblastoma [H]. This small, round, blue cell tumor has onset in infancy, is of sympathetic neural origin, may spontaneously regress to benign ganglioneuroma, and in more than half of cases presents with metastasis. 2/3 originate in the abdomen and pelvis; in the spine, 10% reach into the vertebral canal to encroach upon the neural elements.



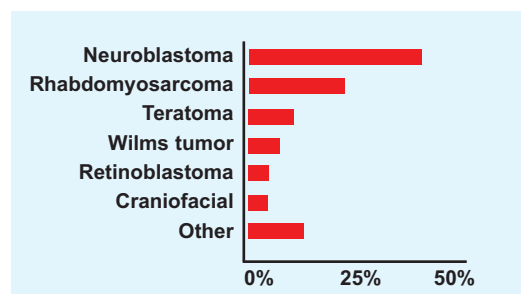
**E Ewing sarcoma** Half are axial and half are appendicular. Subtle radiographic change (yellow) despite a large soft tissue component (red).



**F Metastasis of osteosarcoma and Ewing sarcoma** Metastasis at diagnosis halves the 5-year relapse-free survival.



**G Distribution of skeletal metastasis.**



**H Tumors metastasizing to bone.**

**BENIGN BONE TUMORS**

- Bergstrand H. Über eine eigenartige, wahrscheinlich bisher nicht beschriebene osteoblastische Krankheit in den langen Knochen in der Hand und des Fusses. *Acta Radiol.* 11:596–613, 1930.
- Campanacci M, Ruggieri P, Gasbarrini A, Ferraro A, Campanacci L. Osteoid osteoma. Direct visual identification and intraliesional excision of the nidus with minimal removal of bone. *J. Bone Joint Surg. Br.* 81(5):814–820, 1999.
- Canavese F, Soo BC, Chia SK, Krajchich JI. Surgical outcome in patients treated for hemangioma during infancy, childhood, and adolescence: a retrospective review of 44 consecutive patients. *J. Pediatr. Orthop.* 28(3):381–386, 2008.
- Garg S, Mehta S, Dormans JP. Langerhans cell histiocytosis of the spine in children: long-term follow-up. *J. Bone Joint Surg. Am.* 86(8):1740–1750, 2004.
- Geschickter CF, Keasbey LE. Tumors of blood vessels. *Am. J. Cancer* 23:568–591, 1935.
- Green JA, Bellemore MC, Marsden FW. Embolization in the treatment of aneurysmal bone cysts. *J. Pediatr. Orthop.* 17(4):440–443, 1997.
- Jaffe HL, Lichtenstein L. Solitary unicameral bone cyst with emphasis on the roentgen picture, the pathologic appearance and the pathogenesis. *Arch. Surg.* 44:1004–1025, 1942.
- Kolodny A. Bone sarcoma: the primary malignant tumors of bone and the giant cell tumor. *Surg. Gynec. Obstet.* 44(1):214–241, 1927.
- Mammano S, Candiotti S, Balsano M. Cast and brace treatment of eosinophilic granuloma of the spine: long-term follow-up. *J. Pediatr. Orthop.* 17(6):821–827, 1997.
- Möller E, Mandahl N, Mertens F, Panagopoulos I. Molecular identification of COL6A3-CSF1 fusion transcripts in tenosynovial giant cell tumors. *Genes Chromosomes Cancer* 47(1):21–25, 2008.
- Ramirez AR, Stanton RP. Aneurysmal bone cyst in 29 children. *J. Pediatr. Orthop.* 22(4):533–539, 2002.
- Scaglietti O, Marchetti PG, Bartolozzi P. The effects of methylprednisolone acetate in the treatment of bone cysts. Results of three years follow-up. *J. Bone Joint Surg. Br.* 61(2):200–204, 1979.
- Stanton RP, Abdel-Mota'al MM. Growth arrest resulting from unicameral bone cyst. *J. Pediatr. Orthop.* 18(2):198–201, 1998.
- BENIGN FIBROUS TUMOR**
- Bell SN, Campbell PE, Cole WG, Menelaus MB. Tibia vara caused by focal fibrocartilaginous dysplasia: three case reports. *J. Bone Joint Surg. Br.* 67(5):780–784, 1985.
- Bianco P, Riminiucci M, Majolagbe A, Kuznetsov SA, Collins MT, Mankani MH, Corsi A, Bone HG, Wientroub S, Spiegel AM, Fisher LW, Robey PG. Mutations of the GNAS1 gene, stromal cell dysfunction, and osteomalacic changes in non-McCune-Albright fibrous dysplasia of bone. *J. Bone Miner. Res.* 15(1):120–128, 2000.
- Couture J, Mitri A, Lagace R, Smits R, Berk T, Bouchard H-L, Fodde R, Alman B, Bapat B. A germline mutation at the extreme 3-prime end of the APC gene results in a severe desmoid phenotype and is associated with overexpression of beta-catenin in the desmoid tumor. *Clin. Genet.* 57(3):205–212, 2000.
- Godette GA, O'Sullivan M, Menelaus MB. Plantar fibromatosis of the heel in children: a report of 14 cases. *J. Pediatr. Orthop.* 17(1):16–17, 1997.
- Guille JT, Kumar SJ, MacEwen GD. Fibrous dysplasia of the proximal part of the femur. Long-term results of

curettage and bone-grafting and mechanical realignment. *J. Bone Joint Surg. Am.* 80(5):648–652, 1998.

Jaffe H, Lichtenstein L. Non-osteogenic fibroma of the bone. *Am. J. Pathol.* 18:205–221, 1942.

**BENIGN CARTILAGE TUMORS**

- Chew DK, Menelaus MB, Richardson MD. Ollier's disease: varus angulation at the lower femur and its management. *J. Pediatr. Orthop.* 18(2):202–208, 1998.
- Codman EA. Epiphyseal chondromatous giant cell tumors of the upper end of the humerus. *Surg. Gynecol. Obstet.* 52:543, 1931.
- Dadfarnia T, Velagaleti GV, Carmichael KD, Eyzaguirre E, Eltorky MA, Qiu S. A t(1;9)(q10;q10) translocation with additional 6q23 and 9q22 rearrangements in a case of chondromyxoid fibroma. *Cancer Genet.* 204(12):666–670, 2011.
- Jaffe HL, Lichtenstein L. Chondromyxoid fibroma of bone: a distinctive benign tumor likely to be mistaken especially for chondrosarcoma. *Arch. Path.* 19:541–551, 1943.
- Konishi E, Nakashima Y, Iwasa Y, Nakao R, Yanagisawa A. Immunohistochemical analysis for Sox9 reveals the cartilaginous character of chondroblastoma and chondromyxoid fibroma of the bone. *Hum. Pathol.* 41(2):208–213, 2010.
- Purandare NC, Rangarajan V, Agarwal M, Sharma AR, Shah S, Arora A, Paradar DS. Integrated PET/CT in evaluating sarcomatous transformation in osteochondromas. *Clin. Nucl. Med.* 34(6):350–354, 2009.
- Yasuda T, Nishio J, Sumegi J, Kapels KM, Althof PA, Sawyer JR, Reith JD, Bridge JA. Aberrations of 6q13 mapped to the COL12A1 locus in chondromyxoid fibroma. *Mod. Pathol.* 22(11):1499–1506, 2009.

**MALIGNANT SOFT TISSUE TUMORS**

- Barr FG, Galili N, Holick J, Biegel JA, Rovera G, Emanuel BS. Rearrangement of the PAX3 paired box gene in the paediatric solid tumour alveolar rhabdomyosarcoma. *Nat. Genet.* 3(2):113–117, 1993.
- Deshmukh R, Mankin HJ, Singer S. Synovial sarcoma: the importance of size and location for survival. *Clin. Orthop.* 419:155–161, 2004.
- Galili N, Davis RJ, Fredericks WJ, Mukhopadhyay I S, Rauscher FJ III, Emanuel BS, Rovera G, Barr FG. Fusion of a fork head domain gene to PAX3 in the solid tumour alveolar rhabdomyosarcoma. *Nat. Genet.* 5(3):230–235, 1993.
- Kawai A, Woodruff J, Healey JH, Brennan MF, Antonescu CR, Ladanyi M. SYT-SSX gene fusion as a determinant of morphology and prognosis in synovial sarcoma. *N. Engl. J. Med.* 338(3):153–160, 1998.
- Shapiro DN, Sublett JE, Li B, Downing JR, Naeve CW. Fusion of PAX3 to a member of the forkhead family of transcription factors in human alveolar rhabdomyosarcoma. *Cancer Res.* 53(21):5108–5112, 1993.
- Sharp R, Recio JA, Jhappan C, Otsuka T, Liu S, Yu Y, Liu W, Anver M, Navid F, Helman LJ, DePinho RA, Merlino G. Synergism between INK4a/ARF inactivation and aberrant HGF/SF signaling in rhabdomyosarcomagenesis. *Nat. Med.* 8(11):1276–1280, 2002.
- Stout AP. Rhabdomyosarcoma of the skeletal muscles. *Ann. Surg.* 123(3):447–472, 1946.

**MALIGNANT BONE TUMORS**

- Batson OV. The function of the vertebral veins and their role in the spread of metastasis. *Ann. Surg.* 112(1):138–149, 1940.
- Delattre O, Zucman J, Melot T, Garau XS, Zucker J-M, Lenoir GM, Ambros PF, Sheer D, Turc-Carel C, Triche

TJ, Aurias A, Thomas G. The Ewing family of tumors—a subgroup of small-round-cell tumors defined by specific chimeric transcripts. *N. Engl. J. Med.* 331(5):294–249, 1994.

- Ewing J. Diffuse endothelioma of bone. *Proc. New York Pathol. Soc.* 21:17–24, 1921.
- Honoki K, Stojanovski E, McEvoy M, Fujii H, Tsujiuchi T, Kido A, Takakura Y, Attia J. Prognostic significance of p16(INK4a) alteration for Ewing sarcoma: a meta-analysis. *Cancer* 110(6):1351–1360, 2007.
- Link MP, Goorin AM, Miser AW, Green AA, Pratt CB, Belasco JB, Pritchard J, Malpas JS, Baker AR, Kirkpatrick JA, Ayala AG, Shuster JJ, Abelson HT, Simone JV, Vietti TJ. The effect of adjuvant chemotherapy on relapse-free survival in patients with osteosarcoma of the extremity. *N. Engl. J. Med.* 314(25):1600–1606, 1986.
- Miller CW, Aslo A, Won A, Tan M, Lampkin B, Koeffler HP. Alterations of the p53, Rb, and MDM2 genes in osteosarcoma. *J. Cancer Res. Clin. Oncol.* 122(9):559–565, 1996.
- Ottaviani G, Jaffe N. The etiology of osteosarcoma. *Cancer Treat. Res.* 152:15–32, 2009.
- Pasic I, Shlien A, Durbin AD. Recurrent focal copy-number changes and loss of heterozygosity implicate two noncoding RNAs and one tumor suppressor gene at chromosome 3q13.31 in osteosarcoma. *Cancer Res.* 70(1):160–171, 2010.
- Riccio I, Marcarelli M, Del Regno N, Fusco C, Di Martino M, Savarese R, Gualdiero G, Oreste M, Indolfi C, Porpora G, Esposito M, Casale F, Riccardi G. Musculoskeletal problems in pediatric acute leukemia. *J. Pediatr. Orthop. B.* 22(3):264–269, 2013.
- Schimke RN, Lowman JT, Cowan AB. Retinoblastoma and osteogenic sarcoma in siblings. *Cancer* 34(6):2077–2079, 1974.

**OTHER TUMOR**

- Abe T, Tomatsu T, Tazaki K. Synovial hemangioma of the knee in young children. *J. Pediatr. Orthop. B.* 11(4):293–297, 2002.
- Müller H, Horwitz A, Kuhl J. Acute lymphoblastic leukemia with severe skeletal involvement: a subset of childhood leukemia with a good prognosis. *Pediatr. Hematol. Oncol.* 15(2):121–133, 1998.

**OTHER**

- Adler C-P, Kozlowski K. *Primary Bone Tumors and Tumorous Conditions in Children: Pathologic and Radiologic Diagnosis.* Berlin, Germany: Springer-Verlag; 1993.
- Cheng EY, Thompson RC. New developments in the staging and imaging of soft-tissue sarcomas. *J. Bone Joint Surg. Am.* 81(6):882–891, 1999.
- Enneking WF, Spanier SS, Goodman MA. A system for the surgical staging of musculoskeletal sarcoma. *Clin. Orthop.* 153:106–120, 1980.
- Lowry PA, Carstens MC. Occult trauma mimicking metastases on bone scans in pediatric oncology patients. *Pediatr. Radiol.* 27(2):114–118, 1997.
- Malkin D, Li FP, Strong LC, Fraumeni JF, Nelson CE, Kim DH, Kassel J, Gryka MA, Bischoff FZ, Tainsky MA. Germ line p53 mutations in a familial syndrome of breast cancer, sarcomas, and other neoplasms. *Science* 250(4985):1233–1238, 1990.
- Mankin HG, Lange TA, Spanier SS. The hazards of biopsy in patients with malignant primary bone and soft-tissue tumors. *J. Bone Joint Surg. Am.* 64(8):1121–1127, 1982.
- Mirels H. Metastatic disease in long bones. A proposed scoring system for diagnosing impending pathologic fractures. *Clin. Orthop.* 249:256–264, 1989.