

# A case of amiodarone-induced dystonia in a patient with Parkinson's disease

Raza Zaidi, MD; Joseph Seemiller, MD; Travis Taylor, MD  
Geisinger Medical Center, Danville, PA

## Introduction

Amiodarone is a first line agent used to achieve rhythm control and is associated with several well-known side effects. Neurological side effects, however, are infrequently encountered.

We report a case of cervical dystonia that was time-linked with amiodarone administration in a patient with known Parkinson's disease (PD). This reaction has not previously been reported in the literature related to amiodarone administration. Classification of dystonia as well as common and uncommon causes of dystonia are reviewed, including multiple pharmacologic agents known to cause dystonia.

## Causes of Dystonia

Pathologic	<p><u>Degenerative</u>: Progressive structural changes including neuronal loss</p> <p><u>Static</u>: Non-progressive neurodevelopmental anomalies or acquired lesions</p>
Inherited	Proven genetic origin DYT classification dystonia Inherited as AD, AR, X-linked, mitochondrial
Acquired	<p><u>Perinatal brain injury</u>: Dystonic cerebral palsy</p> <p><u>Infection</u>: Viral encephalitis, HIV, TB</p> <p><u>Drugs</u>: Dopamine agonists, neuroleptics, anticonvulsants, calcium channel blockers</p> <p><u>Toxic</u>: Manganese, cyanide, methanol</p> <p><u>Vascular</u>: Ischemia, hemorrhage</p> <p><u>Neoplastic</u>: Paraneoplastic encephalitis</p> <p><u>Brain injury</u>: Head trauma, surgery</p> <p><u>Psychogenic</u>: Functional dystonia</p>
Idiopathic	Sporadic Familial

**Figure 1.** Numerous different pathologies, both hereditary and acquired, can cause dystonia and should be considered when evaluating a new-onset dystonia. Source: Albanese et al

## Case Presentation

A 79-year-old female with a past medical history of Parkinson's disease (PD) on carbidopa/levodopa, coronary artery disease, hypertension and Type 2 DM presented to the hospital with generalized weakness, diarrhea and dysphagia.

Her hospital course involved cardiac catheterization in workup of chest pain which showed severe multi-vessel disease and required coronary artery bypass graft. Her carbidopa/levodopa was held for approximately 30 hours due to her dysphagia. Post-operatively she developed atrial fibrillation with rapid ventricular response and was loaded with intravenous and oral amiodarone to achieve rhythm control. During this time, she was somnolent, however, examination was non-lateralizing, with cogwheeling rigidity and severe bradykinesia. Non-contrast CT head imaging was normal, and carbidopa/levodopa was restarted with significant reduction in her complaints the following day.

12-16 hours after carbidopa/levodopa was reintroduced, she began to have episodes of right head turn and gaze deviation associated with paucity of speech lasting several seconds to nearly one minute followed by a rapid return to normal. IV diphenhydramine and benzodiazepines were unsuccessful in aborting events. Her amiodarone infusion was stopped and repeat CT head and long-term video EEG monitoring was unrevealing. After discontinuation of the amiodarone infusion, her events did not cease immediately, but the frequency and duration decreased until cessation hours later.

## Hyperkinetic Movements

Table 1: Five Major Types of Hyperkinetic Movement Disorders	
Tremors	Involuntary, alternating movements involving one or more joints occurring at a regular frequency resulting in "rhythmic oscillations"
Chorea	Involuntary, non-rhythmic, abrupt movements resulting from continuous flow of muscle contractions from one muscle group to another resulting in jerky or dance like movements
Dystonia	Involuntary, slow, sustained contractions of agonist and sometimes also antagonist muscles producing twisting movements and/or abnormal posturing
Myoclonus	Involuntary, sudden, brief muscle contractions (positive myoclonus) or inhibition of muscle contractions (negative myoclonus) leading to shock like movements
Tics	Simple or complex, repetitive, abnormal movements or sounds usually preceded by an uncomfortable feeling or sensory urge that is relieved by carrying out the behavior. Tics can often be easily mimicked and suppressed by short efforts of will.

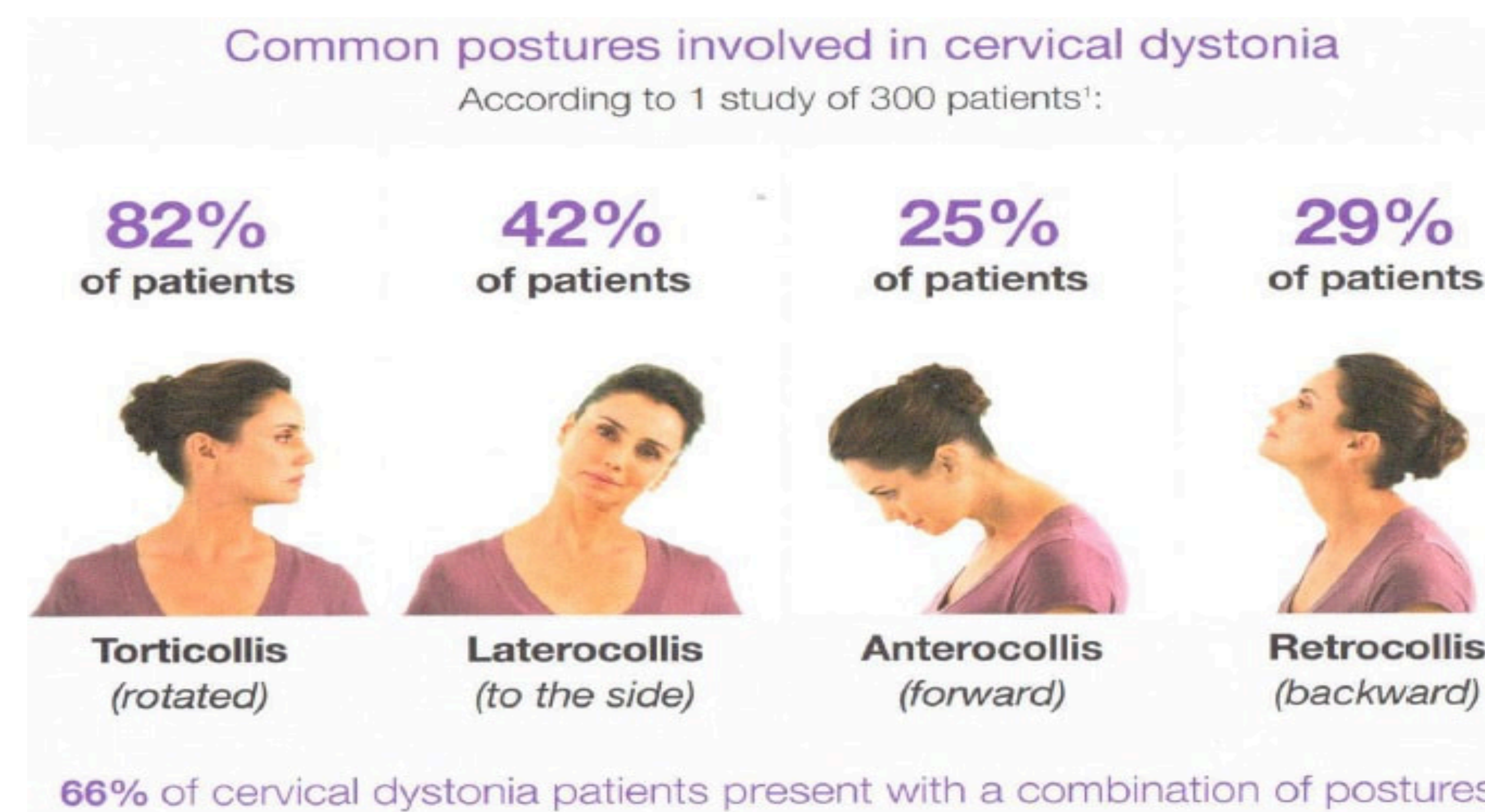
**Table 1.** Dystonia must be distinguished from the other hyperkinetic movement disorders. It is characterized by the slow and sustained nature of the movement. Source: Fahn et al.

## Conclusion

The evaluation of new acute-onset dystonia can be challenging, especially in a patient with pre-existing neurological condition such as PD or in hospitalized patients with significant vascular risk factors such as ours presented, which could cause acute vascular events. Workup of new-onset adult hyperkinetic movements should begin with a classification of the movement into tremor, chorea, dystonia, myoclonus, and tic (figure 2). Cervical dystonia can be further described using several common postures (figure 3). Finally, etiology can be considered (figure 1) and worked up based on the acuity of presentation. Acute vascular events should be promptly evaluated for with imaging (i.e. CT head) and consideration of and consideration of electroencephalography (EEG) if there is high suspicion for seizure. Several medications, as listed, can be related to dystonia onset and should be evaluated for. Finally, further imaging such as MRI and genetic testing can be considered in select cases.

In our case, a dopamine agonist withdrawal syndrome or akinetic crisis was suspected given missed doses of carbidopa/levodopa; however, bradykinesia and significant tremor improved after resumption and were no longer present at the time of the dystonic movement. It is important to note that amiodarone has previously been reported to have rare adverse effects such as action tremor, as well as extrapyramidal symptoms resembling parkinsonism. Given her lack of improvement after IV medications, negative video EEG and response to cessation of her amiodarone infusion, amiodarone-induced dystonia was the most likely diagnosis. We suspect that her threshold for developing these symptoms may have been reduced given that patients with PD can develop dystonia; however, this is the first report to our knowledge of a new-onset marked cervical dystonia time-linked with amiodarone administration.

## Cervical Dystonia



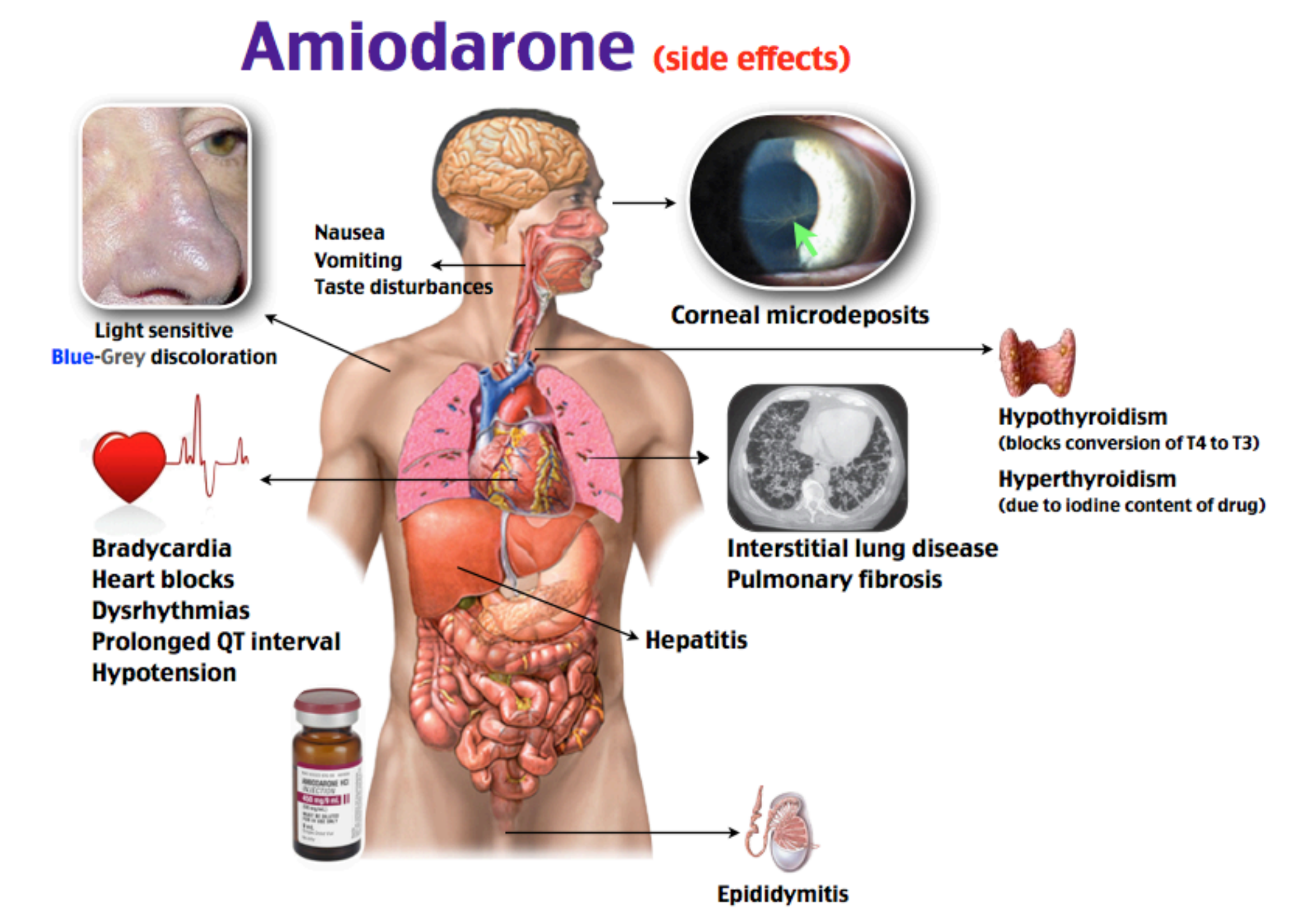
**Figure 3.** Cervical dystonia has multiple presenting postures, which it is important to recognize in order to properly diagnose and treat. Source: Mayo Clinic website (source 3).

## Types of Dystonia

Table 3. Primary Adult-Onset Focal Dystonias.		
Type of Dystonia	Main Clinical Features	Common Misdiagnoses
Cervical dystonia (spasmodic torticollis)	Abnormal head posture Head tremor Neck pain	Muscle strain Cervical disk disease Osteoarthritis
Blepharospasm	Increased blink rate Forced eye closure Difficulty opening eyes	Myasthenia gravis Dry eyes
Oromandibular dystonia	Jaw clenching (bruxism) Jaw in open position Lateral jaw shift	Temporomandibular joint syndrome Myasthenia gravis Dental malocclusion Edentulous movements
Orofacial dystonia	Action dystonias involving lips, tongue, or pharynx	Tic disorders
Spasmodic dysphonia		Chronic laryngitis, vocal-cord polyps, voice tremor, psychogenic causes
Adductor type	Voice breaks and strain	
Abductor type	Breathy voice	
Mixed type	Features of both	
Limb dystonia	Action dystonias affecting writing, playing musical instruments, handling tools, walking	Nerve entrapment Overuse syndromes Muscle cramps
Axial dystonia	Movements of shoulders, back, or abdomen	Myoclonus Motor tics Psychogenic causes

**Table 3:** Dystonia can affect multiple different body regions and can often be misdiagnosed. Source: Tarsy et al.

## Amiodarone side effects



**Figure 5:** Common side effects of amiodarone. Source: Rosh Review.

## References

- Figure 1.** Albanese, Alberto, et al. "Phenomenology and classification of dystonia: a consensus update." *Movement disorders* 28.7 (2013): 863-873.
- Table 1.** Fahn S, Jancovic J. Principles and Practice of Movement Disorders. 1st ed. Philadelphia, PA: Churchill Livingstone Elsevier; 2007
- Figure 3.** Mayo Clinic website. <https://www.mayoclinic.org/diseases-conditions/dystonia/symptoms-causes/syc-20350480>
- Table 3.** Tarsy, Daniel, and David K. Simon. "Dystonia." *New England Journal of Medicine* 355.8 (2006): 818-829.
- Figure 5.** Rosh Review. <https://www.roshreview.com/blog/vodcast/the-rosh-reveal/the-rosh-reveal-ep17/>.