

# Anatomy of the Rhesus Monkey (*Macaca mulatta*): The Essentials for the Biomedical Researcher

*Christophe Casteleyn and Jaco Bakker*

## Abstract

Amongst the non-human primates, the rhesus monkey (*Macaca mulatta*) is the most commonly investigated species in biomedical research. Its similarity to humans regarding the anatomy and physiology has resulted in an increasing number of studies in which the rhesus monkey serves as a model. This book chapter aims to fulfill the researcher's need for easily accessible anatomical data on the rhesus monkey by presenting the essentials of its various anatomical systems. The cadavers of several rhesus monkeys of either gender were dissected for gross anatomical study of the muscular, digestive, respiratory and urogenital systems. The circulatory system was studied after injection of latex into the blood vessels. Not only did this technique allow for better visualization of the blood vessels, but it was also valuable during the description of the peripheral nerves. In addition, methyl methacrylate casts were prepared to gain insight into the organization of the arterial system. The arthrology of the rhesus monkey was studied during the maceration of several cadavers, which ultimately revealed the individual bones that were described. From one such cadaver the skeleton was mounted. The results of the dissections are textually described and illustrated by means of numerous figures.

**Keywords:** Rhesus monkey, Anatomy, Osteology, Arthrology, Myology, Digestive system, Urogenital system, Angiology, Neurology

## 1. Introduction

The rhesus monkey (*Macaca mulatta*) belongs to the class of the mammals (*Mammalia*), the order of the primates (*Primates*), the family of the Old World monkeys (*Cercopithecidae*) and the genus *Macaca*. This animal finds its origin in the southern parts of Asia but is widespread throughout the world as one of the most frequently used laboratory animal. This is the result of the many similarities between the rhesus monkey and humans. Both species have common ancestry with genomes that are identical for 93.5% [1]. Only great apes present a larger degree of similarity with humans, but their use in research is very strictly regulated [2].

Rhesus monkeys are commonly used in toxicity studies and play a pivotal role in unraveling the mechanisms of health and diseases and during the development of vaccines. HIV, SARS and Covid-19 are a few examples of viral diseases that are studied in the rhesus monkey. In addition to investigations that require that the

physiology of this laboratory animal parallels that of man, studies that demand a comparable anatomy are multiple as well. Examples include studies on osteoporosis, osteopenia, lordosis and kyphosis [1].

The aim of this book chapter is to provide the biomedical researcher, who studies and/or uses the rhesus monkey, with the essentials of its anatomy. Although this chapter is rather elaborate, not all the details of the rhesus monkey anatomy can be described. Where appropriate, emphasis is put on those structures that have importance during manipulations of the animal under investigation, such as the muscles that allow for intramuscular injection and the veins that can be punctured to draw blood or inject substances intravenously. Researchers can be referred to two anatomical atlases for further reading. These include the work by Hartman and Straus Jr. from 1933, entitled *The Anatomy of the Rhesus Monkey* (*Macaca mulatta*) [3] and the work by Berringer and coworkers from 1968, entitled *An Atlas and Dissection Manual of Rhesus Monkey Anatomy* [4]. However, these reference works are outdated as they present black-and-white photographs and line drawings to visualize the anatomy. In addition, they make use of human terminology that is often archaic. In the present book chapter, more than 70 full color photographs are shown. In the figure legends, the official veterinary anatomical nomenclature is used [5]. In the text, however, English terms are used to enhance the readability. All materials for this study were obtained from animals that were euthanized for ethical reasons. No animals were euthanized for the purpose of this chapter.

## 2. External appearance

The rhesus monkey exhibits pronounced sex differentiation (**Figure 1**). Females measure approximately 47 cm in length (crown-rump length, thus without tail) and weigh 5–8 kg, whereas males present values of 53 cm and 8–15 kg, respectively [6, 7]. They have a relatively short, nonprehensile tail. As the rhesus monkey is a despotic species, fights often occur related to their hierarchical rank order system causing severe tail wounds all resulting in the veterinarian's decision to amputate the injured tail.

The hairs on the lateral sides of the animal are gray to brown. The inside of the arms and legs, and the belly color pale beige to white. Each finger and toe, five on each hand and foot, possesses a nail (unguis). The palms of the hands and the soles



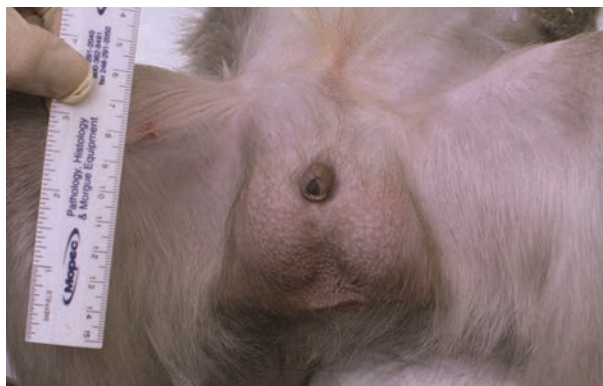**Figure 1.** External appearance of the male (A) and female (B) rhesus monkey. Notice the twins suckling their mother.

of the feet are keratinized showing epidermal ridges [7]. The face, including the ears, has very few hairs and therefore a pinkish appearance. Females possess a pair of pectoral mammary glands.

The skin covering and surrounding the genitals is also devoid of hairs. In males, the scrotum is non-pendulous and contains a pair of testes that measure 4 cm in length [8]. The penis is normally retracted within the preputium (**Figure 2**), only extracted during mating.

Menarche occurs at about 3 years of age and the length of the menstrual cycle is 28 days. The gestation length is around 165 days. Rhesus monkeys are seasonal breeders. Menstrual bleeding (menses) lasts for about 4 days. During the mating season (autumn-early winter), the skin of the face and genitals of females becomes characteristically red and/or swollen (**Figures 3 and 4**) during the period of regular cycles (sex skin coloration). These periodic changes in sex skin coloration are not valid indicators of either ovulation or menstruation. The sex skin is a secondary sex characteristic and reflects estrogenic activity. It fluctuates, as a rule, as to presence, extent, and time of year in a very unpredictable manner. In older females, the sex skin is less pronounced, and the redness may persist for longer intervals. Moreover, sex color is maintained during the entire gestational period and for several weeks after parturition: females who become pregnant during the mating season do not show the significant sex skin coloration decrease seen in nonpregnant females during the months that follow the mating season. Environmental cues, perhaps acting on a seasonal biological clock rather than social factors, are thought to be mainly responsible for the seasonal fluctuations observed. Sex skin involves the skin of the buttocks, hips, and base of tail, but the coloration and swelling can even spread in red splotches down the legs and over the calves to the heel; and there might also be a forward-tapering streak of red splotches from the symphysis to the umbilicus. Females could use color as a gauge to monitor other females' reproductive status or cyclic phase, for competitive purposes, as hindquarter color can advertise the relative timing of ovulation. The possibility might not be plausible for facial color, given that the relationship between face color and cyclic phase is not predictable in rhesus monkeys.

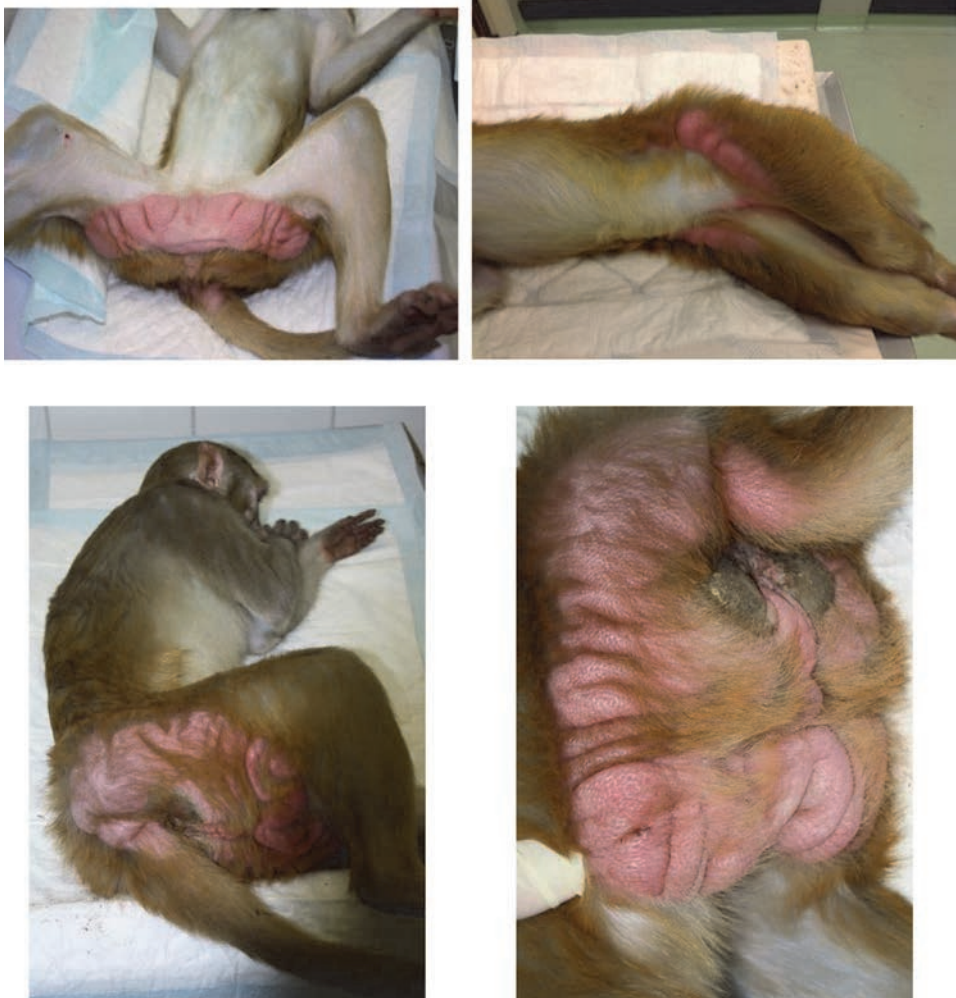In females, the vulva is pronounced, with a large visible clitoris between the sciatic protuberances that are covered with keratinized skin patches (callositas ischii/sciatic protuberances), which is typical for Old World monkeys, both males and females (**Figure 5**).



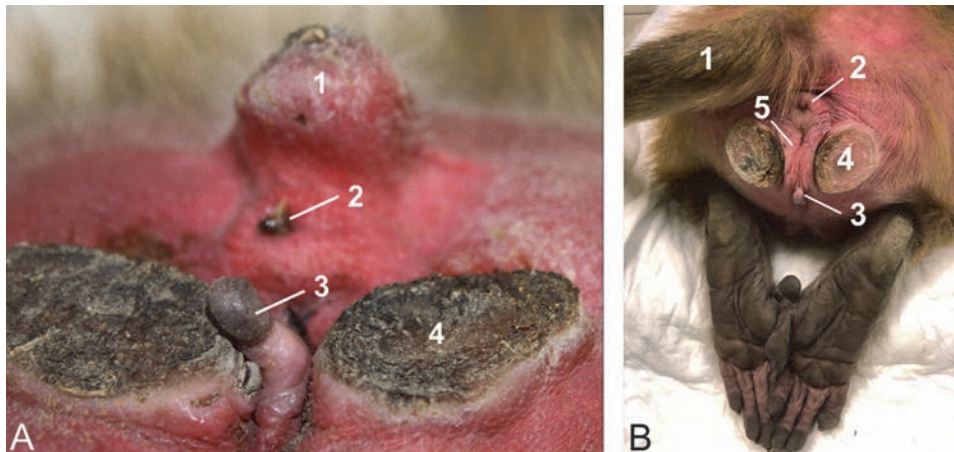
**Figure 2.**  
*External genital organs of the male rhesus monkey with the penis retracted into the preputium.*



**Figure 3.**  
*Two examples of sex skin (coloration and swelling) in the face of females.*



**Figure 4.**  
*Four examples of sex skin coloration and swelling on the buttocks, hips, legs and base of tail in females.*



**Figure 5.**  
(A) Perineum of a female rhesus monkey. This female is presented with a tail stump (1) that is visible just dorsal to the anal opening (2). The large clitoris (3) is present in between the sciatic protuberances (4). (B) This female has an intact tail (1) just dorsal to the anal opening (2). The clitoris (3) is less pronounced but still visible in between the sciatic protuberances (4). The prudential labia (5) can however, more readily be recognized in the female.

### 3. Osteology

The general build of the skeleton of the rhesus monkey is illustrated in **Figure 6**. The skull is large and heavy compared to the slender body. This contrasts with the sturdy external appearance of the rhesus monkey, as depicted in **Figure 1**, which suggests that this species has a well-developed musculature.

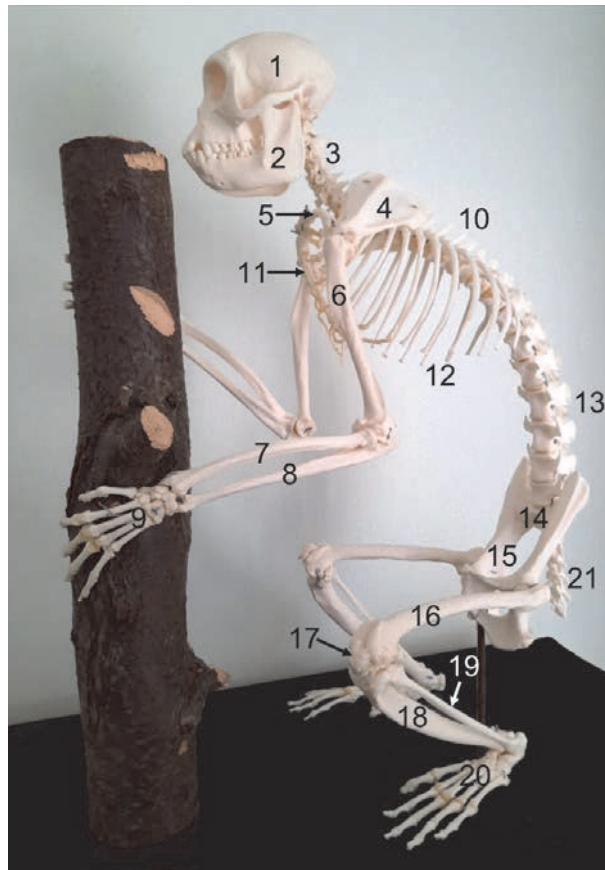
#### 3.1 Skull

The skull including the mandible of an adult male rhesus monkey is depicted in **Figure 7**. Some major anatomical landmarks are indicated. The splanchnocranium is relatively large but presents a reduced length. The very large conical orbits are almost completely postorbitally closed. The neurocranium is situated caudal to the former. It contains the cranial cavity that harbors the brains. The mandible and in particular its body is relatively large. A prominent mandibular angle can be seen. The symphysis between the left and right mandibles is synostotic.

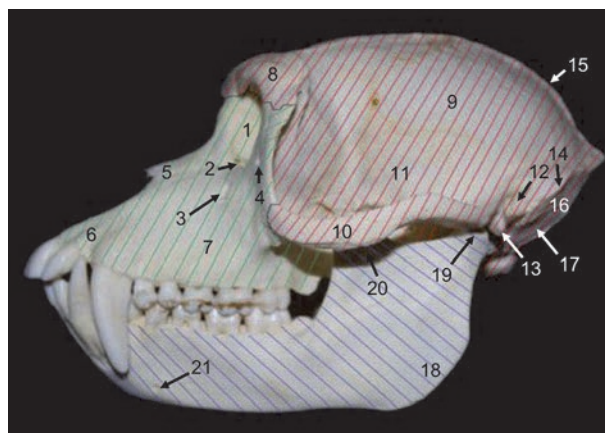
The hyoid bone of the rhesus monkey (**Figure 8**) is not directly connected to the skull. It consists of a body (corpus) and a bilaterally present pair of horns that lie caudally. The lesser horn (cornu minus) is, however, fused with the greater horn (cornu majus). The latter horns are joined with the body by means of cartilage.

#### 3.2 Axial skeleton

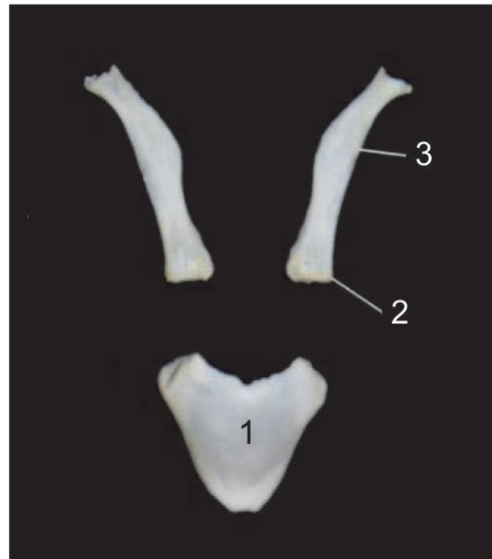The vertebral column consists of 7 cervical vertebrae, 12 thoracic vertebrae, 7 lumbar vertebrae, 3 fused sacral vertebrae and around 19 caudal vertebrae. This number is variable. The fifth, sixth and seventh caudal vertebrae possess a hemal arch that encloses the caudal artery and vein. The number of rib pairs equals the number of thoracic vertebrae, i.e. 12. Consequently, the rhesus monkey presents 24 ribs in total. These are connected to the sternum, which is composed of 7 sternebrae, by means of costal cartilages. The manubrium is the first sternebra to which not only the first pair of ribs is connected, but also the bilaterally present



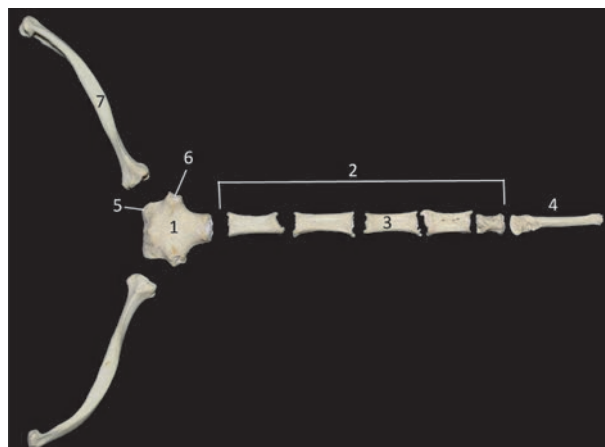
**Figure 6.** Skeleton of a female rhesus monkey. 1: cranium, 2: mandibula, 3: vertebrae cervicales, 4: scapula, 5: clavicula, 6: humerus, 7: radius, 8: ulna, 9: manus, 10: vertebrae thoracales, 11: sternum, 12: arcus costalis, 13: vertebrae lumbales, 14: sacrum, 15: pelvis, 16: femur, 17: patella, 18: tibia, 19: fibula, 20: pes, 21: vertebrae caudales.



**Figure 7.** Left lateral view of the skull of an adult male rhesus monkey. The splanchnocranium and neurocranium are shaded in red and green, respectively. 1: orbita, 2: canalis lacrimalis, 3: foramen infraorbitale, 4: foramen zygomaticofaciale, 5: os nasale, 6: os incisivum, 7: maxilla, 8: os frontale, 9: os parietale, 10: arcus zygomaticus, 11: fossa temporalis, 12: porus acusticus externus, 13: processus styloideus, 14: crista nuchae, 15: linea nuchae, 16: planum nuchale, 17: foramen magnum. The mandible is shaded in purple. 18: angulus mandibulae, 19: processus condylaris, 20: processus coronoideus, 21: foramen mentale.



**Figure 8.**  
*Dorsal view of the hyoid bone. The large corpus (1) is caudally elongated by the bilateral cornu minus (2) and the bilateral cornu majus (3) that are fused.*



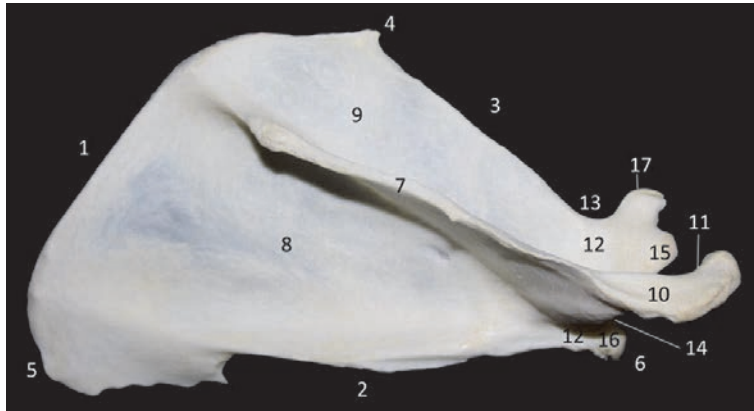
**Figure 9.**  
*Dorsal view of the sternum. 1: manubrium sterni, 2: corpus sterni, 3: sternebra, 4: processus xyphoideus, 5: incisura clavicularis, 6: incisura costalis, 7: clavícula.*

clavicle (**Figure 9**). This bone connects the sternum with the thoracic limb through its junction with the acromion of the shoulder blade.

### 3.3 Appendicular skeleton

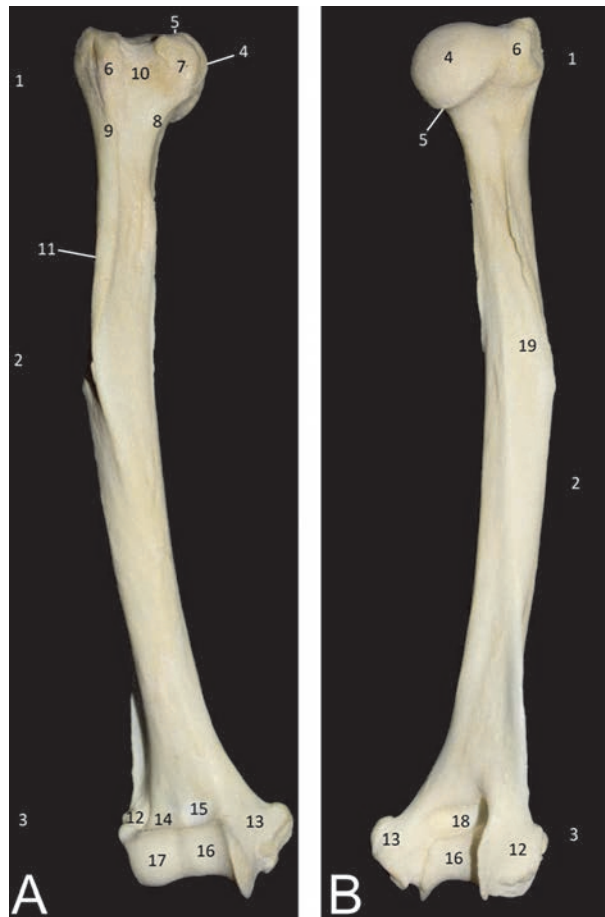#### 3.3.1 Thoracic limb

The thoracic limb, which is connected with the thorax by means of the clavicle, is composed of the shoulder blade or scapula (**Figure 10**), the humerus (**Figure 11**), the medially located radius (**Figure 12**) and the laterally located ulna (**Figure 13**) that are unfused, and the hand (**Figure 14**). The hand contains five fingers that are each composed of 3 phalanges, except the first, called the pollex, that lacks the middle phalanx.



**Figure 10.**

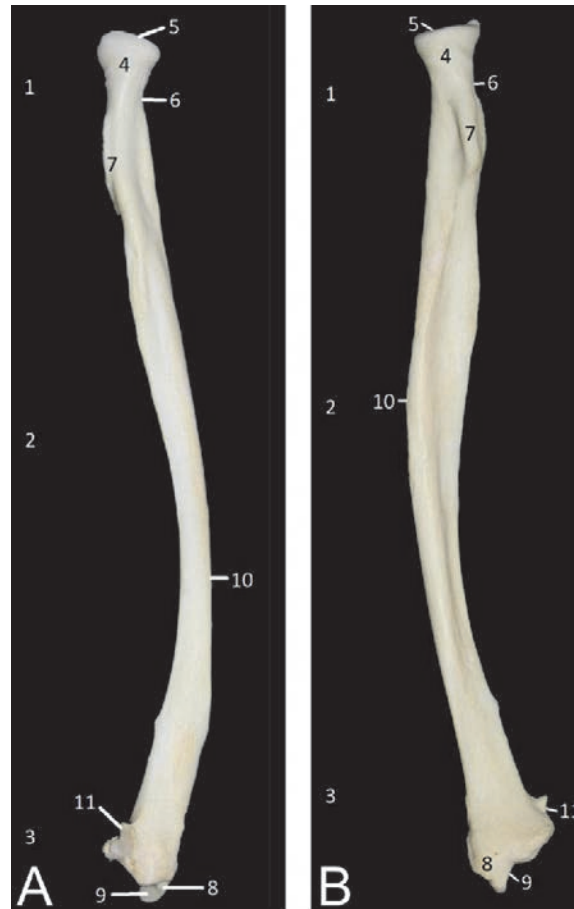Lateral view of the right scapula. 1: margo dorsalis, 2: margo caudalis, 3: margo cranialis, 4: angulus cranialis, 5: angulus caudalis, 6: angulus ventralis, 7: spina scapulae, 8: fossa infraspinata, 9: fossa supraspinata, 10: acromium, 11: facies articularis clavicularis, 12: collum scapulae, 13: incisura scapulae, 14: cavitas glenoidalis, 15: tuberculum supraglenoidale, 16: tuberculum infraglenoidale, 17: processus coracoideus.



**Figure 11.**

Cranial (A) and caudal (B) views of the right humerus. 1: epiphysis proximalis or extremitas proximalis, 2: diaphysis or corpus humeri, 3: epiphysis distalis or extremitas distalis, 4: caput humeri, 5: collum humeri, 6: tuberculum majus, 7: tuberculum minus, 8: crista tuberculi minoris, 9: crista tuberculi majoris, 10: sulcus intertubercularis, 11: tuberositas deltoidea, 12: epicondylus lateralis, 13: epicondylus medialis, 14: fossa radialis, 15: fossa coronoidea, 16: trochlea humeri, 17: capitulum humeri, 18: fossa olecrani, 19: sulcus nervi radialis.





**Figure 12.** Cranial (A) and caudal (B) views of the right radius. 1: epiphysis proximalis or extremitas proximalis, 2: diaphysis or corpus radii, 3: epiphysis distalis or extremitas distalis, 4: caput radii, 5: fovea articularis, 6: collum radii, 7: tuberositas radii, 8: processus styloideus radii, 9: facies articularis carpalis, 10: tuberositas pronatoria, 11: incisura ulnaris.

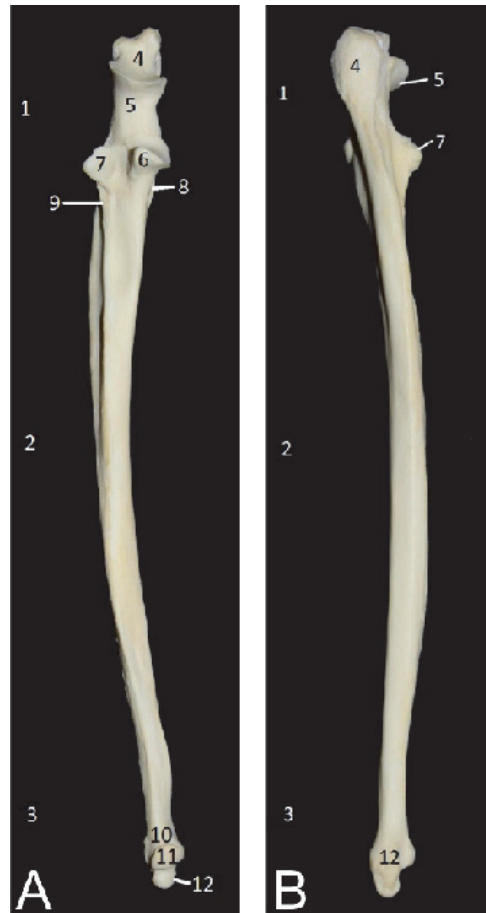### 3.3.2 Pelvic limb

The pelvic limb connects to the body through the pelvis that consists of the fused left and right pelvic bones (**Figures 15 and 16**). The symphysis between these bones is synostotic. The femoral bone or femur presents a distal trochlea for the ovoid patella. Both femoral condyles, which each support a sesamoid bone on their caudoproximal aspects, articulate with the tibial plateau (**Figure 17**). The tibia (**Figure 18**) lies medial to the slender fibula (**Figure 19**). The foot (**Figure 20**) contains five toes that are each composed of 3 phalanges, except the first, called the hallux, that lacks the middle phalanx.

## 4. Arthrology

### 4.1 Head

The various bones of which the skull is composed of are connected by means of sutures that ossify during puberty. As mentioned earlier, the symphysis mandibulae



**Figure 13.** Cranial (A) and caudal (B) views of the right ulna. 1: epiphysis proximalis or extremitas proximalis, 2: diaphysis or corpus ulnae, 3: epiphysis distalis or extremitas distalis, 4: olecranon with tuber olecrani, 5: incisura trochlearis with processus anconeus, 6: processus coronoideus medialis, 7: processus coronoideus lateralis, 8: tuberositas ulnae, 9: crista musculi supinatorii, 10: caput ulnae, 11: facies articularis, 12: processus styloideus ulnae.

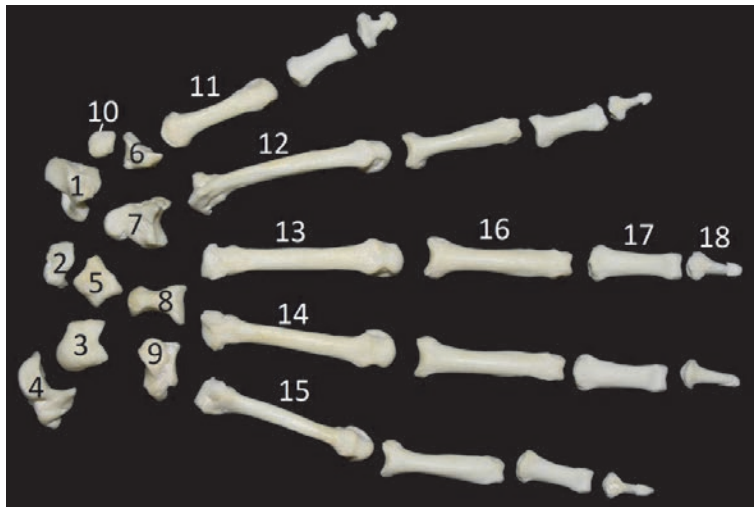
is synostotic. The mandibular joint between the mandible and the skull presents a cartilaginous disc that eliminates the incongruence between the mandibular fossa and the condylar process (**Figure 21**).

#### 4.2 Vertebral column

The atlanto-occipital joint between the occipital condyles of the skull and the cranial articulating foveae of the atlas (first cervical vertebra) is dorsally covered by the atlanto-occipital membrane. The bilateral articulations are laterally reinforced by the lateral ligaments.

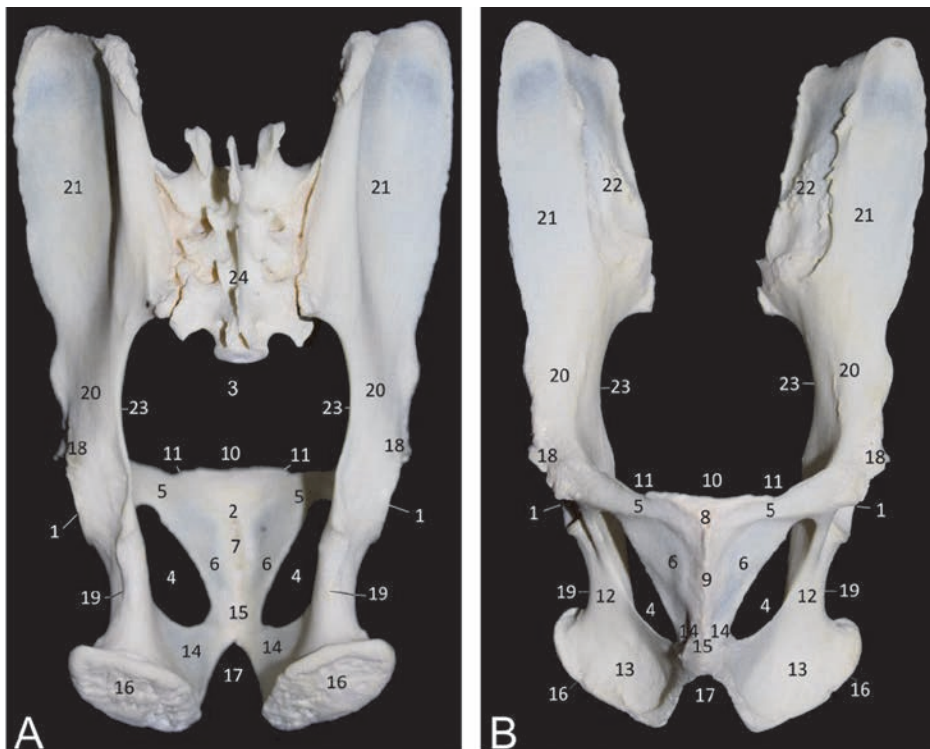
The atlanto-axial joint has three important ligaments. The transverse ligament covers the dens axis. From this dens, the longitudinal dental ligament runs to the ventral edge of the foramen magnum. The alar ligaments connect the dens with the lateral edges of the foramen magnum.

The individual vertebrae, from the third cervical vertebra to the sacrum, are joined together with multiple ligaments and bands (**Figure 22**). The supraspinal ligament is the continuation of the nuchal ligament that connects the external



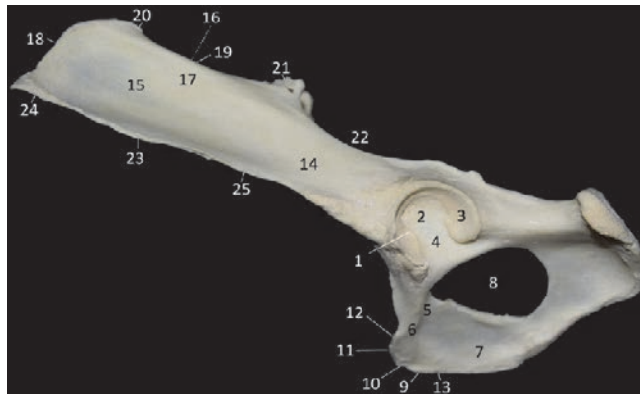**Figure 14.**

Dorsal view of the skeleton of the right hand. 1: *os carpi radiale (os scaphoideum)*, 2: *os carpi intermedium (os lunatum)*, 3: *os carpi ulnare (os triquetrum)*, 4: *os carpi accessorium (os pisiforme)*, 5: *os carpi Centrale*, 6: *os carpale primum (os trapezium)*, 7: *os carpale secundum (os trapezoidum)*, 8: *os carpale tertium (os capitatum)*, 9: *os carpale quartum (os hamatum)*, 10: *os sesamoideum m. abductoris digiti primi (pollicis)*, 11: *os metacarpale primum*, 12: *os metacarpale secundum*, 13: *os metacarpale tertium*, 14: *os metacarpale quartum*, 15: *os metacarpale quintum*, 16: *Phalanx proximalis*, 17: *phalanx media*, 18: *phalanx distalis*.



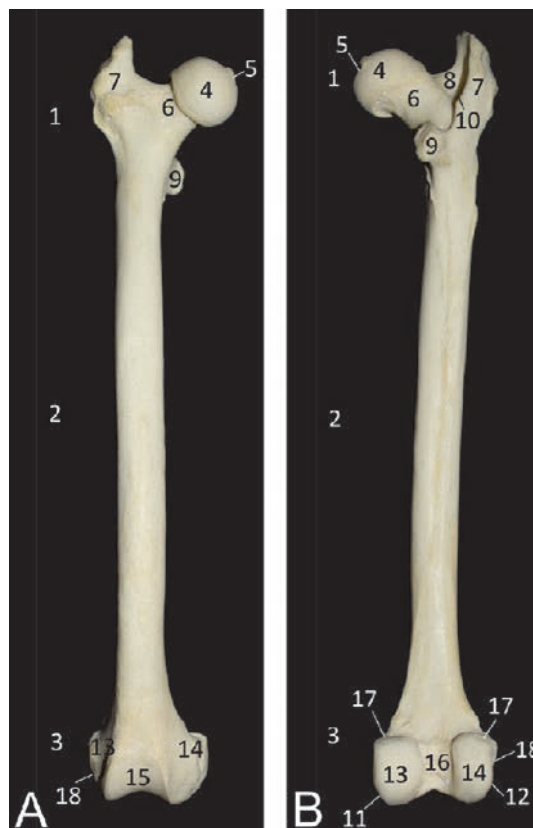**Figure 15.**

Dorsal (A) and ventral (B) views of the pelvis. 1: *acetabulum*, 2: *ossa pubicae*, 3: *cavum pelvis*, 4: *foramen obturatum*, 5: *ramus cranialis ossis pubis*, 6: *ramus caudalis ossis pubis*, 7: *symphysis pubica*, 8: *tuberculum pubicum ventrale*, 9: *crista pubica*, 10: *pecten ossis pubis*, 11: *eminentia iliopubica*, 12: *corpus ossis ischii*, 13: *tabula ossis ischii*, 14: *ramus ossis ischii*, 15: *symphysis ischiadica*, 16: *tuber ischiadicum*, 17: *arcus ischiadicus*, 18: *spina ischiadica*, 19: *incisura ischiadica minor*, 20: *corpus ossis ilii*, 21: *ala ossis ilii*, 22: *facies sacropelvina*, 23: *incisura ischiadica major*, 24: *sacrum*; 7+15 = *symphysis pelvina*.



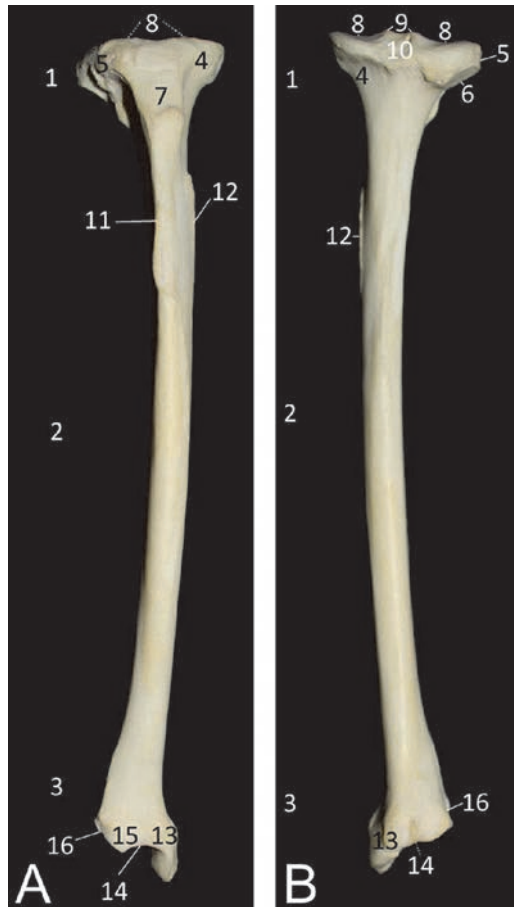
**Figure 16.**

Lateral view of the left os coxae. 1: acetabulum, 2: fossa acetabuli, 3: facies lunata, 4: incisura acetabuli, 5: corpus ossis pubis, 6: ramus cranialis ossis pubis, 7: ramus caudalis ossis pubis, 8: foramen obturatum, 9: symphysis pubica, 10: tuberculum pubicum ventrale, 11: pecten ossis pubis, 12: eminentia iliopubica, 13: crista sacrale or spina iliaca dorsalis, 14: corpus ossis ilii, 15: ala ossis ilii, 16: facies sacropelvina, 17: facies glutea, 18: crista iliaca, 19: tuber incisura ischiadica major, 20: spina iliaca dorsalis cranialis, 21: spina iliaca dorsalis caudalis, 22: incisura ischiadica major, 23: tuber coxae or spina iliaca ventralis, 24: spina iliaca ventralis cranialis, 25: spina iliaca ventralis caudalis.



**Figure 17.**

Cranial (A) and caudal (B) views of the right femur. 1: epiphysis proximalis or extremitas proximalis, 2: diafysis or corpus femoris, 3: epiphysis distalis or extremitas distalis, 4: caput ossis femoris, 5: fovea capitis, 6: collum ossis femoris, 7: trochanter major, 8: fossa trochanterica, 9: trochanter minor, 10: crista intertrochanterica, 11: epicondylus lateralis, 12: epicondylus medialis, 13: condylus lateralis, 14: condylus medialis, 15: trochlea ossis femoris, 16: fossa intercondylaris, 17: facies articularis sesamoidea (lateralis et medialis), 18: fossa m. poplitei.



**Figure 18.** Cranial (A) and caudal (B) views of the right tibia. 1: epiphysis proximalis or extremitas proximalis, 2: diaphysis or corpus tibiae, 3: epiphysis distalis or extremitas distalis, 4: condylus medialis, 5: condylus lateralis, 6: facies articularis fibularis, 7: tuberositas tibiae, 8: facies articularis proximalis, 9: eminentia intercondylaris, 10: tuberculum intercondylare laterale et mediale, 11: crista tibiae, 12: linea muscularis, 13: malleolus medialis, 14: facies articularis distalis, 15: cochlea tibiae, 16: incisura fibularis.

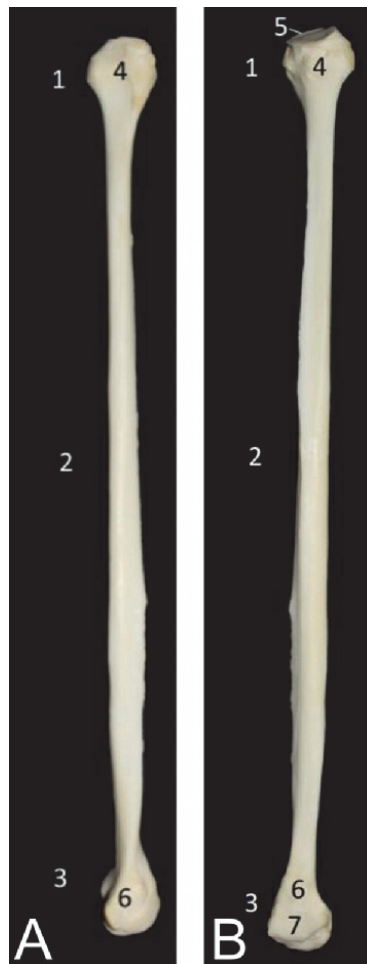occipital protuberance on the skull with the spinal processes of the 3rd tot 7th cervical vertebrae. The dorsal longitudinal ligament that lies immediately dorsal to the vertebral bodies, up to the sacrum, is the continuation of the tectorial membrane that covers the several ligaments of the atlanto-axial joint.

The ribs have three contact points with the thoracic vertebrae. The costal head articulates with the caudal fovea of the cranial thoracic vertebra (or the 7th cervical vertebra in the case of the first rib) and the cranial fovea of the caudal thoracic vertebra. An additional attachment is present between the costal tubercle and the transverse process of the thoracic vertebra, which number equals that of the rib (e.g., thoracic vertebra number 3 bears rib pair number 3). Ribs 11 and 12 lack the typical articulations as they have no costal tubercle.

### 4.3 Limbs

#### 4.3.1 Thoracic limb

The front limb is not only connected to the thorax by means of a synsarcosis (connecting muscles) but also by means of the collar bone that attaches to the

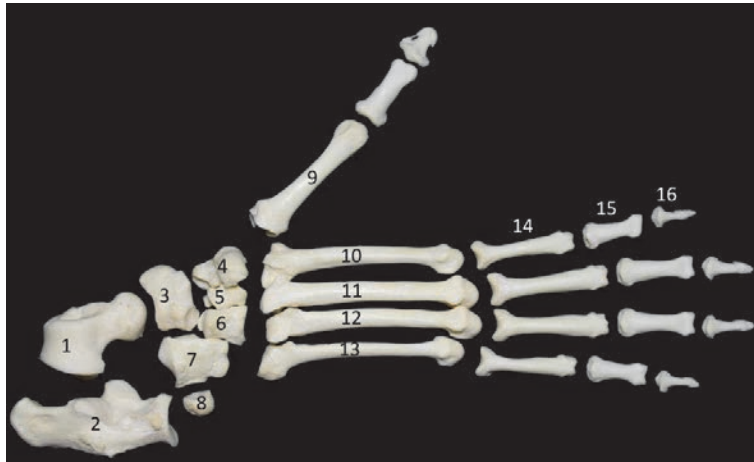


**Figure 19.** Lateral (A) and medial (B) views of the right fibula. 1: epiphysis proximalis or extremitas proximalis, 2: diaphysis or corpus fibulae, 3: epiphysis distalis or extremitas distalis, 4: caput fibulae, 5: facies articularis capitis fibulae, 6: malleolus lateralis, 7: facies articularis malleoli.

manubrium of the sternum, and the acromion and coracoid process of the shoulder blade. The coracoclavicular ligament is worth mentioning.

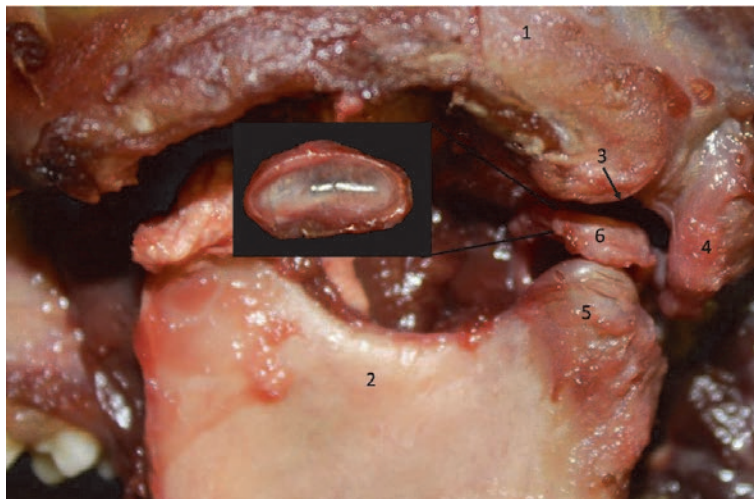
The shoulder joint between the shoulder blade and the humerus is characteristic in that the glenoid cavity of the scapula is narrower than the humeral head. Therefore, a glenoid labrum is present at the rims of the glenoid cavity. The coracohumeral ligament has its origin on the coracoid process of the scapula and inserts into the articular capsule. No collateral ligaments can be observed.

The elbow joint is formed by the humerus, radius and ulna. As such, a humeroradial and a proximal radioulnar articulation are present. The lateral collateral band originates at the lateral epicondyle of the humerus and attaches to the ulna (lateral coronoid process). It is therefore called the ulnar collateral ligament. The radial collateral ligament can be found between the medial humeral epicondyle and the radius (radial head) and ulna (medial coronoid process). The radial annular ligament attaches to both coronoid processes and encloses the radial head. In between the radius and ulna, the interosseous membrane can be seen. The distal radioulnar joint has a firm joint capsule that keeps both bones together.



**Figure 20.**

*Dorsal view of the skeleton of the right foot. 1: talus, 2: calcaneus, 3: os tarsi centrale (os naviculare), 4: os tarsale primum (os cuneiforme mediale), 5: os tarsale secundum (os cuneiforme intermedium), 6: os tarsale tertium (os cuneiforme laterale), 7: os tarsale quartum (os cuboideum), 8: os sesamoideum, 9: os metatarsale primum, 10: os metatarsale secundum, 11: os metatarsale tertium, 12: os metatarsale quartum, 13: os metatarsale quintum, 14: phalanx proximalis, 15: phalanx media, 16: phalanx distalis.*

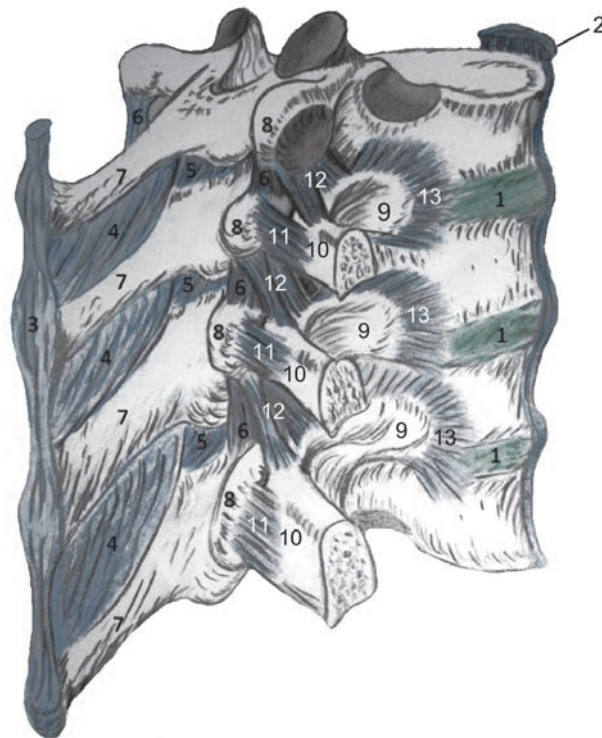


**Figure 21.**

*Left mandibular joint formed between the cranium (1) and the mandibula (2). More specifically, the articulation is present between the fossa mandibularis (3), caudally bordered by the processus styloideus (4), and the processus coronoideus (5). The discus articularis (6), of which a higher magnification is shown in the insert, is located in between these structures.*

The wrist or carpus/carpal joint is very complex. Numerous ligaments connect the several bones. These ligaments can be grouped into antebrachio-carpal (radiocarpal and ulnocarpal), intercarpal and carpometacarpal ligaments. The metacarpal bones are proximally connected to each other by means of the palmar metacarpal ligaments.

Metacarpophalangeal, proximal interphalangeal and distal interphalangeal joints are the several articulations that can be found in the fingers. The pollex only shows a single interphalangeal joint. Lateral and medial collateral bands connect the phalanges to each other and to the respective metacarpal bones.



**Figure 22.** Right lateral view of four thoracic vertebrae with their associated ligaments and ribs. The cranial rib has been removed entirely while the other ribs are cut proximally. 1: discus intervertebralis, 2: ligamentum longitudinale ventrale, 3: ligamentum supraspinale, 4: ligamenta interspinalia, 5: ligamentum interarcuale, 6: ligamenta intertransversaria, 7: processus spinosus, 8: processus spinosus, 9: caput costae, 10: tuberculum costae, 11: ligamentum costotransversarium laterale, 12: ligamentum costotransversarium craniale, 13: ligamenta radiata.

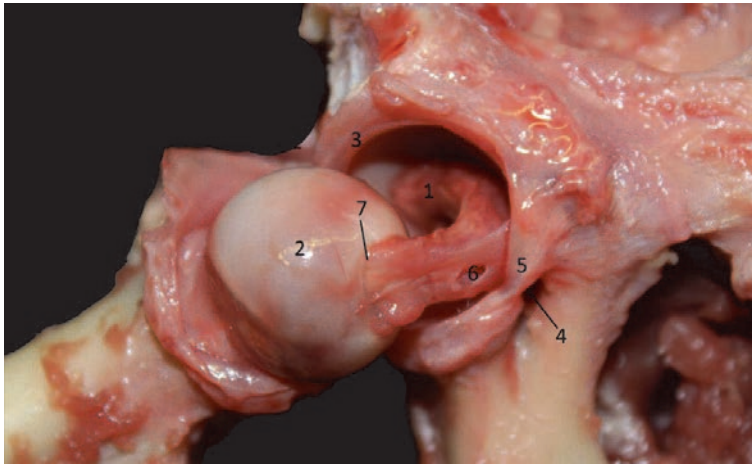
#### 4.3.2 Pelvic limb

The hip joint is formed between the acetabulum of the pelvic bone and the femoral head. The ligament of the femoral head is stretched between these structures. Since the acetabulum is rather shallow compared to the pronounced femoral head, its rim is provided by a cartilaginous labrum (**Figure 23**). No collateral bands are present.

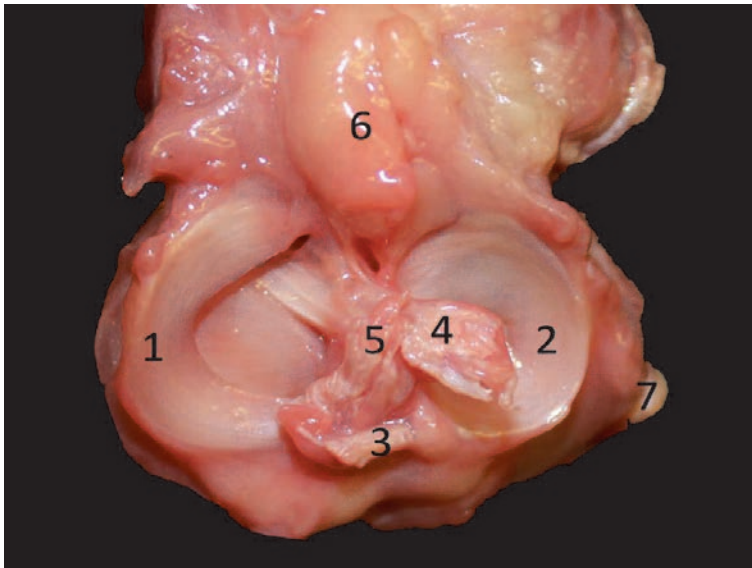
The knee joint is complex. It is composed of the femoropatellar, femorotibial and tibiofibular articulations. The ovoid patella bears a single straight patellar ligament that inserts on the tibial tuberosity. The incongruence between the femoral condyles and the tibial plateau is eliminated by the presence of C-shaped menisci. Both are cranially and caudally attached to the tibia by means of small meniscal ligaments. A cranial or lateral and a caudal or medial cruciate ligament can be observed between the femoral intercondylar fossa and the tibial intercondylar eminence. In addition, a meniscofemoral ligament or false cruciate ligament inserts on the caudal tip of the lateral meniscus. The lateral and medial collateral bands find their origins on the lateral and medial femoral epicondyles, respectively, and insert into the tibial epicondyle and fibular head, respectively (**Figure 24**).

The tarsal joint consists of the articulations between the tibia, the fibula, the several tarsal bones and the metatarsal bones (tarsocrural, proximal intertarsal, distal intertarsal and tarsometatarsal articulations). Numerous long and short ligaments connect the several bones. Long ligaments include the collateral ligaments and the long plantar ligament.





**Figure 23.**  
*Ventral view of the right hip joint. 1: acetabulum, 2: caput femoris, 3: labrum acetabulare, 4: incisura acetabuli, 5: ligamentum transversum acetabuli, 6: ligamentum capitis ossis femoris, 7: fovea capitis.*



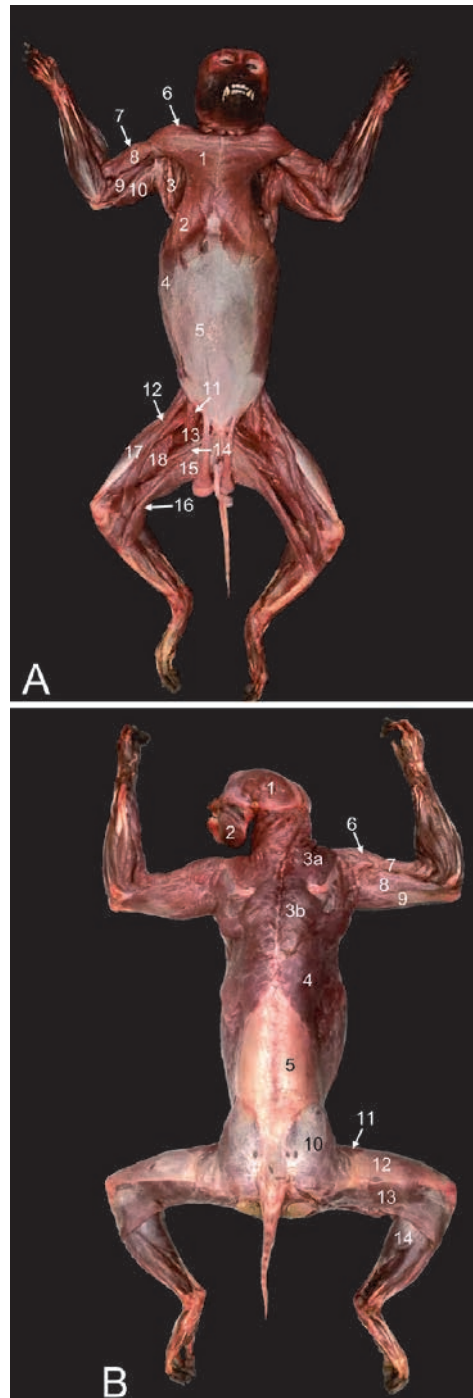
**Figure 24.**  
*View on the tibial plateau of the right limb. 1: meniscus medialis, 2: meniscus lateralis, 3: ligamentum meniscofemorale, 4: ligamentum cruciatum craniale, 5: ligamentum cruciatum caudale, 6: corpus adiposum infrapatellare, 7: ligamentum collaterale laterale.*

Metatarsophalangeal, proximal interphalangeal and distal interphalangeal joints are the several articulations that can be found in the toes. The hallux only shows a single interphalangeal joint. Lateral and medial collateral bands connect the phalanges to each other and to the respective metatarsal bones.

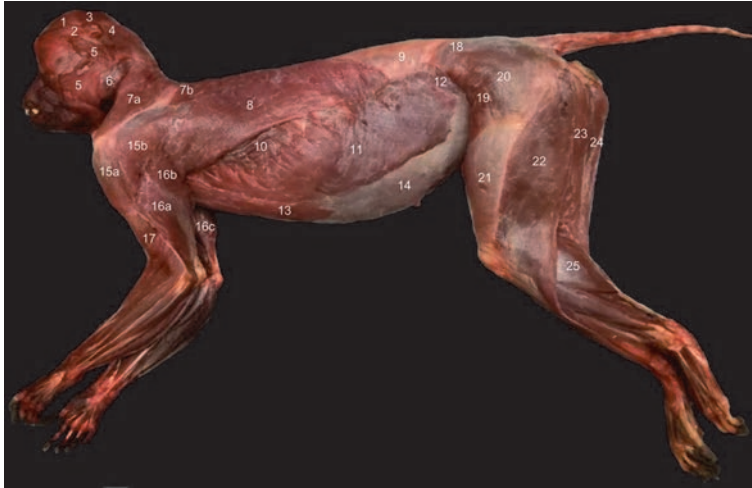## 5. Myology

### 5.1 General overview

The superficial muscles that can be observed immediately after skinning the animal are illustrated in **Figures 25** and **26**, which are ventral, dorsal and left lateral



**Figure 25.** Superficial musculature. A: Ventral view with 1: *m. pectoralis major*, 2: *m. pectoralis abdominalis*, 3: *m. latissimus dorsi*, 4: *m. obliquus externus abdominis*, 5: *m. rectus abdominis*, 6: *m. deltoideus*, 7: *m. biceps brachii caput longum*, 8: *m. biceps brachii caput breve*, 9: *m. triceps brachii caput mediale*, 10: *m. triceps brachii caput longum*, 11: *m. iliopsoas*, 12: *m. sartorius*, 13: *m. pectineus*, 14: *m. adductor longus*, 15: *m. gracilis*, 16: *m. semimembranosus*, 17: *m. rectus femoris*, 18: *m. vastus medialis*. B: Dorsal view with 1: *m. temporalis*, 2: *m. masseter*, 3a: *m. trapezius pars cervicalis*, 3b: *m. trapezius pars thoracica*, 4: *m. latissimus dorsi*, 5: *fascia thoracodorsalis*, 6: *m. deltoideus*, 7: *m. biceps brachii caput longum*, 8: *m. triceps brachii caput laterale*, 9: *m. triceps brachii caput longum*, 10: *m. gluteus superficialis covered by the fascia glutea*, 11: *m. tensor fasciae latae*, 12: *Fascia lata*, 13: *m. biceps femoris*, 14: *m. gastrocnemius caput laterale*.



**Figure 26.**

Left lateral view of the superficial musculature. 1: *m. frontalis*, 2: *m. orbitoauricularis*, 3: *m. auricularis dorsalis*, 4: *m. auricularis caudalis*, 5: *m. platysma*, 6: *m. masseter*, 7a: *m. trapezius pars cervicalis*, 7b: *m. trapezius pars thoracica*, 8: *m. latissimus dorsi*, 9: *fascia thoracodorsalis*, 10: *m. serratus ventralis*, 11: *m. obliquus externus abdominis*, 12: *m. obliquus internus abdominis*, 13: *m. pectoralis abdominalis*, 14: *Lamina externa vaginae m. recti abdominis*, 15a: *m. acromiodeltoideus*, 15b: *m. spinodeltoideus*, 16a: *m. triceps brachii caput laterale*, 16b: *m. triceps brachii caput longum*, 16c: *m. triceps brachii caput mediale*, 17: *m. biceps brachii*, 18: *fascia thoracolumbalis*, 19: *m. tensor fasciae latae*, 20: *m. gluteus superficialis*, 21: *fascia lata*, 22: *m. biceps femoris*, 23: *m. semitendinosus*, 24: *m. semimembranosus*, 25: *m. gastrocnemius caput laterale*.

views, respectively. Below, the musculature of the rhesus monkey is briefly described per region with emphasis on the origin and insertion of each muscle. Readers are referred to anatomical atlases [3, 9] for more details.

## 5.2 Facial muscles

The facial muscles play a pivotal role in the facial expression and therefore the communication between animals [10, 11].

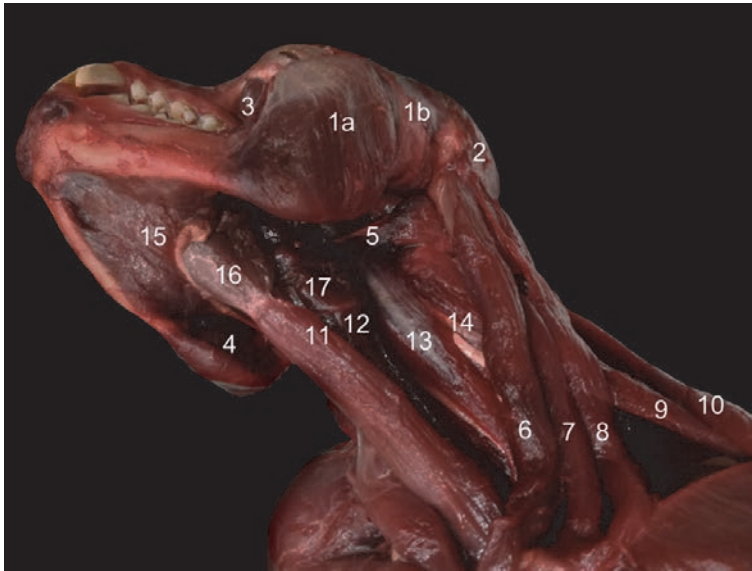- *M. platysma*: This very thin superficial muscle overlies the neck region and inserts into the *m. caninus*, *m. orbicularis oris*, *m. depressor anguli oris*, *m. depressor labii inferioris* and *m. mentalis* (**Figure 26**).
- *M. occipitalis*: This cutaneous muscle lies superficial to the *platysma* muscle.
- *M. frontalis*: This broad, thin muscle covers the forehead and inserts into the *m. orbicularis oculi* (**Figure 26**).
- *M. auricularis caudalis*: This muscle finds its origin in the dorsal cervical region, medial to the *occipitalis* muscle. It bifurcates to insert bilaterally at the caudal aspect of the external acoustic meatus (**Figure 26**).
- *M. auricularis dorsalis*: This muscle is wider and thinner than the former. It lies between the ears and inserts at the dorsal aspect of the external acoustic meatus (**Figure 26**).
- *M. orbitoauricularis*: This inconsistent muscle runs from the lateral orbital angle to the rostral aspect of the external acoustic meatus (**Figure 26**).

- *M. orbicularis oculi*: This muscle surrounds the orbit as a sphincter.
- *M. zygomaticus*: The origin of this band-shaped muscle is the zygomatic arch, whereas the insertion is the lateral angle of the mouth.
- *M. levator labii superioris*: It runs from the nasal and maxillary bones to the dorsal fibers of the orbicularis oris muscle.
- *M. levator labii alaeque nasi*: This muscle lies medial to the former and presents fibers that insert into the nasal wings.
- *M. depressor anguli oris*: This triangular muscle has insertions into the zygomatic and orbicularis oris muscles.
- *M. caninus*: This muscle lies deep to the former. It can be found at the angles of the mouth that cover the canines.
- *M. orbicularis oris*: This muscle surrounds the mouth opening as a sphincter.
- *M. depressor labii inferioris*: This muscle that lies ventromedial to the depressor anguli oris muscle runs between the ventral aspect of the orbicularis oris muscle and the skin of the chin.
- *M. mentalis*. This muscle covers the chin. It has insertions into the ventral aspect of the orbicularis oris muscle.

### **5.3 Masticatory muscles**

The muscles of mastication were studied after the facial musculature was removed.

- *M. masseter*: The masseter originates from the zygomatic arch. It consists of a larger superficial and a smaller deep part that both insert into the mandible (**Figures 25B, 26, and 27**).
- *M. temporalis*: This muscle fills the temporal fossa. Its fibers converge on the coronoid process of the mandible (**Figures 26 and 27**).
- *M. buccinator*: The buccinator is a deep muscle that originates from the rostral part of the zygomatic arch and the maxilla. It is inserted into the mandible (**Figure 27**).
- *M. pterygoideus*: The larger internal part arises from the pterygoid fossa and inserts into the mandibular angle. The smaller external part originates laterally on the pterygoid bone and inserts into the mandible at the level of the mandibular joint (**Figure 27**).
- *M. digastricus*: The rostral and caudal bellies are separated by an intermediate tendon. The caudal belly attaches to the mastoid process while the rostral belly inserts into the rostroventral border of the mandible (**Figure 27**).



**Figure 27.**  
*Ventrolateral view of the masticatory muscles and musculature of the ventral cervical region and tongue. 1a: m. masseter pars superficialis, 1b: m. masseter pars profunda, 2: m. temporalis, 3: m. buccinator, 4: m. pterygoideus, 5: m. digastricus venter caudalis, 6: m. sternomastoideus, 7: m. cleidomastoideus, 8: m. cleidooccipitalis, 9: m. levator scapulae cranialis, 10: m. trapezius pars cervicalis, 11: m. sternohyoideus, 12: m. sternothyroideus, 13: m. longus capitis, 14: m. longus colli, 15: m. mylohyoideus, 16: m. hyoglossus, 17: m. thyrohyoideus.*

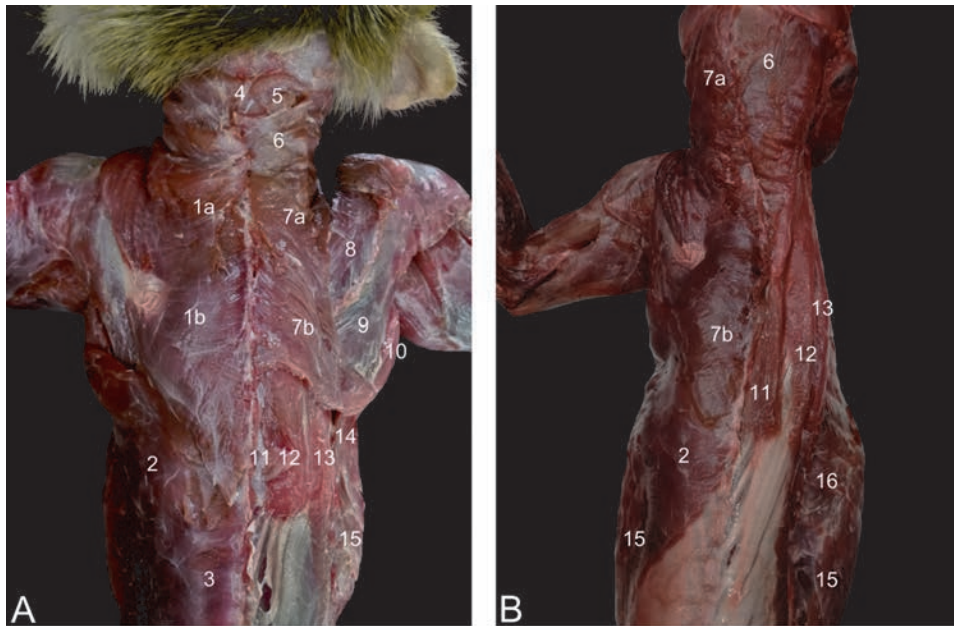
#### 5.4 Muscles of the ventral cervical region and tongue

- M. sternocleidomastoideus:
  - The lateral portion is the m. cleidooccipitalis that arises from the clavicle and inserts into the nuchal line of the skull (**Figure 27**).
  - The medial portion is the m. sternomastoideus that runs from the manubrium of the sternum to the mastoid process of the skull (**Figure 27**).
  - In between both muscles, the m. cleidomastoideus can be seen. It runs from the medial side of the clavicle to the mastoid process (**Figure 27**).
- M. omohyoideus: This fusiform muscle originates from the cranial border of the scapula and inserts into the lateral aspect of the hyoid bone. It runs medial to the sternocleidomastoid muscle and lateral to the common carotid artery and vagosympathetic trunk.
- M. sternohyoideus: This muscle finds its origin on the craniodorsal aspect of the manubrium sterni and inserts into the medial aspect of the hyoid bone. As a result, it covers the trachea in the ventral midline together with its contralateral counterpart (**Figure 27**).
- M. sternothyroideus: This muscle has the same origin as the former but inserts into the thyroid cartilage. It lies medial to the common carotid artery and vagosympathetic trunk, and ventral to the trachea (**Figure 27**).

- *M. longus capitis*: Both the major part (*m. longus capitis major*) and the minor part (*m. longus capitis minor*) insert into the basiocciput. The former arises from the ventral sides of the bodies of the 4th to 6th cervical vertebrae, while the latter has the atlas as its origo (**Figure 27**).
- *M. longus colli*: This muscle lies deep against the ventral sides of all cervical and the first four thoracic vertebrae, dorsal to the trachea. The short muscle fibers interconnect the subsequent vertebrae (**Figure 27**).
- *M. mylohyoideus*: This muscle originates from the medial surface of the mandibular body along its entire length and inserts into the median raphe of the tongue where it meets its counterpart (**Figure 27**).
- *M. hyoglossus*: The hyoid bone is the origin of this muscle that inserts into the tongue (**Figure 27**).
- *M. thyrohyoideus*: This muscle has its origin on the thyroid cartilage and inserts into the hyoid bone.
- *M. geniohyoideus*: This muscle originates from the mandible at the caudal edge of the symphysis and travels caudally towards the hyoid bone.

### 5.5 Muscles of the dorsal and lateral cervical regions

- *M. splenius*: This muscle is reduced in the rhesus monkey. It originates dorsally on the first three thoracic vertebrae and runs cranially towards the occiput.
- *M. complexus*: This muscle arises from the transverse processes of the 3rd to 5th thoracic vertebrae and is inserted into the occipital bone below the nuchal crest near the median plane (**Figure 28**).
- *M. rectus capitis*: The major part (*m. rectus capitis major*) and minor part (*m. rectus capitis minor*) arise from the crest of the axis and dorsal tubercle of the atlas, respectively. Both insert into the occipital bone (**Figure 28**).
- *M. obliquus capitis*: The cranial part (*m. obliquus capitis cranialis*) runs from the wing of the atlas to the occiput. The caudal part (*m. obliquus capitis caudalis*) arises from the crest of the axis and inserts into the wing of the atlas.
- *M. trachelomastoideus*: This muscle arises from the 2nd to 4th thoracic vertebrae and is inserted into the occipital bone and the mastoid process.
- *M. scalenus*:
  - *M. scalenus dorsalis* (*m. scalenus brevis posterior*): The origin is laterocaudal to the ventral scalenus muscle. The insertion is into the transverse processes of all cervical vertebrae.
  - *M. scalenus medius* (*m. scalenus longus*): The origin is on the 3rd to 5th rib. The insertion is on the transverse process of the 4th cervical vertebra (**Figure 30**).

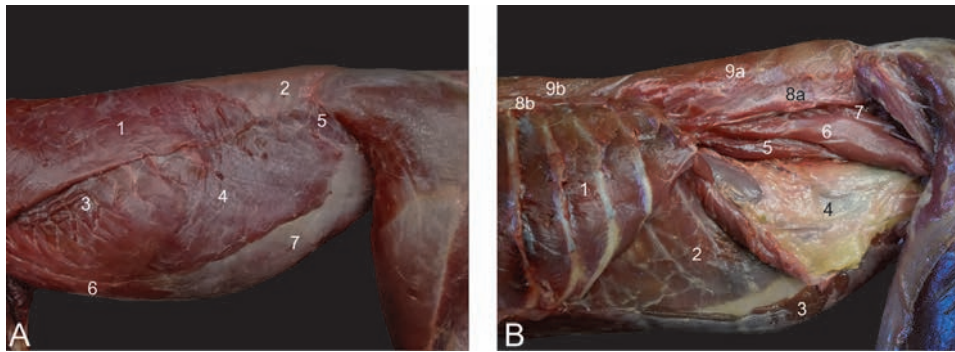


**Figure 28.** Musculature of the dorsal thoracocervical region. A: Superficial layer at the left and deeper layer at the right, B: Superficial layer at the left and deeper layer at the right after removal of the right front limb. 1a: *m. trapezius pars cervicalis*, 1b: *m. trapezius pars thoracica*, 2: *m. latissimus dorsi*, 3: *fascia thoracodorsalis*, 4: *m. rectus capitis*, 5: *m. complexus*, 6: *m. splenius*, 7a: *m. rhomboideus cervicis*, 7b: *m. rhomboideus thoracis*, 8: *m. supraspinatus*, 9: *m. infraspinatus*, 10: *m. teres major*, 11: *m. spinalis*, 12: *m. longissimus dorsi*, 13: *m. iliocostalis*, 14: *m. serratus ventralis*, 15: *m. obliquus externus abdominis*, 16: *m. serratus dorsalis*.

- *M. scalenus ventralis* (*m. scalenus brevis anterior*): The origo can be found craniomedially on the first rib. The insertion is the transverse processes of the 3rd to 5th cervical vertebrae.

## 5.6 Muscles of the spine

- *M. erector spinae*:
  - *M. iliocostalis*: This long muscle originates from the wing of the ilium and inserts into the transverse processes of the lumbar vertebrae, the ribs and transverse processes of the last two cervical vertebrae. As such, a lumbar and thoracic part can be discerned (**Figures 28 and 29**).
  - *M. longissimus dorsi*: This long, cylindrical muscle that is covered by the thoracodorsal fascia lies medial to the former muscle and runs from the ilium to the mastoid process. Insertions can be found into the lumbar, thoracic and cervical vertebrae and the ribs (*pars lumbalis*, *thoracis*, *cervicis* and *capitis*) (**Figure 28**).
  - *M. spinalis*: This is the deepest muscle of this group. The origins and insertions are the spinal processes (**Figures 28 and 29**).
- *M. transversospinalis*:
  - *M. semispinalis (capitis)* = *m. complexus*: This muscle was described earlier with the muscles of the dorsal and lateral cervical region (**Figure 28**).



**Figure 29.**

Left lateral view of the abdominal muscles. A: Superficial musculature with 1: *m. latissimus dorsi*, 2: *fascia thoracodorsalis*, 3: *m. serratus ventralis*, 4: *m. obliquus externus abdominis*, 5: *m. obliquus internus abdominis*, 6: *m. pectoralis abdominalis*, 7: *lamina externa vaginae m. recti abdominis*. B: Deep musculature with 1: *m. intercostalis externus*, 2: *m. transversus abdominis*, 3: *m. rectus abdominis*, 4: *fascia transversalis*, 5: *m. psoas minor*, 6: *m. psoas major*, 7: *m. quadratus lumborum*, 8a: *m. iliocostalis lumborum*, 8b: *m. iliocostalis thoracis* 9a: *m. longissimus lumborum*, 9b: *m. longissimus thoracis*.

- Mm. multifidi et rotatores: These muscles lie very deep against the vertebrae. With their origins and insertions on the transverse processes and into the spinal processes, they can rotate the vertebral column.
- *M. serratus dorsalis cranialis*: The cervicothoracic fascia offers the aponeurotic origin of this muscle that inserts into the 2nd to 5th ribs. The muscle fibers run in craniodorsal direction.
- *M. serratus dorsalis caudalis*: The lumbosacral fascia offers the aponeurotic origin of this muscle that inserts into the caudal ribs. The muscle fibers run in caudodorsal direction.

### 5.7 Tail musculature

The tail of the rhesus monkey is nonprehensile. The muscles found on the dorsal aspect of the caudal vertebrae are the mm. interspinales caudae, the *m. extensor caudae medialis*, the *m. extensor caudae lateralis*, the *m. abductor caudae medialis/internus* and the *m. abductor caudae lateralis/externus*. The ventral muscles of the tail comprise the *m. flexor caudae brevis*, *m. flexor caudae longus* and the mm. *intertransversarii caudae*.

### 5.8 Abdominal muscles

- *M. obliquus abdominis externus*: The muscle has tendinous origins on the 4th to the 12th rib, where it interdigitates with the serratus ventralis muscle. In addition, muscle fibers originate dorsally from the lumbodorsal fascia in the lumbar region. The fibers run caudoventrally towards the linea alba onto which it attaches by means of an aponeurosis (**Figures 29, 36, and 37**).
- *M. obliquus abdominis internus*: The fibers of this muscle that lies beneath the former originate from the thoracolumbar fascia and the iliac spine. The fibers run in cranioventral direction to become tendinous (aponeurosis) at the level of the straight abdominal muscle. The aponeurosis blends with that of the external oblique abdominal muscle and forms the external sheath of the

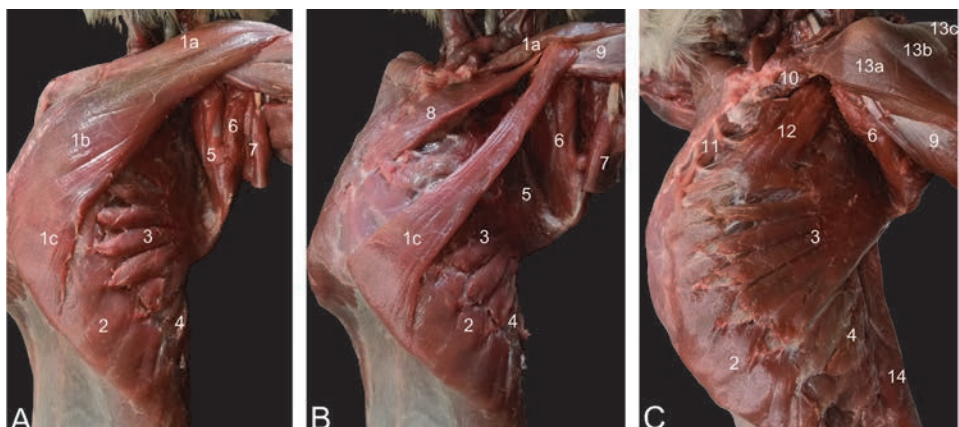


straight abdominal muscle (**Figures 29** and **36**). In the male, the cremaster muscle branches off the internal oblique abdominal muscle (**Figure 37**).

- M. transversus abdominis: This muscle arises from the costal arch, the lumbodorsal fascia and the iliac crest. The fibers run in dorsoventral direction to insert into the linea alba by means of an aponeurosis that forms the internal sheath of the straight abdominal muscle (**Figure 29**).
- M. rectus abdominis: This muscle lies between the fused aponeurosis of the external and internal oblique abdominal muscles on the one hand and the aponeurosis of the transverse abdominal muscle. The muscle runs from the sternum to the pubis and presents several tendinous intersections (**Figures 29** and **36**).

### 5.9 Muscles that connect the thoracic limb to the body

- Pectoral muscles:
  - M. pectoralis superficialis (m. pectoralis major):
    - a. Pars sternocapsularis: The sternoclavicular joint and the manubrium is the origo while the insertion is the intertubercular groove of the humerus (**Figure 30**).
    - b. Pars sternalis: This part has the same insertion site as the former but finds its origin along the entire length of the sternum (**Figure 30**).
    - c. Pars abdominalis: The origin is the xiphoid process and the cranial aspect of the external sheath of the straight abdominal muscle. The muscle inserts deep to the sternal part into the humerus (**Figure 30**).

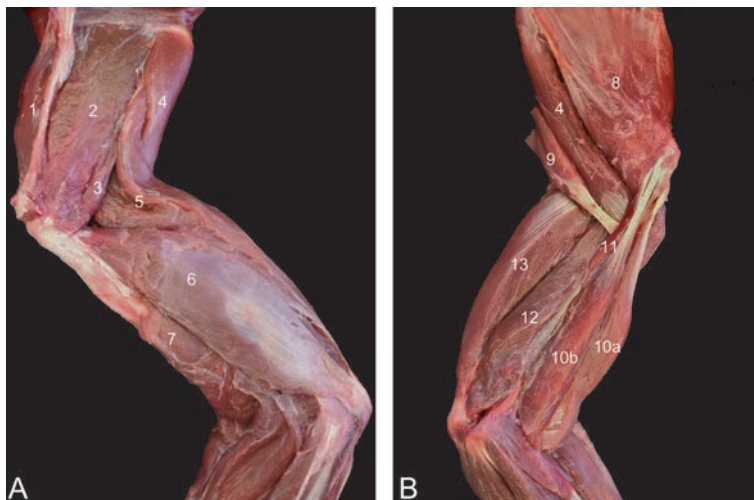


**Figure 30.** Lateral views of the pectoral muscles. A: superficial layer, B: deeper layer, C: deepest layer. 1a: m. pectoralis superficialis pars sternocapsularis, 1b: m. pectoralis superficialis pars sternalis, 1c: m. pectoralis superficialis pars abdominalis, 2: m. obliquus externus abdominis, 3: m. serratus ventralis, 4: m. serratus dorsalis, 5: m. subscapularis, 6: m. teres major, 7: m. latissimus dorsi, 8: m. pectoralis profundus, 9: m. biceps brachii, 10: m. subclavius, 11: m. sternocostalis, 12: m. scalenus medius, 13a: m. cleidodeltoideus, 13b: m. acromiodeltoideus, 13c: m. spinodeltoideus, 14: m. latissimus dorsi.

- *M. pectoralis minor* (*m. pectoralis profundus*): This pectoral muscle lies deep to the superficial pectoral muscle. It has origin on the cartilages of the 2nd to 6th ribs and is inserted into the greater tuberosity of the humerus (**Figure 30**).
- *M. subclavius*: This small fusiform muscle arises from the 1st costal cartilage and is inserted into the clavicle (**Figure 30**).
- *M. trapezius*: Both the cervical and thoracic parts arise from the scapular spine. The occiput and 10th thoracic vertebra are reached cranially, resp. caudally by this muscle that meets its counterpart in the dorsal midline (**Figures 25, 26, and 28**).
- *M. rhomboideus*: The cervical part (*m. rhomboideus cervicis* = *m. levator anguli scapulae*) and thoracic part (*m. rhomboideus thoracis*) arise from the dorsal border of the scapula and insert into the occiput and nuchal ligament, and the first 6 thoracic vertebrae, respectively (**Figure 28**).
- *M. serratus ventralis*: Muscle strands have attachments on the last four cervical vertebrae (*m. serratus ventralis cervicis* = *m. levator scapulae*) and first nine ribs (*m. serratus ventralis thoracis*) and inserts medially on the scapula (**Figures 26, and 28–30**).
- *M. latissimus dorsi*: This muscle originates by means of an aponeurosis at the dorsal midline at the level of the 6th to 12th thoracic vertebrae and the lumbodorsal fascia. The insertion site is twofold, i.e. at the teres major tendon and into the bicipital groove (**Figures 25, 26, and 28–30**).

### 5.10 Muscles of the shoulder region

- *M. supraspinatus*: This muscle fills the supraspinous fossa and has insertion into the greater humeral tubercle (**Figure 31**).



**Figure 31.**

*Musculature of the left shoulder. A: lateral view, B: medial view. 1: m. supraspinatus, 2: m. infraspinatus, 3: m. teres minor, 4: m. teres major, 5: m. triceps brachii caput longum, 6: m. triceps brachii caput laterale, 7: m. brachialis, 8: m. subscapularis, 9: m. latissimus dorsi, 10a: m. biceps brachii caput longum, 10b: m. biceps brachii caput breve, 11: m. coracobrachialis, 12: m. triceps brachii caput mediale, 13: m. triceps brachii caput laterale.*

- *M. infraspinatus*: The origin is the infraspinous fossa. The muscle is covered by the spinodeltoid muscle. Its tendon inserts into the greater tubercle of the humerus, in between the tendons of the supraspinous and teres minor muscles (**Figure 31**).
- *M. deltoideus*: The insertion is the deltoid tuberosity on the humerus. The origin is either the clavicle (*M. cleidodeltoideus* (*M. deltoideus anterior*)), the acromion (*M. acromiodeltoideus* (*M. deltoideus medius*)) or the scapular spine (*M. spinodeltoideus* (*M. deltoideus posterior*)) (**Figure 30**).
- *M. teres minor*: This muscle has origin at the caudodistal margin of the shoulder blade and the caudal aspect of the infraspinatus muscle. It inserts into the greater tubercle of the humerus, just caudal to the insertion of the aforementioned muscle (**Figure 31**).
- *M. teres major*: This muscle originates at the ventral angle and caudal border of the scapula and inserts medially into the humeral shaft in its proximal third (**Figure 31**).
- *M. subscapularis*: The origin and insertion of this muscle are the subscapular fossa and the lesser tubercle of the humerus, respectively (**Figure 31**).

## 5.11 Muscles of the upper arm

### 5.11.1 Extensor musculature

- *M. triceps brachii*: The triceps muscle inserts into the olecranon of the ulna. Its long head (*caput longum*), lateral head (*caput laterale*) and medial head (*caput mediale*) originate from the caudal border of the scapula, the greater tuberosity of the humerus, and the proximo-medial side of the humeral shaft, respectively (**Figures 25, 26, and 31**).
- *M. anconeus (lateralis)*: This small muscle arises distally on the humeral shaft and inserts proximally on the ulna.
- *M. dorsoepitrochlearis*: arises from the lower margin of the latissimus dorsi muscle and attaches to the antebrachial fascia and medial epicondyle of the humerus.

### 5.11.2 Flexor musculature

- *M. biceps brachii*: The long head (*caput longum*) and short head (*caput breve*) run from the supraglenoid tubercle and coracoid process of the shoulder blade, respectively to the radial tuberosity of the radius (**Figures 25, 26, 30, and 31**).
- *M. coracobrachialis*: Both the deep part (*m. coracobrachialis profundus*) and middle part (*m. coracobrachialis medius*) arise from the coracoid process on the shoulder blade. The former part inserts into the humeral neck, while the latter part attaches more distally at the medial side of the humeral shaft (**Figure 31**).
- *M. brachialis*: The lateroproximal aspect of the humerus is the site of origin of this muscle, that follows the brachial sulcus of the humerus to insert into the medial coronoid process of the ulna (**Figure 31**).

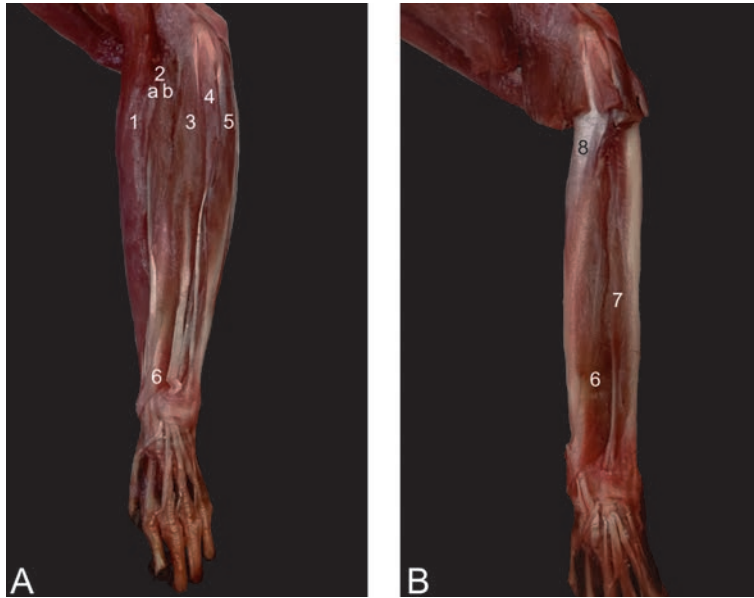
## 5.12 Muscles of the forearm

### 5.12.1 Extensor musculature

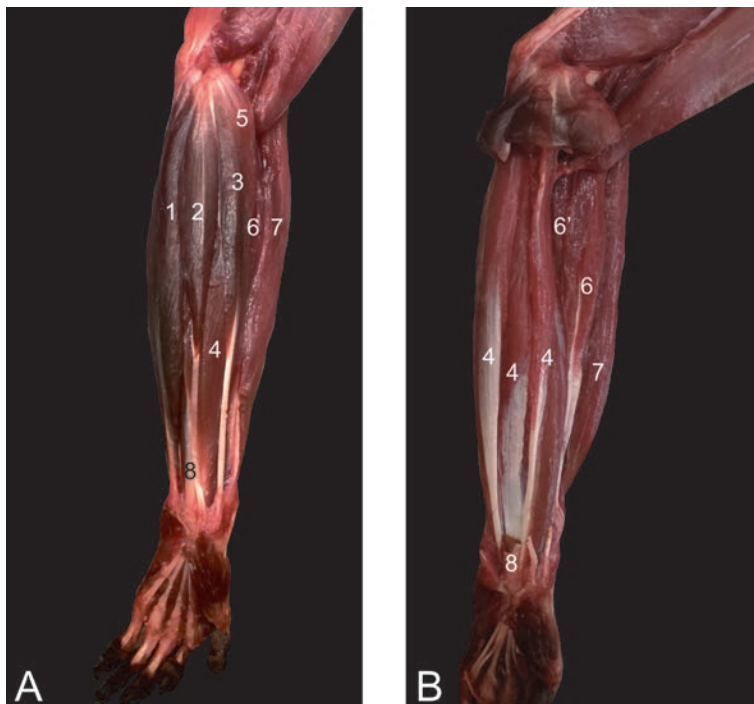
- M. extensor carpi radialis (longus et brevis): The lateral epicondylar crest of the humerus forms the origin of this muscle. The insertion is into the base of the 2nd metacarpal bone (long part) and 3rd metacarpal bone (short part) (**Figures 32–34**).
- M. extensor carpi ulnaris: This muscle arises from the lateral epicondyle of the humerus and is inserted into the base of the 5th metacarpal bone (**Figures 32 and 34**).
- M. extensor digitorum communis: This muscle arises from the lateral epicondyle of the humerus and inserts by means of four tendons into the distal phalanges of digits II to V (**Figures 32 and 34**).
- M. extensor digiti:
  - primi longus (m. extensor pollicis longus): The origin is cranio-laterally on the proximal half of the ulna and inserts into the distal phalanx of the pollex (**Figure 34**).
  - secundi (m. extensor indicis) et tertii: This muscle arises distal to the former muscle. At the level of the carpus, the tendon splits into two tendons, one to the proximal phalanx of the 2nd digit and one for the 3rd digit (**Figures 32 and 34**).
  - quarti: From the lateral humeral epicondyle to proximal phalanx of the 4th digit (**Figures 32 and 34**).
  - quinti: From the lateral humeral epicondyle to the middle phalanx of the 5th digit (**Figures 32 and 34**).

### 5.12.2 Flexor musculature

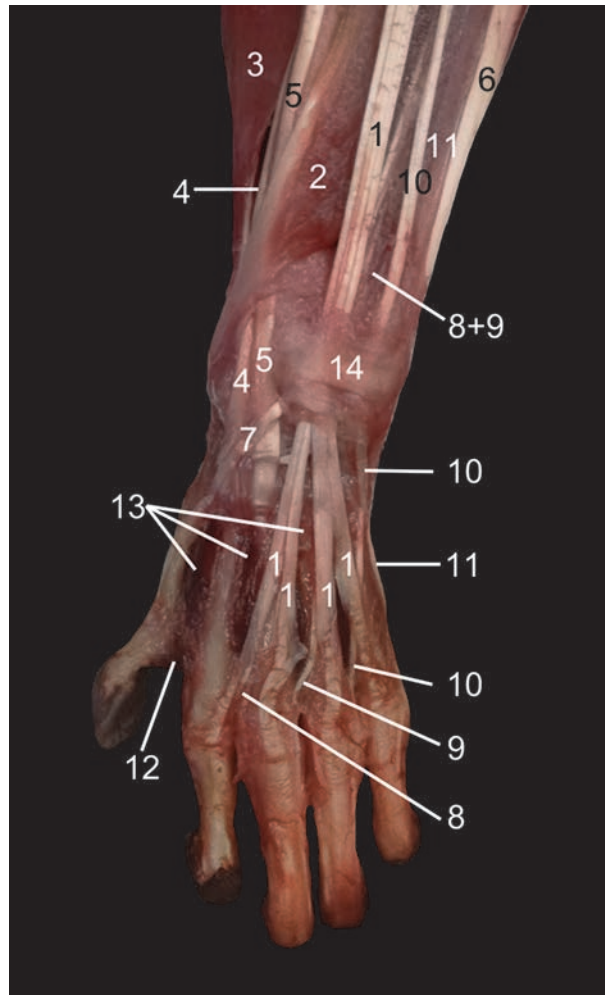
- M. flexor carpi radialis: This muscle arises from the medial humeral condyle and inserts into the base of the 2nd metacarpal bone (**Figures 33 and 35**).
- M. flexor carpi ulnaris: This muscle also arises from the medial humeral epicondyle. It attaches to the pisiform carpal bone (**Figures 33 and 35**).
- M. palmaris longus: This muscle is situated in between the two aforementioned muscles. It also originates at the medial humeral epicondyle. It presents a distal aponeurosis (aponeurosis palmaris) which lies superficially at the palmar side of the hand (**Figures 33 and 35**).
- M. brachioradialis: This muscle runs from the lateral humeral epicondyle to the distal aspect of the radius (**Figures 32–35**).
- M. flexor digitorum superficialis (m. flexor digitorum sublimis): This very thin muscle originates on the medial epicondyle of the humerus. Its four tendons insert on the base of the 2nd phalanx of digits I to IV (**Figures 33 and 35**).



**Figure 32.** Lateral view of the musculature of the left forearm. A: superficial layer with 1: brachioradialis muscle, 2a: long part of extensor carpi radialis muscle, 2b: short part of extensor carpi radialis muscle, 3: extensor digitorum communis muscle, 4: extensor digitorum quarti et quinti muscle, 5: extensor carpi ulnaris muscle, 6: abductor digiti primi longus muscle. B: deep layer with 6: abductor digiti primi longus muscle, 7: extensor digitorum secundi et tertii muscle, 8: supinator muscle.



**Figure 33.** Medial view of the musculature of the left forearm. A: Superficial layer with 1: m. flexor carpi ulnaris, 2: m. palmaris longus, 3: m. flexor carpi radialis, 4: m. flexor digitorum profundus, 5: m. pronator teres, 6: m. extensor carpi radialis longus, 7: m. brachioradialis. B: Deep layer with 4: m. flexor digitorum profundus, 6: m. extensor carpi radialis longus, 6': m. extensor carpi radialis brevis, 7: m. brachioradialis, 8: m. flexor digitorum superficialis.



**Figure 34.**

Dorsal view of the musculature of the left hand. 1: *m. extensor digitorum communis*, 2: *m. abductor digiti primi longus*, 3: *m. brachioradialis*, 4: *m. extensor carpi radialis longus*, 5: *m. extensor carpi radialis brevis*, 6: *m. extensor carpi ulnaris*, 7: *m. extensor digiti primi (pollicis) longus*, 8: *m. extensor digiti secundi*, 9: *m. extensor digiti tertii*, 10: *m. extensor digiti quarti*, 11: *m. extensor digiti quinti*, 12: *m. adductor digiti primi*, 13: *m. interosseous*, 14: *ligamentum carpi dorsale*.

- *M. flexor digitorum profundus*: This muscle arises from the proximal half of the ulna (*caput ulnare*) and the upper two-thirds of the radius (*caput radiale*). Five tendons arise, which are inserted into the palmar sides of the terminal phalanges of all five digits (**Figures 33 and 35**).
- *M. epitrochleoanconeus*: This short muscle runs from the medial humeral epicondyle to the olecranon.

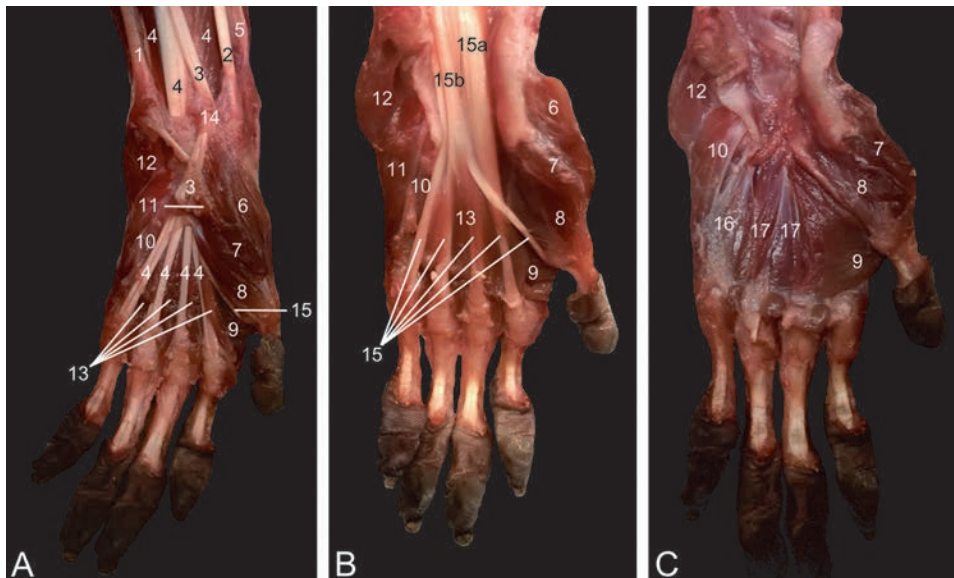
### 5.12.3 The pronators and supinators

- *M. pronator teres*: This pronator muscle of the forearm originates on the medial humeral epicondyle. It runs obliquely towards the middle third of the radius (**Figure 33**).

- M. pronator quadratus: This rectangular muscle can be found at the medial side of the forearm, running from the proximal ulna to the distal radius.
- M. supinator: The supinator of the forearm originates on the lateral humeral epicondyle. It runs obliquely towards the proximal half of the radius.

### 5.13 Muscles of the hand

- M. palmaris brevis: This short muscle, that lies directly subcutaneously, arises from the palmar aponeurosis and is inserted into the subcutis (Figure 35).
- M. abductor digiti primi (pollicis) longus: This muscle has origin at the proximolateral aspect of the ulna and the cranial side of the radius. It attaches to the proximal end of the metacarpal bone of the pollex (Figures 32 and 34).
- M. abductor digiti primi (pollicis) brevis: This muscle arises medially from the transverse carpal ligament. It is inserted into the base of the proximal phalanx of the pollex (Figure 35).
- M. flexor digiti primi (pollicis) brevis: This muscle lies just lateral to the former. It also starts on the transverse carpal ligament and is inserted into the base of the proximal phalanx of the pollex (Figure 35).



**Figure 35.** Palmar view of the musculature of the left hand. A: superficial layer, B: deeper layer, C: deepest layer. 1: m. flexor carpi ulnaris, 2: m. flexor carpi radialis, 3: m. palmaris longus with cut aponeurosis, 4: m. flexor digitorum superficialis, 5: m. brachioradialis, 6: m. abductor digiti primi brevis, 7: m. flexor digiti primi brevis superficialis, 8: m. flexor digiti primi brevis profundus, 9: m. adductor digiti primi, 10: m. flexor digiti quinti brevis, 11: m. abductor digiti quinti, 12: m. palmaris brevis, 13: mm. lumbricales, 14: ligamentum carpi palmare, 15: m. flexor digitorum profundus with 15a: caput radiale and 15b: caput ulnare, 16: m. opponens digiti quinti, 17: mm. contrahentes digitorum manus.

- *M. adductor digiti primi (pollicis)*: This muscle runs from the 2nd and 3rd metacarpal bones towards the proximal phalanx of the pollex. The proximal and distal parts of this muscle cannot be discerned (**Figures 34 and 35**).
- *M. opponens digiti primi (pollicis)*: This muscle lies below the short abductor of the thumb. It runs from the transverse carpal ligament to the 1st metacarpal bone.
- *M. abductor digiti quinti*: This muscle has origin on the transverse carpal ligament and the most lateral carpal bones. Insertion is into the proximal phalanx of the 5th digit (**Figure 35**).
- *M. flexor digiti quinti brevis*: This muscle runs somewhat more medial and superficial compared to the former. The insertion site is the same (**Figure 35**).
- *M. opponens digiti quinti*: This muscle lies deep compared to the abductor and flexor of the 5th digit. It insert along the entire length of the 5th metacarpal bone (**Figure 35**).
- *Mm. lumbricales manus*: These muscles, which are 4 in number, are very well developed. They arise from the medial side of the deep flexor tendons to digits II – V. They are inserted into the base of the proximal phalanx and the metacarpophalangeal joints (**Figure 35**).
- *Mm. contrahentes digitorum manus*: Origins are the proximal epiphyses of the 2nd and 3rd metacarpal bones. Insertion is into the proximal phalanges of the 2nd, 4th and 5th digits (**Figure 35**).
- *Mm. interossei manus*: These muscles form pairs of muscles that are present in each intermetacarpal cleft. They attach to the sides of the metacarpophalangeal joints (**Figure 34**).

## **5.14 Muscles of the hip region**

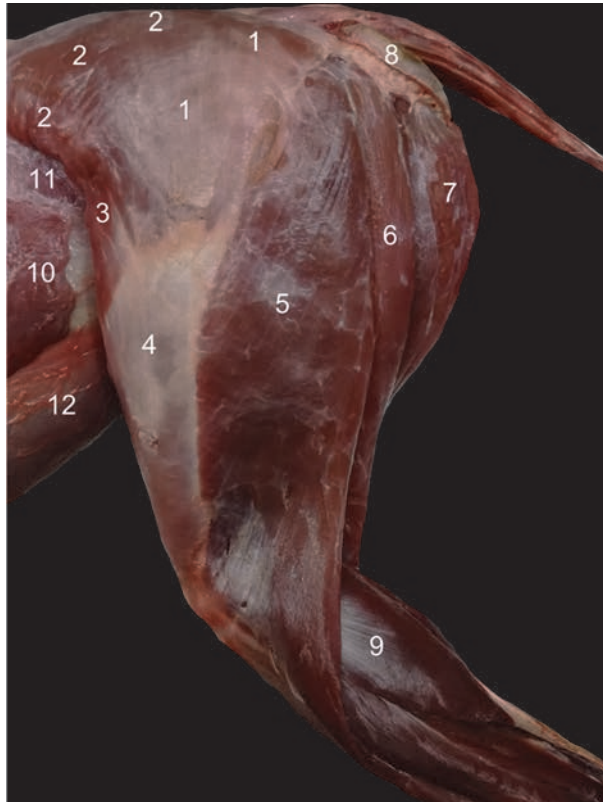
### *5.14.1 Extensor musculature*

- *M. gluteus superficialis (m. gluteus maximus)*: The superficial gluteus muscle arises from the lumbar fascia and the first three caudal vertebrae. The tendon is inserted into fascia lata and the greater trochanter of the femur (**Figures 25, 26 and 36**).
- *M. gluteus medius*: This deeper part of the gluteus musculature arises from the lateral surface of the wing of the ilium, the sacro-iliac joint and the first caudal vertebra. The large muscle is inserted into the greater trochanter of the femur (**Figures 26 and 36**).
- *M. gluteus profundus (m. gluteus minimus)*: This deepest gluteus muscle has its origin on the dorsal aspect of the ilium and inserts into the greater trochanter of the femur.

### *5.14.2 Flexor musculature*

- *M. psoas major*: The psoas major muscle arises from the ventral sides of the lumbar vertebrae. The muscle is inserted into the lesser trochanter of the femur (**Figure 29**).





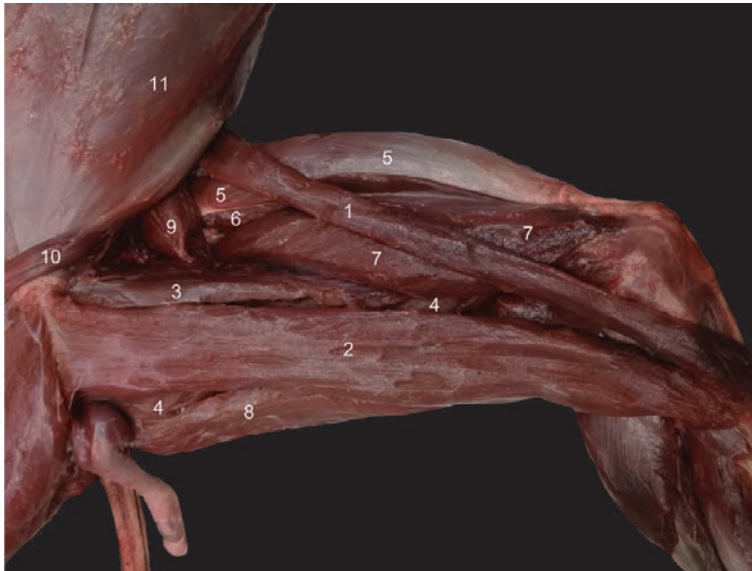**Figure 36.**

Lateral view of the left thigh musculature. 1: *m. gluteus superficialis*, 2: *m. gluteus medius*, 3: *m. tensor fasciae latae*, 4: *fascia lata*, 5: *m. biceps femoris*, 6: *m. semitendinosus*, 7: *m. semimembranosus*, 8: *callositas ischii*, 9: *m. gastrocnemius caput laterale*, 10: *m. obliquus externus abdominis*, 11: *m. obliquus internus abdominis*, 12: *m. rectus abdominis*.

- *M. psoas minor*: This psoas muscle lies ventromedial to the former. It originates from the ventral sides of the first four lumbar vertebrae and is inserted cranially on the pubic bone (*tuberculum m. psoas minoris*) (**Figure 29**).
- *M. iliacus*: The origin of this muscle is the medial aspect of the ilium. It first runs lateral to the psoas major and finally joins it to form the *m. iliopsoas* (**Figure 37**). This muscle has insertion into the lesser trochanter of the femur (**Figure 29**).
- *M. quadratus lumborum*: This muscle finds its origin on the crest and wing of the ilium. This thin quadrilateral muscle is inserted into the last rib and transverse processes of the lumbar vertebrae (**Figure 29**).

### 5.15 The adductors of the hind limb

- *M. sartorius*: This long, slender muscle arises from the cranioventral spine of the ilium. It inserts into the medial side of the proximal third of the tibia (**Figures 25, 37, and 39**).
- *M. gracilis*: This broad muscle starts from the pelvic symphysis and attaches to the craniomedial aspect of the proximal third of the tibia (**Figures 25, 37, and 39**).



**Figure 37.**

*Medial view of the left thigh musculature. 1: m. sartorius, 2: m. gracilis, 3: m. pectineus, 4: m. adductor, 5: m. rectus femoris, 6: m. vastus intermedius, 7: m. vastus medialis, 8: m. semimembranosus, 9: m. iliopsoas, 10: m. cremaster, 11: m. obliquus externus abdominis.*

- M. pectineus: This short, fusiform muscle runs from the pecten pubis to the medioproximal aspect of the femur (**Figures 25 and 37**).
- M. adductor (**Figure 37**):
  - longus: The origin of the long adductor muscle is the pelvic symphysis. It lies lateral (deep) to the gracilis muscle and inserts medially, halfway the femur (**Figure 25**).
  - magnus: This muscle is composed of two parts that individually attach to the proximocaudal part of the femoral diaphysis. Their origins are the pelvic symphysis and tuber sciatic tuberosity, respectively.
  - brevis: The small adductor muscle starts just ventral to the foramen obturatum and attaches to the medioproximal aspect of the femur.

### 5.16 The supinators of the hind limb

- M. obturatorius externus: This muscle arises from the obturator membrane and the bone surrounding the obturator foramen, at its dorsal side. The tendon is inserted into the intertrochanteric fossa.
- M. obturatorius internus: This muscle also arises from the obturator membrane and the bone surrounding the obturator foramen, albeit at its ventral side. The insertion is at the medial side of the greater trochanter of the femur.
- Mm. gemelli: The gemelli originate from the ischium. Their tendons are inserted into the tendon of the m. obturatorius internus.
- M. quadratus femoris: This muscle runs from the sciatic tuberosity to the lesser femoral trochanter.

## 5.17 The extensors of the knee

- M. quadriceps: Intramuscular injections can be administered in this muscle that consists of four parts. All insert into the basis of the patella.
  - M. rectus femoris: The origin is just dorsal to the acetabulum (**Figures 25 and 37**).
  - M. vastus lateralis: This part of the quadriceps muscle arises from the greater trochanter of the femur.
  - M. vastus medialis: This muscle arises from lesser trochanter of the femur (**Figure 37**).
  - M. vastus intermedius (formerly described as the m. crureus): This deep muscle arises from the proximal three-fourths of the shaft of the femur (**Figure 37**).
- M. tensor fasciae latae: The origin of this muscle is the ilium and the fascia overlying the gluteus medius muscle. The muscle is inserted into the fascia lata (**Figures 25, 26, and 36**).

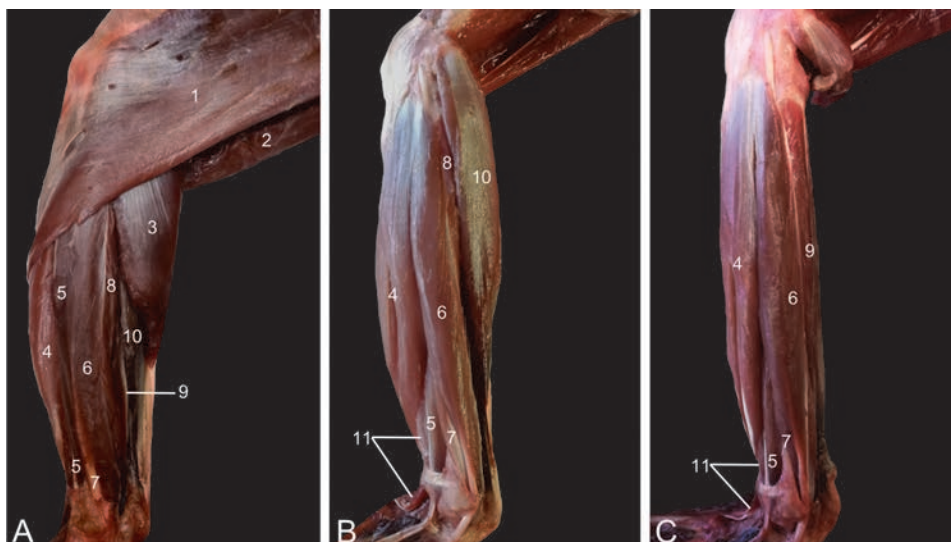
## 5.18 The hamstrings and flexors of the knee

- M. biceps femoris: The biceps femoris muscle arises from the ischial tuberosity. The muscle forms a thin aponeurosis that is inserted into the fascia cruris (**Figures 25, 26, and 36**). This muscle can be used to administer intramuscular injections.
- M. semitendinosus: This muscle also arises from the sciatic tuberosity, just caudal to the biceps femoris muscle. The tendon lies superficial to the semimembranosus muscle and attaches to the medial surface of the tibial shaft, deep to the tendon of the gracilis muscle (**Figures 26, 36, and 38**).
- M. semimembranosus: The semimembranosus muscle consists of the smaller and more lateral semimembranosus proprius muscle and larger and more medial semimembranosus accessories muscle. The origins of both is caudal on the sciatic tuberosity. The semimembranosus proprius muscle is inserted medially on the tibial tuberosity, while the accessory semimembranosus muscle is broadly inserted more proximally, at the level of the medial femoral condyle (**Figures 25, 26, 36, 37, and 39**).
- M. popliteus: This muscle is the only intrinsic flexor muscle of the knee. The fan-shaped muscle is located at the caudal side of the proximal tibial shaft. Its tendon inserts into the popliteal fossa of the femur (**Figure 39**).

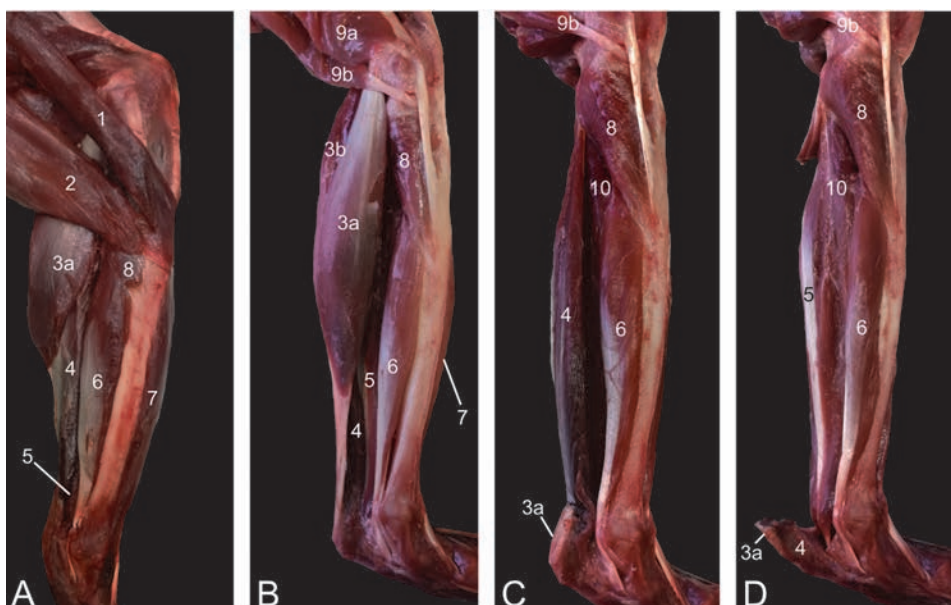
## 5.19 Muscles of the lower leg

### 5.19.1 *The flexors of the tarsal joint and extensors of the digits*

- M. tibialis cranialis: This muscle arises from the lateral condyle of the tibia and from the upper two-thirds of its shaft. Two bellies can be observed. The medial tendon attaches to the 1st tarsal bone, whereas the lateral tendon is inserted into the head of the 1st metatarsal bone (**Figures 38–40**).

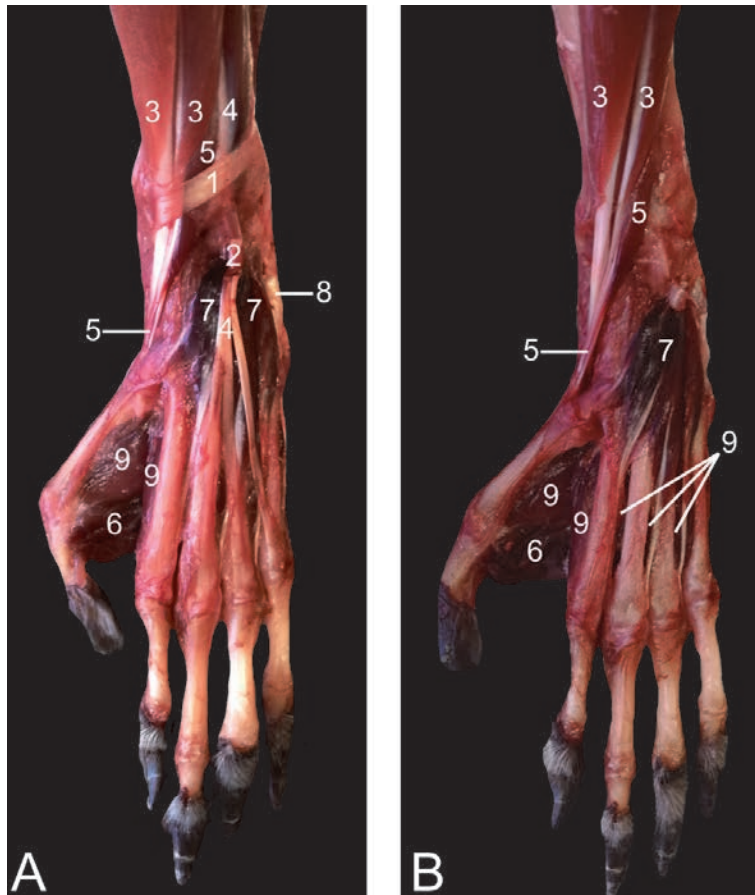


**Figure 38.** Lateral view of the lower leg musculature (left hind limb). A: superficial layer, B: deeper layer, C: deepest layer. 1: *m. biceps femoris*, 2: *m. semitendinosus*, 3: *m. gastrocnemius caput laterale*, 4: *m. tibialis cranialis*, 5: *m. extensor digitorum longus*, 6: *m. fibularis longus*, 7: *m. fibularis brevis*, 8: *m. tibialis caudalis*, 9: *m. plantaris*, 10: *m. soleus*, 11: *m. extensor digiti primi (hallucis) longus*.



**Figure 39.** Medial view of the lower leg musculature (left hind limb). A: superficial layer, B: deeper layer, C: deep layer, D: deepest layer. 1: *m. sartorius*, 2: *m. gracilis*, 3a: *m. gastrocnemius caput mediale*, 3b: *m. gastrocnemius caput laterale*, 4: *m. soleus*, 5: *m. plantaris*, 6: *m. flexor digitorum tibialis*, 7: *m. tibialis cranialis*, 8: *m. popliteus*, 9a: *m. semimembranosus accessorius*, 9b: *m. semimembranosus proprius*, 10: *m. tibialis caudalis*.

- *M. extensor digitorum longus*: The origins of this muscle are the lateral condyle of the tibia, and the fibular head. Three tendons arise at the level of the foot that are inserted into the middle and distal phalanges of the 2nd to 5th digits (Figures 38 and 40).



**Figure 40.**  
 Dorsal view of the musculature of the left foot. A: superficial layer, B: deep layer. 1: retinaculum proximalis, 2: retinaculum distalis, 3: *m. tibialis cranialis* (two bellies), 4: *m. extensor digitorum longus*, 5: *m. extensor digiti primi (hallucis) longus*, 6: *m. adductor digiti primi (hallucis)*, 7: *m. extensor digitorum et digiti primi (hallucis) brevis*, 8: *m. abductor digiti quinti*, 9: *mm. interossei*.

- *M. extensor digiti primi (hallucis) longus*: This very thin muscle that lies deep to the former muscle obtains its origin from the medial side of the fibular diaphysis. The tendon is inserted into the terminal phalanx of the hallux (**Figures 38 and 40**).
- *M. fibularis longus*: This muscle has its origin on the fibula and proximal epiphysis of the fibula. The tendon crosses the lateral malleolus and inserts into the plantar side of the 1st metatarsal bone, thus crossing the plantar side of the foot (**Figure 38**).
- *M. fibularis brevis*: This muscle arises from the lower two-thirds of the shaft of the fibula. Insertion is into the metatarsal bone of the 5th digit (**Figure 38**).
- *M. fibularis digiti quinti*: This muscle present a similar topography as the former muscle, but inserts into the distal phalanx of the 5th digit.

#### 5.19.2 The extensors of the tarsal joint and flexors of the digits

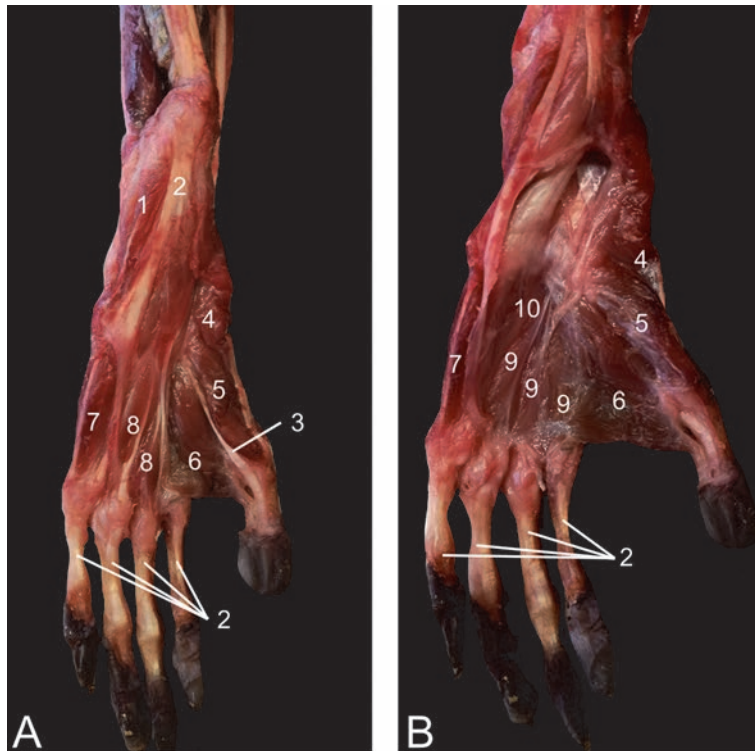
- *M. gastrocnemius*: The lateral and medial heads of the gastrocnemius muscle arise from the lateral and medial epicondyle of the femur, respectively. A

sesamoid bone is present in each tendon of origin (ossa sesamoidea m. gastrocnemii or fabellae). The tendo Achilles attaches to the tuber calcanei (Figures 25, 26, 36, 38, and 39).

- M. soleus: This thin muscle arises from the head of the fibula. Its tendon fuses with the gastrocnemius muscle (Figures 38 and 39).
- M. plantaris: The thin plantaris muscle has its origin on the lateral condyle of the femur. Its thin tendon lies on the medial side of the tendo Achilles and is inserted into the plantar fascia (Figures 38 and 39).
- M. flexor digitorum (longus) tibialis (can be considered as the m. flexor digitorum superficialis): This muscle arises halfway from the caudal side of the tibia. The tendon crosses the medial malleolus and splits to attach to the plantar sides of the distal phalanges of digits II to V (Figure 41).
- M. flexor digitorum (longus) fibularis (can be considered as the m. flexor digitorum profundus): This muscle lies deep to the former. It arises from the caudomedial aspect of the fibula, the interosseous membrane between the tibia and fibula, and the distal part of the tibia. The tendon travels along the plantar side of the tarsal joint, then splits in three tendons, one for digit I, III and IV (Figure 41).
- M. tibialis caudalis: This muscle arises from the caudal side of the tibia. Its tendon crosses the medial malleolus and inserts into the plantar sides of the metatarsal bones of digits II to IV (Figures 38 and 39).

## 5.20 Muscles of the foot

- M. flexor digitorum brevis: The superficial head has its origin on the tuber calcanei. This head forms the short flexor of digit II as it inserts into its middle phalanx. The deep head arises from the flexor digitorum tibialis tendon, at the level of the medial malleolus. The three tendons are inserted into the base of the middle phalanx of digits III to V.
- M. abductor digiti primi (hallucis): This muscle starts from the calcaneus and inserts into the plantar side of the proximal phalanx of the hallux (Figure 41).
- M. flexor digiti primi (hallucis) brevis: Two heads originate from the plantar side of the tarsus and insert into the proximal phalanx of the hallux (Figure 41).
- M. extensor digitorum et digiti primi (hallucis) brevis: This dorsally located muscle starts at the calcaneus and sends four tendons towards distal phalanx of digits I to IV (Figure 40).
- M. adductor digiti primi (hallucis): This broad muscle has origin at the metatarsal bones of the 2nd and 3rd digits. The proximal phalanx of the hallux is the insertion site (Figures 40 and 41).
- M. abductor digiti quinti: This muscle runs from the tuber calcanei towards the proximal phalanx of the 5th digit (Figure 40).



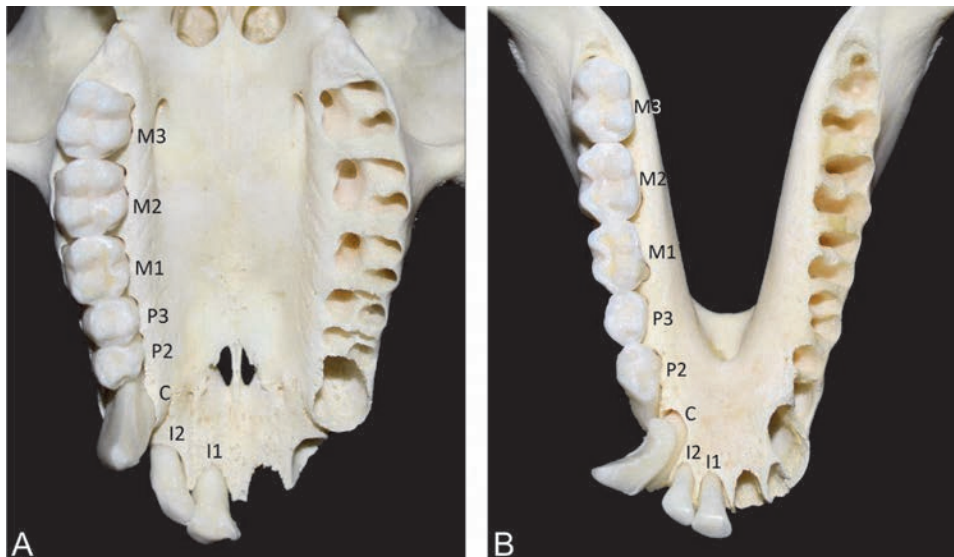
**Figure 41.**  
 Plantar view of the musculature of the left foot. A: middle layer, B: deep layer. 1: *m. quadratus plantae*, 2: *m. flexor digitorum (longus) tibialis*, 3: *m. flexor digitorum (longus) fibularis* (tendon to digit I), 4: *m. abductor digiti primi (hallucis)*, 5: *m. flexor digiti primi (hallucis) brevis*, 6: *m. adductor digiti primi (hallucis)*, 7: *m. flexor digiti quinti brevis*, 8: *mm. lumbricales*, 9: *mm. contrahentes digitorum pedis*, 10: *mm. interossei*.

- *M. abductor ossis metatarsi quinti*: This inconsistently present muscle runs lateral from the former muscle and inserts into the metatarsal bone of the 5th digit.
- *M. flexor digiti quinti brevis*: This muscle has origin at the tendon of the fibularis longus muscle at the level of the metatarsal bone of the 5th digit. It inserts at the proximal phalanx of the 5th digit (**Figure 41**).
- *M. quadratus plantae*: The origin is on the lateral side of the calcaneus. It splits into several tendons that insert into the tendons of the flexor digitorum longus muscles (**Figure 41**).
- *Mm. lumbricales pedis*: Four fine muscle strands find their origins deep to the flexor digitorum brevis muscle. They run medial to the metatarsal bones of the 2nd to 5th digits to insert into their proximal phalanges (**Figure 41**).
- *Mm. contrahentes digitorum pedis*: These muscles have a single aponeurosis in common at the level of the fibularis longus muscle. Three muscular bands originate from here to insert into the proximal phalanges of the 2nd, 4th and 5th digit (**Figure 41**).
- *Mm. interossei pedis*: These muscles form pairs of muscles that are present in each intermetatarsal cleft. They attach to the sides of the metatarsophalangeal joints (**Figures 40 and 41**).

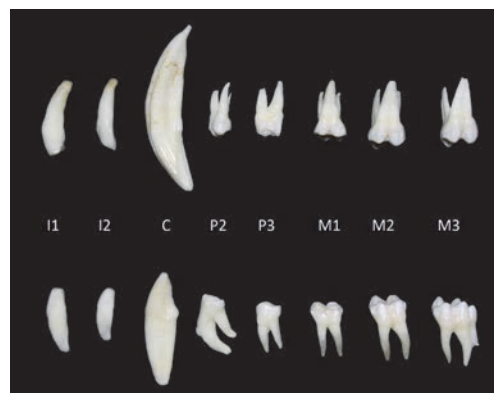
## 6. Splanchnology

### 6.1 Dentition

The rhesus monkey is omnivorous and mainly feeds on fruit, vegetables, insects and small mammals. Its dentition is very similar to that of humans as it also presents 32 teeth of which two incisors, one canine, two premolars and three molars in each quadrant. The teeth are of the brachydont type, thus with typical crowns and roots. The canines are more pronounced in the male compared to the female rhesus monkey. Furthermore, the premolars and molars are of the bunodont type, thus with typical cusps. The number of roots is one for the incisors and the canines, two for the premolars and molars of the mandible, and three for the premolars and molars of the maxilla (Figures 42 and 43).



**Figure 42.** Ventral view of the upper jaw (A) and dorsal view of the lower jaw (B) with the teeth unilaterally present. I1: dens incisivus primus, I2: dens incisivus secundus, C: dens caninus, P2: dens premolaris secundus, P3: dens premolaris tertius, M1: dens molaris primus, M2: dens molaris secundus, M3: dens molaris tertius.



**Figure 43.** Dentition of the rhesus monkey. Upper panel: teeth of the right upper jaw after extraction. Lower panel: teeth of the right lower jaw after extraction. Notice the clear distinction between the crowns and roots, and the number of roots.

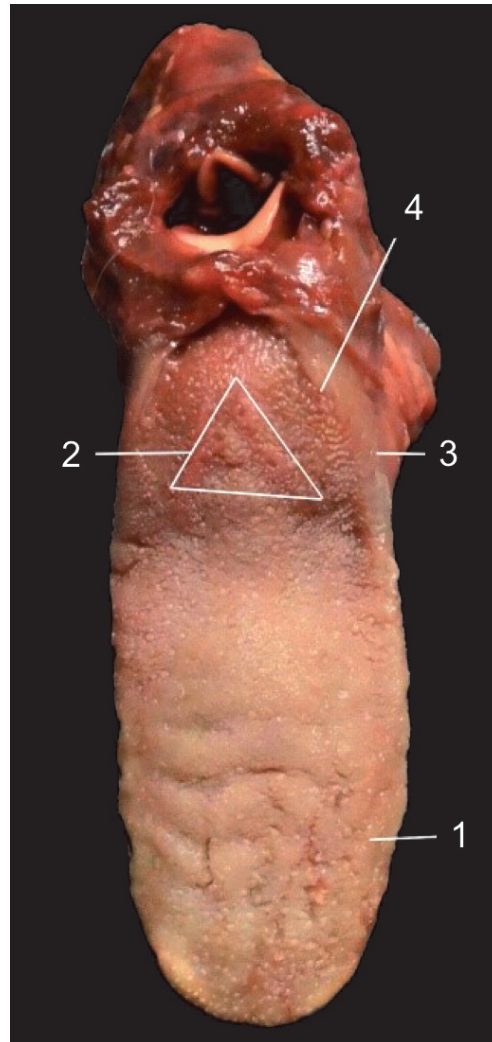


## 6.2 Oral cavity and tongue

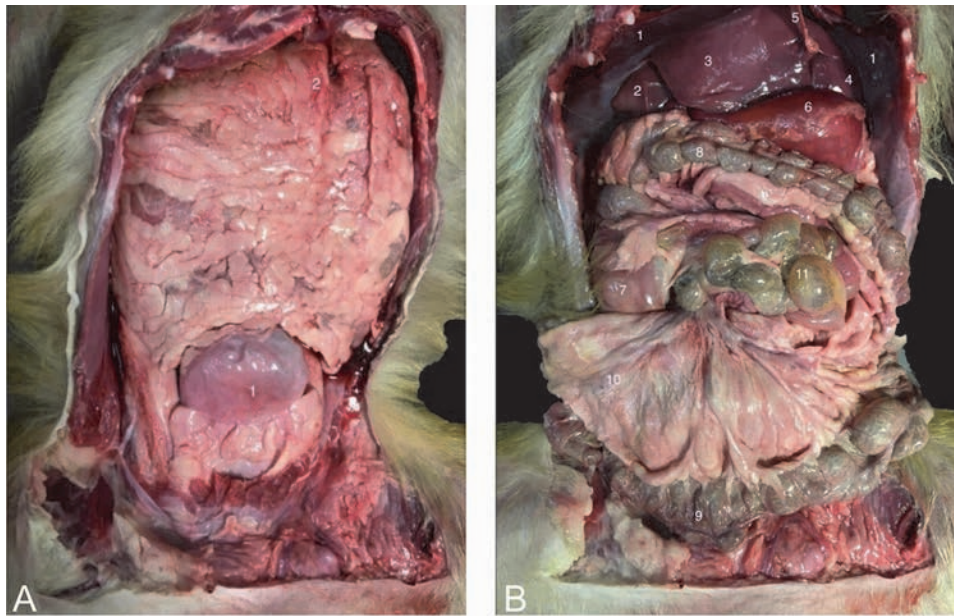
It is worthwhile to mention that the rhesus monkey possesses a pair of cheek pouches [12]. The tongue plays a pivotal role in digestion and vocalization. The muscles that are responsible for the lingual movements are discussed in section 5.4. The dorsal mucosa of the tongue presents several types of papillae. Gustatory papillae include the fungiform, circumvallate and foliate papillae. The filiform papillae are of the mechanical type (**Figure 44**).

## 6.3 Digestive organs

After a ventral midline incision through the abdominal wall has been made, the greater omentum (omentum majus) that covers the majority of abdominal organs can be observed (**Figure 45A**). It consists of the parietal and visceral sheets that enclose the virtual omental bursa. The parietal sheet is attached to the greater curvature of the stomach, while the visceral sheet is attached to the dorsal



**Figure 44.** Dorsal view of the tongue. 1: papillae fungiformes, 2: papillae circumvallatae, 3: papillae foliatae, 4: papillae filiformes.



**Figure 45.**  
*Ventral view of the abdominal cavity after a ventral midline incision was performed. A: The omentum majus is still present with 1: urinary bladder, 2: parietal sheath of the omentum majus. B: The omentum majus is excised with 1: diaphragm, 2: lobus hepatis dexter lateralis, 3: lobus hepatis dexter medialis, 4: lobus hepatis sinister medialis, 5: ligamentum falciforme, 6: curvatura major of the stomach, 7: cecum, 8: colon transversum, 9: colon descendens, 10: mesocolon, 11: jejunum.*

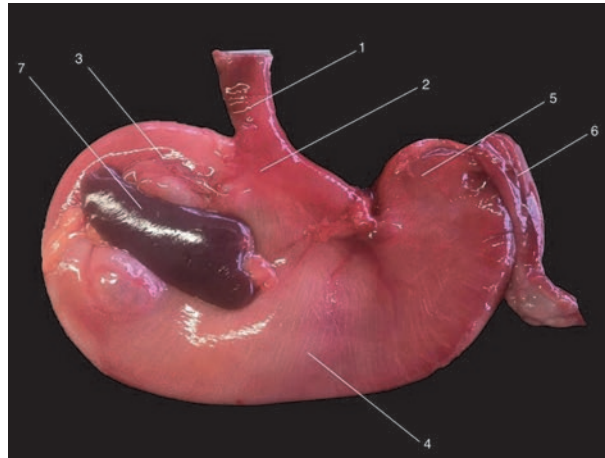
abdominal wall. The abdominal organs can only be observed after retraction or excision of the greater omentum (**Figure 45B**).

The esophagus presents a cervical, thoracic and abdominal segment. The cervical segment lies at the left side of the trachea. It bends to the right side of the body when reaching the thorax and deviates to the left side again to perforate the diaphragm (hiatus oesophageus). Its muscular layer is composed of an outer layer of longitudinally orientated fibers and an inner layer of circular fibers that enable peristalsis. The abdominal segment contains smooth muscle cells, while the other two segments present striated muscle fibers. The esophagus finally enters the stomach a few centimeters caudal to the diaphragm. Here, the cardiac sphincter is located. Relaxation of this sphincter and antiperistalsis in the esophagus allow for vomiting.

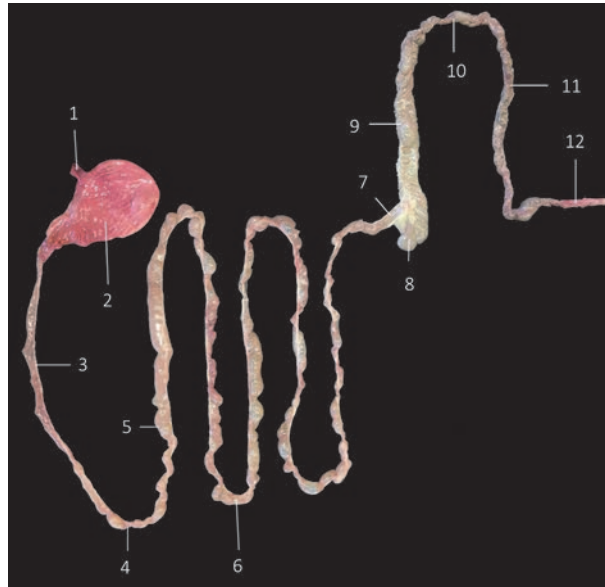
The stomach (**Figure 46**) consists of the fundus, the body, the pyloric canal and the pyloric antrum. The fundus is large and extends cranially left to the esophagus. The corpus is continuous with the esophagus and cannot be delineated from the fundus by any anatomical landmark. The pyloric antrum is continuous with the corpus. It can be distinguished from the body by its smaller diameter. The narrow short tube that follows is the pyloric canal that ends at the pyloric sphincter.

The reddish spleen is tongue-shaped and lies at the left side of the abdomen. It is connected to the stomach by means of the gastro-splenic ligament (**Figure 46**). The spleen is, however, a lymphoid organ.

The isolated intestinal tract of the rhesus monkey is presented in **Figure 47**. The small intestine measures approximately 175 cm in length and is composed of the duodenum, the jejunum and the ileum. The duodenum presents a long descending part (duodenum pars descendens/duodenum descendens) that is located at the right side of the abdomen, a short transverse part (duodenum pars transversa/duodenum transversum) in which the chyme travels from right to left in the caudal half of the abdominal cavity, and a short ascending part (duodenum pars



**Figure 46.**  
*Dorsal view of the stomach with the spleen attached. 1: oesophagus, 2: pars cardiaca, 3: fundus ventriculi, 4: corpus ventriculi, 5: pars pylorica, 6: pars cranialis duodeni, 7: lien.*

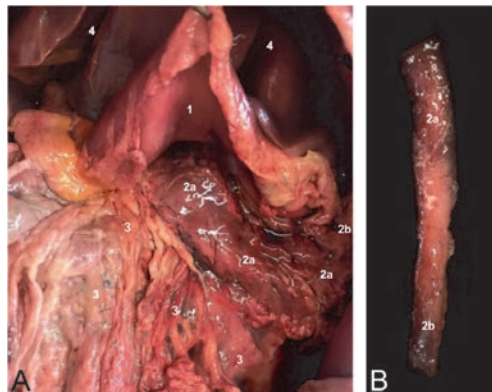


**Figure 47.**  
*Isolated intestinal tract. 1: oesophagus, 2: stomach, 3: duodenum descendens, 4: duodenum transversum, 5: duodenum ascendens, 6: jejunum, 7: ileum, 8: caecum, 9: colon ascendens, 10: colon transversum, 11: colon descendens, 12: rectum.*

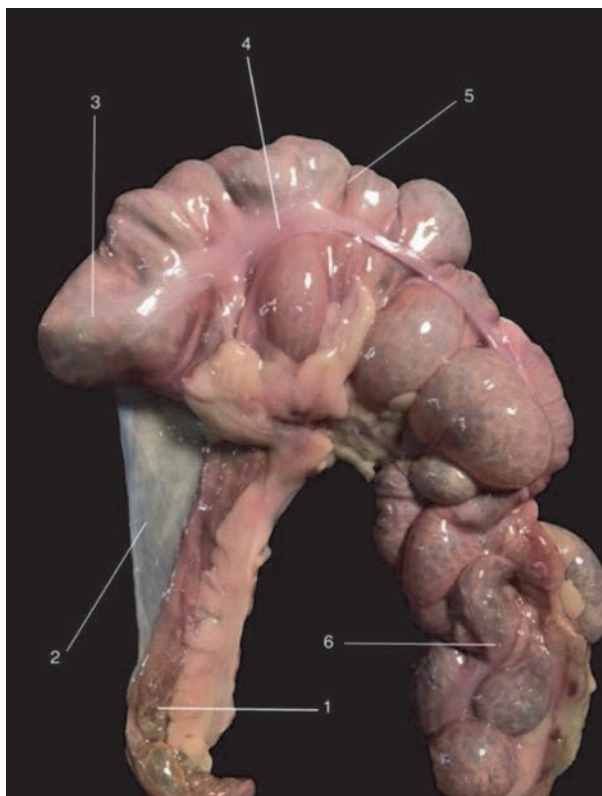
ascendens/duodenum ascendens) at the left side of the abdomen. The basis of the mesentery lies in the middle of the J-shaped duodenum. The common bile duct (ductus choledochus) and the pancreatic ducts (i.e. ductus pancreaticus and ductus pancreaticus accessorius) enter the descending part of the duodenum at 1/3 of its length. The accessory pancreatic duct enters the duodenum separately on the minor duodenal papilla, whereas the common bile duct and the principal pancreatic duct join to terminate on the major duodenal papilla. Within the mesoduodenum descendens, the tail or lobus dexter of the pancreas is found. This organ measures approximately 12 cm by 2 cm. Its body (corpus pancreatis) and left lobe (lobus sinister pancreatis) lie within visceral sheet of the greater omentum against the

stomach and in the mesocolon ascendens (**Figure 48**). The jejunum presents several loops and continues as the ileum that is anatomically defined as that segment of the small intestine that is attached to the cecum by means of the plica ileocecalis. The ileum finally enters the cecum (ostium ileocecale).

The large intestine measures approximately 63 cm in length and consists of the cecum, colon and rectum. The cecum can be found at the junction between the ileum and colon at the right side of the abdomen (**Figure 45B**). The cecum (**Figure 49**) is relatively large, measures 7 cm in length and lacks an appendix.



**Figure 48.** Pancreas of the rhesus monkey in situ (A) and ex corpore (B) with 1: corpus ventriculi, 2a: lobus pancreatis sinister, 2b: lobus pancreatic dexter, 3: omentum majus paries profundus, 4: hepar.



**Figure 49.** Isolated cecum. 1: ileum, 2: plica ileocecalis, 3: apex ceci, 4: tenia, 5: corpus ceci, 6: colon ascendens.

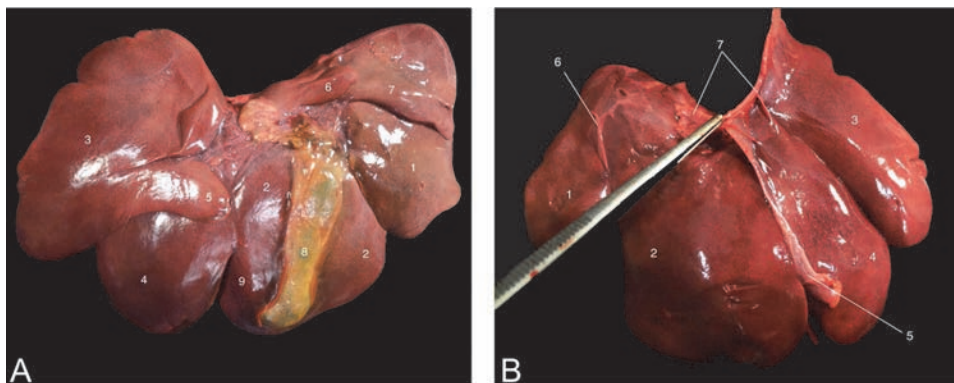
Ventral and dorsal teniae that consist of smooth muscle fibers are present. They give origin to the several sacculations called haustra. The U-shaped colon consists of the ascending part (colon pars ascendens/colon ascendens), the transverse part (colon pars transversa/colon transversum) and the descending part (colon pars descendens/colon descendens). Its total length is approximately 46 cm. It presents two teniae that give origin to haustra. The descending colon travels along the left side of the abdomen and passes insensibly into the rectum that is approximately 10 cm long and is defined as that segment of the large intestine that is located within the pelvic cavity.

The liver lies most cranial in the abdomen (**Figure 45B**). It measures approximately 15 cm by 10 cm. Its diaphragmatic side is located against the diaphragm while its visceral side faces the viscera, in particular the stomach. The esophagus runs in a fissure between the left and the caudate lobes. The lobulation of the liver is presented in **Figure 50**. The falciform ligament runs from the umbilicus to the liver, in between the left and right liver lobes towards the diaphragmatic side. This side is attached to the diaphragm by means of the left and right triangular ligaments and the coronary ligament. At the visceral side, the gall bladder is lodged in between the quadrate lobe and the right medial lobe.

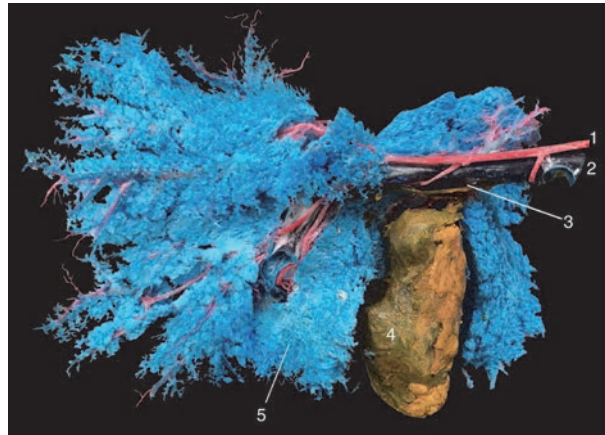
The common bile duct joins the principal pancreatic duct to enter the duodenum on the major duodenal papilla. The portal vein and hepatic artery enter the liver at the porta hepatis. Both vessels join at the level of the sinusoids. The blood within the sinusoidal system flows towards the central veins in the center of the liver lobules. These finally join to form multiple hepatic veins that ultimately drain into the caudal vena cava that runs at the dorsal margin of the liver (**Figure 51**).

#### 6.4 Urinary tract and adrenal glands

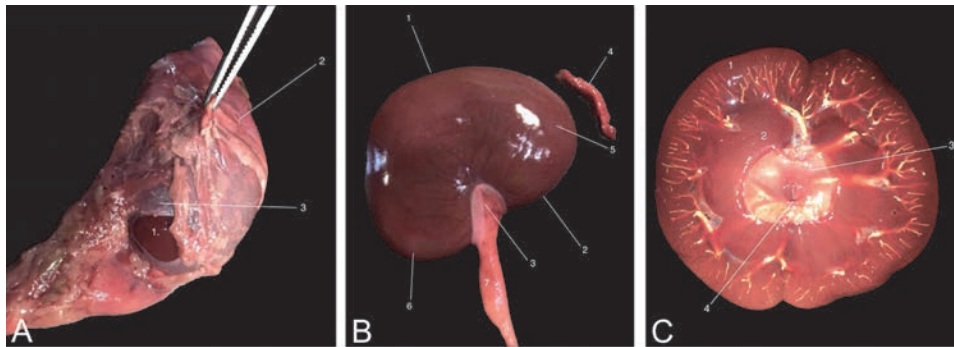
The brownish, bean-shaped kidneys measure approximately 5 cm by 3 cm. The lateral margin is convex while the medial margin is concave (**Figure 52B**). The cranial pole of the left kidney lies against the left lobe of the pancreas and lies more caudal than the right kidney that makes contact with the caudate lobe of the liver. As a result, this liver lobe presents a renal impression. An adipose capsule surrounds the kidneys that are overlaid with a fibrous capsule (**Figure 52A**). At the hilum, the



**Figure 50.**  
*Liver. A: visceral side with 1: lobus hepatis dexter lateralis, 2: lobus hepatis dexter medialis, 3: lobus hepatis sinister lateralis, 4: lobus hepatis sinister medialis, 5: processus anonus, 6: processus papillaris of lobus caudatus, 7: processus caudatus of lobus caudatus, 8: vesica biliaris, 9: lobus quadratus. B: diaphragmatic side with 1 – 4 idem as in A, 5: ligamentum falciforme, 6: ligamentum triangulare dextrum, 7: ligamentum coronarium.*



**Figure 51.**  
*Vascular corrosion cast of the liver, visceral side. 1: a. hepatica, 2: v. portae, 3: ductus choledochus, 4: vesica biliaris, 5: liver sinusoids.*

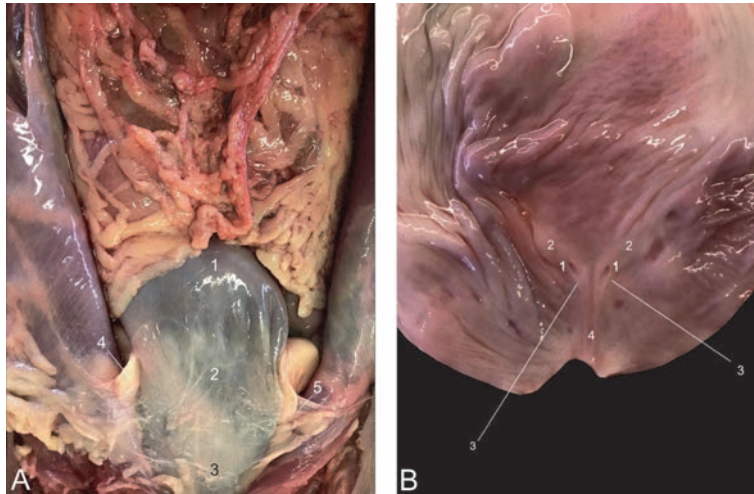


**Figure 52.**  
*A: Kidney (1) encapsulated by the capsula adiposa (2) and capsula fibrosa (3). B: Left kidney and adrenal gland ex corpore with 1: margo lateralis, 2: margo medialis, 3: hilus renalis, 4: glandula adrenalis, 5: polus cranialis, 6: polus caudalis, 7: ureter. C: Longitudinally sectioned kidney of which the blood vessels are filled with white latex rubber showing the cortex (1), medulla (2) and pelvis renalis (3).*

renal artery and renal vein enter the kidney, while the ureter leaves the kidney. After a longitudinal section of the kidney has been performed, the red cortex, brown medulla and the pale pelvis can be observed (**Figure 52C**).

The ureters lead the urine into the urinary bladder. Like the kidneys, they lie retroperitoneally. The abdominal part travels dorsal to the a. and v. ovarica or a. and v. testicularis. The pelvic part is located within the pelvic cavity and crosses the a. and v. iliaca externa ventrally. The intramural part travels obliquely within the wall of the urinary bladder.

The urinary bladder measures approximately 10 cm in length and 7 cm in width when filled with urine. It is attached to the abdominal wall by means of the median ligament (ligamentum vesicae medianum) and the left and right lateral ligaments (ligamenta vesicae lateralia). When the urinary bladder is cut longitudinally from the cervix, over the corpus to the apex, the mucosa can be studied. In the cervix, a left and right ostium ureteris is present on the respective columna ureterica. These distally elongate to form the left and right plica ureterica that distally join at the crista urethralis. As such, the trigonum vesicae is delineated. At the ostium urethrae internum, the urethra finds its origin (**Figure 53**).



**Figure 53.**  
*A: Urinary bladder in situ showing the apex vesicae (1), corpus vesicae (2), cervix vesicae (3), ligamentum vesicae laterale dextrum (4), ligamentum vesicae laterale sinistrum (5). B: Opened urinary bladder with indication of the ostia ureterica (1), columnae uretericae (2), plicae uretericae (3), crista urethralis (4).*

The female urethra is rather short as it opens ventrally into the vagina. This opening, the ostium urethrae externum, forms the border between the actual vagina and the vestibulum vaginae.

The adrenal glands are located within the adipose capsules of the kidneys, at their cranial poles (**Figure 57B**). They have a pink color, are lobulated and measure approximately 1 cm in length and a few mm in width (**Figure 52B**). The pink cortex produces mineralocorticosteroids, glucocorticosteroids and androgens. The brown medulla produces adrenalin and noradrenalin.

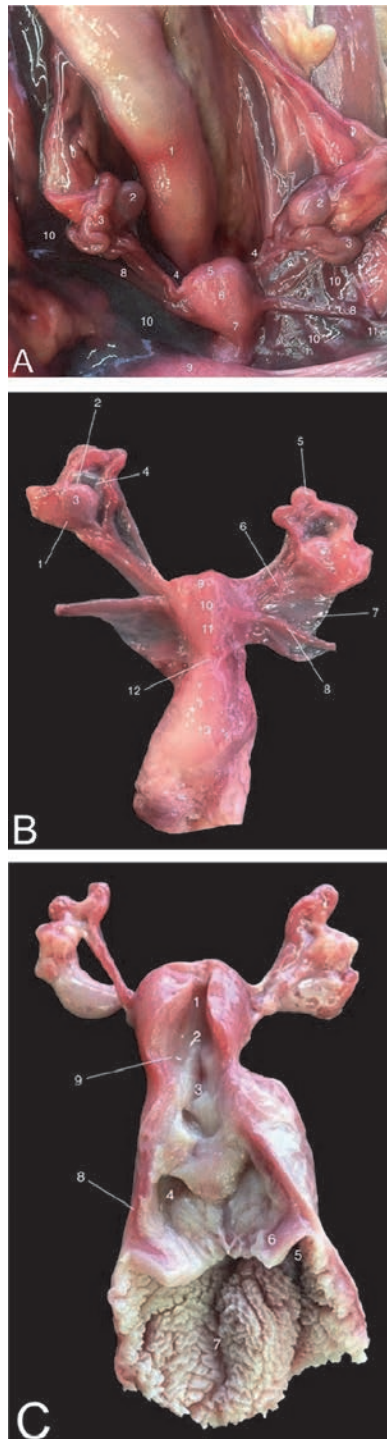
## 6.5 Female reproductive organs

The oval-shaped ovaries measure approximately 8 mm in length and 6 mm in width. At the margo mesovaricus, they are attached to the abdominal wall by means of the mesovarium. The margo liber is devoid of any ligaments. The ligamentum suspensorium ovarii connects the ovary with the lateral pelvic wall. The a. and v. ovarica lie within this ligament. The ligamentum ovarii proprium links the ovary to the uterus.

The coiled fallopian tubes or oviducts lie lateral to the ovaries. They are attached to the abdominal wall by means of the mesosalpinx. The tapered infundibulum that lies against the ovary presents fimbriae to collect the ovulated ovum. Fertilization takes place within the wider ampulla. The isthmus is narrower and opens up into the uterus.

The uterus of the rhesus monkey is of the simplex type. The fundus uteri, corpus uteri and isthmus uteri measure approximately 5 mm, 10 mm and 5 mm in length, respectively. The isthmus is in continuation with the canalis cervicis uteri that is the central canal within the cervix. The uterus is connected with the abdominal wall by means of the mesometrium. Together with the mesosalpinx and the mesovarium, it forms the broad uterine ligament. The ligamentum teres uteri attaches to the uterine body and travels through the inguinal canal. Terminal fibers of this ligament disperse into the vulva lips (**Figure 54**).

The vagina begins distal to the cervix. The portio vaginalis cervicis is the protrusion of the cervix into the vagina. The fornix vaginae is surrounding this structure. The vaginal mucosa is slightly keratinized and presents irregular folds. The vestibulum vaginae lies more distal and can be reached through the ostium vaginae.



**Figure 54.**

*A: The female reproductive tract in situ. 1: rectum, 2: ovarium, 3: tuba uterina, 4: isthmus tubae uterinae, 5: fundus uteri, 6: corpus uteri, 7: isthmus uteri, 8: ligamentum teres uteri, 9: vesical urinaria, 10: ligamentum latum uteri, 11: anulus inguinalis profundus. B: Isolated female reproductive tract. 1: margo liber ovaricae, 2: margo mesovaricus, 3: ovarium, 4: mesosalpinx, 5: tuba uterina, 6: ligamentum ovarii proprium, 7: ligamentum latum uteri, 8: ligamentum teres uteri, 9: fundus uteri, 10: corpus uteri, 11: isthmus uteri, 12: cervix, 13: vagina. C: Isolated female reproductive tract with opened uterus. 1: fundus uteri, 2: corpus uteri, 3: isthmus uteri, 4: canalis cervicis uteri, 5: fornix vaginae, 6: portio vaginalis cervicis, 7: vagina, 8: myometrium, 9: endometrium.*



The border between the vagina and the vestibulum is formed by the urethral opening. This perineal opening that is located ventral to the anal opening is enclosed by a pair of vulva lips.

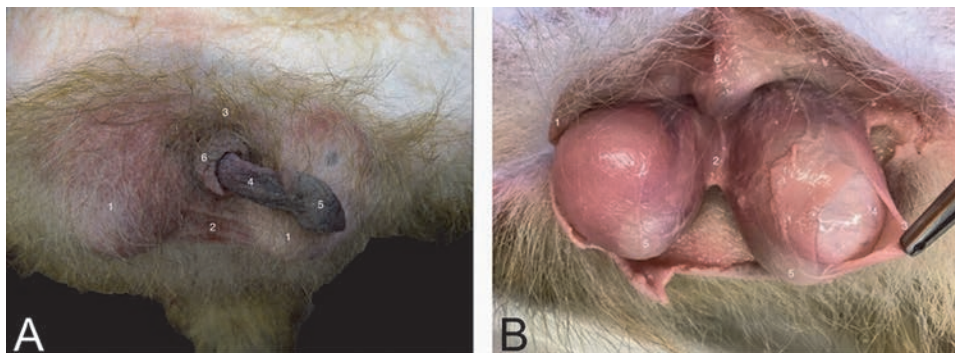
## 6.6 Male reproductive organs

The primary genital glands of the male rhesus monkey are the testes. These are located in the scrotum that lies caudoventrally in the perineal region (**Figure 2**). The scrotal skin is thin and has a limited number of hairs. This favors thermoregulation. The raphe scroti is visible in the midline and is continuous with the internal septum scroti that divides the scrotum in two separate cavities (cavum vaginale). These cavities can be reached by incision through the scrotal skin.

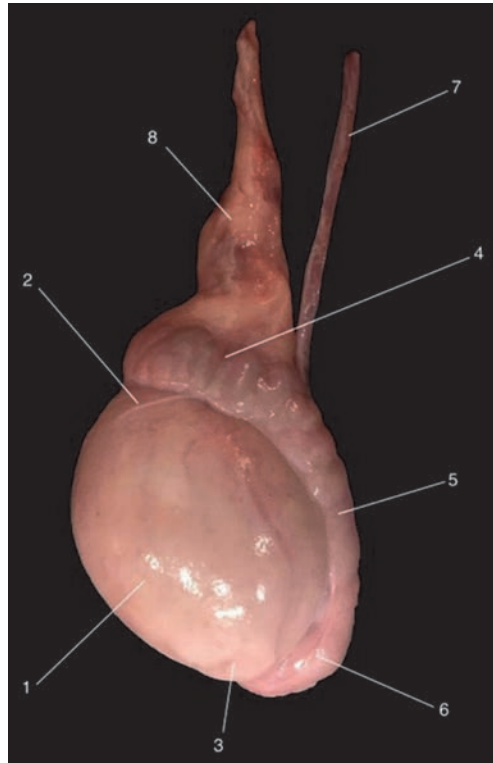
After transecting the wall of the vaginal cavity, i.e. the tunica vaginalis, the testis can be observed. This egg-shaped organ measures approximately 5 cm in length and 3 cm in width. It is encapsulated by the pale tunica albuginea that consists of dense connective tissue (**Figure 55**).

The a. testicularis is responsible for the testicular blood supply. It is surrounded by the venous plexus pampiniformis that cools the arterial blood. The ductus deferens is closely associated with the testicular blood vessels as they form the funiculus spermaticus that is enclosed by the tunica vaginalis. The ductus deferens is the continuation of the ductus epididymidis. This duct is extremely coiled, forming the epididymis, a solid structure adjacent to the testis. It can be divided into the caput, corpus and cauda epididymidis. The corpus lies against the medial side of the testis and is connected with this structure through the ligamentum testis proprium. The cauda epididymidis is attached to the tunica vaginalis by means of the ligamentum caudae epididymidis (**Figure 56**).

The ductus deferens leaves the vaginal cavity through the inguinal canal. After it has entered the abdominal cavity, it presents a caudal flexion dorsal to the ureter to flow into the pelvic part of the urethra. Along this urethral segment, three accessory glands are present. The ellipsoid, lobulated vesicular glands are large, 5–6 cm in length. They are positioned against the neck of the urinary bladder. Their caudal parts have contact with the prostate. This gland is spherical with a diameter of approximately 1 cm. Its body is positioned in between the caudal parts of the vesicular glands, at the dorsal side of the urethra. Some glandular tissue, however, surrounds the urethra. The bulbourethral glands are very small. They can be found caudolateral to the prostate gland (**Figure 57**).

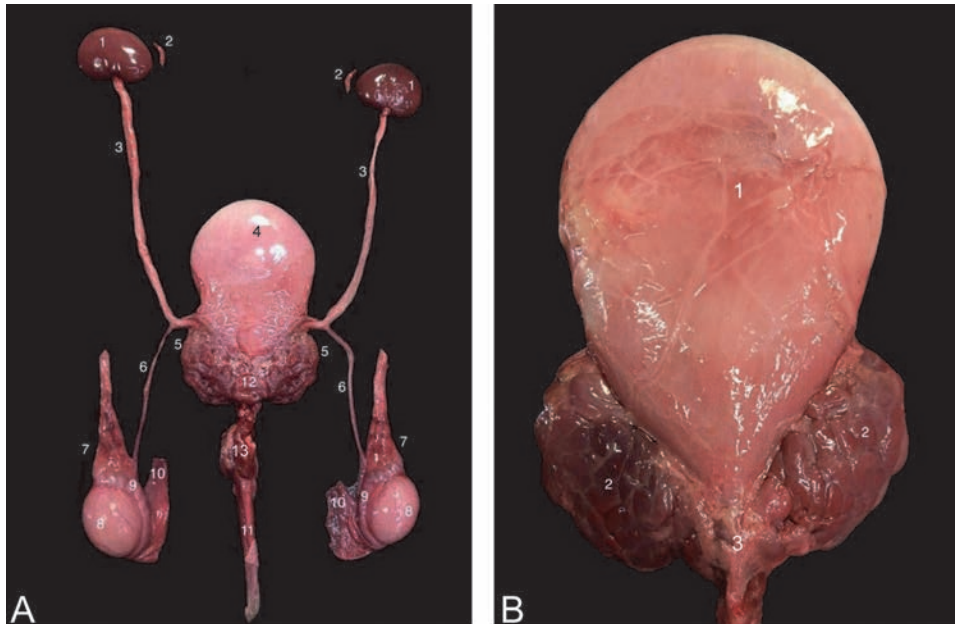


**Figure 55.**  
A: Penis and scrotum of the male rhesus monkey. 1: scrotum, 2: raphe scroti, 3: radix penis, 4: corpus penis, 5: glans penis, 6: preputium. B: Incision through the scrotal skin showing the testes. 1: scrotal skin, 2: septum scroti, 3: tunica vaginalis (partially incised), 4: tunica albuginea, 5: cauda epididymidis, 6: raphe scroti.



**Figure 56.**

*Left testis and epididymis of the rhesus monkey. 1: testis, 2: extremitas dorsalis, 3: extremitas ventralis, 4: caput epididymidis, 5: corpus epididymidis, 6: cauda epididymidis, 7: ductus deferens, 8: plexus pampiniformis.*



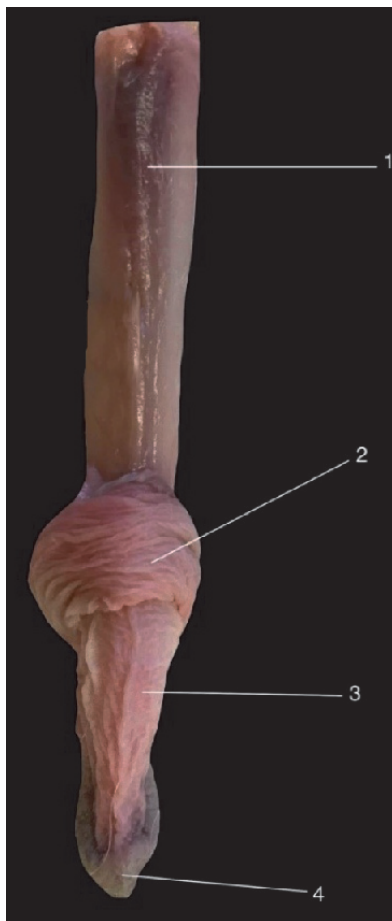
**Figure 57.**

*A: Ventral view of the isolated male urogenital tract. 1: ren, 2: glandula adrenalis, 3: ureter, 4: vesical urinaria, 5: glandula vesicularis, 6: ductus deferens, 7: plexus pampiniformis, 8: testis, 9: epididymis, 10: tunica vaginalis, 11: penis, 12: prostata, 13: glandula bulbourethralis. B: Larger magnification of the urinary bladder (1) and the accessory genital glands comprising the glandula vesicularis (2) and the prostata (3).*

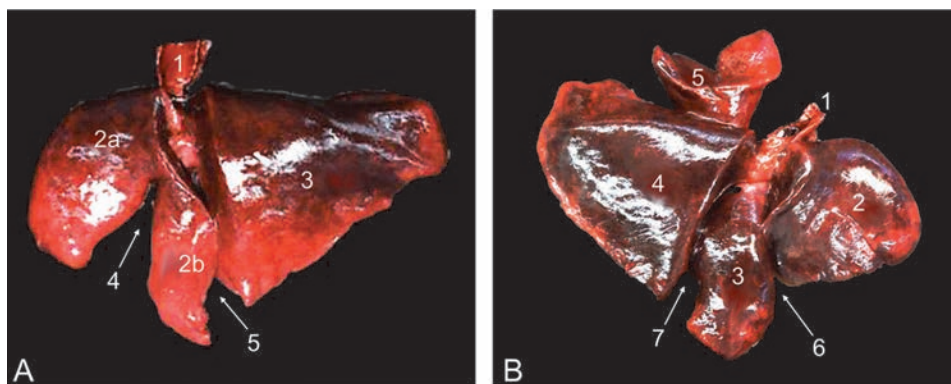
The penis of the rhesus monkey is of the cavernous type. When the penis is transected, the paired corpora cavernosa can be recognized by their pale brown color. Both are divided by the penile septum. The free part of the penis is approximately 5 cm long. It consists of the corpus penis and the glans penis. The urethral opening is located at the ventral side of the glans. The glans is covered by the preputium (**Figure 58**).

## 6.7 Lungs

The major intrathoracic organs are the lungs. The lungs can be examined by auscultation or medical imaging in the region from the 2nd to the 8th intercostal space. They consist of the left and right lungs that are separated by the mediastinum. Both are divided into lung lobes by fissures. The left lung consists of a cranial and caudal lung lobe that are separated by the interlobar fissure. The left cranial lung lobe is additionally divided into a cranial part and a caudal part by the cardiac scissure. The right lung has four lobes. The presence of the cranial and caudal interlobar fissures allows for the determination of the cranial, middle and caudal lung lobes. In addition, an accessory lung lobe is present in the right lung (**Figure 59**).



**Figure 58.**  
*Dorsal view of the penis. 1: radix penis with a. dorsalis penis, 2: preputium, 3: corpus penis, 4: glans penis.*



**Figure 59.**

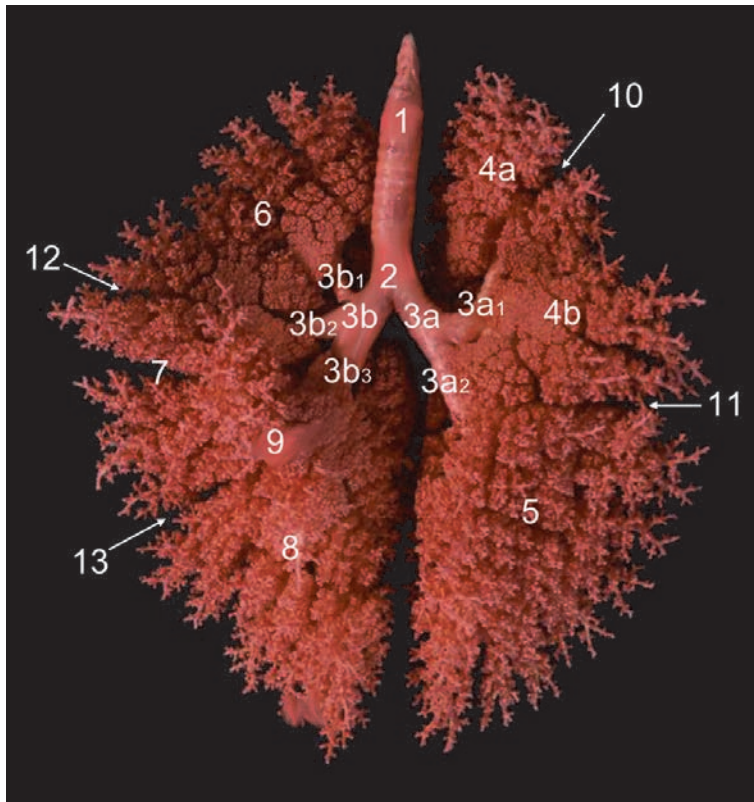
*Lungs. A: Left lateral view of the left lung with 1: trachea, 2a: lobus cranialis, pars cranialis, 2b: lobus cranialis, pars caudalis 3: lobus caudalis, 4: incisura cardiaca, 5: fissura interlobaris. B: Right lateral view of the right lung with 1: trachea, 2: lobus cranialis, 3: lobus medius, 4: lobus caudalis, 5: lobus accessorius, 6: fissura interlobaris cranialis, 7: fissura interlobaris caudalis.*

Each lung lobe is ventilated by a principal bronchus (bronchus principalis sinister et dexter). These are the terminal bifurcation of the trachea. This structure counts approximately 27 cartilaginous rings and measures approximately 10 cm in length and 1 cm in diameter. Intrathoracically, the trachea lies ventral to the esophagus and is crossed by the aortic arch at its left side. From the left and right principal bronchi, two and three specific bronchi (bronchi lobares) for the several lung lobes branch off, respectively. The bronchus for the left cranial lung lobe further splits into a bronchus for the cranial part and one for the caudal part. The bronchus for the accessory lobe of the right lung is a branch from the caudal lobar bronchus (Figure 60).

## 6.8 Heart

The heart lies in the thoracic cavity in the region from the 2nd to the 4th intercostal space. It is located between the lungs, in the middle mediastinum, and is enclosed by the pericardium. This fibrous structure dorsally attaches to the basis of the heart and ventrally to the sternum by means of the sternopericardiac ligament. After removal of the left thoracic wall, the blunt apex of the heart, which is formed by the left ventricle, can be observed in between the left cranial and caudal lung lobes as the longitudinal axis of the heart presents a deviation of approximately 45° towards the left. As a result, both the left and right auricle can be observed from the left. The left lateral aspect of the heart is therefore called the auricular side (facies auricularis). Both atria are visible from the right side. This side of the heart is the atrial side (facies atrialis). After removal of the right thoracic wall, it can be observed that the right heart including the right auricle and ventricle rests on the sternum as a result of the counterclockwise quarter rotation of the longitudinal cardiac axis (Figure 61).

The left atrium, that is enlarged by the presence of the left auricle, receives oxygenated blood from the lungs via the four pulmonary veins. The left atrium is smaller in volume than the right atrium and has a smoother inner surface. From here, the blood flows to the left ventricle. The bicuspid left atrio-ventricular valve, i.e. the mitral valve, separates the left auricle from the left ventricle. It is attached to the papillary muscles in the wall of the left ventricle by means of the chordae tendineae. The latter presents a well trabeculated wall (trabeculae carneae) of approximately 6–9 mm in width. A septomarginal trabecula can be observed. Subsequently, blood flows to the ascending aorta. The aortic valve contains three valvulae.



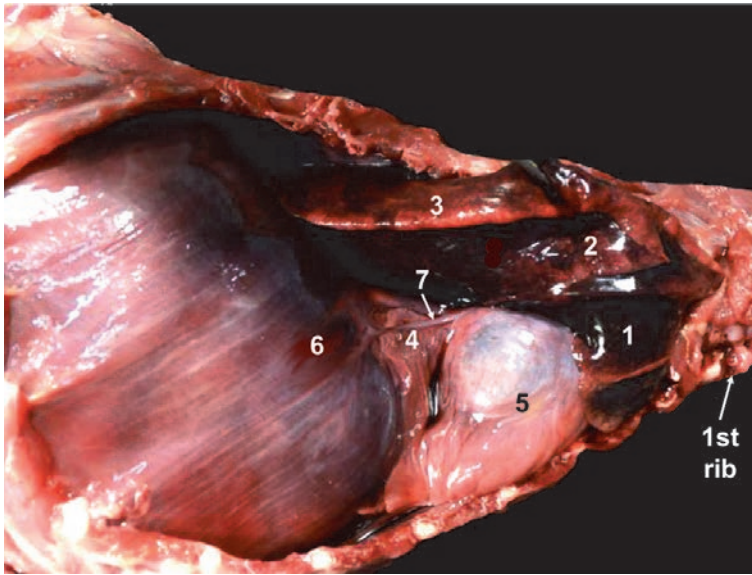
**Figure 60.**

*Polyurethane cast of the lungs, ventral view. 1: trachea, 2: bifurcatio tracheae, 3a: bronchus principalis sinister, 3b: bronchus principalis dexter, 3a1: bronchus lobaris for the left cranial lung lobe, 3a2: bronchus lobaris for the left caudal lung lobe, 3a3: bronchus lobaris for the right cranial lung lobe, 3b1: bronchus lobaris for the right middle lung lobe, 3b2: bronchus lobaris for the right caudal lung lobe, 3b3: bronchus lobaris for the right caudal lung lobe, 4a: pars cranialis lobis pulmonis sinistri, 4b: pars caudalis lobis pulmonis sinistri, 5: lobus caudalis pulmonis sinistri, 6: lobus cranialis pulmonis dextri, 7: lobus medius pulmonis dextri, 8: lobus caudalis pulmonis dextri, 9: lobus accessorius pulmonis dextri, 10: incisura cardiaca, 11: fissura interlobaris, 12: fissura interlobaris cranialis, 13: fissura interlobaris caudalis.*

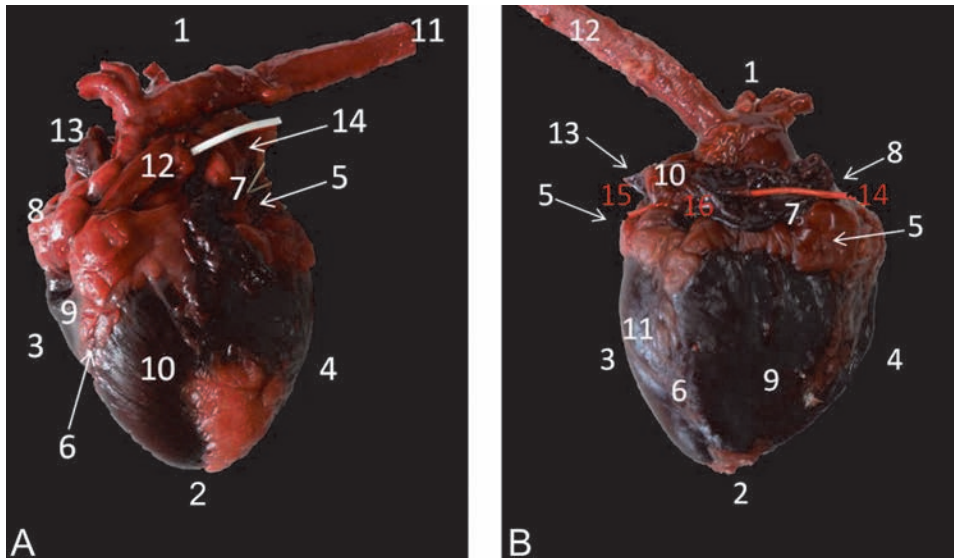
The right atrium, with its right auricle, receives the systemic venous blood through the cranial and caudal vena cava that join at the level of the tuberculum intervenosum. Its wall is characterized by the *mm. pectinati*. The right auriculo-ventricular valve presents three cusps and is therefore known as the tricuspid valve. The wall of the right ventricle is also trabeculated and measures 1–2 mm in width. The right lumen contains a septomarginal trabecula. The pulmonary valve has the typical arrangement with three *valvulae* (**Figures 62 and 63**).

The left and right coronary arteries (*a. coronaria sinistra et dextra*) branch off the short ascending aorta, which runs craniodorsally, just above the aortic valve. These can initially be seen in the coronary sulcus. The *a. coronaria dextra* gives the *a. interventricularis subsinuosus* that runs in the sulcus interventricularis subsinuosus. It ultimately joins the *ramus circumflexus* of the *a. coronaria sinistra*. This coronary artery runs initially in the coronary sulcus, gives the *ramus interventricularis paraconalis* that runs in the sulcus interventricularis paraconalis, and continues as the *ramus circumflexus* that joins the right coronary artery. The left coronary artery is more pronounced than the right (**Figure 63**).

The aortic arch presents a branching pattern that is dissimilar to that in humans. Only two branches can be seen, the brachiocephalic trunk and the left subclavian artery. From the short initial segment of the brachiocephalic trunk, also known as

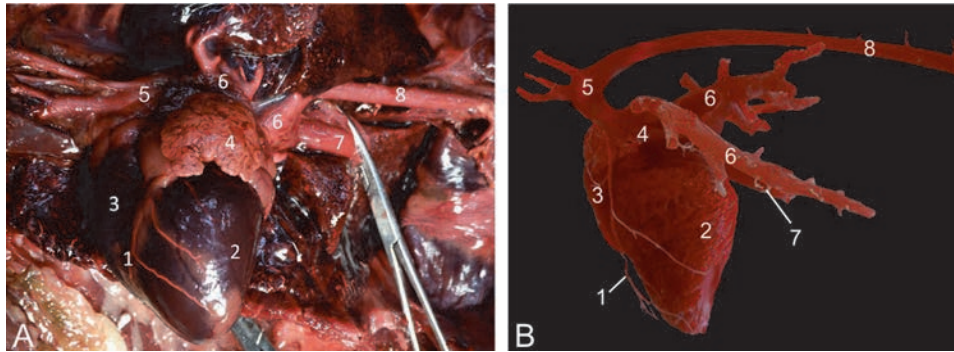


**Figure 61.** Right lateral view of the thoracic cavity with 1: lobus cranialis pulmonis dextri, 2: lobus medius pulmonis dextri, 3: lobus caudalis pulmonis dextri, 4: lobus accessorius pulmonis dextri, 5: heart within the pericardium, 6: diaphragma, 7: n. phrenicus.

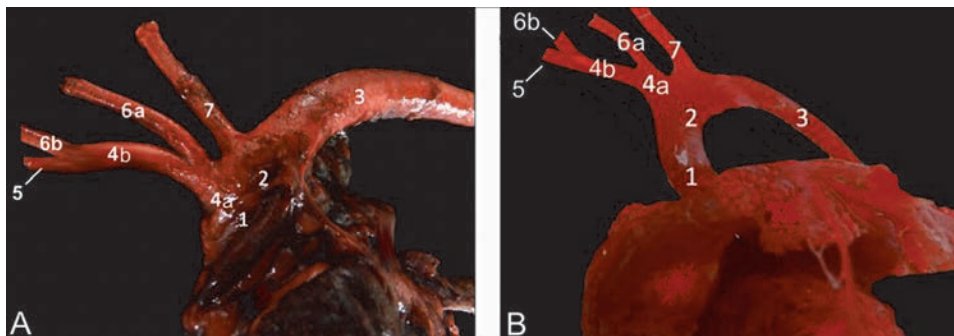


**Figure 62.** External anatomical landmarks of the heart. A: Left view, facies auricularis with 1: basis cordis, 2: apex cordis, 3: margo ventricularis dexter, 4: margo ventricularis sinister, 5: sulcus coronarius, 6: sulcus interventricularis paraconalis, 7: auricula sinistra, 8: auricula dextra, 9: ventriculus dexter, 10: ventriculus sinister, 11: aorta descendens, 12: truncus pulmonalis, 13: v. cava cranialis, 14: vv. pulmonales. B: Right view, facies atrialis with 1: basis cordis, 2: apex cordis, 3: margo ventricularis sinister, 4: margo ventricularis dexter, 5: sulcus coronarius, 6: sulcus interventricularis subsinuosus, 7: atrium dextrum, 8: sulcus terminalis, 9: ventriculus dexter, 10: atrium sinisterum, 11: ventriculus sinister, 12: aorta descendens, 13: vv. pulmonales, 14: v. cava cranialis, 15: v. cava caudalis, 16: sinus venarum cavarum.

the truncus communis, branches the left common carotid artery after a few mm to 1 cm. In humans, the left common carotid artery is a direct branch of the aortic arch. The right common carotid artery branches off subsequently. The continuation of the brachiocephalic trunk is the right subclavian artery (**Figure 64**).



**Figure 63.**  
 Heart and larger vessels. A: Latex injected specimen, B: Vascular corrosion cast. 1: a. coronaria sinistra ramus interventricularis paraconalis, 2: ventriculus sinister, 3: ventriculus dexter, 4: atrium sinistrum, 5: arcus aortae, 6: vv. pulmonales, 7: v. cava caudalis, 8: aorta thoracica.



**Figure 64.**  
 Branching vessels from the aortic arch. A: Native specimen, B: Vascular corrosion cast. 1: aorta ascendens, 2: arcus aortae, 3: aorta descendens, 4a: truncus communis, 4b: truncus brachiocephalicus, 5: a. subclavia dextra, 6a: a. carotis communis sinistra, 6b: a. carotis communis dextra, 7: a. subclavia sinistra.

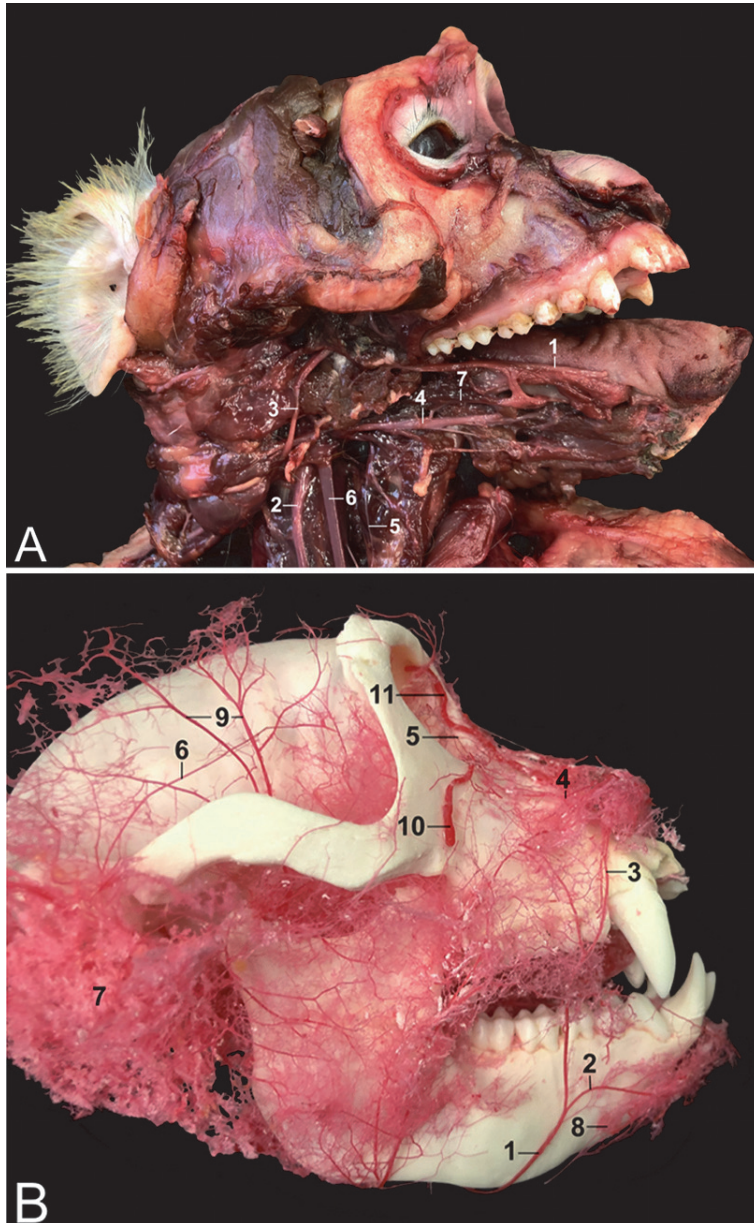
## 7. Angiology and neurology

### 7.1 Head

From the brachiocephalic trunk branches the left and subsequently the right common carotid artery. These arteries are laterally covered by the sternocleidomastoideus muscle. The internal jugular vein and vagal nerve are closely associated and lie just lateral to the artery. The common carotid artery divides into the internal and external carotid arteries at the mandibular angle. The former artery provides blood to the eye and the brains, while the latter gives off, amongst others, the linguofacial artery to continue as the maxillary artery.

The external jugular vein travels along the lateral aspect of the sternocleidomastoideus muscle and drains the venous blood from the head. This vein is suited for venipuncture. The accessory jugular vein lies parallel to the external jugular vein with which it fuses caudal to the collar bone. The caudal auricular veins, superficial temporal vein and maxillary vein drain into the external jugular vein. The facial vein drains partly into this vein, but mainly into the internal jugular vein. Both the external and internal jugular veins drain into the subclavian vein that in turn flow into the brachiocephalic vein. The cranial cava vein receives the left and right brachiocephalic veins.

In between the common carotid artery and the internal jugular vein lies the vagal nerve. It runs separately from the sympathetic trunk that lies deep against the cervical vertebrae. At the entrance of the thorax, the laryngeus recurrens nerve leaves the vagal nerve. The left sweeps around the aortic arch whereas the right makes a curvature around the right subclavian artery. The laryngeus recurrens nerve subsequently returns to the larynx, lateral to the trachea. Some major nerves and blood vessels of the rhesus monkey head are depicted in **Figure 65**.



**Figure 65.**  
*A: Right lateral view of the rhesus monkey head of which the right side of the mandible has been removed with 1: n. lingualis, 2: n. vagus, 3: n. accessorius, 4: n. hypoglossus, 5: ansa cervicalis, 6: a. carotis communis, 7: a. lingualis. B: Right lateral view of a vascular corrosion cast of the rhesus monkey head with 1: a. facialis, 2: a. submentalialis, 3: a. labialis superior, 4: a. nasalis lateralis, 5: a. angularis oculi, 6: a. temporalis superficialis, 7: vascular network of the parotid gland, 8: a. mentalis, 9: aa. temporales profundae, 10: v. facialis, 11: v. angularis oculi.*

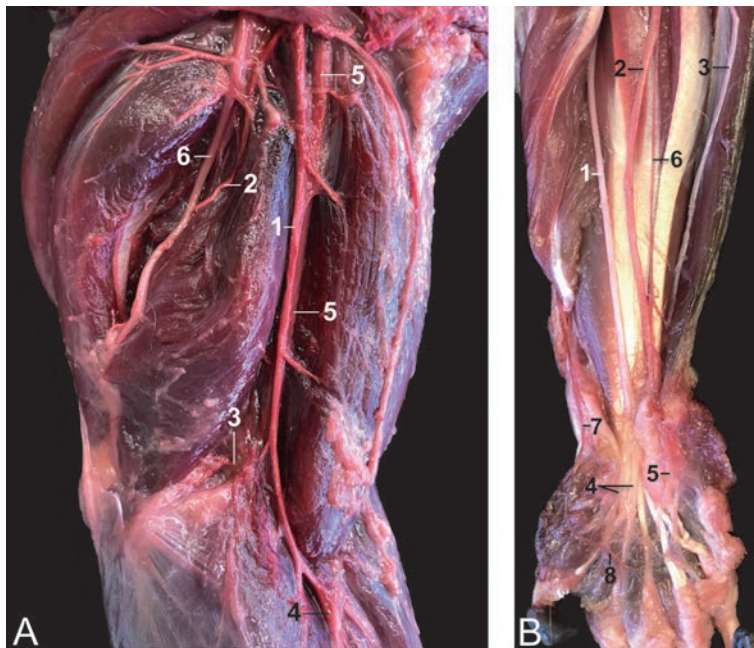


## 7.2 Thoracic limb

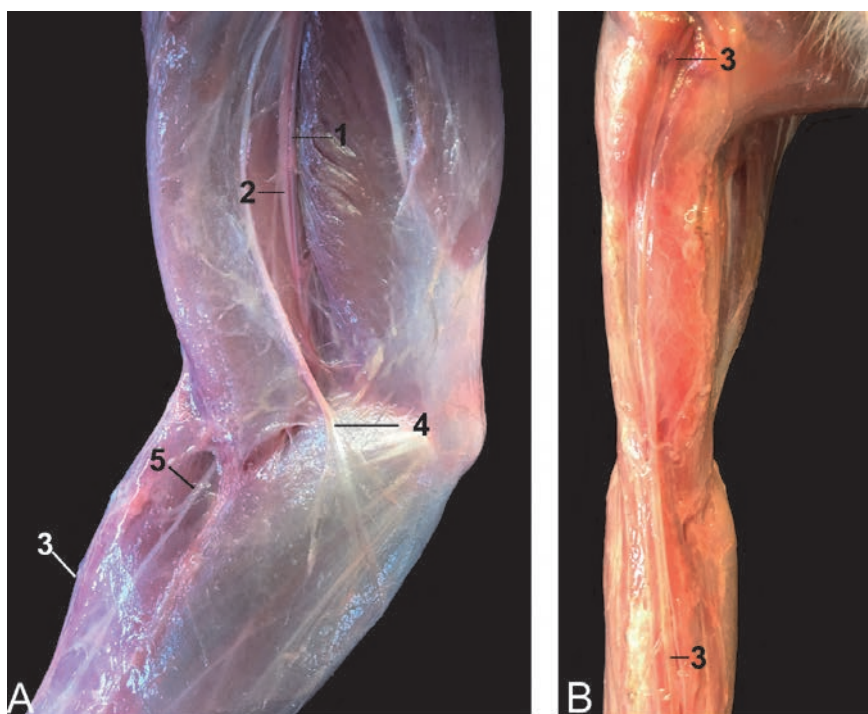
After crossing the 1st rib and giving off several branches to the head, neck, shoulder and thorax, the subclavian artery continues as the axillary artery that is accompanied by the axillary vein. The latter artery continues as the brachial artery after the a. subscapularis and a. circumflexa humeri cranialis have branched off. The brachial artery runs parallel to the n. medianus and gives off the a. profunda brachii as first branch. Subsequent branches are the collateralis ulnaris arteries that run collateral to the n. ulnaris. Just proximal to the elbow joint, the brachial artery splits into the radial and ulnar arteries. The former artery runs at the lateral side of the forearm towards the carpus where it gives origin to the dorsal and palmar arches. The ulnar artery joins the palmar arch. These arches supply the hand and fingers. **Figures 66** and **68** present the discussed arteries.

The venous circulation of the thoracic limbs consists of a deep and a superficial system. The deep system accompanies the arteries (e.g. v. subclavia, v. axillaris, v. brachialis), while the superficial veins have no arterial counterpart. In the rhesus monkey, the superficial venous system is poorly developed since the venous drainage of the hand and forearm is mainly provided by paired vv. comitantes. The cephalic vein, which is located at the cranial side of the antebrachium, is the major superficial vein of the forelimb. It forms a common stem with the accessory jugular vein that drains into the external jugular vein. It can be used for venipuncture, but is not preferred in the rhesus monkey (**Figure 67**).

The nerves of the forelimb originate from the brachial plexus (C5 – T2) at the medial side of the upper arm. The thoracodorsal nerve innervates the latissimus dorsi muscle. The axillary nerve finds its way from medial to lateral superficially in the angle between the coracobrachialis and teres major muscles and deeper between



**Figure 66.** Blood vessels and nerves of the thoracic limb. A: Medial view of the left upper arm with 1: a. brachialis, 2: a. collateralis ulnaris proximalis, 3: a. collateralis ulnaris distalis, 4: a. radialis, 5: n. medianus, 6: n. ulnaris. B: Medial/palmar view of the right forearm and hand with 1: n. medianus, 2: n. ulnaris, 3: ramus dorsalis (n. ulnaris), 4: nn. digitales palmares communes, 5: ramus superficialis (n. ulnaris), 6: a. ulnaris, 7: a. radialis, 8: arcus palmaris.

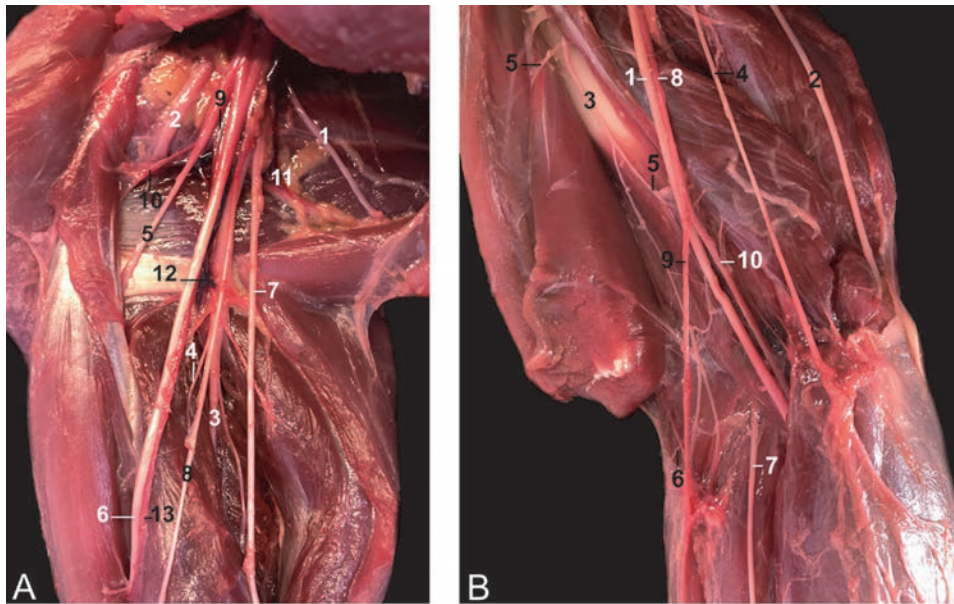


**Figure 67.** Medial (A) and dorsal (B) views of the thoracic limb showing 1: *v. brachialis*, 2: *n. medianus*, 3: *v. cephalica*, 4: *n. cutaneus brachii medialis*, 5: *n. cutaneus antebrachii medialis*.

the triceps and teres minor muscles to innervate the flexor muscles of the shoulder (deltoid, coracobrachialis and both teres muscles). The radial nerve runs from medial to lateral between the lateral and medial heads of the triceps muscle and perforates the brachioradialis muscle. Its muscular branches innervate the triceps and anconeus muscles as well as the extensor musculature of the upper arm, forearm and hand. The musculocutaneous nerve innervates the flexor muscles of the elbow joint (rami musculares to the coracobrachialis, biceps brachii and brachialis muscles). The median nerve runs parallel to the brachial artery in between the biceps brachii and brachialis muscle. More distally, it lies deep to the flexor muscles of the forearm, which it innervates. Its most distal branches are the digital nerves. The ulnar nerve can be found between the medial and long head of the triceps muscle. It crosses the elbow region in between the flexor carpi ulnaris and flexor digitorum profundus muscles to reach the hand. Its dorsal, superficial and deep branches innervate the flexor musculature of the fingers in addition to the median nerve. The *n. cutaneus brachii et antebrachii medialis* runs initially parallel to the ulnar nerve. The brachial and antebrachial branches innervate the skin at the medial sides of the upper and lower arm, respectively. The here discussed nerves are depicted in **Figures 66–68**.

### 7.3 Body

In this paragraph, some essential data on the ramifications of the abdominal aorta and caudal vena cava will be shared. As regards the arterial system that is depicted in **Figure 69**, it should be noticed that the truncus celiacus is very short and soon divides into the common hepatic artery, the gastrolienalis artery and the cranial mesenteric artery. The common hepatic artery branches into the *a. hepatica*



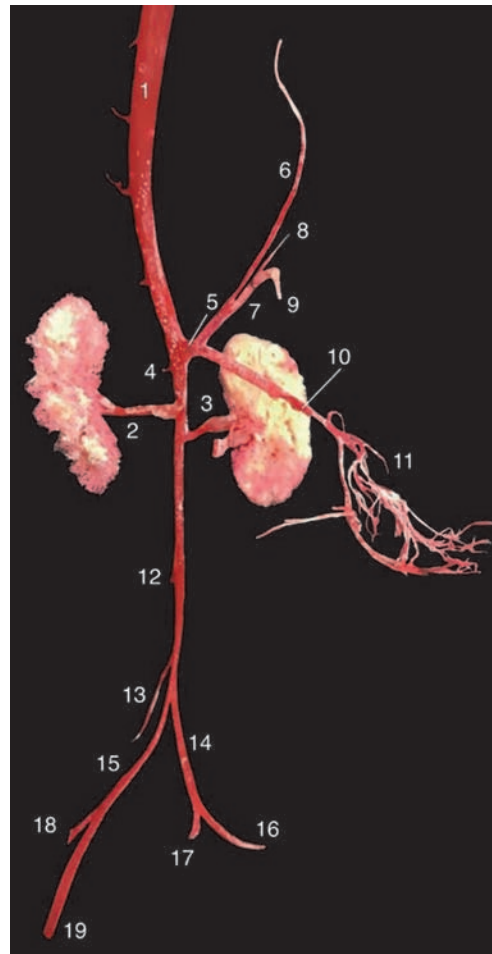
**Figure 68.**  
*Medial views of the nerves and blood vessels of the right forelimb. A: Plexus brachialis at the level of the shoulder joint with 1: n. thoracodorsalis, 2: n. axillaris, 3: n. radialis, 4: rami musculares, 5: n. musculocutaneus, 6: n. medianus, 7: n. ulnaris, 8: n. cutaneus brachii et antebrachii medialis, 9: a. axillaris, 10: a. circumflexa humeri cranialis, 11: a. subscapularis, 12: a. profunda brachii, 13: a. brachialis. B: Blood vessels and nerves at the level of the elbow joint with 1: n. medianus, 2: n. ulnaris, 3: n. musculocutaneus, 4: n. cutaneus brachii et antebrachii medialis, 5: Rami musculares, 6: n. cutaneus antebrachii lateralis, 7: n. radialis, 8: a. brachialis, 9: a. radialis, 10: a. ulnaris.*

propria that supplies the liver and arteries for the stomach, pancreas and duodenum. The a. gastrolienalis subsequently divides into the a. lienalis and a. gastrica sinistra. The a. mesenterica cranialis ramifies into the jejunal, ileal and colic arteries. Only approximately 1 cm caudal to the celiac trunk branches the right renal artery off the abdominal aorta. The left renal artery can be found a few mm more caudal. The caudal mesenteric artery branches off a few cm caudal to the left renal artery. This artery ramifies into the a. colica sinistra, a. sigmoidea and a. rectalis cranialis. Just cranial to the terminal bifurcation of the abdominal aorta into the common iliac arteries can the origin of the a. circumflexa ilium profunda be found.

Regarding the venous system, the reader should be reminded of the fact that the arterial truncus celiacus has no venous counterpart. The portal vein is described above (**Figure 51**). The veins of the caudal segment of the caudal vena cava can be studied by means of **Figure 70**.

#### 7.4 Pelvic limb

The abdominal aorta divides into the left and right common iliac arteries within the pelvic cavity. These arteries subsequently divide into the external and internal iliac arteries (**Figure 69**). In the proximal part of the thigh, the external iliac artery continues as the femoral artery, which is suitable for palpation of the pulse, after the a. profunda femoris has branched off. This artery gives origin to the lateral circumflex artery, which branches supply the vasti muscles. The femoral artery then divides into the saphena artery and the popliteal artery. The latter artery runs deep between both heads of the gastrocnemius muscle and gives the medial and lateral a. genus distalis as branches. These branches supply the knee region together with the

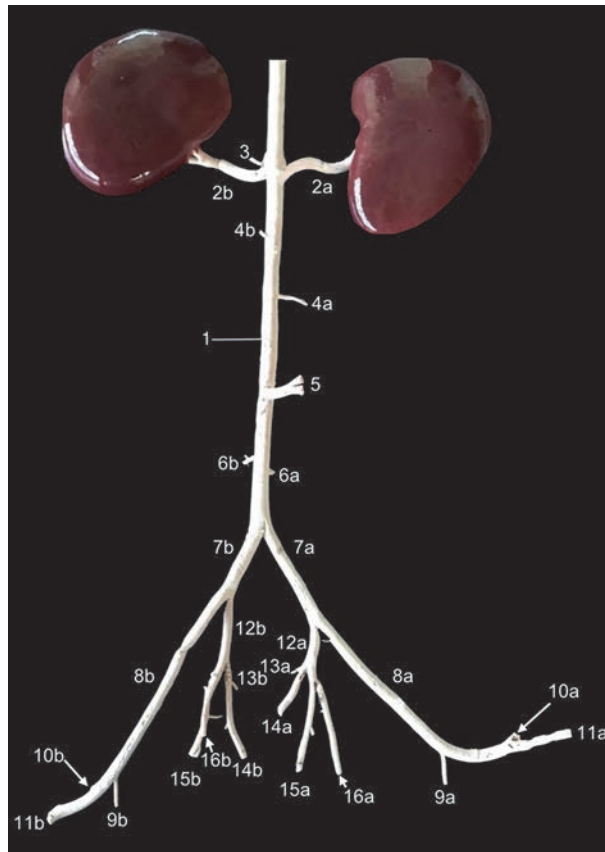


**Figure 69.**

*Corrosion cast of the abdominal arteries, ventral view. 1: aorta abdominalis, 2: a. renalis dextra, 3: a. renalis sinistra, 4: a. adrenalis, 5: truncus celiacus, 6: a. hepatica communis, 7: a. gastroliealis, 8: a. gastrica, 9: a. lienalis, 10: a. mesenterica cranialis, 11: aa. jejunales et ileales, 12: a. mesenterica caudalis, 13: a. circumflexa ilium profunda, 14: a. iliaca communis sinistra, 15: a. iliaca comunis dextra, 16: a. iliaca externa sinistra, 17: a. iliaca interna sinistra, 18: a. iliaca interna dextra, 19: a. iliaca externa dextra.*

a. genus proximalis of the a. saphena. This artery emerges in the angle formed by the sartorius and gracilis muscles and runs superficially to the medial side of the tibia. She subsequently migrates to the cranial aspect of the tarsus to become the a. dorsalis pedis (superficialis et profunda). From the popliteal artery branches the a. tibialis cranialis. She becomes the a. tibialis caudalis at the level of the lower leg. At the level of the foot, the a. tibialis caudalis divides into the a. plantaris lateralis et medialis. The arterial and nerve system of the hind limb are visualized in **Figures 71** and **73**.

In analogy with the thoracic limb, the venous drainage of the pelvic limb is mainly effectuated by the vv. comitantes. The vv. marginalis medialis et lateralis pedis drain the dorsal side of the foot. The v. marginalis medialis pedis drains into the superficially located v. saphena magna that proximately flows into the femoral vein. The v. marginalis lateralis pedis drains into the v. saphena parva. It is an important vein as it drains the larger part of the hind leg and is suitable for venipuncture at the caudal aspect of the calf (**Figure 72**). In the popliteal fossa, she drains into the popliteal vein. This vein runs adjacent to the eponymous artery and

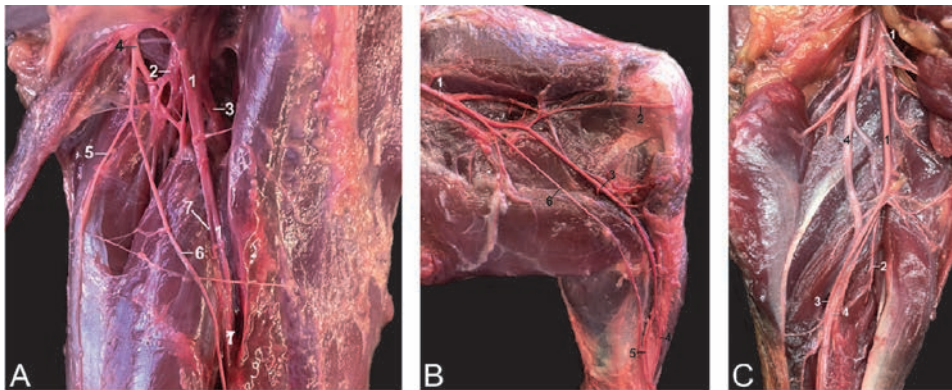


**Figure 70.**

*Latex cast of the caudal segment of the caudal cava vein of the male rhesus monkey, ventral view. 1: v. cava caudalis, 2a: v. renalis dextra, 2b: v. renalis sinistra, 3: v. adrenalis sinistra, 4a: v. testicularis dextra, 4b: v. testicularis sinistra, 5: v. mesenterica caudalis, 6a: v. circumflexa ilium profunda dextra, 6b: v. circumflexa ilium profunda sinistra, 7a: v. iliaca communis dextra, 7b: v. iliaca communis sinistra, 8a: v. iliaca externa dextra, 8b: v. iliaca externa sinistra, 9a: v. profunda femoris dextra, 9b: v. profunda femoris sinistra, 10a: v. circumflexa femoris lateralis dextra, 10b: v. circumflexa femoris lateralis sinistra, 11a: v. femoralis dextra, 11b: v. femoralis sinistra, 12a: v. iliaca interna dextra, 12b: v. iliaca interna sinistra, 13a + 14a: v. gluteus cranialis superficialis dextra, 13b + 14b: v. gluteus cranialis superficialis sinistra, 15a + 15b: Continuation of v. iliaca interna dextra et sinistra, 16a: v. obturatoria dextra, 16b: v. obturatoria sinistra.*

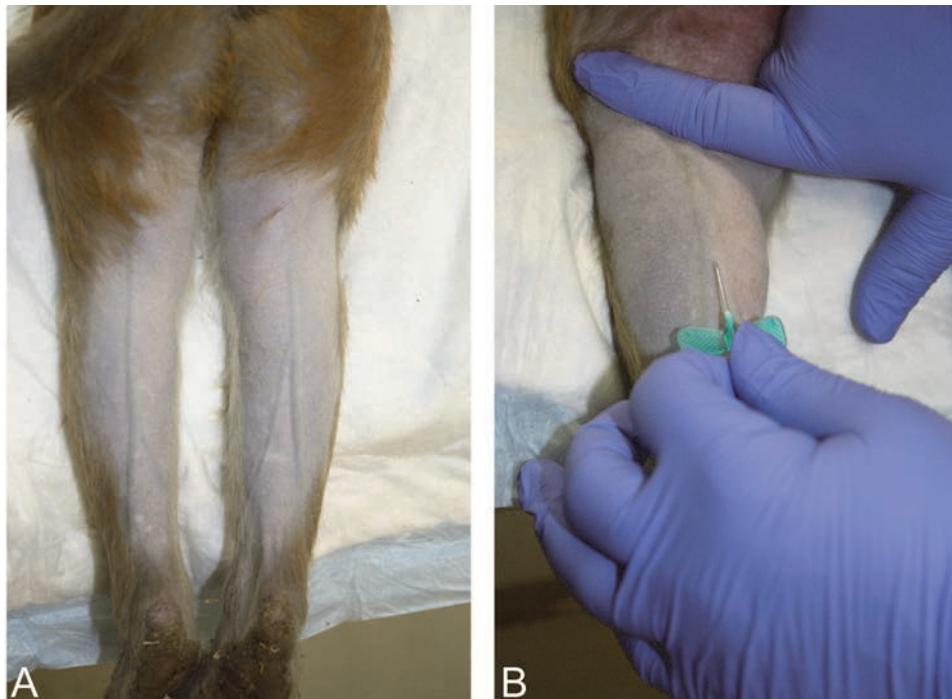flows into the femoral vein. This vein is also suitable for venipuncture. The femoral vein proximally drains into the external iliac vein that in turn flows into the common iliac vein.

The nerves of the hind limb originate from the lumbosacral plexus. The femoral nerve is associated with the eponymous blood vessels. Its muscular branches innervate the extensor muscles of the knee. In addition, cranial cutaneous branches innervate the skin at the craniomedial side of the upper leg and the medial side of the knee. The distal continuation of the femoral nerve is the n. saphenus that accompanies the a. saphena and innervates the skin at the craniomedial aspect of the lower leg. The n. gluteus caudalis, that innervates the m. gluteus superficialis, emerges together with the sciatic nerve. This nerve divides into the n. fibularis communis and n. tibialis. The former nerve deviates towards the lateral head of the gastrocnemius muscle. Halfway the upper leg, the n. cutaneus surae lateralis branches off to innervate the skin at the caudolateral side of the lower leg. Here, nerve biopsy can be performed. At the level of the knee, the n. fibularis communis divides into the n. fibularis superficialis et profundus. The latter travels deep to the



**Figure 71.**

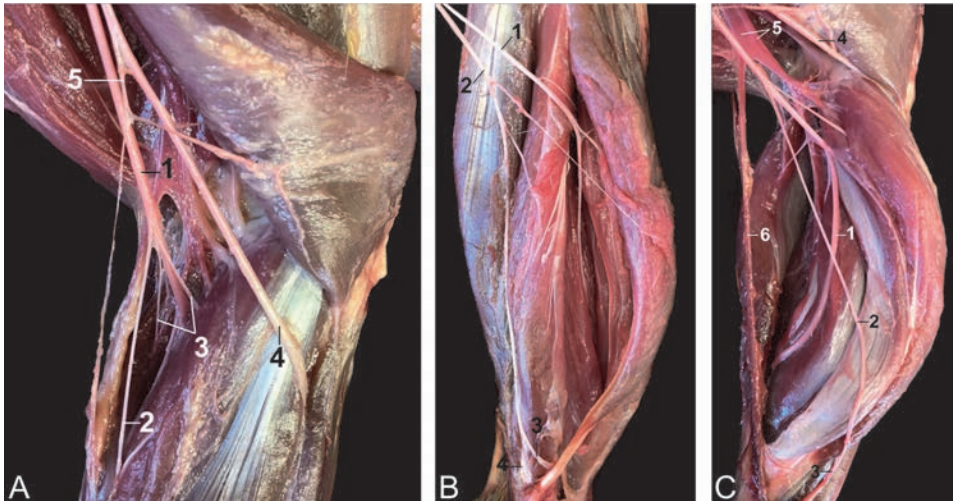
*Vasculature and nerves of the pelvic limb. A: Dorsomedial view of the right upper leg with 1: a. femoralis, 2: a. circumflexa femoris lateralis, 3: a. profunda femoris, 4: n. femoralis, 5: rami cutanei craniales, 6: n. saphenus. B: Medial view of the thigh and knee of the left leg with 1: a. femoralis, 2: a. genus proximalis, 3: a. saphena: 4: a. dorsalis pedis profunda: 5: a. dorsalis pedis superficialis, 6: n. saphenus. C: Caudal view of the popliteal region of the left leg with 1: a. poplitea, 2: a. tibialis cranialis, 3: a. tibialis caudalis, 4: n. tibialis.*



**Figure 72.**

*Superficial veins of the pelvic limb. A: Subcutaneous localization of the v. saphena parva. B: Catheterization of the v. saphena parva.*

fibularis longus and extensor digitorum longus muscles to innervate the flexors of the tarsal joint and the extensors of the toes. The former gives off ramifications to the fibularis muscles and branches into the skin at the dorsolateral side of the foot. The tibial nerve presents several ramifications at the level of the knee. The majority migrate between the heads of the gastrocnemius muscle to innervate the popliteus muscle, the extensors of the tarsal joint and the flexor musculature of the toes. A specific branch, the n. cutaneus surae caudalis, innervates the skin at the caudal side



**Figure 73.**  
*Nerves and blood vessels of the right pelvic limb. Laterocaudal view of the right knee with 1: n. tibialis, 2: n. cutaneus surae medialis, 3: rami musculares, 4: n. fibularis communis, 5: n. cutaneus surae lateralis. B: Laterocaudal, superficial view of the lower leg with 1: n. fibularis profundus, 2: n. fibularis superficialis, 3: n. cutaneus pedis dorsalis medialis, 4: n. cutaneus pedis dorsalis intermedius. C: Laterocaudal, deep view of the lower leg with 1: n. tibialis, 2: n. cutaneus surae medialis, 3: n. suralis, 4: n. fibularis communis, 5: a. et v. poplitea, 6: v. saphena parva.*

of the lower leg. More distally, it runs more laterally and is then called the n. suralis. Just proximal to the medial ankle, the tibial nerve divides into the medial and lateral plantar nerves. The n. flexoris femoris runs adjacent to the proximal part of the tibial nerve and branches into the hamstrings.

## Acknowledgements

The authors would like to thank Carlien Blockhuys (DVM), Lotte Joosten (DVM), Olga Kopilova (DVM), Caroline Mertens (DVM) and Gwenny Van Acoleyen (DVM) for their preliminary dissections that formed the basis of this chapter, and professor Jan Langermans (PhD) and Thea de Koning for critical reading and editing.

## **Author details**

Christophe Casteleyn<sup>1,2\*</sup> and Jaco Bakker<sup>3</sup>

1 Department of Morphology, Faculty of Veterinary Medicine, Ghent University, Merelbeke, Belgium

2 Laboratory for Applied Veterinary Morphology, Faculty of Pharmaceutical, Biomedical and Veterinary Sciences, University of Antwerp, Belgium

3 Animal Science Department, Biomedical Primate Research Centre, Rijswijk, The Netherlands

\*Address all correspondence to: [christophe.casteleyn@ugent.be](mailto:christophe.casteleyn@ugent.be)

## **IntechOpen**

---

© 2021 The Author(s). Licensee IntechOpen. This chapter is distributed under the terms of the Creative Commons Attribution License (<http://creativecommons.org/licenses/by/3.0>), which permits unrestricted use, distribution, and reproduction in any medium, provided the original work is properly cited. 



## References

- [1] Morton WR, Kyes KB, Kyes RC, Swindler DR, Swindler KE. Use of the primate model in research. In: Wolfe-Coote S, editors. *The Laboratory Primate*. London: Academic Press; 2005. p. 405-415.
- [2] Thew M, Bailey J, Balls M, Hudson M. The ban on the use of chimpanzees in biomedical research and testing in the UK should be made permanent and legally binding. *Alternatives to Laboratory Animals*. 2012;40:3-8.
- [3] Hartman CG, Straus Jr WL. *The Anatomy of the Rhesus Monkey (Macaca mulatta)*. London: Ballière, Tindall and Cox; 1933. 383 p.
- [4] Berringer OM, Browning FM, Schroeder CR. *An Atlas and Dissection Manual of Rhesus Monkey Anatomy*. Tallahassee: Anatomy Laboratory Aids; 1968. 115 p.
- [5] Nomina Anatomica Veterinaria, 6th edition (Internet). 2017. Available from: <http://www.wava-amav.org> [Accessed: 2021-05-10]
- [6] Van Wagenen G, Catchpole HR. Physical growth of the rhesus monkey (*Macaca mulatta*). *American Journal of Physical Anthropology*. 1956;14:245-273.
- [7] Lewis AD, Prongay K (2015). Basic physiology of *Macaca mulatta*. In: Bluemel J, Korte S, Schenck E, Weinbauer GF, editors. *The Nonhuman Primate in Nonclinical Drug Development and Safety Assessment*. London: Academic Press; 2015. p. 87-113.
- [8] Van Wagenen G, Simpson ME. Testicular development in the rhesus monkey. *The Anatomical Record*. 1954; 118:231-251.
- [9] Berringer OM, Browning FM, Schroeder CR. Myology. In: Berringer OM, Browning FM, Schroeder CR, editors. *An Atlas and Dissection Manual of Rhesus Monkey Anatomy*. 2nd ed. Tallahassee: Rose Printing Company; 1974. p. 15-54.
- [10] Burrows AM, Waller BM, Parr LA. Facial musculature in the rhesus macaque (*Macaca mulatta*): Evolutionary and functional contexts with comparisons to chimpanzees and humans. *Journal of Anatomy*. 2009;215: 320-334.
- [11] Burrows AM, Waller BM, Micheletta J. Mimetetic muscles in a despotic macaque (*Macaca mulatta*) differ from those in a closely related tolerant macaque (*M. nigra*). *The Anatomical Record*. 2016;299:1317-1324.
- [12] Murray P. The role of cheek Pouches in Cercopithecine monkey adaptive strategy. In: Tuttle RH, editor. *Primate Functional Morphology and Evolution*. Berlin: De Gruyter; 1975. p. 151-170.