

The post-mortem diagnosis of vasocclusive crisis in sickle cell disease

Varsha Bhatia^a, Richa Juneja^a, Vijay Juvekar^a

Bhatia V, Juneja R, Juvekar V. The post-mortem diagnosis of vasocclusive crisis in sickle cell disease [letter]. *Autopsy Case Rep* [Internet]. 2014;4(3):9-11. <http://dx.doi.org/10.4322/acr.2014.023>

Sickle cell disease (SCD) comprises a group of genetic blood disorders that affect the hemoglobin molecular structure, and in some cases, the association with hemoglobin synthesis. In sickle cell anemia, the replacement of glutamic acid by valine at the 6th position on the beta chain from the N terminal results in the synthesis of the abnormal hemoglobin, called hemoglobin S (HbS).¹

Several studies highlight that acute chest syndromes, cerebrovascular events, splenic dysfunction or sequestration, and aplastic crises are the main causes of sudden death, although any presentation of sickling can lead to death if one of these more serious complications then arises.² Recently, sickling crisis followed by bone marrow necrosis and fat embolism was shown to be associated with high index of mortality in a patient with double heterozygosis to HbS and HbC.³

We hereby present two cases: a female child and an adult male (Table 1), both of whom had an unexpected sudden death, which was diagnosed as SCD at autopsy (Figure 1).

In India, SCD is seen mainly in the tribal belts of Central zones comprised of Maharashtra, Madhya Pradesh, and Orissa.⁴ Our patients were residents of Maharashtra. Only meagre histories were available for these patients. Both the patients were virtually asymptomatic and were apparently never diagnosed as having SCD.

SCD is remarkable for its clinical heterogeneity. There is a dearth of data on SCD in India compared with other countries in Africa and America. The

clinical profile of sickle cell patients in Central India is less severe compared that of African countries and is characterized by delayed presentation, paucisymptomatic cases, less frequency of vaso occlusive crisis, and low mortality. Therefore, most of the patients remain undiagnosed.⁵

We are reporting these rare cases of sudden death in a previously undiagnosed SCD in a female child and an adult male of Indian origin with no remarkable medical histories.

Our patients had a very short clinical history of illness of 24 hours. They had no clinical evidence of acute hemolysis, abdominal pain, breathlessness, or anxiety to suggest sickle crisis. The recognized putative factors for sickle cell crisis include infection, fever, excessive exercise, anxiety, and hypoxia,⁶ which were absent in our patients—except for fever. The autopsy findings of our patients did not reveal any major organ infarcts.

The microscopic findings seen in both cases revealed congested blood vessels packed with sickled red blood cells (RBCs) in multiple organs. The incidental finding of necrotizing granulomatous inflammation consistent with tuberculosis was noted in the adult male. As splenomegaly was noted in the autopsy notes of both our cases, the possibility of other hemoglobinopathies, like double heterozygous HbS and HbC, could not be ruled out by means of histology; therefore, the broad diagnostic possibility of SCD was considered.

Hemoglobin electrophoresis is the most common method used to diagnose SCD at autopsy. However,

^a Department of Pathology – Grant Government Medical College, Mumbai – India.



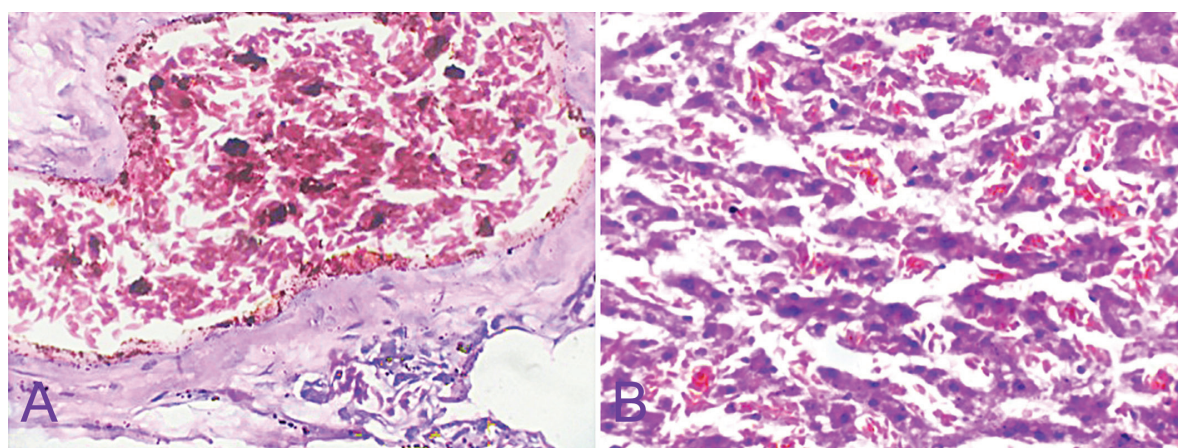


Figure 1. A - Photomicrograph of the lung showing sickle red blood cells filling a medium-sized vessel; B - Photomicrograph of the liver showing sinusoids with sickle red blood cells (H&E, 400X).

Table 1. Clinical characterization of two cases with unexpected sudden death

Parameters	Case 1	Case 2
Age(years)	9	25
Sex	Female	Male
Resident of	Maharashtra, India	Maharashtra, India
Presentation	Fever, seizure one episode	Fever with chills, headache
Past history	Not significant	Not significant
Autopsy performed at	Alibaug Civil Hospital, Mumbai	Rajawadi Hospital, Mumbai
Autopsy finding	Hepatosplenomegaly with yellow discoloration of omentum	Hepatosplenomegaly with congestion in other organs
Provisional cause of death at autopsy	Pyrexia with hepatosplenomegaly to rule out chronic malaria/hepatitis/leptospirosis	Pending for histopathology examination
Viscera received at	Department of Pathology at Grant Government Medical College and Sir JJ Group of Hospitals, Maharashtra	Department of Pathology at Grant Government Medical College and Sir JJ Group of Hospitals, Maharashtra
Microscopy	Spleen, liver and brain showed congested blood vessels with sickle-shaped RBCs (Figure 1A)	All organs showed congested blood vessels with sickle shaped RBCs (Figure 1B) & lung showed necrotizing granulomatous inflammation consistent with tuberculosis
Final cause of death	SCD with the possibility of vaso occlusive crisis in a child	Pulmonary tuberculosis in a case of SCD with the possibility of vaso occlusive crisis

RBCs = red blood cells; SCD = sickle cell disease.

Thogmartin et al.,⁷ in their study, have concluded that histological diagnosis of sickle cell can be done with the sensitivity of 95% and the specificity of 100%.

We conclude that limited clinical history, inadequate evaluation of pathological findings at autopsy, and a lack of laboratory resources (electrophoresis) are major shortcomings in the diagnosis of SCD in medicolegal cases and cases of sudden death. Therefore, autopsy pathologists should be aware of this possibility in such cases. However, precise histopathological examination of tissue in the absence of other ancillary techniques serves as an important tool in diagnosing SCD at autopsy.⁷

REFERENCES

1. Hanmante RD, Dhumure KS, Sawaimul KD, Chopde SW, Kumbhakarna NR, Bindu RS. Sickle cell disease presenting as sudden death: autopsy findings of 5 cases. *IJCST*. 2011;1(2):65-73.
2. Liesner RJ, Vandenberghe EA. Sudden death in sickle cell disease. *J R Soc Med*. 1993;86(8):484-5. PMID:8078054.
3. Campos FPF, Ferreira CR, Felipe-Silva A. Bone marrow necrosis and fat embolism: an autopsy report of a severe complication of hemoglobin SC disease. *Autopsy Case Rep* [Internet]. 2014;4(2):9-20. <http://dx.doi.org/10.4322/acr.2014.012>.

4. Pillai LV, Husainy S, Gosavi S, Vaidya N. Sudden unexpected death in an undiagnosed sickle disease. *Indian J Crit Care Med.* 2005;9(2):92-5.
5. Shrigiriwar MB, Ghormade PS, Tinge CV. Death due to sickle cell anaemia: autopsy diagnosis. *J Indian Acad Forensic Med.* 2013;35(4):383-5.
6. Kark JA, Posey DM, Schumacher HR, Ruehle CJ. Sickle-cell trait as a risk factor for sudden death in physical training. *N Engl J Med.* 1987;317(13):781-7. <http://dx.doi.org/10.1056/NEJM198709243171301>. PMID:3627196
7. Thogmartin JR, Wilson CI, Palma NA, Ignacio SS, Pellan WA. Histological diagnosis of sickle cell trait: a blinded analysis. *Am J Forensic Med Pathol.* 2009;30(1):36-9. <http://dx.doi.org/10.1097/PAF.0b013e3181873835>. PMID:19237851

Correspondence

Varsha Bhatia

Department of Pathology – Grant Government Medical College, Mumbai – India

E-mail drvarshabhatia@gmail.com