

## CASE REPORT

# Amelioration of Symptoms and Reduction of VIP Levels after Hepatic Artery Chemoembolization in a Patient with Sandostatin Resistant VIPoma

Walid Shaib<sup>a</sup>, Kisha Mitchell<sup>b</sup>, and M. Wasif Saif<sup>b\*</sup>

<sup>a</sup>Hospital of Saint Raphael and <sup>b</sup>Yale University School of Medicine, New Haven, Connecticut

Vasoactive intestinal polypeptide secreting islet cell tumors (†VIPomas) are neuroendocrine tumors that secrete excessive amounts of vasoactive intestinal polypeptide (VIP) that cause distinct syndromes characterized by large-volume diarrhea, hypokalemia, and dehydration. The annual incidence of these tumors is estimated to be about one per 10,000,000 individuals in the general population. We report a successful treatment of VIPoma with hepatic chemoembolization of a metastatic hepatic lesion evidenced by a reduction of VIP levels and resolutions of symptoms in a patient with pancreatic VIPoma unresponsive to increased doses of an octreotide analog.

## INTRODUCTION

We would like to report a case in which hepatic chemoembolization of a metastatic hepatic lesion of VIPoma (Vasoactive Intestinal Polypeptide secreting islet cell tumor) leads to a reduction of VIP (Vasoactive Intestinal Polypeptide) levels and resolution of symptoms in a patient with pancreatic VIPoma unresponsive to increased doses of an octreotide analog.

## CASE REPORT

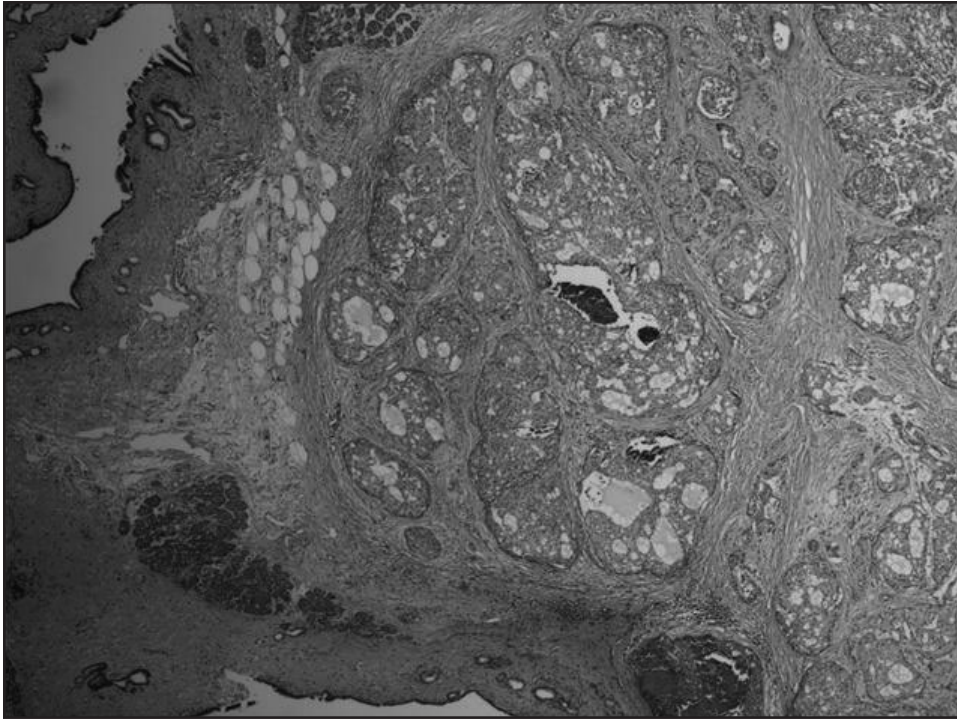
An 80-year-old Caucasian woman with a history of VIPoma diagnosed in 1997 was treated for a 3.5 cm lesion in the head of the pancreas by Whipple procedure surgery (Figure 1). She tolerated the surgery well, except for the development of diabetes controlled with insulin postoperatively. In December 2004, follow-up CT imaging showed a new 2.5 cm mass in the bed of the pancreas. She

---

\*To whom all correspondence should be addressed: M. Wasif Saif, MD, MBBS, Associate Professor, Co-Director, GI Cancers Program, Yale Cancer Center, Yale University School of Medicine, 33 Cedar Street, FMP 116, New Haven, CT 06521; E-mail: wasif.saif@yale.edu.

†Abbreviations: VIPoma, vasoactive intestinal polypeptide secreting islet cell tumor; VIP, vasoactive intestinal polypeptide; LAR, long-acting; WDHA, watery diarrhea, hypokalemia, and achlorhydria; sstrs, somatostatin receptors; TACE, Transcatheter Chemoembolization.

Keywords: Hepatic artery chemoembolization, VIPoma



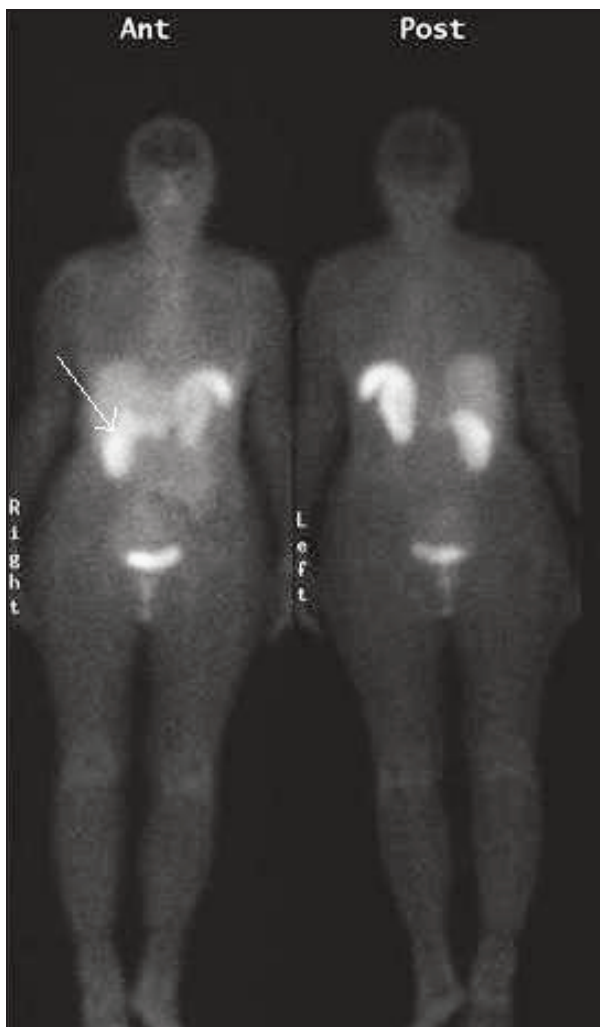
**Figure 1.** Pathology specimen showing pancreatic islet cell tumor.

underwent another resection with positive margins and one out of three lymph nodes positive for malignancy, for which levels of VIP were  $>400$  pg/ml (normal  $<75$ ), chromogranin A 16.2 U/L ( $<31$ ), gastrin 16 pg/ml ( $<110$ ) and serotonin 15 ng/ml ( $<71$ ). Follow-up serial octreotide scans showed stable disease. In May 2005, a follow-up octreotide scan showed the same unresectable retropancreatic tumor with new involvement of the right hepatic lobe (Figure 2). Due to the long and indolent course of the disease and because the patient was asymptomatic, she was treated with Sandostatin long acting (LAR) depot monthly. In September 2006, the patient complained of worsening diarrhea, up to 10 bowel movements in 24 hours. Laboratory data showed that VIP levels were still  $>400$  pg/ml. Patient was re-started on a loading dose of short-acting Sandostatin at 150 micrograms subcutaneously every eight hours for two weeks, followed by LAR Sandostatin 20 mg intramuscularly every 28 days. Due to persistent diarrhea, the dose of LAR Sandostatin was escalated by increments of 10 mg every 28 days to a maximum dose of 100 mg. The VIP levels continued to be high ( $>400$  pg/ml), and

diarrhea transiently improved. Another flare-up occurred in March 2008, manifested by intractable diarrhea and severe metabolic acidosis. Because there are no guidelines in the treatment and follow-up of this disease, we elected to initiate treatment with 5-Fluorouracil (5-FU) and streptozocin, based on reports and success rates. No improvement of diarrhea (consistency and frequency) was noted on this treatment. 5-FU was changed to capecitabine with the same results as 5-FU. She underwent chemo-ablation with mitomycin c, cisplatin, and doxorubicin. Her hospital course after the chemoablation was complicated by pulmonary embolism, atrial fibrillation, pneumonia, and vancomycin-resistant enterococcus bacteremia. After treatment, her diarrhea improved to less than two stools per day. In addition, the VIP levels decreased to 122 pg/ml (Figure 3). Three months later, patient was started on temozolomide as maintenance therapy.

## DISCUSSION

VIPomas are neuroendocrine tumors that secrete excessive amounts of VIP that



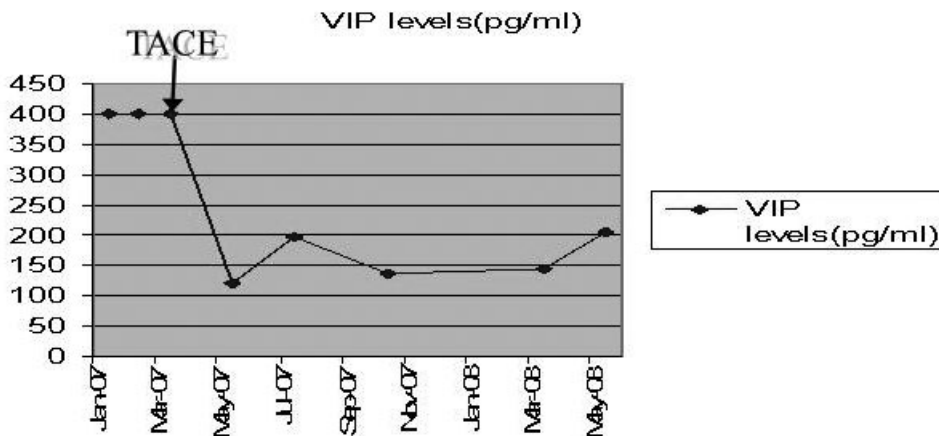
**Figure 2.** Octreoscan from 5/17/05 shows uptake in the right liver superior to the right kidney.

cause distinct syndromes characterized by large-volume diarrhea, hypokalemia, and dehydration. The annual incidence of these tumors is estimated to be about 1 per 10,000,000 individuals in the general population [1]. The mean age of VIPoma patients is 49 years. This syndrome is also called Verner-Morrison syndrome, pancreatic cholera, or WDHA (watery diarrhea, hypokalemia, and achlorhydria) syndrome. In addition to the WDHA, patients can present with flushing secondary to the vasodilatory effect of the VIP. These tumors are usually solitary, more than 3 cm in diameter and occur in the pancreas in 80 percent to 90 percent of cases, mainly in the pancreatic tail

(50 percent to 75 percent) with 37 percent to 68 percent hepatic metastasis at diagnosis. Demonstration of elevated levels ( $>75$  pg/ml) of VIP confirms diagnosis in the clinical setting [2,3]. For localizing and staging of these tumors, somatostatin receptor scintigraphy with octreotide scan has been recommended as the best imaging technique [4]. Treatment preferences depend on the presence of metastasis. In metastatic tumors, long-acting somatostatin analogs are the drugs of choice. Somatostatin analogs are typically initiated at 20 mg daily dosage, and gradual escalation of the dose as needed, for optimal control of symptoms, is recommended [5]. Hepatic resection is indicated for the treatment of metastatic liver disease in the absence of diffuse bilobar involvement, compromised liver function, or extensive extrahepatic metastases [6].

Other treatment options have been described with no set recommendations. Interferon- $\alpha$  added to octreotide is used as one of the modalities for treatment of refractory diarrhea in these patients [7]. Experiences with chemotherapeutic agents are limited. Fjallskog et al. concluded that combined streptozotocin and liposomal doxorubicin is a safe and efficient treatment for endocrine pancreatic tumors. The efficacy seems to be comparable to that of combined streptozotocin and doxorubicin; whereas, the cardiac toxicity clearly favors using the liposomal drug combination [8]. Streptozotocin plus 5-fluorouracil produced objective responses in 17 out of 31 (54 percent) patients with a median duration of response of 23 months [9].

Medical management with octreotide analogs has proven useful in the management of pancreatic islet cell tumors with un-



**Figure 3.** Levels were consistently >400 pg/mL, and the patient was symptomatic on escalated dosing of Sandostatin. On introduction of TACE (Transcatheter Chemoembolization) with mitomycin c, cisplatin and doxorubicin, patient became asymptomatic and VIP levels decreased as shown in the graph.

resectable disease and/or metastases [10,11]. Neuroendocrine gastrointestinal tumors express somatostatin receptors (sstrs) in 80 percent to 90 percent of cases, and somatostatin analogs have become increasingly important in the management of these patients. Most of the currently available somatostatin analogs bind to the sstr2 and sstr5 receptor types and in higher doses to sstr3 of the sstrs 1-5 described. Clinical improvement during somatostatin analog therapy is mainly mediated via a direct inhibitory effect on hormone production from the tumors, seen in 30 percent to 70 percent of patients. Indirect non-tumor mediated effects on peripheral target organs contribute to the subjective improvement achieved in 30 percent to 70 percent of patients. Significant improvement of quality of life has been demonstrated with long-acting depot formulations. There is little or no effect on tumor growth during octreotide therapy. Tumor shrinkage has been reported in 10 percent to 20 percent of patients, but stabilization of tumor growth can be achieved in about half of the patients in eight to 16 months after starting treatment. Induction of apoptosis has been reported by octreotide analogs as a possible mechanism of action on these tumors [12]. Octreotide inhibits hormone secretion by various neuroendocrine tumors and may occasionally reduce metastatic tumor burden [13]. Vary-

ing data exist about the quantitative reduction of tumor size and symptomatic relief. Oberg et al. reported a significant tumor response in <5 percent of patients but a symptomatic response in 60 percent of patients [14]. Maton et al. observed 83 percent symptomatic response but fewer than 20 percent reduction in tumor size [15]. A case report by Kraenzlin et al. showed that long-acting Sandostatin not only controlled the diarrhea without side effects, but also appeared to have possibly induced a reduction in metastatic tumor size. Conventional measures of surgery, chemotherapy, and hepatic artery embolization ultimately failed to control the severity of diarrhea, resulting from vasoactive intestinal polypeptide hypersecretion [16]. Cho and Vinik evaluated tumor blood flow using angiography in eight patients with different types of neuroendocrine tumors receiving octreotide. They found a marked decrease in blood flow in two patients with gastrinomas and two patients with VIPomas, with a hypothesis that octreotide either decreases blood flow to these tumors or decreases tumor size or hormonal secretion [17].

Contrary to all these reports, VIP hypersecretion kept elevating in our patient, although long-acting octreotide analog doses were increased. Similar to our report, Lamberts et al. reported two patients with

metastatic VIPomas developed resistance to somatostatin analog with regard to clinical and inhibitory effect [18]. An “escape phenomenon” to somatostatin analog was noticed for a few days with a usual response after discontinuation of the treatment [19]. In another report, 10 patients with metastatic pancreatic endocrine tumors were treated with the long-acting somatostatin analog octreotide. Three patients showed no response, clinically or biochemically, and treatment was, therefore, withdrawn. The seven remaining patients continued treatment for a median period of 28 months (range 13-54 months). Treatment was initially effective, symptoms improved, and the concentrations of tumor-related hormones were reduced. Worsening of symptoms and rising levels of tumor-related hormone concentrations occurred at a median of five months (range 1-6 months) after the start of therapy and were initially reversed by increasing the dose of octreotide over a median of 10 months (range 6-16 months). However, after a median of 13 months (range 5-34 months) at the maximum dosage, symptoms recurred and were no longer responsive to a further increase in dosage of octreotide or other therapeutic measures. All patients died within five months once this “resistance phase” of their illness had been reached [20]. However, resistance was never confirmed on histological or biochemical studies. Arterial chemoembolization is recommended for patients with significant symptoms who have failed to respond to more conservative therapy and are not surgical candidates [21].

For patients with hepatic metastasis, initial expectant observation and medical management of symptoms is appropriate in view of the long and indolent course of the disease. As mentioned earlier, hepatic resection is indicated for the treatment of metastatic liver disease in the absence of diffuse bilobar involvement, compromised liver function, or extensive extrahepatic metastases. VIPomas are often large or metastasizing, but generally require surgical debulking to alleviate hormonal symptoms and have favorable survival outcomes [6].

In a clinical trial conducted by Eriksson et al., patients having midgut, foregut carcinoids and neuroendocrine pancreatic tumors, treatment of liver metastases by surgical resection and/or radiofrequency ablation (RFA) was successful in patients with midgut carcinoids with only less success in reducing symptoms in patients with foregut carcinoids or neuroendocrine tumors. In addition, patients with non-functioning neuroendocrine tumors may benefit from debulking procedure to reduce morbidity and improve survival. Proposal of surgical debulking or RFA as means that limit procedure-related morbidity and efficiently alleviate symptoms has been beneficial in these patients, especially as this disease has a high incidence of recurrence [6,22]. Azimuddin et al. reported that hepatic arterial embolization is the preferred management in these cases [23]. Case et al. confirmed the finding that hepatic artery embolization can be very effective and durable as a treatment modality for patients with metastatic VIPomas (or other neuroendocrine tumors) who are clinically symptomatic from the effects of hormone hypersecretion. It is applied as a palliative technique in symptomatic patients with unresectable hepatic metastasis [24]. Furthermore, the study of Gupta et al. at MD Anderson has compared embolization alone to chemoembolization of the hepatic artery and has concluded that in pancreatic islet cell tumors (without specifying the subtype of the tumor), chemoembolization has improved response rate by 50 percent compared to 25 percent with embolization alone. Moreover, chemoembolization of these tumors had a survival benefit as compared to embolization alone (31.5 months vs. 18.2 months) [25]. Yao et al. demonstrated that for unresectable but liver dominant disease, chemoembolization was the treatment of choice, with median survival of 32 months post chemoembolization and a five-year survival rate of 40 percent. Chemoembolization effectively controlled tumor growth and alleviated symptoms in 90 percent of patients [26]. This modality helped in controlling the symptoms of our patient. Moreover; the VIP levels trended down as shown by the graph

in Figure 3. Huang et al. concluded that treatment for metastatic pancreatic islet cell tumors require a multidisciplinary approach. Metastasis of the tumor is not a contraindication for aggressive therapy. Combined cytoreductive surgery and TACE can relieve symptoms and are of benefit for patients with pancreatic islet cell tumors with liver metastases [27].

Temozolomide is another treatment option for metastatic disease. As a monotherapy, it has acceptable toxicity and antitumoral effects in a small series of patients with advanced malignant neuroendocrine tumors with some radiologic responses [28].

## REFERENCES

- Friensen SR. Update on the diagnosis and treatment of rare neuroendocrine tumors. *Surg Clin North Am.* 1987;67:379.
- Perry RR, Vinik AI. Clinical review: diagnosis and management of functioning islet cell tumors. *J Clin Endocrinol Metab.* 1995;80:2273.
- Lecorguille M, Hammel P, Couvelard A, et al. [jejunal vipoma]. *Gastroenterol Clin Biol.* 2004;28:797.
- Melen-Mucha G, Lawnicka H, Kierszniewska-Stepien D, Komorowski J, Stepien H. The place of somatostatin analogs in the diagnosis and treatment of the neuroendocrine glands tumors. *Recent Patents Anticancer Drug Discov.* 2006;1(2):237-54.
- Newman CB, et al. Safety and efficacy of long term octreotide therapy of acromegaly: Results of a multicenter trial in 103 patients — a clinical research center study. *J Clin Endocrinol Metab.* 1995;80:2768.
- Akerström G, Hellman P. Surgery on neuroendocrine tumours. *Best Pract Res Clin Endocrinol Metab.* 2007;21(1):87-109.
- Tiensuu Janson EM, Ahlström H, Andersson T, Oberg KE. Octreotide and interferon alfa: a new combination for the treatment of malignant carcinoid tumours. *Eur J Cancer.* 1992;28A(10):1647-50.
- Fjallskog ML, Janson ET, Falkmer UG, Vatn MH, Oberg KE, Eriksson BK. Treatment with combined streptozotocin and liposomal Doxorubicin in metastatic endocrine pancreatic tumors. *Neuroendocrinology.* 2008;88(1):53-8. Epub 2008 Feb 18.
- Eriksson B, Oberg K. An update of the medical treatment of malignant endocrine pancreatic tumors. *Acta Oncol.* 1993;32(2):203-8.
- Peng SY, Li JT, Liu YB, Fang HQ, Wu YL, Peng CH, et al. Diagnosis and treatment of VIPoma in China: (case report and 31 cases review) diagnosis and treatment of VIPoma. *Pancreas.* 2004;28(1):93-7.
- O'Dorisio T, Mekhjian HA, Gaginnella TS. Medical therapy of VIPomas. *Endocrinol Metab Clin North Am.* 1989;18:545-56.
- Eriksson B, Oberg K. Summing up 15 years of somatostatin analog therapy in neuroendocrine tumors: future outlook. *Ann Oncol.* 1999;10(Suppl 2):S31-8.
- Kraenzlin ME, Ch'ng JL, Wood SM, Carr DH, Bloom SR. Long-term treatment of a VIPoma with somatostatin analogue resulting in remission of symptoms and possible shrinkage of metastases. *Gastroenterology.* 1985;88(1 Pt 1):185-7.
- Oberg K. Chemotherapy and biotherapy in the treatment of neuroendocrine tumours. *Ann Oncol.* 2001;12(Suppl 2):S111-4.
- Maton PN, Gardner JD, Jensen RT. Use of long-acting somatostatin analog SMS 201-995 in patients with pancreatic islet cell tumors. *Dig Dis Sci.* 1989;34(3 Suppl):28S-39S. Review.
- Kraenzlin ME, Ch'ng JL, Wood SM, Carr DH, Bloom SR. Long-term treatment of a VIPoma with somatostatin analogue resulting in remission of symptoms and possible shrinkage of metastases. *Gastroenterology.* 1985;88(1 Pt 1):185-7.
- Cho KJ, Vinik AI. Effect of somatostatin analogue (octreotide) on blood flow to endocrine tumors metastatic to the liver: angiographic evaluation. *Radiology.* 1990;177(2):549-53.
- Lamberts SW, Pieters GF, Meteselaar HJ, Ong GL, Tan HS, Reubi JC. Development of resistance to a long-acting somatostatin analogue during treatment of two patients with metastatic endocrine pancreatic tumours. *Acta Endocrinol (Copenh).* 1988;119(4):561-6.
- Koelz A, Kraenzlin M, Gyr K, Meier V, Bloom SR, Heitz P, et al. Escape of the response to a long-acting somatostatin analogue (SMS 201-995) in patients with VIPoma. *Gastroenterology.* 1987;92(2):527-31.
- Wynick D, Anderson JV, Williams SJ, Bloom SR. Resistance of metastatic pancreatic endocrine tumours after long-term treatment with the somatostatin analogue octreotide (SMS 201-995). *Clin Endocrinol (Oxf).* 1989;30(4):385-8.
- Perry LJ, Stuart K, Stokes KR, Clouse ME. Hepatic arterial chemoembolization for metastatic neuroendocrine tumors. *Surgery.* 1994;116(6):1111-6, discussion 1116-7.
- Eriksson J, Stålberg P, Nilsson A, Krause J, Lundberg C, Skogseid B, et al. Surgery and radiofrequency ablation for treatment of liver metastases from midgut and foregut carcinoids and endocrine pancreatic tumors. *World J Surg.* 2008;32(5):930-8.
- Azimuddin K, Chamberlain RS. The surgical management of pancreatic neuroendocrine tumors. *Surg Clin North Am.* 2001;81(3):511-25.

24. Case CC, Wirfel K, Vassilopoulou-Sellin R. Vasoactive intestinal polypeptide-secreting tumor (VIPoma) with liver metastases: dramatic and durable symptomatic benefit from hepatic artery embolization, a case report. *Med Oncol.* 2002;19(3):181-7.
25. Gupta S, Johnson MM, Murthy R, Ahrar K, Wallace MJ, Madoff DC, et al. Hepatic arterial embolization and chemoembolization for the treatment of patients with metastatic neuroendocrine tumors: variables affecting response rates and survival. *Cancer.* 2005;104(8):1590-602.
26. Yao KA, Talamonti MS, Nemcek A, Angelos P, Chrisman H, Skarda J, et al. Indications and results of liver resection and hepatic chemoembolization for metastatic gastrointestinal neuroendocrine tumors. *Surgery.* 2001;130(4):677-82, discussion 682-5.
27. Huang YH, Lee CH, Wu JC, Wang YJ, Chang FY, Lee SD. Functional pancreatic islet cell tumors with liver metastasis: the role of cytoreductive surgery and transcatheter arterial chemoembolization: a report of five cases. *Zhonghua Yi Xue Za Zhi (Taipei).* 1998;61(12):748-54.
28. Ekeblad S, Sundin A, Janson ET, Welin S, Granberg D, Kindmark H, et al. Temozolomide as monotherapy is effective in treatment of advanced malignant neuroendocrine tumors. *Clin Cancer Res.* 2007;13(10):2986-91.