

## Testicular Germ Cell Tumors: Serological and Immunohistochemical Diagnosis

Ivan Damjanov\*

Department of Pathology and Laboratory Medicine, The University of Kansas School of Medicine, Kansas City, KS 66160, USA

**Correspondence:** [idadmiano@kumc.edu](mailto:idadmiano@kumc.edu); Tel.: + 011 267 400 9562; Fax.: + 011 913 588 8780

**Received:** 21 December 2020; **Accepted:** 25 December 2020

### Abstract

This review deals with serologic and immunohistochemical tumor markers used in clinical laboratories for the diagnosis of testicular germ cell tumors. Time tested serologic markers such as alpha-fetoprotein, human chorionic gonadotropin, and lactate dehydrogenase are routinely used in the work-up of patients with testicular tumors. Professional organizations regulating the practice of medicine in most countries worldwide require that the laboratory values for these serologic reactants be included in the pathology reports on testicular tumors as part of the tumor staging process. Immunohistochemical markers of testicular germ have been identified and widely tested during the first two decades of the XXI century. We have selected the most useful immunohistochemical markers from a few of these markers and discussed them in this review. **Conclusion.** Published data show that testicular tumor markers are widely used in routine practice. The study of tumor markers has improved the pathologic and clinical diagnosis of testicular germ cell tumors and has thus contributed to their treatment.

**Key Words:** Testicular Tumors ■ Germ Cell Tumors ■ Serologic Diagnosis ■ Immunohistochemistry ■ Tumor Markers.

### Introduction

Lecturing for many years to medical students about testicular tumors, I adopted the same principle that the U.S. Navy applied to the design of new weapons in the 1960's. This principle is best known as *KISS*, an acronym, which stands for "keep it simple, stupid" (1).

Using the *KISS* principle, in these simplified lectures, I would tell my students that testicular tumors are "more than 90 percent tumors":

- More than 90% are malignant;
- More than 90% are of germ cell origin and thus classified as germ cell tumors (GCT);
- More than 90% sporadic (i.e., not related to exogenous or endogenous or genetic factors);
- More than 90% are diagnosed in adult males in the 20-45 years age group and

- More than 90% of patients have long-term survival and most are cured by modern therapeutic approaches.

Even though testicular tumors account for only 1% of malignant neoplasms in males, they have become a poster example of malignant tumors that can be cured by combining surgery, chemotherapy, and, if need be, radiation therapy, as reviewed in several recent publications (2-5). These tumors, which have previously accounted for significant cancer related mortality in adult men, who were in the most productive period of their lives were literally conquered by modern medicine.

The study of serologic and immunohistochemical tumor markers, to be reviewed here, has contributed to diagnosis and treatment of GCT.

### Clinicopathologic Classification

Pathology has made significant contributions to this modern medicine paradigmatic success sto-

\*ORCID: <http://orcid.org/0000-0002-1394-6052>

ry. It all began with the groundbreaking study of Friedman and Moore (6), who examined more than 900 testicular tumors diagnosed in soldiers of the U.S. Armed Forces during World War II. The basic tenets of that study were subsequently confirmed and expanded in numerous clinicopathologic studies. Widely accepted worldwide, these classifications were disseminated in the atlases of the Armed forces Institute of Pathology (AFIP) and included in consecutive classifications of the World Health Organization (WHO), the latest of which was published in 2016 (7).

Histopathologic classification of testicular tumors is primarily based on the histogenesis of these tumors. Even though testicular tumors' exact histogenesis has not been fully elucidated, all the data indicate that most neoplasm can be traced to the germ cell line and its early embryonic and fetal precursors (8-11). Subclassification of germ cell tumors is essential, primarily because of the biological and clinical differences between seminoma on one hand side and mixed germ cell tu-

mors, also known clinically as “nonseminomas” or “nonseminomatous germ cell tumors (NSGCT)” on the other (7).

According to the most widely used classification of germ cell tumors, testicular GCT can be classified into three categories, which have distinct features: patients' age, histologic characteristics, and molecular and cellular histogenesis (8, 11). Type I GCT include teratomas and yolk sac tumors of neonates and infants, which do not develop from a preexistent intratubular germ cell neoplasia in situ (GCNIS) (Figure 1). Type II GCT develop from preexistent GCNIS of the testis and include seminomas and mixed (nonseminomatous) germ cell tumors (also known as NSGCT), which develop mostly in adolescents and adults. Type III category of GCT includes only spermatocytic tumors (previously known as spermatocytic seminoma), which develop without a preinvasive GCNIS in older adults. Over 90% of all invasive GCT develop from GCNIS and belong to type II neoplasms.

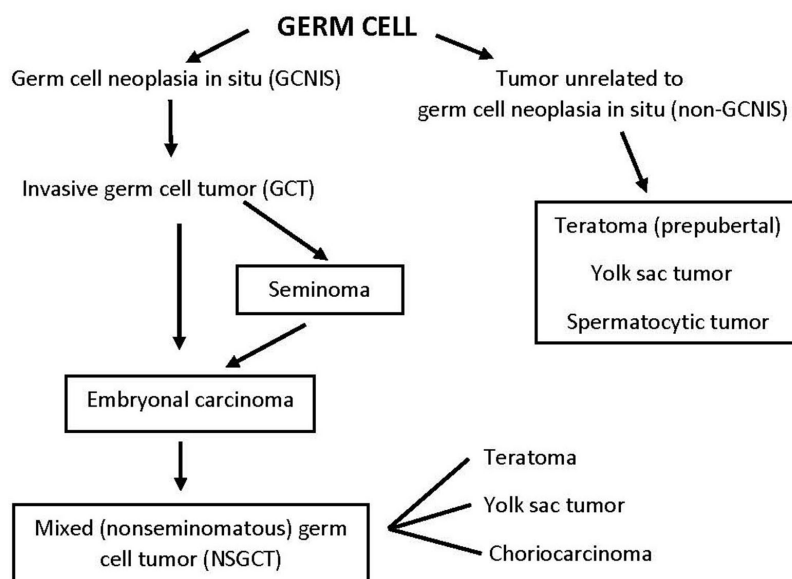


Figure 1. Histogenetic classification of testicular germ cell tumors. Tumors may develop directly from intratubular germ cells or a preinvasive form of intratubular germ cell neoplasia in situ (GCNIS). Tumors that develop directly from germ cells include prepubertal teratoma and childhood yolk sac tumor, and spermatocytic tumor. Most invasive GCTs are classified as type II GCT that develop from GCNIS. GCNIS give rise to invasive malignant stem cells, which may be classified as embryonal carcinoma or seminoma. Seminoma is the most common GCT. The malignancy of seminoma cells may progress, and they become embryonal carcinoma. Embryonal carcinoma cells are the stem cells of mixed (nonseminomatous) germ cell tumors. In addition to their malignant stem cells (embryonal carcinoma), the components of these mixed germ cell tumors include teratoma, yolk sac, and choriocarcinoma. These components may grow clonally and give rise to pure teratoma, yolk sac tumor or choriocarcinoma.

Tumors originating from sex cord lineages or nonspecific stromal cells are less common (12-15). These tumors are mentioned only for the completeness of the presentation and will not be discussed in detail. Tumors originating from testicular adnexa, including rete testis, or tunica vaginalis (mesothelial cells) and some embryonic structures that normally involute during fetal life, such as müllerian ducts, are also quite rare (16-20). Metastatic tumors to the testis and lymphoma are rare but must be considered in the differential diagnosis, especially in elderly patients (21, 22).

Algorithms used by diagnostic pathologists are practice-proven thus straight forward and include the following questions sequentially:

- 1) Is this testicular lesion a neoplasm or something else?
- 2) If it is a neoplasm, is it a primary testicular/epididymal tumor or a metastasis?
- 3) If it is a primary tumor, is it originating from germ cells and their precursors, or from sex cord cells, stromal cells of adnexal structures, or embryonic
- 4) If the tumor is a GCT, is it a seminoma or NSGCT?
- 5) If the tumor is an NSGCT, its microscopic components must be identified and listed, such as embryonal carcinoma (EC), teratoma, yolk sac tumor (YST), or choriocarcinoma. For example, it is well known that the extent of embryonal carcinoma in an NSGCT determines the malignancies of such a tumor—the more EC, the more likely the tumor be more malignant. Seminoma elements may be found in 46.9% of mixed germ cell tumors (23), which are otherwise classified as NSGCT. However, the admixture of seminoma to NSGCT does not have any clinical significance.

As stated above, more than 90% of all testicular tumors are of germ cell origin. Accordingly, unless specified otherwise, most clinical and histopathologic problems encountered in the diagnostics and treatment of testicular tumors relate to germ cell tumors. As reported in a large recent study of more than 5 000 testicular tumors from North Rhein-Westphalia, Germany, 93.9% of all tumors

were of germ cell origin (23). Approximately 5% of testicular tumors included in cancer registers and national statistics seem to be inadequately documented and cannot be appropriately classified (23). Novel or controversial new testicular tumor entities continuously appear in the literature and are not correctly classified, requiring additional studies (24-28).

## Tumor Markers

Tumor markers used in clinical and pathologic practice can be classified as a) serologic markers secreted by or released from the tumor cells and readily detectable in serum, and b) cell-related markers detectable by immunohistochemistry or molecular biologic techniques applied to tumor tissue that was obtained by biopsy or surgical intervention. In this review, we will limit our discussion to tumor markers, which have proven their usefulness for diagnosing testicular tumors.

### *Serologic Tumor Markers*

From the historical point of view, testicular tumors have played an important role in defining tumor markers, such as human chorionic gonadotropin (hCG) (29-31), alpha fetoprotein (AFP) (32-34), placental like alkaline phosphatase (34) and lactate dehydrogenase (LDH) (35). Serologic tumor markers AFP, hCG, and LDH are currently routinely used in testicular tumors' clinical work-up and are included as part of the staging protocol for germ cell tumors (36-41), and are also used for formulating the prognosis after treatment (42).

**Human Chorionic Gonadotropin** (hCG) is produced by placental syncytiotrophoblasts during pregnancy (43). As a tumor marker, it is a reliable marker for choriocarcinoma originating from the placenta, as well as ovarian and testicular choriocarcinomas. Patients with mixed germ cell tumors containing choriocarcinoma elements are also positive for hCG (44).

hCG consist of two chains labeled alpha and beta (43). The alpha subunit of hCG has a molecular weight of approximately 14.5 kD. It is identi-

cal to the alpha subunit of three pituitary trophic hormones: two gonadotropins (FSH and LH) and thyroid-stimulating hormone (TSH). The beta subunit ( $\beta$ -hCG) has a molecular weight of approximately 22.2 kD and is found only in hCG. It is encoded by the *HCGB* gene complex comprising seven *HCGB* genes that form a cluster on the long arm of chromosome 19 (45).

hCG detected in serum can be further subclassified depending on the analytical technique used. To improve the diagnostic value, proposals have been made to selectively look for these subtypes such as  $\beta$ -subunit hCG,  $\beta$ -core fragment hCG, and hyperglycosylated, nicked hCG. However, most laboratories report either regular intact hCG or  $\beta$ -hCG. Hyperglycosylated hCG is the form seen in choriocarcinoma.

$\beta$ -hCG is measured routinely in the serum of testicular cancer patients. Elevated concentrations of  $\beta$ -hCG found in approximately 50% of patients with NSGCT (41). The serum levels of  $\beta$ -hCG vary depending on the tumor stage and the extent of choriocarcinoma elements in each tumor. Pure choriocarcinomas are always positive.

Immunohistochemistry with polyclonal or monoclonal antibodies to  $\beta$ -hCG is widely used in daily histopathology practice to identify choriocarcinoma cells in the tumor tissue. Since tumor cells secrete  $\beta$ -hCG into the plasma, it will often be seen inside the blood vessels of the tumor and permeating the tissues near the neoplastic choriocarcinoma cells.

Scattered syncytiotrophoblastic multinucleated giant cells can be seen in approximately 20% of seminomas. Patients who have such seminomas have elevated levels of hCG can be elevated in serum, albeit in concentrations that are much lower than those in patients with NSGCT (41).

The half-life of hCG in serum is 2-3 days. Accordingly, one can expect normalization of serum hCG in about 10-15 days (five half-lives) after removing the tumor. However, such a normalization does not exclude metastases composed of embryonal carcinoma cells, which do not produce hCG. Recurrence of NSGCT is associated with rising hCG levels in serum in approximately 25% of cases (41).

**Alpha Fetoprotein** is a 70kD protein normally found in fetal serum. In the early stages of intra-uterine life, it is produced by the yolk sac and, after that by the fetal liver and parts of the gastrointestinal tract (46). The postnatal liver continues to secrete AFP, and therefore the serum levels of AFP remain elevated during infancy and even in early childhood. The *AFP* gene is located on the long arm of chromosome 4 (4q25) (47).

AFP is a widely used tumor marker, most useful in diagnosing hepatocellular carcinoma, NSGCT of the testis, yolk sac tumor of infancy and childhood, extragonadal germ cell tumors, and mixed germ cell tumors of the ovary. AFP is a reliable marker for yolk sac components of germ cell tumors in testicular and ovarian tumors. Overall, AFP is elevated in the serum of 25% of all patients with testicular germ cell tumors (41). In the subgroup of patients with NSGCT, serum AFP levels are elevated in 60% of cases (41).

The half-life of AFP is approximately 5–7 days, and therefore, one could expect the serum AFP to normalize 25–35 days (five half-lives) after orchidectomy for NSGCT (37, 44). False-positive results could result from liver injury related to chemotherapy or even some non-neoplastic liver diseases such as steatohepatitis or chronic viral hepatitis and cirrhosis. In patients receiving chemotherapy, tumor lysis syndrome may include elevated serum AFP levels, even though there are no viable tumor cells in the treated patient's body. Three isoforms of AFP are known to appear in blood: L1 found in the serum of patients with non-neoplastic liver disease, L2 found in patients with yolk sac tumors, and L3 in patients with hepatocellular carcinoma (48). In routine clinical practice, these subtypes are of limited significance.

Immunohistochemistry with polyclonal or monoclonal antibodies is routinely used in the work-up testicular NSGCT, extragonadal germ cell tumors, and yolk sac tumors (49, 50). AFP is a useful marker for most forms of yolk sac tumors, even though some variants, such as parietal yolk sac tumor, are negative. This is important to keep in mind because AFP positive yolk sac rich tumors may undergo clonal evolution and transform into AFP

---

negative neoplasms (51). It is also important to note that AFP can be elevated in the serum of patients who have adenocarcinomas of the gastrointestinal tract and the upper aerodigestive system (37).

**Placental Alkaline Phosphatase** also known as Regan isoenzyme, is one of the four alkaline phosphatases (AP) typically found in the human tissues from which they are released into the circulation (52). Functionally, they are all hydrolases that have their optimal enzymatic activity in an alkaline milieu. Each of these four alkaline phosphatases is derived from a different organ and encoded by its gene. In addition to PLAP, other three forms are known as hepatic, bone and kidney AP, intestinal A.P., and placental like AP. *PLAP* is encoded by a gene on the long arm of chromosome 2 (2q37), which also contains the genes for placental-like and intestinal AP (53). *PLAP* gene is usually expressed in trophoblastic cells and fetal primordial germ cells. It is not expressed on normal spermatogenic cells of the adult testis. Monoclonal antibodies to PLAP and those specific for other isoenzymes of AP are available, making their immunohistochemical localization in tissue sections possible (54).

PLAP was initially considered a useful marker for seminoma. However, later on, it became evident that it is also expressed on the cells forming the intratubular GCNIS and embryonal carcinoma cells, yolk sac tumor, and choriocarcinoma. Accordingly, it is a useful tumor marker for testicular and ovarian, and extragonadal GCTs (54-56). Immunohistochemical studies with monoclonal antibodies disclosed that AP of testicular germ cell tumors could be either PLAP or placental-like isoenzyme (54), confounding the issue of specificity of PLAP as a tumor marker. Subsequent studies disclosed PLAP on some non-germ cell tumors. Furthermore, it was detected in the serum of smokers, which reduced its overall utility as a tumor marker (57). Antibodies to PLAP are still used in clinical laboratories but considerably less often than the newer reagents.

**Lactate Dehydrogenase** (LDH) is a ubiquitous enzyme present in nearly all human tissues, from which it is released into the serum (58). Structur-

ally it is a tetramer composed of four subunits, the most common being LDH-M and LDH-H protein, encoded by two *LDH* genes, called *LDHA* and *LDHB*, respectively (59). Serum LDH and its main isoenzymes are routinely measured in clinical laboratories.

LDH is found inside the cell of most human tumors (60, 61) and is thus often measured in cancer patients. Due to its wide distribution in normal and neoplastic tissues, it cannot be used as a diagnostic tumor marker. Nevertheless, serum LDH values can be used as a valuable laboratory finding, reflecting tumor burden, invasiveness of neoplastic cells, and the extent of tumor spread and metastasis. In patients receiving chemotherapy, serum LDH can be used to monitor the residual total tumor mass and spontaneous and chemotherapy-induced tumor necrosis.

American Joint Committee on Cancer (AJCC) staging system for testicular tumors (39) requires from clinicians to record the serum levels of LDH at the time of diagnosis and periodically monitored them after surgical intervention and chemotherapy. In patients diagnosed with small tumors limited to the testis, serum LDH is within normal limits in 80-90% of cases. As the tumors grow, serum levels of LDH will rise proportionally to the size of the tumor. Patients with metastatic tumors have almost all high LDH serum levels. Likewise, tumor lysis is accompanied by markedly increased levels of serum LDH. Recurrence of tumors is also typically associated with high serum LDH levels.

### Stem Cell Markers of Germ Cell Tumors

Testicular tumor stem cell markers have been studied immunohistochemically and by means of molecular biology. These studies' primary aims were to elucidate the histogenesis of germ cell tumors, define the developmental pluripotency of tumor cells and their pluripotentiality, and improve the histopathologic diagnosis of germ cell tumors. The salient data from these studies have been reviewed comprehensively (7-10, 62, 63). The important tumor cell markers identified so far will be briefly discussed here.

### **Octamer-Binding Transcription Factor 4 (Oct4)**

Oct4 (also known as Oct3, Oct3/4, Pou1f1, POU5F1, and Otf3) is a member of the POU-domain family of octamer-binding transcription factors expressed in early murine embryonic cells and primordial germ cells (8-10, 57). *OCT4* gene has been localized to chromosome 6p21.3 (64).

*OCT4* gene accounts for the stemness and pluripotency of embryonic cells before implanting the embryo and early stages of post-implantation development. If injected into differentiated somatic cells and three other genes (*SOX2*, *MYC*, and *KLF4*), it may transform them into developmentally pluripotent undifferentiated embryonic stem cells (65). It is also expressed in primordial germ cells in the developing fetus but is not apparent in adult spermatogenic cells. *OCT4* is also expressed in human embryonic stem cells (EST) cultured in vitro. If these cells are injected into immunodeficient mice, they form benign teratoma composed of somatic tissues. These teratoma cells do not express *OCT4* (66). Malignant stem cells produced from EST also express *OCT4* (67). However, if these stem cells are allowed to differentiate into yolk sac cells or somatic tissues, they lose *OCT4* activity.

*OCT4* protein is localized in the nucleus. It is resistant to formalin fixation, and thus it can be demonstrated by immunohistochemistry in tissues. As one would expect from these experimental data mentioned above, testicular embryonal carcinoma cells are also Oct4 positive (68, 69). Furthermore, seminomas and intratubular preinvasive germ cell neoplasia in situ cells are also positive. These studies have also shown that Oct4 is not expressed in yolk sac tumor cells, choriocarcinoma and somatic cells forming teratoma components of NSGCT. The cells of the spermatocytic tumor also negative for Oct4 (11). Several malignant tumors may be positive for Oct4, such as carcinoma of the lung or thymus (57).

### ***c-KIT* Protooncogene (CD117)**

*c-KIT* proto-oncogene was initially identified as a human equivalent of the animal oncogene of the Hardy-Zuckerman IV feline sarcoma virus (HZ4-

FeSV), including its transforming activity (57, 70, 71). The human *c-KIT* gene has been localized to chromosome 4q12 (72).

The human *c-KIT* gene encodes the type III tyrosine kinase receptor, also known as tyrosine-protein kinase KIT, or mast/stem cell growth factor receptor (SCFR). Most pathologists know it as CD117 (73) since it reacts with the antibody to the cluster of differentiation 117 (CD117). It occurs in multiple transcript variants and isoform and is expressed on numerous cells. The c-KIT enzyme plays an important role in many physiological processes such as cell growth and proliferation, melanogenesis, hematopoiesis, angiogenesis and gametogenesis. Dysregulation of c-Kit signaling or gain-of-function mutations of *c-KIT* gene plays a role in the pathogenesis of various neoplasms (71, 72).

In a comprehensive review of normal tissue and tumors, Miettinen and Lasota (73) have found CD117 immunoreactivity on various cell types including mast cells, some hematopoietic stem cells, germ cells, melanocytes, and Cajal cells of the gastrointestinal tract. Other c-KIT-positive normal cells include epithelial cells in skin adnexa, breast, and subsets of cerebellar neurons. c-KIT positivity has been variably reported in sarcomas such as angiosarcoma, Ewing sarcoma, synovial sarcoma, leiomyosarcoma, and malignant fibrous histiocytoma (MFH); results of the last three are controversial. In addition, c-KIT is expressed in pulmonary and other small cell carcinomas, adenoid cystic carcinoma (breast and salivary glands), renal chromophobe carcinoma, thymic, and some ovarian and few breast carcinomas (usually with basal-like and triple-negative phenotype).

*c-KIT* gene is expressed in normal fetal gonocytes but not in adult spermatogonia and their derivatives (74). It is expressed in intratubular GCNIS and seminoma (75, 76). Approximately 30% of seminomas are positive in the testis, with a higher rate of positivity recorded in bilateral tumors, extragonadal seminomas, and dysgerminomas (77). Embryonal carcinoma cells and other components of NSGCT are negative. Immunohistochemistry with antibodies to c-KIT is useful when trying to distinguish seminoma from embryonal carcinoma cells.

### **Sall4**

Sall4 is a zinc-finger transcription factor originally cloned on sequence homology to *Drosophila* homeotic genes of the Spalt family (57, 78-80). The human *SALL4* gene is located on chromosome 20q13.2 (80). It interacts with three other genes, *OCT4*, *NANOG*, and *SOX2* in maintaining the stemness and pluripotency of early embryonic cells and *in vitro* propagated murine and human embryonic stem cells.

*SALL4* gene is expressed on primordial germ cells and weakly several fetal organs during early stages of organogenesis, such as neural tube formation, intestinal differentiation, and hepatogenesis. In the testis, it is weakly expressed in normal spermatogonia, in contrast to intense immunohistochemical staining of the nuclei of GCNIS, embryonal carcinoma, and seminoma. Antibodies to Sall4 are among the rare antibodies that react with some of the cells in spermatocytic tumors (57). It is negative in choriocarcinomas, even though sometimes it may react with cytotrophoblastic cells (57). *SALL4* is strongly expressed in yolk sac tumors. In the teratomatous part of the mixed germ cell tumors antibodies to Sall4 react with neural tubes and neural cell precursors, as well as many other immature cells (81, 82).

As stated by Miettinen et al. (83), *SALL4* is an excellent marker for germ cell tumors, as long as one keeps in mind that it may be expressed in some immature somatic tissues of teratomas. *SALL4* can be expressed in poorly differentiated serous carcinoma of the ovary, high-grade urothelial carcinoma, and gastric adenocarcinoma (especially the intestinal type). *SALL4* was only rarely ( $\leq 5\%$ ) expressed in common adenocarcinomas, such as breast, large intestine, and squamous cell carcinomas. Many *SALL4*-positive carcinomas are poorly differentiated and often show strong immunohistochemical positivity mimicking its expression in GCT. *SALL4* is not found in hematopoietic tumors and lymphomas, and most sarcomas, but may be found in rhabdoid tumors of the kidney and extrarenal sites and the Wilms tumor (nephroblastoma).

### **Sox2**

Sox2 protein is encoded by the gene *SOX2*, which belongs to the family of some 20 *SOX* genes (84). The term *SOX* is a contraction for their full designation, including keywords such as SRY (sex-determining region Y) and high mobility group (HMG) box. These proteins' functions range from embryonic development and stem cell maintenance to homeostasis in adult tissues.

*SOX2* gene, one of the *SOX* family members, was discovered and characterized in humans in 1994 and then localized to the chromosome 3q26.3-q27 (85). *SOX2* has a crucial role in stem cell maintenance, lineage fate determination and reprogramming of somatic cells back towards pluripotency. *SOX2* plays a role in the pathogenesis of several forms of cancer, including testicular germ cell neoplasia, usually by interacting with the protein product of the *OCT4* gene (86). During the testis' fetal development and in testicular germ cell tumors, it is reciprocally expressed to Sox17, another protein of this group, encoded by a gene located on the 8q11.23 chromosome (57, 86).

Studies performed *in vitro* on ESC, human embryonal carcinoma cells and TCam-2 cell line that has features of seminoma show that Sox2 interacts with Oct4 and is essential for maintaining the undifferentiated state by activating pluripotency-linked genes (86-88). In contrast to Oct4, which is present in primordial germ cells and fetal gonocytes, suppressing these cells' apoptosis, Sox2 is not found in these cells. These cells contain, however, Sox17. As expected, GCNIS and seminoma cells are positive for Oct4 and Sox17 but negative for Sox2. On the other hand, embryonal carcinoma cells are positive for Sox2 and Oct4 and negative for Sox17. Embryonal carcinoma cell lines and seminoma like TCam-2 cell line cultured *in vitro* reflect the reciprocal expression of Sox2 and Sox17 in germ cell tumors as evidenced immunohistochemically (87, 88).

Immunohistochemical studies of testicular germ cell tumors show that *SOX2* gene is expressed in embryonal carcinoma cells, immature neuroepithelium, and some differentiated somatic tissues in teratomas, such as squamous epithelium

(57, 89, 90). GCNIS and seminoma, yolk sac tumor, and choriocarcinoma, as well as spermatocytic tumor, are negative. *SOX2* gene expression is not limited to GCT, and it may be expressed in several somatic adenocarcinomas, such as those of the ovary, breast, and prostate. Its expression correlates with the invasiveness of these cancers (91).

### **Other Markers for Embryonal Carcinoma and Seminoma**

Several antibodies raised against various human antigens have been found to react selectively with embryonal carcinoma cells or seminoma cells (92). This reactivity cannot be explained now. Nevertheless, some of these antibodies have been adopted in diagnostic histopathology and will be briefly reviewed here.

**CD30** is a cytokine receptor that belongs to the tumor necrosis factor superfamily (57). Antibodies to CD30 are used as a diagnostic marker in hematopathology. However, these antibodies also react quite specifically with embryonal carcinoma cells in various GCT (92, 93). Overall, CD30 is considered a useful marker for embryonal carcinomas, especially if there is a need to distinguish embryonal carcinoma from seminoma or yolk sac tumors, which are negative for this marker. CD30 is not expressed in GCNIS either. Some seminomas contain scattered CD30 positive cells; most likely, these cells are nascent embryonal carcinoma cells within those seminomas that are abortively trying to differentiate into embryonal carcinoma (57). Embryonal carcinoma cells surviving chemotherapy often lose CD30, and accordingly, antibodies to CD30 should not be used for identifying embryonal carcinoma cells in post-chemotherapy patients (94).

**Podoplanin** (PDPN) is a transmembrane sialoglycoprotein found in numerous tissues, most notably lymphatic endothelium (57). Its name relates to the fact that it was identified in glomerular podocytes, but it is also known as M2A (D2-40) antigen and gp36 (aggrus, T1A-2) (95). The best-known commercially available monoclonal antibody reacting with PDPN is D2-40. Antibody D2-

40 reacts with fetal gonocytes, but not with spermatogenic cells in the adult seminiferous tubules (95, 96). However, it is positive in GCNIS and seminoma and could be considered an excellent marker for seminomas. However, a certain number of embryonal carcinomas react with D2-40 antibody as well (97). Therefore, Lau et al. (97) warn that D2-40 is not always a reliable antibody for distinguishing seminomas from embryonal carcinoma and recommend using antibodies to CD117 and CD30 instead.

**Other Antibodies**, usually in the monoclonal form, have been tested on germ cell tumors to identify diagnostic tumor cell markers. Some of these markers have been reviewed in detail by Favilla et al. (92), Preda and Nogales (57), and Oosterhuis and Looijenga (76). Most of these markers have not been adopted for routine usage in diagnostic pathology laboratories, even though they have been extensively tested in investigative studies. Expression of potential tumor markers such as doublesex and mab-3 related transcription factor 1 (encoded by the gene *DMRT1*) has been registered in very rare testicular GCT, such as spermatocytic tumors and mixed germ cell-sex cord Sertoli cell tumors; reagents for such markers will be limited in use to only highly specialized laboratories (98). Some of potentially useful GCT markers including proteins encoded by genes such as *NANOG*, *LIN28*, *TCL-1*, *UTF-1*, *KLF4*, *AP-2 $\gamma$* , *IMP3* have been reviewed recently (57, 92).

It is worth mentioning that antibodies to some ubiquitous cell components, such as cytokeratins, can be used in the immunohistochemical evaluation of some germ cell tumors (99). However, such antibodies are best used if included in a diagnostic panel with other reagents. Positive or negative results obtained with such antibodies are thus interpreted in the context of other findings. On the other hand, some antibodies considered to be diagnostic for certain pathological entities are occasionally found to react with GCT and could cause a diagnostic pitfall, as in terminal deoxynucleotidyl transferase (TdT), a well-known hematopathologic biomarker (100). Likewise, thyroid transcription factor 1 (encoded by the gene *TTF-1*), a reli-

---



able marker of the thyroid and pulmonary cancers, may be positive in some yolk sac tumors (101).

### ***Yolk Sac Tumor Markers***

Yolk sac tumors (YST) of the infantile testis and the yolk sac components of mixed germ cell tumors react with several antibodies, some of which have proven to be useful in histopathological practice. Since YST presents in various microscopic patterns (101), such tumors' immunohistochemical profile may be quite variable.

Alpha-fetoprotein is a reliable yolk sac marker, discussed above. However, AFP is expressed unevenly in yolk sac tumors, and the interpretation of spotty findings may be problematic. Furthermore, as a secretory protein, it is found in the plasma, and accordingly, the staining of tissue sections may be smudgy. Additional markers have thus been used for immunohistochemical diagnosis of yolk sac tumor, usually to prove their GCT nature and/or early endodermal or hepatoid differentiation.

The most reliable GCT marker for yolk sac tumors is *SALL4*. *PLAP* is also positive, whereas the tumor cells are negative for *SOX2*, *OCT4*, and *CD117* (102). YSTs are also positive for *CDX2*, an endodermal and intestinal marker, as well as for glypican 3 and *GATA3*. Markers for hepatoid differentiation such as *HEPAR1*, hepatocyte nuclear factor 1  $\beta$  (103, 104) are also useful markers for YST. Zinc finger and BTB domain containing 16 (*ZBTB16*), a gene expressed during spermatogenesis, is another promising YST marker (105).

### **Conclusions and Future Directions**

Serologic and immunohistochemical markers for GCT have been extensively studied during the last 30 years. Reagents for the most useful markers have been included in the standard sets used in clinical practice. Genetic and molecular biologic profiling of GCT has been performed in numerous laboratories providing genetic underpinning to the clinical and serologic tests. Many of these genetic studies, including those that are still in the experimental stage, have been reviewed in detail in

several lengthy articles (106-113), clearly showing that molecular biology will play a pivotal role in future research and many international efforts to refine the diagnosis of testicular GCT. Collaborative initiatives such as Gene Expression Omnibus (GEO), an international public repository that archives and freely distributes microarray and next-generation sequencing (NGS) data, could facilitate the search for novel GCT markers (114).

**Conflict of Interest:** The author declares that he has no conflict of interest.

### **References**

1. About KISS 2020 [cited 2020 Oct 10]. Available from: [https://en.wikipedia.org/wiki/KISS\\_principle](https://en.wikipedia.org/wiki/KISS_principle).
2. Bosl GJ, Motzer RJ. Testicular germ-cell cancer. *N Engl J Med*. 1997;337(4):242-53.
3. Hanna NH, Einhorn LH. Testicular cancer--discoveries and updates. *N Engl J Med*. 2014;371(21):2005-16.
4. Adra N, Einhorn LH. Testicular cancer update. *Clin Adv Hematol Oncol*. 2017;15(5):386-96.
5. Chieffi P, De Martino M, Esposito F. New Anti-Cancer Strategies in Testicular Germ Cell Tumors. *Recent Pat Anticancer Drug Discov*. 2019;14(1):53-9.
6. Friedman NB, Moore RA. Tumors of the testis; a report on 922 cases. *Mil Surg*. 1946;99(5):573-93.
7. Moch H HP, Ulbright TM, Reuter VE. WHO classification of tumours of the urinary system and male genital organs. 4th ed. Lyon: IARC; 2016.
8. Oosterhuis JW, Looijenga LH. Testicular germ-cell tumours in a broader perspective. *Nat Rev Cancer*. 2005;5(3):210-22.
9. Looijenga LH, Stoop H, Biermann K. Testicular cancer: biology and biomarkers. *Virchows Arch*. 2014;464(3):301-13.
10. Oosterhuis JW, Looijenga LHJ. Human germ cell tumours from a developmental perspective. *Nat Rev Cancer*. 2019;19(9):522-37.
11. Baraban EG, Cooper K. Pathogenesis of Testicular Germ Cell Neoplasia: A Conceptual Approach. *Adv Anat Pathol*. 2019;26(4):241-5.
12. Fankhauser CD, Grogg JB, Hayoz S, Wettstein MS, Dieckmann KP, Sulser T, et al. Risk Factors and Treatment Outcomes of 1,375 Patients with Testicular Leydig Cell Tumors: Analysis of Published Case Series Data. *J Urol*. 2020;203(5):949-56.
13. Zhang C, Ulbright TM. Nuclear Localization of beta-Catenin in Sertoli Cell Tumors and Other Sex Cord-

- Stromal Tumors of the Testis: An Immunohistochemical Study of 87 Cases. *Am J Surg Pathol.* 2015;39(10):1390-4.
14. Conlon N, Schultheis AM, Piscuoglio S, Silva A, Guerra E, Tornos C, et al. A survey of DICER1 hotspot mutations in ovarian and testicular sex cord-stromal tumors. *Mod Pathol.* 2015;28(12):1603-12.
  15. Tatsi C, Fauz FR, Blavakis E, Carneiro BA, Lyssikatos C, Belyavskaya E, et al. Somatic PRKAR1A Gene Mutation in a Nonsyndromic Metastatic Large Cell Calcifying Sertoli Cell Tumor. *J Endocr Soc.* 2019;3(7):1375-82.
  16. Al-Obaidy KI, Idrees MT, Grignon DJ, Ulbright TM. Adenocarcinoma of the Rete Testis: Clinicopathologic and Immunohistochemical Characterization of 6 Cases and Review of the Literature. *Am J Surg Pathol.* 2019;43(5):670-81.
  17. Young RH, Scully RE. Testicular and paratesticular tumors and tumor-like lesions of ovarian common epithelial and mullerian types. A report of four cases and review of the literature. *Am J Clin Pathol.* 1986;86(2):146-52.
  18. Lin M, Awalt H, Ayala AG, Ro JY. Clear cell carcinoma of testis: A review. *Ann Diagn Pathol.* 2019;40:26-9.
  19. Butnor KJ, Pavlisko EN, Sporn TA, Roggli VL. Mesothelioma of the tunica vaginalis testis. *Hum Pathol.* 2019;92:48-58.
  20. Drevinskaite M, Patasius A, Kevlicius L, Mickys U, Smailyte G. Malignant mesothelioma of the tunica vaginalis testis: a rare case and review of literature. *BMC Cancer.* 2020;20(1):162.
  21. Ulbright TM, Young RH. Metastatic carcinoma to the testis: a clinicopathologic analysis of 26 nonincidental cases with emphasis on deceptive features. *Am J Surg Pathol.* 2008;32(11):1683-93.
  22. Ghazarian AA, Rusner C, Trabert B, Braunlin M, McGlynn KA, Stang A. Testicular cancer among U.S. men aged 50 years and older. *Cancer Epidemiol.* 2018;55:68-72.
  23. Stang A, Rusner C, Trabert B, Oosterhuis JW, McGlynn KA, Heidinger O. Incidence of testicular tumor subtypes according to the updated WHO classification, North Rhine-Westphalia, Germany, 2008-2013. *Andrology.* 2019;7(4):402-7.
  24. Paluru S, Ulbright TM, Amin M, Montironi R, Epstein JI. The Morphologic Spectrum of Sertoliform Cystadenoma of the Rete Testis: A Series of 15 Cases. *Am J Surg Pathol.* 2018;42(2):141-9.
  25. Gibson WE, Gonzalez RS, Cates JMM, Liu E, Shi C. Hepatic micrometastases are associated with poor prognosis in patients with liver metastases from neuroendocrine tumors of the digestive tract. *Hum Pathol.* 2018;79:109-15.
  26. Michalova K, Michal M Jr, Kazakov DV, Sedivcova M, Hes O, Hadravsky L, et al. Primary signet ring stromal tumor of the testis: a study of 13 cases indicating their phenotypic and genotypic analogy to pancreatic solid pseudopapillary neoplasm. *Hum Pathol.* 2017;67:85-93.
  27. Ulbright TM. Recently Described and Clinically Important Entities in Testis Tumors: A Selective Review of Changes Incorporated Into the 2016 Classification of the World Health Organization. *Arch Pathol Lab Med.* 2019;143(6):711-21.
  28. Michalova K, McKenney JK, Kristiansen G, Steiner P, Grossmann P, Putzova M, et al. Novel insights into the mixed germ cell-sex cord stromal tumor of the testis: detection of chromosomal aneuploidy and further morphological evidence supporting the neoplastic nature of the germ cell component. *Virchows Arch.* 2020;477(5):615-23.
  29. Zondek B. Gonadotropic Hormone in the Diagnosis of Chorionepithelioma. *Journal of the American Medical Association.* 1937;108(8):607-11.
  30. Kirwin TJ. Chorioepithelioma of the Testis, With Report of a Case Showing Extensive Metastasis. *J Urol.* 1937;38(1):91-9.
  31. Abelev GI. Alpha-fetoprotein in ontogenesis and its association with malignant tumors. *Adv Cancer Res.* 1971;14:295-358.
  32. Sell S, Becker FF, Leffert HL, Watabe L. Expression of an oncodevelopmental gene product (alpha-fetoprotein) during fetal development and adult oncogenesis. *Cancer Res.* 1976;36(11 Pt. 2):4239-49.
  33. Damjanov I, Sell S. Yolk sac carcinoma grown from rat egg cylinders. *J Natl Cancer Inst.* 1977;58(5):1523-5.
  34. Lange PH, Millan JL, Stigbrand T, Vessella RL, Ruoslahti E, Fishman WH. Placental alkaline phosphatase as a tumor marker for seminoma. *Cancer Res.* 1982;42(8):3244-7.
  35. Lippert MC, Javadpour N. Lactic dehydrogenase in the monitoring and prognosis of testicular cancer. *Cancer.* 1981;48(10):2274-8.
  36. Lange PH, McIntire KR, Waldmann TA, Hakala TR, Fraley EE. Serum alpha fetoprotein and human chorionic gonadotropin in the diagnosis and management of non-seminomatous germ-cell testicular cancer. *N Engl J Med.* 1976;295(22):1237-40.
  37. Gilligan TD, Seidenfeld J, Basch EM, Einhorn LH, Fancher T, Smith DC, et al. American Society of Clinical Oncology Clinical Practice Guideline on uses of serum tumor markers in adult males with germ cell tumors. *J Clin Oncol.* 2010;28(20):3388-404.
  38. Javadpour N. The role of biologic tumor markers in testicular cancer. *Cancer.* 1980;45(7 Suppl):1755-61.
  39. Amin MB, Edge S, Greene F, Byrd DR, Brookland RK, Washington MK, et al. (editors). *AJCC Cancer Staging Handbook.* New York: Springer; 2017.
  40. Marshall C, Enzerra M, Rahnemai-Azar AA, Ramaiya NH. Serum tumor markers and testicular germ cell tumors: a primer for radiologists. *Abdom Radiol (N.Y.).* 2019;44(3):1083-90.
  41. Dieckmann KP, Simonsen-Richter H, Kulejewski M, Anheuser P, Zecha H, Isbarn H, et al. Serum Tumour Markers in Testicular Germ Cell Tumours: Frequencies of Elevated

- Levels and Extents of Marker Elevation Are Significantly Associated with Clinical Parameters and with Response to Treatment. *Biomed Res Int.* 2019;2019:5030349.
42. Siddiqui BA, Zhang M, Pisters LL, Tu SM. Systemic therapy for primary and extragonadal germ cell tumors: prognosis and nuances of treatment. *Transl Androl Urol.* 2020;9(Suppl 1):S56-65.
  43. Cole LA. Human chorionic gonadotropin and associated molecules. *Expert Rev Mol Diagn.* 2009;9(1):51-73.
  44. Kohli M ZB, Costello BA. Management of germ cell tumors. In: Nogales FF, Jimenez RE, editors. *Pathology and Biology of Germ Cell Tumours.* Heidelberg: Springer; 2017. p. 181-94.
  45. Talmadge K, Boorstein WR, Fiddes JC. The human genome contains seven genes for the beta-subunit of chorionic gonadotropin but only one gene for the beta-subunit of luteinizing hormone. *DNA.* 1983;2(4):281-9.
  46. Tomasi TB, Jr. Structure and function of alpha-fetoprotein. *Annu Rev Med.* 1977;28:453-65.
  47. Yang F, Luna VJ, McAnelly RD, Naberhaus KH, Cupples RL, Bowman BH. Evolutionary and structural relationships among the group-specific component, albumin and alpha-fetoprotein. *Nucleic Acids Res.* 1985;13(22):8007-17.
  48. Tsuchida Y, Kaneko M, Fukui M, Sakaguchi H, Ishiguro T. Three different types of alpha-fetoprotein in the diagnosis of malignant solid tumors: use of a sensitive lectin-affinity immunoelectrophoresis. *J Pediatr Surg.* 1989;24(4):350-5.
  49. Nogales FF, Quinonez E, Lopez-Marin L, Dulcey I, Preda O. A diagnostic immunohistochemical panel for yolk sac (primitive endodermal) tumours based on an immunohistochemical comparison with the human yolk sac. *Histopathology.* 2014;65(1):51-9.
  50. Kinjo T, Taniguchi H, Kushima R, Sekine S, Oda I, Saka M, et al. Histologic and immunohistochemical analyses of alpha-fetoprotein--producing cancer of the stomach. *Am J Surg Pathol.* 2012;36(1):56-65.
  51. Damjanov I, Amenta PS, Zarghami F. Transformation of an AFP-positive yolk sac carcinoma into an AFP-negative neoplasm. Evidence for in vivo cloning of the human parietal yolk sac carcinoma. *Cancer.* 1984;53(9):1902-7.
  52. Fishman WH. Alkaline phosphatase isozymes: recent progress. *Clin Biochem.* 1990;23(2):99-104.
  53. Seargeant LE, Stinson RA. Evidence that three structural genes code for human alkaline phosphatases. *Nature.* 1979;281(5727):152-4.
  54. Paiva J, Damjanov I, Lange PH, Harris H. Immunohistochemical localization of placental-like alkaline phosphatase in testis and germ-cell tumors using monoclonal antibodies. *Am J Pathol.* 1983;111(2):156-65.
  55. Manivel JC, Jessurun J, Wick MR, Dehner LP. Placental alkaline phosphatase immunoreactivity in testicular germ-cell neoplasms. *Am J Surg Pathol.* 1987;11(1):21-9.
  56. Kommos F, Oliva E, Bittinger F, Kirkpatrick CJ, Amin MB, Bhan AK, et al. Inhibin-alpha CD99, HEA125, PLAP, and chromogranin immunoreactivity in testicular neoplasms and the androgen insensitivity syndrome. *Hum Pathol.* 2000;31(9):1055-61.
  57. Preda O NF. Diagnostic immunopathology of germ cell tumors. In: Nogales FF, Jimenez RE, editors. *Pathology and Biology of Germ Cell Tumours.* Heidelberg: Springer; 2017. p. 131-80.
  58. Glick JH Jr. Serum lactate dehydrogenase isoenzyme and total lactate dehydrogenase values in health and disease, and clinical evaluation of these tests by means of discriminant analysis. *Am J Clin Pathol.* 1969;52(3):320-8.
  59. Lactate dehydrogenase 2020 [cited 2020 Oct 10]. Available from: [https://en.wikipedia.org/wiki/Lactate\\_dehydrogenase](https://en.wikipedia.org/wiki/Lactate_dehydrogenase).
  60. Gallo M, Sapio L, Spina A, Naviglio D, Calogero A, Naviglio S. Lactic dehydrogenase and cancer: an overview. *Front Biosci (Landmark Ed).* 2015;20:1234-49.
  61. Petrelli F, Cabiddu M, Coinu A, Borgonovo K, Ghilardi M, Lonati V, et al. Prognostic role of lactate dehydrogenase in solid tumors: a systematic review and meta-analysis of 76 studies. *Acta Oncol.* 2015;54(7):961-70.
  62. Looijenga LH, Oosterhuis J.W. Pathobiology of germ cell tumors - applying the gossip test! *Int J Dev Biol.* 2013;57(2-4):289-98.
  63. Ulbright TM, Tickoo SK, Berney DM, Srigley JR, Members of the IliDUPG. Best practices recommendations in the application of immunohistochemistry in testicular tumors: report from the International Society of Urological Pathology consensus conference. *Am J Surg Pathol.* 2014;38(8):e50-9.
  64. Guillaudeux T, Mattei MG, Depetris D, Le Bouteiller P, Pontarotti P. In situ hybridization localizes the human OTF3 to chromosome 6p21.3-->p22 and OTF3L to 12p13. *Cytogenet Cell Genet.* 1993;63(4):212-4.
  65. Takahashi K, Yamanaka S. Induction of pluripotent stem cells from mouse embryonic and adult fibroblast cultures by defined factors. *Cell.* 2006;126(4):663-76.
  66. Damjanov I, Andrews PW. Teratomas produced from human pluripotent stem cells xenografted into immunodeficient mice - a histopathology atlas. *Int J Dev Biol.* 2016;60(10-11-12):337-419.
  67. International Stem Cell Initiative, Adewumi O, Aflatoonian B, Ahrlund-Richter L, Amit M, Andrews PW, et al. Characterization of human embryonic stem cell lines by the International Stem Cell Initiative. *Nat Biotechnol.* 2007;25(7):803-16.
  68. Looijenga LH, Stoop H, de Leeuw HP, de Gouveia Brazao CA, Gillis AJ, van Roozendaal KE, et al. POU5F1 (OCT3/4) identifies cells with pluripotent potential in human germ cell tumors. *Cancer Res.* 2003;63(9):2244-50.
  69. Jones TD, Ulbright TM, Eble JN, Baldrige LA, Cheng L. OCT4 staining in testicular tumors: a sensitive and specific marker for seminoma and embryonal carcinoma. *Am J Surg Pathol.* 2004;28(7):935-40.

70. Lennartsson J, Jelacic T, Linnekin D, Shivakrupa R. Normal and oncogenic forms of the receptor tyrosine kinase kit. *Stem Cells*. 2005;23(1):16-43.
71. Wang H, Boussouar A, Mazelin L, Tauszig-Delamasure S, Sun Y, Goldschneider D, et al. The Proto-oncogene c-Kit Inhibits Tumor Growth by Behaving as a Dependence Receptor. *Mol Cell*. 2018;72(3):413-25.e5.
72. Vandenbark GR, deCastro CM, Taylor H, Dew-Knight S, Kaufman RE. Cloning and structural analysis of the human c-kit gene. *Oncogene*. 1992;7(7):1259-66.
73. Miettinen M, Lasota J. KIT (CD117): a review on expression in normal and neoplastic tissues, and mutations and their clinicopathologic correlation. *Appl Immunohistochem Mol Morphol*. 2005;13(3):205-20.
74. Robinson LL, Gaskell TL, Saunders PT, Anderson RA. Germ cell specific expression of c-kit in the human fetal gonad. *Mol Hum Reprod*. 2001;7(9):845-52.
75. Kemmer K, Corless CL, Fletcher JA, McGreevey L, Haley A, Griffith D, et al. KIT mutations are common in testicular seminomas. *Am J Pathol*. 2004;164(1):305-13.
76. Oosterhuis JW, Looijenga LHJ. Germ cell tumors from a developmental perspective: Cells of origin, pathogenesis, and molecular biology (emerging patterns). In: Nogales FF, Jimenez RE, editors. *Pathology and Biology of Germ Cell Tumours*. Heidelberg: Springer; 2017. p. 23-131.
77. Yang J, Chai L, Fowles TC, Alipio Z, Xu D, Fink LM, et al. Genome-wide analysis reveals Sall4 to be a major regulator of pluripotency in murine-embryonic stem cells. *Proc Natl Acad Sci U S A*. 2008;105(50):19756-61.
78. Tatetsu H, Kong NR, Chong G, Amabile G, Tenen DG, Chai L. SALL4, the missing link between stem cells, development and cancer. *Gene*. 2016;584(2):111-9.
79. Rao S, Zhen S, Roumiantsev S, McDonald LT, Yuan GC, Orkin SH. Differential roles of Sall4 isoforms in embryonic stem cell pluripotency. *Mol Cell Biol*. 2010;30(22):5364-80.
80. Cao D, Li J, Guo CC, Allan RW, Humphrey PA. SALL4 is a novel diagnostic marker for testicular germ cell tumors. *Am J Surg Pathol*. 2009;33(7):1065-77.
81. Wang F, Liu A, Peng Y, Rakheja D, Wei L, Xue D, et al. Diagnostic utility of SALL4 in extragonadal yolk sac tumors: an immunohistochemical study of 59 cases with comparison to placental-like alkaline phosphatase, alpha-fetoprotein, and glypican-3. *Am J Surg Pathol*. 2009;33(10):1529-39.
82. Liu A, Cheng L, Du J, Peng Y, Allan RW, Wei L, et al. Diagnostic utility of novel stem cell markers SALL4, OCT4, NANOG, SOX2, UTF1, and TCL1 in primary mediastinal germ cell tumors. *Am J Surg Pathol*. 2010;34(5):697-706.
83. Miettinen M, Wang Z, McCue PA, Sarlomo-Rikala M, Rys J, Biernat W, et al. SALL4 expression in germ cell and non-germ cell tumors: a systematic immunohistochemical study of 3215 cases. *Am J Surg Pathol*. 2014;38(3):410-20.
84. Novak D, Huser L, Elton JJ, Umansky V, Altevogt P, Utikal J. SOX2 in development and cancer biology. *Semin Cancer Biol*. 2020;67(Pt 1):74-82.
85. Bass AJ, Watanabe H, Mermel CH, Yu S, Perner S, Verhaak RG, et al. SOX2 is an amplified lineage-survival oncogene in lung and esophageal squamous cell carcinomas. *Nat Genet*. 2009;41(11):1238-42.
86. de Jong J, Stoop H, Gillis AJ, van Gurp RJ, van de Geijn GJ, Boer M, et al. Differential expression of SOX17 and SOX2 in germ cells and stem cells has biological and clinical implications. *J Pathol*. 2008;215(1):21-30.
87. Nettersheim D, Heimsoeth A, Jostes S, Schneider S, Fellermeier M, Hofmann A, et al. SOX2 is essential for in vivo reprogramming of seminoma-like Tcam-2 cells to an embryonal carcinoma-like fate. *Oncotarget*. 2016;7(30):47095-110.
88. Jostes SV, Fellermeier M, Arevalo L, Merges GE, Kristiansen G, Nettersheim D, et al. Unique and redundant roles of SOX2 and SOX17 in regulating the germ cell tumor fate. *Int J Cancer*. 2020;146(6):1592-605.
89. Sonne SB, Perrett RM, Nielsen JE, Baxter MA, Kristensen DM, Leffers H, et al. Analysis of SOX2 expression in developing human testis and germ cell neoplasia. *Int J Dev Biol*. 2010;54(4):755-60.
90. Nonaka D. Differential expression of SOX2 and SOX17 in testicular germ cell tumors. *Am J Clin Pathol*. 2009;131(5):731-6.
91. Chaudhary S, Islam Z, Mishra V, Rawat S, Ashraf GM, Kolatkar PR. Sox2: A Regulatory Factor in Tumorigenesis and Metastasis. *Curr Protein Pept Sci*. 2019;20(6):495-504.
92. Favilla V, Cimino S, Madonia M, Morgia G. New advances in clinical biomarkers in testis cancer. *Front Biosci (Elite Ed)*. 2010;2:456-77.
93. Leroy X, Augusto D, Leteurtre E, Gosselin B. CD30 and CD117 (c-kit) used in combination are useful for distinguishing embryonal carcinoma from seminoma. *J Histochem Cytochem*. 2002;50(2):283-5.
94. Berney DM, Shamash J, Pieroni K, Oliver RT. Loss of CD30 expression in metastatic embryonal carcinoma: the effects of chemotherapy? *Histopathology*. 2001;39(4):382-5.
95. Sonne SB, Herlihy AS, Hoei-Hansen CE, Nielsen JE, Almstrup K, Skakkebaek NE, et al. Identity of M2A (D2-40) antigen and gp36 (Aggrus, T1A-2, podoplanin) in human developing testis, testicular carcinoma in situ and germ-cell tumours. *Virchows Arch*. 2006;449(2):200-6.
96. Schacht V, Dadras SS, Johnson LA, Jackson DG, Hong YK, Detmar M. Up-regulation of the lymphatic marker podoplanin, a mucin-type transmembrane glycoprotein, in human squamous cell carcinomas and germ cell tumors. *Am J Pathol*. 2005;166(3):913-21.
97. Lau SK, Weiss LM, Chu PG. D2-40 immunohistochemistry in the differential diagnosis of seminoma and embryonal carcinoma: a comparative immunohistochemi-

- cal study with KIT (CD117) and CD30. *Mod Pathol.* 2007;20(3):320-5.
98. Roth LM, Michal M, Michal M, Jr., Cheng L. Protein expression of the transcription factors DMRT1, TCLF5, and OCT4 in selected germ cell neoplasms of the testis. *Hum Pathol.* 2018;82:68-75.
99. Brobeil A, Wagenlehner F, Gattenlohner S. Expression of terminal deoxynucleotidyl transferase (TdT) in classical seminoma: a potential diagnostic pitfall. *Virchows Arch.* 2018;472(3):433-40.
100. Shojaei H, Hong H, Redline RW. High-level expression of divergent endodermal lineage markers in gonadal and extragonadal yolk sac tumors. *Mod Pathol.* 2016;29(10):1278-88.
101. Nogales FF, Preda O, Nicolae A. Yolk sac tumours revisited. A review of their many faces and names. *Histopathology.* 2012;60(7):1023-33.
102. Jimenez RA GS, Herrera-Hernandez LP, Sebo TP. testicular germ cell tumors. In: Nogales FF, Jimenez RE, editors. *Pathology and Biology of Germ Cell Tumours.* Heidelberg: Springer; 2017. p. 267-326.
103. Rougemont AL, Tille JC. Role of HNF1beta in the differential diagnosis of yolk sac tumor from other germ cell tumors. *Hum Pathol.* 2018;81:26-36.
104. Gallo A, Fankhauser C, Hermanns T, Beyer J, Christiansen A, Moch H, et al. HNF1beta is a sensitive and specific novel marker for yolk sac tumor: a tissue microarray analysis of 601 testicular germ cell tumors. *Mod Pathol.* 2020;33(11):2354-60.
105. Xiao GQ, Li F, Unger PD, Katerji H, Yang Q, McMahon L, et al. ZBTB16: a novel sensitive and specific biomarker for yolk sac tumor. *Mod Pathol.* 2016;29(6):591-8.
106. Murray MJ, Huddart RA, Coleman N. The present and future of serum diagnostic tests for testicular germ cell tumours. *Nat Rev Urol.* 2016;13(12):715-25.
107. Blanco L, Tirado CA. Testicular Germ Cell Tumors: A Cytogenomic Update. *J Assoc Genet Technol.* 2018;44(4):128-33.
108. Buljubasic R, Buljubasic M, Bojanac AK, Ulamec M, Vlahovic M, Jezek D, et al. Epigenetics and testicular germ cell tumors. *Gene.* 2018;661:22-33.
109. Singla N, Lafin JT, Ghandour RA, Kaffenberger S, Amatruda JF, Bagrodia A. Genetics of testicular germ cell tumors. *Curr Opin Urol.* 2019;29(4):344-9.
110. Chang Y, Wang X, Xu Y, Yang L, Qian Q, Ju S, et al. Comprehensive characterization of cancer-testis genes in testicular germ cell tumor. *Cancer Med.* 2019;8(7):3511-9.
111. Lobo J, Gillis AJM, Jeronimo C, Henrique R, Looijenga LHJ. Human Germ Cell Tumors are Developmental Cancers: Impact of Epigenetics on Pathobiology and Clinic. *Int J Mol Sci.* 2019;20(2):258.
112. Dieckmann KP, Radtke A, Geczi L, Matthies C, Anheuser P, Eckardt U, et al. Serum Levels of MicroRNA-371a-3p (M371 Test) as a New Biomarker of Testicular Germ Cell Tumors: Results of a Prospective Multicentric Study. *J Clin Oncol.* 2019;37(16):1412-23.
113. Raos D, Kasic J, Masic S, Abramovic I, Coric M, Kruslin B, et al. In Search of TGCT Biomarkers: A Comprehensive In Silico and Histopathological Analysis. *Dis Markers.* 2020;2020:8841880.
114. Batool A, Karimi N, Wu XN, Chen SR, Liu YX. Testicular germ cell tumor: a comprehensive review. *Cell Mol Life Sci.* 2019;76(9):1713-27.