



# Neonatal Hypoxic-Ischemic Injury: Ultrasound and Dynamic Color Doppler Sonography perfusion of the Brain and Abdomen with pathologic correlation.

---

Ricardo Faingold,MD

Montreal Children's Hospital  
Medical Imaging  
McGill University



Maputo 2016

AJR 2012, in press

# Disclosure

---

- *Pixelflux Chameleon software* was acquired with a grant from CHAR-GE (Canadian Heads of Academic Radiology)

# Outline

---

- Perinatal asphyxia
- HIE/HII
- Imaging : focus on US and CDS
- Brief description of dynamic CDS
- Review Imaging of brain and abdominal organs
- Interesting case

# Introduction

---

- Perinatal asphyxia (PA) represents impaired gas exchange that results in hypoxia, hypercarbia and acidosis. If the metabolic abnormalities last long enough, the brain and other vital organ vascular autoregulation may fail.

# Perinatal Asphyxia

---

- Perinatal asphyxia has devastating consequences in neonates, including hypoxic ischemic encephalopathy, renal, hepatic and cardiac failure .
- Meconium aspiration.
- It is associated with changes in blood flow distribution (diving reflex)



BF brain, heart, adrenals



BF kidneys, intestines and skin

# HIE

---

- Hypoxic-ischemic encephalopathy (HIE) is a major contributor to neonatal death and morbidity.
- An estimated 23% of the 4 million neonatal deaths and 8% of all deaths at < 5 years of age throughout the world each year are associated with signs of asphyxia at birth.
- Even at referral centers in developed countries, death or moderate to severe disability occurs in 53% to 61% of infants diagnosed as having moderate to severe HIE.

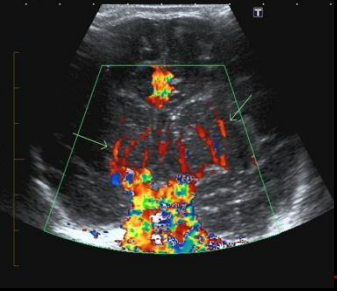# Therapeutic hypothermia

---

- Therapeutic hypothermia has been used more frequently in infants with moderate to severe encephalopathy.
- It results in improved neurological outcome in survivors.



Shankaran S. et al N.Engl J Med 353, 1574 (2005)



## Perinatal Asphyxia: HII Mechanism

- **A-** Decreased cerebral blood flow and potential ischemic brain injury
- **B-** During the post-asphyxiated period a consistent observation has been a marked increase in Cerebral Blood Flow which continues for several hours or days. This increase in CBF called **reperfusion phase - injury**

Berger R et al. Brain Res Rev 30,107 (1999)

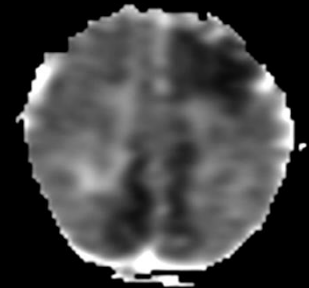
Ilves P, et al J Ultrasound Med 2009; 28:1471-1480.



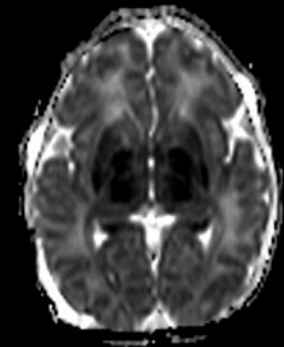
# Severity of HII

---

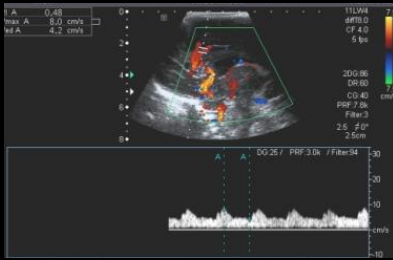
- Mild to moderate : Watershed areas



- Severe : Involvement of basal ganglia and thalami associated with poor outcome.



# Imaging



- Cerebral MRI is the imaging standard in HIE
- CT is not routinely done
- Head Ultrasound helpful in the routine care of neonates with HIE. Pulsed Doppler Flow velocities and Resistive index are altered in the cerebral arteries and splancnic arteries, such as SMA in asphyxiated neonates.

Epelman M, Daneman A, et al *Pediatr Radiol* 2010; 40:1640-1650.

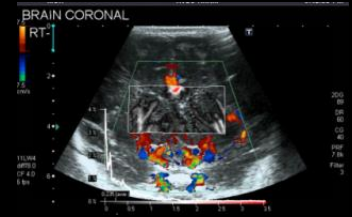Ilves P, et al *J Ultrasound Med* 2009; 28:1471-1480.

# Imaging

---

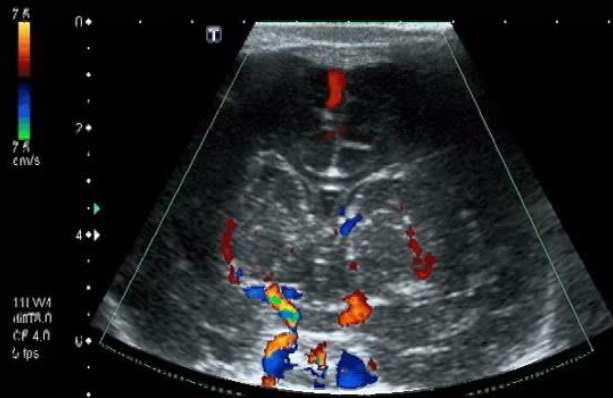
- Dynamic color Doppler sonography (CDS) is a non-invasive technique that has been used to assess and quantify tissue perfusion in different organs and systems with a software.
- This software allows automatic quantification of Doppler data of video clips from a chosen region of interest (ROI), by dynamically assessing color pixels and flow velocity during the heart cycle

# Imaging: Dynamic CDS



- CDS video measurements used to calculate **Perfusion Intensity (cm/s)** using chosen software (*Pixelflux Chameleon* software) .
- Color Doppler videos of the blood flow in the basal ganglia (marker of severe HII) obtained with an 11LW4 MHz linear transducer, in the coronal plane, used to calculate the CPI.

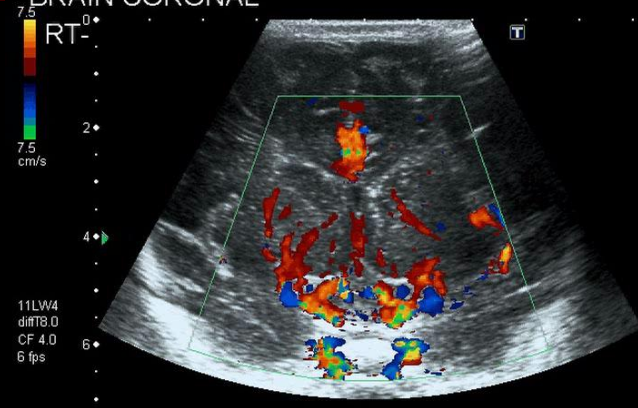
# Dynamic coronal cerebral CDS - CPI



A0 IP6

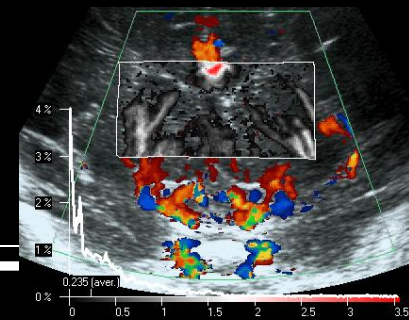
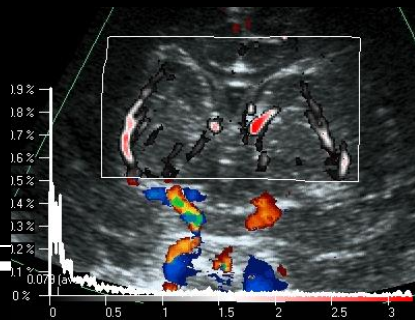
Whole intensity =  $2 \times I$   
mix [cm/s]: **0.09**  
Angle correction [°]: **0**

BRAIN CORONAL



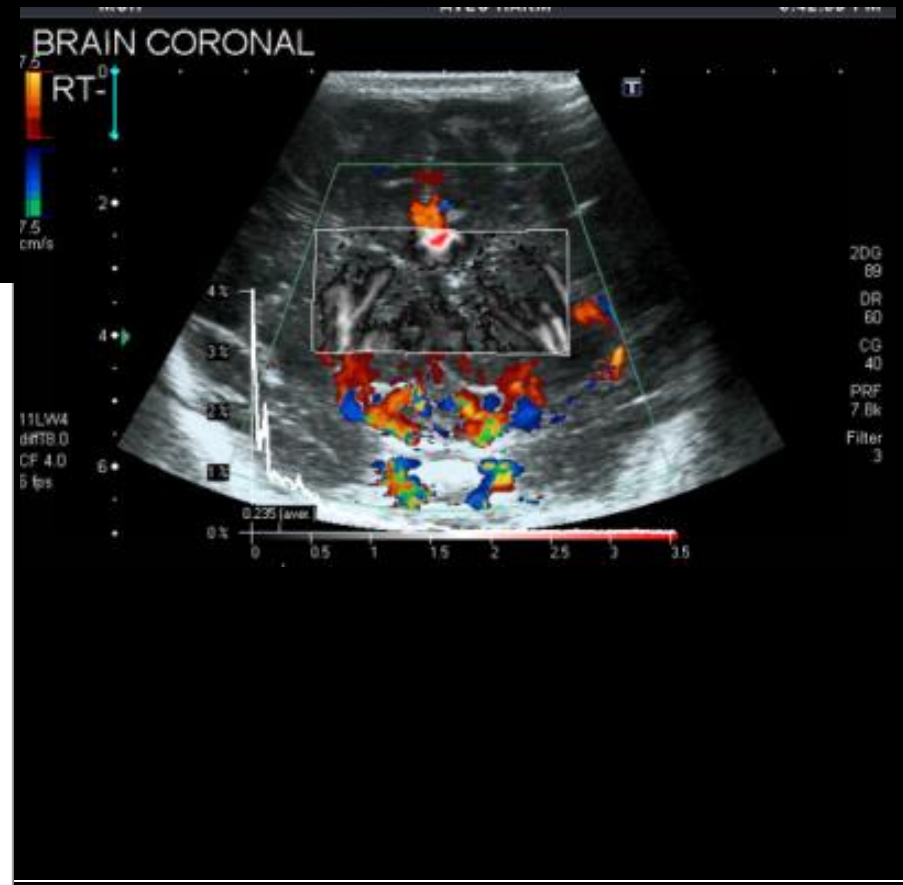
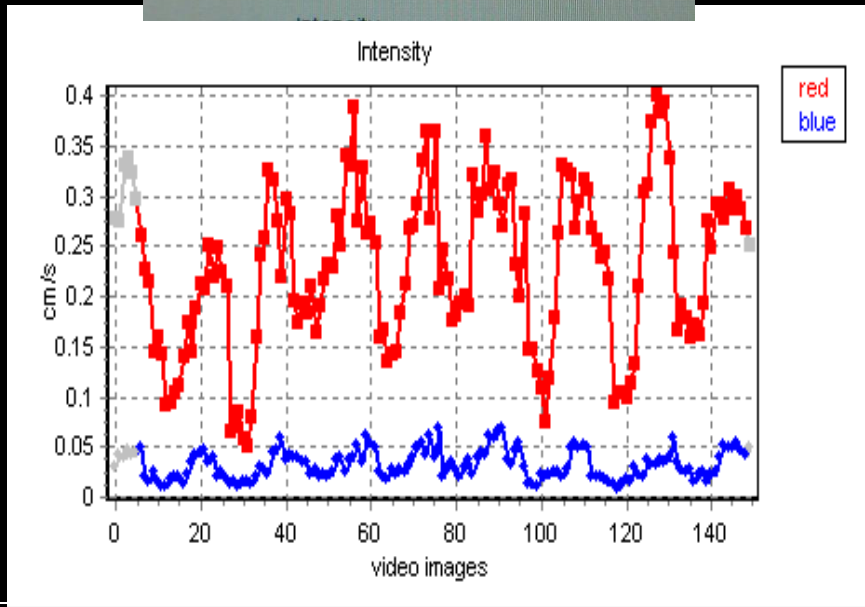
A0 IP6

Whole intensity =  $2 \times I$   
mix [cm/s]: **0.241**  
Angle correction [°]: **0**



# Dynamic Cerebral CDS - CPI

size of ROI [cm <sup>2</sup> ]	8.761
average intensity = 1 mix [cm/s]	0.121
Whole intensity = 2 * 1 mix [cm/s]	<b>0.241</b>
Angle correction [°]	<input type="text" value="0"/>



# Imaging

---

- Therefore US is non-invasive modality, by the bedside, that can provide comprehensive imaging of multiple organs and systems.
- Review with illustration of US and CDS perfusion findings of the brain and abdomen in neonatal HII.

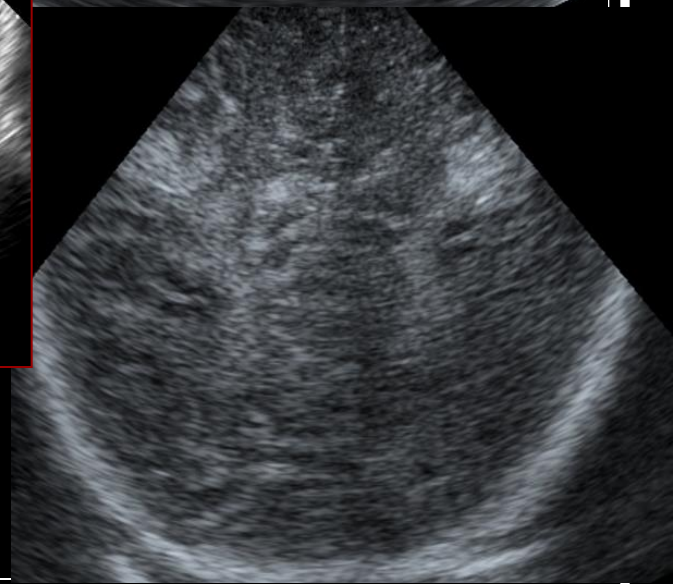
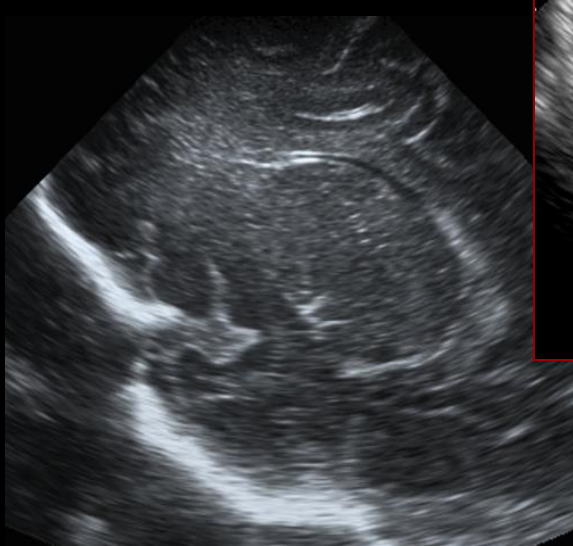
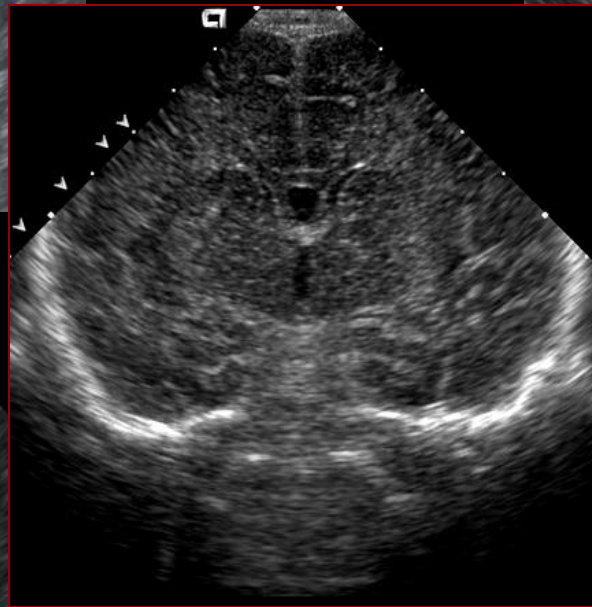
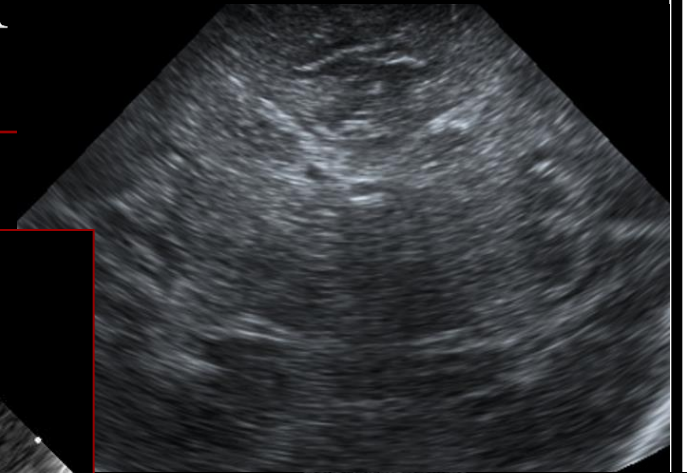
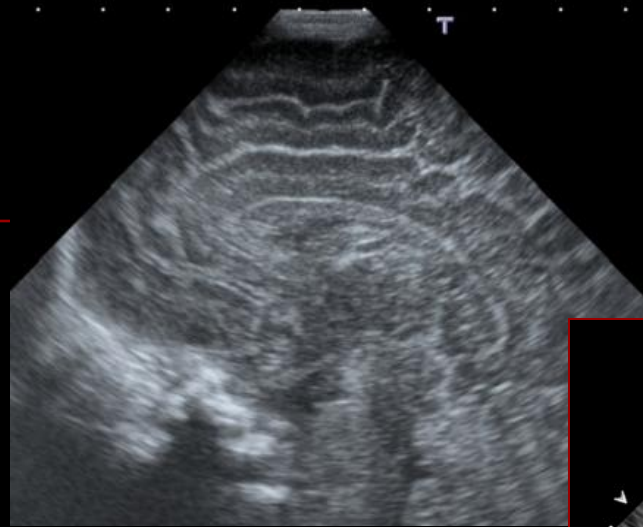# Brain

---

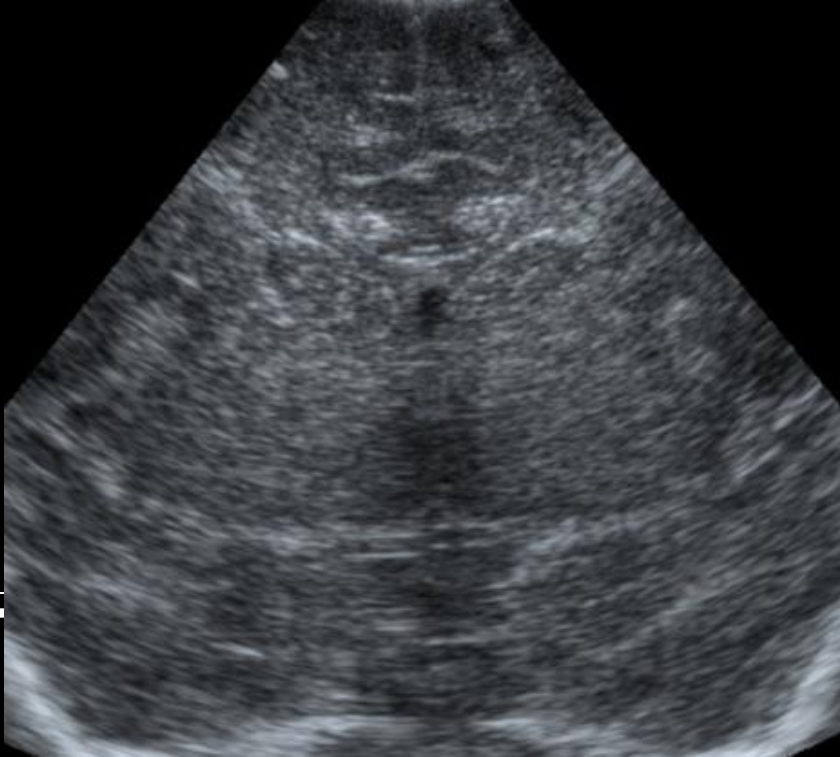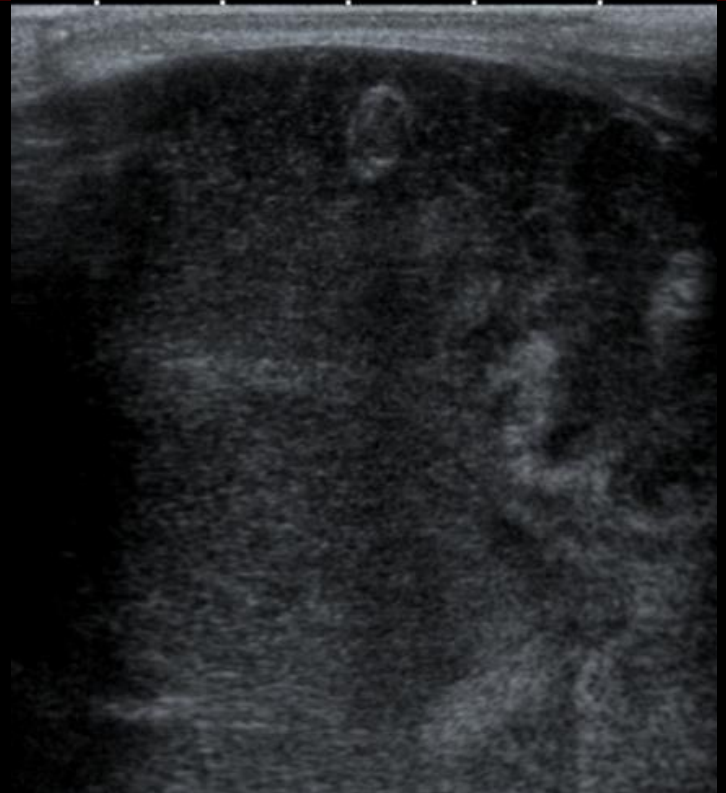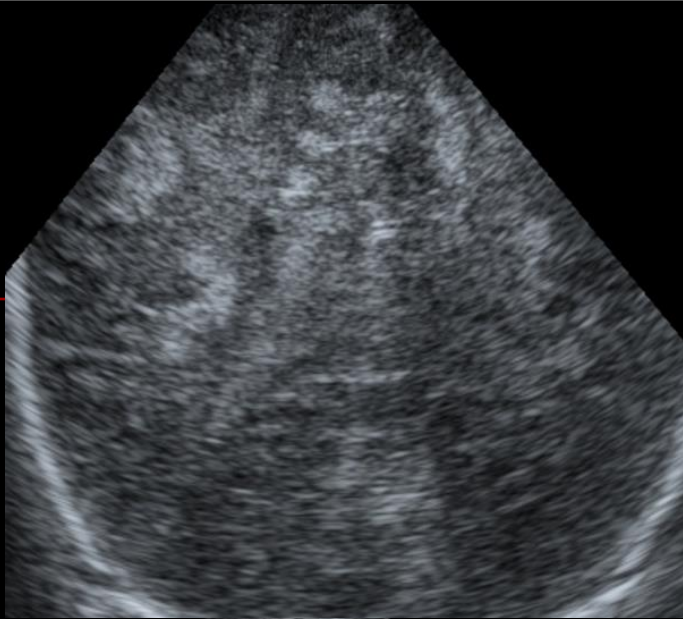- Gray-scale
- CDS : mild x severe HII



# Brain

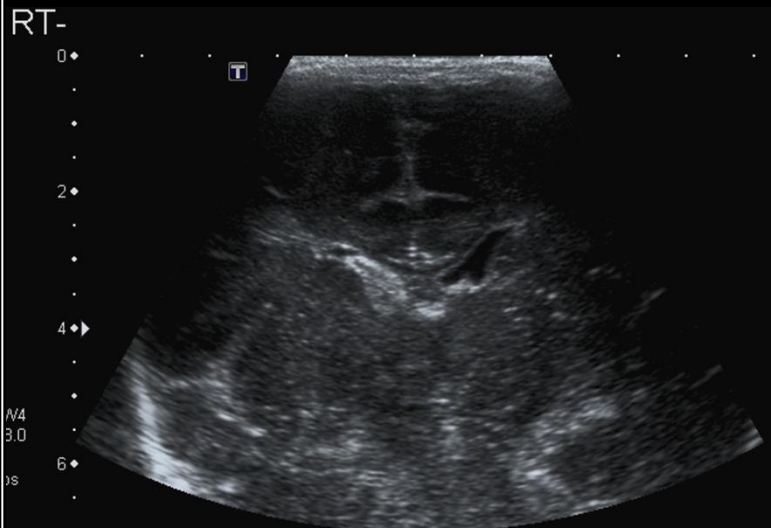


# Brain

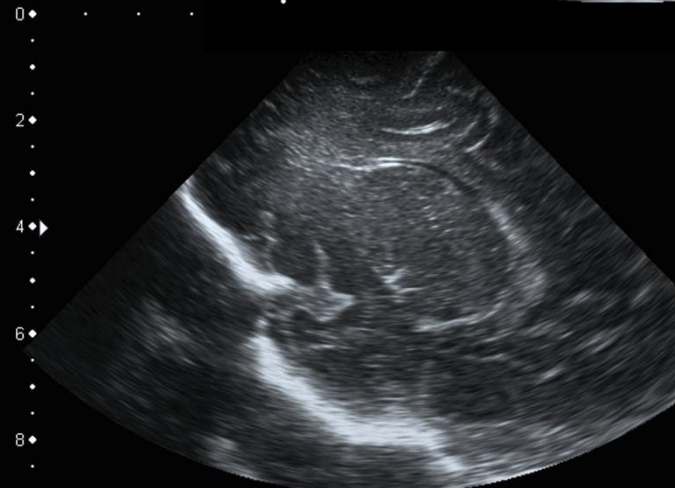

# IVH in term neonates with HII

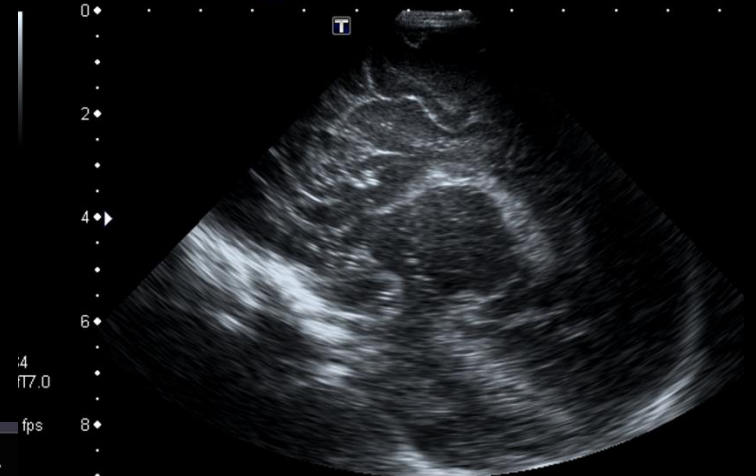
## ■ Choroid plexus bleed



LT- LATERAL

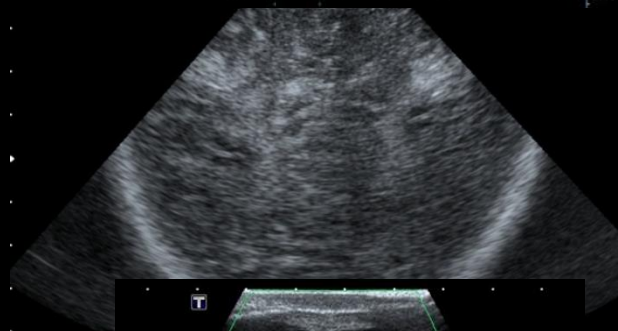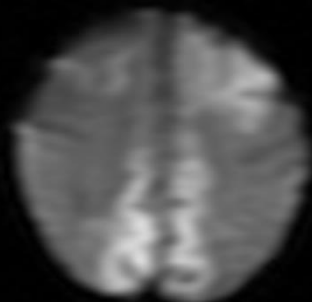
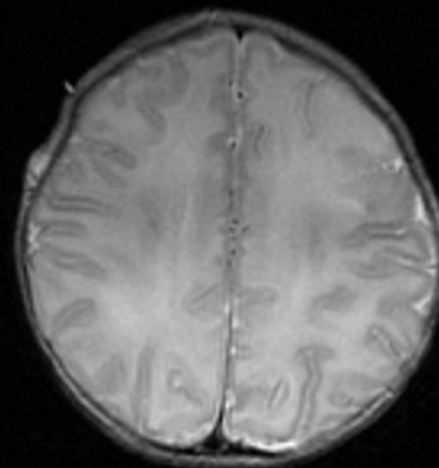
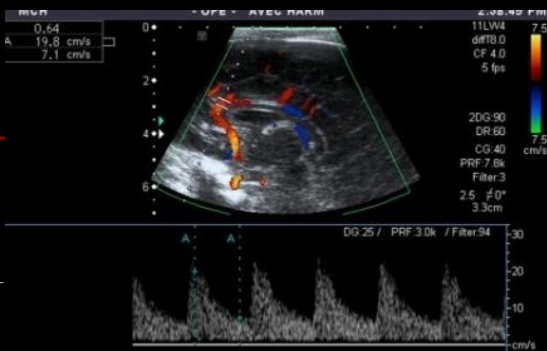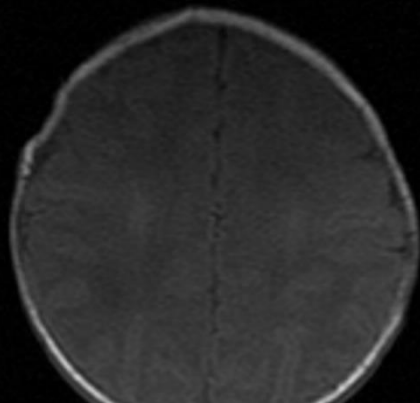


RT- LATERAL

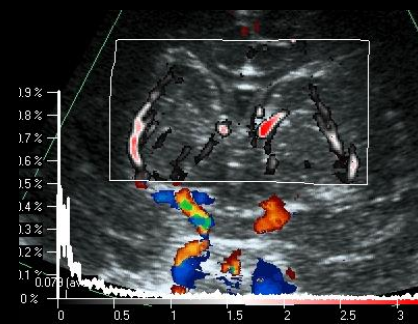
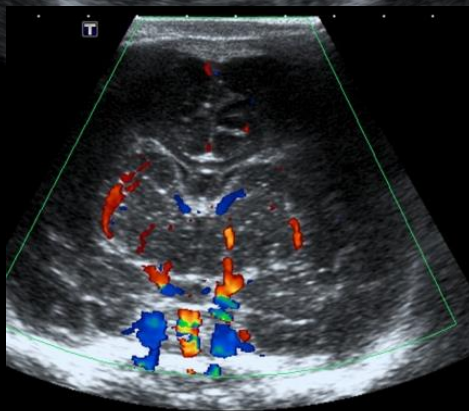
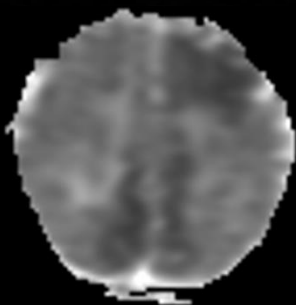




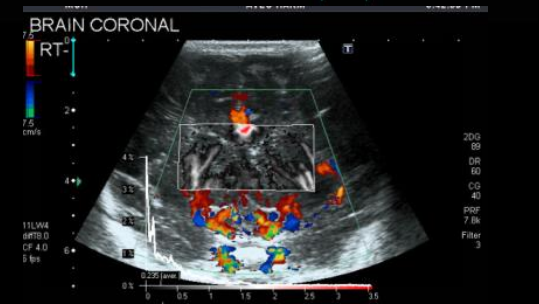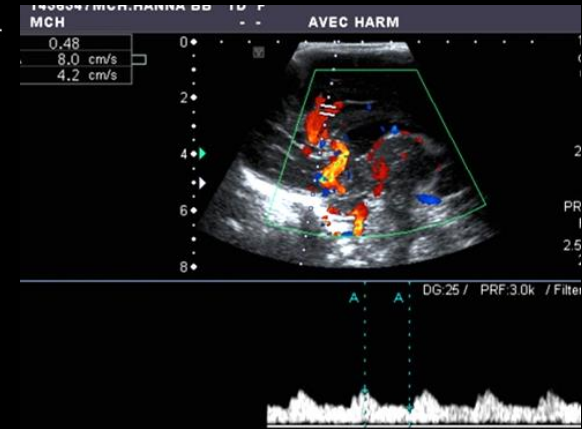
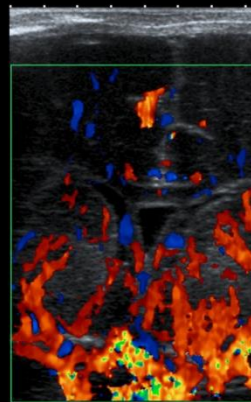
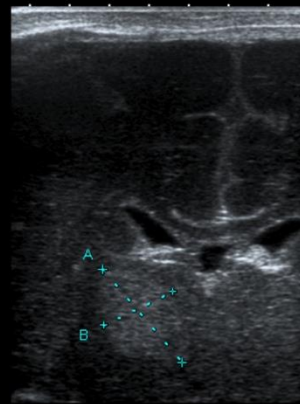
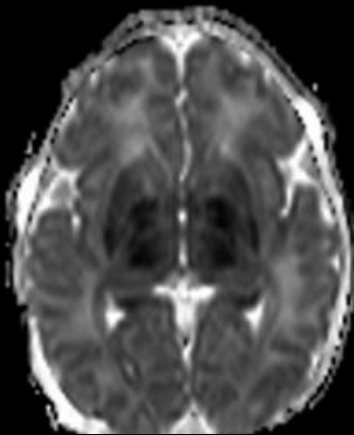
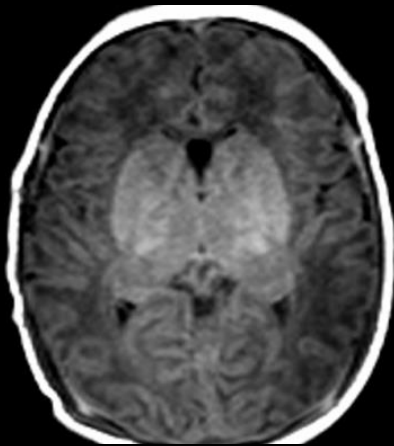
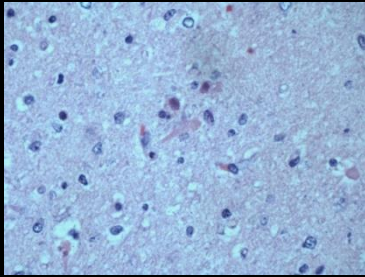
# Mild HII



Whole intensity =  $2 \times I$  0.09  
mix [cm/s]:  
Angle correction [°]:



# Severe HII



Whole intensity =  $2 \times 1$   
mix [cm/s]: **0.241**  
Angle correction [°]: **0**

# Results

---

- **Overall:** CPI values were significantly higher in the 7 neonates that died ( $0.226 \pm 0.221$  cm/s vs.  $0.111 \pm 0.082$  cm/s;  $p=0.02$ )

	Survivors (23)	Non- survivors (7)	<i>p</i>
CPI	$0.111 \pm 0.082$	$0.226 \pm 0.221$	<b>0.02</b>

# Abdominal organs

---

- Bowel
- Adrenal glands
- Kidneys
- Liver

# Bowel

---

- 29% of neonates with HII show GI dysfunction. Multiple-organ failure occurs in 50-60% of neonates with severe HII.
- In severe HII, significant decrease in the mean blood flow velocities and increase in RI detected in the superior mesenteric artery (SMA).
- Accurate assessment of the mesenteric perfusion changes in asphyxia may help staging this devastating disease and understanding the mechanism of intestinal auto-regulation in neonates.



# Bowel

---

- Gray-scale abdominal US images of the bowel and color Doppler videos of the mural blood flow acquired with an 11LW4 MHz linear transducer to assess the Intestinal Perfusion Intensity (IPI), with similar technique and analyzed with same software as described previously.

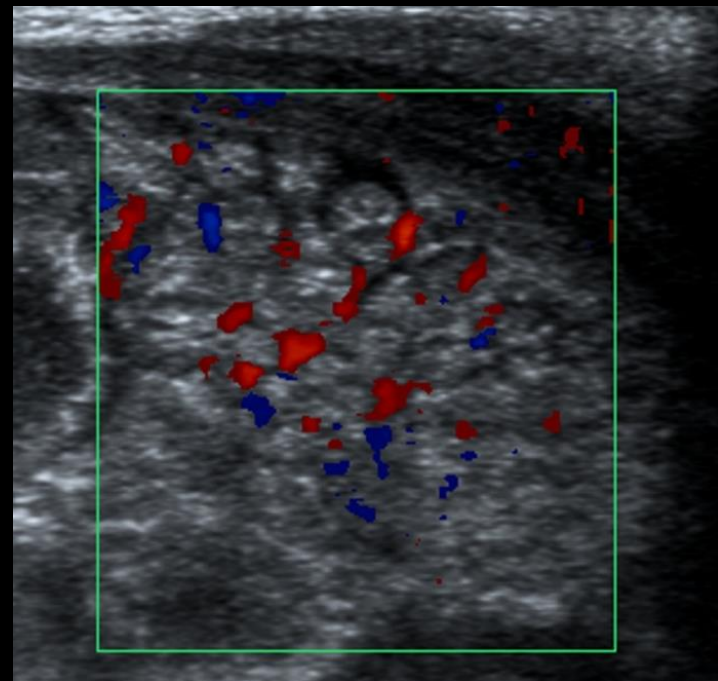
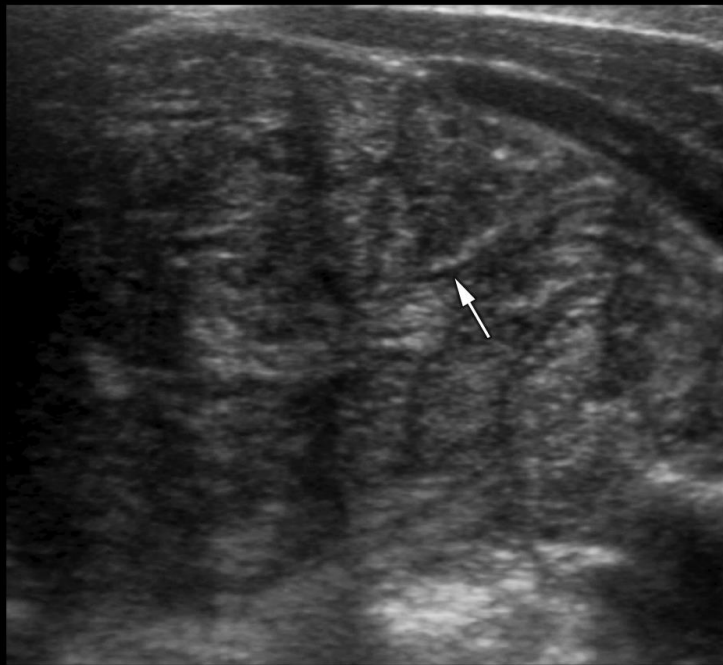# Bowel

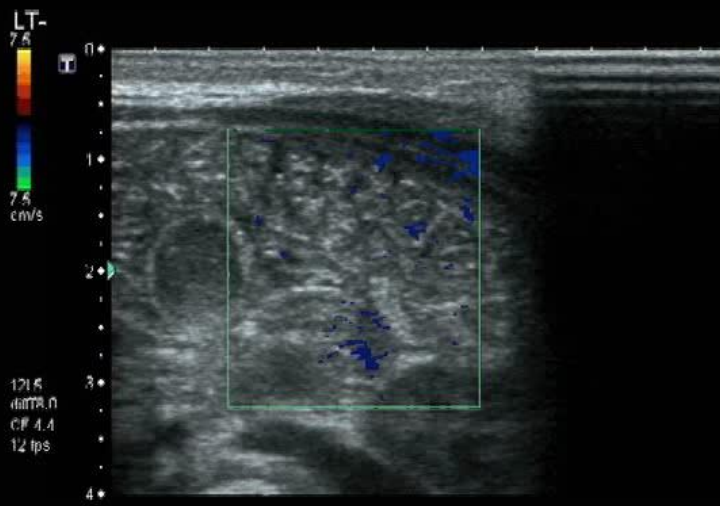
---

- Gray-scale appearances, including sloughed mucosa.
- CDS and dynamic CDS.

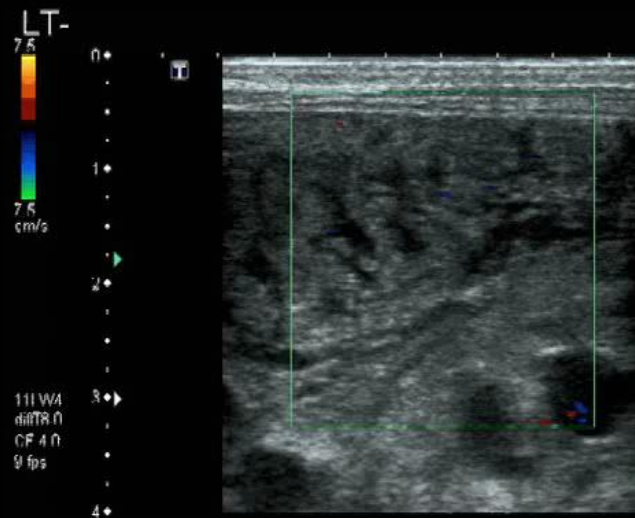
# Bowel

---





2DG  
R4  
DR  
60  
CG  
40  
PRI  
10.4k  
Filter  
3



2DG  
R4  
DR  
60  
CG  
40  
PRI  
11.7k  
Filter  
3

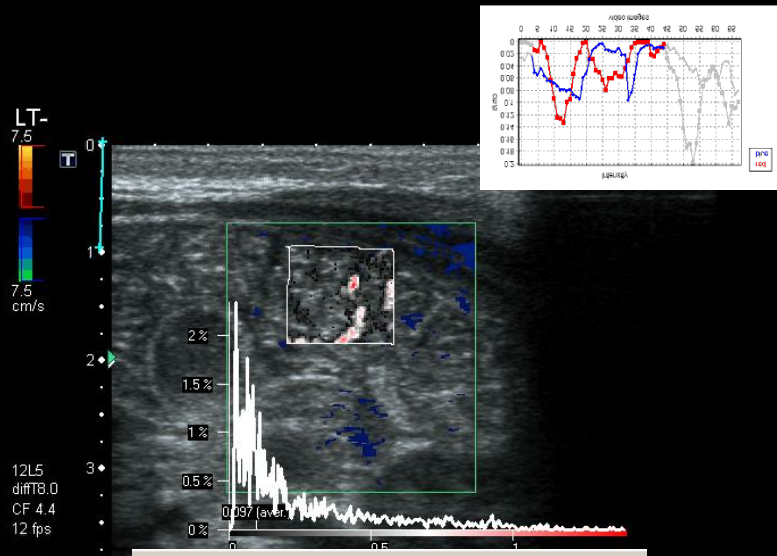
A.0 IP6

A.0 IP6

# Intestinal Perfusion Intensity

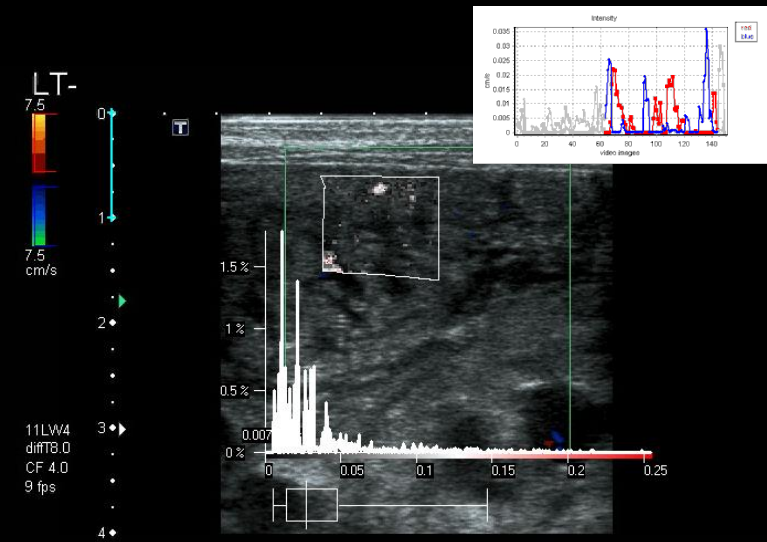
■ IPI : (cm/s)

ROI : 1 cm<sup>2</sup>



size of ROI [cm <sup>2</sup> ]	0.858
average intensity = I mix [cm/s]:	0.048
Whole intensity = 2 * I mix [cm/s]:	<b>0.097</b>
Angle correction [°]:	0

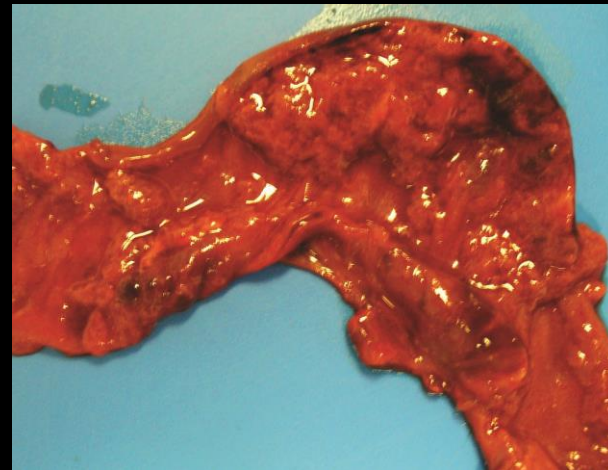
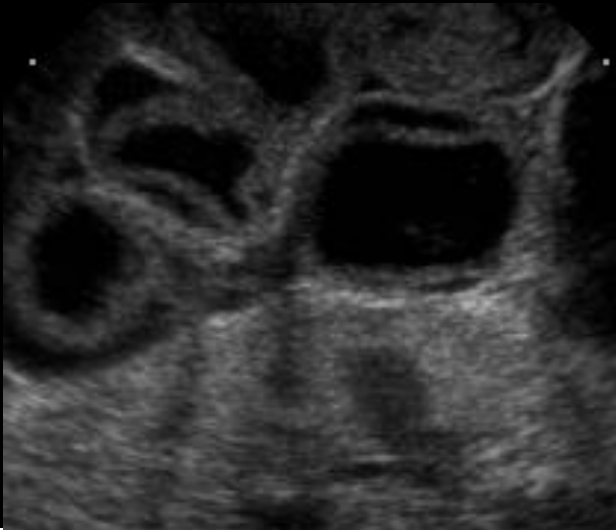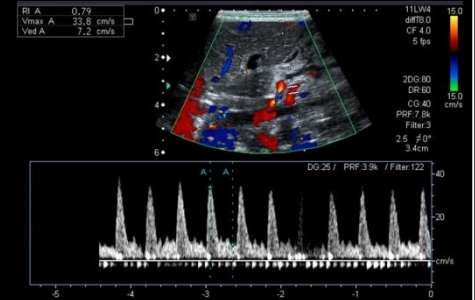
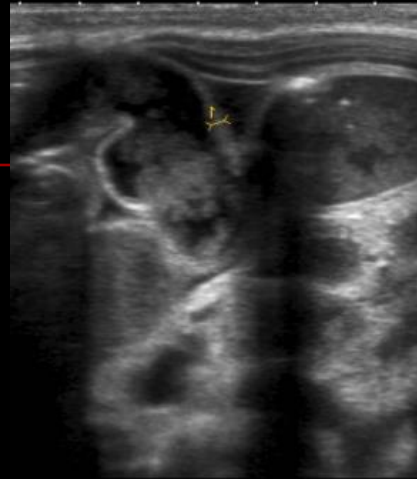
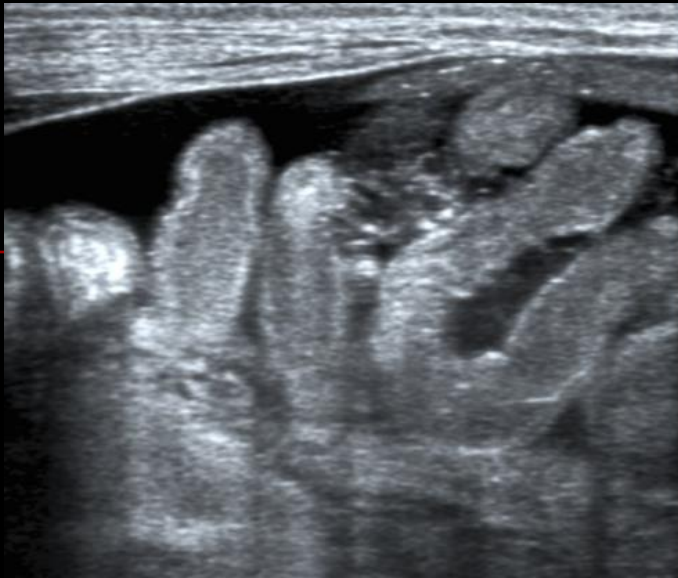
A.0 IP6



size of ROI [cm <sup>2</sup> ]	0.993
average intensity = I mix [cm/s]:	0.002
Whole intensity = 2 * I mix [cm/s]:	<b>0.004</b>
Angle correction [°]:	0

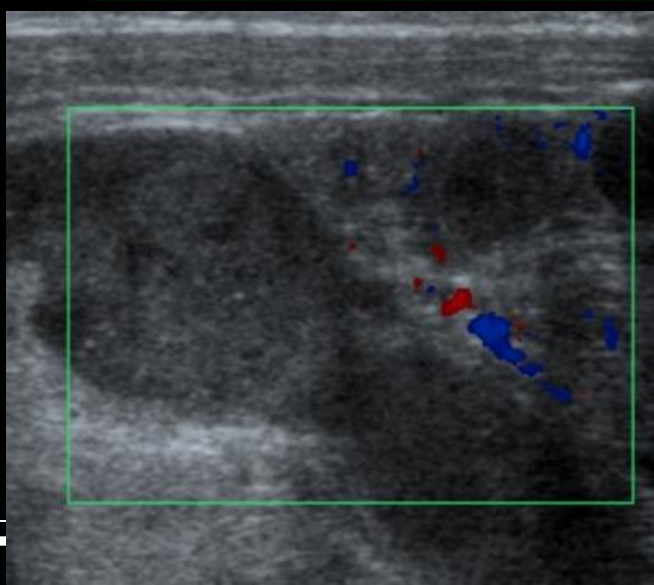
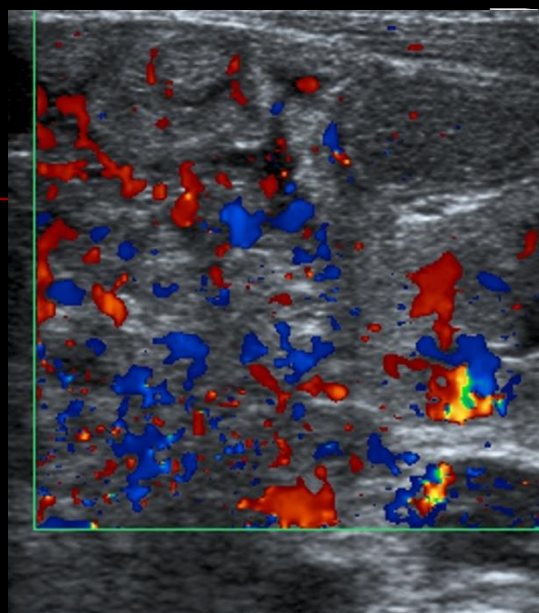
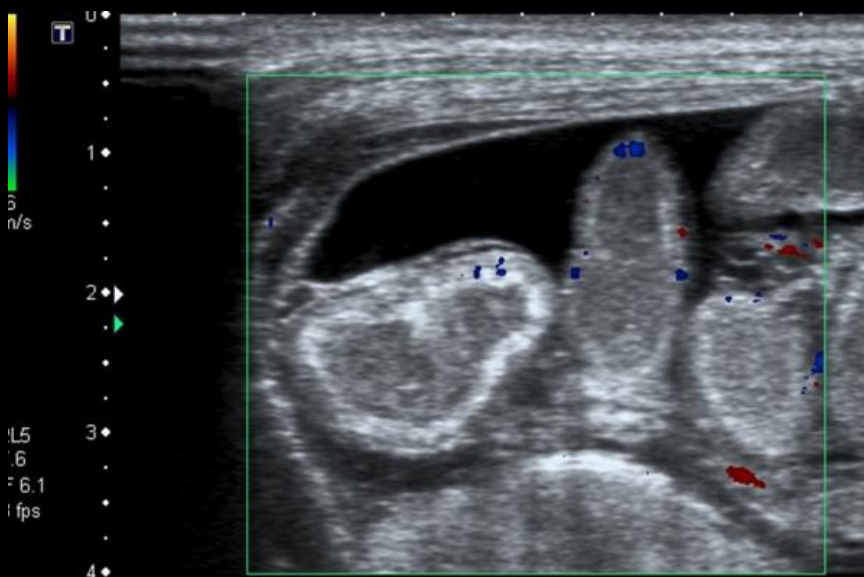
A.0 IP6

# Bowel





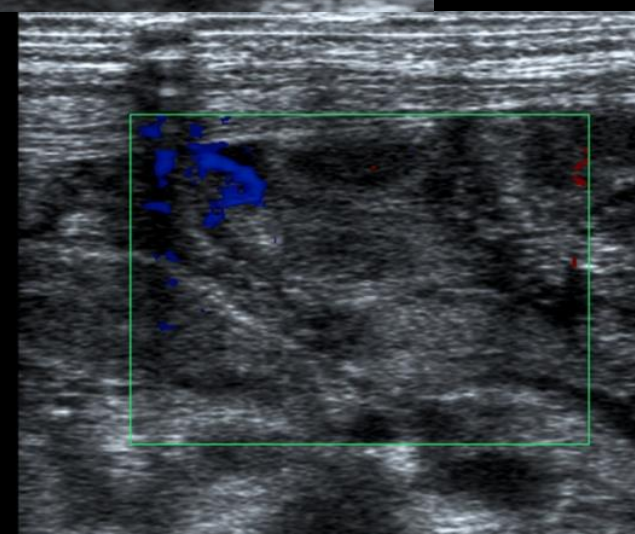
# Bowel



T  
1  
2

7.5  
cm/s

11LW4  
diffT8.0  
CF 4.0  
11 fps



# Results

---

IPI : There was a trend to decreased mural perfusion in neonates that died

Presence of sloughed mucosa was highly associated with mortality

US/outcome	Survivors (21)	Non- Survivors (7)	<i>p</i>
Sloughed mucosa	0 (0)	6 (86)	<b>&lt;0.01</b>



# Adrenal

---

- Adrenal swelling and thickening has been described in infants with PA and also other causes of perinatal stress.
- Sonographically they may be enlarged or may lose their central echogenic stripe. Diffuse congestion of sinusoids has been described in histological specimens.

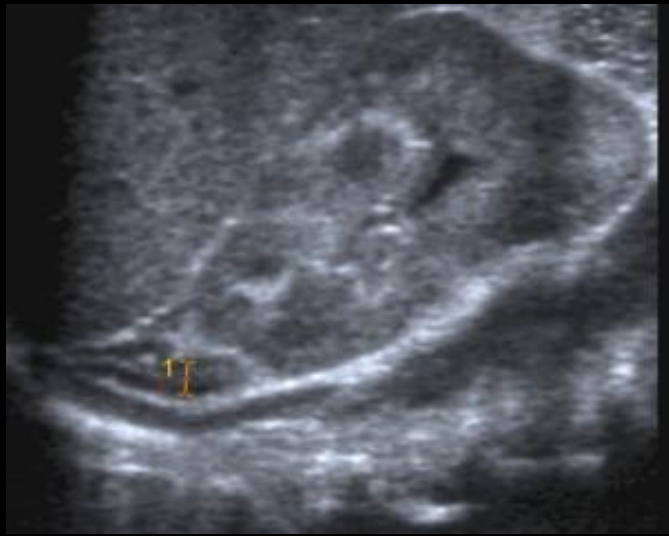
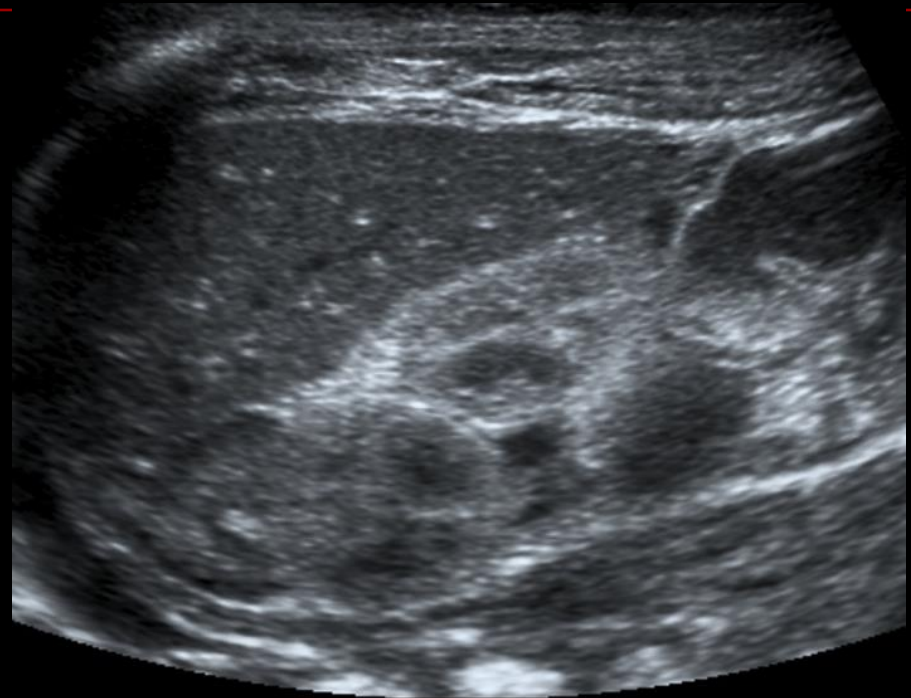
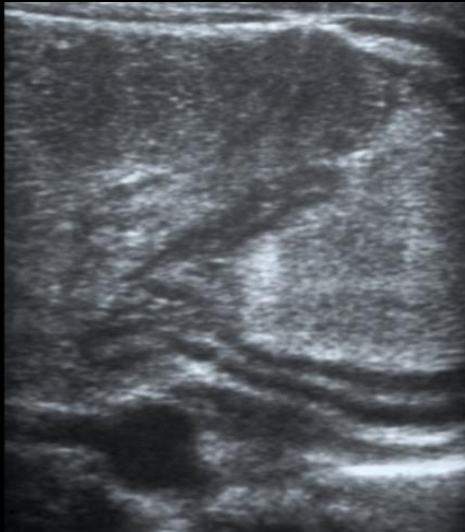
Koplewitz BZ, Daneman A, et al. *Pediatr Radiol* 1998; 28:958-962.

# Adrenal

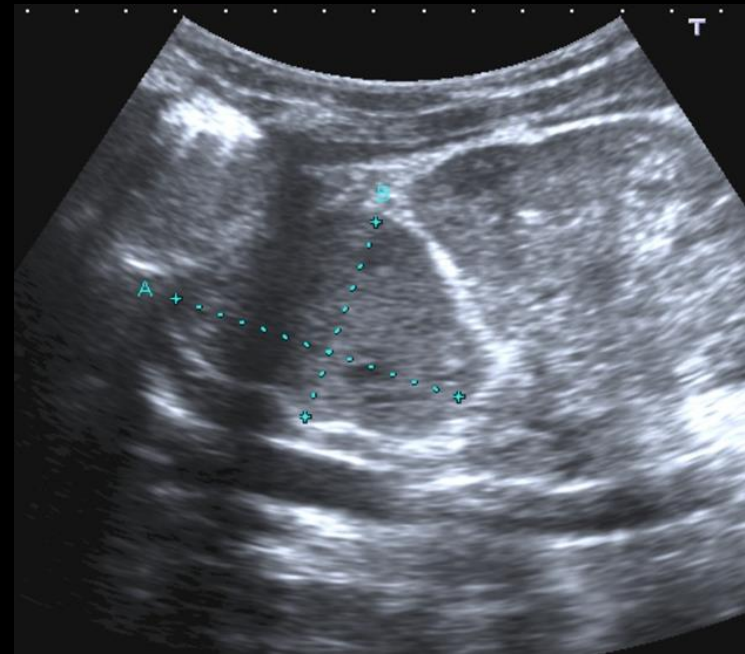
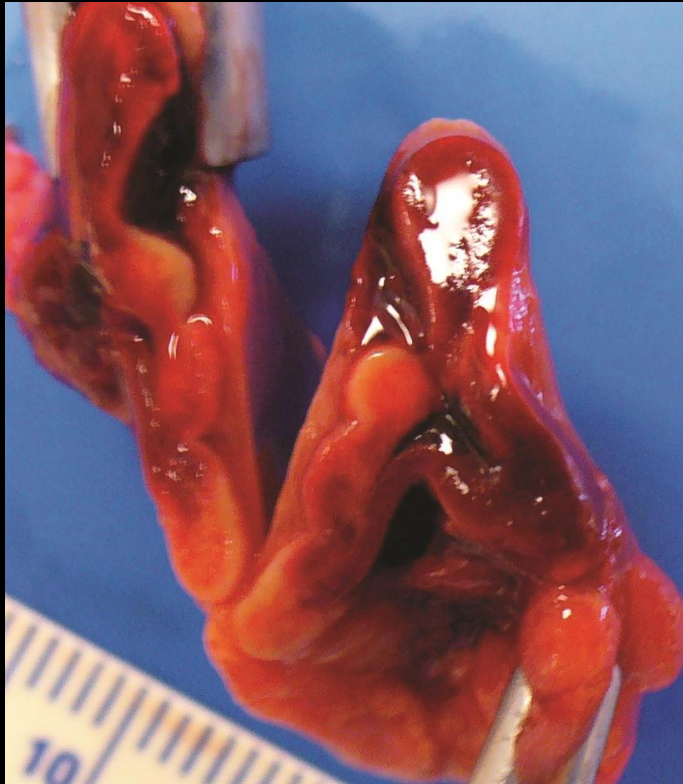---

- Adrenal hemorrhage is a relatively uncommon in neonates. It has been described in association with PA, birth trauma ,septicemia, and bleeding diathesis.
- The incidence ranges from approximately 1.7 per 1000 of autopsied neonates to approximately 3% in abdominal ultrasound

# Adrenal



# Adrenal

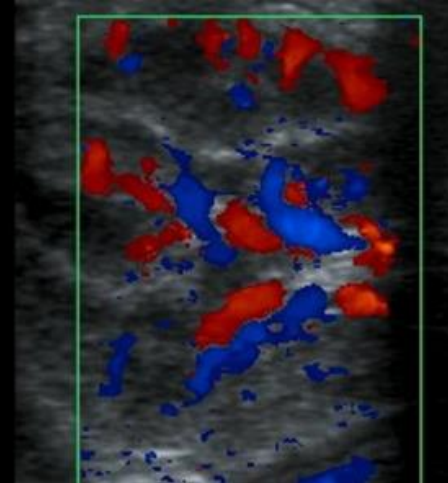
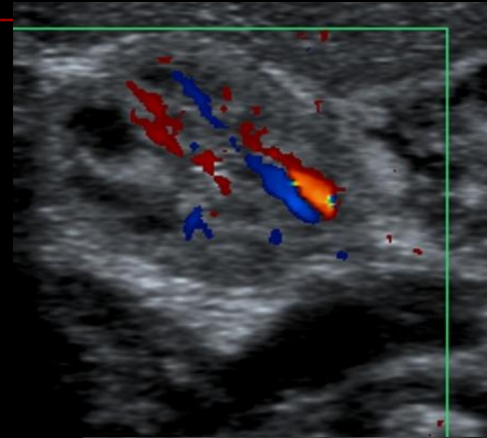
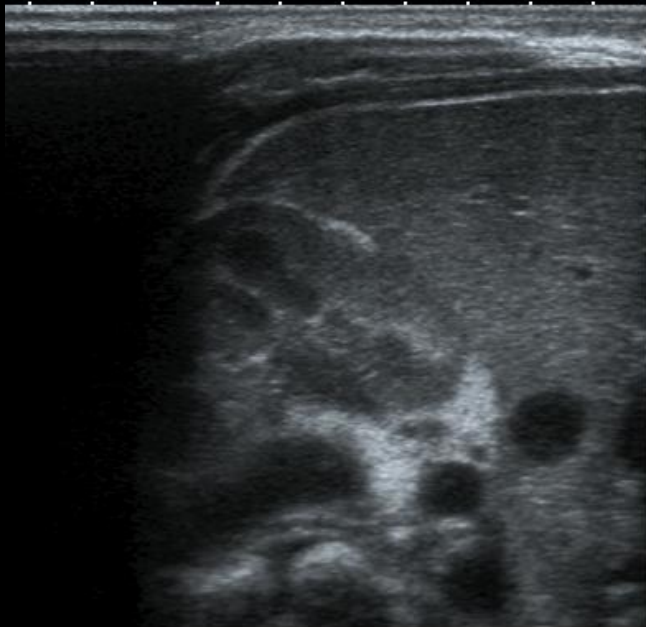


# Renal

---

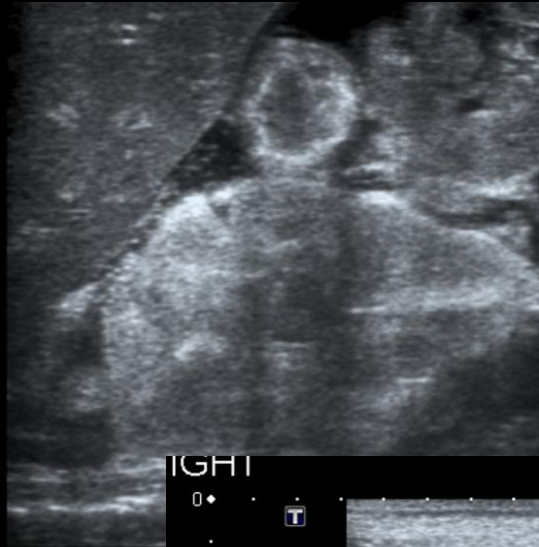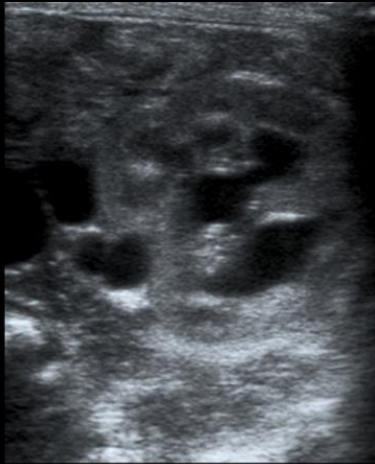- Shah et al examined 130 term neonates with HIE over a 10 year period and found that all infants developed either renal, cardiac, pulmonary or hepatic dysfunction following the initial insult.
- In another study conducted by Martin-Ancel et al , 2-year follow up of 72 term neonates with PA, revealed 42% renal, complications. In both these studies, clinical as well as laboratory findings were used as a measure of organ dysfunction.

# Renal





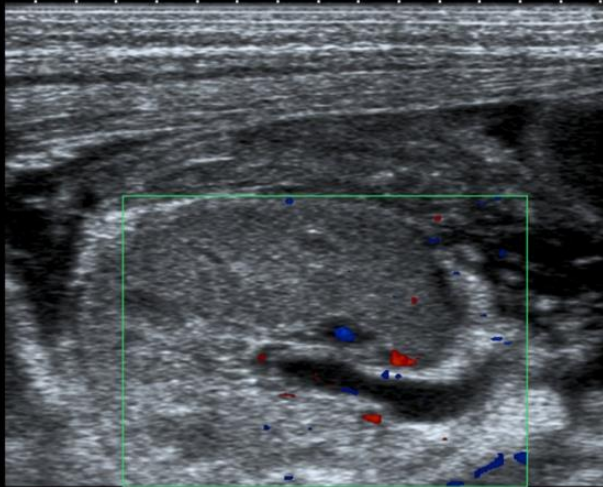
# Renal



RT-

7.5  
7.5  
cm/s

11LW4  
diffTB.0  
CF 4.0  
11 fps



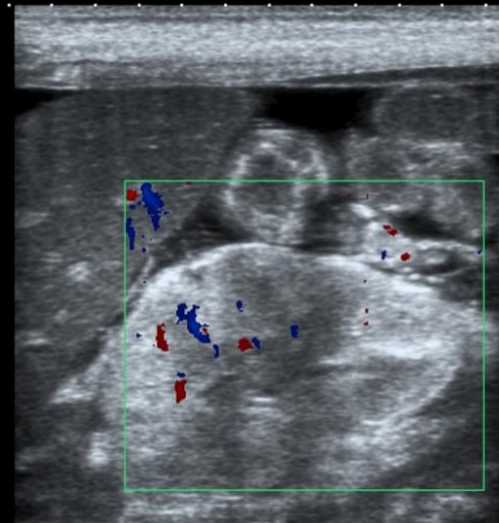
IGFI

0

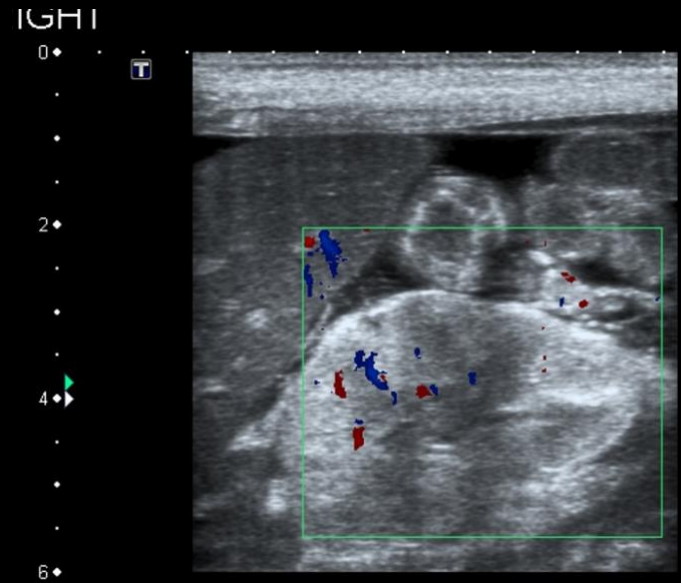
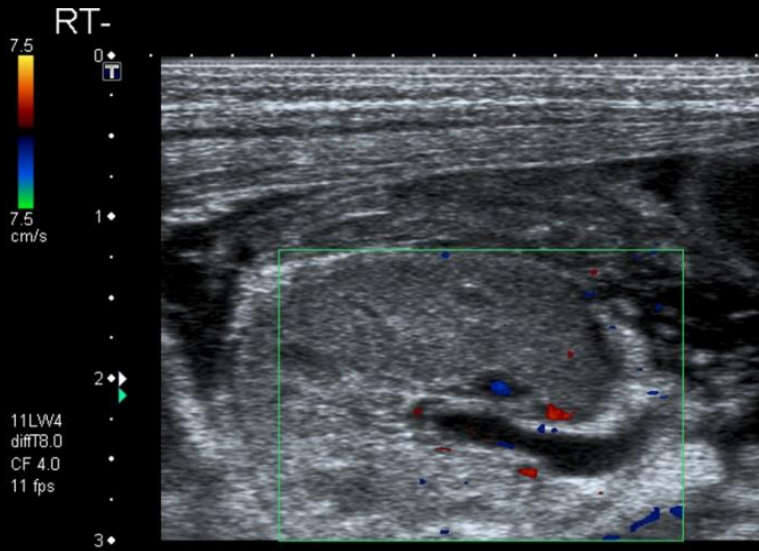
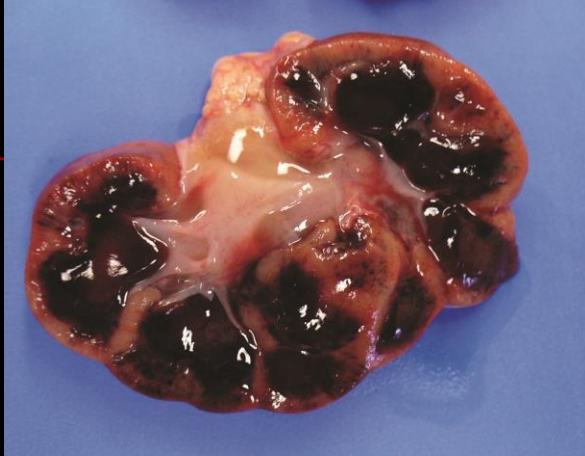2

4

6



# Renal



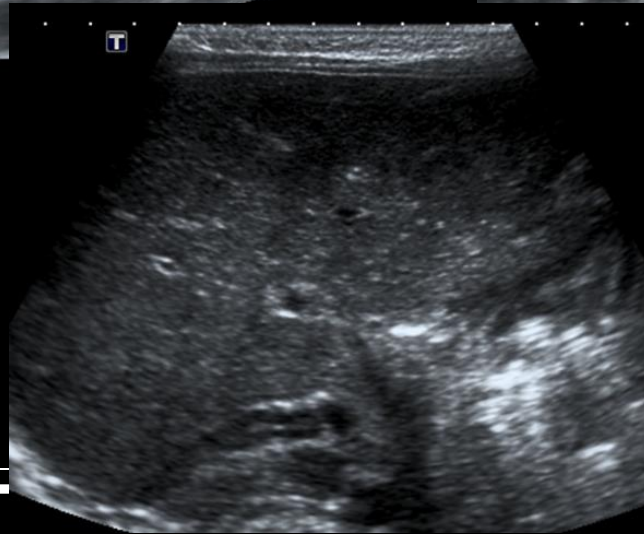
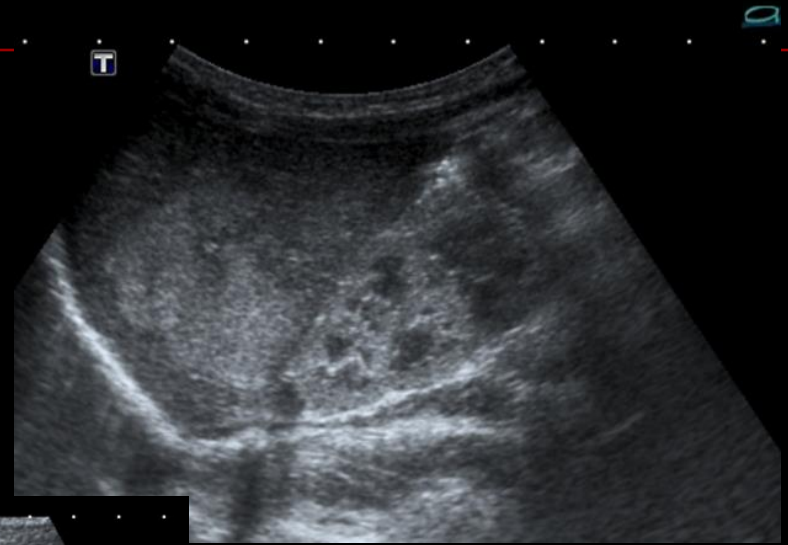
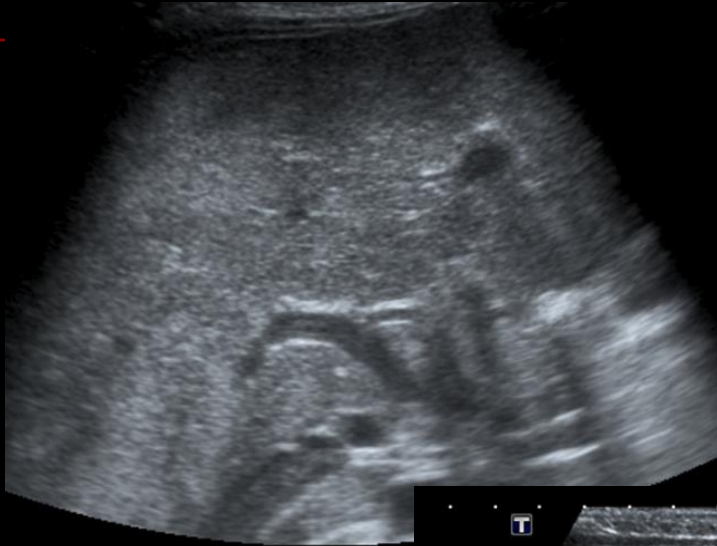

# Hepatic Injury

---

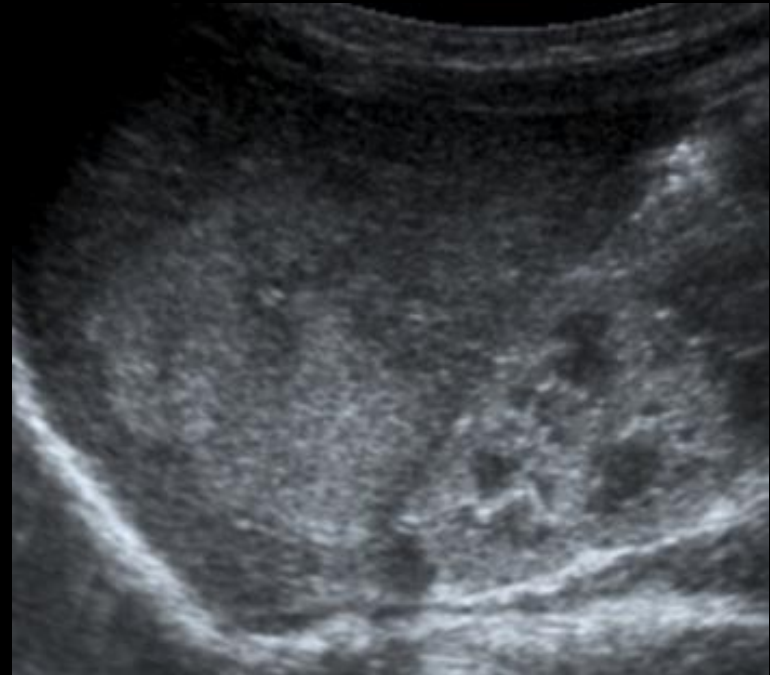
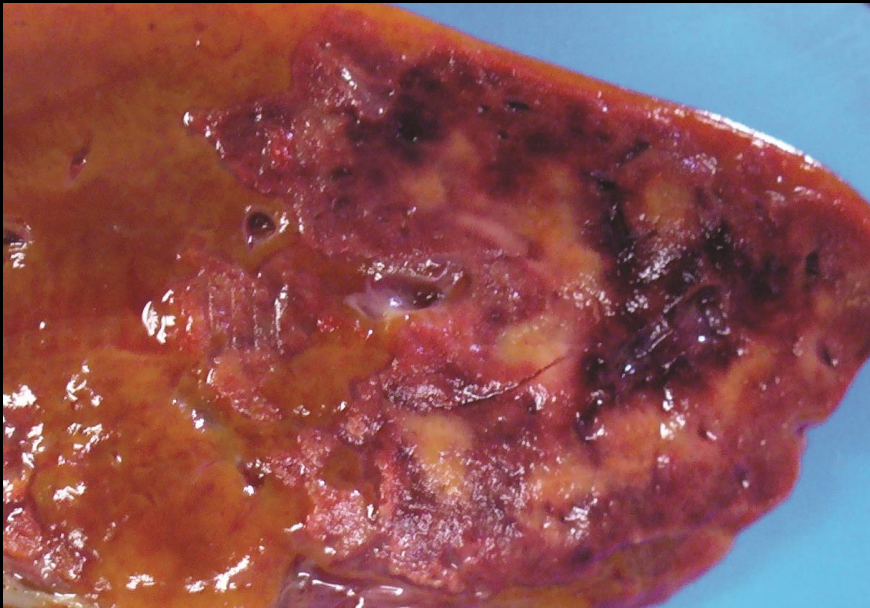
- Hepatic dysfunction in HII ranges from 29 to 48%.
- Neonatal hepatic failure is rare –regenerative capacity of the liver.

# Hepatic Injury



# Hepatic Injury

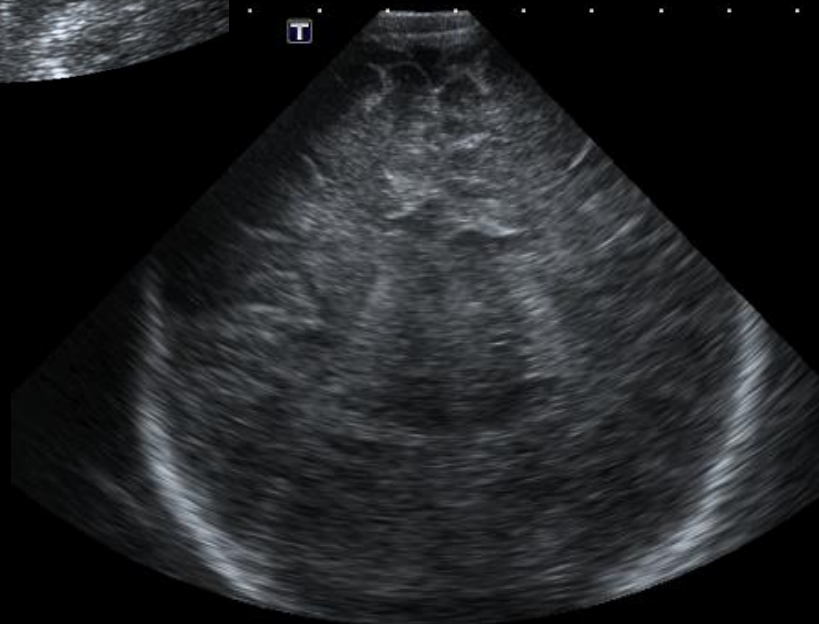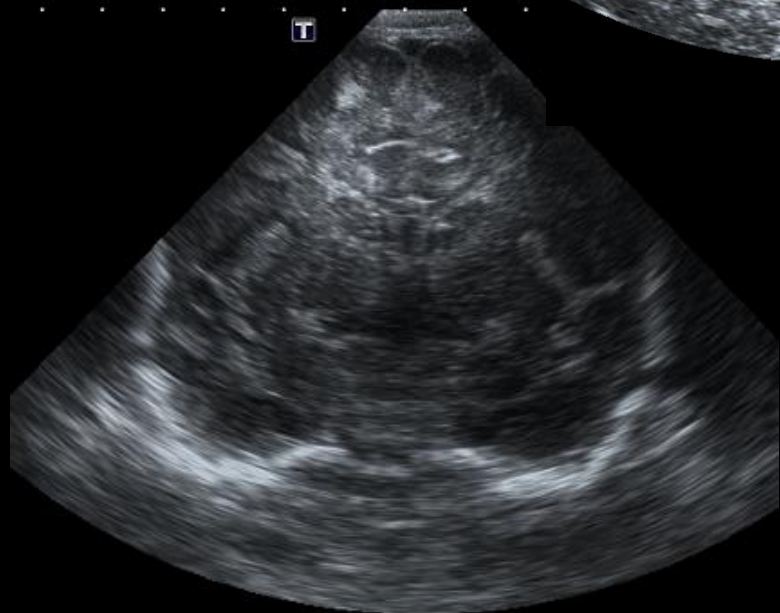
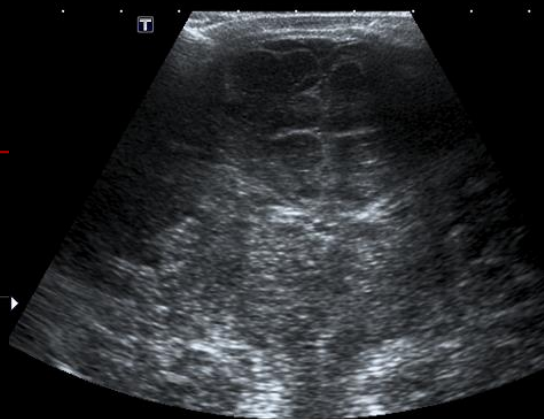
---

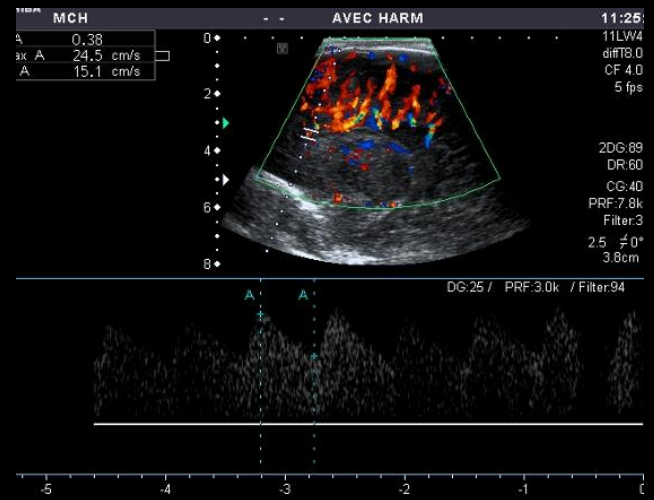
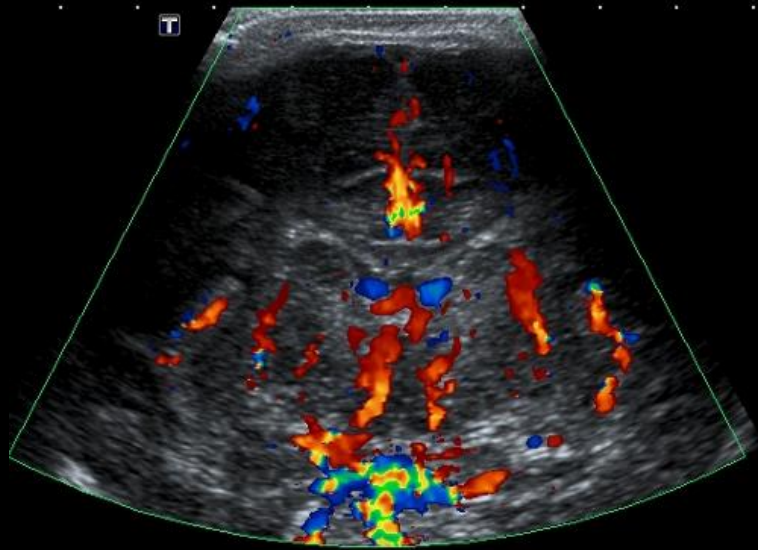


# Interesting case

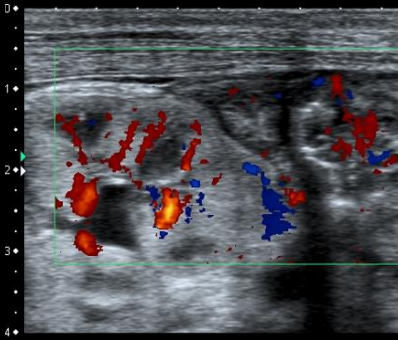
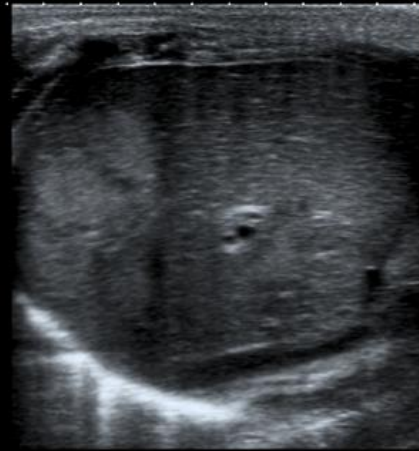
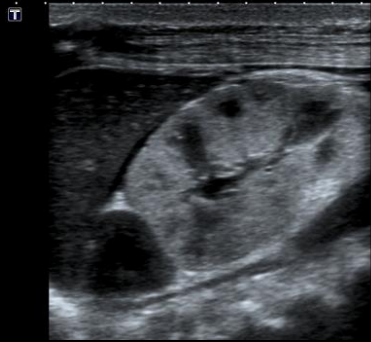---

- 1 day old male with Sarnat stage II-III
- Seizures, hepatic and renal failure and increase in lactate

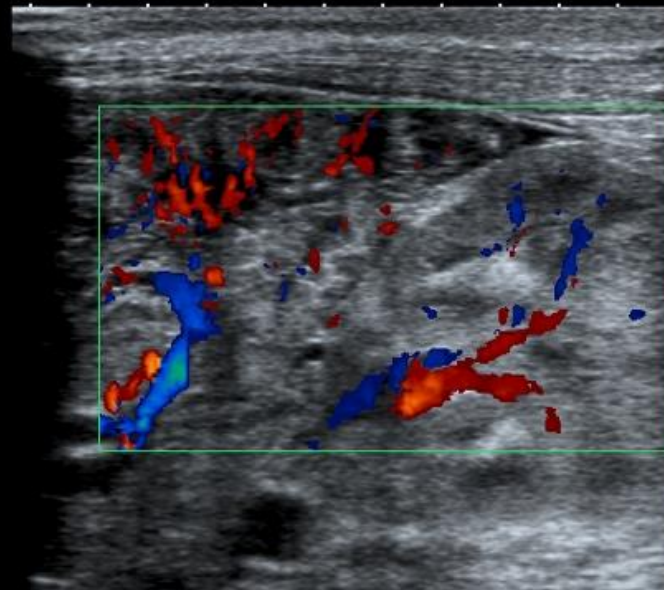
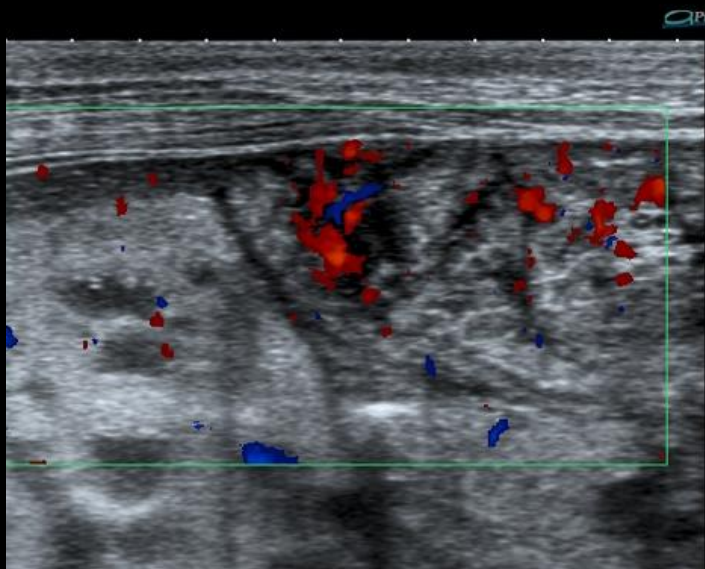












# Conclusion

---

- Review with illustration US and CDS perfusion findings of the brain and abdomen in neonatal HII.
- US is non-invasive modality, by the bedside, that can provide comprehensive imaging of multiple organs and systems.

# THANK YOU FOR YOUR ATTENTION!

---

