

Approach to Pediatric Abdominal X-Rays

Ben Pi, Dr. J. Jaremko
PedsCases
University of Alberta



Hello and welcome to a PedsCases' podcast on a basic approach to interpreting pediatric abdominal x-rays.

My name is Ben Pi and I am a medical student at the University of Alberta. This podcast was developed with the help of Dr. Jacob Jaremko, a pediatric MSK radiologist at the University Of Alberta Hospital, and the support of the PedsCases team.

Learning Objectives

1. Develop a basic approach to interpreting pediatric abdominal x-rays.
2. Identify relevant anatomy on pediatric abdominal x-rays.
3. Describe radiological findings of common abdominal pathologies

In the next 15 minutes, I hope to present one systematic approach to the interpretation of abdominal X-rays, describe some of the relevant anatomy, and finally familiarize you with some common abdominal pathologies.

Before you begin

- Correct patient, correct study
- Quality: penetration, exposure
- Views:
 - Supine
 - Upright
 - Lateral decubitus
 - Lateral Shoot-through

Before you begin any imaging, always ensure that the right patient and the right study is selected.

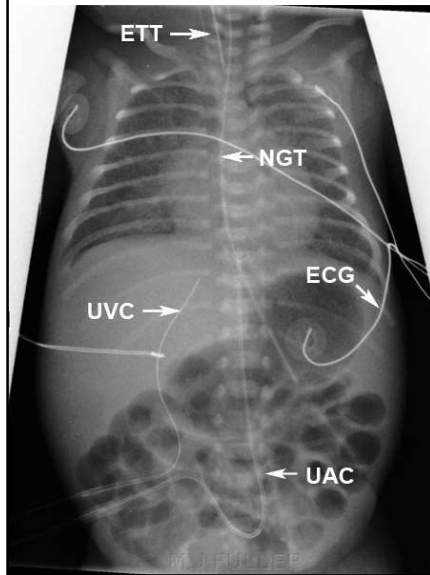
It is also important to keep in mind the different views available to you, as additional perspectives will complement and supplement the information found on a single view. Finally, quality of the X-ray is generally assessed with penetration and exposure. My friend and colleague Colin Siu has a detailed description of this in his podcast “Approach to Pediatric CXR”, also available on PedsCases website.

Approach

- Tubes, Lines, Other objects
- Air: Intra-luminal (ex. bowel gas pattern), Extra-luminal (ex. Free air)
- Solid Organs
- Osseous and Soft tissue

Let us begin with an overview of the general approach when interpreting X-rays. I personally like to think in 4 main sections: extrinsic objects such as tubes and lines, the air pattern, the solid organs, and finally the bony and soft tissues structures.

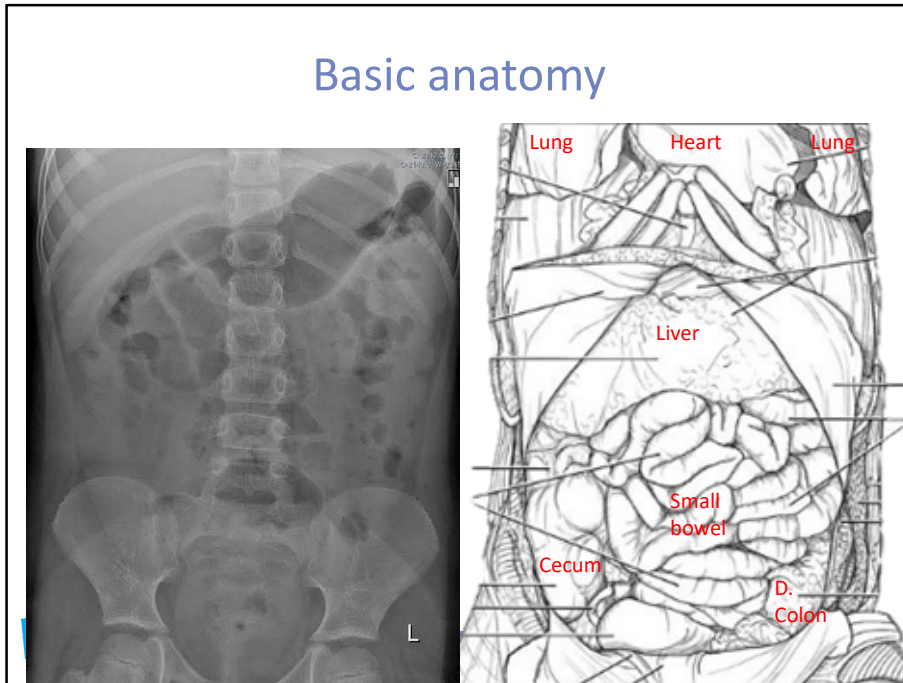
Tubes and Lines



- ETT = Endotracheal Tube
- NGT = Nasogastric Tube
- UVC = Umbilical Vein Catheter
- UAC = Umbilical Artery Catheter
- ECG = Electrocardiogram Lead

The first thing to comment on is the presence of extrinsic objects such as tubes, lines, medical devices or other objects that are not intrinsic to the body. This XR shows some of the common ones, such as ETT in the midline trachea, NGT descending midline and ending in the gastric body, UAC and UVC entering at the umbilicus and traversing cranially. There are certainly many more possibilities but we will not go into those details today.

Basic anatomy



Next let us go through our approach while keeping in mind some of the basic anatomy involved.

First we look at the GI tract, starting with the gastric bubble, usually seen in the LUQ.

Moving distally, you can see gas within the small and large intestines. In pediatrics it may be difficult to distinguish which is small and which is large bowel. You do not need to know this at the medical student level. Just understand that (similar to adults) the valvulae conniventes are present on the small bowel, whereas the haustra is on the large bowel.

Finishing off the GI Tract, you can identify gas in the rectum, usually located midline, behind the pubic symphysis. Be sure to look under the diaphragm bilaterally, as free-air in the peritoneum (ie. Pneumoperitoneum) will tend to collect here on an upright film.

Moving on to the solid organs, the liver edge may be faintly seen in the RUQ, and the spleen edge in the LUQ. The kidneys may also be seen located lateral to the thoracolumbar spine.

Next looking at the bones, along the lower ribs, thoracolumbar spine, sacro-iliac joint, ilium, ischium and pubis, finally the proximal femur if visible. Look for any cortical defects, deformities and asymmetries. Note that in this infant X-ray, the bones are all separated by soft tissue densities, which are simply cartilaginous, as the ossification centers have not ossified yet.

Finally look around the abdominal and pelvic soft tissue, ensure there are no masses, stones or defects within.

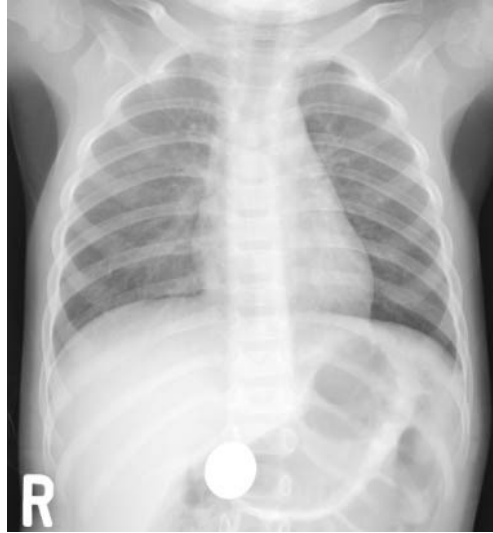
Tubes, lines, others

- Foreign Body

With the extrinsic and intrinsic structures in mind, let's go over some pathologies and practice our approach. Feel free to pause the video if you want to go over it by yourself and then compare.

Case 1

- A 2.5 year old female presents to your ER with a panicking mom

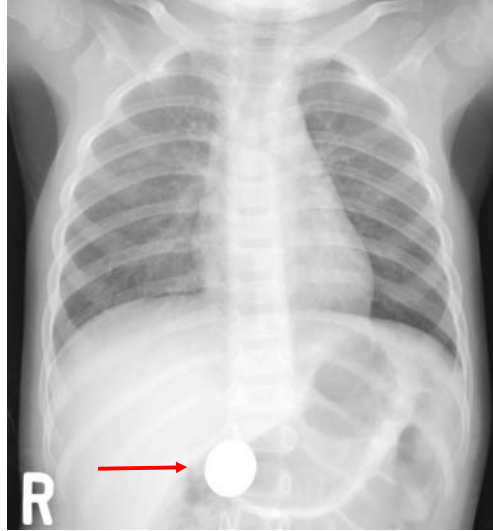


ped
CASES Pediatrics
for Medical
Students

Case 1 is a 2.5 year old female who presents to the ER with a panicking mom.

Case 1

- Foreign body ingestion (red)
 - NB. Some objects are not radiopaque
 - Dangerous = batteries, magnets, sharp objects



While this one might be obvious, let's still practice the approach to ensure we do not miss anything.

First of all, there are no tubes or lines. However, there is a round, radiopaque foreign body in the distal stomach near the pylorus. This could be a coin, which is innocuous, or a lithium button battery, which can erode through the gastrointestinal lining within hours and would be reason for urgent endoscopic removal.

Air pattern is normal, no dilatation of the bowel is seen. No free air is seen.

Solid organs, bones and soft tissue are unremarkable.

Foreign body (FB) ingestion is a very common presentation in the ER. Remember that FB can be found almost anywhere in the GI tract, and not all are seen on X-rays. Worrisome objects include batteries, multiple magnets, sharp objects or any objects causing obstruction and other symptoms.

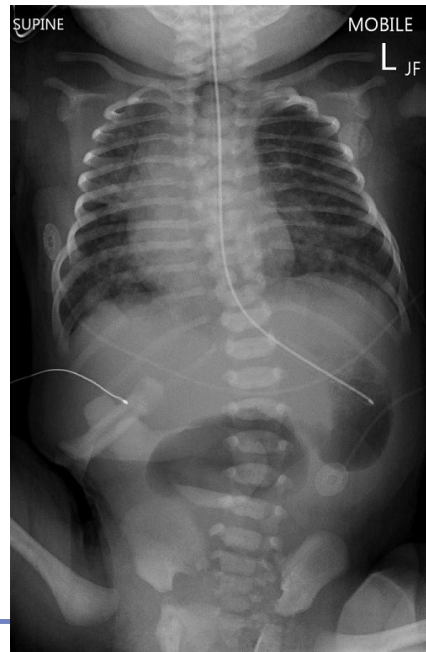Air

- Pneumoperitoneum
- Bowel Obstruction
- Necrotizing Enterocolitis
- Constipation
- Duodenal Atresia

Thinking of the next major component in our approach, let's look at some abnormal air patterns. This is usually the area of the highest yield.

Case 2

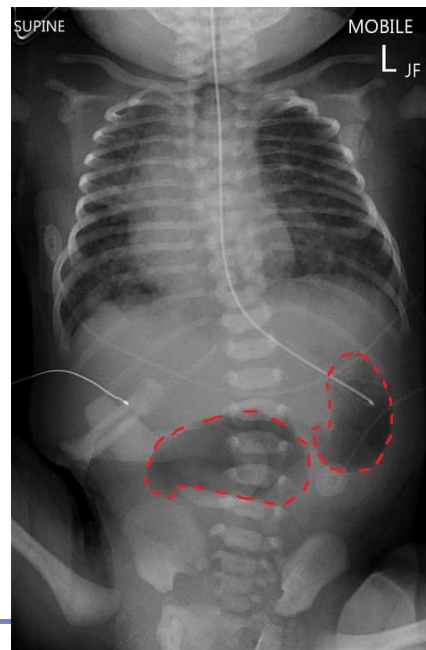
- 2d old male with bilious vomiting, irritability, and lack of meconium passage



Our next case is a 2d old male presenting with bilious vomiting, irritability, and lack of meconium passage. This is his abdominal x-ray.

Case 2

- Duodenal Atresia
 - Double bubble sign (gas filled stomach and duodenum. Note the lack of gas distally)



There is an ECG lead seen coming in from the L flank, as well as an NG tube placed appropriately with tip in the gastric fundus.

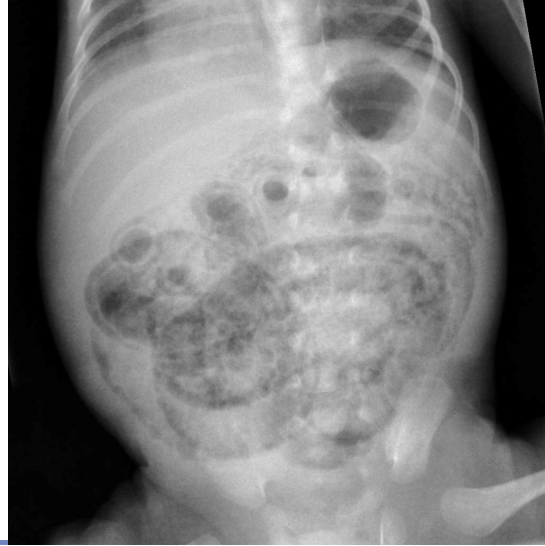The notable abnormality is a very large gastric air bubble, with 1 additional pocket of air just distally. Very aptly named the double bubble sign, this abnormal air pattern represents duodenal atresia, which is commonly seen in kids with Down Syndrome. Note that no air is seen distally, consistent with an obstructive picture. No free air is seen.

Normal liver and spleen edge are faintly seen in the R and L upper quadrants.

Bones and soft tissue are otherwise unremarkable.

Case 3

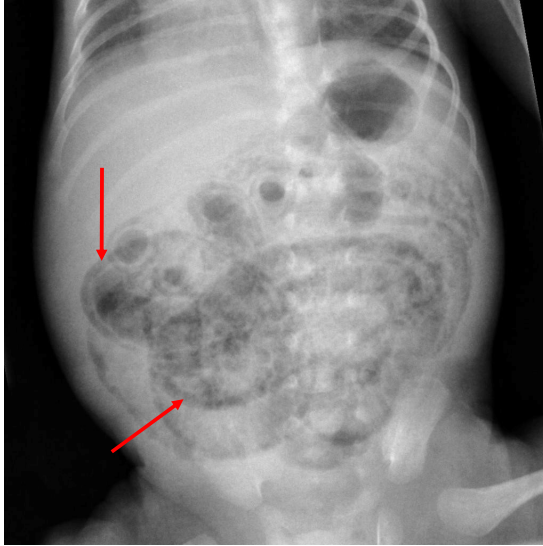
- 1 month old ill-appearing premature infant with poor feeding, bloody diarrhea, abdominal distention, and failure to thrive.



Our next case is a 1 month old ill-appearing premature infant with poor feeding, bloody diarrhea, abdominal distention, and failure to thrive.

Case 3

- Necrotizing Enterocolitis
 - Pneumatosis Intestinalis (red)
 - Bowel loop distention
 - Portal venous air (not seen here)
 - Pneumoperitoneum (not seen here)



We do not see any extrinsic lines and tubes are seen.

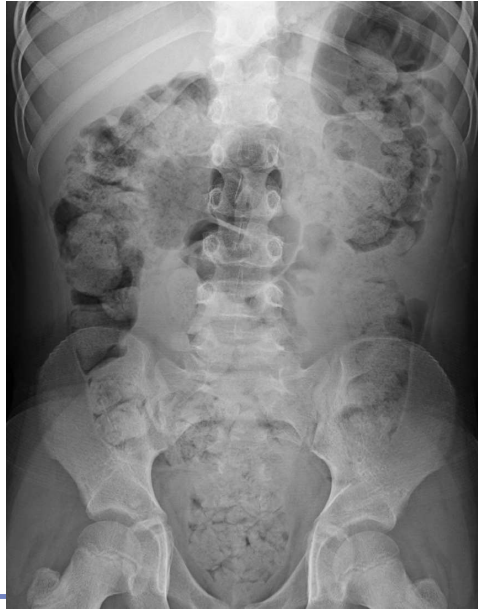We do however see air that appears to be just beyond the lumen wall. This specific appearance of gas within the bowel wall is called pneumatosis intestinalis, which is caused by gas-producing bacteria in the bowel wall. This is seen with necrotizing enterocolitis, a potentially deadly condition commonly associated with prematurity.

No free air is seen here, but pneumoperitoneum is not uncommon with NEC. Sometimes you may also see gas in the hepatic veins in the RUQ.

Other organs, bones and soft tissue are unremarkable.

Case 4

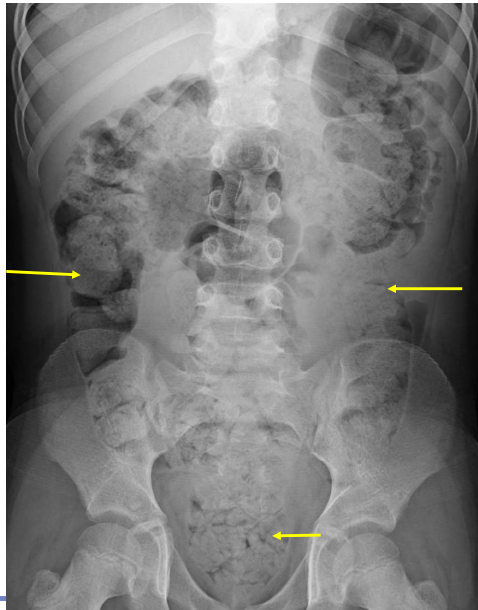- A 10 year old child presents with vague intermittent abdominal pain.



Our next case is a 10 year old child presents with vague intermittent abdominal pain.

Case 4

- Constipation
 - Intraluminal fecal matter (yellow)
 - Complications include overflow incontinence, toxic megacolon, perforation, etc.



ped
CASES Pediatrics
for Medical
Students

No extrinsic lines or tubes are seen.

In this case, we still see bowel gas throughout the abdomen. In addition, there is intraluminal solid matter, which is in keeping with fecal loading or constipation. No bowel dilation or free air is seen.

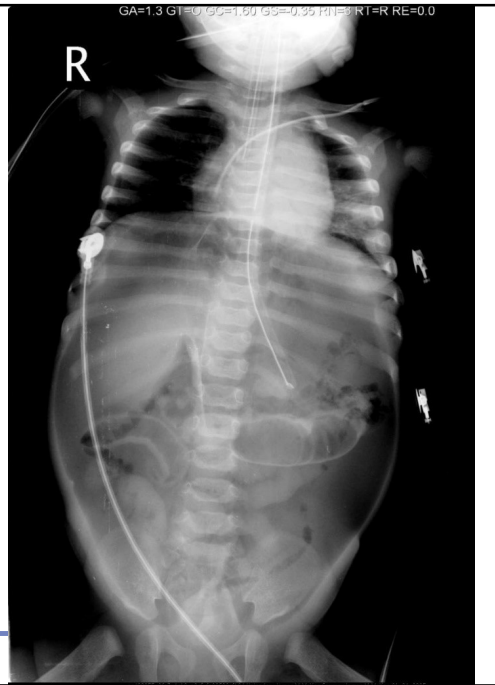Solid organs are within normal limits. No bony or soft tissue abnormalities.

Note that constipation is very common in the pediatric population, especially during times of transition (ex. potty-training, starting school, moving, etc). They may end up in a cycle of stool retention, holding behaviors and pain, which can lead to serious sequelae such as overflow incontinence, UTI, even toxic megacolon and perforation.

Case 5

- 2mo old infant with significant abdominal distention, vomiting, and irritability

ped
CASES Pediatrics
for Medical
Students

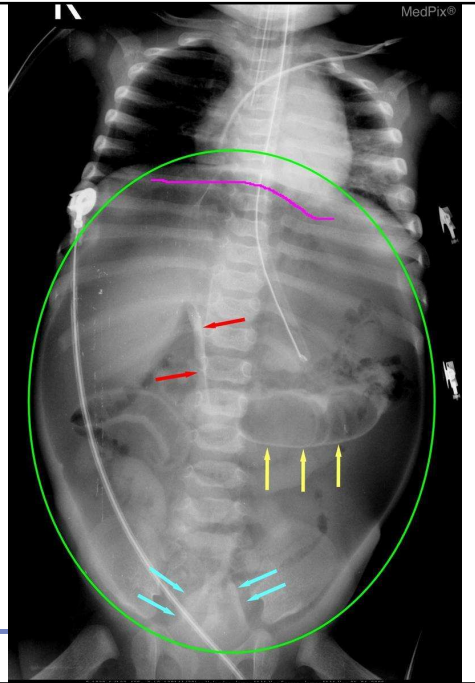


Our next case is a sick appearing 2mo old infant with significant abdominal distention, vomiting, and irritability.

Case 5

- Pneumoperitoneum
 - Football sign (green)
 - Rigler's sign / Double wall sign (yellow)
 - Continuous diaphragm sign (magenta)
 - Falciform ligament sign (red)
 - Inverted V sign (teal)

peds
cases
Pediatrics
for Medical
Students

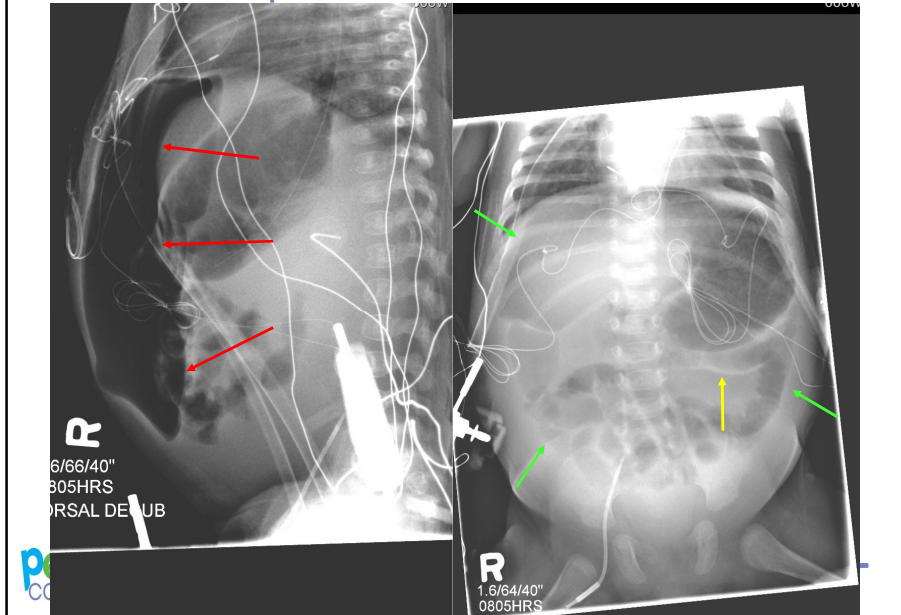


In this radiograph, you can see ETT, OG Tube and ECG leads.

The air pattern is markedly abnormal, showing multiple signs of pneumoperitoneum. There is air under the diaphragm (continuous diaphragm sign in magenta color). Rigler's sign is also present at the yellow arrows, where both sides of the bowel wall are seen. Finally in the red, the outline of the falciform ligament is also seen. All of these signs are the result of free air (low density) being directly next to another structure of higher density.

Pneumoperitoneum indicates perforation of a hollow viscus, and may arise from various etiologies. ex. NEC (most common), Mec Ileus, Hirschsprung, PUD, intestinal atresia

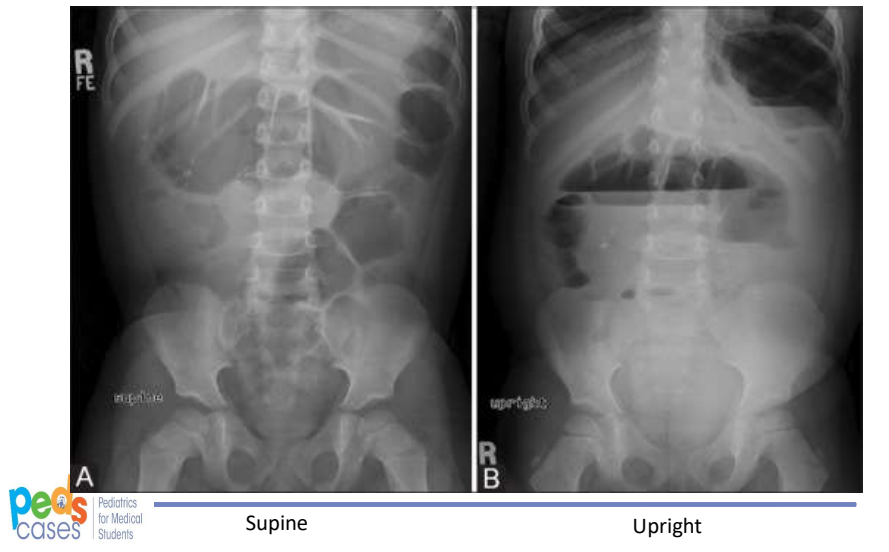
Case 5 Companion Case



Here is another case with findings of pneumoperitoneum on the AP view (right), including Football sign and Rigler's sign. Notice the large pocket of air (lucency) at the top of the abdomen on lateral view.

Case 6

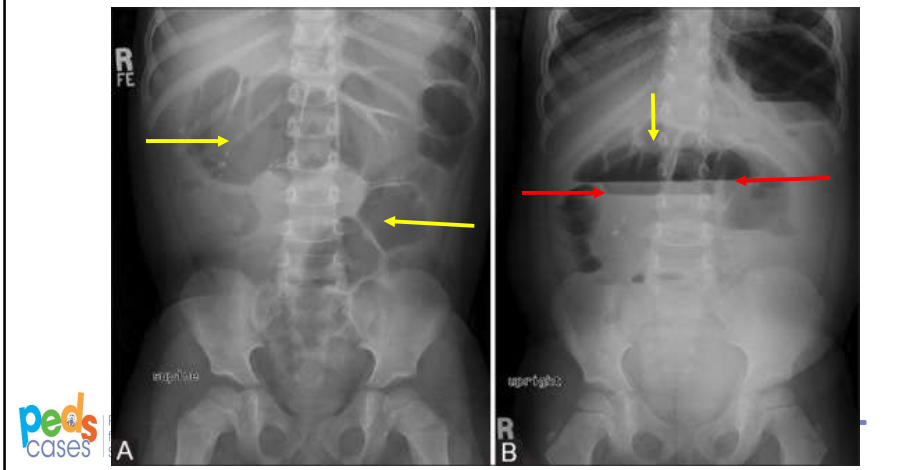
- 4 year old female with bloating, nausea and vomiting



In this next case, we have a 4 year old female with bloating, nausea and vomiting. Here we see 2 radiographs, an upright view, and a supine view.

Case 6

- Bowel obstruction
 - Air-fluid levels (red)
 - Dilated loops of bowel (yellow)



No extrinsic lines or tubes

Air pattern is abnormal, with multiple dilated bowel loops, which is more evident on the supine view shown in the yellow. On the upright view, the intraluminal air shifts, and demonstrates step-ladder like air-fluid levels in the red, which is highly suspicious for intestinal obstruction. There are a number of causes for obstruction including intestinal atresia, meconium plug syndrome, and so forth. The differential is less important here, we just want you to appreciate that the air pattern is abnormal as well as the air-fluid levels.

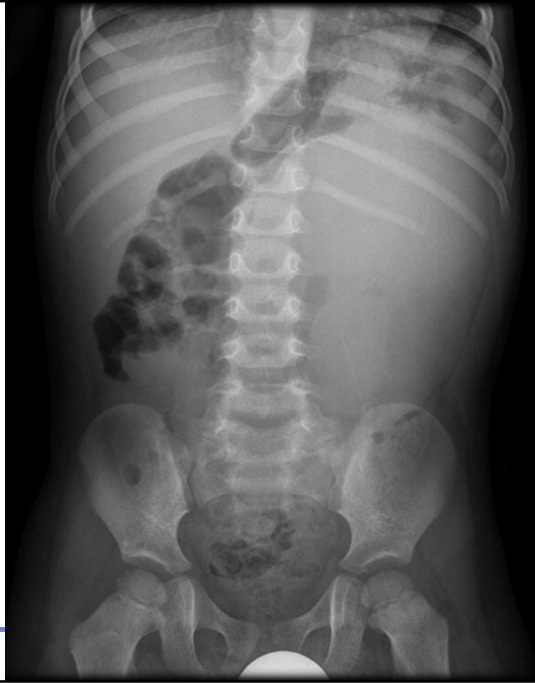Organ

- Wilm's Tumor / Nephroblastoma
- Gastroschisis

Now let's look at some organs pathologies. Keep in mind what normal anatomy should be when you interpret the following X-rays.

Case 7

- 3yo male with asymptomatic abdominal mass and intermittent discomfort.

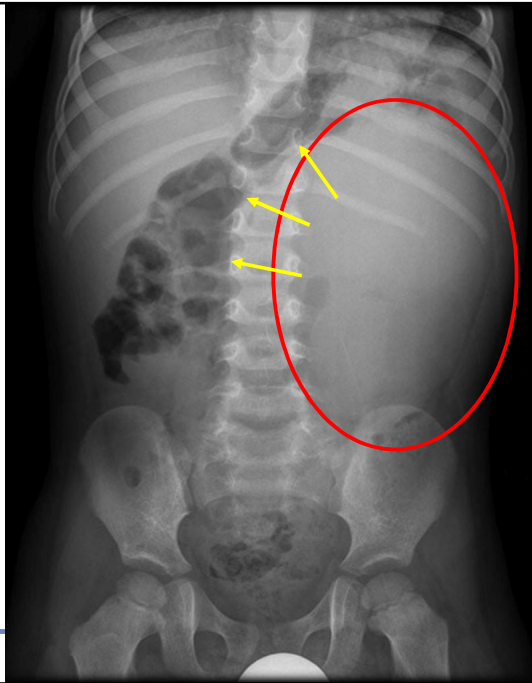


This next case is a 3yo male with asymptomatic abdominal mass and intermittent discomfort.

Case 7

- Wilm's Tumor
 - Soft tissue opacity (red)
 - Displacement of adjacent bowel (yellow)

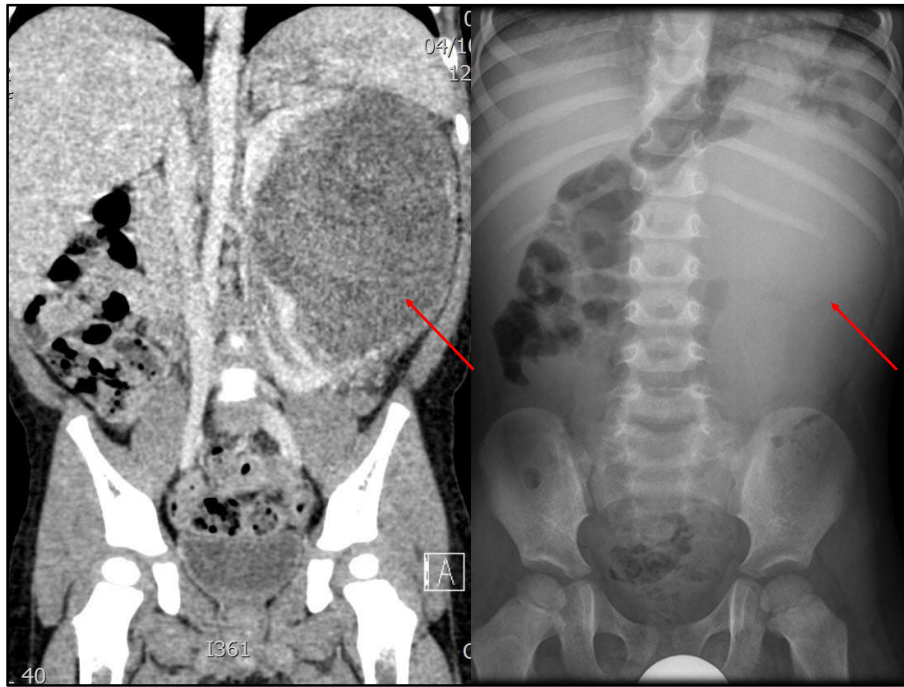
peds
cases | Pediatrics
for Medical
Students



No lines or tubes seen.

The bowel gas may initially look non-specific, but on closer examination, you may appreciate that it does not seem to go to the right side.

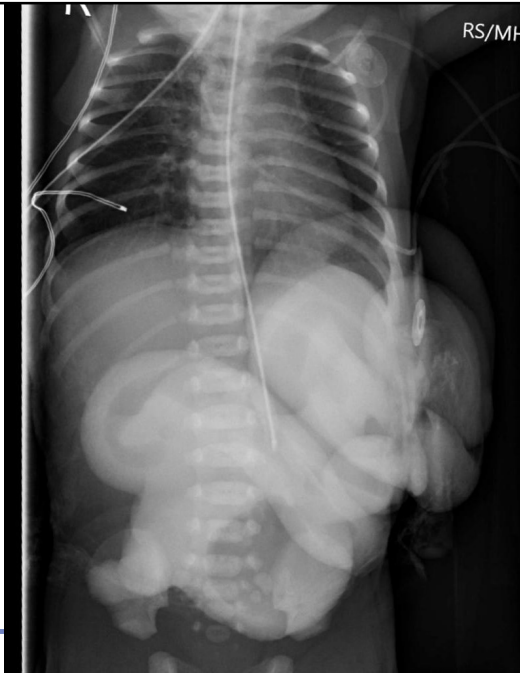
A liver edge is faintly seen in the RUQ. Additionally you will notice a large soft tissue density in the R side, spanning the upper and lower quadrants. It is difficult to confer a specific diagnosis at this point, but further imaging did reveal Wilm's tumor or Nephroblastoma, the most common childhood abdominal malignancy.



Here is a CT correlate to the previous case seen on the coronal view. As you can see, there is a large LUQ mass representing a Wilm's Tumor.

Case 8

- Newborn male with bowel mass outside the body, not enveloped by a membrane

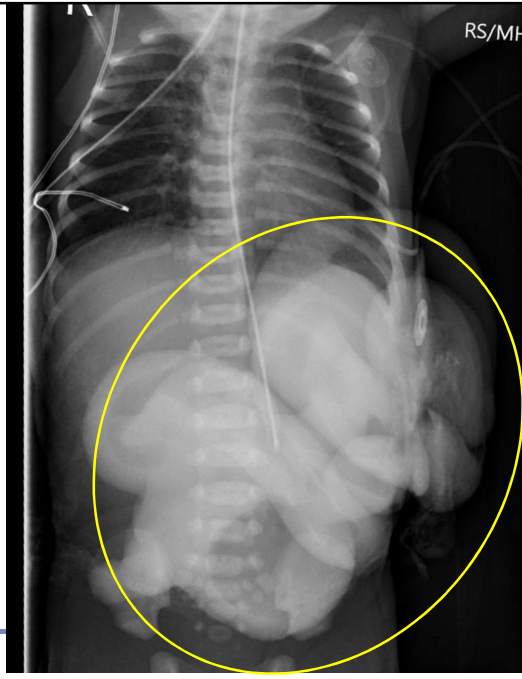


The next case is a newborn male with bowel mass outside the body, not enveloped by a membrane. An x-ray was taken shortly after birth.

Case 8

- Gastroschisis
 - Extrusion of bowel into amniotic cavity (yellow)
 - Through defect in anterior abdominal wall

peds
CASES Pediatrics
for Medical
Students



This one should be fairly obvious, but let's still go through the approach.

In this radiograph, you can see ECG wires and OG tube.

Minimal amount of air is seen in the bowel loops. No free air under the diaphragm.

Multiple segments of bowel appear outside the body with no obvious membranous covering. This represents gastroschisis, the extrusion of bowel in to the amniotic cavity through a defect in the anterior abdominal wall. The other organs are unremarkable.

Osseous structures are intact.

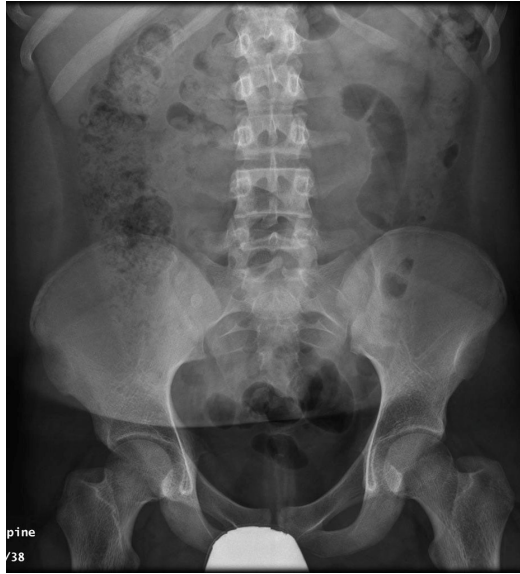Osseous and Soft Tissue

- Fecalith

Moving on the final component, don't forget to check the bones and soft tissue.

Case 9

- 16yo M presents to the ED with 2d history of central to right sided abdominal pain, nausea and fever.

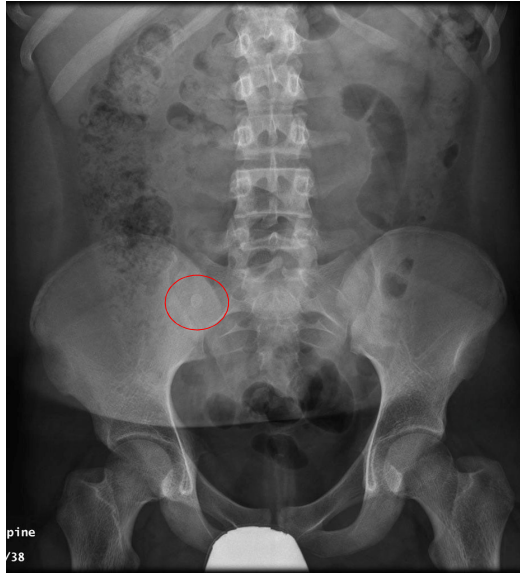

ped
CASES Pediatrics
for Medical
Students

Our final case is a 16yo M presents to the ED with 2d history of central to right sided abdominal pain, nausea and fever. This is his abdominal x-ray.

Case 9

- Fecalith (red)
 - Calcified lesions
 - May be suggestive of appendicitis (typically RLQ), but not very sensitive



ped
CASES Pediatrics
for Medical
Students

No lines or tubes are seen.

There is non-specific gas pattern is seen within the entirety of the bowels. Some fecal material is noted in the descending colon.

No abnormalities of the solid organs.

Tracing over each bone, there is no obvious osseous lesions. However looking at the abdominal soft tissue, we see a round 1-2mm hyperdense lesion in the RLQ. Given the clinical history, this favors a radiopaque fecalith and acute appendicitis. Other calcified lesions that you may see include renal calculi, but these are usually seen more medially in the ureters, which descend beside the transverse processes.

Resources

- Learning Radiology – excellent teaching files on pediatrics and other topics

<http://www.learningradiology.com/toc/tocsubsection/tocpeds.htm>

- Radiology Assistant – another friendly teaching site

<http://www.radiologyassistant.nl/en/p526bd2e468b8c/lines-and-tubes-in-neonates.html>

- Radiopaedia – Radiology encyclopedia for junior and senior students alike

<http://radiopaedia.org/>



That brings us to the end of our podcast. I hope you now have a slightly better understanding of the pediatric abdominal X-ray, and will have a basic approach if asked to interpret one. Just remember the 4 main elements: extrinsic lines, the air pattern, major organs and the osseous and soft tissues.

If you want some extra readings, practice questions or tips and tricks, here are some additional resources that I found helpful.

References

- Appendicolith. Case courtesy of A.Prof Frank Gaillard, Radiopaedia.org, rID: 5881.
- <http://radiopaedia.org/cases/appendicolith-2>. Accessed Sept 15, 2016.
- Berrocal T, Lamas M, Gutiérrez J, Torres I, Prieto C, del Hoyo ML. Congenital Anomalies of the Small Intestine, Colon, and Rectum. RadioGraphics 2009;19(5):1219-1236. doi:10.1148/radiographics.19.5.g99se041219.
- D'Alessandro DM and D'Alessandro MP. Figure 13. AP radiograph of the chest showing a round foreign body in the antrum / pylorus of the stomach. [Internet]. Available from: <https://pediatriceducation.org/2005/03/28/oh-where-oh-where-did-that-little-foreign-body-go/>. Accessed July 23, 2016. Reproduced with permission from Dr. D'Alessandro.
- Duodenal Atresia. Case courtesy of Dr Ian Bickle, Radiopaedia.org, rID: 24277. <http://radiopaedia.org/articles/double-bubble-sign>. Accessed Sept 15, 2016.
- Gastroschisis. Case courtesy of Dr Jeremy Jones, Radiopaedia.org, rID: 23837. Available from: <http://radiopaedia.org/cases/gastroschisis-4>. Accessed July 2, 2016



Finally, I would like to thank PedsCases, Dr. Mel Lewis, and Dr. Jaremko for their contribution and support in making this podcast. I would also like to thank all the authors who posted images for sharing and educational purposes under the Creative Commons license.

I hope you found it helpful. If you have any questions or concerns regarding the podcast, please do not hesitate to contact me at pi@ualberta.ca.

Thank you and good day.

References

- Heilman J. Significant constipation in an 8 year old as seen on plain X ray. [Internet]. Available from: [https://commons.wikimedia.org/wiki/File:Constipation\(lots\).png#/media/File:Constipation\(lots\).png](https://commons.wikimedia.org/wiki/File:Constipation(lots).png#/media/File:Constipation(lots).png). Accessed Sept 23, 2016.
- Karrer FM. Pediatric Duodenal Atresia. Medscape. Available from: <http://emedicine.medscape.com/article/932917-overview>. Accessed July 12, 2016.
- Khan N, Phillips GS, Heller MT, Linam LE, Parnell SE, Moshiri M, Bhargava P. Imaging in pediatric small bowel transplantation. Indian J Radiol Imaging. 2014 Oct-Dec; 24(4): 379–388.
- McKee JM. Pneumoperitoneum secondary to gastric perforation. In: National Library of Medicine MedPix. [Internet]. Available from: <https://medpix.nlm.nih.gov/case?id=59680252-dc5b-4fc4-bb40-87a20ac15576>. Accessed June 20, 2016.
- Necrotising Enterocolitis. Case courtesy of A.Prof Frank Gaillard, Radiopaedia.org, rID: 9793. Available from: <http://radiopaedia.org/articles/necrotising-enterocolitis-1>. Accessed July 3, 2016.

References

- Normal abdominal radiograph – Pediatric. Case courtesy of Dr Ian Bickle, Radiopaedia.org, rID: 46426. Available from: <http://radiopaedia.org/cases/normal-abdominal-radiograph-paediatric>. Accessed July 30, 2016
- Paulino AC. Wilms Tumor. Medscape. Available from: <http://emedicine.medscape.com/article/989398-overview>. Accessed July 12, 2016.
- Stanford Bassett Anatomy. Abdominal organs in situ, general anterior view. In: Lane Stanford Medical Library. [Internet]. Stanford, California, USA. Available from: <http://lane.stanford.edu/biomed-resources/bassett/raw/bassettLargerView.html?t=largerView&bn=138-3>. Accessed August 9, 2016
- WikiFoundry. Umbilical catheter position. [Internet]. Available from: <http://www.wikiradiography.net/page/Neonatal+Abdominal+Radiography>. Accessed July 1, 2016
- Wilm's Tumor. Case courtesy of A.Prof Frank Gaillard, Radiopaedia.org, rID: 5957. Available from <http://radiopaedia.org/cases/wilms-tumour>. Accessed July 12, 2016.