

Approach to Interpreting Pediatric Chest X-rays



Developed by Colin Siu and Dr. Melissa Chan for PedsCases.com.

Welcome to PedsCases' video on an approach to interpreting pediatric chest x-rays. My name is Colin Siu and I'm a medical student at the University of Alberta. This podcast was developed with Dr. Melissa Chan, a pediatric emergency physician and Clinical Lecturer at the University of Alberta and Stollery Children's Hospital in Edmonton, Alberta, Canada

Learning Objectives

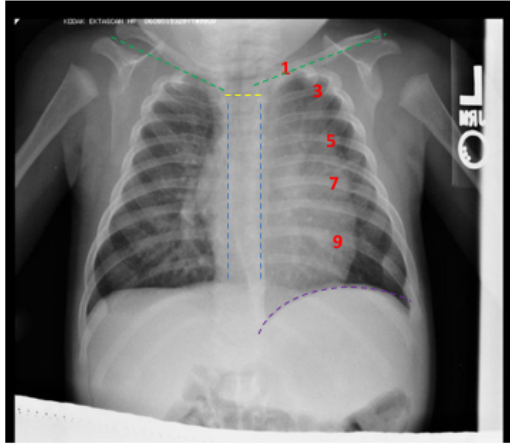
1. Demonstrate an approach to interpreting pediatric chest x-rays.
2. Describe expected radiographic findings of common pediatric conditions including: cardiomegaly, pneumothorax, pleural effusion, pneumonia, asthma, cystic fibrosis, and non-accidental injuries.

The approach that will be explored in this video is that of a top to bottom approach. We will begin by looking at the thymus, followed by the mediastinum, heart, lung fields, diaphragm and end off with looking at the bony structures.

The learning objectives for this video is to 1) Demonstrate an approach to interpreting pediatric chest x-rays and 2) Described expected radiographic findings of common pediatric conditions including cardiomegaly, pneumothorax, pleural effusion, pneumonia, asthma, cystic fibrosis, and non-accidental injuries.

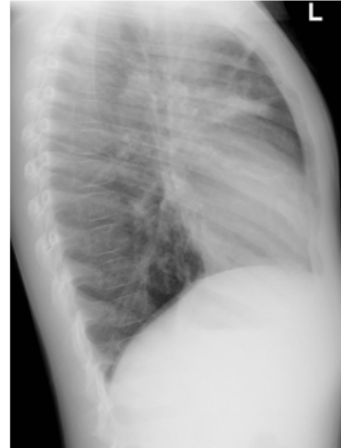Chest X-Rays

Pediatric PA Film



(http://images.radiopaedia.org/images/574436/9cec9b251b52a3f59bdcd6b5ea058b_jumbo.jpg)

Pediatric Lateral Film



(http://images.radiopaedia.org/images/1990835/a2aea705346f7cbf486aa37676f6d2_jumbo.jpg)



Pediatrics
for Medical
Students

Developed by Colin Siu and Dr. Melissa Chan for PedsCases.com.

This video is a series of cases that will take you step by step through how to interpret a pediatric chest x-ray. We will begin by understanding the components that make up an adequate quality film and then move on to the actual interpretation of pediatric chest x-rays, moving through each organ system with a top-down approach. Please feel free to pause the video at any point if you would like to take a stab at interpreting the x-ray or coming up with a diagnosis prior to the big reveal.


Now, let's jump right into it. The most commonly ordered pediatric x-ray is the posterior-anterior film. A posterior-anterior or PA film is preferable to an anterior-posterior film as the latter may result in a magnified heart shadow. AP films are reserved for situations where the patient is too unstable to move and a portable machine, which can only produce AP films, is required. Firstly, check that the correct x-ray views have been obtained and that the film is that of your patient. Before analyzing the film, you must ensure that the film is of adequate quality. You can do this by examining for three factors which are: penetration, inspiration, and rotation. Firstly, penetration. You should be able to appreciate the thoracic spine through the heart. (1) If the film is underpenetrated, the left hemidiaphragm will not be visible. (2) Secondly, inspiration. An adequate film will show 9 to 10 posterior ribs. (3) Pediatric chest x-rays must be taken with a sufficient inspiratory effort from the patient as a film taken on expiration or with minimal inspiratory effort may exaggerate the heart size and bronchovascular markings. Thirdly, rotation. The spinous process of the vertebral body should be equidistant from the medial ends of

the clavicle. (4) Additionally, ensure that you order two views when ordering any pediatric chest x-ray such as a lateral view in addition to a PA view. Lastly, be aware that lines and tubes often appear on chest films – though they will not be covered in this video, it is important to recognize what they are and to not mistake them as pathological features.

Thymus

6 MO OLD WITH COUGH, FEVER AND INCREASED WOB

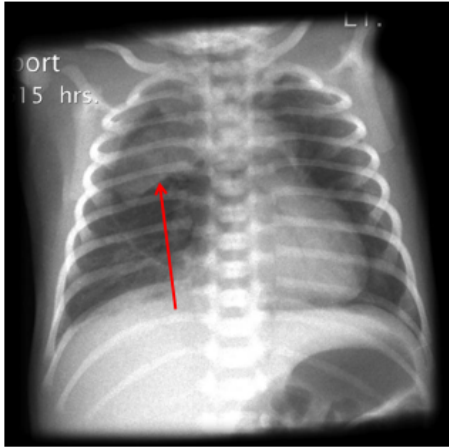
Thymic Sail Sign



6mo with prominent normal thymus.

(http://images.radiopaedia.org/images/2518656/dcc31d9116ec89a8f37d88db14342e_big_gallery.jpg)

Spinnaker Sail Sign



Neonate with pneumomediastinum

(http://images.radiopaedia.org/images/25257/f22d75d7d57e07e04969f2d0e0653c_big_gallery.jpg)

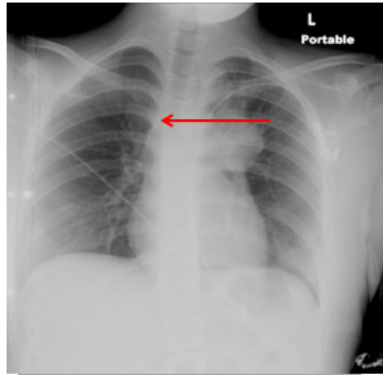
Developed by Colin Sit and Dr. Melissa Chan for PedsCases.com.

So here we have our first case (1) : a 6 month old boy comes in with cough, fever and increased work of breathing. A chest x-ray is ordered for this patient. You ascertain that this film is that of your patient's. You note that penetration and inspiration are adequate as the vertebral bodies are visible through the heart and that approximately 8-9 posterior ribs are visible. You conclude that the rotation is normal as the clavicles are equidistant from the spine. Now, you can begin interpreting the film using the top to bottom approach. You start at the top and note that there seems to be increased opacity at the right upper lobe of the lung. What do you think this represents? (2)

(3) This area of increased opacity represents the normal thymus in a pediatric patient. The thymus in a pediatric patient is highly variable in size and shape – it can shrink in size following illness or increase following chemotherapy. The thymus is normally not appreciable on film after the age of 8. In a pediatric patient, you may appreciate the thymic sail sign – this is a normal finding. The thymic sail sign is usually seen on the right mediastinum– the right thymus is seen as a triangle with a horizontal fissure as the base of the triangle, and the two sides of the triangle consisting of the trachea and a line paralleling the chest wall. In contrast, the Spinnaker sail sign is an abnormal finding indicative of a pneumomediastinum. (4) In the Spinnaker sail sign, the lobes of the thymus are laterally displaced from its position near the trachea.

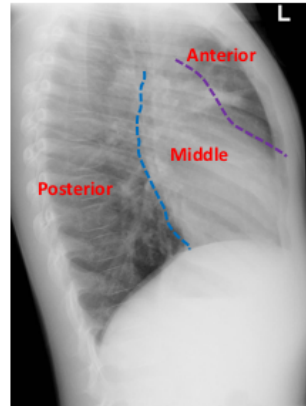
12YO WITH WEIGHT LOSS & 6 MONTHS

Visualization of the hilar vessels through the mass indicating an anterior mass



Young patient with lymphoma and bronchiolitis

Lateral view of mediastinal compartments



Child with asthma

(1) Our second case involves a 12 year old child that presents with weight loss over the last 6 months. The chest film is slightly underexposed as the vertebral bodies are not visible through the heart. 9-10 posterior ribs are visible, and the clavicles are equidistant from the spine. Let's take a stab at interpreting this chest x-ray. Are there any abnormalities present on the film and what is your diagnosis?

Firstly, we remember that because this patient is 12 years old, we do not expect to see the thymus on this chest film and indeed it is not visible. On the film, it seems as though there's an opacity at the right lower lobe of the lung and the hilar vessels also seem more prominent as well. What is the pathology behind this? Let's find out! (2)

(3) This section will go over the identification of masses in the mediastinum. First, we need to ascertain that the mass is indeed intra-mediastinal. Intra-mediastinal masses do not contain air bronchograms, and have obtuse margins with the lungs. In contrast, a lung lesion will create acute angles with the lung.

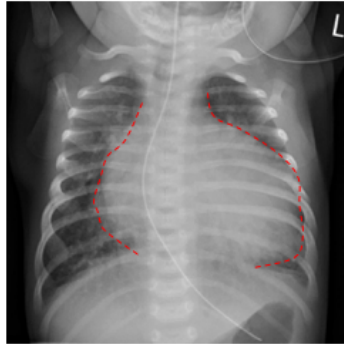
The mediastinum is divided into the anterior, middle and posterior sections. The middle section is comprised of the great vessels, trachea and esophagus. Certain clues are important to remember in order to localize a mediastinal mass to one of these three sections. Posterior deviation of the trachea, obliterated costophrenic angles, effacement of the ascending aorta, and visualization of the hilar vessels through the mass, such as in our patient, are indicative of an anterior mediastinal

mass. With the anterior mediastinum, a mnemonic called the terrible T's can be used to remember the differential diagnosis. The five T's consist of the thymus tumours, teratoma and germ cell tumours, thyroid tumours, thoracic aorta and terrible lymphoma. Further investigations done for our patient showed that they had lymphoma. (4) Lateral deviation of the trachea and widening of the paravertebral line are indicative of a middle mediastinal mass. Lastly, the splaying or destruction of the posterior ribs and extension of the mass above the superior clavicle are indicative of a posterior mediastinal mass. (5) In cases where the location of the mass is uncertain after the review of PA films, a lateral film will help to further delineate the location of the mass.

3 MONTH OLD WITH RESPIRATORY DISTRESS, COUGH, AND FAILURE TO THRIVE

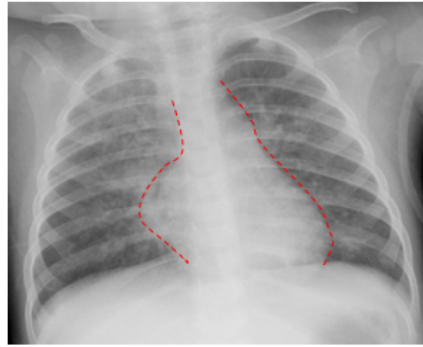
Heart

Cardiomegaly.



3mo with respiratory distress, cough, and failure to thrive.

Normal heart size.



4mo with respiratory syncytial virus infection..

peds
cases
Students

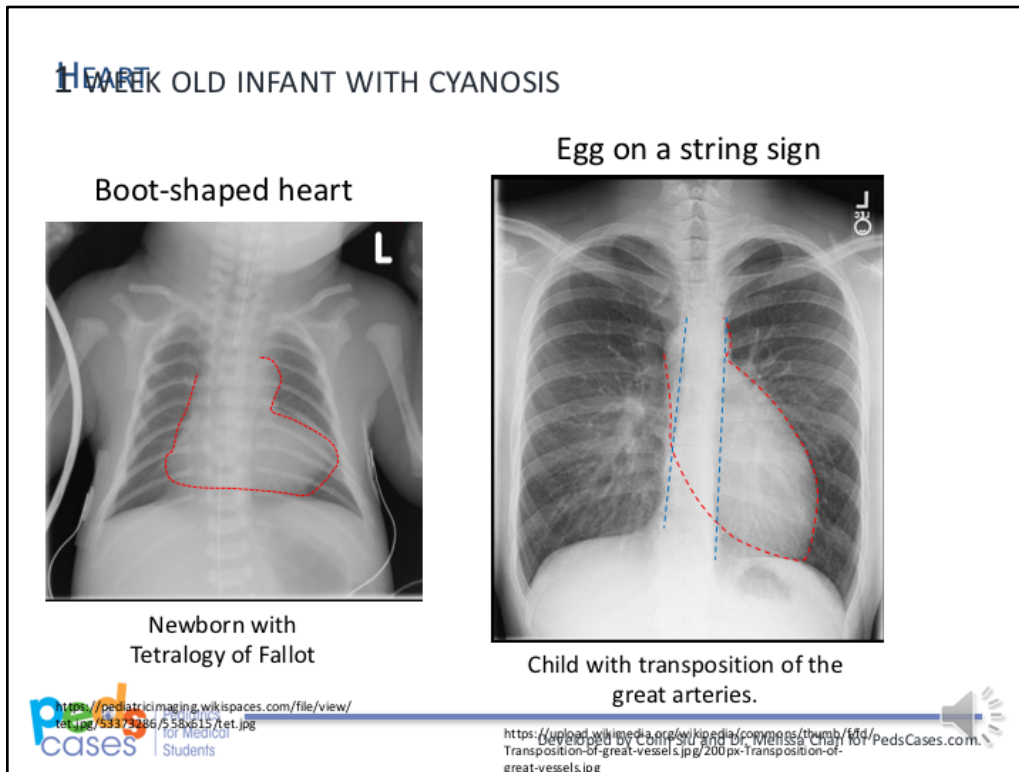
<https://images.radiopaedia.org/images/4230341/1c0c518851eb42e78d7>

https://pediatricimaging.wikispaces.com/file/view/PAchest_RS_SV.jpg/53792306/418x383/PAchest_RS_SV.jpg

Developed by Colin Siu and Dr. Melissa Chan for PedsCases.com.

(1) Our next patient is a 3 month old coming in with respiratory distress, cough and failure to thrive. On x-ray, the spinal vertebrae are visible, 9-10 posterior ribs are seen, and the clavicles are equally spaced from the spine. Though the thymus may be seen in a chest x-ray film for a 3 month old, it is not seen here. There are no opacities visible in the lung fields that point towards a mass. However, the heart looks a little bit abnormal, doesn't it? (2)

(3) In a pediatric patient, the heart's width may occupy up to 60% of the mediastinum. However, our patient's heart's width is definitely more than 60% of the diameter of the mediastinum, thus indicating cardiomegaly. Common pediatric causes of cardiomegaly include congenital heart disease, cardiomyopathy, congestive heart disease and pericardial effusions. An echo-cardiogram is often ordered as a follow-up diagnostic tool if cardiomegaly is appreciated.

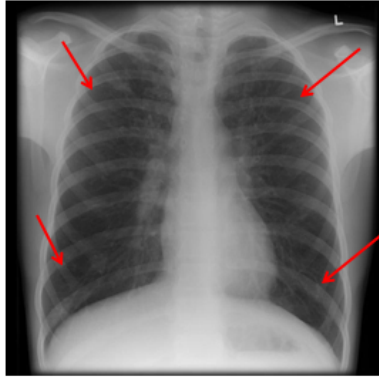


(1) The next patient is urgent: a week old infant with worsening cyanosis. A stat x-ray is ordered for him. You quickly ascertain that the chest is adequate by checking penetration, inspiration and rotation, all of which are normal in this film. The thymus is not present and there are no abnormal masses present in the film. The heart seems a little larger than 60% of the mediastinum's diameter but more importantly, you notice that the shape of the heart looks a little bit off. What is your working diagnosis at this point? (2)

(3) There are also some congenital cardiac conditions that are readily recognizable on chest films and that students should commit to memory. The first is that found in our patient: the boot-shaped heart, a sign synonymous with a diagnosis of tetralogy of Fallot. Tetralogy of Fallot refers to the four defining characteristics of the condition including a ventricular septal defect, pulmonary stenosis, overriding aorta, and right ventricular hypertrophy. Next, is the transposition of the great arteries, a condition that results in the egg on a string sign. (4) Transposition of the great arteries, is the most common cyanotic congenital condition found in newborns and is characterized by a pulmonary artery that arises from the left ventricle and an aorta that arises from the right ventricle. The enlarged heart appears as an egg that has been laid on its side while the string is the mediastinum that has been narrowed by thymic atrophy and lung hyperinflation.

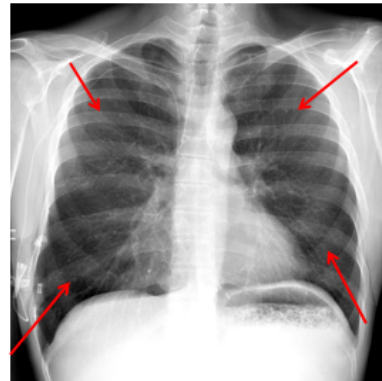
Lung Lucency

Diffuse bithoracic hyperlucent
lungs



15yo with cystic fibrosis.

Lung with normal lucency



Child with pectus excavatum

ped
cases
Pediatrics
for
Students

http://images.radiopaedia.org/images/25152/dac5127f97a7a555ed06e52431adda_big_gallery.jpg

<http://images.radiopaedia.org/images/131177/39700d01324b5eb2...>

Downloaded by Dr. Siu and Dr. Melissa Chan for PedsCases.com.

(1) You preceptor asks you to see the next patient and tells you that they have a diagnosed medical condition. However, she wants to see if you can figure out what their medical condition is by looking at their chest x-ray. Looking at the x-ray, you note that the film may be a little bit underpenetrated as the vertebral bodies are invisible. At the same time, the lung fields also look darker than normal and you wonder if there are any elements of over-penetration here. However, you move along and find that the inspiration and rotation are normal for this film but find that the lungs fields look taller than normal. You do not see a thymus, nor any masses and the heart seems to be of regular size and shape. You revisit your previous findings of a hyperlucent lung with enlarged lung fields. What do you think is the patient's medical condition?

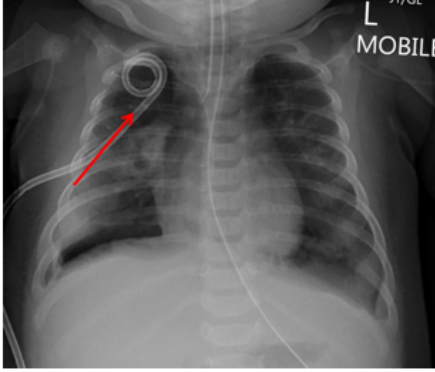
All examinations of the lungs on chest x-rays should start by firstly looking at areas of differing lucency. (2) The lungs should appear black on most films. Normal lungs should include thin white lung markings that extend almost to the periphery of the lung fields. Diffuse bithoracic increased translucency may be present in a well patient who has taken a bigger breath or with over-exposure of the film but may also be observed in patients with asthma, bronchiolitis, cystic fibrosis or an upper airway obstruction. In our patient's case, the diffuse bithoracic hyperlucency is a radiologic finding of their diagnosed cystic fibrosis. Another feature of cystic fibrosis that may be appreciated in our patient's film is that of an increase in bronchovascular markings in the perihilar region. Furthermore, bronchiectasis is also seen in chest films of patients

with cystic fibrosis. A hypolucent lung may result from atelectasis or obstruction of the bronchus. The presence of unequal translucency between the thoraces warrants serious investigation. Patient rotation is the most common reason for unequal translucency, in which case, a straight radiograph should be redone. With unequal translucencies, the side that is abnormal is the side with decreased pulmonary vascularity, the side which changes more on expiration, or the side with a small completely opaque hemithorax.

Pneumothorax

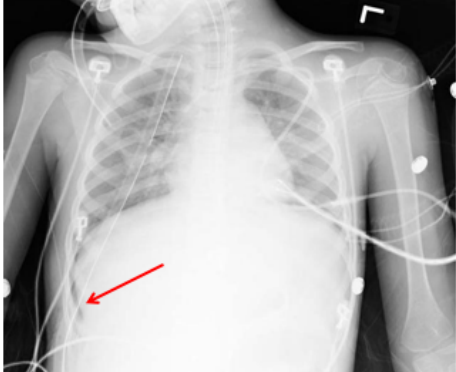
3 DAY OLD ON CPAP WITH WORSENING RESPIRATORY DISTRESS AND A DECREASE IN BP

Area of hyperlucency in the R. hemithorax



3 day old neonate with R. pneumothorax and chest drain.

Hyperlucent R. costophrenic angle – “Deep sulcus sign”



Child with R. pneumothorax

http://images.radiopaedia.org/images/5679405/2d8c6193854290585617a646deb0b3_big_gallery.jpg

http://images.radiopaedia.org/images/576961/cc40034c530b03249f37d7b87079c3_big_gallery.jpg

Developed by Colin Siu and Dr. Melissa Chan for PedsCases.com.

(1) The following patient is a 3 day old neonate that presents with worsening respiratory distress and normal blood pressure while on continuous positive airway pressure or CPAP. A chest film is ordered. The PA upright film is well-penetrated as the vertebrae are visible, 9-10 posterior ribs are visible and the clavicles are equidistant from the spinous process. The thymus is not visible in this film and no obvious masses are visible. The heart's width is less than 60% of the mediastinum and has a normal shape. Now, let's look at the lucency of the lungs. There seems to be an area of hyperlucency in the right upper lung and there also seems to be a tube of sorts inserting into approximately the same region. There also seems to be a smaller area of hyperlucency in the right lower lung near the R. hemidiaphragm. Aside from that, the chest x-ray looks pretty normal. What is your working diagnosis at this point? (2)

(3) Our 3 day old patient has a pneumothorax. A pneumothorax can occur as a result of trauma injury to the chest, as a complication of a long-standing lung condition, or as a spontaneous idiopathic entity. Tall and thin adolescent males are at a higher risk of developing spontaneous pneumothoraces. Pneumothoraces in neonates are often idiopathic in nature but are also associated with complications of ventilator therapy. As with our patient, a pneumothorax is visualized as an area of radiolucency between the chest wall and the lung; in other words, this area appears darker with no apparent lung markings. Our patient also has a chest tube that has been inserted in order to help drain the air. On a supine film, the air accumulates in the posterior

chest but may be present at the diaphragm in early stages, while on an upright film, such as with our case, the air accumulate in the lung apices. In addition, a neonatal pneumothorax may also present with a more sharply defined mediastinum and diaphragm when compared to the contralateral side, this is known as an etched heart border sign. The air in a pneumothorax may also elevate the thymus from the mediastinum, resulting in an angel wing appearance. (4) The presence of a hyperlucent or dark costophrenic angle in a pneumothorax is known as the deep sulcus sign.

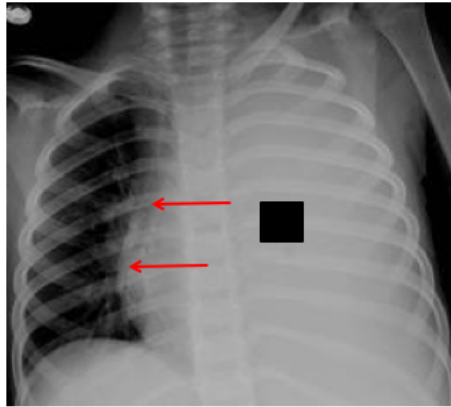
If a pneumothorax is suspected, a lateral decubitus film should be obtained with the side in question being the side that is facing upwards.

Pleural Effusion

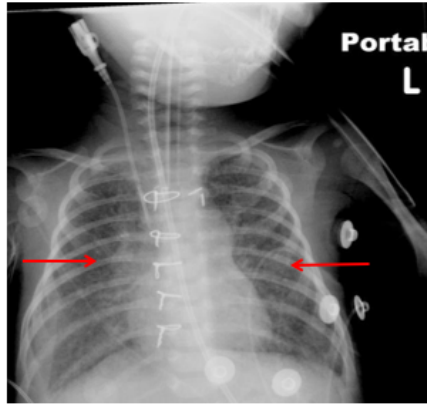
3 YO WITH CHEST PAIN AND TACHYPNEA

Opacification of L. hemithorax with
ass. contralateral mediastinal shift

Bilateral pleural effusions and
interstitial pulmonary edema



3yo with pleural effusion secondary to a
necrotizing pneumonia



11 week old with chylothorax

Peds
Cases

Pediatrics
https://pediatricimaging.wikispaces.com/file/view/Choi-002-PA_Nec.jpg/72933163/253x227/Choi-002-PA_Nec.jpg

<https://pediatricimaging.wikispaces.com/file/view/ser1001img01001.jpg/442842586/800x664/ser1001img01001.jpg>
Developed by Colin Siu and Dr. Melissa Chan for PedsCases.com.

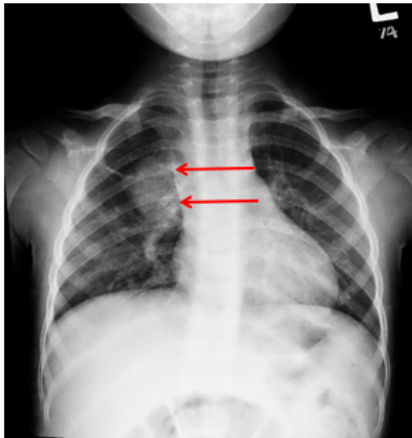
(1) Phew, it's been a long day! It's about time for lunch in your clinic so feel free to chow down on some food while we go over the next patient's chest film. We're approximately at the halfway mark! While you grab a bite, let's look at our next patient. Our next patient is a 3 year old that comes in complaining of chest pain on inspiration as well as tachypnea, he has previously had a history of cough and fever for the last 10 days. Let's take a look at the x-ray! The vertebrae are visible through the heart, 9-10 ribs are visible and the clavicles are approximately equidistant from the spine. The thymus is not visualized and no obvious masses are present. It is hard to comment on the heart size and shape because of the hypolucency obscuring the left heart margin. Upon gross examination of the film, the most remarkable finding is the unilateral hypolucency present diffusely in the L lung. More so, the R lung field seems to be decreased and the heart seems to be shifted towards the right side. What is your working diagnosis? (2)

(3) Our patient here has a pleural effusion as a result of a complication of a previous pneumonia. As seen on our patient's film, a hemithorax on supine film that is diffusely hazy or has increased opacity may be indicative of a pleural effusion. Large pleural effusions may shift the mediastinum to the contralateral side. If a pleural effusion is suspected, an ultrasound of the chest should be carried out to determine whether the fluid is confined to one area or free-moving, the latter of which lends itself to percutaneous drainage. An ultrasound will also help determine the quantity and quality of the effusion. Effusions present in the pleural cavity may be an

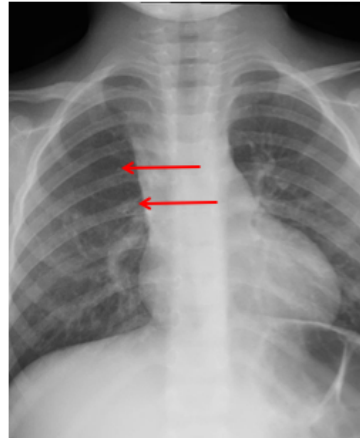
empyema, collections of pus, a hemothorax resulting from chest trauma, or an exudative effusion from a diseased nearby structure, which includes subdiaphragmatic abscesses, pericarditis, and pancreatitis. The only realistic way to differentiate these different types of effusions is to conduct a thoracentesis and pleural fluid analysis.

8yo boy presents with fever, cough and lethargy. PNEUMONIA

Chest film pre-treatment



Chest film post-treatment



http://images.radiopaedia.org/images/246993/0106e6ec478a9475654893142d7279_jumbo.jpg

<http://images.radiopaedia.org/images/247005/73fe78b05846ffb02ba706e6d59c0fbc.jpg>

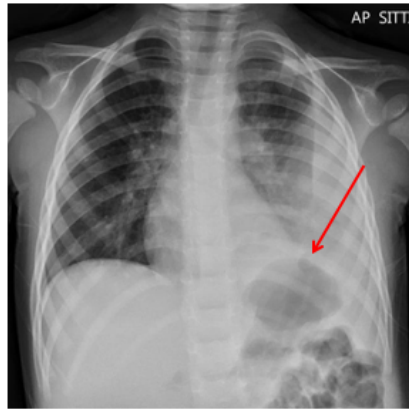
(1) Next, we have an 8 year old boy that presented with fever, cough and lethargy. You start off by checking that the film is for the right patient. Then ascertain that the film is of adequate quality by checking the penetration, inspiration, and rotation. All of these three components are fine with this film. You start analyzing the film with a top-down approach starting with the thymus which is not visualized, the mediastinum and the heart, all of which are normal. Now let's take a look at the lungs. The pulmonary vessels are clearly demarcated and taper gradually, but you notice an area of hypolucency in the right upper lung field. There are no associated signs of pneumothorax or appreciable pleural effusion. Now let's take a closer look at our area of hypolucency. The opacity is well-circumscribed with no central cavity. What is your working diagnosis here? (2)

(3) Pulmonary nodules are discrete areas of opacity within the lung. Of these, the round pneumonia is the most common type of solitary lesion in the pediatric population. Our patient does indeed have a round pneumonia but your differential for a pulmonary nodule may also include a bronchogenic cyst, a pleural fibroma or a fungal infection. The presence of an air bronchogram within an opacity lends itself to the diagnosis of a bacterial pneumonia. An air bronchogram is when a normally dark air-filled bronchi is made visible by the opacification of surrounding alveoli. Round pneumonia is most commonly present in those under 8, is located in the lower lobe, and is present without any other chest wall abnormalities. Pneumococcal infection is the culprit in the majority of round pneumonia cases. (4) The film on the right hand

side was taken after 10 days and shows resolution of the consolidation after empiric Amoxicillin treatment.

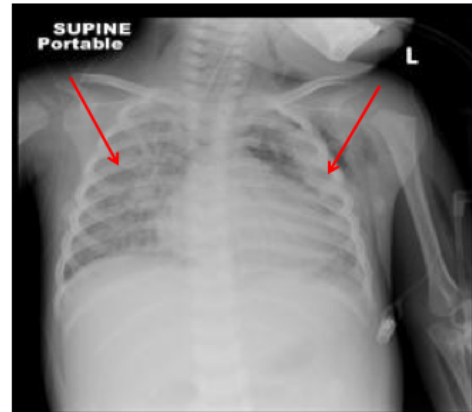
MORE PNEUMONIA

L. lung opacity with
intra-opacity cavity



Child with necrotic
pneumonia

Bilateral diffuse hypolucency



6yo with respiratory
syncytial virus pneumonia

http://images.radiopaedia.org/images/4369751/6bb84c4b85c1b7d3e8543b1b56e767_big_gallery.jpg

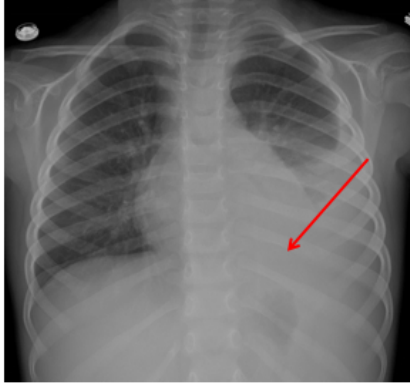
<http://images.radiopaedia.org/images/381738/22c5e601934e4b64379ee0762174e11914663.jpg> Dr. Melissa Chan for PedsCases.com.

The subsequent patient is a 5 year old patient again coming in with a fever and a cough. However, this x-ray looks a little bit different from our previous one. Let's walk through the steps again. This film is again well-penetrated, 8-9 posterior ribs are visualized and the clavicles are equidistant from the spinous process. The thymus is not visualized in this film and there are no obvious masses present. The heart seems to be of normal shape and size. There is no associated signs of pneumothorax or pleural effusion. (1) You do notice however that the left lower lobe of the lung seems to be more hypolucent than the right and there seems to be a bubble-like hyperlucency structure amidst the opacity in the left lower lung. What is your working diagnosis at this point?

Our patient has a necrotizing pneumonia, characterized by the presence of a cavity within an opacity. Let's quickly look at another case. Here we have a 6 year old similarly presenting with a fever and cough. (2) However, looking at their x-ray, we can see that there's bilateral diffuse opacity. Viral pneumonia, such as a RSV pneumonia, often present with a more ill-defined or ground glass pattern and are often bilateral. As you can see, pneumonia may present in many different shapes and forms.

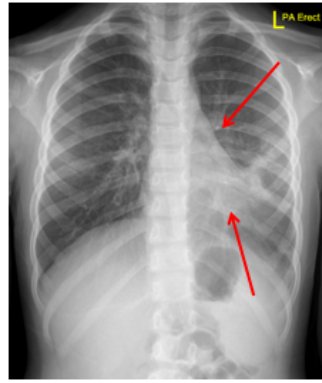
SILHOUETTE SIGN

L. hypolucency with loss of left
hemi-diaphragm



3yo with L. lower lobe necrotizing
pneumonia

L. hypolucency with loss of the
L. heart border



6yo with L. lingula
segmental pneumonia

<https://pediatricimaging.wikispaces.com/file/view/choi-002-PA.jpg/7292927/choi-002-PA.jpg>
PedsCases.com
for Medical
Students

http://images.radiopaedia.org/images/7998100/ff26c0a0db1550a7a3d68e2a64c86d_big_gallery.png
Developed by Colin Siu and Dr. Melissa Chan for PedsCases.com.

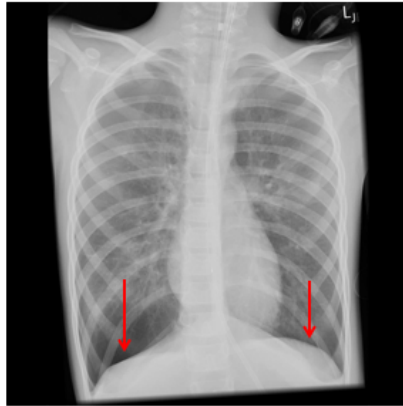
Now that we've gone over some cases of pneumonia. Let's work on findings way to localize the pneumonia on a chest film. (1) The Silhouette sign is very helpful in determining the location of the infiltrate. The Silhouette sign points to the loss of the silhouette of key structures normally seen on x-ray films. The loss of the right paratracheal stripe silhouette points to an infiltrate in the right upper lobe of the lung, the loss of the right heart border points to an infiltrate in the right middle lobe or medial right lower lobe, and the loss of the right hemidiaphragm points to an infiltrate in the right lower lobe. (2) The loss of the aortic knuckle correlates with an infiltrate in the left upper lung, and loss of the left heart border correlates with the lingula segments of the left upper lobe. Lastly, as visualized in this film, loss of the left hemi-diaphragm or descending aorta silhouette correlates with a left lower lobe infiltrate.

Now a quick test. Can you localize the infiltrate that is present on this chest x-ray?

This patient has a left lingula segmental pneumonia as indicated by the left hypolucency and loss of the left heart border.

Diaphragms

13YO WITH SHORTNESS OF BREATH AND INCREASED WOB
Hyperexpanded lungs with flattened diaphragms



13yo with pneumothorax
with background asthma

peds
cases

Pediatrics
for Medical
Students

http://images.radiopaedia.org/images/5/804262/8a909352e853e142ee54b7ce924a93_jumbo.jpg
Developed by Colin Siu and Dr. Melissa Chan for PedsCases.com.



(1) Hold on tight, we're approaching the home stretch! Our next patient is a 13 year old that comes in with shortness of breath and increased work of breathing. Let's take a quick look at his x-ray. The vertebrae are visible through the heart and the clavicles are equidistant from the spine. However, inspiration seems to be a bit abnormal as 11 to 12 ribs are visible on the film. Hold onto this thought, we'll revisit this in a bit. As expected, the thymus is not visualized in this 13 year old. There are no masses apparent in the mediastinum and the heart is of normal shape and size. In looking at the lucency of the film, it is a bit hard to appreciate in the photograph but there is an area of decreased lung markings in the right apical lung that was determined to be a small pneumothorax. There are no signs of a pleural effusion or pulmonary nodules. Let's go back to our earlier finding regarding the presence of 11-12 ribs on the film. Furthermore, you notice that both hemi-diaphragms seem a bit more flattened than normal. What medical condition can result in this presentation?
(2)

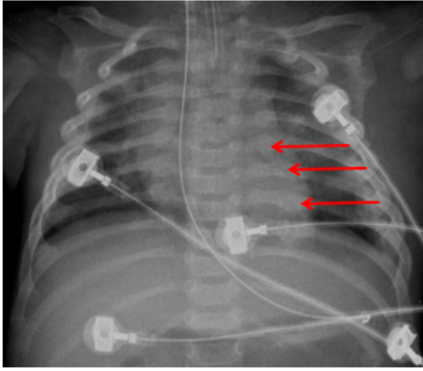
(3) A flattened diaphragm is most often due to an overinflated lung, as seen with our patient. Our patient actually has underlying chronic asthma that has resulted in hyperinflation of the lungs and flattening of the diaphragm. Another feature that may be present in x-ray films of asthmatic patients is that of peribronchial cuffing or thickening of the bronchial walls. You may be able to appreciate on our patient's film that the bronchial walls are more apparent than on a normal film.

Let's take a further look at other pathologies that may affect the diaphragm. When examining the diaphragm, first look to see if both sides are equal, though the right diaphragm may be slightly higher than the left due to the presence of the liver. The diaphragm is usually visible at the level of the 9th or 10th rib. Curving of the diaphragm may result from phrenic nerve paralysis, liver enlargement or an abdominal tumour. Loss of clarity in the area of the diaphragm is most likely due to pulmonary collapse or a consolidation obscuring the diaphragm. Also examine for the presence of free air underneath the diaphragm. A marked elevation of the diaphragm may be due to a loss of lung volume, paralysis of the phrenic nerve, replacement of diaphragmatic muscles with fibroelastic tissues, a congenital diaphragmatic hernia or subpulmonary effusion.

Ribs

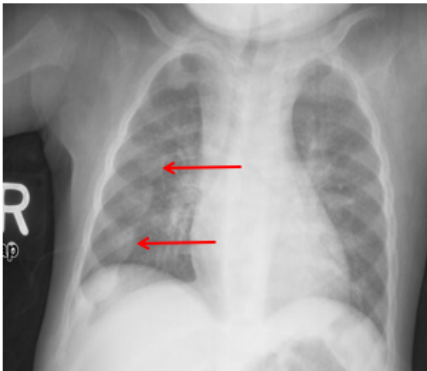
INFANT WITH ANTERIOR THORAX BRUISES

Posteromedial rib fractures.



Infant fell off couch, hit head and had a seizure – presentation suspicious of non-accidental injury

Expanded edges of the anterior ribs



5 week old presenting with cough and background rickets

http://images.radiopaedia.org/images/574370/0498d61406c2691e9642b87d1ba9f_jumbo.jpg
<http://images.radiopaedia.org/images/4339767/9044cd981c879b2e1e1c5011c01a1.jpg>

(1) Phew, that was a long day. Here comes your last patient of the day: an infant comes in to Emergency and the parent tells you that he fell off the couch, hit his head and had a seizure at home. You notice some bruises on his anterior thorax in your physical exam and you decide to order a chest x-ray. The vertebrae are clearly visible through the heart, 8-9 ribs are visible and the clavicles are equi-distant from the spine. Please note that this film has been darkened in order to enhance the pathology. The thymus is not visualized and no masses are seen. The heart is a normal size and shape. There are no areas of hypo- or hyperlucency and no signs of a pneumothorax, pleural effusion or pneumonia. The diaphragms do not seem to be flattened or elevated. Let's now take a closer look at the ribs. What abnormalities do you see and what is your working diagnosis? (2)

(3) When looking at the ribs, usually 10-12 ribs should be appreciated. The ribs are important indicators for possible child abuse, more correctly termed non-accidental injuries. Postero-medial rib fractures, which are present in our patient's film, especially have high specificity for non-accidental injuries in children under 3. Other less common causes of rib fractures include trauma during birth delivery or in a motor vehicle accident or trauma in infants with fragile bones. Fractures of the scapula, spinous process and sternum are also specific for non-accidental injuries but less common. If these signs are seen on a chest film, look for other signs that are highly correlated with non-accidental injuries including multiple fractures elsewhere in the body, fractures in different stages of healing, delay in seeking medical

treatment, and other coexisting injuries. Though hospital protocols may vary in regards to reporting non-accidental injuries, it is quintessential that any suspicions be reported to child protection services or an equivalent agency at your healthcare centre.

Other rib anomalies include bifid ribs that are often picked up in the pediatric population and present as an asymptomatic hard mass. (4) Additionally, look for expanded anterior edges in the ribs – a marker of rickets. Destructive bone lesions may point to the presence of infections or malignancies.

Quick review

- **Thymus:**
 - Is normal in a child but look out for Spinnaker sign.
- **Mediastinum:**
 - Remember that the mediastinum can be separated into the anterior, middle and posterior compartments.
 - The differential diagnosis for an anterior mediastinal mass is the terrible T's.
- **Heart**



Normal heart should be less than 60% of

Developed by John Stewart, MD, Melissa Chan for PedsCases.com.



Let's end with a quick review of the systems that were covered in this video. Firstly remember to check the adequacy of the film by checking inspiration, penetration, and rotation. Then, approach the film using a top down format. The appearance of the thymus on a chest film is normal in patients up to eight years of age but the presence of the Spinnaker sign indicates a pneumomediastinum. Remember the mediastinum can be separated into the anterior, middle and posterior compartments; pathology associated with each compartment will appear differently on a chest film. To remember the differential diagnosis for an anterior mediastinal mass, remember the terrible T's. The normal heart should be less than 60% the width of the mediastinum. Tetralogy of Fallot is visualized as a boot-shaped heart while transposition of the great arteries is visualized as an egg on a string.

Quick review

- **Lungs**

- Examine the lucency of the lungs.
- A pneumothorax is visualized as an area of radiolucency between the chest wall and the lung. The presence of a hyperlucent costophrenic angle in a pneumothorax is known as the deep sulcus sign.
- A hemithorax on supine film that is diffusely hazy or has increased opacity may be indicative of a pleural effusion. Large pleural effusions may shift the mediastinum to the contralateral side.
- Round pneumonia is the most common type of solitary lesion in the pediatric population. The Silhouette sign can be helpful in determining the location of the infiltrate.

When examining the lungs, look for areas of differing lucency in the lung. A pneumothorax is seen as an area of radiolucency between the chest wall and the lung. The presence of the deep sulcus sign also points towards the diagnosis of a pneumothorax. Round pneumonia is the most common type of solitary lesion in the pediatric population and the Silhouette sign can be useful in determining the location of this lesion. A pleural effusion is often visualized as a hemithorax that is diffusely hazy or has increased opacity. Large pleural effusions may cause a contralateral mediastinal shift.

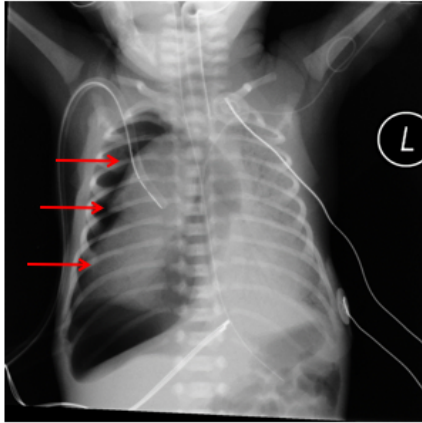
Quick review

- **Diaphragm**
 - Check that both hemidiaphragms are of equal elevation and assess for free air under the hemidiaphragms.
- **Ribs**
 - Look for any lesions in the bones and any deformities in the edges of the ribs.
 - Be aware of common signs of non-accidental injuries.

For the diaphragm, check that both hemidiaphragms are at the same level and look for free air under the hemidiaphragms. Lastly, look for any lesions or deformities in the ribs and be on the look out for common signs of non-accidental injuries.

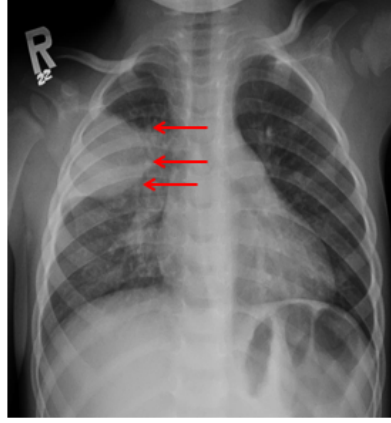
Self-test 1

R. pneumothorax with
contralateral mediastinal shift



Neonate with R. tension pneumothorax

Round pneumonia
in R. upper lobe



Unwell infant with a fever

peds
cases

Pediatrics
http://images.radiopaedia.org/images/13870902/fa9b0ced1397-5647912101fa444d1_jumbo.jpeg

<http://images.radiopaedia.org/images/454292/c32b79e12b235a-201705060951jumbo.jpg>
Developed by Melissa Chan for PedsCases.com.

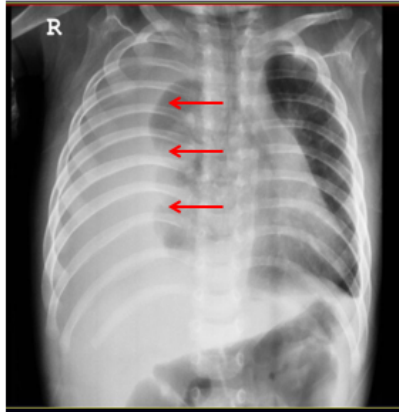
This marks the end of our video on an approach to interpreting pediatric chest x-rays. The following slides are a quick self-test for you in interpreting pediatric chest x-rays. A chest film will be presented, after which you will have approximately 10 seconds to think of your diagnosis. If you need more time, feel free to pause the video at this point. After 10 seconds, the pathology and diagnosis will be given. 6 chest films will be presented for this self-test followed by a list of online resources that you may want to consult for further information on pediatric chest x-rays. Thank you for watching this video.

(1) 1) Here we have a neonate with a R. tension pneumothorax as indicated by the presence of free air within the lung and a contralateral mediastinal shift towards the left.

(2) 2) This unwell infant with a fever has a chest film that shows a round pneumonia in the right upper lobe.

Self-test 2

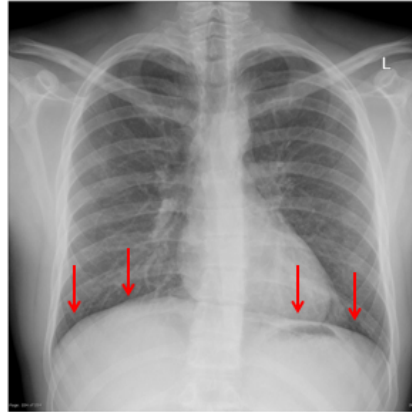
Pleural effusion in R. hemithorax and contralat. mediastinal shift



5yo boy with respiratory distress

 Pediatrics
http://images.radiopaedia.org/images/2261687/1189791a22cd130f7a02c486cd65f_jumbo.jpg

Patient with background asthma and acute pneumomediastinum



22yo male with sudden onset and L sided pleuritic chest pain

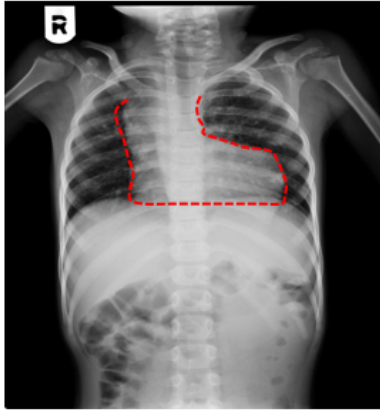
 Pediatrics
http://images.radiopaedia.org/images/208764c2b6438133013e332c299f1bbe9e_jumbo.jpg

(1) 1) The patient, a 5 year old boy with respiratory distress, has a pleural effusion in the R. hemithorax as shown by the diffuse opacity in the R. hemithorax. Furthermore, there is a contralateral mediastinal shift towards the left as well.

(2) 2) Here, we have a 22 year old male with sudden onset and left-sided pleuritic chest pain. Our patient has background asthma as indicated by the flattened diaphragms and hyperinflated lungs. Furthermore, our patient has an acute pneumomediastinum, a feature not commonly seen in the pediatric population.

Self-test 3

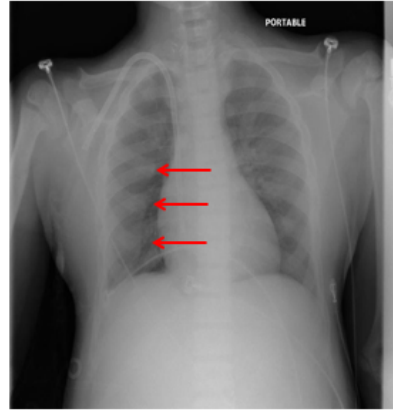
Boot-shaped heart with
a R. sided aortic arch



5yo boy with cough and
underlying Tetralogy of Fallot

https://images.radiopaedia.org/images/10856235/d4a689ffbd67d3cbff512c3c76166_jumbo.jpg

Expansion of the anterior rib ends
at the costophrenic junctions



Patient with rickets

https://images.radiopaedia.org/images/573740/b1b0a2a6b1445com.0278032f24ad5346_jumbo.jpg

- (1) 1) The patient, a 5 year old boy, shows a boot-shaped heart on his chest x-ray. The boot-shaped heart is pathognomonic for a diagnosis of Tetralogy of Fallot. Furthermore, there is an associated R. sided aortic arch visualized on the film.
- (2) 2) Lastly, we have a film that shows expansion of the anterior rib ends at the costophrenic junctions. This is pathognomonic for a diagnosis of rickets.

For more resources on plain radiographic films, visit:

- Radiopaedia.org
 - <http://radiopaedia.org/>
- UCLA Radiology Website
 - <https://pediatricimaging.wikispaces.com/>
- Medpix by the Uniformed Services University of the Health Sciences
 - http://rad.usuhs.edu/medpix/parent.php3?mode=peds_tf2



Developed by Colin Siu and Dr. Melissa Chan for PedsCases.com.

For more resources on plain radiographic films, please visit radiopedia.org, the UCLA radiology website or the Uniformed Services University of the Health Sciences.

References

- 1) Arthur R. Interpretation of the Paediatric Chest X-Ray. Current Paediatrics. 2003 November; 13 (6): 438-447.
- 2) Barber L, and Bynum F. Night Float Module Interpretation of Chest Radiographs [Internet]. [Los Angeles, (CA)]. c2012 [revised 2012; cited 2015 July 12]. Available from: <https://www.google.ca/url?sa=t&rct=j&q=&esrc=s&source=web&cd=1&cad=rja&uact=8&ved=0CB4QFjAA&url=http%3A%2F%2Fpediatrics.uchicago.edu%2Fchiefs%2FNight%2520Float%2520Curriculum%2Fdocuments%2FChestX-Rays2012.ppt&ei=VT6jVaeJG5b6oQTexoqABQ&usg=AFQjCNHUHB57e6rq53WPqE5Jq9Uqu5nW6Q&sig2=8YoBMv3d964EgxXncBDv9g&bvm=bv.97653015,d.cGU>
- 3) Bhalla S, Hazewinkel M, and Smithuis R. Mediastinum – Masses [Internet]. [St. Louis, (MO)]. c2007 [revised 2007 June 5; cited 2015 July 25]. Available from: <http://www.radiologyassistant.nl/en/p4620a193b679d/mediastinum-masses.html>
- 4) Brody A. Interpreting Pediatric Chest X-Rays [Internet]. Cincinnati, (OH). c2005 [revised 2005 September 8; cited 2015 July 12]. Available from: <http://www.cincinnatichildrens.org/WorkArea/DownloadAsset.aspx?id=79706>
- 5) Crapp S. Pediatric Chest Imaging- The Basics [Internet]. [Loxahatchee, (FL)]. c2012 [revised 2012 November 24; cited 2015 July 12]. Available from: <http://www.slideshare.net/scrappmd/pediatric-chest-imaging>

References

- 6) Department of Radiology. Education Page [Internet]. [Indianapolis, (IN)]. [cited 2015 July 12]. Available from:
<http://radtf.indyrad.iupui.edu/radt/QMachine.ASP?UID=0V20PGPD>
- 7) Emalee F, Perez-Rossello J, Levine M, and Hennrikus W. Evaluating Children With Fractures for Child Physical Abuse [Internet]. c2014 [cited 2015 July 26]. Available from: <http://pediatrics.aappublications.org/content/133/2/e477.full#cite-by>
- 8) Ferguson E, Krishnamurthy R, and Oldham S. Classic Imaging Signs of Congenital Cardiovascular Abnormalities [Internet]. Houston, TX. C2007 [cited 2015 July 25]. Available from: <http://pubs.rsna.org/doi/full/10.1148/rg.275065148>
- 9) Herring W. Recognizing a Technically Adequate Chest X-ray [Internet]. C2003 [cited 2015 July 25]. Available from:
<http://www.learningradiology.com/medstudents/recognizingseries/recogadequateflashpage.htm>
- 10) Mearadji M. Systemtic Interpretation of Paediatric Chest X-Rays [Internet]. Rotterdam, Netherlands. [cited 2015 July 12]. Available from:
<http://www.ifpia.com/voordrachten/respiratory/Systematic%20in%20interpretation%20of%20pediatric%20chest%20X-ray.pdf>