

ORIGINAL ARTICLE

Volume Perimetry: Measurement in Depth of Visual Field Loss

PremNandhini Satgunam*, Henry L. Apfelbaum†, and Eli Peli‡

ABSTRACT

Purpose. Volume scotomas are three-dimensional regions of space that are not visible to the observer. Volume perimetry maps volume scotomas. Volume scotomas predicted from combining monocular visual fields assume known fixation locus (mainly foveal). However, fixation loci are not always known, especially with central field loss (CFL). Here we demonstrate methods for measuring and calculating volume scotomas and discuss their practical implications.

Methods. Three patients (bitemporal hemianopia, binasal scotoma, and CFL) were evaluated. Slices through the volume scotomas were measured at three distances: at the plane of fixation, at a plane anterior to fixation (representing anterior volume perimetry), and at a plane posterior to fixation (representing posterior volume perimetry). For anterior volume perimetry, patients fixated on a screen 100 cm away through a beamsplitter that reflected the perimetric stimulus (at 50 cm). For posterior volume perimetry, patients fixated on a near target (50 cm), while perimetric stimuli were presented on a screen 150 cm beyond fixation. At the plane of fixation, monocular visual fields under binocular viewing conditions were measured using a computerized dichoptic perimeter.

Results. Posterior and anterior volume scotomas were documented in patients with bitemporal hemianopia and binasal scotomas, respectively. The CFL patient demonstrated both anterior and posterior volume scotomas. Scotoma magnitude was considered to determine its effect on visual function.

Conclusions. Direct measurement of volume scotomas can be performed. Anterior and posterior volume visual fields can vary substantially from conventional binocular perimetry measured at the fixation plane, revealing blind areas not otherwise identified. These volume scotomas are likely to impair functional vision such as driving (for bitemporal hemianopes) and near work with small hand tools (for binasal scotomas). Patients with CFL will have impaired functional vision for both distance and near tasks. Consideration of volume scotomas can help provide more effective vision rehabilitation and counseling.

(Optom Vis Sci 2012;89:E1265–E1275)

Key Words: visual field defects, vision impairment, hemianopia, functional vision, bitemporal, binasal

Visual field loss is usually measured monocularly for diagnostic or treatment follow-up purposes. For functional evaluation, the binocular visual field is more relevant. For example, in most jurisdictions in the United States, binocular visual field extent is specified in the vision requirements for driving licensure.¹ Binocular field loss is also considered in determining pedestrian mobility and safety.^{2,3} Normal visual field areas in one eye frequently compensate for corresponding non-seeing visual

field areas (scotomas) of the other, as is the case with the normal binocular field, wherein the physiological scotomas due to the optic nerve heads (ONHs) of each eye are compensated by the other.⁴ Visual field loss (monocular or binocular) is typically measured on a single surface; the surface of the perimeter. However, patients function in a three-dimensional world, and the functional impact of the visual field loss may need to be considered in that domain.

Volume scotomas are volumes in physical space from within which objects cast their images onto blind (or diminished sensitivity) areas of the retina (or into a blind area of one retina that has no binocular visual field overlap). Mapping of volume scotomas is referred to as volume perimetry. The term “volume scotoma” was coined by Arditi,⁴ who subsequently also introduced the terms “volume perimetry” and “volume visual field.”⁵ Evaluation of the

*BS(Opt), MS, PhD

†BA

‡MSc, OD, FAAO

Schepens Eye Research Institute and Massachusetts Eye and Ear, and Department of Ophthalmology, Harvard Medical School, Boston, Massachusetts.

Supplemental digital contents are available for this article. Direct URL citations appear in the printed text and are provided in the HTML and PDF versions of this article on the journal's Web site (www.optvissci.com).

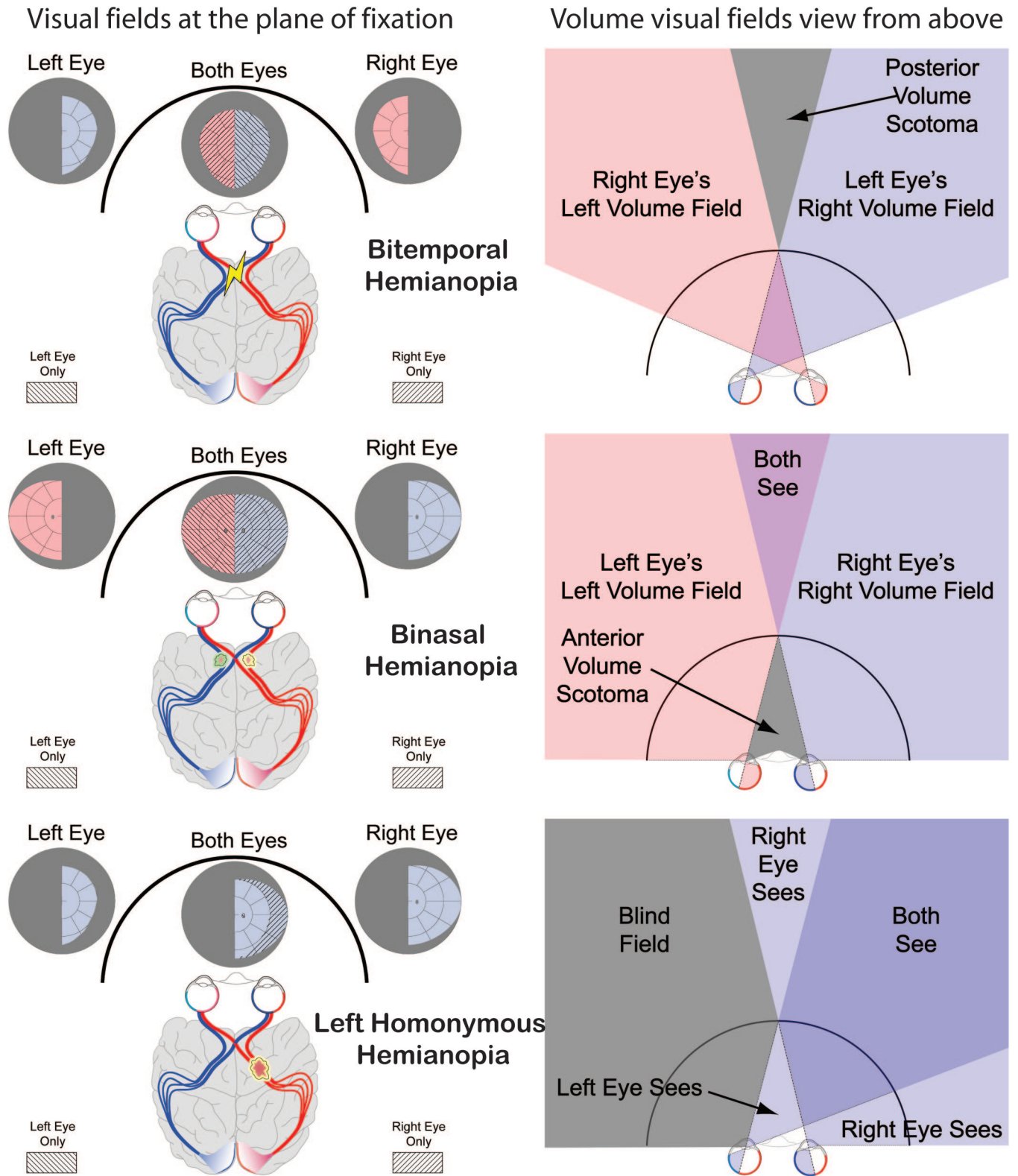


FIGURE 1.

Conventional visual fields for three different hemianopic conditions (bitemporal, binasal, and homonymous) are shown in the left column and the corresponding views from above illustrating the volume visual fields are shown in the right column. The arc represents the bowl of the perimeter. Hatching legends apply only to the binocular fields. The volume visual field shown for bitemporal hemianopia is similar to Fig. 6 in the article by Arditi.⁵ A color version of this figure is available online at www.optvissci.com.

impact of volume scotomas on patients' visual function, therefore, requires computing or mapping the volume field. Importantly, absence of a binocular scotoma at the plane of fixation (or the perimeter surface) does not exclude the presence of a volume scotoma at a different distance (refer to examples in Fig. 1). Conversely, presence of a binocular scotoma at the fixation surface (or plane) does not mandate binocular scotomas for every other depth plane, as will be shown later in the text. Theoretical computation of volume scotomas from the two monocular perimetry plots is possible,⁵ at least in cases where foveal fixation is present in both eyes. However, constructing the binocular visual field (volume or even standard) from two monocular visual fields may not be simple in situations such as central field loss (CFL), as occurs in age-related macular degeneration (AMD), particularly when the two monocular preferred retinal loci (PRLs) are not in corresponding retinal areas.^{6,7}

Functional vision can be affected by the presence of volume scotomas even if standard binocular perimetry reveals no scotoma. An example of this is shown in an illustration of a driving scene, as it might appear to a bitemporal hemianopic driver fixating straight ahead (Fig. 2A). The standard measurement of binocular visual fields at the plane of fixation for bitemporal hemianopes would only show the peripheral field loss of the temporal crescents. With a residual binocular field of about 120°, such patients would qualify for driving in most jurisdictions. However, when these patients fixate at a near target, such as the speedometer or GPS in the illustration (Fig. 2B), or a windshield-level Head-up display, such as an augmented vision system,^{8,9} a central wedge of the visual field is eliminated,¹⁰ as diagrammed in Fig. 1. The impact of this posterior volume scotoma on road visibility may be substantial, although intermittent (refer to RESULTS section). Note that the driver may not even notice that a large section of the road view has become invisible (Fig. 2B), especially because that view is in the peripheral volume field, outside the instantaneous focus of attention.

In cases of anterior volume scotomas, as would be the case with binasal hemianopia, close work and object manipulation may be affected. For example, patients may find threading a needle difficult, as the thread along with the gripping fingers may disappear into the anterior volume scotoma when fixating on the needle, or the tip of a screwdriver may be invisible when fixating on a screw head. Kirkham described difficulties such as these, due to the posterior volume scotoma in a patient with bitemporal hemianopia.¹⁰

The magnitude and location of the volume scotomas vary with the instantaneous fixation distance or the convergence of the eyes. A complete volume perimetry for distances ranging from very close (e.g., 20 cm) to very far (e.g., ≥ 600 cm) may not be practical. However, slices through the visual fields measured at two or more depth planes may be sufficient to provide the required information about the nature and the magnitude of the volume scotoma in a given viewing (fixation/convergence) condition. In heteronymous hemianopia, such volume scotomas expand behind fixation (posterior volume scotoma) in bitemporal hemianopia or in front of fixation (anterior volume scotoma) in binasal hemianopia. In cases of complete homonymous hemianopia, where half the binocular visual field is not visible at the fixation plane, the volume scotoma posterior to the fixation plane decreases by half the convergence angle (Fig. 1), as that volume will be visible to one eye (contralateral to the field defect). Similarly, the volume scotoma anterior to the fixation decreases by half the convergence angle, as it is seen by the eye ipsilateral to the field loss.

With the more common condition of bilateral central scotomas, a zone of volume scotoma may be present, depending on the size and locations of the central scotomas and the convergence angle. A central scotoma that encompasses the fovea can be conceptually split into nasal and temporal portions. Patients with bilateral central scotomas use a PRL for fixation with each eye when measured monocularly. Under binocular conditions, however, a binocular PRL will be used (which may or may not be one of the two monocular PRLs, if they are not on corresponding retinal loci). When




FIGURE 2.

Simulated view of a road for a driver with bitemporal hemianopia. (A) When fixating far down the road, the view is not affected (assuming orthophoria). (B) When the driver fixates on the high-mounted GPS unit here, the posterior volume scotoma eliminates much of the relevant road view. The images were created using a three-dimensional model of the scene, cutting out a wedge in (B) and joining the edges. Blur was added to indicate defocus away from fixation/accommodation distance. In both cases, the driver generally does not notice the blur. A color version of this figure is available online at www.optvissci.com.

the PRLs are below the fovea (as frequently found in Stargardt disease¹¹), the central scotomas span the vertical meridian of fixation. Such central scotomas combine the effects of “partial” bitemporal hemianopia and “partial” binasal hemianopia, and therefore should result, respectively, in both posterior and anterior volume scotomas. However, because of the partial extent of these “hemianopic” field losses, the interaction of the shape and magnitude of the volume scotoma with the fixation distance is more complex than that found with the complete heteronymous hemianopias. In addition, these monocular central scotomas may each interact with the physiological scotoma of the other eye.^{5,12}

In Fig. 3, for the sake of simplicity and illustration, the central scotomas in each eye are assumed to be equal in diameter and centered on the fovea in each eye; thus, the binocular scotoma at fixation is equal to the monocular scotoma size. Under this condition, when the two eyes fixate at a distant target (with an inferior PRL), the visual axes are essentially parallel, extending to infinity. By definition, there is no posterior volume scotoma because fixa-

tion is at infinity (Fig. 3A). However, a measurable anterior volume scotoma is formed. This anterior volume scotoma shrinks as it gets closer to the eye and then disappears at an angle that depends on the binocular scotoma size (refer to Appendix Eq. A1, available online at <http://links.lww.com/OPX/A101>). For any fixation distance for which the convergence angle is smaller than the angular size of the binocular scotoma, a posterior volume scotoma extends to infinity. When the eyes fixate with a convergence angle equal to the angular size of the scotoma, a measurable anterior volume scotoma exists, but the posterior volume scotoma becomes a “tunnel” scotoma with a fixed width equal to the patient’s interpupillary distance (IPD) extending to infinity (Fig. 3B). The angular extent of such a tunnel scotoma at the eyes thus shrinks rapidly with distance. For convergence angles greater than the angular scotoma size, a confined zone of volume scotoma exists with measurable but limited angular extent for both anterior and posterior volume scotomas (Fig. 3C). The extent of this volume scotoma (angular width, size, and boundary distances) can be calculated

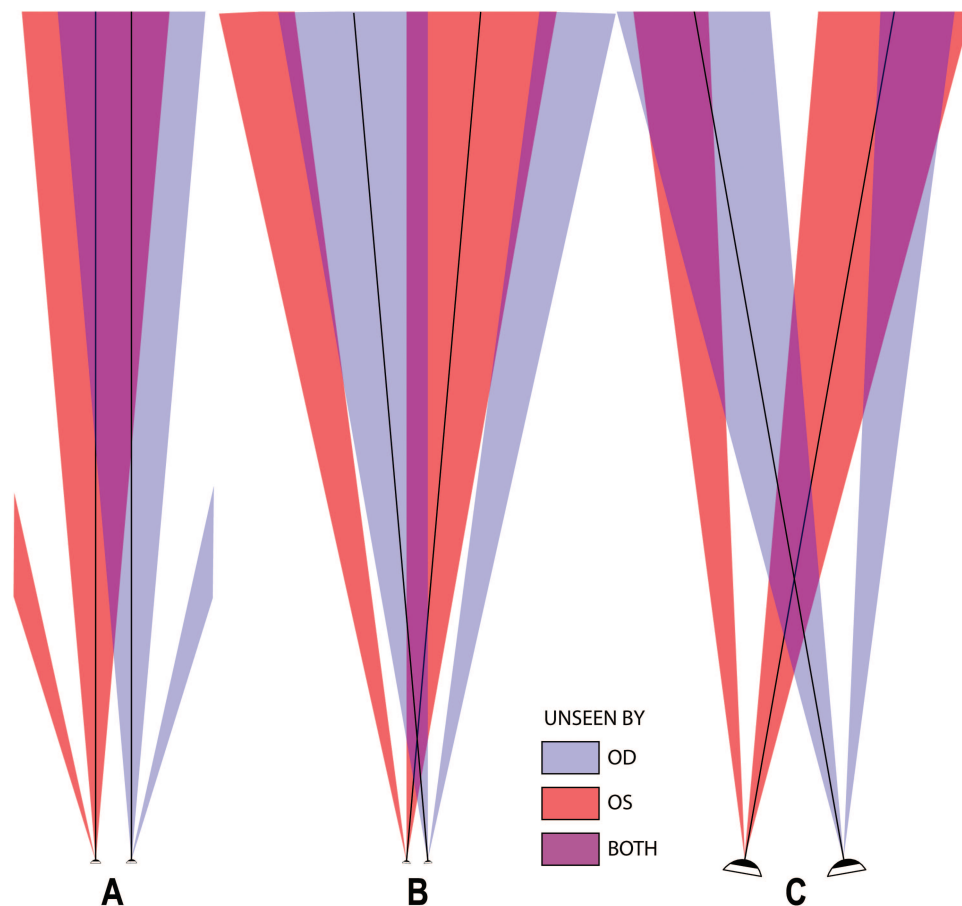


FIGURE 3.

Illustration of volume scotomas due to binocular central scotomas under different fixation conditions (assuming equal scotomas centered on the fovea in each eye and inferior PRL). The thick line within the projected scotomas represents the direction of the visual axis. (A) When the eyes fixate at infinity, an anterior volume scotoma of constant angular extent equal to the angular size of the scotomas extends to infinity from the point at which the monocular scotomas begin to overlap (refer to Appendix Eq. A1, available at <http://links.lww.com/OPX/A101>). (B) When the convergence angle to fixation is equal to the angular scotoma size, an anterior volume scotoma is present (starting at the distance given in Appendix Eq. A2, available at <http://links.lww.com/OPX/A101>) along with a posterior tunnel scotoma (of constant linear size equal to the IPD) that extends to infinity. (C) When the convergence angle is greater than the scotoma size, a finite kite-shaped zone of volume scotoma with anterior (Eq. A2) and posterior (Eq. A3, available at <http://links.lww.com/OPX/A101>) limits is formed. The projected scotomas due to the ONH physiological blind spots are shown. Equations A4 to A7 delimit these interactions. The scale is varied to include the interactions of the ONH and central scotomas. Scaling for 10° central scotomas and an IPD of 6.6 cm is used in all cases. The scale differences may be appreciated by comparing the eye size and IPDs between the various images. A color version of this figure is available online at www.optvissci.com.

using the central scotoma size, convergence angle, and IPD for the simplified case assumed here (refer to Appendix Eqs. A2 and A3, available online at <http://links.lww.com/OPX/A101>). Slices through the volume scotomas can measure the anterior and posterior volume scotomas corresponding to a given fixation distance.

The posterior volume scotoma, therefore, is fairly small at the convergence distance where the angle of convergence is equal to the angle of the scotoma, and shrinks further at closer convergence distances. A bilateral central scotoma of 10° diameter will become a tunnel volume scotoma at a convergence distance of 38 cm and will shrink even further for closer convergence. At the closer convergence distances, however, the physiological scotomas formed by the ONHs will interact with the central scotomas and will result in additional volume scotomas lateral and farther than the central volume scotoma (Fig. 3C). Thus, with decreasing convergence distance, the volume scotoma due to overlapping of the bilateral CFL is traded for the scotomas due to the overlapping of the CFL and the ONHs.

Under the more general case when the PRLs are lateral to the bilateral central scotomas, usually to the left of the scotoma, as commonly seen in AMD,¹³ the situation is more complicated. If the lateral PRLs are at corresponding retinal locations in both eyes, the field loss resembles that of a “partial” homonymous hemianopia. Note that posterior and anterior to fixation, such scotomas will shrink in the same way illustrated for homonymous hemianopia in Fig. 1. That reduction may substantially reduce the volume scotoma when the patient converges to fixate on a closer object. However, the unequal size of the scotomas needs to be considered. If the PRLs are not in corresponding loci, the locus of the binocular PRL needs to be determined under dichoptic binocular viewing conditions to compute the volume scotoma. Alternatively, volume scotomas could be measured directly. Besides hemianopic and central scotomas, visual field loss resulting from other eye diseases, such as glaucoma (e.g., nasal step defects), and optic neuropathies (e.g., altitudinal defects) could also result in volume scotomas, depending on the configuration of the monocular scotomas. All these may be quite difficult to compute, especially without knowing the monocular visual fields under binocular viewing conditions, but can be relatively easily measured (at least slices through the posterior scotoma can be made with no special equipment, as explained in METHODS). Arditi et al. have described a computer program that computes and displays the geometric relationships in volume visual fields, given gaze direction of each eye and shape and retinal locations of any scotomas.^{14,15} Although the program was developed to model astronaut’s vision in a crew station, including under various temporary blinding conditions, the calculations could nonetheless be applied to patient populations of the type we now examine. Here again, the program can accurately compute the volume visual fields if the monocular fields are representative of binocular viewing conditions.

Although the concept of volume scotoma and computing volume perimetry has been proposed,⁵ to the best of our knowledge, direct volume perimetry measurements have never been demonstrated. The program computing the volume scotoma could illustrate the locations and objects in space that will be invisible, but a striking illustration of the appearance of the space under these conditions, such as Fig. 2, had not been generated. And although the possibility of computing volume scotomas was identified, little

consideration was given to the magnitude and impact of these scotomas for different visual impairments and with varying fixation distances. Here we illustrate techniques to measure slices through the volume scotomas anteriorly and posteriorly to fixation, for patients with bitemporal hemianopia, binasal visual field loss, and CFL. We show how the magnitude of the volume scotoma may be calculated or estimated, at least in simple cases, and we draw conclusions from these calculated magnitudes on the likely functional impact of various visual field losses across space.

METHODS

Three patients participated in this study. They signed an informed consent approved by the institutional review board of Schepens Eye Research Institute.

Patient 1 (29 years/male) had bitemporal hemianopia resulting from traumatic chiasmal syndrome due to closed-head injury. Visual acuity measured 20/20 (OD), 20/15 (OS), and 20/15 (OU); IPD = 6.8 cm.

Patient 2 (36 years/male) had North Carolina macular dystrophy and was born with asymmetric central scotomas that resulted in binasal paracentral scotomas when fixating with his customary binocular PRL (non-corresponding monocular PRLs). Visual acuity was 20/80 (OD, OS) and 20/60 (OU); IPD = 6.3 cm.

Patient 3 (70 years/female) had Stargardt disease and a superior binocular central scotoma when fixating with her customary binocular PRL. Visual acuity was 20/100 (OD, OS) and 20/80 (OU); IPD = 6.6 cm.

Volume Perimetry

Measuring volume perimetry requires using at least two planes at the same time: one for fixation (the fixation plane), as used for standard perimetry, and the other for measuring slices through the volume field (the measurement planes) anterior and posterior to the fixation plane. If the measurement plane is anterior to the fixation plane, it is called anterior volume perimetry. If the measurement plane is posterior to the fixation plane, it is called posterior volume perimetry. Our methods for posterior and anterior volume perimetry are described below.

Posterior Volume Perimetry

A posterior volume slice can be measured by having the patient fixate on a fixation target suspended in space on a thin pole or a wire while projecting perimetry targets on a screen (measurement plane) mounted beyond the fixation target. The distances to the fixation target and the measurement plane can be easily varied in this case.

In the data reported here, patients were asked to fixate on a bright round 2° fixation target attached to a thin post that was mounted 50 cm from the patient’s eyes (Fig. 4A). A computerized rear projection perimeter was used to present binocular targets (targets visible to both eyes) on a measurement plane that can be set at variable distances from the patient (200 cm in this study). The computerized perimeter¹⁶ automatically provided a calibrated perimeter grid output for the viewing distances used. If another perimeter such as tangent screen is used, the mapped field needs to be rescaled for the appropriate measurement distance. The fixation

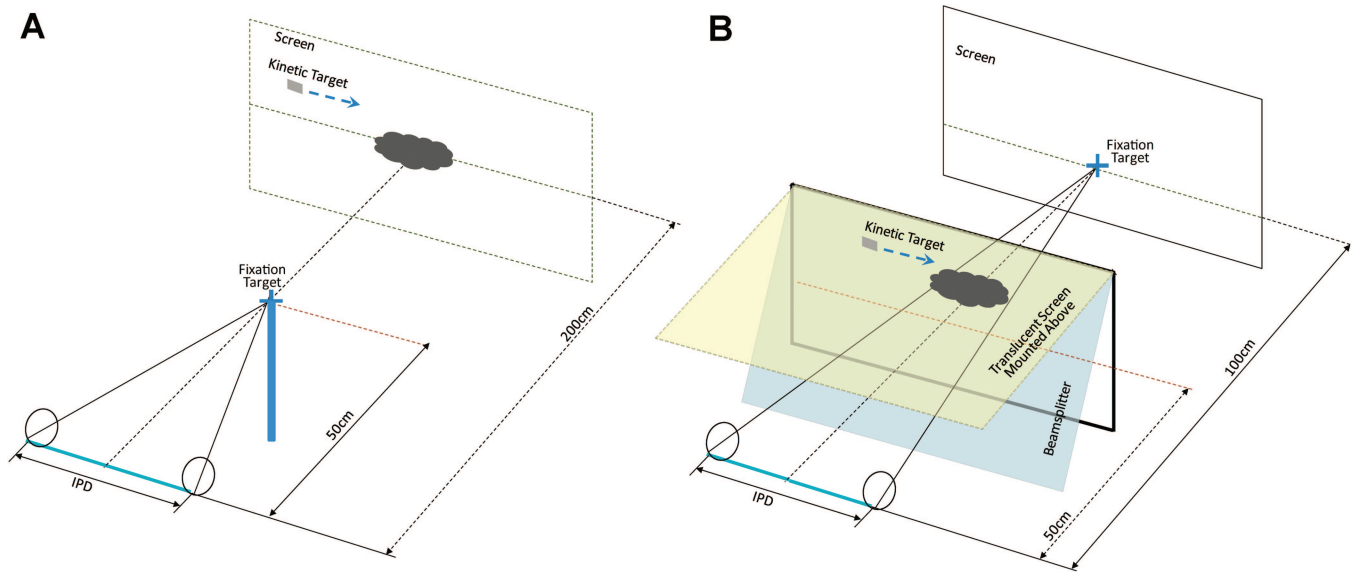


FIGURE 4.

Experimental setup for measuring a slice through (A) a posterior volume scotoma and (B) an anterior volume scotoma. A color version of this figure is available online at www.optvissci.com.

post and target were too small to interfere with the mapping of the posterior volume scotoma. The patient's mid-sagittal plane and the fixation target were aligned to the center of the measurement plane. A calibration grid was projected on the posterior measurement plane to check for alignment. Owing to physiological diplopia, the near fixation or the farther grid center would appear double, depending on fixation. Hence, the experimenter aligned the fixation target laterally to appear equidistant from the calibration grid center on the right and left by alternately closing one eye. Kinetic perimetry white targets (17 mm, 0.5°) controlled by the experimenter's mouse, moving from unseen to seen areas were presented over a black background using the dichoptic perimeter software. Patient's responses were automatically registered when they pressed a hand-held button to indicate target detection.

Anterior Volume Perimetry

To measure a slice through the anterior visual field, we had the patient fixate through a large beamsplitter onto a fixation target at 100 cm while reflecting the perimetry measurement plane with the same beamsplitter (Fig. 4B). A transparent plate mounted above the beamsplitter was used as the measurement plane. A printed paper perimetry chart (produced and calibrated automatically for the viewing distance of 50 cm by the computerized perimetry system) was mounted on the transparent plate. The center of the grid on the chart was aligned with the distant fixation target (2.8° white cross on a black background) using the same approach described earlier in the text. Although the fixation distance can be easily varied in this method, the measurement plane distance was fixed at 50 cm in our setup. One could build a similar system with adjustable measurement plane distance within a reasonable range of distances, if so desired.

To measure a slice through the anterior volume scotoma, the examiner moved a laser pointer on the paper grid, performing kinetic perimetry. When the patient pressed a buzzer button on target detection, the position of the laser spot was recorded on the

paper by the examiner. The laser pointer aperture was masked with black tape to limit the size and brightness of the laser beam target to avoid extraneous reflections at the beamsplitter. The size of the laser spot seen through the perimeter chart was 3 mm for patient 2 and 1 mm for patients 1 and 3 (0.3° and 0.1° , respectively).

Dichoptic Perimetry

Dichoptic perimetry involved presenting a binocular fixation target (2.4° white cross at 100 cm on a gray background) while plotting monocular visual fields with kinetic perimetry targets (white, 0.6° to 1°). This was done using a stereoscopic projection system that can present stimuli separately to each eye or to both eyes. More details about this system developed in our lab can be found elsewhere.¹⁶ The dichoptic perimetry enables us to measure each eye's position under binocular fixation. This is especially important when the relative alignment of each eye with respect to the other is not obvious, as is the case with bilateral central scotomas (patients 2 and 3). Dichoptic perimetry was performed in this study only at the 100 cm fixation plane and not in volume perimetry, although it could be easily used in measuring the posterior volume scotoma with our system and, with some hardware modification, the anterior volume scotoma as well. Eye movements were not monitored when mapping the visual fields. Patients were repeatedly instructed to maintain fixation, and targets were occasionally presented in the blind fields, to ensure that fixation was maintained.

Predicted Field Diagrams

We measured dichoptic fields at 100 cm fixation for each patient to produce diagrams predicting anterior and posterior volume scotoma slices (Fig. 5A to 7A). The diagrams show slices at 50, 100, and 200 cm from the eyes. For the anterior volume prediction, sight lines (visual axis through the nodal point of the eye extending through the volume visual fields) were drawn from the

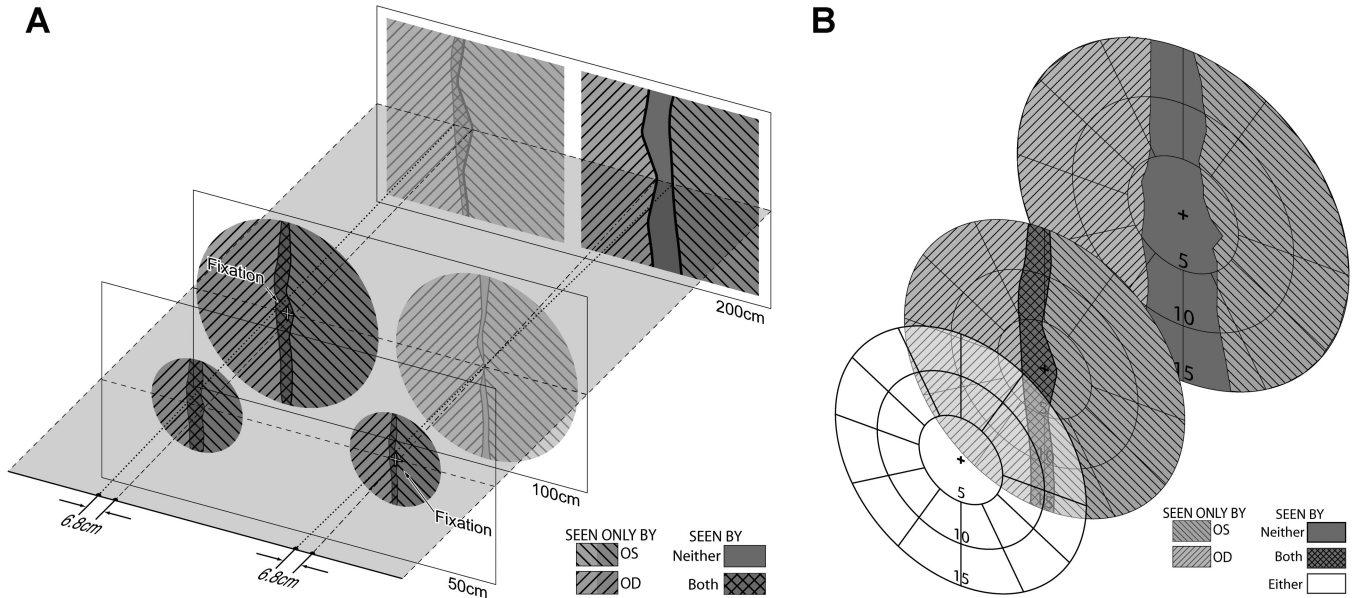


FIGURE 5.

(A) Expected/calculated and (B) actually measured slices through the volume visual fields (at distances of 50, 100, and 200 cm) for patient 1 (bitemporal hemianopia). Two different fixation distances were used to map the anterior (left) and posterior (right) volume scotomas, respectively, as shown in (A). The visual fields that were not measured at the given fixation distances are shown in lower contrast in (A). The circular boundaries in (A) represent the liquid-crystal shutter goggles' restriction of the dichoptic perimeter.

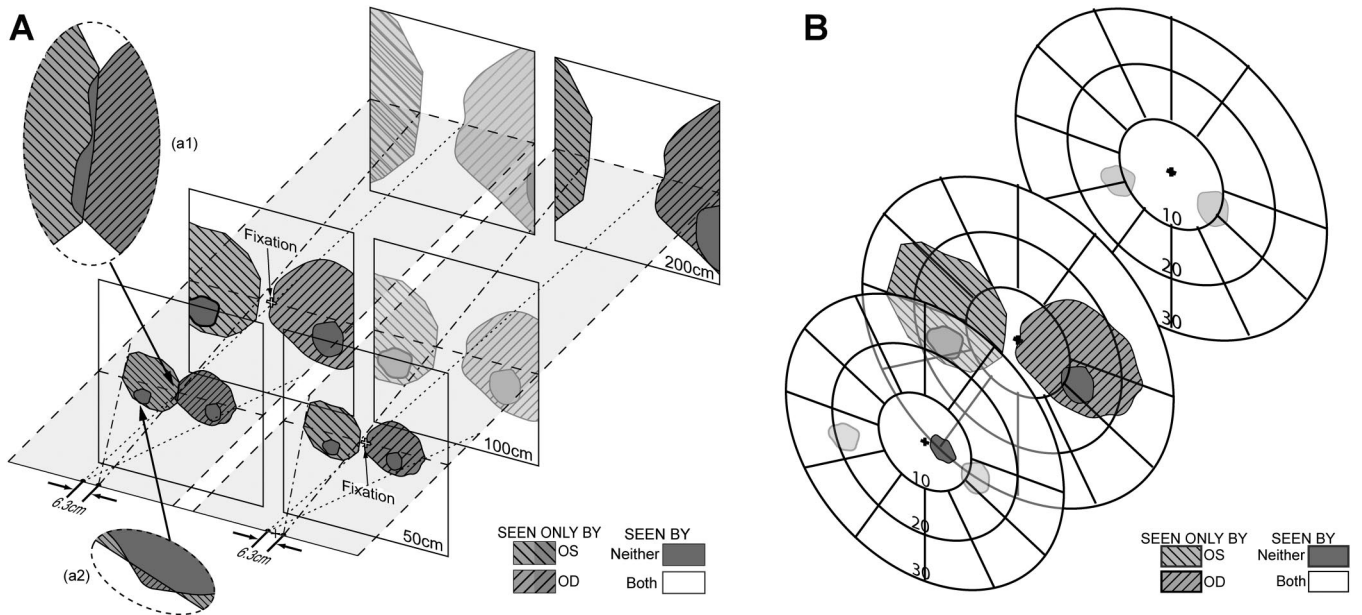


FIGURE 6.

(A) expected/calculated and (B) measured slices through the volume visual fields for patient 2 (partial binasal scotomas). Inset (a1) details the predicted anterior volume scotoma. Inset (a2) shows how the area within the OS physiological blind spot is no longer completely overlapping the OD scotoma and is thus seen by OD. There is no measured central binocular scotoma seen in the posterior plane in (B). The physiological blind spots shown faded in (B) based on the projections in (A) would remain, but were not mapped.

diagrammed eyes to features in the 100 cm fixation results. The scotomas at 100 cm were reduced by a factor of 2 and OS and OD scotomas were separately shifted on the 50 cm plane slice so that the sight lines intersected the corresponding features. In all cases, we used the crossings of the scotoma edges at the horizontal meridian as the features to align. This operation is a graphical computation similar to the computations produced by Arditi et al.^{14,15}

To predict the posterior volume scotomas at 200 cm with 50 cm fixation, we first reduced the size of the 100 cm fixation results by half and placed that diagram on a 50 cm plane slice. Sight lines were drawn from the eyes to the scotoma crossings at 50 cm and then extended to the 200 cm plane. The intersection of the sight lines and the 200 cm horizon defined the positions of scotomas whose size was doubled from the 100 cm perimeter (and is quadruple the size at fixation). We also used the sight lines to position

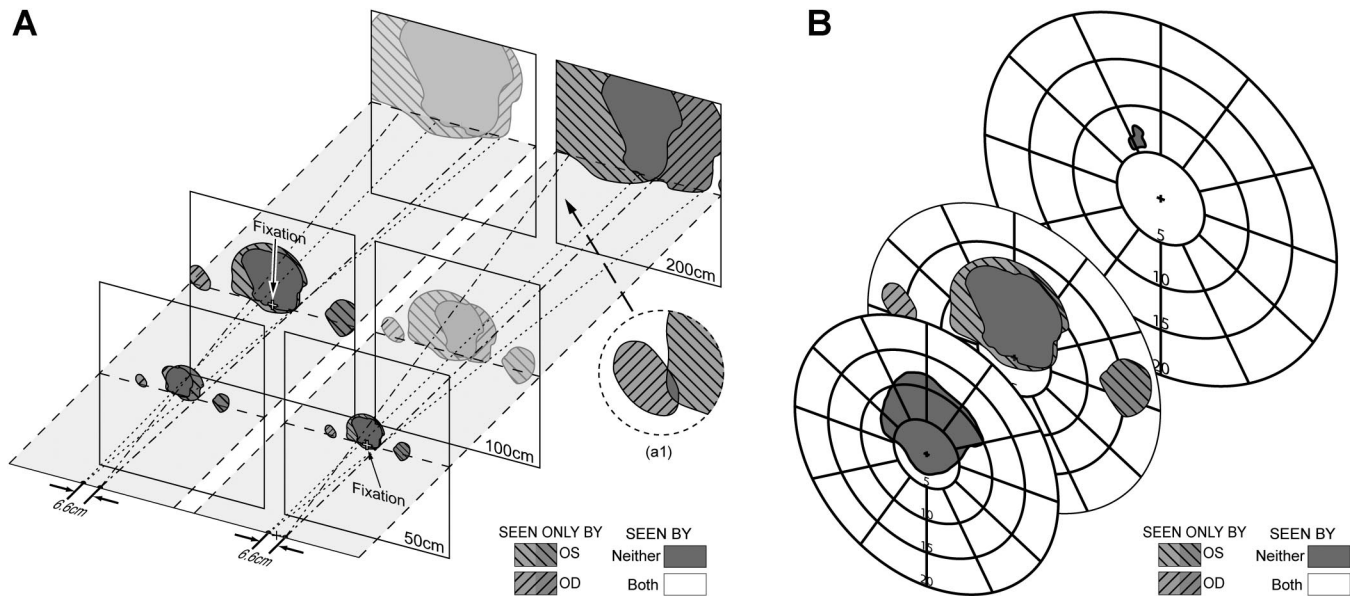


FIGURE 7.

(A) Expected and (B) measured slices through the volume visual fields for patient 3 (CFL). In the projection at 200 cm with 50 cm fixation (A, left), the OD CFL scotoma and OS ONH have shifted enough to overlap and form another binocular volume scotoma. Because that occurs outside the diagram frame, it is shown in inset (a1). CFL-ONH volume scotomas are discussed in more detail in the Appendix (available online at <http://links.lww.com/OPX/A101>).

hypothetical scotomas on the 200 cm plane for the anterior volume case and 100 cm plane for the posterior volume case. Those diagrams are faded to indicate that we did not have corresponding measurements for those cases. The text compares projected and measured results. Note that this approach assumes fusion at fixation, resulting in identical bilateral scotomas at any distance. This assumption is violated at least for the cases of bitemporal and binasal complete hemianopia. In our bitemporal case, we applied our phoria measurements to predict the relative positions of the two eyes at 50 cm fixation from those measured at 100 cm with dichoptic perimetry.

RESULTS

Bitemporal Hemianopia

When patient 1, with an IPD of 6.8 cm, fixates at 50 cm, his convergence angle is $2 \cdot \arctan [(6.8 \text{ cm}/2)/50 \text{ cm}] = 7.8^\circ$. As expected, no binocular anterior volume scotoma was detected (Fig. 5B, front), as the effect of the exotropia (with right eye fixating) and resulting overlap is even greater when projected back to 50 cm (Fig. 5A, left). At 200 cm, the projected average posterior volume scotoma width is about 3° (Fig. 5A, right), and the average width by volume perimetry is about 6° (Fig. 5B, rear). Assuming that 6° measured value, if this patient fixates at a windshield-mounted GPS at 50 cm, the patient's posterior volume scotoma diverges at an angle of about 8.6° from a point 64 cm ahead. A full road lane (3.6 m) would be lost within his posterior volume scotoma at any distance beyond 47 m, and a full four-lane highway would disappear beyond 185 m.

Binasal Scotoma

Patient 2 had an unusual visual field loss due to his congenital macular dystrophy. The scotoma in each eye was mostly nasal to

fixation (i.e., foveal lesions were temporal to the PRL). His binocular PRL was positioned between these two scotomas (adjacent to the dominant left eye's scotoma), resulting in a "partial" binasal field loss. Thus, under binocular viewing conditions, the only scotomas that would be recordable on a conventional perimeter at the plane of fixation are the ONH blind spots of each eye that overlapped the central scotoma in the other eye. This patient's PRL position and fixation stability were measured using a Nidek MP1 (Padova, Italy). Fixation stability within 2° was observed 89 and 99% of the time for OD and OS, respectively. The dichoptic perimetry at the plane of fixation (100 cm) shows the monocular and binocular scotomas (Fig. 6A, left). When this patient, with an IPD of 6.3 cm, fixates at 100 cm, his convergence angle is 3.6° . Thus, the anterior volume scotoma should be 3.6° at any measured distance from the 100 cm fixation distance if the binasal scotomas were in perfect apposition, and the angular scotoma width at 50 cm would also be 3.6° . However, there was a separation between the binasal scotomas (about 3°); therefore, the overlap of the anterior scotomas at 50 cm would only be about 0.5° , comparable with the projected anterior scotoma width (Fig. 5A, left). The measured (Fig. 6B) anterior volume scotoma (6°), however, was larger than the calculated anterior volume scotoma size. This probably resulted from the small and dim laser target (smaller by a factor of 2 in diameter than the target used at fixation). Unlike the relatively sharp scotoma margins expected with hemianopia, the isopter lines of the diagrams are not indicative of the sloping margins of the scotomas expected with this dystrophy. The position of the measured anterior scotoma was not central, but shifted to the left. This could have resulted from imprecise alignment for this patient, or perhaps resulting from a fixation bias toward the dominant left eye during measurement. No posterior volume scotoma was mapped for this patient within the measured plane, except for the physiological blind spots that remain. The temporal blind spot of each eye

overlapped the nasal scotoma of the other eye at the fixation plane. However, the relative position between the scotoma and the blind spot will vary with distance, depending on the angle of convergence. This can be seen in Fig. 6A (inset a2), where the blind spot of the left eye just barely spills out of the anterior scotoma and is partially compensated by the seeing field of the right eye.

Central Field Loss

Patient 3 had a bilateral central scotoma with an inferior PRL in each eye, as determined by both the Nidek MP1 and the standard perimetry. The fixation stability observed for this patient was within 2° 86 and 74% of the time for OD and OS, respectively. With an IPD of 6.6 cm and fixating at 100 cm, this patient had a convergence angle of 3.8°. The bilateral superior scotoma measured 14° horizontally at its widest point in the plane of fixation (Fig. 7). This scotoma size (14°) is larger than the convergence angles when fixating at 100 cm (3.8°) and 50 cm (7.6°). The posterior volume scotoma extends to infinity in both these cases.

When fixating at 100 cm, the projected diameter of the anterior volume scotoma for a measurement slice at a distance of 50 cm is still 12°, as portions seen monocularly at fixation slide together to approximately maintain the binocular loss. Had the scotomas met the criteria of Appendix case II for equally sized scotomas, the scotoma at 50 cm would have shrunk to about 10°. The projected value agrees reasonably with the measured value of about 16° (Fig. 7B). When fixating at 50 cm, the projected diameter of the posterior volume scotoma is 9° wide and 12° high at a measurement slice distance of 200 cm. The measured scotoma was 2° wide and 3° high, using the perimeter target of 17 mm (0.5°; Fig. 7B). Note, however, that the projected diagrams are based on dichoptic perimetry, in which each eye is measured separately but with binocular fixation. The shutter goggles of the perimeter have an open transmittance of only about 30%, and are open less than one-third of the time for each eye. The posterior volume scotoma was measured binocularly, without goggles, so each eye received about a log unit brighter target than in the dichoptic sessions, and both eyes were viewing simultaneously. In addition, less dense portions at the scotoma margins are also involved as the scotomas separate. Together, these effects likely account for the large difference between our projections and the measured results for this patient. A reviewer noted that the blurred appearance of a stimulus presented far from fixation distance would affect perimetry stimulus retinal size, and we note that this and the corresponding decrease in intensity due to the spreading make any computation of the blur effect on the volume scotoma difficult.

DISCUSSION

Measuring volume scotomas exhaustively across depth is impractical, likely requiring specialized equipment and displays, and may take substantially longer time than standard perimetry. However, measuring a few slices through the volume scotomas at various distances is quickly achievable with relatively simple equipment. The standard binocular visual field represents one such slice. Measuring a posterior scotoma slice is as simple as setting up a fixation target in front of the perimeter surface. Measuring anterior scotoma slices requires more specialized equipment, including a

beamsplitter and a mapping surface to interpose stimuli at the desired distance in front of the fixation target. In patients with binocular visual field loss, these volume visual fields can vary substantially from the visual field measured at the plane of fixation, and can reveal volume scotomas not identified and measured otherwise.

The dimensions of volume scotomas in bitemporal hemianopia and binasal hemianopia can be calculated easily, as we have shown. Thus, measuring the volume scotoma may not be necessary, as it can be calculated. Note, however, that such calculation requires knowledge of the positions of both foveae. Bifoveal fixation cannot be safely assumed, especially in cases with complete bitemporal hemianopia. In fact, hemifield sliding is a common finding in bitemporal hemianopia.¹⁰ The presence of tropia (or manifested phoria) in such cases of hemifield sliding will complicate the calculation, as the actual angle of convergence may vary unpredictably with fixation distance, unlike the simple relationship assuming orthophoria used here. Calculated volume visual fields based on monocular fields with monocular fixation, although appropriate in some cases, may not match the actual fields experienced in other cases.

Acknowledging the presence of the volume scotoma and considering its magnitude is essential for effective visual rehabilitation and counseling. Patients should be told about the spatial distortion (object shrinking) that could be perceived as a result of the missing midline strip of volume in space anteriorly (for binasal hemianopia; a rare condition) and posteriorly (for bitemporal hemianopia). More importantly, the potential for not noticing the effect of the scotoma on missing objects should be highlighted. Our patient 1 did complain of missing objects posterior to his fixation.

The potential effects of volume scotomas for driving should be clearly explained to patients with bitemporal hemianopia. The driving requirements in some states (such as Virginia and Wisconsin) deny licenses to people with bitemporal hemianopia, as those states require a temporal extent of the monocular field in at least one eye.¹⁷ These regulations can be understood and be justified in view of the analysis presented here. However, it should be noted that about 10° of temporal field in one eye may be sufficient to compensate for the posterior scotoma. Wisconsin requires just 20° of temporal field in one eye for non-commercial drivers. A large screening study found accident rates for drivers with significant visual field loss in both eyes to be twice that of those with normal visual fields or with monocular field loss.¹⁸ Although this earlier study predominantly recorded peripheral field loss, binocular CFL¹⁹ and even just paracentral field loss²⁰ can also affect driving performance. The volume scotomas we addressed here are all central or paracentral.

With binasal hemianopia or binasal visual field loss, as was the case for patient 2, difficulties due to the anterior volume scotoma in performing tasks such as threading a needle or using small hand tools should be explained to patients, so they will better understand and acknowledge the source of these difficulties. Our patient 2 did not report any such difficulties, perhaps because of better adaptation to a congenital condition, or owing to the separation of the scotomas that further reduced the anterior scotoma.

A binocular central scotoma straddles the vertical fixation plane when the binocular PRLs are either inferior or (more rarely) superior. This has the effect of a combined partial binasal and bitemporal field defect. The resulting volume scotoma varies in a complex manner, depending on the size and shape of the central scotomas and the fixation distance. As the fixation distance increases, resulting in a convergence angle smaller than the binocular scotoma, the angular diameter of the posterior volume scotoma extends to infinity. There is, however, a finite anterior volume scotoma limit. With a lateral PRL, the volume scotoma posterior and anterior to fixation shrinks by an effect similar to that shown for homonymous hemianopia in Fig. 1. The visual field expansion provided in such cases when convergence is at close distances, within arm's length, is substantial and may compensate for much of the field loss due to the scotoma (although the acuity loss remains). This effect may explain why lateral PRL develops in most patients with AMD.

We calculated the average binocular scotoma diameter to be 13° (ranging from 5 to 35°) for 17 AMD patients who participated in a different study in our lab. The convergence angle would be 13° at a fixation distance of about 30 cm (for a 6.6 cm IPD). At that distance, the posterior volume scotoma for a patient with bilateral symmetric scotomas of 13° diameter and a PRL below the scotoma would become a tunnel scotoma. For fixation distances >30 cm, the convergence angle would be smaller than the binocular scotoma size and would result in a posterior volume scotoma that expands and extends to infinity (Appendix case II). The anterior volume scotoma has a finite limit in all these cases (Appendix Eq. A2, available online at <http://links.lww.com/OPX/A101>). For closer fixation distances, a zone of volume scotoma exists with a finite limit to both the anterior (Eq. A2) and posterior (Eq. A3) volume scotomas (Fig. 3C). For most activities of daily living and for social interactions, a distance of 1 m or closer is of relevance. The relationship between the scotoma size and fixation distance beyond which the posterior volume scotoma extends to infinity is

shown in Fig. 8. As this figure shows, for most patients with bilateral central scotomas, at near-task fixation distances the posterior scotoma is finite. At longer fixation distances or with very large scotomas, the posterior scotoma would extend to infinity. However, at near fixation distances, the ONH scotomas are likely to interact with the CFL scotomas, creating additional binocular scotomas that may extend to infinity (Appendix Fig. A4, available online at <http://links.lww.com/OPX/A101>).

Using at least two dichoptically measured slices through a volume scotoma may be sufficient to acquire the data for a computer program that will be able to display full volume perimetry and derive slices at any other desirable plane and at any fixation distance. The scotomas in many conditions may not have sharp margins, and the relative density of the scotoma could vary within the lesion and between the eyes. Computational programs will need to consider the relative density of the scotomas in both eyes (possibly by measuring multiple isopters) and their interactions to predict volume scotomas.¹⁵ In contrast, volume perimetry directly measures that interaction and provides a definitive measure of the volume scotoma slice at the measured isopter.

Confrontation perimetry is commonly used to give a quick coarse estimate of the visual field. Confrontation perimetry, if done binocularly, is analogous to anterior volume perimetry. Here, examiners bring their hands or a target from the side between the patient and themselves into a visual field that is in front of the patient's fixation plane (usually the examiner's eye or nose). Thus, results of confrontational perimetry and standard perimetry may not be identical, as one measures the anterior volume scotomas and the other measures scotomas at the plane of fixation. It is possible that a patient could show an anterior volume scotoma in binocular confrontation perimetry but when tested with conventional perimetry may not show any field defect (or vice versa, for binasal scotomas). To make comparable measurements, the targets shown for confrontation perimetry must be held at the same plane as the fixation target (usually the plane of the examiner nose).

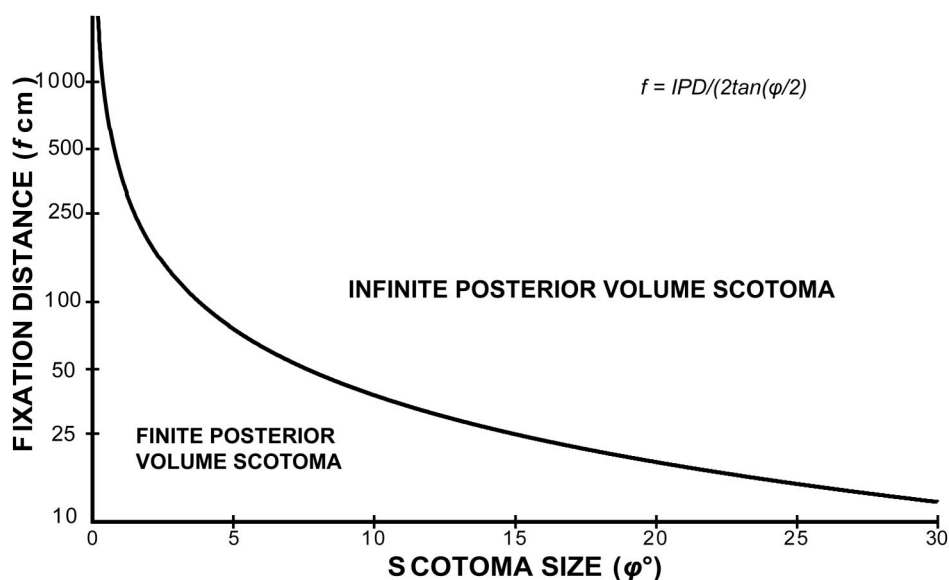


FIGURE 8.

Relationship between scotoma size and the fixation distances beyond which the posterior volume scotoma extends to infinity. The graph assumes equal-diameter CFL scotomas OD and OS centered above the PRL. An IPD of 6.6 cm was used, but the curve varies little with IPD. Points lying on the curve yield the “tunnel” scotoma of Fig. 3B.

Although we demonstrated the measurement of volume scotomas in this study using simple experimental setups, there is room for improvement for these measurements, particularly for anterior volume perimetry. In this study, a small laser target moved manually by the examiner was used as a stimulus, and response was manually recorded. This methodology can be improved by having a flat screen monitor mounted on top of the beamsplitter, driven by the computerized perimeter software. The image of a stimulus on the monitor can then be reflected by the beamsplitter. The luminance of this monitor can be set to an adequate level such that both the background and the targets reflected in the beamsplitter are matched to those used in the measurements at the fixation plane. Computerizing the anterior volume perimetry would give more accurate measurements of the anterior volume scotoma than those achieved here. Importantly, the use of a stereo flat screen will make it possible to perform dichoptic perimetry at the anterior plane as well.

Volume scotoma slices measured through volume perimetry, and consideration of volume scotomas in general, can help better understand the functional vision of patients, correlate with their activities of daily living, and help in developing better plans for visual rehabilitation.

ACKNOWLEDGMENTS

Supported in part by NIH grant EY12890 and P30EY003790. We thank Alex Hwang for help with illustrations and Dekuang Yu for helping with Fig. 2.

Received: January 10, 2012; accepted May 14, 2012.

APPENDIX

The Appendix is available online at <http://links.lww.com/OPX/A101>.

REFERENCES

- Wang CC, Kosinski CJ, Schwartzberg JG, Shanklin AV. Physician's Guide to Assessing and Counseling Older Drivers. Washington, DC: National Highway Traffic Safety Administration; 2003.
- Woods RL, Giorgi RG, Berson EL, Peli E. Extended wearing trial of Trifield lens device for 'tunnel vision.' *Ophthalmic Physiol Opt* 2010;30:240–52.
- Turano KA, Broman AT, Bandeen-Roche K, Munoz B, Rubin GS, West S. Association of visual field loss and mobility performance in older adults: Salisbury Eye Evaluation Study. *Optom Vis Sci* 2004; 81:298–307.
- Arditi A. The adaptive significance of the location of the optic disk. *Perception* 1987;16:649–54.
- Arditi A. The volume visual field: a basis for functional perimetry. *Clin Vis Sci* 1988;3:173–83.
- Labianca AT, Peli E. Monocular and binocular PRL are inconsistent. In: Proceedings of the International Conference on Low Vision, "Vision '96." Madrid, Spain: ONCE; 1997:381–7.
- Kabanarou SA, Crossland MD, Bellmann C, Rees A, Culham LE, Rubin GS. Gaze changes with binocular versus monocular viewing in age-related macular degeneration. *Ophthalmology* 2006;113: 2251–8.
- J. D. Power and Associates. Heads Up Display Technology. Available at: <http://www.jdpower.com/content/detail.htm?jdpaArticleId=206>. Accessed July 24, 2012.
- Murph D. GM shows off sensor-laden windshield, new heads-up display prototype. Available at: <http://www.engadget.com/2010/03/18/gm-shows-off-sensor-laden-windshield-new-heads-up-display-protol/>. Accessed June 14, 2012.
- Kirkham TH. The ocular symptomatology of pituitary tumours. *Proc R Soc Med* 1972;65:517–18.
- Sunnness JS, Applegate CA, Haselwood D, Rubin GS. Fixation patterns and reading rates in eyes with central scotomas from advanced atrophic age-related macular degeneration and Stargardt disease. *Ophthalmology* 1996;103:1458–66.
- Arditi A, Zihl J. Functional aspects of neural visual disorders of the eye and brain. In: *The Lighthouse Handbook on Vision Impairment and Vision Rehabilitation*. Oxford: Oxford University Press; 2000: 263–86.
- Verezen CA, Hoyng CB, Meulendijks CF, Keunen JE, Klevering BJ. Eccentric gaze direction in patients with central field loss. *Optom Vis Sci* 2011;88:1164–71.
- Arditi A, Azueta S. Visualization of 2-D and 3-D aspects of human binocular vision. In: *Society for Information Display (SID) International Symposium Digest of Technical Papers*. Playa del Rey, CA: Society for Information Display; 1992:1–4.
- Arditi A, Azueta S, Larimer J, Prevost M, Lubin J, Bergen J. Visualization and modeling of factors influencing visibility in computer-aided crewstation design. In: *Proceedings of the 22nd International Conference on Environmental Systems*; Seattle, Washington: SAE Technical Paper No. 921135. Warrendale, PA: Society of Automotive Engineers, Inc.; 1992:1–10.
- Woods RL, Apfelbaum HL, Peli E. DLP-based dichoptic vision test system. *J Biomed Opt* 2010;15:1–13.
- Peli E. Low vision driving in the USA: who, where, when, and why. *CE Optom* 2002;5:54–8.
- Johnson CA, Keltner JL. Incidence of visual field loss in 20,000 eyes and its relationship to driving performance. *Arch Ophthalmol* 1983; 101:371–5.
- Bronstad PM, Bowers AR, Goldstein RB, Albu A, Peli E. The impact of macular disease on pedestrian detection: a driving simulator evaluation. In: *Proceedings of the Fifth International Driving Symposium on Human Factors in Driver Assessment, Training and Vehicle Design*, Big Sky, Montana, June 22–25, 2009. Iowa City, IA: University of Iowa, Public Policy Center; 2009:320–6. Available at: http://drivingassessment.uiowa.edu/DA2009/044_BronstadBowers.pdf. Accessed June 14, 2012.
- Bronstad PM, Bowers AR, Albu A, Goldstein RB, Peli E. Hazard detection by drivers with paracentral homonymous field loss: a small case series. *J Clin Exp Ophthalmol* 2011;S5:001. doi: 10.4172/2155-9570.S5-001.

Eli Peli

Schepens Eye Research Institute

20 Staniford St

Boston, MA 02114-2500

e-mail: eli.peli@schepens.harvard.edu