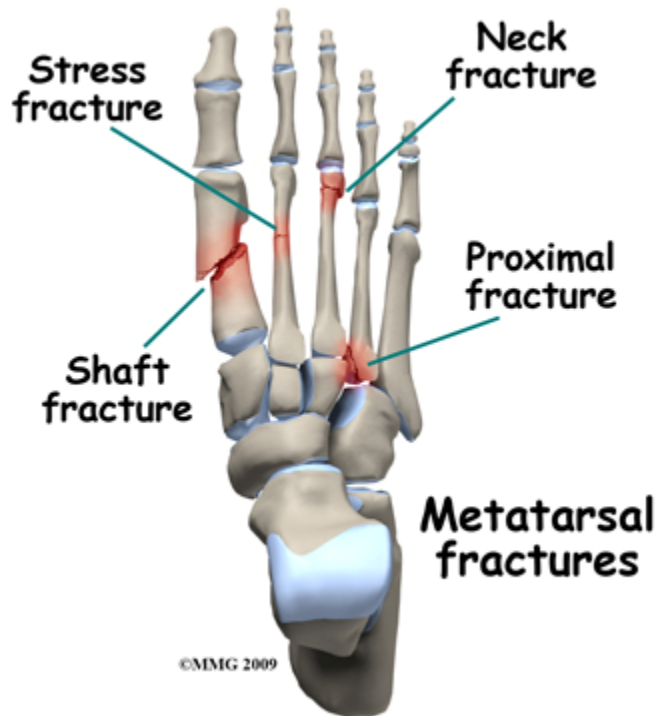


Introduction

Foot Fractures



Feet hurt! Everyone has aching feet. The remarkable thing is that feet don't hurt more often and more severely. When the heel strikes the ground during normal walking it absorbs a blow equivalent to twice body weight. Are there many other parts of your body which could shrug off a 300lb blow 30 times a minute? The skin, the fatty tissue, the muscles, ligaments, joints, and bones of the foot are all work together to absorb this shock and to keep a spring in your step.

If you overload the system and break something, you temporarily lose the ability to walk without pain and you disrupt the complex working relationship between the parts of the foot. It takes time to recover this but the good news is that most foot fractures heal well without major intervention.

There are 26 bones in the foot with over 30 joints between them; they can all be injured, making the task of describing "foot fractures" difficult. A comprehensive account of all possible fractures of the foot would make dull reading especially as you are really only interested in one type of fracture - yours. This guide will focus more on the general principles of the treatment and rehabilitation of major injuries to the foot and describe a few of the more common fractures in detail.

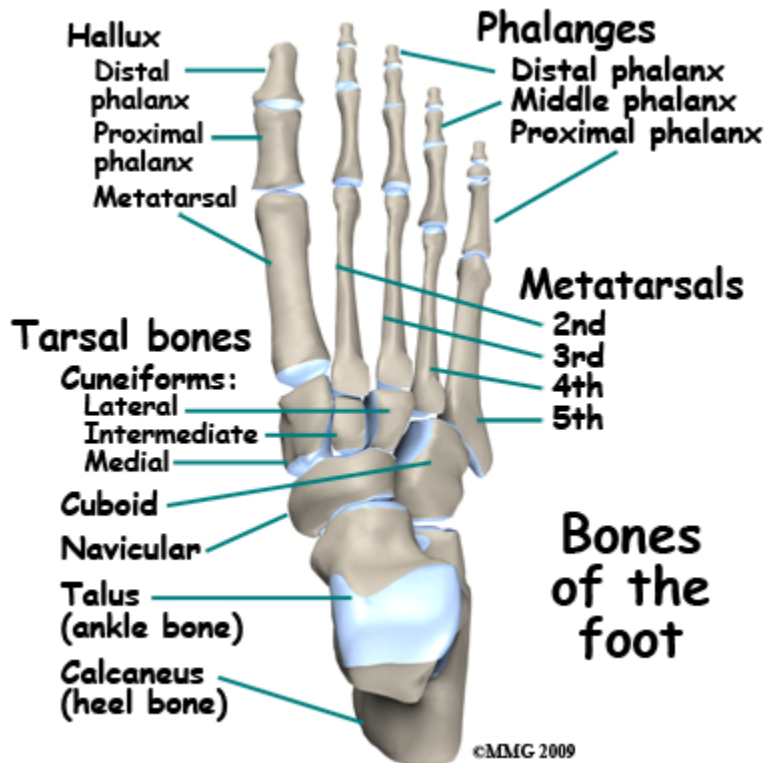This guide will help you understand

- what parts of the foot are involved
- what the symptoms are
- what can cause these fractures
- how doctors diagnose these fractures
- what the treatment options are

Anatomy

What structures are most commonly injured?

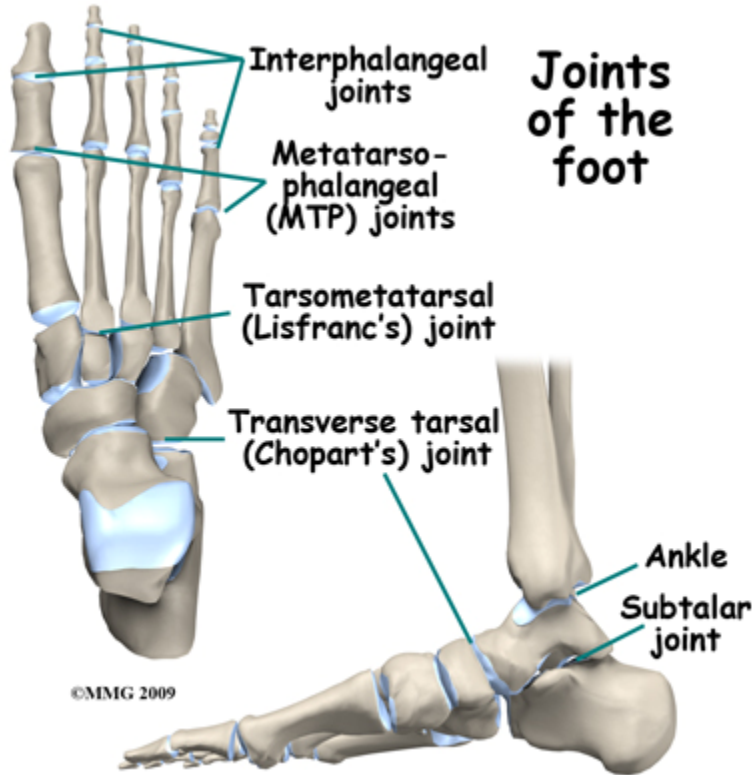
The foot has 26 bones, but it also has four layers of muscles and tendons, joints, veins, arteries, nerves and fatty tissue. It is very important to remember that a force severe enough to break a bone will damage some of these other tissues as well. Injury causes swelling and bleeding which eventually forms scar tissue. During the healing process, this scar tissue can bind together the muscles and tendons which normally glide over one another. How well the foot functions after a fracture depends on how well both bone and soft tissue heal.



The names of the bones going from the heel forwards are:

- Calcaneus – Heel bone
- Talus – Ankle Bone
- Navicular
- Medial, Intermediate (Middle) and Lateral Cuneiform
- Cuboid
- Metatarsals (Lesser Toes)
- 1st Metatarsal (Big Toe, Hallux)
- 1st Proximal Phalanx (Big Toe, Hallux)
- 1st Distal Phalanx (Big Toe, Hallux)
- Proximal, Middle & Distal Phalanges (Lesser Toes)

The big toe is officially called the *hallux*. Many parts of the foot that are associated with the hallux include the word *hallucis* in the name. For example, the long muscle that flexes (bends) the big toe downwards is called *flexor hallucis longus*.



There are a large number of joints between the bones in the foot. The important ones are:

The *ankle joint* between the end of the shin and the talus (ankle bone). It allows up and down movement of the foot.

The *subtalar joint* between the talus and the calcaneus (heel bone). It allows side to side movement so that you can stand on the side of a sloping surface.

The *transverse tarsal joint* (also called *Chopart's joint*) is formed by the talus and calcaneus on one side and the navicular and cuboid on the other. It allows some pivoting movements of the forefoot on the hindfoot and flattening of the arch.

The *tarsometatarsal joint* (also called *Lisfranc's joint*) is between the distal tarsal bones, (the three cuneiforms and the cuboid) and the metatarsals. Its complex anatomy allows for a little movement of the longitudinal arch of the foot and a bit more movement at the outer border of the foot. Dislocation of this joint is a serious injury often associated with fracture of the metatarsals and/or cuneiform bones.

Metatarsophalangeal (MTP) joints. There are five of these. These joints are between the heads of the metatarsals and the proximal phalanges. They allow flexion and extension of the toes. When you stand on tiptoe the MTP joints are extended and you are bearing weight on the toes and the joints.

Interphalangeal joints. These nine joints are located between the *phalanges* (toe bones) and allow the toes to curl. Loss of this function is not usually a severe handicap.

The big muscles that power walking by moving the ankle, foot and toes, are located in the leg. If you wiggle your toes and put your fingers on the muscle on the outer side of the front of the leg just below the knee, you can feel the muscles contracting. Their pull is transferred to the bones of the foot by long thin tendons that extend from the muscle in the leg, down

across the ankle and into the foot to end in the toes. These tendons glide inside special tendon sheaths. These tendon sheaths may be damaged when the foot is injured.

Other *intrinsic* muscles of the foot form the flesh of the sole of the foot. There are actually four layers of muscles on the sole of the foot. They are important in maintaining the arch of the foot, a critical part of the shock absorption system. These muscles are protected from weight bearing by the *plantar fascia*, a tough layer of fibrous tissue next to the skin on the sole of the foot. Bleeding into the sole of the foot from a fracture may result in scar tissue which may bind all these layers together and interfere with function.

Viewed from the side there are other interesting aspects of [foot anatomy](#). The heel pad is a specialized region situated between the heel bone and the skin. It has an elastic honeycomb-like structure with the "cells" filled with fatty tissue. These cells work like a shock absorber. When the heel comes down the cells stretch and flatten, absorbing some of the shock. An injury severe enough to break the *calcaneus* (heel bone) is also often severe enough to disrupt the heel pad. It may heal with solid scar replacing the specialized heel pad structure. This reduces its ability to absorb shock.

Further forward is the arch of the foot. This is a dynamic feature of the foot only partly due to the shape of the bones. When you are standing, the muscles that maintain the arch relax and it partially flattens. When you rise on the ball of the foot to take a step the arch is restored. The ball of the foot itself is at the level of the metatarsophalangeal (MTP) joints between the metatarsals and the toes.

You bear quite a lot of weight on the heads of the metatarsals as you spring off the foot at the end of a pace. The smaller toes do not contribute much to walking but a good deal of force goes through the big toe. In a normal pace the weight of the body first meets the ground at the heel then is gradually transferred forward along the outer margin of the foot, across the ball of the foot ending on the big toe. Fractures of bones along this path have more serious consequences for foot function.

Causes

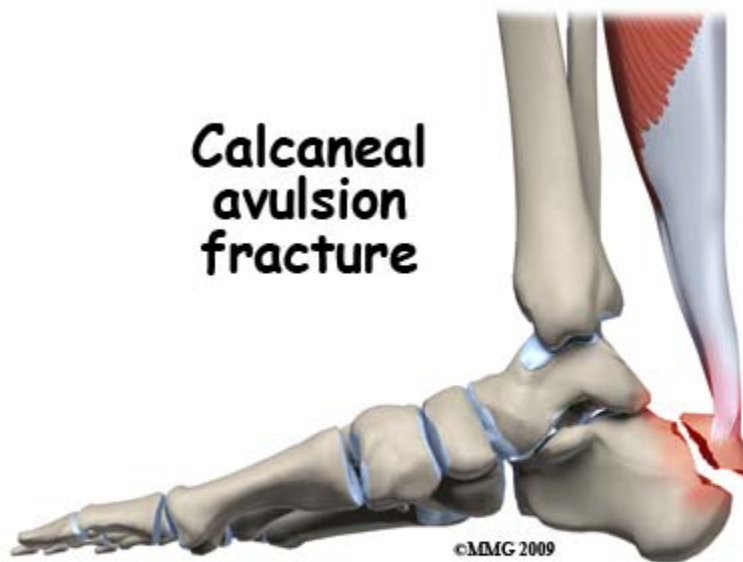
How do fractures of the foot commonly happen?

Bones break when the force applied to them exceeds their strength. In the foot this type of overload happens with falls from a height, from crushing injuries when something falls on the foot, from kicking something, or from catching the foot in something and twisting. Catching the foot in machinery may cause devastating crush injuries. A rare but well recognized type of foot fracture results from fatigue failure. This stress fracture is seen when repetitive loads are excessive.

Types

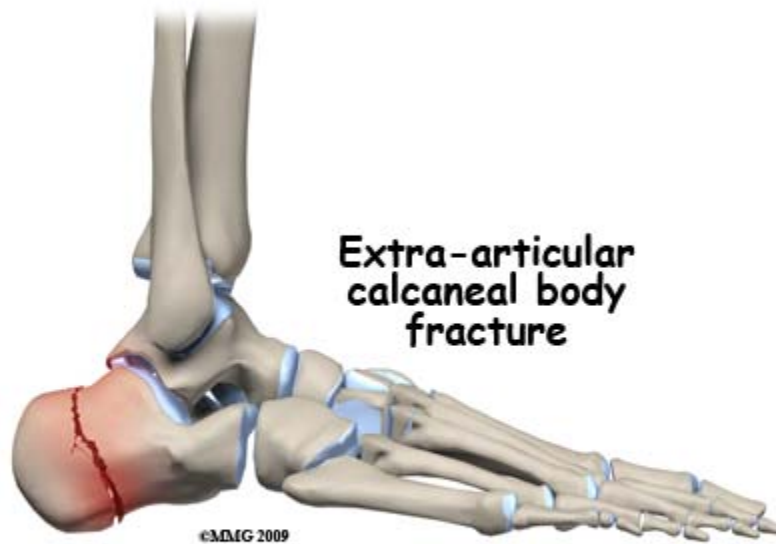
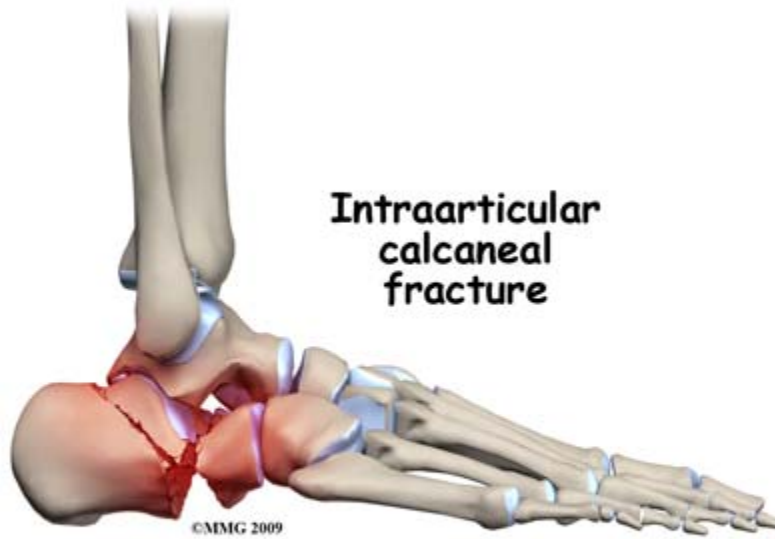
Calcaneus

The *calcaneus*, or heel bone, is the most frequently fractured tarsal bone, accounting for 2% of all fractures seen in adults and more than 60% of tarsal fractures.

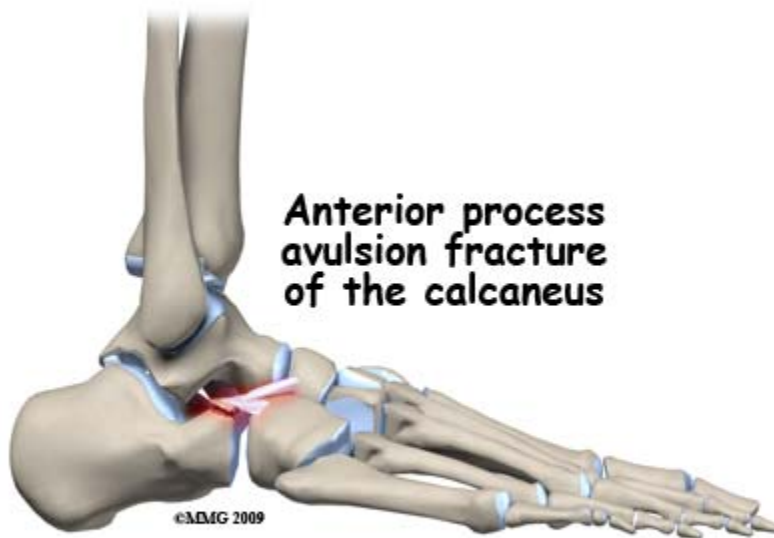


Avulsion fractures (3%) can occur by over-pull of the heelcord ([achilles tendon](#)) usually during a major effort in sports or jumping. It can be the result of fatigue failure with multiple repetitive effort.

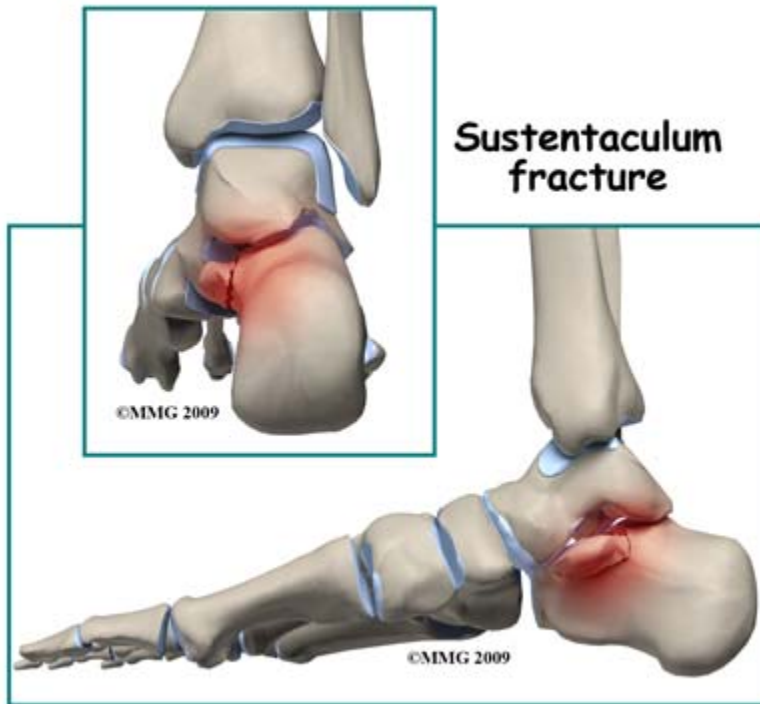
A fracture occurring into the joint between the talus and the calcaneus(70%) is one of the most serious foot fractures. It is caused by axial over-loading, driving the talus (ankle bone) down into the heel bone. Motor vehicle accidents and falls from ladders are common causes. There is quite a high risk of other injuries with fractures of the other heel, fractures of the spine and injuries to the kidney all being quite common. Disruption of the heel pad is also common and compartment syndrome of the foot can occur. Because it makes a major weight bearing joint surface irregular, this injury may be treated by surgery to restore the joint to smoothness.



A fracture may also that does not involve the joint. This fracture is caused in a different way. A direct blow to the side of the heel or trapping and twisting the heel may cause a fracture which does not go into the joint. Most often these can be treated without surgery.

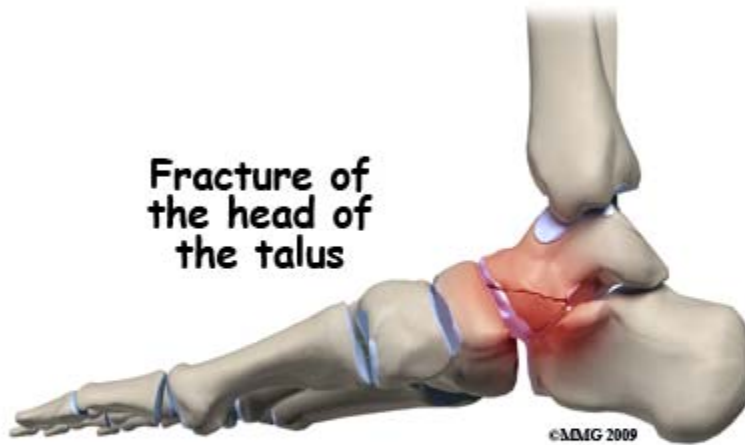


A fracture of the *anterior calcaneus process* is a rare fracture that can be caused either by avulsion of the attachment of a ligament when the foot is twisted inwards or by compression when the foot is twisted outwards.

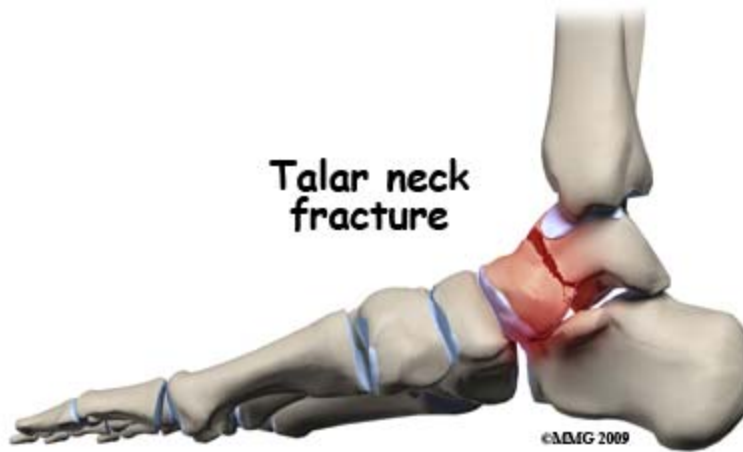

A portion of the calcaneus that juts out to support the talus is called the *sustentaculum*. It may be broken in an accident in which the foot is twisted inwards while bearing a significant amount of weight.

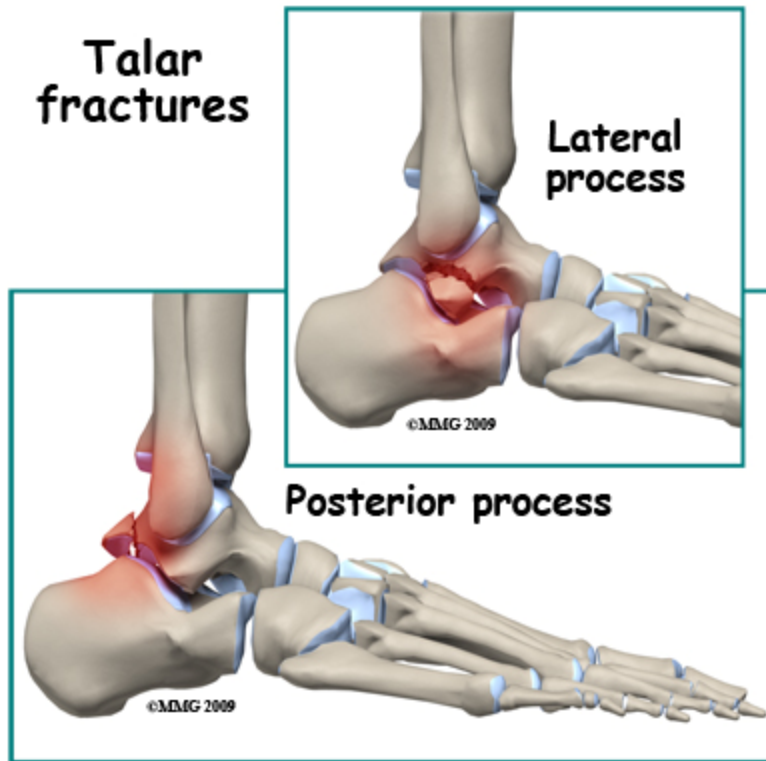
Talus



A fracture of the head of the talus accounts for 5 to 10 percent of all fractures of the talus. This fracture is caused by a compressive force when the foot is pointed downwards. The fracture enters the joint between the talus and the navicular. If it is displaced it is often treated by surgery (ORIF), because it involves a joint surface.

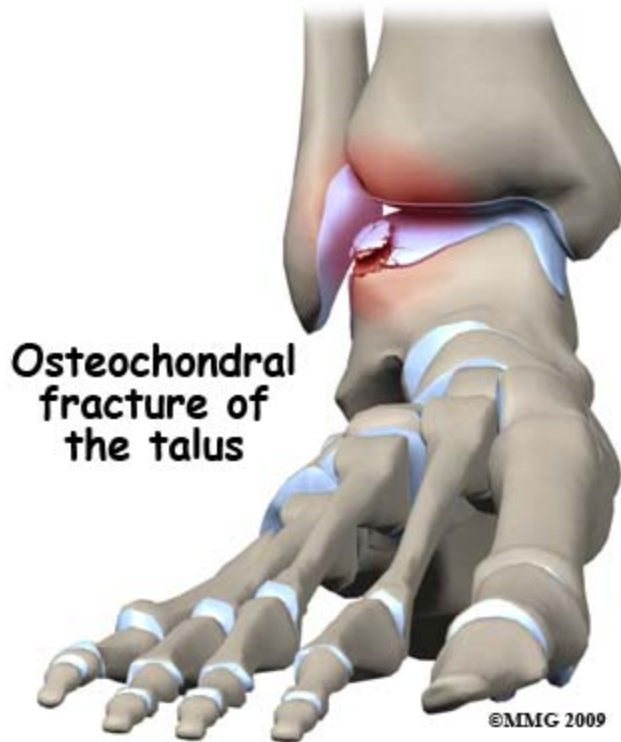

A fracture of the neck of the talus is a serious injury. This fracture passes transversely across the talus and isolates the part of the bone that forms the [ankle joint](#). Forces that bend the foot up beyond its limit are responsible for this pattern of fracture. Open fractures are common. There is a high incidence of *avascular necrosis* of the dome of the talus. Avascular necrosis is a condition where the blood supply to a bone is damaged. This results in death of the area of bone that is normally supplied by the blood vessels that are injured. Over time, this bone may collapse causing severe damage to the joint and *post traumatic arthritis*.



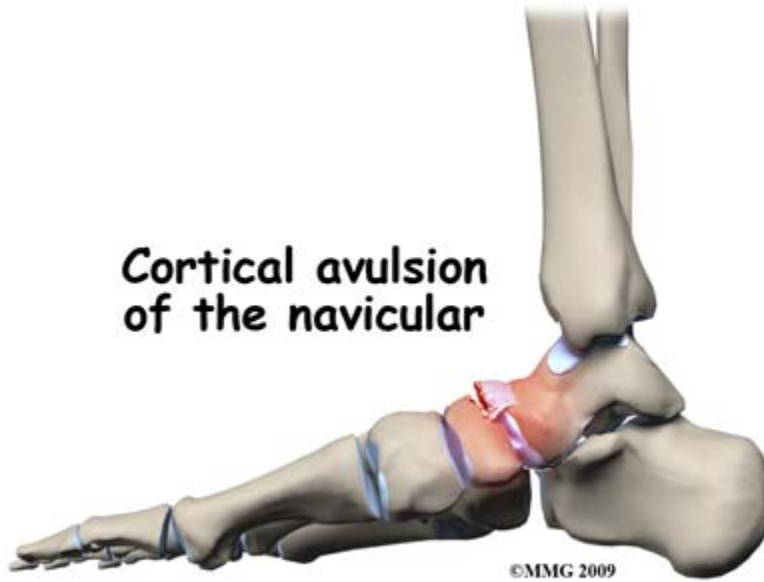
The *lateral process* is a small bump of bone on the outside of the talus which is the attachment of ligaments of the ankle joint and the subtalar joint. Severe twisting forces to these joints may tear the ligament ([ankle sprain](#)) or pull off the piece of bone ([lateral process fracture](#)). The treatment and outcome of this fracture depends on how much of the nearby joint surfaces are damaged.

The *posterior process* of the talus may be fractured. Either the inner (medial) or outer (lateral) side of the back of the talus may be broken off when the ankle is severely twisted. Ligaments of the ankle and subtalar joints attach here. The surface of the joint with the heel-bone may be damaged.

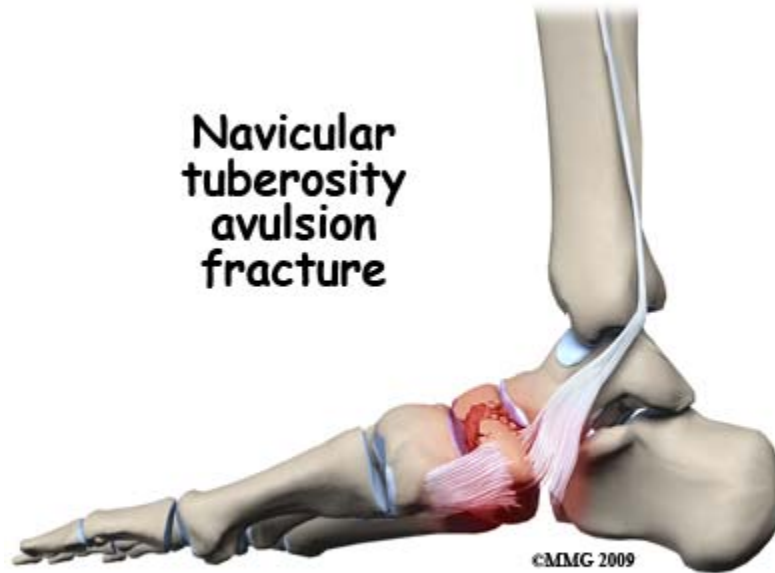


A fracture of the joint surface of the talus is called an *osteochondral fracture*. In some [ankle sprains](#) a portion of the joint surface of the talus can become separated from the rest. This is difficult to see on x-ray. In some cases the fragment will heal if the joint is immobilized. In others it may need to be removed.

Navicular

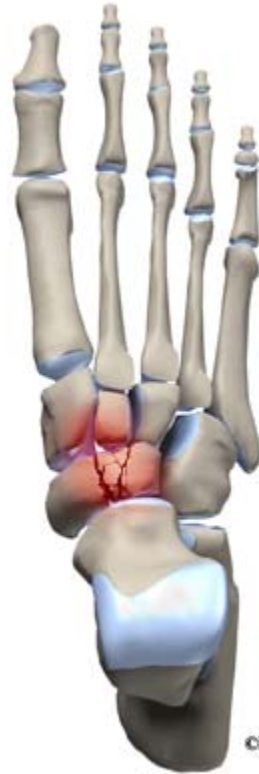

A *cortical avulsion* fracture may be caused by over-pull of muscle or ligament attachments. These injuries occur when the foot is twisted. Normally, they heal without intervention except for resting the foot. However, if the fragment is displaced 1 cm or more it is advisable to operate to replace it and fix it back in position.



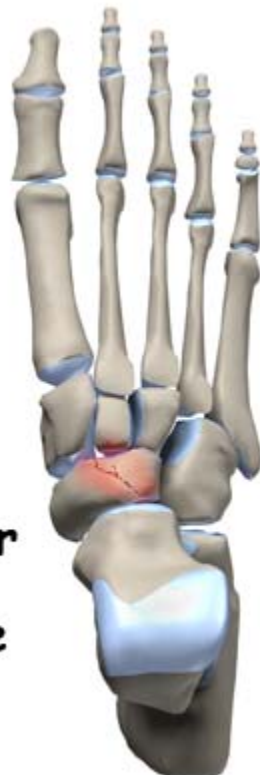A *navicular tuberosity fracture* is also an avulsion fracture caused by over-pull of the tibialis posterior muscle. This is a powerful muscle that inverts (turns the foot inward) the foot and maintains the arch. Surgery is often required to replace and fix the fragment.

**Navicular
body
fracture**



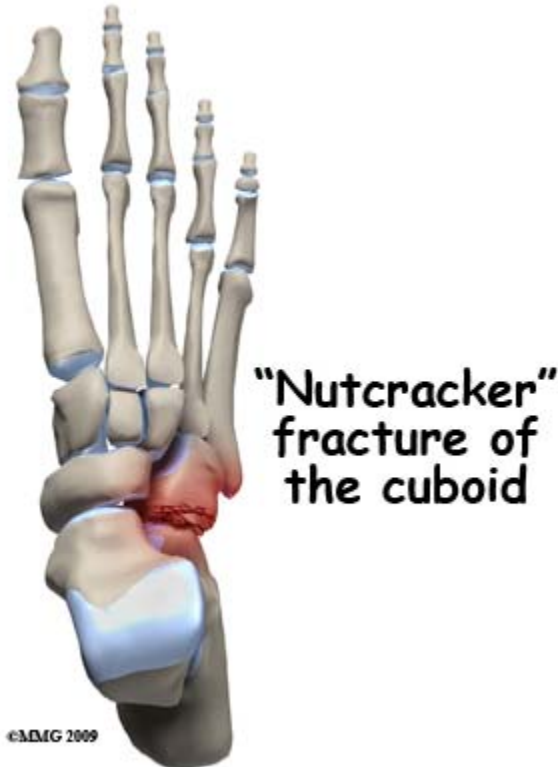
Fractures of the *navicular body* often pass through the joints with the talus, the cuneiform or both. If there is any displacement they need to be treated surgically with ORIF.

**Navicular
stress
fracture**



A *stress fracture* of the navicular is a relatively common fatigue failure fracture in athletes and military recruits who undertake repetitive training exercises that load the foot. Diagnosis is often delayed because these fractures do not initially show up on X-ray. Simply resting the foot for several weeks is usually successful treatment.

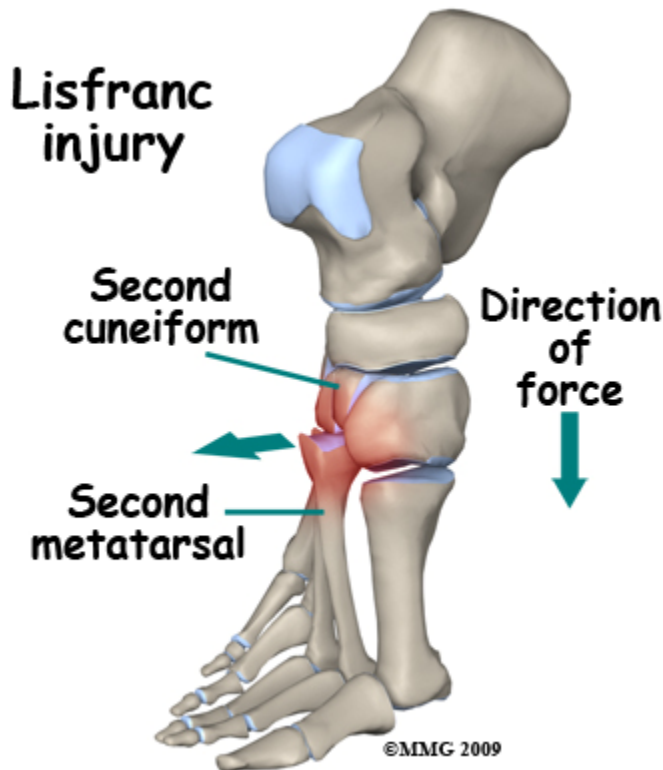
Cuboid



A isolated fracture of the Cuboid is relatively uncommon. The bone is more often broken when a major force injures the midfoot and fractures the cuneiforms or the talus and/or the navicular as well. Treatment depends on the overall situation.

The *nutcracker injury* results from a force pushing the foot outwards and crushing the cuboid between the calcaneus and the 4th & 5th Metatarsals. If the cuboid is badly crushed the outer border of the foot will be distorted even after the bone heals. In some cases the length of the cuboid can be restored by an open operation to reduce and fix the fracture then supplement the crushed bone with bone graft.

Medial Cuneiform, Intermediate Cuneiform, Lateral Cuneiform

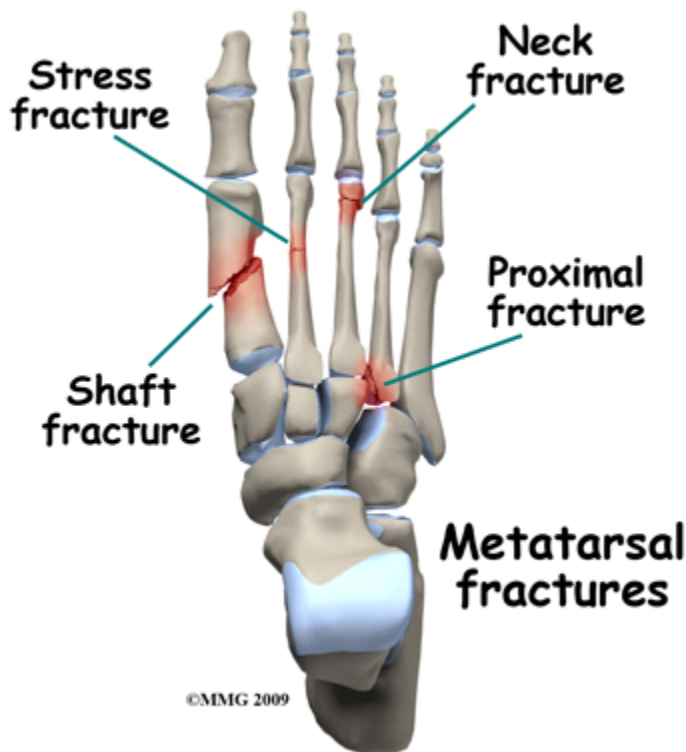


Isolated fractures of these bone are quite rare but may occur from direct impact – dropping something on the foot. More commonly, fractures to these bones occurs in association with fractures of other bones of the midfoot and hindfoot. An injury that disrupts the tarsometatarsal joint often also causes fracture of one or more cuneiform bones.

One relatively common injury occur at the *tarsometatarsal (Lisfranc's) joint*. Partial or complete dislocation with or without fractures of one or more of the metatarsals is called a *Lisfranc Dislocation*. It is caused by axial loading the foot when standing on tiptoe or by impact or twisting the mid-foot. It is sometimes difficult to diagnose on standard x-rays. Stress views of the mid-foot show that the joint between the 2nd metatarsal and the cuneiforms is disrupted. This is an unstable injury which often requires operative treatment.

1st – 4th Metatarsals

Injuries of these metatarsals usually occur as fractures of the neck region, shaft fractures or stress fractures. Neck fractures often affect more than one metatarsal bone and are caused by dropping a weight on the instep, kicking or loading when on tiptoe. Even though the fractures may be quite displaced they usually heal without intervention and cause no significant long term problems.



Metatarsal shaft fractures are also usually caused by impact or crushing. Treatment is individualized but many such fractures can be treated non-operatively.

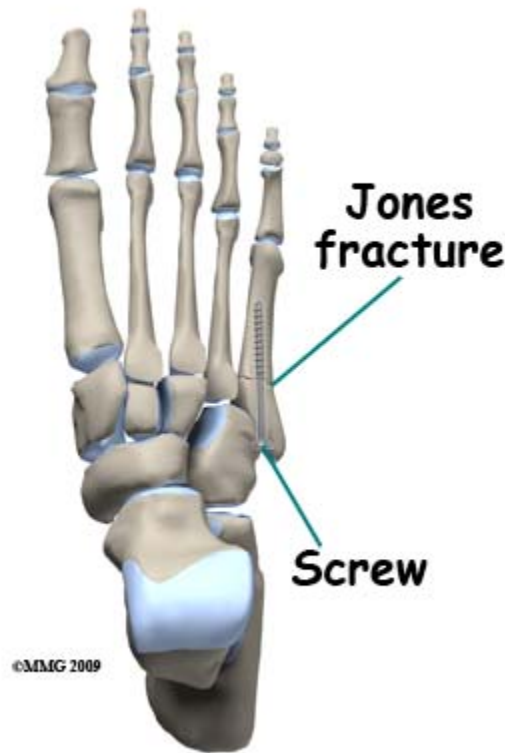
Stress fractures occur in the proximal region of the metatarsal shaft. They are caused by repetitive activity and were first described in army recruits who were expected to undertake long marches and drill activities. These injuries are fatigue failures of the bone and usually heal if the activity which causes them is stopped and the foot is allowed to rest for several weeks.

Insufficiency fractures occur in people with [osteoporosis](#) and the metatarsal can break with very little force. These are *fragility fractures* which are a warning that there is a greater risk of spinal and [hip fractures](#) in the patient. Treatment of the fracture is often quite simple with rest and non-weight bearing resulting in healing. However, the patient should be assessed for osteoporosis and may need treatment for that condition.

Related Document: [A Patient's Guide to Osteoporosis](#)

5th Metatarsal

A very common foot fracture that sometimes occurs during an ankle sprain is the *avulsion fracture* of the tuberosity, or base, of the fifth metatarsal. The injury is caused by *inverting* or turning the ankle over - the same movement that occurs when an ankle sprain occurs. One of the muscles that attempts to prevent this is the peroneus brevis. Over-action by this muscle causes an avulsion fracture of the tuberosity of the 5th metatarsal where the muscle's tendon attaches. This injury will heal without intervention and should be treated quite simply with rest and protection.



A more serious type of 5th metatarsal fracture is known as the *Jones fracture*. This injury is also caused by an inversion twist of the foot. It is a fracture of the upper end of the 5th metatarsal as well but slightly further out, or distal, than the avulsion fracture. This fracture also enters the joint with the 4th metatarsal. This fracture is more serious primarily because it may not heal and may require surgery.

Stress fractures can also occur in the 5th metatarsal. Patients may present with a painful outer border of the foot without a clear history of an accident. Although it seems very similar to the avulsion fracture, the stress fracture behaves very differently with a high rate of non-union. Some surgeons prefer to treat this fracture by surgery even if it is an acute injury; chronic injuries or stress fractures are very often treated by surgery (ORIF).

Phalanges (Toes)

The little bones that make up the toes are collectively called phalanges. Fractures to these bones are common and can be caused by kicking, stubbing the toe or when something is dropped onto the toe. The fractures can be roughly divided into those that affect the joint at one end or the other (intraarticular fractures) and those which do not (shaft fractures). Restoring the smoothness of the joint surface may sometimes require surgery (ORIF) but it is actually rare for either type of fracture to require operation. Most people do not put a lot of weight through their toes so they don't have to heal straight.

Symptoms

What symptoms do foot fractures cause?

Pain and tenderness are the most frequent symptoms that arise from a foot fracture. Both the pain and the tenderness are usually localized to the broken bone. Moving the foot or hanging it down tend to increase the pain while elevation, ice, and immobilization make it better. Bruising and swelling are also very common and arise within a few minutes of the injury. Wounds in the foot need to be carefully evaluated in case there is an underlying open fracture.

Foot fractures are quite common in multiple injuries – such as motor vehicle accidents. Where there are other major symptoms from fractures of the long bones, head injuries, or abdominal injuries, the symptoms from foot fractures may not be very prominent. It is not unusual for foot fractures to be unrecognized for a few days in these circumstances.

Evaluation

How will my fracture be evaluated?

At the scene of the injury, first aid for foot fractures consists of dressing any wounds, treating shock, taking weight off the foot, and transferring the patient to hospital. Sometimes it is advisable to splint the foot.

In the Emergency Room the focus of the treating team is on treating pain and shock, diagnosing the foot injury accurately, making sure that there are no other significant injuries, and arranging for referral to the appropriate specialist. Many foot fractures can be treated by the Emergency Room Physician and followed by your Family Doctor, but others require referral to an orthopaedic surgeon or podiatrist.

The evaluation will include taking an account of the accident and the type of force that hurt your foot. The foot will be examined for wounds, tenderness, swelling, bruising, or any abnormality of the shape of the foot or toes. It may be helpful to compare it with the uninjured side. Many of the accidents that cause a fracture on one side also cause a less prominent but still significant injury on the other. Footwear and socks must be removed for the examination and this may require cutting off the shoe or boot to prevent further pain.

X-rays of the foot, toes, or ankle will be taken if there is a suspicion of fracture. The standard views are often sufficient but special x-rays, including stress views, can be ordered for fractures of the talus and injuries of Lisfranc's joint.

The specialist's assessment will repeat the history and physical examination. The patient's general medical status, occupation, sports activity, and expectations are all important aspects which may affect the treatment plan. The surgeon will evaluate the x-rays and may order more specific views to make sure the full extent of the injury is known.

For fractures of the calcaneus, ankle bone and mid-foot a Computerized Tomography (CT) Scan may be useful. Once the anatomy of the fracture is completely understood the surgeon will discuss the treatment options with you. This discussion may take into account the exact nature of the fracture and its prognosis as well as your expectations, preferences, and general medical status.

Treatment

What treatments should I consider?

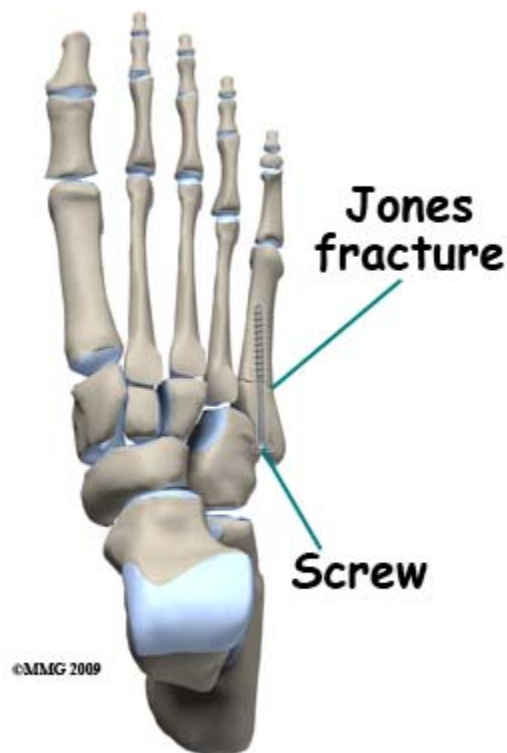
Nonsurgical Treatment

Most foot fractures recover well without surgery. The common fractures of the toes and metatarsals do not need 100% accurate reduction for your foot to heal and perform normally. In these cases the goals of treatment are to relieve pain, protect the foot against further harm and allow the bones to heal.

Pain medication, rest, elevation, and avoidance of weight bearing are the principle treatment methods. It is not always necessary to apply a **cast** or splint to the foot as this does not affect the healing process. A splint may be applied to help with pain relief or to protect the foot. These splints may be discontinued after a few days. Crutches are used to allow you to get around without bearing weight on the fracture, until there are signs of healing on x-ray – usually six weeks.

Toe fractures which are in an unacceptable position may need to be reduced before splinting. This can usually be done under local anesthetic. The toe can then be pulled straight and splinted to its neighbor. This is commonly referred to as *buddy taping*.

Surgery



Unstable foot fractures are likely to lose the correct position and fail to heal (nonunion) or heal with deformity (malunion). The Jones fracture of the 5th Metatarsal is a common example. These fractures may be treated by reducing the fracture fragment back into position by manipulation and holding it there with pins passed through the skin and across the fracture. The foot would be protected by a splint after this procedure and the pin(s) would stay in place until there was evidence of healing on x-ray. This generally takes about six

weeks. Pin removal is a minor procedure which is usually done in the office or clinic and does not require an anesthetic.

Surgery is needed for open fractures. The bone and surrounding muscles and tendons are contaminated by bacteria which have entered the wound. All dirt and dead tissue must be removed from the wound and this may mean quite an extensive opening up of the wound to make sure that the tendons that glide over the bone are cleaned up.

Fractures that disrupt important joints such as calcaneus fractures, fractures of the talus and injuries of Lisfranc's joint are often treated by open reduction and internal fixation (ORIF). The aim is to restore the joint surface to smoothness and minimize future post traumatic [arthritis](#) of the joint. Calcaneus fractures can be treated by applying a plate along the outer side of the bone. Many other situations can be treated by fixing the fragments in place with screws.

Where ORIF has been performed, the implants (screws and plates) used to hold the fracture fragments in position are usually left in place. Sometimes protruding screw heads or tips cause symptoms and this prompts hardware removal. Many patients worry about the operation to remove hardware and expect it to be as painful as the original fracture treatment. This is rarely the case because the bone is healed and there is much less collateral damage in the way of swollen tissue and torn muscle. Recovery after hardware removal is usually quite rapid and most people are very pleased to have it done.

Regardless of the amount of intervention, the management plan usually involves close follow up. It is important to know that the fracture is behaving as predicted and the fragments are remaining in an acceptable position. You should make sure that you are able to return for follow up as recommended.

Rehabilitation

What happens as I recover?

After treatment the foot stays symptomatic for several weeks. It hurts and swells when it hangs down; bruising may be evident for some time also. Rather mysteriously, it is common for fractures of the hind-foot, ankle & mid-foot to result in bruising between the toes. Because the bones are deep inside the muscle layers the bleeding may track to distant areas rather than coming to the skin right under the broken bone.

Most foot bones show evidence of healing by six weeks post fracture. Until then it is often more comfortable to avoid bearing weight on the affect foot, so you should use crutches and keep the foot off the ground. Once the pain and swelling has settled you may be able to bear some weight, depending on the location and nature of the fracture. Take your doctor's advice about this. If you put too much weight on the foot too soon, you risk displacing the fracture or breaking the pins or screws if you have had surgery.

Overall it takes about 18 months for fractures to heal fully. The first six weeks is the fastest; during that time a scar is formed between the fracture fragments and stiffened with calcium deposits. This achieves about 50% of the eventual strength of the healed bone. After that there is a slower process of maturation and consolidation of the healing area of the bone until it has the strength and appearance of normal bone. One can normally use your healed foot for all normal activities including sports by about three months. However, there will still be some aching and swelling continuing with use but getting better for another year or more.

Although some foot fractures are treated in a [cast](#), brace, or special shoe, many need no support or protection. Toe fractures are often treated with buddy taping and weight bearing on the ball of the foot. You can get a shoe with a build up under the ball of the foot to keep

weight off the toe(s). If some form of support is needed it may be discontinued at six weeks if the fracture shows evidence of healing.

Physical therapy may be needed to start you off walking safely on crutches. However, there is little need for it until after the bone has healed. Once you can put weight through the healing area it may be helpful to have an exercise program to recover movement, strength and endurance.

Fractures that damage weight bearing joints in the foot may cause post traumatic **arthritis**. The intent of treatment is to limit this possibility but if the accident crushes or scrapes off the joint surface it does not recover or re-grow. In time the joint will become painful and stiff. Much more often the results of healing of a foot fracture are very good with complete return to normal function, work and sports being the norm.

Complications

What are the potential complications of these fractures?

Complications are rare problems that make recovery from the injury longer or more "complicated". The intent of treatment is to keep these complications as rare as possible; that is why orthopaedic surgeons pay so much attention to them.

Compartment Syndrome

Bleeding from broken bones or torn muscles deep inside the foot may cause swelling inside the muscle compartment. This compartment cannot enlarge much so the pressure may rise high enough to cut off circulation to the living muscle that occupies this region. Now this muscle too is at risk of dying and swelling more in turn. This dangerous sequence causes severe pain when the muscles are moved actively or passively. If the condition is diagnosed early, before any muscle death occurs then surgery to open up the muscle compartments will save the situation and allow the muscle to heal normally. The treating staff are very much on the look out for this problem, even though it is rare. The observations getting you to move your toes right after surgery make sure that a compartment syndrome is not developing or that it is detected right away.

Malunion

When a bone heals with a deformity and looks different from the normal shape it is said to be mal-united. Malunion of a joint surface leaves it rough and irregular. Movement of the joint may then be limited or painful and there is a higher risk that the joint would wear out. The assessment of the injury and the choice of treatment including operation looks at the likelihood and consequences of malunion. Malunion in areas of the bone outside the joint may be better tolerated even if the bone heals with a "kink" in it.

If poor alignment is identified before the bone has healed (mal-alignment) it may be possible and desirable to improve the position either by manipulation or by surgery. If the bone has truly healed (malunion) the position can only be improved by cutting the bone and re-aligning it. It may not be worth doing something as elaborate as that.

Post Traumatic Arthritis (PTA)

PTA means that the joint has become painful and stiff because it has worn out. The joint wears out because it was injured or because it healed with deformity (malunion). This arthritis is the same process as normal wear-and-tear arthritis of old age (**osteoarthritis**), but is accelerated by the damage to the joint. The pain may be treated with medication, weight loss, and restriction of activities that hurt. If it is too much to bear, the painful arthritic joint may be treated by surgery.

In the foot, the surgery recommended to treat an arthritic, painful joint is usually an *arthrodesis*, or *fusion* of the joint. To perform a fusion, the remaining joint surface is removed, the bone ends are placed together and held until bone grows across the gap making two bones into one. This surgery aims to replace a painful joint with an immobile but painless one. Since many of the joints in the foot do not have to move much anyway, this type of operation is successful in improving foot function after post traumatic arthritis.

Nonunion

Nonunion implies that the fracture has failed to heal even though more than enough time has passed. There are often two main reasons – poor mechanics and/or poor biological environment. The mechanics are poor if the fracture is still mobile or if it moves when weight is placed on the foot. Any attempts to heal are therefore disrupted. If there is an infection, or if the blood supply is poor then the body cannot produce the healing reaction. Nonunions are most common with the fractures that are caused by fatigue (stress fractures). Fractures of the neck of the talus and Jones fracture also have a bad reputations.

You feel a nonunion as an aching pain made worse by walking. Most often the symptoms are severe enough to require intervention. Sometimes the nonunion will heal if the foot is rested for long enough. More often, surgery is required to improve the mechanics and the biology of the situation. This is done by rigidly fixing the two parts of the fracture together (mechanics) and by inserting bone graft or some other biologically active material to improve the biology. Nonunions generally heal with treatment, but it can sometimes take more than one attempt.

Avascular Necrosis

With some fractures the blood supply of one of the bone fragments is cut off and part of the bone dies. Even if the fracture heals the dead bone may not support the weight of the body and will crush down. This can occur with fractures of the neck of the talus. The dome of the talus which supports the **ankle joint** loses the blood supply that comes up through the neck.

If the fracture heals, new living bone may eventually replace the dead bone by a process called "creeping substitution". New blood vessels grow into the area and bring in new living bone cells. These bone cells then make new bone using the dead bone as a scaffold on which the new bone grows. This a long process and weight bearing needs to be restricted or avoided while this occurs to prevent collapse of the dead bone. If the bone does not grow back, the bone supporting the joint will eventually give way and the joint will need surgery (usually fusion).

Loss of blood supply may also affect other foot fractures, particularly where there has been a massive crush injury. The Jones fracture may disrupt blood supply to the proximal part of the 5th Metatarsal. This may cause the failure of healing seen frequently in this injury.

Summary

There are a wide variety of foot fractures and foot fractures are quite common. Most of them heal with little or no intervention but fractures involving the main joints of the foot can be troublesome and require surgery.