

Journal of Point of Care Ultrasound

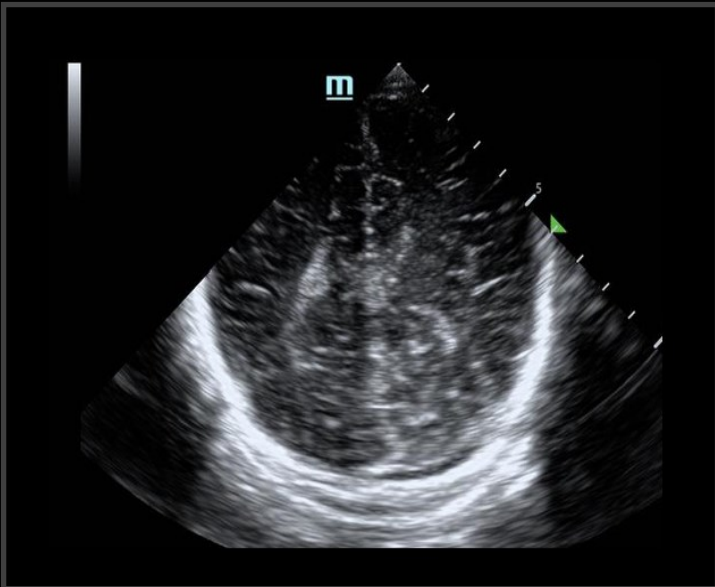
# POCUS Journal

EMERGENCY MEDICINE. INTERNAL MEDICINE. CRITICAL CARE. CARDIOLOGY. PRIMARY CARE. ANESTHESIOLOGY. PULMONOLOGY

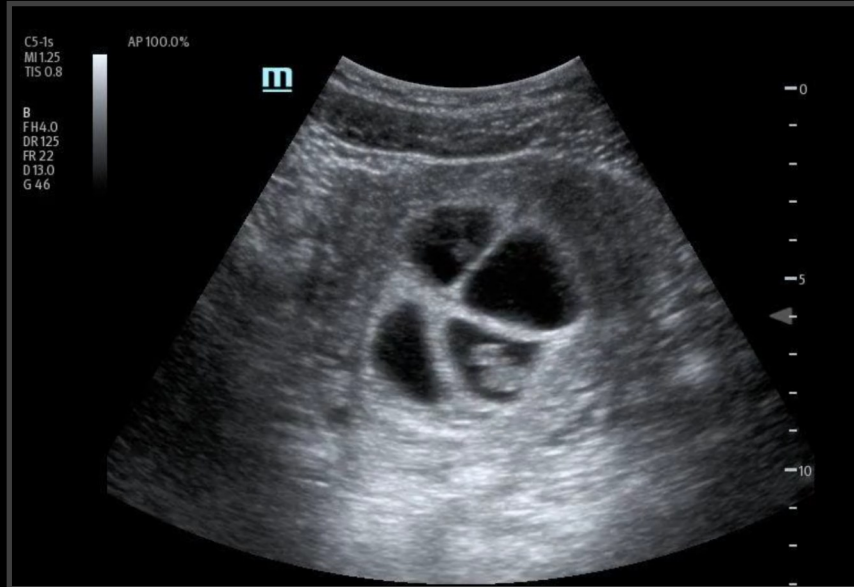Research

Education

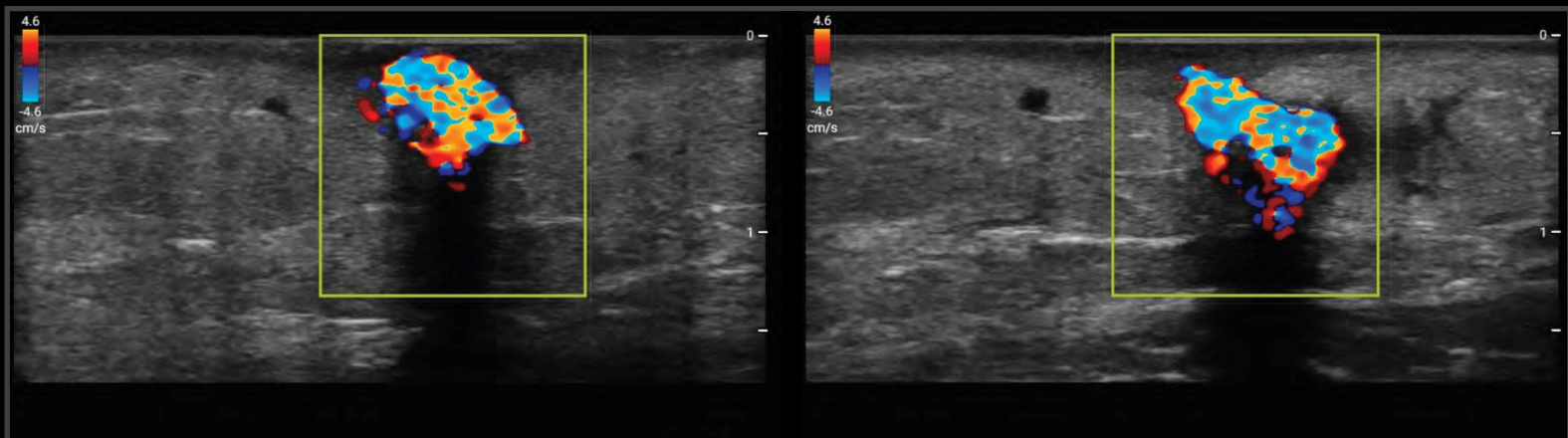
Practice



Davenport et al (pg. 165)



Vidal Pimentel (pg. 126)



Jerome et al. (pg. 142)

## Table of Contents | Volume 8 | Issue 02 | November 2023

---

### Commentary

**103** [Inside the November 2023 Issue](#)

Benjamin Galen, MD

### Letters

**104-105** [High Tech POCUS Education in Remote Environments: An App Review](#)

Jeremy J. Webb, MD; Chad Mosby, MD; John Stadnyk, MD; Michael Jones, PharmD

**106-108** [Rekindling the Relevance of Obstetrical Transvaginal POCUS: Overcoming Barriers to Ensure Patient-Centered Care](#)

Alexis Salerno, MD FPD-AEMUS; Resa E. Lewiss, MD

### Innovations in POCUS Curriculum

**109-112** [Obstetric-Focused POCUS Training for Medical Students](#)

Koral Cohen, BA, MS; Jennifer Kidd, MD, MPH; Emily Schiller, BS; Agata Kantorowska, MD; Wendy Kinzler, MD; Martin Chavez, MD

### Case File

**113-115** [Asteroid Hyalosis: A Mimicker of Vitreous Hemorrhage on Point of Care Ultrasound: A Case Report.](#)

Eniola C. Gros, MD; Lauren R. McCafferty, MD

**116-117** [The Use of Point of Care Ultrasound in Diagnosis of Peritonsillar Abscess](#)

Brian Kohen, MD; Melanie Perez, DO; Jheanelle McKay, MD; Rolando Zamora, MD; Curtis Xu, MD

**118-120** [Acute Type A Aortic Dissection Diagnosed by POCUS in a 29-year-old Man](#)

Vladimir Cárdenas López, MD; Pablo Blanco, MD

**121-123** [Cough Causing Abdominal Pain? A Rapid POCUS Diagnosis of Rectus Sheath Hematoma](#)

William Noel, MD; Brian B. Donahue, MD

**124-125** [The Importance of Serial POCUS Exams – Dual Pathologies in Play](#)

Rahul Nair, MD; Jonathan Zuo, BS; Ariel L Shiloh, MD

**126-128** [Optimizing Care for High-Risk Multiple Pregnancy with POCUS – A Case of Quadruplet Pregnancy Early Diagnosis](#)

Bernardo Vidal Pimentel, MD; Christopher Tsoutsoulas, MD; Kristin Lythgoe, MD; Frank Myslik, MD

**129-131** [Role of POCUS in Assessing an Acute Aortic Thrombus](#)

Zachary Boivin, MD; Emily Mensel, MD; Trent She, MD

---

## Table of Contents (con't)

---

### Case Report

**132-135 Renal Transplant Artery Stenosis and Kinking: An Unusual Association**

R. Haridian Sosa Barrios, MD, MSc; V. Burguera Vion, MD, MSc; E. Casillas Sagrado, MD; D. Villa Hurtado, MD; S. Jiménez Álvaro MD; I. Martín Capón, MD; M. Fernández Lucas, MD, PhD; Maite E. Rivera Gorrín, MD, PhD

**136-141 Troubleshooting Paracentesis Using POCUS**

Angelina Voronina, DO; Nachele Aurelien, MD; Edward Bergin, MD; Paula Roy-Burman, MD, MPH, DTM&H

**142-145 Twinkle Artifact Observed During POCUS of a Human Myiasis Caused by the Dermatobia hominis Botfly**

David Jerome, MD, MSc, CCFP(EM); Matthew Stacey, MD, CCFP(EM); Joseph Newbigging, MD, CCFP(EM), FCFP

### Research

**146-152 Dissemination of a Pediatric Musculoskeletal POCUS Scoring System via Virtual Education: A Proof-of-Concept Study**

Ysabella Esteban, MD MSc RhMSUS; Jackeline Rodriguez-Smith, MD MSc RhMSUS; Marie Tominna, DO; Amy Cassedy, PhD; Arthur B. Meyers, MD; Michael Henrickson, MD MPH RhMSUS; Tracy V. Ting, MD MSc RhMSUS; Patricia Vega-Fernandez, MD MSc RhMSUS

**153-158 A Prospective Cohort Study to Evaluate Needle Passes Using a Portable Ultrasound Device versus Traditional Landmark Approach for Epidural Anesthesia in a Busy Obstetric Tertiary Care Center**

Antonio Gonzalez Fiol, MD; Pedro Acevedo Rodriguez, MD; Xiwen, Zhao, PhD; Robert Gaiser, MD; Adriana Herrera, MD; Aymen Alian, MD

**159-164 Can Untrained Patients Perform Their Own Skin and Soft Tissue Ultrasound Examination by Teleguidance?**

Ammar Saati, MD; Arthur Au, MD; Aditi U. Joshi, MD MSc; Rebecca Davis, MD FACP; Frances Mae West, MD MS; Resa E Lewiss, MD

**165-169 Brain Point of Care Ultrasound in Young Children Receiving Computed Tomography in the Emergency Department: A Proof of Concept Study**

Stephanie R Davenport, MD, FRCPC; Nadya Ben Fadel, MD, FRCPC, FAAP; Jorge Davila MD, FRCPC; Nick Barrowman, PhD; Vid Bijelic, MSc; Allan E Shefrin, MD, FRCPC

**170-174 The Use of POCUS-Obtained Optic Nerve Sheath Diameter in Intracerebral Hemorrhage**

Alireza Nathani, DO; Shekhar A Ghamande, MD; Sarita Kambhampati, MD; Braden Anderson, DO; Matthew Lohse, MD; Heath D White, DO

---

## Table of Contents (con't)

---

### Research (con't)

- 175-183** [Handheld Lung Ultrasound to Detect COVID-19 Pneumonia in Inpatients: A Prospective Cohort Study](#)  
Thomas F. Heyne, MD, MSt; Kay Negishi, MD; Daniel S. Choi, MD; Ahad A. Al Saud, MBBS; Lucas X. Marinacci, MD; Patrick Y. Smithedajkul, MD; Lily R. Devaraj, MD; Brent P. Little, MD; Dexter P. Mendoza, MD; Efren J. Flores, MD; Milena Petranovic, MD; Steven P. Toal, MSc; Hamid Shokoohi, MD, MPH; Andrew S. Liteplo, MD; Benjamin P. Geisler, MD, MPH
- 184-192** [Association of Internal Medicine Point of Care Ultrasound \(POCUS\) with Length of Stay, Hospitalization Costs, and Formal Imaging: a Prospective Cohort Study](#)  
David M Tierney, MD, FACP; Terry K Rosborough, MD, FACP; Lynn M Sipsey, MD; Kai Hanson, MS; Claire S Smith, MS; Lori L Boland, MPH; Robert Miner, MD, FACP
- 193-201** [The Impact of a Handheld Ultrasound Device in a Rheumatic Heart Disease Screening Program in Ethiopia](#)  
Zachary P Kaltenborn, MD; Anteneh Zewde, MD; Jonathan D Kirsch, MD; Michelle Yates, MD; Katelyn M Tessier, MS; Eileen Nemec, RDCS FASE; Ronald A Johannsen, MD
- 202-211** [Critical Care Ultrasound Competency of Fellows and Faculty in Pulmonary and Critical Care Medicine: A Nationwide Survey](#)  
Mark H Adelman, MD; Himanshu Deshwal, MD; Deepak Pradhan, MD, MHPE, FCCP, ATSF
- 212-216** [Carotid Flow Time Compared with Invasive Monitoring as a Predictor of Volume Responsiveness in ICU patients](#)  
Tomislav Jelic, MD; Jordan Chenkin, MD
- 217-222** [Prevalence of Phantom Scanning in Cardiac Arrest and Trauma Resuscitations: The Scary Truth](#)  
Zachary Boivin, MD; Curtis Xu, MD; Donias Doko, MD; Meghan Kelly Herbst, MD; Trent She, MD
- 223-229** [Venous Excess Ultrasound \(VExUS\) Grading to Assess Perioperative Fluid Status for Noncardiac Surgeries: a Prospective Observational Pilot Study](#)  
Justin C. Magin, BS; Jacob R. Wrobel, BS; Xinming An, PhD; Jacob Acton, MD; Alexander Doyal, MD, MPH; Shawn Jia, MD; James Krakowski, MD; Jay Schoenherr, MD; Ricardo Serrano MD; David Flynn, MD; Duncan McLean, MBChB; Stuart A. Grant, MBChB
- 230-236** [Effectiveness of Ultrasound-guided versus Landmark-based Glucocorticoid Injection in the Treatment of First Carpometacarpal Joint Osteoarthritis](#)  
Shamma Ahmad Al-Nokhatha, MD; Sinead Maguire, MD; Luke Corcoran, MD; Neil Mac Eoin, MD; Richard Conway, MB BCh BAO, PhD, CCD, FRCPI; Ciaran Johnson, MB, FFR RCSI, FRCR (UK)
- Review**
- 237-242** [Exploring the Applicability of Pre-Anesthetic Cardiac POCUS in Unexpected Conditions: Could it be Helpful?](#)  
Rodolfo C Sabogal, MD
-

## Inside the November 2023 Issue

Dear Readers,

This is a very exciting time for POCUS Journal. As the world's leading point of care ultrasound journal, we remain free for both authors and readers. Our content brings the POCUS community together as we strive to showcase POCUS use by clinicians from a wide variety of fields in every possible clinical setting.

The era of being indexed on PubMed has attracted many high-quality submissions, from truly novel case reports to late breaking, practice-changing research on POCUS. The November issue houses such great scholarship from the around the world it is difficult to select the highlights. Tierney *et al.* (page 185-192) studied a prospective cohort of hospitalized patients and found that the availability and use of POCUS could reduce hospitalization cost, radiology cost, and chest x-rays. This is a major finding that provides concrete evidence for what POCUS users have believed for many years, but now finally have the proof to garner continued support for their POCUS programs. Saati, *et al.* (page 159-164) conducted a pilot study showing that patients can perform their own POCUS exams after brief teleguidance training.

This proof-of-concept has broad implications for the POCUS field as we evolve to use new technologies to find better ways to provide individualized care to patients in the future.

Alas, the November issue of POCUS Journal brings with it some bittersweet news. It will be the last issue for our founding managing editor Julia Herr, MSc, to whom all of us in the POCUS community owe a debt of gratitude. Her dedication to this journal and pursuit of excellence in publishing have brought the POCUS Journal platform to where it is today.

Please find our author guidelines here: <https://pocusjournal.com/author-guidelines/>

Sincerely,

Benjamin T. Galen, MD

Department of Medicine, Albert Einstein College of Medicine, Bronx, NY

Editor-In-Chief , POCUS Journal



Dr. Benjamin T. Galen, Editor-in-Chief, POCUS Journal

---

This work is licensed under a [Creative Commons Attribution 4.0 International License](https://creativecommons.org/licenses/by/4.0/).

Author(s) retain the copyright for their work. At the time of submission to POCUS Journal the author(s) grant the journal a limited and non revokable right to publish in the Journal under a [Creative Commons Attribution 4.0 International License](https://creativecommons.org/licenses/by/4.0/).

DOI: <https://doi.org/10.24908/pocus.v8i2.16970>

# High Tech POCUS Education in Remote Environments: An App Review

Jeremy J. Webb, MD<sup>1\*</sup>; Chad Mosby, MD<sup>1</sup>; John Stadnyk, MD<sup>1</sup>; Michael Jones, PharmD<sup>1</sup>

(1) LewisGale Medical Center, Emergency Medicine Residency Program, Salem VA, USA

## Letter

In recent years, the development of hand-held devices have intrigued POCUS enthusiasts due to improved affordability, portability, and ease of use. They also provide extra functionality for image storage and transmission for remote provider-to-provider communication and review. Due to these capabilities, portable ultrasound has found its use expanded to pre-hospital, wilderness, and austere settings, where cart-based machines and other imaging modalities are not an option [1]. As resident educators, it is exciting to see the enthusiasm our trainees have for POCUS, prehospital, and wilderness medicine. But how do we train the next generation of POCUS wielders for best use in remote environments?

Queue the “Awesome Ultrasound Simulator”, an iOS app created by Swedish physician Per Östergren (Figure 1) [2]. Advertising a method to “Train as you fight, and fight as you train”, the app boasts a unique way to teach POCUS image acquisition and image interpretation in any

environment. Currently, it costs \$14.99 USD and its use requires two iOS devices. One serves as the “remote” and the other as the “monitor”. There are several cases to choose from, with preloaded cine loops, but there is also the ability to upload your own clips as well. The student may use a dummy probe or an untethered hand-held ultrasound device to phantom-scan either a manikin or a live person. The instructor can then wirelessly trigger cine loops via the “remote” device to the “monitor” device based on the site scanned for the student to interpret (Figures 2 and 3).

We recently had the opportunity to trial this app during our residency’s annual Wilderness Medicine simulation day. The event was held outside of town, at the foot of the Blue Ridge Mountains, on a plot of land with lots of acreage and wooded forest. In addition to map and topography assessment, improvised splinting, field extrication, and tourniquet application, we included a station requiring use of a hand-held ultrasound device to clinch a diagnosis. Our scenario involved a hunter (manikin) who had fallen out of a tree-stand from a

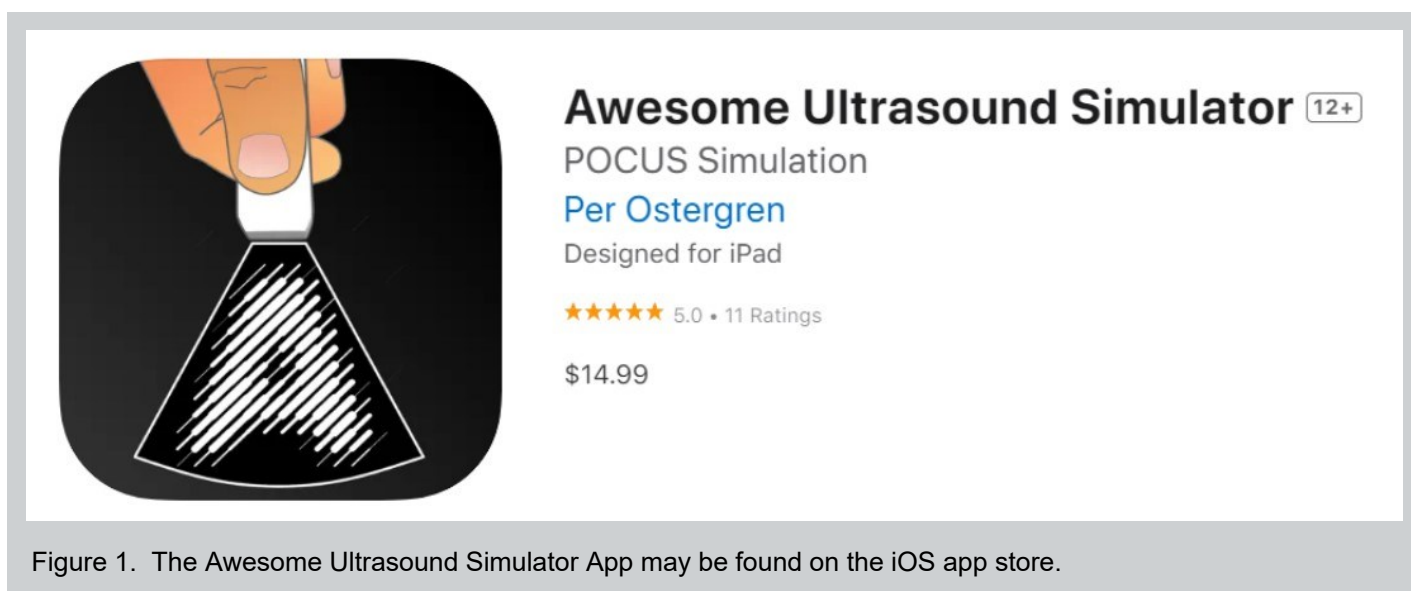

Figure 1. The Awesome Ultrasound Simulator App may be found on the iOS app store.

\*Corresponding Author: Jeremy J. Webb (email: [webb.jeremy@gmail.com](mailto:webb.jeremy@gmail.com))

This work is licensed under a [Creative Commons Attribution 4.0 International License](https://creativecommons.org/licenses/by/4.0/).

Author(s) retain the copyright for their work. At the time of submission to POCUS Journal the author(s) grant the journal a limited and non revokable right to publish in the Journal under a [Creative Commons Attribution 4.0 International License](https://creativecommons.org/licenses/by/4.0/).

DOI: <https://doi.org/10.24908/pocus.v8i2.16780>



Figure 2. The “Remote” device (iPhone™) may be used to trigger the display of normal or pathologic cine loops.

significant height with resultant chest wall trauma. Residents were required to perform a trauma survey and identify a pneumothorax through identification of lack of lung sliding and a lung point on simulated POCUS assessment. Not only could residents phantom-scan the chest wall and lung, but they could perform a brief cardiac exam and a FAST examination as well.

The Awesome Ultrasound Simulator worked as advertised and provided a realistic feel to the scenario. There is a small learning curve for uploading clips to the device, and when using in a remote location you must ensure adequate battery charges on your devices. The app leans heavy on image interpretation over image acquisition, although instructors may withhold triggering of a cine loop until appropriate probe positioning by the trainee occurs. All in all, our department found tremendous use in this easy to use and affordable application. The ability to simulate real pathology and promote out-of-hospital use of POCUS was both impressive and fun. We hope to continue to use the app in efforts to teach high tech diagnosis in remote environments, and maybe you will too.



Figure 3. Emergency Medicine residents performing an E-FAST exam in the field, interpreting images on the “Monitor” device (iPad™). An unconnected Clarius handheld device is used as the dummy probe.

## Disclosures

The authors have no conflicts of interest to share. We share no relationship, financial or otherwise, with the “Awesome Ultrasound Simulator” application or its creator. The opinions above are our own.

## References

1. Canepa CA, Harris NS. Ultrasound in Austere Environments. *High Alt Med Biol.* 2019 Jun;20(2):103-111. doi: 10.1089/ham.2018.0121. Epub 2019 May 21. PMID: 31112050.
2. Per Östergren. (2020). Awesome Ultrasound Simulator (Version 3.6.1) [Mobile app]. iOS App Store. <https://apps.apple.com/us/app/awesome-ultrasound-simulator/id1064416294>

# Rekindling the Relevance of Obstetrical Transvaginal POCUS: Overcoming Barriers to Ensure Patient-Centered Care

Alexis Salerno, MD FPD-AEMUS<sup>1\*</sup>; Resa E. Lewiss, MD<sup>2</sup>

- (1) Assistant Professor of Emergency Medicine, Department of Emergency Medicine, University of Maryland School of Medicine  
(2) Professor of Emergency Medicine, The University of Alabama at Birmingham

## Letter

The transvaginal pelvic point of care ultrasound (POCUS) examination remains a patient-centered and relevant examination. Since 2008, emergency medicine physicians are required to learn, perform, and interpret POCUS examinations to deliver safe and patient-centered diagnostic and procedural care. Pelvic POCUS is one of these core applications in the emergency physician scope of practice. A pelvic POCUS examination seeks to answer the focused question, “Is there an intrauterine pregnancy (IUP)” and risk stratifies the patient when ectopic pregnancy is a clinical concern [1]. Transvaginal ultrasound (TVUS) is necessary beyond transabdominal POCUS as it enhances the image quality of the uterus, ovaries and adnexal complexes. It can also assist providers in obtaining further clinically important information.

In a 2006 survey, 25% of community-based emergency departments reported having neither an ultrasound technologist available in the hospital at night nor a radiologist available to read the examinations performed [2]. Consequently, most emergency physicians are responsible for and should be able to execute a TVUS examination for safe patient care. Not making a timely diagnosis in a patient with symptoms suggestive of an ectopic pregnancy can be life-threatening [3]. The pelvic POCUS examination is especially relevant to emergency physicians who practice outside of a tertiary academic medical center and without 24-hour radiology-based ultrasound services. This represents the majority of emergency physicians in practice. A 2017 survey of emergency physicians who completed the 2017 ConCert examination found that 76.3% of participants identified as community emergency physicians, while 19.6% identified as academic emergency physicians [4].

Despite the established role of the pelvic POCUS examination in emergency medicine patient care practice, we are increasingly concerned that residents are not being taught the TVUS technique and faculty are not using this diagnostic imaging test for patient-centered care. A 2020 Society for Clinical Ultrasound Fellowships survey asked directors to report on the use of TVUS by faculty, fellows, and residents: Shockingly, only 20% of emergency physicians used TVUS *regularly*. 58% reported using TVUS *occasionally* [5].

We believe there are multiple factors contributing to what we perceive as a decline in performing this examination. 1) Better POCUS hardware: there is an improved quality in transabdominal imaging making TVUS considered less necessary. 2) Few training opportunities: emergency medicine residents find limited training opportunities when working with attendings who do not perform TVUS and when patients are preferentially transported to the radiology for TVUS. 3) Infection control measures: POCUS leaders anecdotally note the increasing surveillance in transducer cleaning and sterilization practices as a deterrent to performing a TVUS examination [6].

## TVUS Still Offers Improved Imaging

We believe that TVUS continues to be relevant, important, and patient-centered to emergency medicine practice. The TVUS examination offers improved image quality over the transabdominal technique. The TVUS examination identifies early pregnancy structures one week earlier than a transabdominal examination with the use of a curvilinear transducer in a patient with a full bladder [7]. Logistically, the TVUS transducer is higher frequency. We acknowledge that ultrasound imaging has improved over the last decade, and in some instances the

\*Corresponding Author: Dr. Alexis Salerno (email: alexis.salerno@som.umaryland.edu )

This work is licensed under a [Creative Commons Attribution 4.0 International License](https://creativecommons.org/licenses/by/4.0/).

Author(s) retain the copyright for their work. At the time of submission to POCUS Journal the author(s) grant the journal a limited and non-revokable right to publish in the Journal under a [Creative Commons Attribution 4.0 International License](https://creativecommons.org/licenses/by/4.0/).

DOI: <https://doi.org/10.24908/pocus.v8i2.16855>



high frequency linear transducer can identify an IUP [8]; however, transabdominal imaging is not equivalent to TVUS. One cohort study of over 500 patients showed that EP performed TVUS helped diagnose a viable IUP in 50% of patients with an inconclusive curvilinear transabdominal ultrasound [9]. As a result, the ED length of stay was 3 hours for patients with emergency physician performed TVUS examination, versus 6 hours for patients with a technician in radiology performed TVUS examination [9]. The image quality improvement by TVUS may be greater in patients with high BMI, abdominal surgical scars, or poor visualization of structures due to bowel gas.

### TVUS is a Teachable Skill

With increased experience and training in TVUS, emergency physicians can determine the presence or absence of an IUP. One study showed that emergency medicine residents require a relatively short training period to learn and competently perform a TVUS [10]. After a 1-hour didactic session, a written examination, and 10 supervised studies, the residents were able to perform a TVUS examination to evaluate for IUP with good concordance with the ED director of ultrasound [10]. Learners continued to benefit from performing a greater number of TVUS exams and felt confident after performing 25 examinations [11].

To help medical educators ensure that TVUS remains a procedure that residents learn, we suggest creating training opportunities. The opportunities to learn TVUS are many: direct patient care in the emergency department, a rotation on the obstetrics-gynecology service, a rotation in radiology, and of course the emergency medicine POCUS rotation. Simulation centers that offer both static and dynamic pelvic ultrasound simulators are excellent education resources. Simulated examinations offer many advantages, including competency assessments and the opportunity for direct feedback [12]. One study showed that simulation based TVUS training not only increased clinician comfort in performing the examination and decreased the duration of live TVUS examinations, but also showed that residents who had simulation training had decreased patient discomfort scores [12].

### TVUS Transducers Can Be Maintained

There has been an increased focus on infection control guidelines by national organizations, such as the Joint Commission on Accreditation of Healthcare Organizations (JCAHO), specifically on the use of TVUS. We believe that if radiology and gynecology staff are able to follow the cleaning protocol, then certainly the emergency department can too. Cleaning and disinfecting the TVUS requires high level disinfection

(HLD) [13]. We acknowledge that the education and maintenance for the TVUS transducer may be perceived as cumbersome and difficult to maintain, yet there are many solutions. This could be performed in the emergency department where team members learn the HLD protocols. This requires upfront resource investment and then the process should be easy to follow [14]. Alternatively, some EDs, which are unable to support a HLD system can share resources with the Department of Radiology or the hospital central sterilization department. Further research on cost/resource utilization of the TVUS may help overcome this barrier.

In conclusion, the pelvic TVUS ultrasound examination is an easy to learn, patient-centered examination. While TVUS is being infrequently taught and performed, its significant benefits should prompt research into how this technique can be incorporated into bedside practice.

### Disclosures

This work has not been presented at meetings, no grant support was received. REL serves on the Medical Advisory Board for EchoNous, on the board of PURE, on the board of Society for Clinical Ultrasound Fellowships (SCUF), and previously received equipment support from Phillips Healthcare and Butterfly Network. Otherwise, there are no disclosures of relevant commercial interests.

### References

1. Emergency Ultrasound Imaging Criteria Compendium. *Ann Emerg Med.* 2016;68(1):e11-e48. doi:10.1016/j.annemergmed.2016.04.028
2. Moore CL, Molina AA, Lin H. Ultrasonography in Community Emergency Departments in the United States: Access to Ultrasonography Performed by Consultants and Status of Emergency Physician-Performed Ultrasonography. *Ann Emerg Med.* 2006;47(2):147-153. doi:10.1016/j.annemergmed.2005.08.023
3. Adhikari S, Blaivas M, Lyon M. Diagnosis and management of ectopic pregnancy using bedside transvaginal ultrasonography in the ED: a 2-year experience. *Am J Emerg Med.* 2007;25(6):591-596. doi:10.1016/j.ajem.2006.11.02
4. Marco CA, Wahl RP, Thomas JD, et al. Emergency medicine practice environment and impact on concert examination performance. *Am J Emerg Med.* 2019;37(5):859-863. doi:10.1016/j.ajem.2018.07.055
5. SCUF – Society of Clinical Ultrasound Fellowship. Accessed December 6,2022. <http://eusfellowships.com>
6. O'Connor TP, Garton N, Jones C, Estephan M, Lu M, Adler D. Emergency physician utilization of transvaginal ultrasound after initiation of revised sterilization protocol. *Am J Emerg Med.* 2019 Apr;37(4):789-791. doi: 10.1016/j.ajem.2018.08.077.
7. Jain K, Hamper U, Sanders R. Comparison of transvaginal and transabdominal sonography in the detection of early pregnancy and its complications. *American Journal of Roentgenology.* 1988;151(6):1139-1143. doi:10.2214/ajr.151.6.1139
8. Çelik A, Yazıcı MM, Oktay M. The impact of high-frequency linear transducer on the accuracy of pelvic ultrasound in early pregnancy pelvic pain and bleeding. *Am J Emerg Med.* 2022;61:105-110. doi:10.1016/j.ajem.2022.08.045
9. Panebianco NL, Shofer F, Fields JM, et al. The utility of transvaginal ultrasound in the ED evaluation of complications of first trimester pregnancy. *Am J Emerg Med.* 2015;33(6):743-748. doi:10.1016/j.ajem.2015.02.023

10. MacVane CZ, Irish CB, Strout TD, Owens WB. Implementation of Transvaginal Ultrasound in an Emergency Department Residency Program: An Analysis of Resident Interpretation. *J Emerg Med.* 2012;43(1):124-128. doi:10.1016/j.jemermed.2011.05.099

11. Derr C, Shteyman A, Jackson SA, et al. Determination of Endovaginal Ultrasound Proficiency and Learning Curve Among Emergency Medicine Trainees. *Journal of Ultrasound in Medicine.* 2022;41(7):1741-1752. doi:10.1002/jum.15857

12. Tolsgaard MG, Ringsted C, Rosthøj S, et al. The Effects of Simulation-based Transvaginal Ultrasound Training on Quality and Efficiency of Care. *Ann Surg.* 2017;265(3):630-637. doi:10.1097/SLA.0000000000001656

13. Guideline for Ultrasound Transducer Cleaning and Disinfection. *Ann Emerg Med.* 2018 Oct;72(4):e45-e47. doi: 10.1016/j.annemergmed.2018.07.035. PMID: 30236343.

14. Shokoohi H, Armstrong P, Tansek R. Emergency department ultrasound probe infection control: challenges and solutions. *Open Access Emergency Medicine.* Published online January 2015:1. doi:10.2147/OAEM.S50360



UT Health  
San Antonio

17<sup>th</sup> Point-of-care  
Ultrasound

# Workshop

**CLICK HERE TO REGISTER NOW!**

**January 18-19, 2024 ~ Austin, Texas**  
*October 5-6, 2023 ~ Seattle, Washington - SOLD OUT!*

# Obstetric-Focused POCUS Training for Medical Students

Koral Cohen, BA, MS<sup>1</sup>; Jennifer Kidd, MD, MPH<sup>1,2,3</sup>; Emily Schiller, BS<sup>1</sup>; Agata Kantorowska, MD<sup>1,2</sup>; Wendy Kinzler, MD<sup>1,2</sup>; Martin Chavez, MD<sup>1,2</sup>

(1) NYU Grossman School of Medicine, Mineola, NY, USA

(2) Department of Obstetrics and Gynecology, NYU Langone Health-Long Island, Mineola, NY, USA

(3) Donald and Barbara Zucker School of Medicine at Hofstra/Northwell, Northwell Health, Hempstead, NY, USA

## Introduction

Point of care ultrasound (POCUS) is rapidly expanding throughout the United States. Due to its ability to quickly and accurately diagnose and guide therapy for critical conditions, POCUS is becoming routine in many specialties, with established guidelines in fields such as emergency medicine and critical care [1–3]. For example, a study entitled “Ultrasound Integration in Undergraduate Medical Education: Comparison of Ultrasound Proficiency Between Trained and Untrained Medical Students” initiated an Emergency Medicine POCUS curriculum for first-year medical students that showed an increase in ultrasound capability [4]. In short, as POCUS becomes more common practice, medical schools are beginning to implement POCUS training into their undergraduate medical education; studies from these institutions demonstrate that implementing a formal ultrasound curriculum into preclinical medical education significantly increases medical students’ POCUS capabilities [4,5] and assisted in their understanding and learning of anatomy [6,7].

To the authors’ knowledge, there has not been a study that focused on integrating Obstetrics and Gynecology (OBGYN) POCUS curriculum within the medical school’s curriculum. An OBGYN Ultrasound Lecture Series was created for Ob/Gyn residents and was designed by the American Institute of Ultrasound Medicine (AIUM) [9]. The 32 videos offered by this Lecture Series cover topics within OBGYN, Obstetric Imaging, and Gynecologic Imaging [9]. These educational, in-depth videos may not be easily understandable/digestible for beginners in this field. They are very detailed and provide an extensive level of knowledge for residents. However, this results in a gap between medical students with limited knowledge and curricula with an extensive knowledge base. There are no widely available curricula to serve as an

introduction for medical students of obstetrics imaging to assist in the closure of this educational gap.

We describe a beginner-level, student-led para-curricular POCUS obstetric imaging workshop on obstetric imaging led by medical students. This workshop and curriculum were made assuming that students have no prior experience with obstetric imaging and, in general, have limited experience with ultrasound. In addition, the assumption was also made that these medical students have had limited clinical experience. Hence, this workshop should be educationally fit for any medical student level and aimed at beginners in obstetric imaging. This workshop also acknowledges the increasing importance of POCUS proficiency in medical professionals. Still, many medical schools struggle to find time in their curriculum and trained faculty to implement POCUS training programs [8]. At our institution, students have limited exposure to POCUS throughout a 3-year, accelerated curriculum. Students are eager to gain skills in POCUS, which led to a student-led initiative.

## Curricula

At our institution, medical students complete a 3-year accelerated curriculum. During year 1, the preclinical year, students attend radiology lectures that complement an organ-system-based curriculum twice weekly. During these radiology lectures, students mainly review various imaging modalities, including x-ray, CT, and ultrasound of adults, to understand the anatomy and pathology of multiple organs such as gallbladder, thyroid, testicles, and vasculature. First-year students do not learn how to utilize ultrasound probes or POCUS devices. POCUS is available for second-year students. It is introduced to second-year medical students participating in clinical rotations (MS2 students) through a one-day POCUS workshop focusing on venous compression ultrasound,

---

\*Corresponding Author: Koral Cohen (email: koralcohen81@gmail.com)

This work is licensed under a [Creative Commons Attribution 4.0 International License](https://creativecommons.org/licenses/by/4.0/).

Author(s) retain the copyright for their work. At the time of submission to POCUS Journal the author(s) grant the journal a limited and non revokable right to publish in the Journal under a [Creative Commons Attribution 4.0 International License](https://creativecommons.org/licenses/by/4.0/).

DOI: <https://doi.org/10.24908/pocus.v8i2.16316>

lung assessment, and the Focused Assessment with Sonography in Trauma (FAST) exam. There is no formal POCUS training on obstetric ultrasound in the three-year curriculum. In addition, there is no formal POCUS training integrated into any clinical rotations. However, throughout medical school's second and third years, students may be exposed to POCUS in various settings throughout their clinical rotations. For example, during the 6-week Obstetrics and Gynecology rotation, Phase 2 medical students utilize ultrasound frequently for fetal assessment to detect fetal head. Still, there have been no formal curricula that cover how to do so.

At our three-year accelerated medical school, medical students interested in pursuing OBGYN residency training recognized the benefit of early training in POCUS. They organized a series of POCUS workshops utilizing a handheld ultrasound device. Medical students interested in applying to an OBGYN residency met at the Maternal Fetal Medicine (MFM) sonography unit. This workshop was outside scheduled didactic teaching, and clinical rotation responsibilities and participation were voluntary. Before the first workshop, students were provided with an obstetric POCUS primer. This short video lecture outlined ultrasound science and the advantages of POCUS technology. The lecture concluded with the specific knowledge addressed during the obstetric ultrasound workshop: detect a fetal heart rate, confirm fetal head location, identify placental location, and identify a maximum vertical pocket of amniotic fluid. In addition, before the workshop, students completed a workshop gauging their interests in ultrasound training, career/specialty selection, prior experience with ultrasounds, and comfort and understanding of identifying specific structures (Table 1).

The POCUS workshop was a 60-minute, hands-on, skills-based session led by maternal-fetal medicine faculty. Students learned four core skills that included how to 1) detect a fetal heart, 2) confirm fetal head location, 3) identify placental location, and 4) identify a maximum vertical pocket of amniotic fluid (Figure 1). Six medical students participated in this workshop. The faculty asked patients if they were interested in participating in medical student education. Patients had the teaching part of their ultrasound after the scheduled care portion was completed. Each student had approximately 6 minutes of personal hands-on scanning under the direct observation of the MFM faculty, allowing for real-time feedback and instruction. Three months later, the students that participated in the workshop, along with an additional six students that did not attend the workshop, performed fetal POCUS in the labor and delivery triage as a follow-up from the original workshop. Students were compared on their ability to perform all four core skills within five minutes.

Table 1. Survey administered prior to workshop

	1 = Disagree	2 = Neutral	3 = Agree
I feel confident in my understanding of how ultrasound works.	4	3	1
I feel enthusiastic about the use of point-of-care ultrasound.	0	2	6
I feel comfortable detecting fetal heart rate.	6	1	1
I feel comfortable detecting fetal head location.	6	1	1
I feel comfortable detecting placenta location.	6	1	1
I feel comfortable detecting maximum vertical pocket of amniotic fluid.	6	2	0
I feel comfortable triaging labor and delivery patients.	6	1	1
I know how to apply proper probe techniques to a fetal ultrasound scan.	6	1	1
I feel comfortable performing a fetal ultrasound scan.	6	2	0
I intend to continue learning about ultrasound and refining my skills.	0	0	8

### Follow up

The initiative of implementing ultrasound workshops in medical schools through student-led interest groups was a success, with 100% attendance (8 students) from the OBGYN interest group reported. Six of the students were first-year medical students, and 2 of the students were second-year medical students. Six of the students were solely interested in pursuing OBGYN residencies, and 2 of the students were exploring OBGYN and one other field in medicine, either Internal Medicine or Surgery. Four of the students reported some prior experience with ultrasound, and 4 of the students reported no prior experience with ultrasounds. Two of the students had completed the OBGYN rotation (Phase 2), and all eight students had completed their Endocrine and Reproduction course (Phase 1). Students completed a survey before the workshop. Six out of the eight students

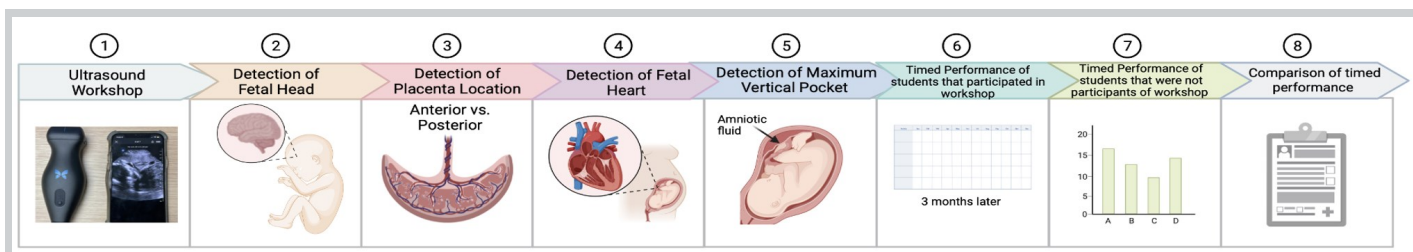


Figure 1. Summary of Methods.

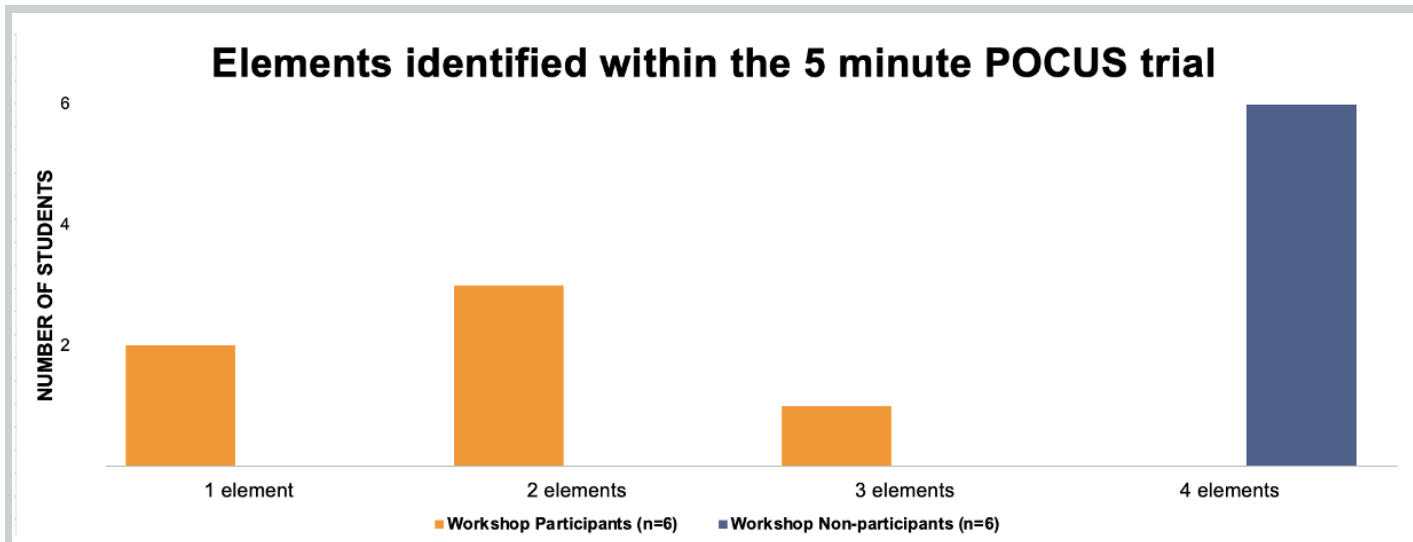


Figure 2. Summary of workshop results. Comparison of students, by participation status, in completing imaging elements identified during time constraint.

agreed that they felt “enthusiastic about the use of POCUS,” and two reported neutral regarding the statement. 100% of students reported that they intend to continue learning about ultrasound and refining their skills. Six of the eight students said they felt uncomfortable detecting fetal heart rate, fetal head location, placental location, and maximum vertical pocket before the workshop (Table 1).

Six out of the eight students that participated in the workshop were assessed three months later. An MFM fellow timed the student while the student was tasked with identifying the four imaging skills they were taught in the workshop on patients in the Labor and Delivery triage. Patients consented to this before medical students utilized the POCUS device. The average time it took the students who completed the workshop to identify all four elements was 2 minutes and 36 seconds. The six students that served as controls were given five minutes to recognize the four imaging skills, and none could complete all four skills in the five minutes. Two out of 6 students identified one element, and 1 out of the six identified three elements (Figure 2).

## Discussion

The results of our study show that the creation of POCUS workshops is an accessible and effective way of retaining obstetric POCUS skills. Students that participated in the workshop were not only able to identify the four elements but were also able to efficiently identify them within a time constraint. In contrast, students who did not participate in the workshop could not locate all of the imaging elements within the time constraint. Initiating and implementing student-driven ultrasound workshops can be an effective way of providing valuable hands-on experiences to students. Additional POCUS workshops during the Endocrine and Reproduction course for first-year medical students in Phase 1 of the medical school’s curriculum and during the orientation of OBGYN rotation in Phase 2 will take place during the 2023-2024 academic year. These planned workshops will occur similarly to our original approach with additional feedback from students to continue expanding and improving this POCUS obstetric curriculum.

Student-initiated workshops introducing POCUS training early in medical school can serve as a helpful tool, particularly for students interested in OBGYN

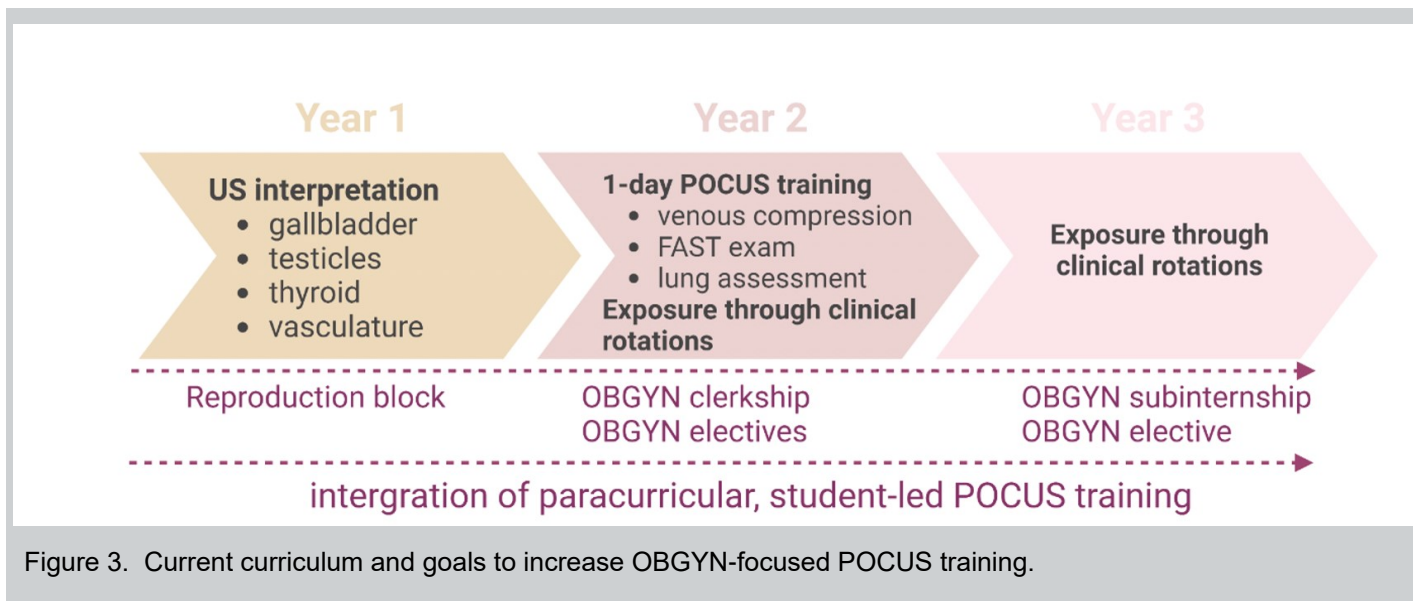


Figure 3. Current curriculum and goals to increase OBGYN-focused POCUS training.

residencies. Future workshops will help further integrate POCUS education across preclinical and clinical years. Ultrasound exposure is integrated into our institution's three-year curriculum. In the first year, students learn to interpret ultrasound images of the gallbladder, testicles, thyroid, and vasculature during an organ system-based preclinical year. However, this is from traditional ultrasound machines and not with the utility of POCUS. In year 2, students receive a 1-day POCUS training in venous compression ultrasound, lung assessment, and the FAST exam and may get exposure throughout the clinical rotations. Paracurricular, student-led obstetric-focused POCUS workshops could be integrated into a medical student curriculum to increase familiarity with POCUS in obstetric care.

Integration of ultrasound training and POCUS training is vital in medical education to par with current technology and educate students to integrate this technology into clinical care. Integrating ultrasound training into student-led interest groups can be an excellent way for students and faculty to collaborate and create learning objectives aligned with students' interests. In addition, ultrasound workshops can empower students to advance POCUS knowledge and utility across rotations. This early POCUS exposure in medical education could improve future training as these students transition to residents. Student-led initiatives such as this obstetric-focused POCUS workshop are supplementing medical student curricula. This could transition to a formalized portion of the medical student curricula to address potential gaps in ultrasound knowledge for a more graduated learning process. This knowledge provides priming for resident-level education and competency. By participating in these workshops, medical students increase their obstetric skills for residency and familiarity with the obstetric use of POCUS.

### Disclosures

Dr. Chavez has engaged in consulting work for Samsung Corporation. The authors report no additional disclosures relevant to this article.

### References

- Weber MD, Lim JKB, Ginsburg S, Conlon T, Nishisaki A. Translating Guidelines into Practical Practice Point-of-Care Ultrasound for Pediatric Critical Care Clinicians. *Crit Care Clin*. 2022;
- Ultrasound Guidelines: Emergency, Point-of-Care and Clinical Ultrasound Guidelines in Medicine. *Ann Emerg Med*. 2017;69(5):e27–54.
- Stewart DL, Elsayed Y, Fraga MV, Coley BD, Annam A, Milla SS, RADIOLOGY COFANASO, Eichenwald E, Guillory C, Hand I, Hudak M, Kaufman D, Martin C, Lucke A, Parker M, Pramanik A, Wade K, Jancelewicz T, Surgery AS on, Narvey M, Society CP, Miller R, Gynecologists AC of O and, Barfield RW, Prevention C for DC and, Grisham L, Nurses NA of N, Couto J, 2021–2022 S on REC, Otero HJ, Acharya PT. *Pediatrics*. 2022;150(6).
- Dinh VA, Dukes WS, Prigge J, Avila M. Ultrasound Integration in Undergraduate Medical Education: Comparison of Ultrasound Proficiency Between Trained and Untrained Medical Students. *J Ultras Med*. 2015;34(10):1819–24.
- Oberoi MK, Perera NC, Reynaga J, Yoo BR, Miller CC, Lockhart W, Entezampour M, Friedman L. Students Teaching Students: Student-Led Ultrasound Curriculum in Medical School Education. *Cureus*. 2021;13(11):e19332.
- Ireson M, Warring S, Medina-Inojosa JR, O'Malley MT, Pawlina W, Lachman N, Narula J, Bhagra A. First Year Medical Students, Personal Handheld Ultrasound Devices, and Introduction of Insonation in Medical Education. *Ann Glob Health*. 2019;85(1):123.
- Rempell JS, Saldana F, DiSalvo D, Kumar N, Stone MB, Chan W, Luz J, Noble VE, Liteplo A, Kimberly H, Kohler MJ. Pilot Point-of-Care Ultrasound Curriculum at Harvard Medical School: Early Experience. *West J Emerg Medicine Integrating Emerg Care Popul Heal*. 2016;17(6):734–40.
- Dinh VA, Fu JY, Lu S, Chiem A, Fox JC, Blaivas M. Integration of Ultrasound in Medical Education at United States Medical Schools. *J Ultras Med*. 2016;35(2):413–9.
- Obstetric Ultrasound. <https://www.aium.org/uls/lectures.htm>. Accessed February 3, 2023.

# Asteroid Hyalosis: A Mimicker of Vitreous Hemorrhage on Point of Care Ultrasound: A Case Report

Eniola C. Gros, MD<sup>1\*</sup>; Lauren R. McCafferty, MD<sup>1</sup>

(1) Department of Emergency Medicine, University Hospitals Cleveland Medical Center/Case Western Reserve University School of Medicine

## Abstract

Ocular point of care ultrasound (POCUS) can help make timely recognition of multiple emergent ocular conditions and differentiate these from more benign conditions. While asteroid hyalosis (AH) is benign, it can easily mimic the more potentially serious vitreous hemorrhage on ocular POCUS, as both consist of numerous echogenic opacities within the vitreous with a classic “washing machine” appearance with eye movement. However, asteroid hyalosis particles tend to be more discrete, hyperechoic, scintillating, and seen throughout the vitreous. Knowledge of this mimic and ability to recognize the subtle sonographic differences can help differentiate these disease processes, which can influence management and potentially disposition.

## Background

Point of care ultrasound (POCUS) is often utilized in the emergency department (ED) to quickly evaluate for several potentially vision-threatening pathologies. This includes, but is not limited to, retinal detachment (RD), foreign body, lens dislocation, posterior vitreous detachment (PVD), and vitreous hemorrhage (VH) [1,2]. A potential mimicker of VH in particular is asteroid hyalosis, a relatively rare, benign degenerative condition that often has little impact on vision [3,4]. Similar to VH, POCUS findings of asteroid hyalosis consist of mobile hyperechoic opacities within the vitreous [5-7]. Being able to recognize the subtle differences between the two is important, as the management of each is quite different.

We present a case of a patient who presented to the ED for painless monocular vision changes. Ocular POCUS revealed numerous distinct, mobile, hyperechoic opacities throughout the vitreous and was initially thought to be VH. However, on closer inspection and with ophthalmologic evaluation, the patient was diagnosed with asteroid hyalosis and did not require additional ophthalmologic management.

## Case Report

The patient was a fifty-nine year-old female with a history of hypertension, hyperlipidemia, coronary artery disease

status post percutaneous coronary intervention, chronic obstructive pulmonary disease and fibromyalgia who presented to the ED with right-sided facial pain and intermittent blurred vision. She stated her symptoms began gradually while grocery shopping the prior evening and had been persistent since. She denied a headache, foreign body sensation, flashes of light, floaters, double vision, vision loss, pain with extraocular movements, or abnormalities of the surrounding skin.

Physical examination revealed pupils that were equal, round, mid-range in size, and reactive to light bilaterally. Extraocular movements were intact. There were no keratotic lesions, hyphema, or conjunctival injection noted. There was tenderness to light touch over the right periorbital region, cheek and nose without any skin lesions, erythema, or swelling. Intraocular pressure was within normal limits. Visual acuity was 20/40 in the right eye, 20/30 in the left eye. Intraocular pressure was within normal limits. A neurologic examination further revealed fluent speech, normal strength and sensation in all four extremities, and no facial asymmetry.

On POCUS of the right eye, there was no evidence of RD. However, within the vitreous there were numerous hyperechoic foci which were mobile with a dynamic exam. While it had the classic “washing machine”[5] appearance of VH, the particles were more echogenic and distinct than what is typically seen with VH (Figure 1,

---

\*Corresponding Author: Dr. Eniola Gros (email: eniola.gros@uhhospitals.org)

This work is licensed under a [Creative Commons Attribution 4.0 International License](https://creativecommons.org/licenses/by/4.0/).

Author(s) retain the copyright for their work. At the time of submission to POCUS Journal the author(s) grant the journal a limited and non revokable right to publish in the Journal under a [Creative Commons Attribution 4.0 International License](https://creativecommons.org/licenses/by/4.0/).

DOI: <https://doi.org/10.24908/pocus.v8i2.16391>

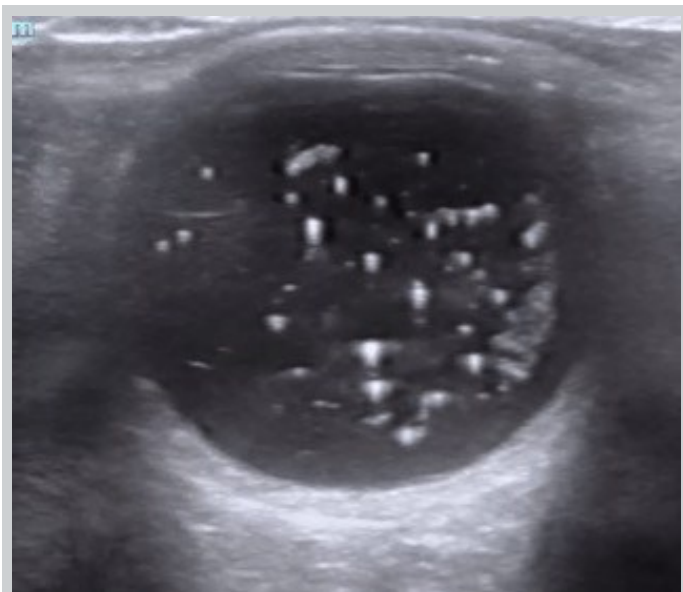


Figure 1. Transverse view of the affected eye demonstrates distinct hyperechoic opacities within the vitreous body consistent with asteroid hyalosis.

Video S1). Ophthalmology was consulted given the patient's presenting symptoms and abnormal ocular ultrasound findings. Dilated fundoscopic examination confirmed the diagnosis of asteroid hyalosis. No other acute pathology was noted, other than possible early herpes zoster ophthalmicus. Outpatient management was deemed appropriate, so she was discharged home with a prescription for antivirals and advised to follow up with ophthalmology later that week. She did not require follow up for the asteroid hyalosis alone.

### Discussion

Asteroid hyalosis, named for resembling "stars in a night sky", is a benign degenerative ocular condition resulting in calcium, phosphate, and lipid deposits varying in size within the vitreous body [3]. Increasing age and male sex are the most significant risk factors for asteroid hyalosis [4]. Systemic comorbidities, such as diabetes, hyperlipidemia, and hypertension, have been reported to be associated with asteroid hyalosis [8]; however, when adjusted for age and sex, this association appears to lack significance [9].

Asteroid hyalosis is rarely symptomatic unless severe or if concurrent ocular pathology, including cataracts, vitreous hemorrhage, or diabetic retinopathy, is present. While often an incidental finding, asteroid hyalosis can confound retinal or fundoscopic imaging due to its numerous vitreous opacities [3,8]. While often detected by a comprehensive ophthalmologic examination, asteroid hyalosis can also be detected with POCUS, a readily available diagnostic tool for emergency physicians.

A POCUS assessment for asteroid hyalosis is similar to that of RD, PVD, or VH, which is well described in the ultrasound literature [1,3-5,10,11]. Visualization of these conditions is often optimized when the gain is increased. Asteroid hyalosis most closely mimics vitreous hemorrhage (Figure 2), as both consist of numerous echogenic opacities within the vitreous with a classic "washing machine" appearance with eye movement. However, asteroid hyalosis particles tend to be more discrete, hyperechoic, scintillating, and seen throughout the vitreous, whereas vitreous hemorrhage particles tend to be more heterogeneous and layer in the most posterior aspect of the chamber [1,3].

Given its benign, degenerative nature, asteroid hyalosis rarely requires any particular treatment and non-emergent ophthalmologic follow-up is appropriate. It often does not require further ophthalmologic workup unless other pathology is suspected, or significant vision loss occurs.

### Conclusion

Emergency physicians can use POCUS to promptly evaluate for several time-sensitive, vision-threatening ocular conditions. While relatively rare, asteroid hyalosis is a benign condition that can easily mimic VH, RD, or other concerning pathology that typically warrants urgent or emergent ophthalmologic evaluation. Knowledge of this mimic and ability to recognize its subtle sonographic

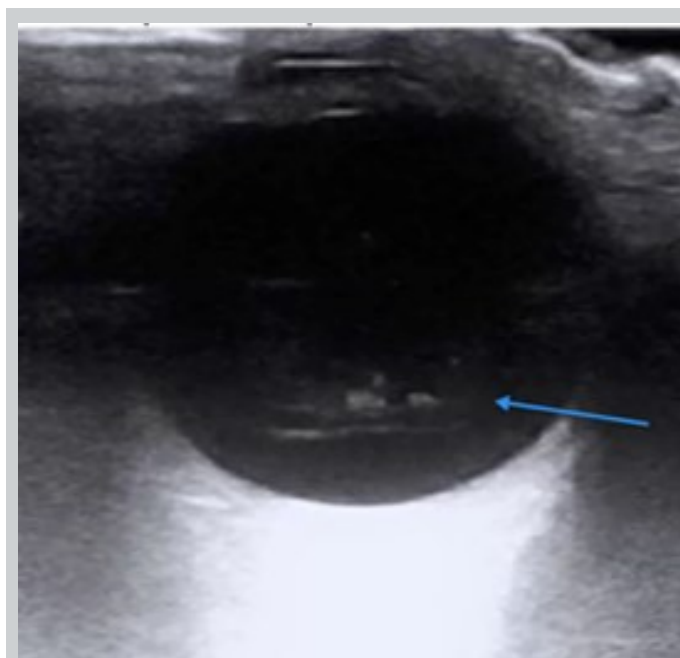


Figure 2. Transverse view of the affected eye demonstrating vitreous hemorrhage, characterized by echogenic blood layering posterior in the vitreous body (blue arrow). The more hyperechoic areas represent clotted blood.



features can be useful in differentiating from other pathologies, communicating with ophthalmology, and influencing management and disposition.

## Disclosures

The authors declare that they have no known competing conflicts interests or personal relationships that could have appeared to influence the work reported in this paper.

## Patient Consent

Patient consent was obtained by the authors in addition to approval from the hospital ethics department.

## References

1. Lahham S, Shniter I, Thompson M, Le D, Chadha T, Mailhot T, et al. Point-of-Care Ultrasonography in the Diagnosis of Retinal Detachment, Vitreous Hemorrhage, and Vitreous Detachment in the Emergency Department. *JAMA Netw Open*. 2019;2(4):e192162.
2. Lyon M, von Kuenssberg Jehle D. Ocular. In OJ Ma, JR Mateer, RF Reardon, SA Joing (eds), *Ma and Mateer's Emergency Ultrasound* (3rd ed). New York, NY: McGraw-Hill Education. pp 569-586.
3. Khoshnevis M, Rosen S, Sebag J. Asteroid hyalosis: a comprehensive review. *Surv Ophthalmol*. 2019; 64: 452-462.
4. Møller-Lorentzen TB, Eckmann-Hansen C, Faber C, Larsen M, Subji Y. Global prevalence of asteroid hyalosis and projection of its future burden: a systematic review and meta-analysis. *Acta Ophthalmol*. 2020;98 (8):755–762.
5. Stringer CEA, Ahn JS, Kim DJ. Asteroid Hyalosis: A Mimic of Vitreous Hemorrhage on Point of Care Ultrasound. *CJEM*. 2017;19 (4):317-320.
6. Lema PC, Mantuani D, Nagdev A, Adhikari S. Asteroid Hyalosis Masquerading as Vitreous Hemorrhage on Point-of-Care Sonography. *J Ultrasound Med*. 2018; 37(1):281-284.
7. Arthurs B, Connor-Schuler R, Kreifels W, Suszanski J, Baliga S, Amponsah D. Asteroid hyalosis seen on point-of-care ultrasound. *Clin Pract Cases Emerg Med*. 2019; 3(3): 318-320.
8. Scott DAR, Møller-Lorentzen TB, Faber C, Wied J, Grauslund J, Subhi Y. Spotlight on Asteroid Hyalosis: A Clinical Perspective. *Clin Ophthalmol*. 2021;15:2537-2544.
9. Fawzi AA, Vo B, Kriwanek R, Ramkumar HL, Cha C, Carts A, Heckenlively JR, Foos RY, Glasgow BJ. Asteroid hyalosis in an autopsy population: The University of California at Los Angeles (UCLA) experience. *Arch Ophthalmol*. 2005;123(4):486-90.
10. Jacobsen B, Lahham S, Lahham S, Patel A, Spann S, Fox JC. Retrospective Review of Ocular Point-of-Care Ultrasound for Detection of Retinal Detachment. *West J Emerg Med*. 2016;17(2):196-200.
11. Vrablik ME, Snead GR, Minnigan HJ, Kirschner JM, Emmett TW, Seupaul RA. The diagnostic accuracy of bedside ocular ultrasonography for the diagnosis of retinal detachment: a systematic review and meta-analysis. *Ann Emerg Med*. 2015;65(2):199-203.e1.

# The Use of Point of Care Ultrasound in Diagnosis of Peritonsillar Abscess

Brian Kohen, MD<sup>1</sup>; Melanie Perez, DO<sup>2</sup>; Jheanelle McKay, MD<sup>3</sup>; Rolando Zamora, MD<sup>1</sup>; Curtis Xu, MD<sup>4</sup>

(1) Memorial Healthcare System, Pembroke Pines, Florida, USA

(2) University of Texas Southwestern Medical Center, Dallas, Texas, USA

(3) Joe DiMaggio's Children's Hospital, Hollywood, Florida, USA

(4) University of Connecticut Health Center, Farmington, Connecticut, USA

## Abstract

The use of point of care ultrasound (POCUS) for diagnosis and treatment of peritonsillar abscess (PTA) is increasing [1]. Proven advantages include improved diagnostic accuracy and treatment success rates as well as decreased otolaryngology consultation, computed tomography (CT) usage, return visits to the emergency department (ED), and length of stay [1]. We present a case of a patient with a PTA that was diagnosed and successfully treated utilizing POCUS, avoiding the need for otolaryngology consultation and CT.

## Case Presentation

An 18-year-old girl who recently recovered from infectious mononucleosis presented to the pediatric emergency department (ED) with a sore throat. She had completed a course of steroids due to persistent sore throat associated with right-sided neck pain and hoarseness. Over the following 2 days, her symptoms worsened and progressed to odynophagia and trismus, prompting her visit to the ED. In the ED, she was well appearing in no acute distress with normal vital signs. On examination, she had a leftward uvular deviation in addition to a mass in the right peritonsillar space, concerning for a PTA. An intraoral POCUS was performed using an endocavitary probe to better visualize the abscess and plan for drainage (Video S1). Using POCUS, the emergency physicians were able to confirm the abscess, measure its size, and identify the depth of nearby vessels to avoid while performing the drainage (Figure 1). The PTA was subsequently safely and successfully drained, yielding about 7 milliliters of pus which later grew *Streptococcus pyogenes*. The patient experienced immediate relief and was discharged on oral antibiotics.

## Discussion

PTA is a common deep neck space infection, with an incidence of about 3 in 10,000 per year [2]. Physical examination is often unreliable, with reported sensitivity

and specificity of 78% and 50%, respectively, even amongst experienced specialists [3]. Moreover, it is often difficult to distinguish between peritonsillar abscess and other deep neck space infections such as tonsillitis and peritonsillar cellulitis clinically [4]. Imaging modalities such as CT are accurate but have several disadvantages such as increased costs, length of stay, intravenous contrast and radiation risk. POCUS has increasingly been used as

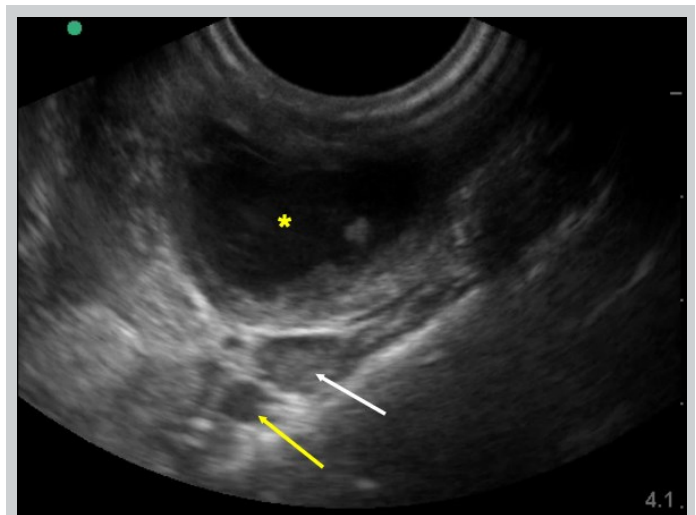


Figure 1. Peritonsillar abscess (\*) adjacent to the internal carotid artery (yellow arrow) and internal jugular vein (white arrow) at a depth of about 3cm.

\*Corresponding Author: Brian Kohen (email: brik591@gmail.com)

This work is licensed under a [Creative Commons Attribution 4.0 International License](https://creativecommons.org/licenses/by/4.0/).

Author(s) retain the copyright for their work. At the time of submission to POCUS Journal the author(s) grant the journal a limited and non revokable right to publish in the Journal under a [Creative Commons Attribution 4.0 International License](https://creativecommons.org/licenses/by/4.0/).

DOI: <https://doi.org/10.24908/pocus.v8i2.16568>

an adjunct for diagnosis of PTA, with a sensitivity ranging from 89-95% and specificity of 78-100% [3,5]. Additionally, when used for the treatment of PTA, POCUS increases successful drainage and diagnostic accuracy, and decreases otolaryngology consultation, CT utilization, return visits to the ED, and length of stay [1,6,7]. In our case, PTA was rapidly diagnosed and successfully treated in the ED without the need for otolaryngology consultation or CT.

## Disclosures

The authors report no disclosures related to this work.

## References

1. Gibbons RC, Costantino TG. Evidence-Based Medicine Improves the Emergent Management of Peritonsillar Abscesses Using Point-of-Care Ultrasound. *J Emerg Med*. 2020 Nov;59(5):693-698. doi: 10.1016/j.jemermed.2020.06.030. Epub 2020 Aug 19. PMID: 32826122.
2. Herzon FS, Harris P. Moshier Award thesis. Peritonsillar abscess: incidence, current management practices, and a proposal for treatment guidelines. *Laryngoscope*. 1995 Aug;105(8 Pt 3 Suppl 74):1-17. doi: 10.1288/00005537-199508002-00001. PMID: 7630308
3. Scott PM, Loftus WK, Kew J, et al. Diagnosis of peritonsillar infections: a prospective study of ultrasound, computerized tomography and clinical diagnosis. *J Laryngol Otol*. 1999;113:229-232.
4. Situ-LaCasse E, Adhikari S. Soft tissue infections. In: Ma OJ, Mateer JR, et al. *Ma & Mateer's Emergency Ultrasound*. 4<sup>th</sup> ed. McGraw Hill; 2020:(Ch) 22.
5. Secko M, Sivitz A. Think ultrasound first for peritonsillar swelling. *Am J Emerg Med*. 2015 Apr;33(4):569-72. doi: 10.1016/j.ajem.2015.01.031. Epub 2015 Jan 23. PMID: 25737413
6. Bryczkowski C, Haussner W, Rometti M, Wei G, Morrison D, Geria R, Mccoy JV. Impact of Bedside Ultrasound on Emergency Department Length of Stay and Admission in Patients With a Suspected Peritonsillar Abscess. *Cureus*. 2022 Dec 5;14(12):e32207. doi: 10.7759/cureus.32207. PMID: 36620852
7. Costantino TG, Satz WA, Dehnkamp W, Goett H. Randomized trial comparing intraoral ultrasound to landmark-based needle aspiration in patients with suspected peritonsillar abscess. *Acad Emerg Med*. 2012 Jun;19(6):626-31. doi: 10.1111/j.1553-2712.2012.01380.x. PMID: 22687177

# Acute Type A Aortic Dissection Diagnosed by POCUS in a 29-year-old Man

Vladimir Cárdenas López, MD<sup>1</sup>; Pablo Blanco, MD<sup>2\*</sup>

(1) Intensive Care Unit, Hospital "Dr. Miguel Belascuain", Concepción, Argentina.

(2) High-dependency Unit, Hospital "Dr. Emilio Ferreyra", Necochea, Argentina.

## Abstract

Aortic dissection (AD) is a medical emergency with a poor prognosis if not recognized early and treated promptly. In this setting, clinical data may be equivocal, while electrocardiogram, laboratory tests, and chest radiography often show nonspecific findings. In contrast, cardiac point of care ultrasound (POCUS) has proven useful in the diagnosis and detection of complications of AD. We present the case of a 29-year-old man with marfanoid habitus presenting with chest pain and acute heart failure, in whom cardiac POCUS aided in the rapid diagnosis of type A AD and pulmonary edema. POCUS contributed to optimizing the medical treatment and allowed for early activation of the surgical team.

## Introduction

Aortic dissection (AD) is the most common type of acute thoracic aortic syndromes, compared to intramural hematoma and penetrating atherosclerotic ulcer [1]. It has an incidence of 5- 30 cases per million people per year and is more common in men [1]. Known risk factors include arterial hypertension, thoracic aortic aneurysm, bicuspid aortic valve, and genetic conditions affecting the tunica media, such as Marfan or Ehlers-Danlos syndrome, aortitis, pregnancy, trauma, and iatrogenia [1]. Based on the Stanford classification, dissection including the ascending aorta is known as Type A (A-AD), and dissection not including the ascending aorta is known as type B (B-AD). Two-thirds of dissections are A-AD [2]. Early surgery is mandatory in A-AD, whereas B-AD is often treated medically, unless it ruptures or causes malperfusion syndromes [2].

Patients with AD typically present severe chest pain. In addition, depending on the propagation of the dissection, patients may show features of heart failure, myocardial infarction, tamponade, shock, or malperfusion syndromes. These overlapping presentations may confound the attending physician and delay the diagnosis or may even pose a patient's risk if some treatments are indicated. For instance, there is further urgency of

diagnosing aortic dissection as an etiology of stroke as early thrombolytic therapy may be indicated.

To diagnose AD, clinical findings alone may be equivocal, and electrocardiogram, laboratory tests or chest radiography often show nonspecific findings. Cardiac POCUS (transthoracic) can be considered the preferred tool for screening patients with suspected AD given its acceptable diagnostic accuracy (particularly in A-AD), its quickness, non-invasiveness, lack of ionizing radiation, and widespread availability in acute care settings [1]. In addition to AD diagnosis, POCUS may aid in the detection of complications, such as aortic regurgitation, acute heart failure, or tamponade.

## Case presentation

A 29-year-old man was admitted to the Emergency Department (ED) with chest pain radiating to the right shoulder, progressively worsening over the last five days, accompanied by dyspnea at rest, diaphoresis, and emesis. Vital signs were: heart rate 118 beats per minute; respiratory rate 30 breaths per minute, blood pressure 110/75 in both arms, oxygen saturation 80% on room air; and temperature 36°C. A physical examination revealed a severely distressed patient with excruciating chest pain, orthopnea, and diffuse bilateral crackles on chest

---

\*Corresponding Author: Pablo Blanco, MD, (email: ohtusabes@gmail.com)

This work is licensed under a [Creative Commons Attribution 4.0 International License](https://creativecommons.org/licenses/by/4.0/).

Author(s) retain the copyright for their work. At the time of submission to POCUS Journal the author(s) grant the journal a limited and non revokable right to publish in the Journal under a [Creative Commons Attribution 4.0 International License](https://creativecommons.org/licenses/by/4.0/).

DOI: <https://doi.org/10.24908/pocus.v8i2.16533>

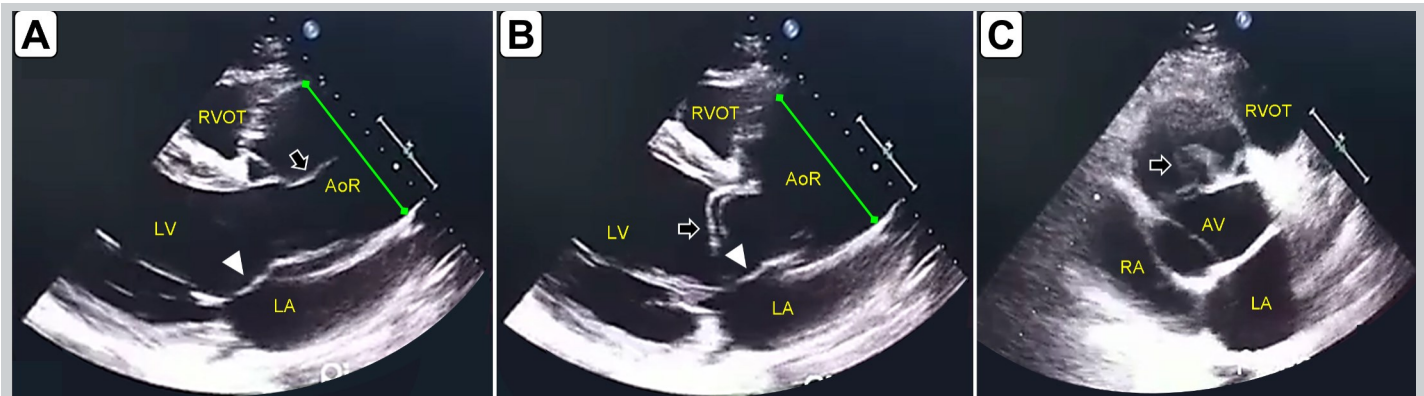


Figure 1. Cardiac point-of-care ultrasound (POCUS) showing signs of type A aortic dissection (A-AD). A. Parasternal long axis (PLAX) view in a systolic frame. B. PLAX view in a diastolic frame. C. Parasternal short-axis view. Arrow indicate the intimal flap, while the continuous green line indicate the aortic root dilation (pseudo-double aortic valve). Arrowhead is pointing to the anterior leaflet of the mitral valve. LV: left ventricle; LA: left atrium; RVOT: right ventricular outflow tract; RA: right atrium; AoR: aortic root; AV: aortic valve.

auscultation. He had marfanoid habitus. Surface electrocardiography showed sinus rhythm at 118 QRS complexes per minute, with a 1 mm ST level depression in leads DII, DIII, and AVF, and 2 mm from leads V4 to V6. Cardiac POCUS (transthoracic) was performed on arrival. In the parasternal long-axis view, POCUS showed a severely dilated aortic root with a long intimal flap originating from its anterior aspect, protruding into the left ventricle in diastole, and touching the anterior leaflet of the mitral valve (Figure 1A,1B and Video S1). The left ventricle was dilated, and systolic function was severely impaired (Video S1). Severe acute aortic regurgitation was also observed. In the short axis, a pseudo- double aortic valve was mimicked with the pseudo valve as the intimal flap (Figure 1C and Video S2). Diffuse bilateral B-lines confirmed acute pulmonary edema. Chest computed tomography with intravenous contrast medium confirmed an A-AD limited to the aortic root and ascending aorta (Figure 2). The patient was

transferred to the operating room, where the preoperative findings were also confirmed (Figure 3). He successfully underwent the Bentall procedure and continued his care in the intensive care unit.

### Discussion

The case presented here is one of several reported cases that highlight the value of cardiac POCUS in diagnosing A-AD without delays in the Emergency Department, leading to improved patient care. The diagnostic accuracy of cardiac POCUS is better for A-AD than B-AD. For A-AD, the sensitivity is 78-100%, whereas for B-AD it is 31–55% [2]. In cases where the diagnosis is unequivocal on cardiac POCUS and the patient is unstable, the patient should go directly to the operating room without further imaging techniques [3]. However, when cardiac POCUS does not rule out AD and suspicion remains high, advanced imaging techniques such as transesophageal echocardiography

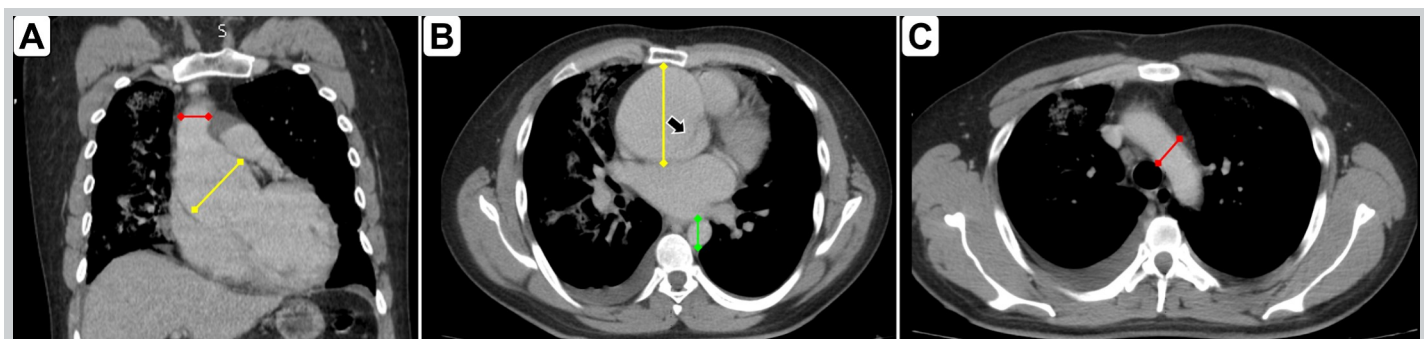


Figure 2. Confirmation of A-AD by chest computed tomography with intravenous contrast medium. A. Coronal plane showing a dilated aortic root/ascending aorta (continuous yellow line) and a normal aortic arch (continuous red line). B. Axial plane showing a dilated ascending aorta (continuous yellow line) with an intimal flap indicated by the arrow, and the normal descending aorta (continuous green line). C. Axial plane at the level of the normal aortic arch (continuous red line).

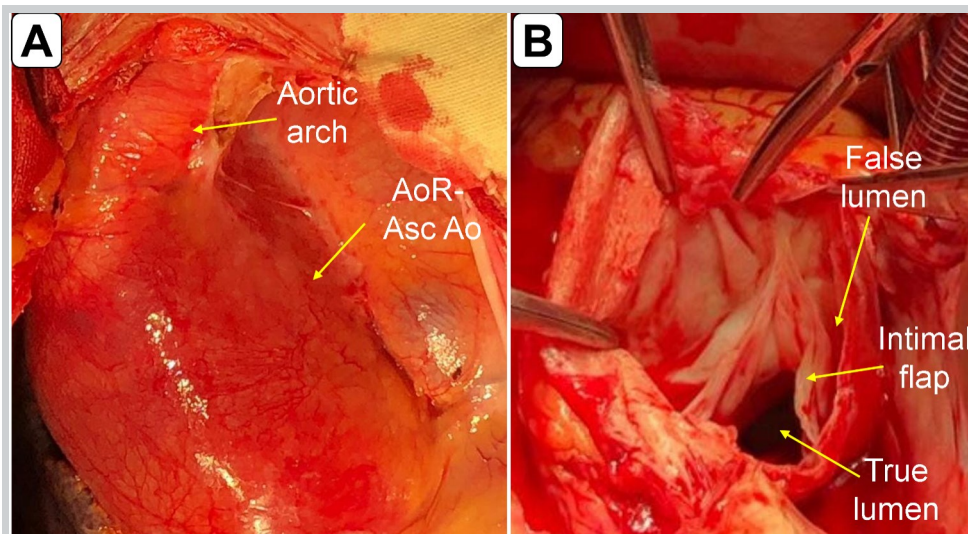


Figure 3. Operative findings of A-AD. A. Aortic root/ascending aorta dilatation and a normal aortic arch are observed. B. The intimal flap and a true and false lumen are demonstrated by opening the aortic root. AoR: aortic root; Asc Ao: ascending aorta.

(TEE) in unstable patients, chest computed tomography (the most common modality in practice), or magnetic resonance imaging in stable patients should be performed [2-6].

Signs of dissection on Cardiac POCUS include aortic dilation and an intimal flap separating the aortic lumen in a true and false lumen. When evaluating for an intimal flap, physicians should be aware of mimickers such as artifacts resembling a double aortic lumen. Reverberating and side-lobe artifacts are often observed in the ascending aorta and aortic root, respectively, leading to false-positive AD diagnosis [7]. Regional wall motion abnormalities and pericardial effusion may occur in cases where dissection includes the coronary ostia and pericardium, respectively. Aortic regurgitation of varying degrees can also be observed, as well as B lines, as a sign of pulmonary edema.

The clinical data and phenotypic features of our patient raised the suspicion of A-AD. Dilation and dissection limited to the aortic root/ascending aorta are typical of Marfan syndrome [6], which was easily observed by cardiac POCUS, leading to early offering a definite treatment. In our patient, a chest CT was performed to confirm AD, which seemed unnecessary, and the patient could be transferred to the operating room without the need for advanced imaging techniques [3].

### Conclusion

The case presented here is a clear example of the paramount importance of cardiac POCUS in the diagnosis of aortic dissection, leading to the early initiation of medical treatment and activation of the surgical team to reach a definite treatment. Without POCUS, the diagnosis could be delayed or even missed, obscuring the patient prognosis.

### Statement of ethics approval/consent

Complete written informed consent was obtained from

the patient's next of kin for the publication of this case file.

### Disclosures

This work has not been presented at any conferences and has not been supported by any grants. All authors have no conflicts of interest to disclose.

### References

1. Pare JR, Liu R, Moore CL, Sherban T, Kelleher MS Jr, Thomas S, Taylor RA. Emergency physician focused cardiac ultrasound improves diagnosis of ascending aortic dissection. *Am J Emerg Med.* 2016;34(3):486-92. doi: 10.1016/j.ajem.2015.12.005.
2. Bossone E, LaBounty TM, Eagle KA. Acute aortic syndromes: diagnosis and management, an update. *Eur Heart J.* 2018;39(9):739-749d. doi: 10.1093/eurheartj/ehx319.
3. Carmody K, Asaly M, Blackstock U. Point of Care Echocardiography in an Acute Thoracic Dissection with Tamponade in a Young Man with Chest Pain, Tachycardia, and Fever. *J Emerg Med.* 2016;51(5):e123-e126.
4. Isselbacher EM, Preventza O, Hamilton Black J 3rd, Augoustides JG, Beck AW, Bolen MA, Braverman AC, Bray BE, Brown-Zimmerman MM, Chen EP, Collins TJ, DeAnda A Jr, Fanola CL, Girardi LN, Hicks CW, Hui DS, Schuyler Jones W, Kalahasti V, Kim KM, Milewicz DM, Oderich GS, Ogbechie L, Promes SB, Gyang Ross E, Schermerhorn ML, Singleton Times S, Tseng EE, Wang GJ, Woo YJ. 2022 ACC/AHA Guideline for the Diagnosis and Management of Aortic Disease: A Report of the American Heart Association/American College of Cardiology Joint Committee on Clinical Practice Guidelines. *Circulation.* 2022;146(24):e334-e482. doi: 10.1161/CIR.0000000000001106.
5. MacGillivray TE, Gleason TG, Patel HJ, Aldea GS, Bavaria JE, Beaver TM, Chen EP, Czerny M, Estrera AL, Firestone S, Fischbein MP, Hughes GC, Hui DS, Kissoon K, Lawton JS, Pacini D, Reece TB, Roselli EE, Stulak J. The Society of Thoracic Surgeons/American Association for Thoracic Surgery Clinical Practice Guidelines on the Management of Type B Aortic Dissection. *Ann Thorac Surg.* 2022;113(4):1073-1092. doi: 10.1016/j.athoracsur.2021.11.002.
6. de Beaufort HWL, Trimarchi S, Korach A, Di Eusanio M, Gilon D, Montgomery DG, Evangelista A, Braverman AC, Chen EP, Isselbacher EM, Gleason TG, De Vincentiis C, Sundt TM, Patel HJ, Eagle KA. Aortic dissection in patients with Marfan syndrome based on the IRAD data. *Ann Cardiothorac Surg.* 2017;6(6):633-641. doi: 10.21037/acs.2017.10.03.
7. Quien MM, Saric M. Ultrasound imaging artifacts: How to recognize them and how to avoid them. *Echocardiography.* 2018;35(9):1388-1401. doi: 10.1111/echo.14116.

# Cough Causing Abdominal Pain? A Rapid POCUS Diagnosis of Rectus Sheath Hematoma

William Noel, MD<sup>1</sup>; Brian B. Donahue, MD<sup>1\*</sup>

(1) Emergency Medicine Residency Program, Ascension Resurrection Medical Center, Chicago, Illinois

## Abstract

We present a case of a 59-year-old man who arrived to the emergency department with abdominal pain and bruising after coughing. Point of care ultrasound (POCUS) was used to make the diagnosis of rectus sheath hematoma (RSH). This diagnosis was made within minutes of arrival to the ED and subsequently confirmed on computed tomography (CT) of the abdomen. As abdominal ultrasound is a technically straightforward imaging technique which includes a sensitivity that rises about 90%, its utilization to identify rectus sheath hematoma can reduce the rate of CT imaging and time to diagnosis for this pathology.

## Case Presentation

A 59-year-old man with past medical history including obesity status post gastric banding surgery and atrial fibrillation on rivaroxaban, presented to the emergency department with a complaint of focal pain to his right abdomen along with areas of visible bruising. He noted that since his diagnosis of COVID-19 a week prior, he had been having paroxysms of coughing. During one episode of coughing a few days prior to seeking medical care, the patient recalled a “ripping” sensation in his right abdomen followed by intermittent aching and bruising to that area. The patient reported that his pain worsened with certain movements and coughing but he could tolerate food and liquids without any issues. Although his ecchymosis was scattered across his abdomen on exam, he elicited focal tenderness in his right upper quadrant (Figure 1). The assessing medical provider placed an ultrasound probe directly over the area of pain which revealed a hypoechoic, ovoid hematoma adjacent to the rectus sheath (Figure 2). As the patient was taking rivaroxaban, a CT was obtained to rule out active extravasation. CT confirmed the finding of rectus sheath hematoma without acute bleeding (Figure 3). A complete blood count revealed a normal hemoglobin. Liver function tests, lipase, lactic acid and basic metabolic panel were also within normal limits. The patient was subsequently discharged home with instructions to apply intermittent ice to his abdomen, hold his rivaroxaban for two days,

and follow up with his primary care physician in three days.

## Discussion

Although abdominal pain is a common presenting complaint for emergency department visits, rectus sheath hematoma (RSH) is an uncommon etiology, and in some reports may account for as little as 2% of diagnoses [1]. Historically, RSH was thought to arise due to abdominal trauma or spontaneously with anticoagulant use but more

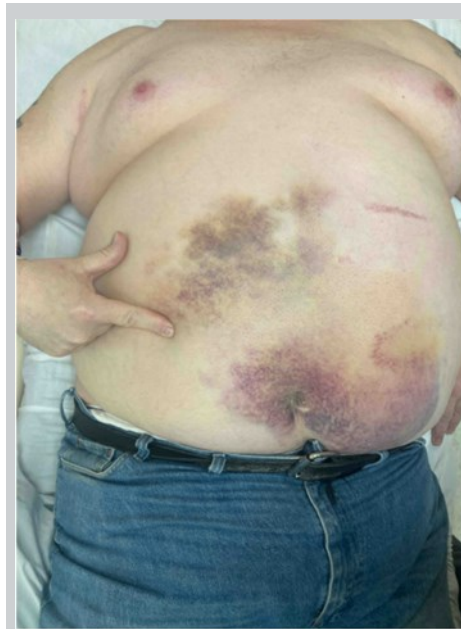

Figure 1. Patient pointing to area of focal tenderness on exam. Visible scattered ecchymosis (including positive Cullen's Sign) in various stages of healing noted over abdomen.

\*Corresponding Author: Brian Donahue MD, (email: bdonah1@gmail.com)

This work is licensed under a [Creative Commons Attribution 4.0 International License](https://creativecommons.org/licenses/by/4.0/).

Author(s) retain the copyright for their work. At the time of submission to POCUS Journal the author(s) grant the journal a limited and non revokable right to publish in the Journal under a [Creative Commons Attribution 4.0 International License](https://creativecommons.org/licenses/by/4.0/).

DOI: <https://doi.org/10.24908/pocus.v8i2.16500>

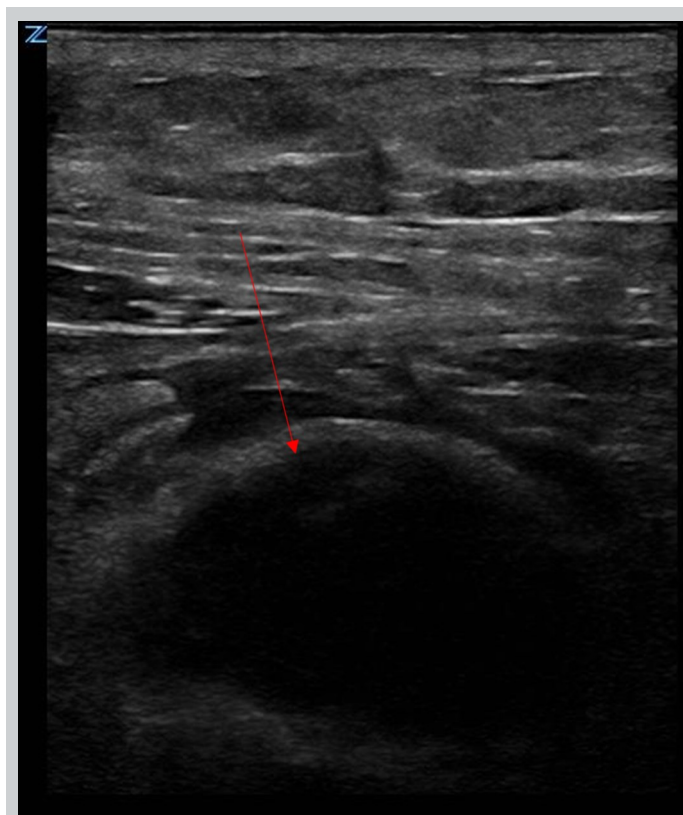


Figure 2. POCUS finding of rectus sheath hematoma. Hypoechoic hematoma (red arrow) deep to the hyperechoic aponeurosis of the anterior rectus sheath.

recently coughing has been identified as a risk factor. In a study by Cherry and Mueller, of 126 patients with an identified RSH, 37 (29%) had history of an acute coughing spell. Other common presenting features of RSH may include nausea, vomiting, palpable mass, or visible bruising on the abdomen [2]. In terms of diagnosis, CT imaging is reported to reach a sensitivity and specificity of 100% and the sensitivity of ultrasound for identifying RSH can reach 90% [1]. Ultrasound may be somewhat limited in its use to assess for continued bleeding. If there is concern for acute hemorrhage, the clinician may perform serial sonographs to observe the characteristics of the lesion – with an enlarging hematoma being suggestive of active extravasation. This could take time to appear in a stable patient with slow active bleeding but ultrasound may be the diagnostic modality of choice in an unstable patient. Ultimately, if the patient possesses high risk features such as pregnancy, elderly age, or anticoagulant use, the clinician should elect for CT imaging and additional workup such as coagulation studies, serial hemoglobin levels, and possible admission for abdominal compartment checks [3]. However, the vast majority of RSH are self-limiting so it may be an appropriate option to forgo CT imaging in which an RSH is identified on ultrasound as long as the patient is deemed low risk for

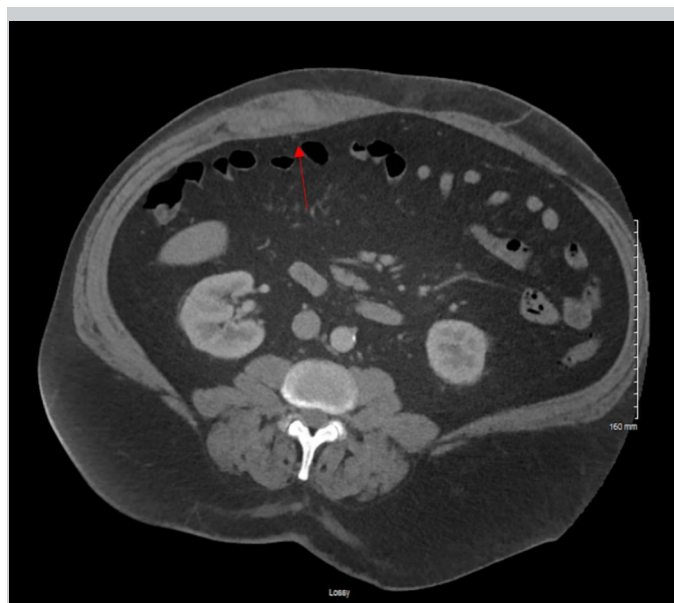

Figure 3. Transverse cut of CT imaging revealing right abdominal wall hematoma (red arrow) that was measured to be approximately 11.4 x 2.6 x 8.4cm in volume.

worsening bleeding and is able to follow up promptly. Conservative treatment includes measures such as rest, intermittent icing, analgesics, and compression of hematoma. Rarely is anticoagulation reversal or blood transfusion necessary. In patients with acute anemia, hemodynamic instability, severe peritonitis or abdominal compartment syndrome, admission and aggressive treatment such as celiotomy or arterial embolization may be advised [4, 5].

### Conclusion

Although not a common etiology of abdominal pain in the emergency department, rectus sheath hematoma is an important consideration in the differential diagnosis and may be rapidly identified by POCUS. This approach might expedite stabilization and treatment of an unstable patient and may also avoid the cost, radiation and time associated with CT imaging altogether in stable patients with rectus sheath hematoma.

### Disclosures

The authors have no conflict of interests to declare.

### Funding

The authors received no funding.

### Patient consent

The authors gained consent from the patient to publish.

### References

- 1 Klingler PJ, Wetscher G, Glaser K, Tschmelitsch J, Schmid T, Hinder RA. The use of ultrasound to differentiate rectus sheath hematoma



- from other acute abdominal disorders. *Surg Endosc.* 1999 Nov;13(11):1129-34. doi: 10.1007/s004649901188. PMID: 10556453.
2. Cherry WB, Mueller PS. Rectus sheath hematoma: review of 126 cases at a single institution. *Medicine (Baltimore).* 2006 Mar;85(2):105-110. doi: 10.1097/01.md.0000216818.13067.5a. PMID: 16609349.
3. Osinbowale O, Bartholomew JR. Rectus sheath hematoma. *Vasc Med.* 2008 Nov;13(4):275-9. doi: 10.1177/1358863X08094767. PMID: 18940904.
4. Hatjipetrou A, Anyfantakis D, Kastanakis M. Rectus sheath hematoma: a review of the literature. *Int J Surg.* 2015 Jan;13:267-271. doi: 10.1016/j.ijssu.2014.12.015. Epub 2014 Dec 19. PMID: 25529279.
5. Bello, G, Blanco, P. Giant rectus sheath hematoma. *Ultrasound J* 11, 13 (2019). <https://doi.org/10.1186/s13089-019-0129-4>

# The Importance of Serial POCUS Exams – Dual Pathologies in Play

Rahul Nair, MD<sup>1\*</sup>; Jonathan Zuo, BS<sup>2</sup>; Ariel L Shiloh, MD<sup>1</sup>

1) Division of Critical Care Medicine, Department of Medicine. Montefiore Medical Center/Albert Einstein College of Medicine, Bronx, NY

2) Albert Einstein College of Medicine, Bronx, NY

## Abstract

Serial point of care ultrasound (POCUS) exams are essential to assess acute pericardial effusions which can rapidly evolve into cardiac tamponade. A typical presentation includes dyspnea, tachycardia, and chest pain. Importantly, serial cardiac exams in such high-risk patients can detect other concurrent pathologies. We present an unusual case of a patient who initially presented with an acute circumferential pericardial effusion and upon serial POCUS exams developed an unexpected Takotsubo cardiomyopathy in the setting of cardiac tamponade.

## Case

A 63-year-old woman with a past medical history of Human Immunodeficiency Virus, asthma, and previously treated Hodgkin's lymphoma presented to the emergency department with 3 weeks of worsening shortness of breath. On initial assessment in the emergency department, the patient was hemodynamically unstable with a heart rate of 140 beats per minute (bpm) and a blood pressure of 88/68 mm Hg. Bedside point of care ultrasound (POCUS) was performed and demonstrated a moderate circumferential pericardial effusion with normal left ventricular function and a collapsible inferior vena-cava (IVC). Intravenous fluids were initiated with resolution of the patient's hemodynamic instability (Video S1). A computer tomography (CT) of the chest was also obtained in the emergency department which showed extensive mediastinal lymphadenopathy with right middle lobe consolidation. The patient was admitted for evaluation of the pericardial effusion and CT findings.

Forty-eight hours after admission, the patient reported persistent midsternal chest pain and shortness of breath with a blood pressure of 110/60 mm Hg, heart rate of 127 bpm, and an oxygen saturation of 100% on 2-liters nasal cannula. Repeat troponin I was elevated at 1.02ng/ml (ref - <0.03 ng/ml). POCUS was performed which revealed mid-to apical left ventricular (LV) akinesis and an interval

reduction of LV function along with right atrial systolic collapse, right ventricular diastolic collapse and a plethoric IVC (Video S2). Limited transthoracic echocardiogram done by the echocardiography lab shortly after confirmed the findings. These findings were concerning for Takotsubo/stress induced cardiomyopathy in the setting of tamponade physiology.

The patient underwent a pericardiocentesis with removal of 240 mL of fluid with improvement of tachycardia and dyspnea. Formal echocardiography 48 hours after the procedure showed minimal residual effusion with improvement of LV function, which returned to normal within a week (Video S3). Cytology of the pericardial fluid showed inflammatory and mesothelial cells with no evidence of malignant cells. However, subsequent lymph node biopsy revealed recurrence of Hodgkin lymphoma to which her pericardial effusion was attributed.

## Discussion

Cardiac tamponade is a pericardial syndrome characterized by impairment of diastolic filling of the ventricles causing reduction of cardiac output. The classically advanced signs of tamponade described as hypotension, distension of jugular veins, and diminished heart sounds (Becks Triad) are present in a minority of patients. The most common initial presenting symptoms

---

\*Corresponding Author: Rahul Nair, MD, (email: Ranair@montefiore.org)

This work is licensed under a [Creative Commons Attribution 4.0 International License](https://creativecommons.org/licenses/by/4.0/).

Author(s) retain the copyright for their work. At the time of submission to POCUS Journal the author(s) grant the journal a limited and non revokable right to publish in the Journal under a [Creative Commons Attribution 4.0 International License](https://creativecommons.org/licenses/by/4.0/).

DOI: <https://doi.org/10.24908/pocus.v8i2.16595>

are dyspnea and tachycardia, which may be present in the absence of hypotension [1].

Echocardiographic evaluation of tamponade includes:

- i) Quantity and quality of pericardial fluid
- ii) Systolic right atrial collapse
- iii) Diastolic right ventricular size and variability with the respiratory cycle
- iv) Interventricular septal shift of the left ventricle during inspiration
- v) Collapsibility of IVC [2,3].

Diastolic right ventricular collapse is specific for tamponade while IVC plethora is highly sensitive. Systolic right atrial collapse is often the earliest sign of tamponade. Comprehensive or advanced critical care echocardiography can be used to detect exaggerated respiratory cycle changes in mitral and tricuspid valve inflow velocities as a surrogate for pulsus paradoxus [2]. Ideally electrocardiographic gating is used to delineate systole and diastole but this not often routine with POCUS.

In this patient the initial POCUS exam revealed a moderate sized pericardial effusion with a fully collapsible IVC making tamponade physiology less likely. When the patient developed new onset chest pain and shortness of breath this raised the concern for worsening tamponade. A repeat ultrasound revealed an unexpected finding of stress induced cardiomyopathy which can potentially be attributable to progressive tamponade development. Potentially the tamponade was further exacerbated by left ventricular dysfunction. In dog models right atrial and ventricular collapse occurred with significantly smaller volumes of pericardial fluid in the setting of induced left ventricular dysfunction [4]. This could certainly lead to a vicious cycle of LV systolic dysfunction and worsening tamponade physiology leading to acute decompensation.

Takotsubo-associated myocardial dysfunction is irrespective of vascular territories, and commonly presents as transient mid to apical akinesia, hypokinesia, or dyskinesia in the absence of obstructive coronary disease. Other findings include circumferential apical dilatation (apical ballooning), basal hyperkinesia and a severely reduced left ventricular function [5]. Treatment of Takotsubo cardiomyopathy is mainly supportive, however complications that arise such as Left Ventricular outflow tract obstruction (LVOT) (20%), cardiogenic shock (12.4%), thrombus formation (8%) all will have differing managements [6,7]. Drainage of the pericardial effusion improved the patient's hemodynamic status and led to the resolution of the cardiomyopathy, favouring a diagnosis of Takotsubo cardiomyopathy. Ideally, a true diagnosis of Takotsubo requires cardiac catheterization

as the patient's troponin plateaued at 1ng/ml cardiac catheterization was not pursued at the time by the inpatient cardiology service [8].

## Conclusion

This case highlights the importance of serial cardiac POCUS examinations in the evaluation of pericardial effusion. Additionally, it highlights the importance of recognizing an acute concurrent cardiac pathology that can quickly lead to a vicious cycle of cardiac dysfunction leading to decompensation.

## Statement of Consent

The authors confirm that consent to publish this case was obtained from the patient.

## Disclosures

All authors of this manuscript have no conflicts of interest. The authors listed have no affiliations with or involvement in any organization or entity with any financial interest in the subject matter or materials discussed in this manuscript.

## References

1. Alerhand S, Adrian RJ, Long B, Avila J. Pericardial tamponade: A comprehensive emergency medicine and echocardiography review. *Am J Emerg Medicine*. 2022;58:159-174. doi:10.1016/j.ajem.2022.05.001
2. Pérez-Casares A, Cesar S, Brunet-Garcia L, Sanchez-de-Toledo J. Echocardiographic Evaluation of Pericardial Effusion and Cardiac Tamponade. *Frontiers Pediatrics*. 2017;5:79. doi:10.3389/fped.2017.00079
3. Bodson, Laurent; Bouferrache, Kocēila; Vieillard-Baron, Antoine. Cardiac tamponade. *Current Opinion in Critical Care*: October 2011 - Volume 17 - Issue 5 - p 416-424 doi: 10.1097/MCC.0b013e3283491f27
4. Hoit BD, Gabel M, Fowler NO. Cardiac tamponade in left ventricular dysfunction. *Circulation*. 1990;82(4):1370-1376. doi:10.1161/01.cir.82.4.1370
5. Izumo M, Akashi YJ. Role of echocardiography for takotsubo cardiomyopathy: clinical and prognostic implications. *Cardiovasc Diagnosis Ther*. 2017;8(1):90-100. doi:10.21037/cdt.2017.07.03
6. De Backer, O., Debonnaire, P., Gevaert, S. et al. Prevalence, associated factors and management implications of left ventricular outflow tract obstruction in takotsubo cardiomyopathy: a two-year, two-center experience. *BMC Cardiovasc Disord* 14, 147 (2014). <https://doi.org/10.1186/1471-2261-14-147>
7. Stiermaier T, Eitel C, Desch S, et al. Incidence, determinants and prognostic relevance of cardiogenic shock in patients with Takotsubo cardiomyopathy. *Eur Heart J Acute Cardiovasc Care*. 2016;5(6):489-496. doi:10.1177/2048872615612456
8. Citro R, Okura H, Ghadri JR, et al. Multimodality imaging in takotsubo syndrome: a joint consensus document of the European Association of Cardiovascular Imaging (EACVI) and the Japanese Society of Echocardiography (JSE). *European Hear J - Cardiovasc Imaging*. 2020;21(11):1184-1207. doi:10.1093/ehjci/jeaa149

# Optimizing Care for High-Risk Multiple Pregnancy with POCUS – A Case of Quadruplet Pregnancy Early Diagnosis

Bernardo Vidal Pimentel, MD<sup>1</sup>; Christopher Tsoutsoulas, MD<sup>2,3</sup>; Kristin Lythgoe, MD<sup>4,5</sup>; Frank Myslik, MD<sup>4,5</sup>

(1) Department of Internal Medicine, Hospital da Luz Lisboa, Lisbon, Portugal

(2) Division of Emergency Medicine, Department of Medicine, University of Toronto, Toronto, Ontario, Canada

(3) North York General Hospital, Toronto, Ontario, Canada

(4) Division of Emergency Medicine, Western University, London, Ontario, Canada

(5) London Health Sciences Centre, London, Ontario, Canada

## Abstract

Managing multiple pregnancies is challenging and requires careful evaluation. Point of care ultrasound (POCUS) has emerged as a potentially crucial tool in assessing suspected first-trimester pregnancies. However, its role in evaluating multiple pregnancies remains uncertain. We present the case of a 36-year-old Ghanaian female who presented with acute vaginal bleeding after undergoing *in vitro* fertilization. A bedside transabdominal POCUS identified four intrauterine gestations with fetal poles and cardiac activity, suggesting a quadruplet viable pregnancy. A subsequent transvaginal ultrasound confirmed the findings. The patient was discharged with a follow-up appointment with an Obstetrician-Gynecologist. This case highlights the significance of POCUS in early pregnancy diagnosis, facilitating accurate identification and appropriate referral for further management. It also demonstrates the utility of POCUS in determining gestational age and viability. To our knowledge, no published case reports specifically address the diagnosis of a quadruplet pregnancy, emphasizing the role of POCUS in optimizing care for high-risk multiple pregnancies.

## Introduction

Point of care ultrasound (POCUS) has evolved into an invaluable tool for numerous healthcare professionals, spanning from the emergency department (ED) to the internal medicine ward [1]. Obstetric POCUS has proven beneficial in the ED by offering real-time visualization and diagnostic information at the bedside [2]. POCUS has significant enhanced obstetric care, particularly in resource-limited, remote, and austere environments [3, 4]. While its utility in various obstetric conditions has been well-documented, there remains a scarcity of published articles specifically addressing the diagnosis and management of multiple gestations using POCUS.

## Clinical Case

A 36-year-old Ghanaian female presented to our tertiary academic hospital's emergency department with a chief complaint of vaginal bleeding. She disclosed having undergone *in vitro* fertilization (IVF) one-month prior in Ghana due to a 6-year history of infertility.

At triage, her vital signs were temperature of 36.9 °C, heart rate of 83 bpm, blood pressure of 122/84 mmHg, respiratory rate of 18 bpm and SpO<sub>2</sub> of 99%. Physical examination revealed a non-tender abdomen and a closed cervical os with no active bleeding.

In order to further evaluate the patient's condition, an obstetric POCUS examination was performed using a 3-5MHz curvilinear transducer. The POCUS examination identified the presence of four distinct live intrauterine gestations, each displaying a fetal pole and cardiac activity (Figures 1 to 6 and supplemental Video S1).

A serum beta human chorionic gonadotropin level subsequently drawn revealed a value of 377, 520 IU/L (<5 UI). A comprehensive obstetric ultrasound was further requested and confirmed the four viable intrauterine gestations, with estimated gestational ages ranging from 8 weeks 0 days to 8 weeks 2 days. There was no evidence of heterotopic ectopic pregnancy.

---

\*Corresponding Author: Bernardo Vidal Pimentel (email: [bernardo.vidal.pimentel@hospitaldaluz.pt](mailto:bernardo.vidal.pimentel@hospitaldaluz.pt))

This work is licensed under a [Creative Commons Attribution 4.0 International License](https://creativecommons.org/licenses/by/4.0/).

Author(s) retain the copyright for their work. At the time of submission to POCUS Journal the author(s) grant the journal a limited and non revokable right to publish in the Journal under a [Creative Commons Attribution 4.0 International License](https://creativecommons.org/licenses/by/4.0/).

DOI: <https://doi.org/10.24908/pocus.v8i2.16562>

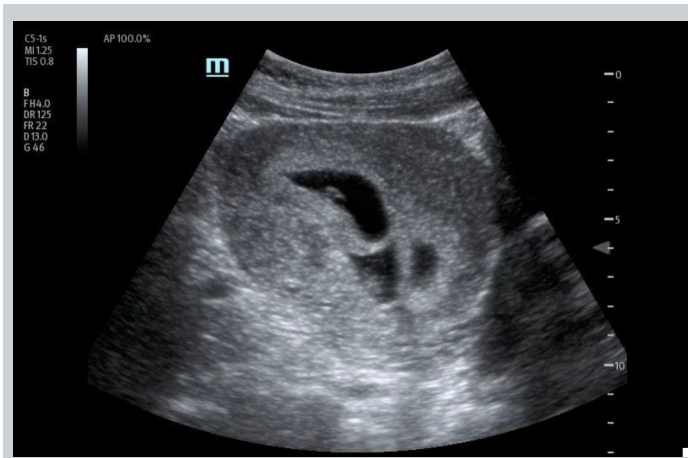

Figure 1. Bladder uterine juxtaposition.

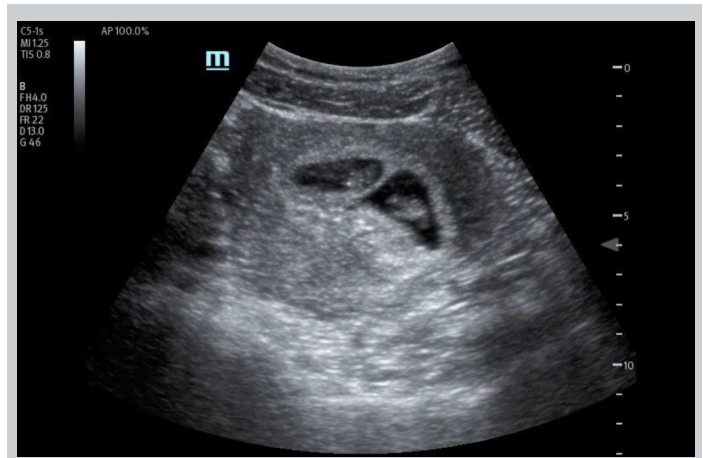

Figure 4. Right and left superior fetal poles.

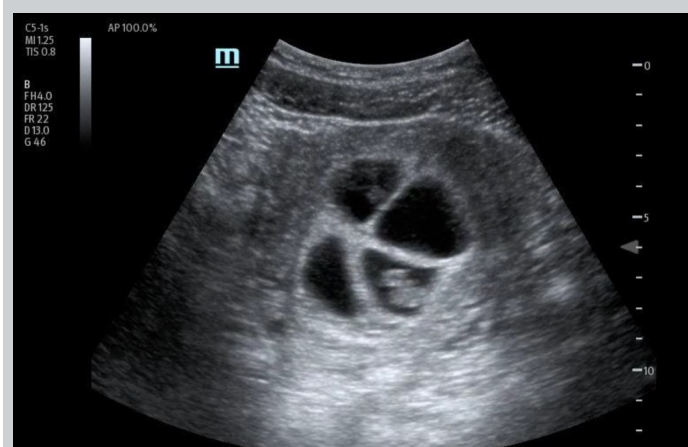

Figure 2. Four gestational sacs.

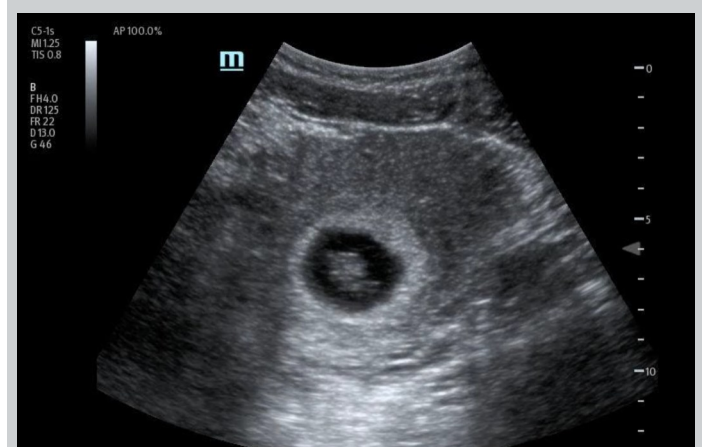

Figure 5. Right inferior fetal pole.

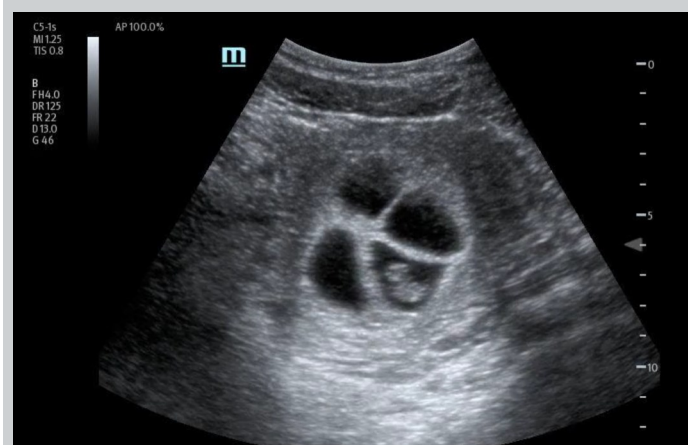

Figure 3. Left inferior fetal pole.

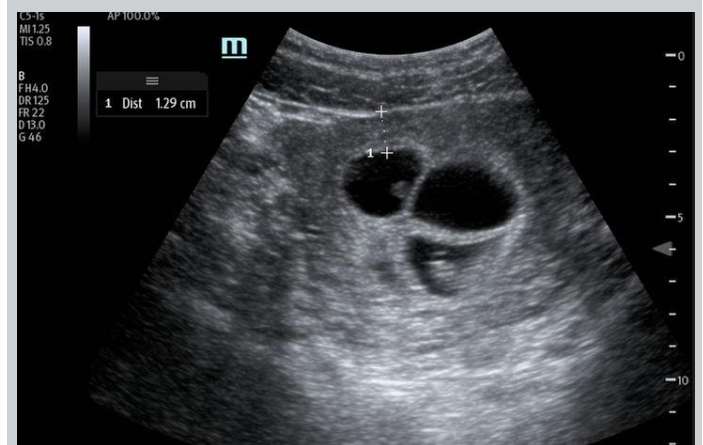

Figure 6. Myometrial Mantle Thickness.

Following the diagnosis, the patient was discharged from the emergency department with an urgent appointment booked with the on-call Obstetrician-Gynecologist for further management and follow-up. Due to the POCUS and comprehensive ultrasound exams identifying multiple gestations, we were able to provide the patient urgent follow up for her high-risk pregnancy. Typically, first

trimester patients with vaginal bleeding at our center are referred to our Early Pregnancy Assessment Unit (EPAU), which does not always necessitate a call to the on-call Obstetrician-Gynecologist.

Additionally, we hereby declare that the referred patient provided us with her verbal consent and had the opportunity to review this manuscript.

## Discussion

Multiple pregnancies including quadruplet pregnancies are rare and associated with increased risks of adverse maternal and neonatal outcomes [5]. Multiple pregnancies following assisted reproductive technology are associated with similar if not higher risks such as ectopic or heterotopic pregnancy and ovarian hyperstimulation syndrome [6]. The accurate identification of multiple gestations such as quadruplet pregnancies through POCUS enables healthcare providers to initiate timely and appropriate prenatal care, including close monitoring and management of potential complications [2-4].

Our case file highlights the utility of POCUS in providing crucial information regarding gestational age and viability in a patient presenting with first-trimester vaginal bleeding. Prior to our examination, the patient was unaware that she was pregnant. Furthermore, POCUS facilitated early diagnosis and referral for high-risk prenatal care. Early initiation of prenatal care has been associated with positive outcomes, including reduced neonatal and infant mortality rates and decreased incidence of low birth weight [7].

It is important to acknowledge the limitations of transabdominal obstetric POCUS. Firstly, it should be noted that transabdominal POCUS cannot definitively rule out ectopic pregnancy. A recent systematic review encompassing both transabdominal and/or transvaginal POCUS examinations performed by emergency physicians reported a sensitivity of only 90% [8]. Secondly, transabdominal ultrasound demonstrates lower diagnostic accuracy compared to transvaginal ultrasound, particularly in cases of ectopic tubal pregnancy [9-11]. Third, it typically can only confirm the diagnosis of intrauterine gestation after the 6-8<sup>th</sup> week of pregnancy, particularly when the fetal heart rate becomes detectable around the 8<sup>th</sup> week [12]. As a result, providers should not solely rely on POCUS as a substitute for comprehensive obstetric ultrasound examinations.

To our knowledge, this is the first case report to identify four live intrauterine gestations using obstetric POCUS. Utilizing POCUS in patients with high-risk multiple pregnancies who have undergone assisted reproduction can aid in the assessment and management of potential complications.

In this case, POCUS correctly identified multiple viable live intrauterine gestations and helped facilitate appropriate prenatal care and follow-up.

## Disclosures

The authors have no disclosures related to this work.

## References

1. Leidi A, Rouyer F, Marti C, Reny J, Groscurin O. Point of care ultrasonography from the emergency department to the internal medicine ward: current trends and perspectives. *Internal and emergency medicine* 2020; 15(3):395-408.
2. Dietrich CF, Goudie A, Chiorean L, et al. Point of care ultrasound: a WFUMB position paper. *Ultrasound in medicine & biology* 2017; 43(1):49-58.
3. Ganchi FA, Hardcastle TC. Role of Point-of-Care Diagnostics in Lower-and Middle-Income Countries and Austere Environments. *Diagnostics* 2023; 13(11):1941.
4. Kim ET, Singh K, Moran A, Armbruster D and Kozuki N. Obstetric ultrasound use in low and middle income countries: a narrative review. *Reproductive health* 2018; 15:1-26.
5. Benirschke K and Kim CK. Multiple pregnancy. *New England Journal of Medicine* 1973; 288(24):1276-1284.
6. Doyle P. The outcome of multiple pregnancy. *Human Reproduction* 1996; 11(suppl\_4):110-120.
7. Qin J, Wang H, Sheng X, Liang D, Tan H, Xia J. Pregnancy-related complications and adverse pregnancy outcomes in multiple pregnancies resulting from assisted reproductive technology: a meta-analysis of cohort studies. *Fertility and sterility* 2015; 103(6):1492-1508.
8. Kuhnt J, Vollmer S. Antenatal care services and its implications for vital and health outcomes of children: evidence from 193 surveys in 69 low-income and middle-income countries. *BMJ open* 2017; 7(11): e017122.
9. McRae A, Edmonds M, Murray H. Diagnostic accuracy and clinical utility of emergency department targeted ultrasonography in the evaluation of first-trimester pelvic pain and bleeding: a systematic review. *Canadian Journal of Emergency Medicine* 2009; 11(4): 355-364.
10. Li, Yinghui, Tao Feng, Jiandong Sun. Evaluation of clinical effect of transabdominal sonography and transvaginal sonography in early diagnosis of ectopic gestation. *Pakistan Journal of Medical Sciences* 2017; 33(1):53.
11. Nahar, MN, Quddus MA, Sattar A et al. Comparison of transvaginal and transabdominal ultrasonography in the diagnosis of ectopic pregnancy. *Bangladesh Medical Research Council Bulletin* 2013; 39(3):104-108.
12. Hu, HJ, Sun J, Feng R, et al. Comparison of the application value of transvaginal ultrasound and transabdominal ultrasound in the diagnosis of ectopic pregnancy. *World Journal of Clinical Cases* 2023; 11(13):2945.
13. Soni NJ, Arntfield R, Kory P. *Point of care ultrasound, 2<sup>nd</sup> edition.* Elsevier Health Sciences, 2019.

# Role of POCUS in Assessing an Acute Aortic Thrombus

Zachary Boivin, MD<sup>1\*</sup>; Emily Mensel, MD<sup>2</sup>; Trent She, MD<sup>2</sup>

(1) University of Connecticut Emergency Medicine Residency, Farmington, CT, USA

(2) Department of Emergency Medicine, Hartford Hospital, Hartford, CT, USA

## Abstract

A 67-year-old female patient presented with abdominal pain with a recent diagnosis of paroxysmal atrial fibrillation. Computed tomography (CT) of the abdomen demonstrated a filling defect concerning for an aortic thrombus. Point of care ultrasound (POCUS) confirmed a mobile thrombus in the proximal abdominal aorta in close proximity to several major arterial branches, leading to urgent surgical consultation due to a concern for mesenteric and end-organ ischemia. POCUS played a role in determining patient management in this novel case, and the patient was anticoagulated and ultimately discharged from the hospital.

## Presentation

A 67-year-old female patient with a past medical history of hypertension presented to the emergency department (ED) with abdominal pain. She reported intermittent palpitations for the past three months, fevers for one week, and a recent admission three days prior for a pleural effusion and atrial fibrillation. Her pleural effusion was drained; cytology was negative for malignancy. She was not discharged on rate or rhythm controlling agents, nor was she anticoagulated. She was given urgent outpatient follow up but returned to the ED sooner than her appointment due to worsening symptoms.-

In her second ED visit, she complained of upper abdominal pain along with palpitations and weakness. Her physical exam was normal, with her abdomen soft and nontender. She was found to have a leukocytosis of  $23.7 \times 10^3/\mu\text{L}$ , a normal creatinine of 0.8 mg/dL, a rising lactic acid from 1.5 mmol/L to 2.7 mmol/L. A computed tomography (CT) of the abdomen and pelvis with intravenous contrast revealed concern for a proximal aortic thrombus and an acute renal infarction (Figure 1). The patient was placed on a heparin infusion and surgical consultation was obtained. At this time, point of care ultrasound (POCUS) was performed to further assess and characterize the potential thrombus. A mobile,

hyperechoic thrombus was located within the aorta at the level of the celiac trunk that moved both proximally and distally with aortic pulsations (Figure 2, Video S1, Video S2). The aorta was not noted to be aneurysmal, nor was a dissection identified on either CT or POCUS.

After discussion with the ED and vascular surgical team, the patient was deemed to be a high risk for mesenteric ischemia due to thrombus mobility, location, and the presence of a renal infarct. Conservative management was favored due to the patient's recent fevers and leukocytosis. The patient was admitted to the medical step-down unit with repeat imaging planned in 48 hours with close monitoring to ensure no further signs of thrombus progression. She had a formal transthoracic echocardiogram performed which did not reveal any cardiac abnormalities or shunt. The patient remained on anticoagulation, and she was discharged home after an uneventful seven-day hospital stay with outpatient follow-up. Workups for both hypercoagulability and malignancy were unrevealing. There was concern the aortic thrombus was related to her new-onset atrial fibrillation, but no definitive cause was established.

## Discussion

Previous literature suggests multiple potential causes of aortic thrombi, including intrinsic aortic pathology such as

---

\*Corresponding Author: Zachary Boivin, MD (email: [Zboivin.md@gmail.com](mailto:Zboivin.md@gmail.com))

This work is licensed under a [Creative Commons Attribution 4.0 International License](https://creativecommons.org/licenses/by/4.0/).

Author(s) retain the copyright for their work. At the time of submission to POCUS Journal the author(s) grant the journal a limited and non-revokable right to publish in the Journal under a [Creative Commons Attribution 4.0 International License](https://creativecommons.org/licenses/by/4.0/).

DOI: <https://doi.org/10.24908/pocus.v8i2.16480>

Figure 1. Computed tomography image showing an abdominal aortic thrombus (yellow arrow).

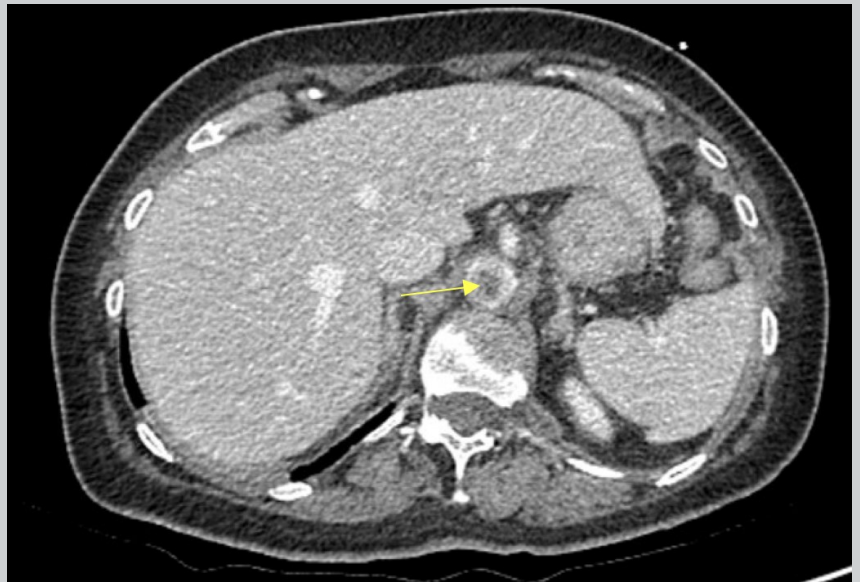
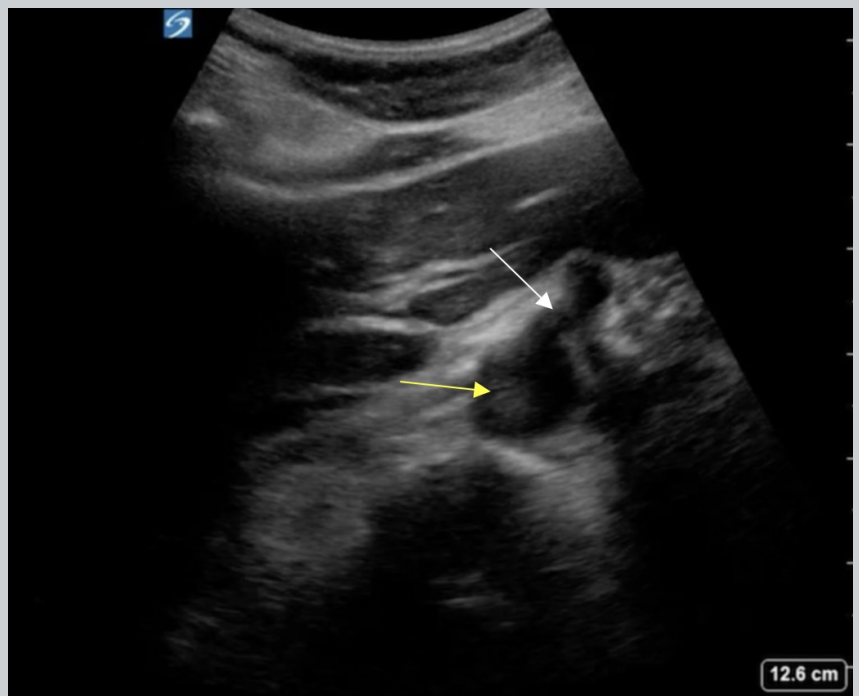

Figure 2. Abdominal aortic thrombus (yellow arrow) at the level of the celiac trunk (white arrow).



dissection or abdominal aortic aneurysm (AAA), or extrinsic causes such as hypercoagulability [1-5]. Both the aortic thrombus and associated intrinsic aortic pathology can be visualized with POCUS. When an aortic thrombus is associated with a dissection, the echogenic thrombus is seen with a visible flap on POCUS that is thinner and attached to the wall of the aorta [2]. An associated thrombus with an AAA (when the aorta is  $\geq 3$  cm in diameter) is seen in a false lumen surrounding the true lumen of the aorta [6]. While an aortic thrombus in the descending aorta can be easily visualized with abdominal POCUS, an aortic arch thrombus can only be visualized with a suprasternal cardiac POCUS view, which can be difficult to obtain [7].

A thrombus from atrial fibrillation is typically smaller than from other causes, as it typically breaks off from a larger left atrial thrombus, and can travel distally causing solid organ damage, mesenteric ischemia, or limb ischemia [8, 9]. This is the primary reason patients with atrial fibrillation are considered for anticoagulation. We could not find any prior reports of POCUS assessment of an aortic thrombus in the proximal abdominal aorta, as other reports detail use of CT and cardiology-performed echocardiogram [3, 10-12].

We suspect that this patient was in paroxysmal atrial fibrillation during the three months she reported palpitations, which may have been the cause of her aortic thrombus. She had a calculated CHA2DS2-VASc



score of 3 for age, sex, and hypertension, making her a moderate-high risk with a recommendation favoring anticoagulation [13]. Without anticoagulation, she was at high risk for both development and propagation of thrombus. While atrial fibrillation offers a potential etiology, especially since no alternate etiology was found, this is an unusual cause of proximal aortic thrombus as thrombi from atrial fibrillation often travel more distally due to its size and the aorta's high velocity flow [5].

The initial treatment for acute abdominal aortic thrombus is therapeutic anticoagulation with operative intervention considered on a case-by-case basis [4, 11, 14-17]. The selection of therapy must balance the benefit of preventing further embolic complications against the risk of iatrogenic thrombus propagation. Mobile thrombi that are in proximity to solid organs or vascular branches of the aorta, particularly those that are persistent through anticoagulation, often require endovascular or open intervention. POCUS can play a large role in decision making after diagnosis, providing real-time information on thrombus mobility and treatment efficacy during hospitalization, and may decrease the number of repeat CT scans needed to assess for thrombus resolution, saving the patient radiation, time, and contrast loads. This novel use of aortic POCUS is not meant to replace the use of CT, but it can augment patient care during admission as an adjunctive imaging technique with serial POCUS exams to provide additional information about the thrombus. In our case, the mobility of the thrombus as well as its location close to several major aortic vascular branches were key pieces of information ascertained by POCUS that were major factors in our patient's care.

## Conclusion

The use of POCUS during this case was important to further characterize the dynamic movement of the thrombus that was not captured on CT scan. Although the information gained from POCUS was utilized for initial decision making, the patient was ultimately discharged on anticoagulation without intervention, with atrial fibrillation as a potential cause of her aortic thrombus given a lack of other identifiable etiology.

## Statement of Consent

Informed consent was obtained from the patient by the authors. The patient has consented to the use of de-identified images, video clips, and health information to be published within the journal.

## Disclosures

The authors have no disclosures related to this work.

## References

1. Yee AM, Etebari CV, Adhikari S, Amini R. Point of Care Ultrasound Diagnosis of a Massive Thoracoabdominal Aortic Aneurysm. *Cureus*. 2017;9(8):e1611. <https://doi.org/10.7759/cureus.1611>.
2. Earl-Royal E, Nguyen PD, Alvarez A, Gharahbaghian L. Detection of Type B Aortic Dissection in the Emergency Department with Point-of-Care Ultrasound. *Clin Pract Cases Emerg Med*. 2019;3(3):202-7. <https://doi.org/10.5811/cpcem.2019.5.42928>.
3. Khine K, Toor A, Khalighi K, Krishnamurthy M. Incidental descending thoracic aortic thrombus: the conundrum of medical versus surgical therapy. *J Community Hosp Intern Med Perspect*. 2019;9(6):491-4. <https://doi.org/10.1080/20009666.2019.1684230>.
4. Maloberti A, Oliva F, De Chiara B, Giannattasio C. Asymptomatic aortic mural thrombus in a minimally atherosclerotic vessel. *Interact Cardiovasc Thorac Surg*. 2016;22(3):371-3. <https://doi.org/10.1093/icvts/ivv349>.
5. Agarwal KK, Douedi S, Alshami A, DeJene B, Kayser RG. Peripheral Embolization of Left Ventricular Thrombus Leading to Acute Bilateral Critical Limb Ischemia: A Rare Phenomenon. *Cardiol Res*. 2020;11(2):134-7. <https://doi.org/10.14740/cr1030>.
6. Beales L, Wolstenhulme S, Evans JA, West R, Scott DJ. Reproducibility of ultrasound measurement of the abdominal aorta. *Br J Surg*. 2011;98(11):1517-25. <https://doi.org/10.1002/bjs.7628>.
7. Kinnaman KA, Kimberly HH, Pivetta E, Platz E, Chudgar A, Adduci A, et al. Evaluation of the Aortic Arch from the Suprasternal Notch View Using Focused Cardiac Ultrasound. *J Emerg Med*. 2016;50(4):643-50.e1. <https://doi.org/10.1016/j.jemermed.2015.12.002>.
8. Lyaker MR, Tulman DB, Dimitrova GT, Pin RH, Papadimos TJ. Arterial embolism. *Int J Crit Illn Inj Sci*. 2013;3(1):77-87. <https://doi.org/10.4103/2229-5151.109429>.
9. Bloom B, Gibbons R, Brandis D, Costantino TG. Point-of-care Ultrasound Diagnosis of Acute Abdominal Aortic Occlusion. *Clin Pract Cases Emerg Med*. 2020;4(1):79-82. <https://doi.org/10.5811/cpcem.2019.11.44311>.
10. Sugiura T, Dohi Y, Yamashita S, Murai S, Ohte N. A case report of asymptomatic aortic thrombosis incidentally detected by computed tomography in apparently healthy subject with a history of cancer surgery. *Thromb J*. 2016;14:16. <https://doi.org/10.1186/s12959-016-0090-4>.
11. Yang S, Yu J, Zeng W, Yang L, Teng L, Cui Y, et al. Aortic floating thrombus detected by computed tomography angiography incidentally: Five cases and a literature review. *J Thorac Cardiovasc Surg*. 2017;153(4):791-803. <https://doi.org/10.1016/j.jtcvs.2016.12.015>.
12. Quach N, Medina M, Burton É. Incidentally Found Ascending Aortic Thrombus. *JACC: Case Reports*. 2021;3(13):1489-93. <https://doi.org/10.1016/j.jaccas.2021.07.027>.
13. Harb SC, Wang TKM, Nemer D, Wu Y, Cho L, Menon V, et al. CHA (2)DS(2)-VASc score stratifies mortality risk in patients with and without atrial fibrillation. *Open Heart*. 2021;8(2) <https://doi.org/10.1136/openhrt-2021-001794>.
14. Martins APD, Bertolucci LH, Warpechowski RB, Angonese A, de Azevedo MS, Rodrigues C, et al. Mobile thrombus of the abdominal aorta: a narrative review. *J Vasc Bras*. 2022;21:e20220028. <https://doi.org/10.1590/1677-5449.202200282>.
15. Meyermann K, Trani J, Caputo FJ, Lombardi JV. Descending thoracic aortic mural thrombus presentation and treatment strategies. *J Vasc Surg*. 2017;66(3):931-6. <https://doi.org/10.1016/j.jvs.2017.05.109>.
16. Fayad ZY, Semaan E, Fahoum B, Briggs M, Tortolani A, D'Ayala M. Aortic mural thrombus in the normal or minimally atherosclerotic aorta. *Ann Vasc Surg*. 2013;27(3):282-90. <https://doi.org/10.1016/j.avsg.2012.03.011>.
17. Siani A, Accrocca F, De Vivo G, Mounayergi F, Marcucci G. Endovascular Treatment of Symptomatic Thrombus of the Descending Thoracic Aorta. *Ann Vasc Surg*. 2016;36:295.e13-e16. <https://doi.org/10.1016/j.avsg.2016.03.027>.

# Renal Transplant Artery Stenosis and Kinking: An Unusual Association

R. Haridian Sosa Barrios, MD, MSc<sup>1-3\*</sup>; V. Burguera Vion, MD, MSc<sup>1,3</sup>; E. Casillas Sagrado, MD<sup>1</sup>; D. Villa Hurtado, MD<sup>1,3</sup>; S. Jiménez Álvaro MD<sup>1</sup>; I. Martín Capón, MD<sup>1</sup>; M. Fernández Lucas, MD, PhD<sup>1,2</sup>; Maite E. Rivera Gorrín, MD, PhD<sup>1-3</sup>

(1) Hospital Universitario Ramón y Cajal, IRYCIS, Madrid, Spain

(2) Universidad de Alcalá de Henares, UAH, Madrid, Spain

(3) Grupo de Nefrología Diagnóstica e Intervencionista de la Sociedad Española de Nefrología (GNDI), Madrid, Spain.

## Abstract

Renal artery stenosis of the kidney allograft associated with kinking is not a frequent finding. As a correctable cause of graft dysfunction, it is important to diagnose it as soon as possible to avoid further graft damage and improve graft and patient survival. As pulsed wave Doppler ultrasound mapping of the graft's renal arteries is essential to diagnose possible alterations, point of care ultrasound (POCUS) is a highly useful tool for early diagnosis. We present a case in which nephrologists performed this examination promptly allowing a timely diagnosis and treatment plan.

## Introduction

Renal artery stenosis of the kidney allograft is an infrequent finding, as is mechanical kinking of the artery. The right renal artery's greater length in comparison to the vein, limited space within the iliac fossa, and post-operative shifting in graft components all increase the likelihood of kinking. Renal artery stenosis and kinking can either coexist or kinking can result in stenosis. Nevertheless, since both these abnormalities can be corrected with timely treatment, early diagnosis is crucial to prevent permanent to the renal allograft.

Nephrologist-performed point of care ultrasound (POCUS) can be used to diagnose renal artery dysfunction in the allograft and expedite appropriate next steps in management. Doppler ultrasound mapping of the renal transplant is an effective, inexpensive, and reproducible test that provides relevant information in such scenario. We present a case in which POCUS evaluation of a renal transplant promptly identified renal artery stenosis (RAS) and led to the diagnosis of renal artery kinking.

## Case Report

A 61-year-old woman with end-stage kidney disease due to autosomal dominant polycystic kidney disease

(ADPKD) started hemodialysis in December 2018 through a brachio-cephalic arteriovenous fistula. Her past medical history included hypertension and dyslipidemia. Eight months later, she had an expanded criteria deceased donor kidney transplant implanted in her right iliac fossa with one renal vein anastomosed end-to-side with the external iliac vein, and the renal artery anastomosed end-to-side with the external iliac artery. She had low immunological risk with 0% panel reactive antibodies and her immunosuppressive therapy included induction with basiliximab and triple therapy (tacrolimus, everolimus and steroids). A protocol ultrasound Doppler mapping of the kidney graft was done 24 hours post biopsy by an interventional nephrologist as per our center protocol, showing a normal sized graft with good general perfusion, no collections or hydronephrosis and normal intrarenal spectral Doppler registries. Serum creatinine started improving on day 6 post-transplant but halted two weeks post-operatively. Blood pressure was within acceptable levels and similar to her usual values at home (100-130/65-72 mmHg), there were no electrolyte abnormalities and cytomegalovirus viral load was undetectable. Prerenal causes were ruled out and her tacrolimus level was within goal range (7-9 ng/ml), so a kidney transplant ultrasound was performed by another interventional nephrologist, showing high velocities within

\*Corresponding Author: R. Haridian Sosa Barrios (email: haridian@gmail.com)

This work is licensed under a [Creative Commons Attribution 4.0 International License](https://creativecommons.org/licenses/by/4.0/).

Author(s) retain the copyright for their work. At the time of submission to POCUS Journal the author(s) grant the journal a limited and non revokable right to publish in the Journal under a [Creative Commons Attribution 4.0 International License](https://creativecommons.org/licenses/by/4.0/).

DOI: <https://doi.org/10.24908/pocus.v8i2.16461>

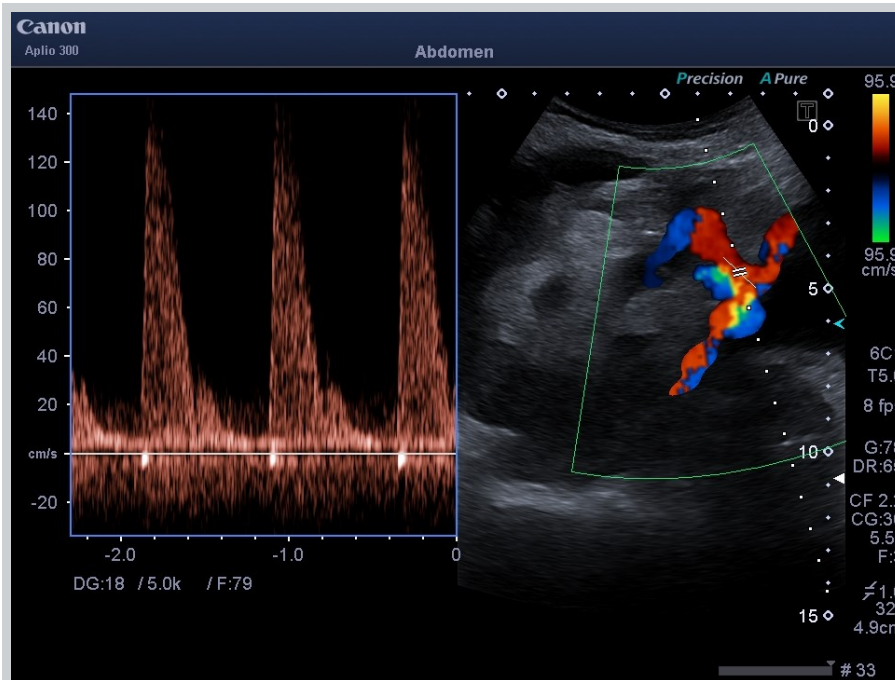


Figure 1. POCUS pulsed wave Doppler with aliasing at anastomosis level showing turbulent flow even when adjusted for high pulse repetition frequency to reduce noise.

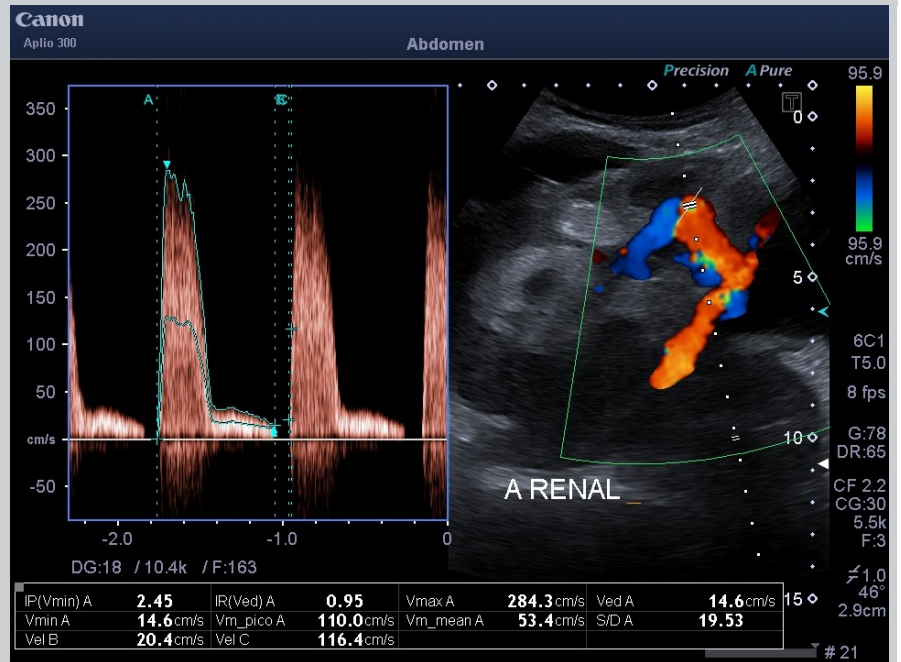


Figure 2. High velocities >200 cm/s at kidney transplant artery kinking. Also, aliasing at anastomosis level.

the graft renal artery near the iliac artery anastomosis with aliasing (confetti-like pattern) suggesting turbulent flow, increasing in the vicinity of a kinking image near the renal hilum (Figure 1,2,3) even when pulse repetition frequency (PRF) was adjusted for high velocities (> 95.9 cm/s). The sample volume (approximately 2 mm) was placed inside the renal artery and measurements were taken at the anastomosis, along the artery and at the hilum, with an angle of insonation between 30 to 60° to minimize alterations of flow velocities and waveform blunting. These findings were not present on POCUS examination performed on postoperative day 1.

A computerized tomography (CT) angiogram was performed, confirming RAS at the anastomosis, and kinking of the graft renal artery (Figure 4). High velocities were also observed within the iliac artery before the anastomosis. This CT angiogram allowed radiologists to measure the diameter of the stenotic area and decide on balloon size, as well as assessing feasibility of stenting, which was deemed not suitable due to high risk of thrombosis.

After a careful multidisciplinary evaluation, a sequential approach was devised: endovascular angioplasty of the stenotic area without stenting (due to high thrombotic risk

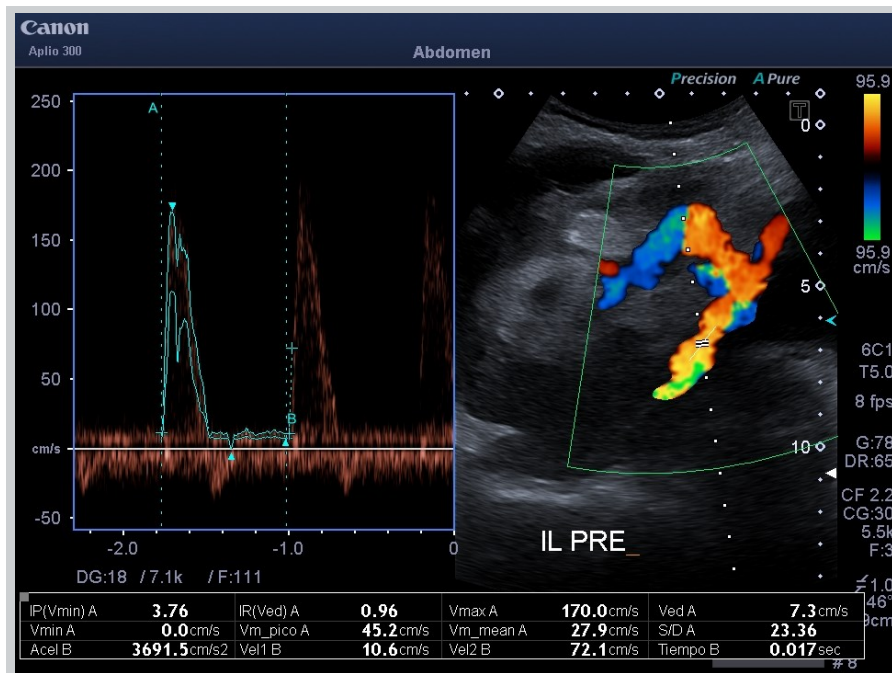


Figure 3. High velocities also in the iliac artery pre anastomosis.

secondary to associated kinking) was performed, but unsuccessful. Doppler parameters suggestive of RAS persisted (peak systolic velocity 284.3 cm/s at 46° insonation angle) with deteriorated renal function, and open surgery vascular reconstruction was carried out a week after angioplasty: shortening of the renal artery with reimplantation to iliac artery was performed. Within a week, there was a graft function improvement and hemodynamic parameters on the follow up POCUS were within normal range.

## Discussion

Transplantation is the best renal replacement therapy nephrologists can offer, providing better survival and quality of life, generally. Improving kidney transplant outcomes remains a primary challenge from both medical and surgical point of view. RAS refers to a narrowing within the renal artery, where the lumen must exhibit a minimum reduction of 50% to hold hemodynamic significance. Renal artery Doppler US is usually the first line imaging test and universally accepted criteria for RAS diagnosis is a peak systolic velocity of >180 cm/s at the level of stenosis [1]. RAS of the kidney graft is a correctable cause of hypertension and graft dysfunction in kidney transplant recipients. Its incidence is widely variable, ranging from 1 to 23% [2], and several risk factors may contribute to its development, like extended criteria donors, surgical technique, atheroma, and immunological vascular damage. Kinking of the graft artery is rare in association with stenosis, worsening prognosis as kinking renders angioplasty less effective. As mentioned, kinking of the transplant renal artery is usually related to graft malposition, lack of space in the iliac fossa and a longer graft artery with shorter vein, and

its incidence is very low with few cases reported [3-6].

Mapping of the renal transplant using POCUS is an inexpensive and reproducible test that provides relevant information [7]. At our tertiary center, our Unit has a transplant ultrasound protocol where all patients have an examination with both two-dimensional and Doppler POCUS on day one post operatively, then every 48 hours until discharge and whenever the treating physician deems necessary. A formal report is generated, validated and images are archived for every scan.

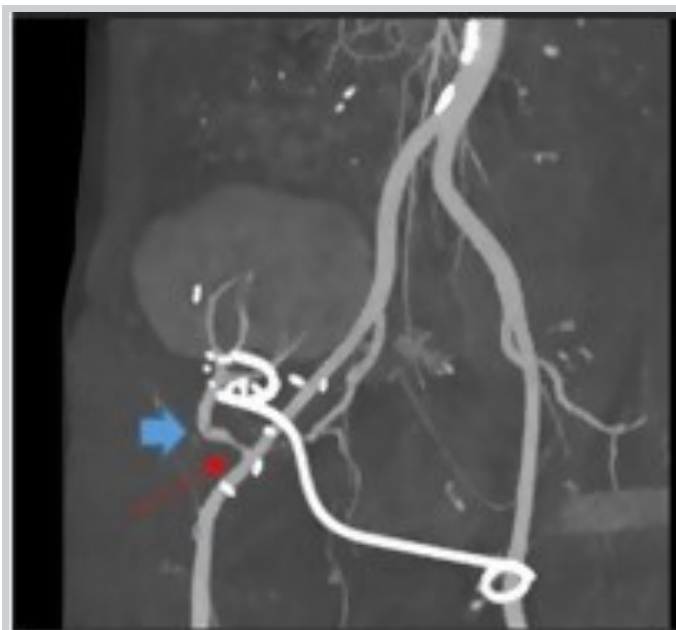

Figure 4. CT scan reconstruction showing both kidney transplant artery stenosis (red arrow) and kinking (blue arrow).

We have a specialized Diagnostic and Interventional Nephrology (DIN) Unit which has been operating since 1991, with all medical staff trained in Doppler ultrasonography of both native (NK) and transplanted kidneys (KT). Starting in 1991, renal biopsies and 2D renal ultrasound examinations were performed by nephrologists on both NK and KT cases with an average of 2200 ultrasound scans, 500 Doppler studies and 100–120 biopsies per year with a daily scheduled list [8-10]. All our Nephrology specialist registrars spend at least 6 dedicated months during the 4-year training period in the DIN Unit, excluding on call procedures.

Since 2008 our Section has accommodated approximately 20 external Nephrology specialist registrars each year from national hospitals. Additionally, we have been providing educational workshops at a national scale since 2013, focusing on kidney ultrasound, arteriovenous fistula mapping and Doppler assessment.

A structured POCUS examination should be performed in all kidney transplant patients. Complete pulsed wave Doppler mapping of the graft's renal arteries is essential to diagnose possible alterations, as more than one issue can arise. Kinking is rare and should be kept in mind [11,12], even if a stenosis is seen, like in this case, the pathology leading to hemodynamic changes could be other than RAS, change prognosis and management. In our case, we believe the lack of abdominal space due to ADPKD could have played a role in the renal artery kinking.

## Conclusion

In conclusion, we believe a protocolized Doppler ultrasound mapping of the transplanted kidney is essential when graft dysfunction is observed. This case illustrates the importance of POCUS for nephrologists: early diagnosis is the key, and nephrologists with proper training in POCUS can promptly perform this examination.

## Conflict of Interest

All authors declare there are no conflicts of interest.

## Ethical approval

All procedures performed in studies involving human participants were in accordance with the ethical standards of the institutional research committee and with the 1964 Helsinki declaration and its later amendments or comparable ethical standards. This article does not contain any studies with animals performed by any of the authors.

## Informed consent

Informed consent from the patient was obtained. All images were anonymized to reduce likelihood of identification.

## References

1. Introduction to Vascular Ultrasonography, 4th Edition, by William J. Zwiebel, W.B. Saunders Company, Philadelphia, PA, 2000. ISBN: 0-721-66949-2
2. Audard V, Matignon M, Hmery F et al. Risk factors and long-term outcome of transplant renal artery stenosis in adult recipients after treatment by percutaneous transluminal angioplasty. *Am J Transplant*. 2006;6(1):95.
3. Adibelli Z, Woo E, Abt P, Goral S, Elevated serum creatinine in a kidney transplant recipient: unusual suspect, *Clin. Nephrol.* 78 (10) (2012) 322–324, <https://doi.org/10.5414/cn107121>.
4. Chua GC, Snowden S, Patel U, Kinks of the transplant renal artery without accompanying Intraarterial pressure gradient do not require correction: five-year outcome study, *Cardiovasc. Intervent. Radiol.* 27 (6) (2004) 643–650, <https://doi.org/10.1007/s00270-003-0156-0>.
5. DeVries BL, Wechsler B, Yim D. Case report of transplant renal artery stenosis secondary to mechanical renal artery kinking: Balloon angioplasty as a supportive diagnostic tool? *Int J Surg Case Rep.* 2021 Jun;83:106052. doi: 10.1016/j.ijscr.2021.106052. Epub 2021 May 29.
6. Hawlina S, Orožen B, Arnol M and Kšela J (2022) Use of absorbable hemostat bolster for prevention of donor renal artery kinking in kidney transplant. *Front. Surg.* 9:1032946. doi: 10.3389/fsurg.2022.1032946
7. Taylor KJ, Morse SS, Rigsby CM, Bia M, Schiff M: Vascular complications in renal allografts: Detection with duplex Doppler US. *Radiology* 1987;162:31–38.
8. Rivera M, Ortuño J. Ultrasonography in nephrology. *Am J Kidney Dis.* 1998;32(4):703. doi: 10.1016/S0272-6386(98)70040-X
9. Rivera M, Merino JL, Puig-Hooper C, et al. Interventional nephrology: a one-center experience for 15 years. *J Am Soc Nephrol.* 2006;17:754<sup>a</sup>. doi: 10.1681/ASN.2005050571.
10. Rivera M. Incorporación de la ecografía a la práctica rutinaria del nefrólogo: nuestra experiencia. *Nefrología* 1995;15:104-7.
11. Krumme B, Pisarski P, Blum U, Kirste G, Schollmeyer P: Unusual Cause of Early Graft Dysfunction after Kidney Transplantation. *Am J Nephrol* 1998;18:237-239. doi: 10.1159/000013343.
12. Reddy VK, Guleria S, Abdullah SM, Bansal R. A kink in transplantation: A rare cause of early graft dysfunction. *Saudi J Kidney Dis Transpl* 2013;24:965-8.

# Troubleshooting Paracentesis Using POCUS

Angelina Voronina, DO<sup>1,2\*</sup>; Nachele Aurelien, MD<sup>1</sup>; Edward Bergin, MD<sup>1,3</sup>; Paula Roy-Burman, MD, MPH, DTM&H<sup>1</sup>

(1) Weill Cornell Medical Center, Department of General Internal Medicine, Section of Hospital Medicine

(2) New York-Presbyterian Queens, Department of Pulmonary/Critical Care

(3) Campbell County Memorial Hospital; Sidney Health Center

## Abstract

Paracentesis is a procedure routinely performed at the bedside in the evaluation and management of ascites. While point of care ultrasound (POCUS) assistance during paracentesis is known to reduce the risk of procedure-related complications, intraprocedural POCUS to overcome commonly occurring issues, such as obstructed flow through the centesis catheter, remain poorly described. In this report, we present two cases in which bowel adhered to the catheter during paracentesis. POCUS was used in an attempt to restore flow. Based on our literature review and procedural experience, we propose an algorithm to surmount this routinely encountered problem.

## Introduction

Ascites, or the pathologic accumulation of fluid within the abdominal cavity, can be the result of multiple processes. Cirrhosis is the most common etiology in the United States; left untreated, it portends a 60% risk of developing ascites within the first ten years of diagnosis [1]. Accumulation of ascites often necessitates fluid removal with paracentesis – a procedure of percutaneously inserting a catheter or hollow needle through the abdominal wall into the peritoneal space – for symptom relief and/or laboratory analysis. Medicare data demonstrate that from 1993 to 2008 the number of paracenteses performed in the United States have more than doubled from 64,371 to 149,699 [2]. Concomitantly, data from 2004 to 2012 demonstrate a 10% increase in the number of paracentesis procedures performed in the inpatient setting [3].

Paracentesis is a generally well-tolerated procedure. Adverse events are estimated at 1% and include infection, post-procedural leakage of ascitic fluid, abdominal wall hematoma, bowel perforation, and intraperitoneal hemorrhage [1, 4-14]. There are additional intraprocedural concerns such as the aspiration of intestinal wall or omentum into the centesis catheter, or the placement of the catheter tip within the abdominal soft tissue. Though the frequency of these latter complications are not well described, they may result in unsuccessful paracentesis through disruption of ascites drainage [15].

Pre-procedural point of care ultrasound (POCUS) is known to minimize the risks of paracentesis by identifying a safe procedural site, and is widely acknowledged as the standard of care [4, 6, 10-14, 16]. However, there is a paucity of literature which considers the role of intraprocedural POCUS in troubleshooting poor or interrupted ascitic drainage. Here, we present two cases of failed peritoneal drainage and the techniques utilized to restore flow through the catheter. We analyze our experience and posit how direct visualization by POCUS may improve the success of paracentesis drainage.

## Case 1

A 23-year-old man with metastatic cancer of unknown origin complicated by ascites requiring repeated intraperitoneal drainage presented to the hospital with abdominal pain, distension, and early satiety. Our inpatient procedure service was consulted for therapeutic paracentesis. POCUS was used to identify a safe pocket in the right lower quadrant, approximately 10 cm in depth (Figure 1a). Ultrasound-assisted paracentesis was performed according to standard protocol adopted by our local institution. Eight-hundred milliliters of amber-colored fluid collected into an evacuated container before drainage abruptly ceased. The operators attempted to restore flow through the intraperitoneal catheter by discontinuing vacuum suction (i.e., closing the three-way stopcock on the tubing system), rotating the catheter by 180° in clockwise and counterclockwise directions, and

\*Corresponding Author: Angelina Voronina, DO (email: anv9109@nyp.org; par2015@med.cornell.edu)

This work is licensed under a [Creative Commons Attribution 4.0 International License](https://creativecommons.org/licenses/by/4.0/).

Author(s) retain the copyright for their work. At the time of submission to POCUS Journal the author(s) grant the journal a limited and non revokable right to publish in the Journal under a [Creative Commons Attribution 4.0 International License](https://creativecommons.org/licenses/by/4.0/).

DOI: <https://doi.org/10.24908/pocus.v8i2.16265>

Figure 1. 23-year-old man with metastatic cancer of unknown origin complicated by ascites. A) Pre-procedure POCUS exam demonstrating a large pocket of ascites in the right lower quadrant of the patient described in Case 1. [Asterisk = liver] B) Intraprocedural POCUS demonstrating paracentesis catheter attached to omentum/bowel. Note that the ultrasound probe was inadvertently flipped in this image. [Arrow = catheter; asterisk = liver]

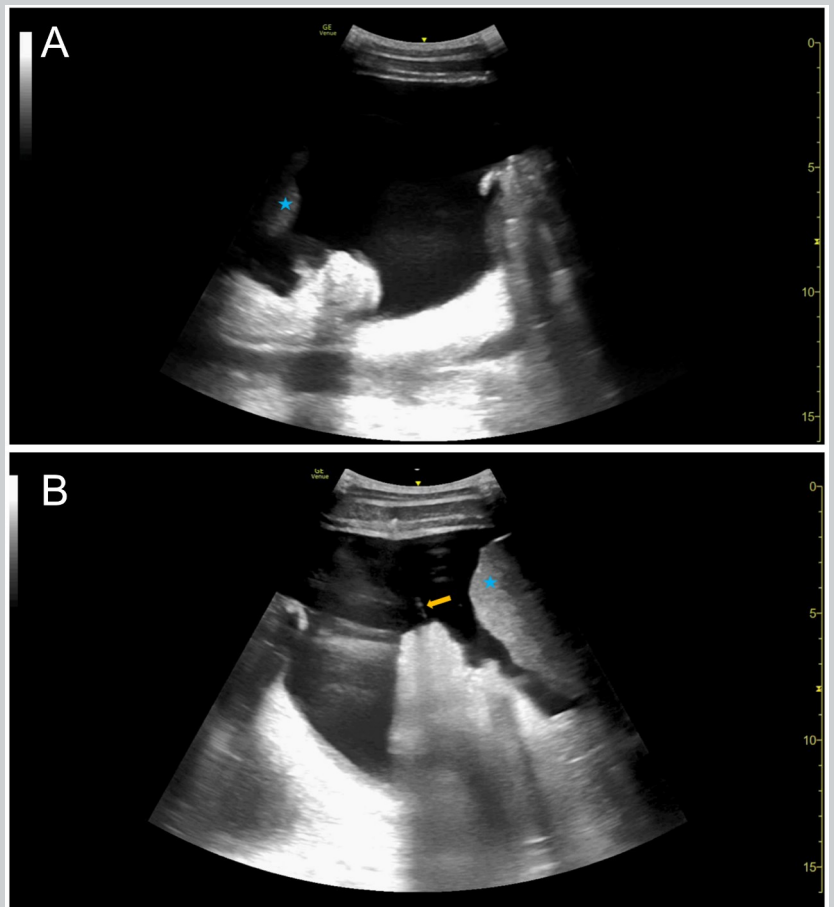
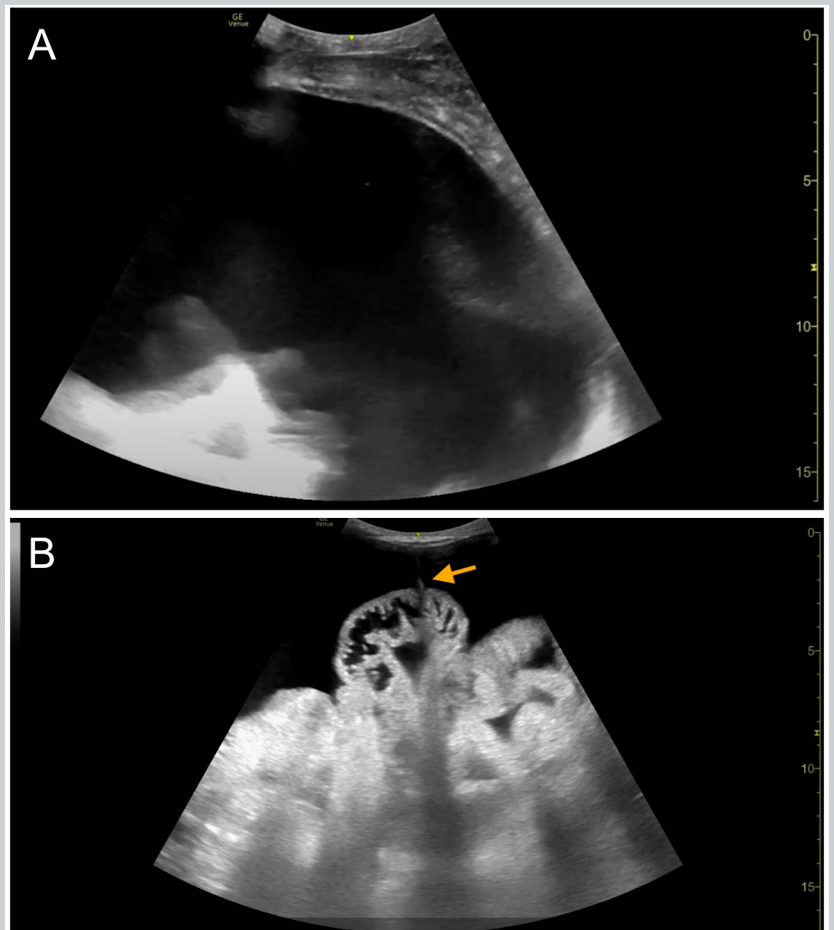


Figure 2. 68-year-old woman with decompensated alcoholic cirrhosis. A) Pre-procedural POCUS exam demonstrating large volume ascites in the left lower quadrant of the patient described in Case 2. B) Intraprocedural POCUS exam demonstrating attachment of omentum/bowel to the paracentesis catheter. [Arrow = catheter]



attempting manual aspiration via one-way syringe. These techniques resulted in minimal drainage (<20 mL). The aforementioned steps were repeated with gentle retraction of the catheter in one-centimeter increments without success. At this juncture, POCUS was employed under sterile conditions and demonstrated persistent ascites and attachment of bowel to the paracentesis catheter (Figure 1b).

## Case 2

A 68-year-old woman with decompensated alcoholic cirrhosis presented to the hospital with altered mental status and acute kidney injury in the setting of medication noncompliance. She was determined to have hepatic encephalopathy and poor renal perfusion secondary to abdominal compartment syndrome. Our inpatient procedure service was consulted to perform a large-volume paracentesis. Following standard protocol, ultrasound-assisted paracentesis was performed in the left lower quadrant after identifying free-flowing ascites approximately 10 cm in depth (Figure 2a). After initial drainage of 1.1 L of clear, yellow fluid into evacuated containers, flow through the paracentesis catheter abruptly terminated. Given ongoing physical exam findings of a tense, distended abdomen, and pre-procedural insonation of significant peritoneal fluid, obstruction of flow through the catheter was suspected. POCUS performed with sterile technique demonstrated attachment of bowel with retraction of the catheter (Figure 2b; Supplemental Video S1).

## Discussion

In both cases, a common technical challenge was encountered: interruption of ascites drainage by bowel/omentum. Here, we discuss how intraprocedural POCUS examination was relevant to our attempts to restore flow through the centesis catheter. Our intention is to provide proceduralists of all skill levels a practical approach to this commonly encountered problem. We begin with a summary of the literature available on tactics to address disrupted catheter flow, and ultimately offer a troubleshooting algorithm for proceduralists.

While numerous sources describe the paracentesis technique and the use of ultrasound to decrease the risk of adverse events, formal literature on procedural troubleshooting is scant. The most systematic approach to changes in flow through the intraperitoneal catheter was found in a procedure manual developed by the Canadian Internal Medicine Ultrasound (CIMUS) group [17]. Recommended troubleshooting techniques included inspection of the procedure set-up for leaks or loss of vacuum, adjustment of the catheter to address flow obstruction, and adjustment of the patient's position to address changes in ascites volume with drainage. All

*Table 1. Troubleshooting techniques. Table summarizing real-time procedural adjustments in the setting of failed peritoneal drainage.*

REFERENCE	RECOMMENDED TECHNIQUE
<b>Verify procedure setup</b>	
Desy et al., 2021 [17]	Check for leaks or loss of vacuum in the procedure set up
<b>Confirm ongoing ascites</b>	
Wheeler, 2019 [18]	Percuss abdomen
Wheeler, 2019 [18] Killu et al., 2017 [20]	Assess the procedure area with ultrasound
<b>Adjust for poor drainage</b>	
Desy et al., 2021 [17] Killu et al., 2017 [20] Glauser et al., 2008 [21]	Reposition the patient (e.g., rotate patient, elevate head of bed, etc.)
<b>Adjust for obstructed catheter</b>	
Desy et al., 2021 [17] Wheeler, 2019 [18] Glauser et al., 2008 [21]	Manipulate catheter (e.g., re-angle, rotate, and/or retract)
Jeong et al., 2015 [19] Killu et al., 2017 [20] Glauser et al., 2008 [21]	Release suction at the catheter tip (e.g., close and reopen stopcock)
Wheeler, 2019 [18] Jeong et al., 2015 [20]	Flush catheter

of the sources we identified provided recommendations to address obstructed flow through a catheter, which is suggestive of the relative frequency of this complication. The use of POCUS to assess the procedure area, untwisting the catheter, and flushing the catheter with sterile saline were all proposed as techniques to issues with catheter flow [18, 19]. (A complete list of references and recommendations can be found in Table 1.)

We compared these techniques with our experience. In Case 1, after troubleshooting techniques were employed, the problem was verified by direct visualization using ultrasound (Supplemental Video S2). Sterile saline was flushed incrementally in an attempt to release the bowel from the catheter and visualized entering the peritoneal space. The bowel, however, remained attached. The procedure was terminated by withdrawing the catheter while applying gentle pressure at the insertion site. The



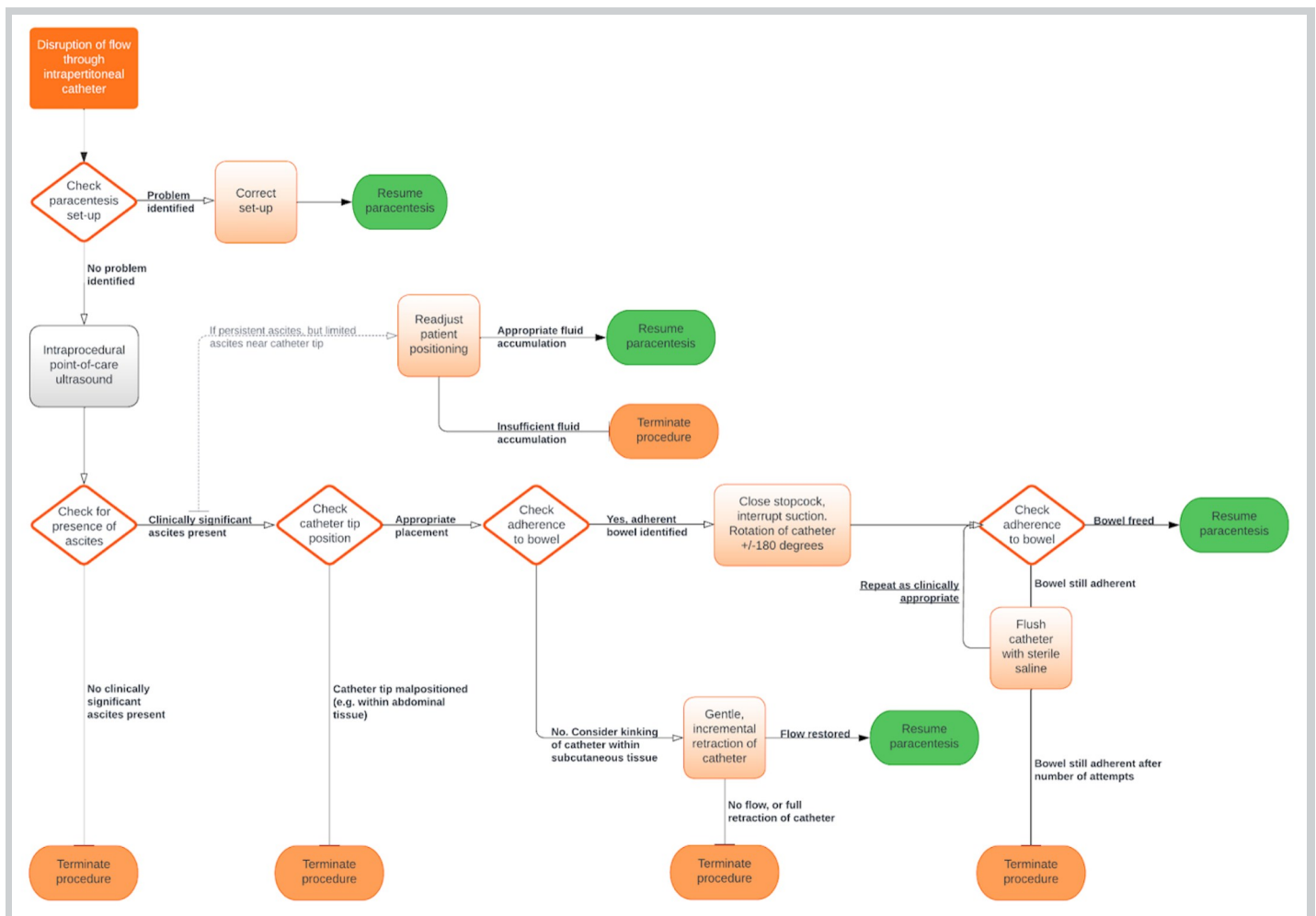


Figure 3. Proposed paracentesis troubleshooting algorithm. Systematic approach to identifying the etiology of obstructed peritoneal drainage and improve catheter flow during paracentesis.

patient did not report any discomfort. On repeat insonation, the omentum and bowel were visualized as free-floating. Paracentesis was performed from a different site, and 3 L of amber-colored peritoneal fluid was successfully removed without complication.

In Case 2, troubleshooting techniques were attempted after confirmation of obstructed catheter flow. Flow was initially restored by first closing the three-way stopcock towards the patient to release any suction, and then gently rotating the catheter 180° clockwise and counterclockwise to free the bowel from the catheter side port. Approximately 150 mL of ascitic fluid was drained before flow was again obstructed. The aforementioned steps were repeated and the procedure was resumed utilizing a 60 mL syringe for manual aspiration. Another 100 mL of fluid was aspirated before flow was again disrupted by the bowel. A saline flush was then attached to the three-way stopcock, and the device opened toward the patient. After rapid and repeated infusion of 10 mL saline (Supplemental Video S3), an additional 1 L of ascitic fluid was removed before flow abruptly terminated.

Given repeated obstruction and persistent large volume ascites, the procedure was discontinued. Paracentesis was reattempted in the right lower quadrant with removal of 2.3 L of clear, yellow fluid. The patient tolerated both procedures well and did not experience any complications.

Though intraprocedural POCUS was employed in both cases, the timing of its use differed. Whereas ultrasound was introduced at the outset in Case 2, ultrasound was utilized after several troubleshooting techniques were first attempted in Case 1. We speculate that the earlier use of intraprocedural POCUS contributed to the total amount of ascites successfully aspirated in Case 2.

POCUS has the potential to rapidly elucidate the etiology of disrupted flow by confirming the presence of ongoing ascites and visualizing catheter position. The techniques used to restore flow through the catheter can be monitored and adjusted prior to reattempting aspiration. Premature aspiration while the catheter is still blocked has the potential to worsen the obstruction such that subsequent troubleshooting efforts are unsuccessful,

*Table 2: Modified paracentesis procedure checklist. Revised procedure checklist to accommodate for intraprocedural ultrasound. Additional elements are denoted by an asterisk (\*).*

- Paracentesis Kit
- Fluid collection system (e.g., evacuated containers and vials for laboratory specimens)
- Personal protective equipment (e.g., sterile gown, gloves, and mask)
- Skin antiseptic (e.g., chlorhexidine or iodine)
- Ultrasound machine and gel
- Sterile probe cover\*
- Sterile ultrasound gel\*
- Sterile saline\*
- Various sized sterile syringes (e.g., 10-35 mL)\*

necessitating a repeat procedure and further time spent at the bedside.

Considering the existing literature and our case experiences, we propose an algorithm to systematically address issues with catheter flow (Figure 3). In the first step, the system of tubing and connections is assessed. This includes verifying that attachments are appropriate (e.g., stopcock valves turned in the correct direction), and without external kinks or air leaks (e.g., loss of vacuum from an evacuated container). Intraprocedural ultrasound is then incorporated to confirm presence of ongoing ascites and identify catheter position. If the catheter is obstructed by intraperitoneal structure such as bowel, a series of techniques (i.e., releasing suction, twisting the catheter, flushing with saline, etc.) can be attempted. The success of each effort is monitored by ultrasound. Switching from vacuum to manual aspiration may be helpful in controlling the degree of negative pressure applied to the system and prevent repeated bowel attachment.

When attempting to flush the catheter port with fluid, we find that rapid infusion yields the most success. We favor a small 10-20 mL syringe as larger syringes have more resistance. Syringes should be attached to the stopcock at the base of the centesis catheter to limit the distance the fluid must travel. It may be helpful to rotate the catheter at the time of flushing. Bowel may also be freed from the catheter with gentle retraction. Direct visualization of the peritoneal space using POCUS can determine the location of the catheter tip in relation to the volume of ascites present. This information can guide the proceduralist to retract the catheter more liberally than

the one centimeter increments often recommended by expert opinion. If after repeated attempts, the bowel fails to detach from the catheter, the procedure should be terminated and reattempted at a different site, if needed. The optimal number of attempts and the amount of fluid to be tolerated is yet undetermined.

To implement this algorithm, proceduralists will need materials in addition to routine paracentesis supplies (Table 2). Most importantly, we recommend having an ultrasound on hand with a sterile probe cover and conducting medium to maintain a sterile procedure field. In an optimized scenario, an assistant would be available to operate the ultrasound machine while the proceduralist remains sterile.

## Conclusion

The rapid determination of obstructed flow through a paracentesis catheter has the potential to increase successful paracentesis, decrease the number of reattempts, and save valuable time of the proceduralist at the bedside. We propose an algorithm which uniquely incorporates intraprocedural POCUS and serial reassessment in hopes to systematically approach this commonly encountered problem. Formalized studies are necessary to evaluate success of such an algorithm and its component recommendations.

## Ethics statement

The authors of this manuscript have all agreed to authorship. They have read and approved the manuscript, and given consent for submission and subsequent publication. All authors have been actively involved in the substantial work leading to the paper and will take public responsibility for its content.

Informed consent was obtained per hospital protocol for the two cases; one of the patients is deceased.

## Disclosures

The authors report no relevant disclosures related to this work.

## References

1. Wong F. Management of ascites in cirrhosis: Management of ascites in cirrhosis. *Journal of Gastroenterology and Hepatology*. 2012;27(1):11-20.
2. Duszak, Richard Jr et al. "National fluid shifts: fifteen-year trends in paracentesis and thoracentesis procedures." *Journal of the American College of Radiology : JACR* vol. 7,11 (2010): 859-64.
3. O'Brien CR, Chang J, Campos RA, et al. Characterizing the safety of paracentesis in hospitalized patients with cirrhosis and ascites from 2004-2012 in the United States. *Gastroenterology*. 2016;150(4). [https://doi.org/10.1016/S0016-5085\(16\)32196-5](https://doi.org/10.1016/S0016-5085(16)32196-5).
4. Cho J, Jensen TP, Reiersen K, et al. Recommendations on the use of ultrasound guidance for adult abdominal paracentesis: a position statement of the society of hospital medicine. *Journal of Hospital Medicine*. 2019;14(1).
5. Sharzehi K, Jain V, Naveed A, Schreiber I. Hemorrhagic

complications of paracentesis: a systematic review of the literature. *Gastroenterology Research and Practice*. 2014;2014:1-6.

6. Aithal GP, Palaniyappan N, China L, et al. "Guidelines on the management of ascites in cirrhosis" *Gut* 2021;70:9-29.
7. Mallory A, Schaefer JW. Complications of diagnostic paracentesis in patients with liver disease. *JAMA*. 1978;239(7):628-630.
8. Pache I, Bilodeau M. Severe haemorrhage following abdominal paracentesis for ascites in patients with liver disease. *Aliment Pharmacol Ther*. 2005;21(5):525-529.
9. De Gottardi A, Thévenot T, Spahr L, et al. Risk of complications after abdominal paracentesis in cirrhotic patients: a prospective study. *Clin Gastroenterol Hepatol*. 2009;7(8):906-909.
10. Sekiguchi H, Suzuki J, Daniels CE. Making paracentesis safer: a proposal for the use of bedside abdominal and vascular ultrasonography to prevent a fatal complication. *Chest*. 2013;143(4):1136-1139.
11. Bard C, Lafortune M, Breton G. Ascites: ultrasound guidance or blind paracentesis? *CMAJ*. 1986;135(3):209-210.
12. Sudalagunta SR, Sodalagunta MB, Bangalore Raja SK, Khorram H, Sepéhrar M, Noroozpour Z. Clinical profile and complications of paracentesis in refractory ascites patients with cirrhosis. *Gastroenterology Res*. 2015;8(3-4):228-233.
13. Mehmood F, Khalid A, Tow C. A diagnostic paracentesis leading to intra-abdominal hematoma and small bowel obstruction. *Cureus*. 2022;14(3):e23472.
14. Mercaldi CJ, Lanes SF. Ultrasound guidance decreases complications and improves the cost of care among patients undergoing thoracentesis and paracentesis. *Chest*. 2013;143(2):532-538.
15. De Gottardi A, Thévenot T, Spahr L, et al. Risk of complications after abdominal paracentesis in cirrhotic patients: a prospective study. *Clin Gastroenterol Hepatol*. 2009;7(8):906-909.
16. Millington SJ, Koenig S. Better with ultrasound. *Chest*. 2018;154(1):177-184.
17. Desy J, Brotherson D, Ma I. *University of Calgary and University of Alberta General Internal Medicine Procedural Manual Ultrasound Guided Paracentesis*. Canada: Online; 2021, <https://sites.google.com/site/calgaryimus/home/procedures/paracentesis>. Accessed December 22, 2022.
18. Wheeler, James. "Paracentesis." *Charlie's ED*, 25 Sept. 2019, <https://scghed.com/2016/01/paracentesis/>. Accessed August 3, 2022.
19. Jeong, Jordan, et al. "How to Use Continuous Wall Suction for Paracentesis." *ACEP Now*, 8 June 2015, <https://www.acepnow.com/article/use-continuous-wall-suction-paracentesis>. Accessed August 3, 2022.
20. Killu C, Ault M. Paracentesis. In: Oropello JM, Pastores SM, Kvetan V. eds. *Critical Care*. McGraw Hill; . Accessed December 21, 2022. <https://accessmedicine.mhmedical.com/content.aspx?bookid=1944&sectionid=143522962>
21. Glauser F, Barras AC, Pache I, Monti M. [Abdominal paracentesis]. *Rev Med Suisse*. 2008;4(177):2324-2328.

# Twinkle Artifact Observed During POCUS of a Human Myiasis Caused by the *Dermatobia hominis* Botfly

David Jerome, MD, MSc, CCFP(EM)<sup>1,2</sup>; Matthew Stacey, MD, CCFP(EM)<sup>2</sup>;  
Joseph Newbigging, MD, CCFP(EM), FCFP<sup>2\*</sup>

(1) Northern Ontario School of Medicine University, Thunder Bay, ON, Canada

(2) Queen's University, Department of Medicine, Kingston, ON, Canada

## Abstract

An 81-year-old man presented to urgent care for assessment of an area of erythema and tenderness on his right thigh after recent travel to Belize. Point of care ultrasound (POCUS) revealed a hyperechoic structure with acoustic shadowing in the subcutaneous tissue. Colour Doppler assessment of the structure produced a twinkle artifact. The structure was removed and pathology identified the object as a *Dermatobia hominis* larva (human botfly). The use of POCUS helped identify and localize the subcutaneous foreign body. The use of colour Doppler produced the twinkle artifact, which has not been previously reported as a finding produced during ultrasonographic assessment of botfly larvae.

## Introduction

Myiasis is the infestation of live human and vertebrate animal tissues by botfly larvae. A number of botfly species are capable of causing human myiasis. The most common form of myiasis encountered in North America is due to infestation by *Dermatobia hominis* (*D. hominis*) in travellers returning from Central and South America [1]. The *D. hominis* fly lays her eggs on the underside of a blood-sucking arthropod (usually a mosquito). When the arthropod host subsequently feeds on a human, the botfly eggs hatch and the larvae infiltrate into the human's tissues [1,2]. Once in the human host, botfly larvae live in the subcutaneous tissue and feed on the host's tissues until the larvae are mature and spontaneously exit the host. Human infestation usually lasts for four to eighteen weeks.

Patients with a botfly infestation present with an erythematous, raised, furuncle-like lesion [1-4]. The lesion usually appears to have central umbilication or necrosis. Patients sometimes report the sensation of movement within the subcutaneous tissues. Larval removal can be facilitated by the application of an occlusive substance over the wound (such as petroleum jelly). This starves the larva of oxygen, causing it to emerge from the host's skin [1].

Here we present a case report of the use of point of care ultrasound (POCUS) to assess a patient with myiasis, including the first known report of a Doppler twinkle artifact observed during ultrasound assessment of a human myiasis.

## Case Report

An 81-year-old man presented to an urgent care centre in Ontario, Canada for assessment of an area of swelling and erythema on his right thigh. The patient was bitten by an unknown insect five weeks previous while travelling in Belize and his symptoms developed around the site of the insect bite. He had presented to a primary care provider two weeks prior for assessment of the lesion where he was diagnosed with cellulitis and prescribed a course of oral cephalexin. The patient reported that his symptoms initially improved while taking the antibiotics but reoccurred after the course of antibiotics was complete. The patient denied any recent history of fevers, chills, nausea, vomiting or diarrhea. He did not have any calf swelling, calf pain, dyspnea or hemoptysis.

On presentation, the patient's vital signs were within normal limits. He had a round, raised, 5-10 millimetre-wide area of inflammation on the medial aspect of his right thigh, resembling a furuncle. There was no fluctuance, fluid drainage, or visible break in the skin.

---

\*Corresponding Author: Dr. Joseph Newbigging (email: Joseph.Newbigging@kingstonhsc.ca)

This work is licensed under a [Creative Commons Attribution 4.0 International License](https://creativecommons.org/licenses/by/4.0/).

Author(s) retain the copyright for their work. At the time of submission to POCUS Journal the author(s) grant the journal a limited and non revokable right to publish in the Journal under a [Creative Commons Attribution 4.0 International License](https://creativecommons.org/licenses/by/4.0/).

DOI: <https://doi.org/10.24908/pocus.v8i2.16712>

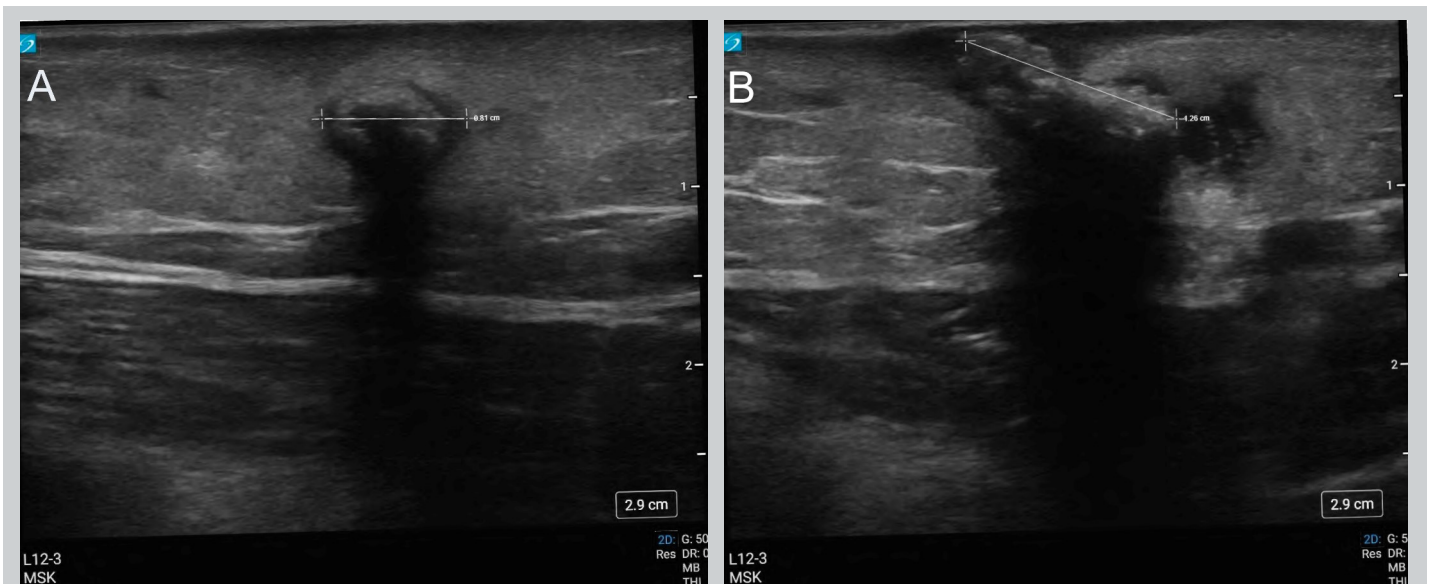


Figure 1. POCUS images of the myiasis viewed in short axis (A), and in long axis (B): the structure presents as a hyperechoic object with a surrounding anechoic ring and shadow artifact deep field.

POCUS assessment of the lesion was completed using a Sonosite PX ultrasound machine with a 12MHz high-frequency linear transducer. A longitudinal sausage-shaped structure (8 x 12mm) was identified within the subcutaneous tissue which demonstrated a thin anechoic ring surrounding a hyperechoic structure with acoustic shadowing (Figure 1). There was no evidence of posterior acoustic enhancement that would have been anticipated if the lesion were a furuncle or cutaneous abscess. The structure was not compressible, nor did it appear to have any intrinsic movement.

Interrogation of the lesion with colour Doppler was completed to assess if the structure had any vascularity

prior to attempting an incision and excision. The lesion did not show any Doppler signal suggestive of vascular flow. Instead the structure, and continuing deep-field, demonstrated constant alternating colours of Doppler signal, giving the appearance of turbulent blood flow (Figure 2, Videos S1 & S2). This finding was consistent with a sonographic “twinkle sign”.

Following the POCUS examination, the area surrounding the foreign body was anesthetized with local anesthetic in preparation for an incision. Before the procedure could be completed, an organism was observed in the process of exiting the centre of the furuncle-type lesion. Traction with forceps succeeded in extracting an intact 12mm long

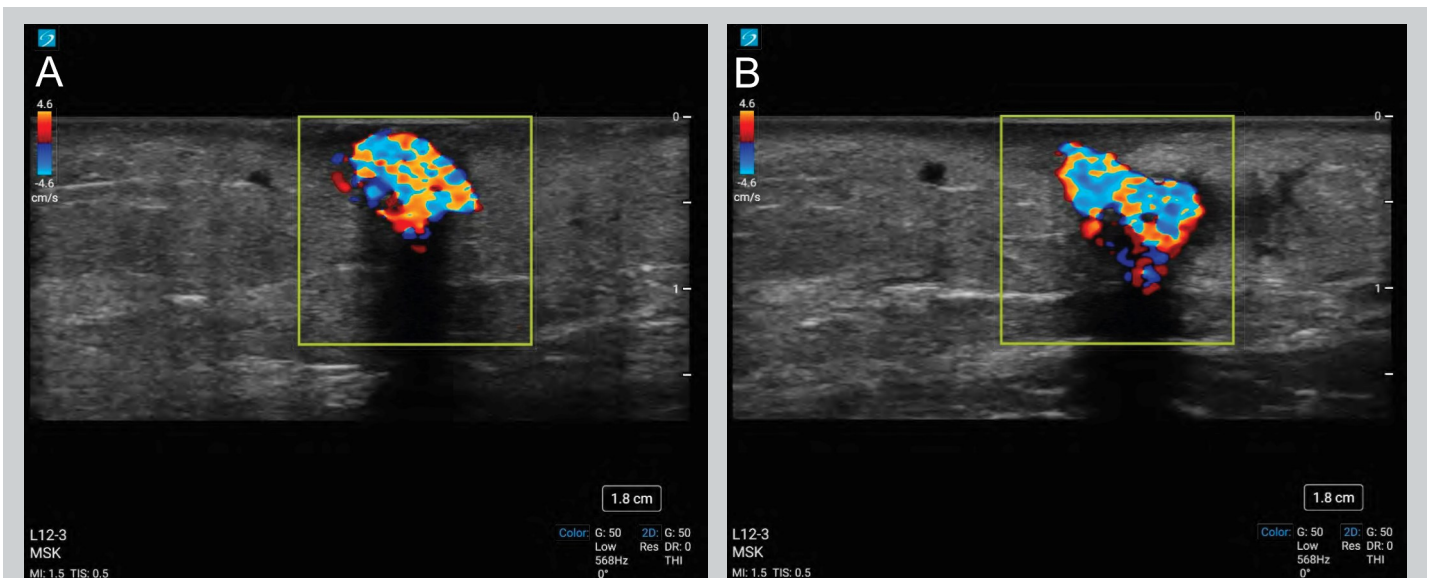


Figure 2. Twinkle artifact viewed with colour Doppler scanning of the myiasis in short axis (A) and in long axis (B).

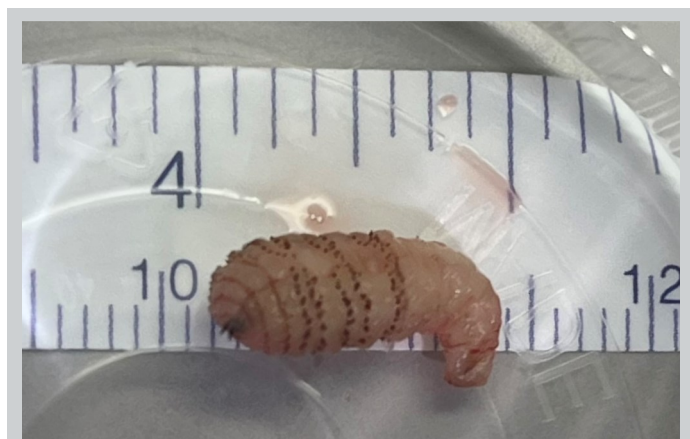

Figure 3. The *D. hominis* botfly assessed by POCUS, viewed after excision.

organism (Figure 3). The patient was discharged home with no new prescription. Pathological examination subsequently confirmed that the specimen was a *D. hominis* larva (human botfly). During a follow-up phone call one month later, the patient reported complete resolution of his symptoms.

### Discussion

Previous reports on the use of formal ultrasound and POCUS to assess lesions caused by botfly myiasis have reported that the larvae appear as hyperechoic round or oval structures with shadow artifact [2-4]. The larvae are usually noted to be surrounded by a ring of hypoechoic fluid [2,4]. Some authors have reported observing larval movement during the ultrasound scan [2,3]. The ultrasound findings in this case report are consistent with these observations, though we did not note any sonographic evidence of larval movement during our assessment. In contrast, POCUS assessment of a cutaneous abscess typically demonstrates contents that are anechoic to hyperechoic, with a hyperchoic rim that is hyperemic on colour doppler flow [5]. Abscesses typically show posterior acoustic enhancement. Compression of an abscess can elicit sonographically visible swirling of the purulent contents [5]. Application of colour doppler flow on an abscess would not be expected to show a twinkle artifact.

The twinkle artifact (also known as twinkle sign or colour comet artifact) during Doppler ultrasound was first described in 1996 [6]. It presents as a rapidly changing mixture of red and blue signal deep field to a reflective structure and is understood to represent noise within the Doppler signal caused by reflections off of a highly echogenic surface [6]. Clinicians classically look for a twinkle artifact during Doppler sonographic assessment for a calcium containing calculus (either nephrolithiasis or cholelithiasis). A retrospective chart review found that the

presence of the twinkle sign on initial ultrasound had a high positive predictive value (78%) for the presence of nephrolithiasis on subsequent unenhanced CT [7].

The twinkle sign has also been observed during sonography of other structures. Nagafuchi *et al* reported on the presence of a twinkle artifact in rheumatologic patients when scanning periarticular calcification secondary to intra-articular corticosteroid injections [8]. In a series of 46 consecutive patients with microcalcifications on mammogram, looking for the twinkle artifact during ultrasound-guided biopsies increased the sensitivity for suspicious lesions from a baseline of 30% with B-mode up to 89% with Doppler [9]. The twinkle sign has also been described when scanning strongly reflective surfaces with a rough texture that do not contain any calcium, such as iron fillings and ground glass [6,7]. The artifact is not observed when scanning smooth reflective surfaces, such as metal wire [6].

Here we present the first known report documenting a twinkle artifact during the sonographic assessment of a myiasis. The etiology of the myiasis twinkle artifact is presumed to be a result of the hard, irregular and spiny larva carapace. It is possible that more immature larvae, with less developed carapaces, will not demonstrate twinkle artifact and that this sonographic characteristic may only be seen with later presentations of myiasis. This case involved a *D. hominis* larvae. Other species of myiasis (eg. *Cordylobia anthropophaga*) have a similar carapace composition and surface texture as *D. hominis*, and so we would anticipate that POCUS assessment of these lesions would produce a similar sonographic twinkle sign, but this is currently unknown [10].

During our POCUS assessment the botfly larva was located within the patient's subcutaneous tissues. Within a few minutes, however, the larva began spontaneously exiting the host. We suspect that the ultrasound gel applied during the POCUS exam acted as an occlusive coating, prompting the larva's exit. In this case it is possible that in addition to diagnostic assistance, the POCUS provided some therapeutic value.

Due to the low incidence of botfly infestation in North America, patients with myiasis are often misdiagnosed with cellulitis [2,3]. This leads to unnecessary repeat healthcare visits, inappropriate use of antibiotics and a delay in the initiation of appropriate treatment. This report demonstrates the importance of maintaining a broad differential diagnosis for localized swelling and erythema, especially in the context of recent travel history, and the value of employing POCUS in order to make an accurate diagnosis. In this case, the application of POCUS demonstrated some features already described, as well as a newly described sonographic feature in the context of myiasis assessment, the myiasis twinkle sign.

## Statement of Consent

Informed consent was obtained for the use of the images in this report.

## Conflict of Interest

The authors have no conflicts of interest to declare.

## Acknowledgments

The patient described in this report reviewed and provided valuable feedback on the draft manuscript. The authors thank him for his contributions.

## References

1. Safdar N, Young DK, Andes D. Autochthonous furuncular myiasis in the United States: case report and literature review. *Clin Infect Dis*. 2003 Apr 1;36(7): e73-80. doi: 10.1086/368183.
2. Jones CH, Leon M, Auerbach J, Portillo-Romero J. Ultrasound Detection of Human Botfly Myiasis of the Scalp: A Case Report. *Cureus*. 2020 Dec 4;12(12):e11905. doi: 10.7759/cureus.11905.
3. Minakova E, Doniger SJ. Botfly larva masquerading as periorbital cellulitis: identification by point-of-care ultrasonography. *Pediatr Emerg Care*. 2014 Jun;30(6):437-9. doi: 10.1097/PEC.000000000000156.
4. Davis CA, Patterson J, Hampton KA. Point-of-Care Ultrasound Findings in a Case of Botfly Myiasis Contracted in the United States. *Wilderness Environ Med*. 2022 Sep;33(3):337-339. doi: 10.1016/j.wem.2022.04.004.
5. Squire BT, Fox JC, Anderson C. ABSCESS: applied bedside sonography for convenient evaluation of superficial soft tissue infections. *Acad Emerg Med*. 2005 Jul;12(7):601-6. doi: 10.1197/j.aem.2005.01.016.
6. Rahmouni A, Bargoin R, Herment A, Bargoin N, Vasile N. Color Doppler twinkling artifact in hyperechoic regions. *Radiology*. 1996 Apr;199(1):269-71. doi: 10.1148/radiology.199.1.8633158.
7. Dillman JR, Kappil M, Weadock WJ, Rubin JM, Platt JF, DiPietro MA, Bude RO. Sonographic twinkling artifact for renal calculus detection: correlation with CT. *Radiology*. 2011 Jun;259(3):911-6. doi: 10.1148/radiol.11102128.
8. Nagafuchi Y, Sumitomo S, Soroida Y, Kanzaki T, Iwasaki Y, Michishita K, Iwai T, Ikeda H, Fujio K, Yamamoto K. The power Doppler twinkling artefact associated with periarticular calcification induced by intra-articular corticosteroid injection in patients with rheumatoid arthritis. *Ann Rheum Dis*. 2013 Jul;72(7):1267-9. doi: 10.1136/annrheumdis-2012-202897.
9. Relea A, Alonso JA, González M, Zornoza C, Bahamonde S, Viñuela BE, Encinas MB. Usefulness of the twinkling artifact on Doppler ultrasound for the detection of breast microcalcifications. *Radiologia (Engl Ed)*. 2018 Sep-Oct;60(5):413-423. doi: 10.1016/j.rx.2018.04.004.
10. Ockenhouse CF, Samlaska CP, Benson PM, Roberts LW, Eliasson A, Malane S, Menich MD. Cutaneous myiasis caused by the African tumbu fly (*Cordylobia anthropophaga*). *Arch Dermatol*. 1990 Feb;126(2):199-202.

# Dissemination of a Pediatric Musculoskeletal POCUS Scoring System via Virtual Education: A Proof-of-Concept Study

Ysabella Esteban, MD MSc RhMSUS<sup>1\*</sup>; Jackeline Rodriguez-Smith, MD MSc RhMSUS<sup>2</sup>; Marie Tominna, DO<sup>3</sup>; Amy Cassedy, PhD<sup>4</sup>; Arthur B. Meyers, MD<sup>5</sup>; Michael Henrickson, MD MPH RhMSUS<sup>2</sup>; Tracy V. Ting, MD MSc RhMSUS<sup>2</sup>; Patricia Vega-Fernandez, MD MSc RhMSUS<sup>2</sup>

(1) Division of Rheumatology, Nationwide Children's Hospital, Columbus, Ohio, USA

(2) Department of Pediatrics, University of Cincinnati, Division of Rheumatology, Cincinnati Children's Hospital Medical Center, Cincinnati, Ohio, USA

(3) Beaumont Hospital, Royal Oak, Michigan, USA

(4) Department of Pediatrics, University of Cincinnati, Division of Biostatistics and Epidemiology, Cincinnati Children's Hospital Medical Center, Cincinnati, Ohio, USA

(5) Department of Radiology, University of Cincinnati, Division of Radiology and Medical Imaging, Cincinnati Children's Hospital Medical Center, Cincinnati, Ohio, USA

## Abstract

Point of care pediatric musculoskeletal POCUS scanning and scoring protocols for childhood arthritis have emerged in recent years. However, pediatric musculoskeletal POCUS curricula in rheumatology fellowship programs are limited due to availability of trained faculty and resources. This proof-of-concept study investigated the effectiveness of educational methods for a pediatric musculoskeletal POCUS scoring protocol among fellows and physicians of differing subspecialties. Educational methods assessed included recorded videos and virtual review sessions. Effectiveness was assessed by calculating interrater reliability for the musculoskeletal POCUS scoring systems using the intra-class correlation coefficient (ICC). Following training sessions, participants then underwent scoring exercise (s) until the goal of an excellent ICC  $\geq 0.75$  was reached. Four participants completed two rounds of virtual education, review, and scoring sessions. Excellent interrater reliability was achieved for most views. This proof-of-concept study demonstrated virtual education covering advanced concepts of pediatric musculoskeletal POCUS provides a knowledge base for physicians from different subspecialties and various experience.

## Introduction

In recent years, point of care ultrasound (POCUS) is becoming more prevalent in medical education and in patient care [1]. After the onset of the COVID-19 pandemic, there are examples of successful virtual adaptation of POCUS in medical student and radiological resident education [2,3]. From a practical standpoint, the use of musculoskeletal POCUS is becoming more widespread and ubiquitous within medicine, specifically within the field of rheumatology. In addition, a previous study demonstrated successful teaching of sonographic findings of inflammatory arthritis to medical students, based on utilization of a multiple-choice exam, practical skills assessment, and overall score determined by the educators [4].

Advancing a POCUS skillset relies mostly on self-directed education and/or enrollment in specific curricula [5-8]. In recent years, musculoskeletal POCUS training has been integrated into many adult rheumatology fellowship programs, with over 100 programs in the United States providing education on this imaging modality. However, the availability of standardized curricula varies between fellowship programs [5]. In an effort to support musculoskeletal POCUS training, the American College of Rheumatology (ACR) introduced a musculoskeletal POCUS educational curriculum for adult patients, with related appendices for pediatric patients [6]. In order to quantify the availability of pediatric musculoskeletal POCUS curricula, one recent cross-sectional study showed that 20 of the 36 ACGME-accredited pediatric rheumatology fellowship programs in the United States

\*Corresponding Author: Ysabella Esteban, MD MSc RhMSUS (email: Ysabella.Esteban@nationwidechildrens.org)

This work is licensed under a [Creative Commons Attribution 4.0 International License](https://creativecommons.org/licenses/by/4.0/).

Author(s) retain the copyright for their work. At the time of submission to POCUS Journal the author(s) grant the journal a limited and non-revokable right to publish in the Journal under a [Creative Commons Attribution 4.0 International License](https://creativecommons.org/licenses/by/4.0/).

DOI: <https://doi.org/10.24908/pocus.v8i2.16229>



and Canada offer some level of musculoskeletal POCUS training [8]. However, the dissemination of pediatric musculoskeletal POCUS curricula can be limited due to the availability of trained faculty, constraints on time and resources to perform these studies, and decreased awareness of available curricula [8].

Within the context of clinical applications of pediatric musculoskeletal POCUS, there exists definitions for pediatric sonographic findings of healthy joints as well as sonographic findings of inflammatory arthritis [9-11]. Recent studies within the field of pediatric rheumatology and musculoskeletal POCUS have focused on the development of pediatric-specific scanning protocols for the assessment of synovitis in juvenile idiopathic arthritis (JIA) and corresponding scoring systems, including those proposed by the Outcome Measures in Rheumatology (OMERACT) and Childhood Arthritis and Rheumatology Research Alliance (CARRA) ultrasound work groups [12-17]. However, the establishment of curricula for advanced concepts including consensus-based scoring systems for pediatric synovitis within the context of

rheumatic disease has not been well explored.

This proof-of-concept study aims to explore this knowledge gap, and to provide further insight into educational opportunities within the field. Here, we provided an initial assessment of 1) the educational methods used to teach and 2) the reproducibility of a pediatric-specific musculoskeletal POCUS scoring system among fellows-in-training and a pediatric radiology attending.

### Materials and Methods

This was a proof-of-concept study, and participants included those with various degrees of training and experience in musculoskeletal POCUS (from 1 year to >10 years), including three fellows (two pediatric rheumatology fellows, one pediatric radiology fellow) and one radiology attending with expertise in musculoskeletal imaging and 10 years of post-training experience. The education provided for the group included two modalities: 1) recorded educational videos and 2) follow-up review sessions via virtual meet space. These videos and review sessions were guided by an expert pediatric

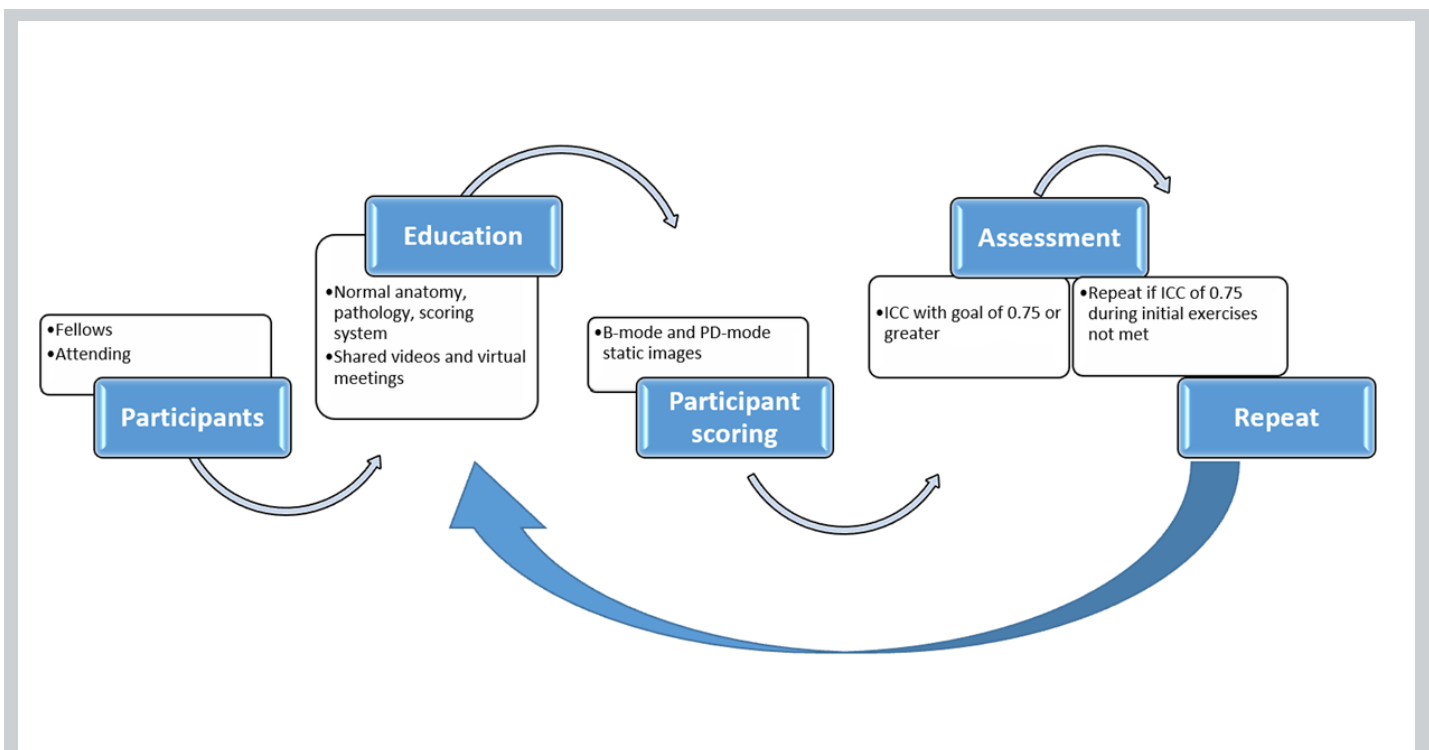


Figure 1. Methods. Methodology used for education and scoring exercises. Participants included 3 fellows in training from pediatric rheumatology (2) and pediatric radiology (1), as well as 1 attending from musculoskeletal radiology. Sessions were led by a trained pediatric Musculoskeletal Ultrasound Certification in Rheumatology (RhMSUS) certified sonographer of >10 years. Education materials covered normal sonographic anatomy, pathologic findings related to arthritis, as well as a semiquantitative scoring system. [13,15] Scoring exercises were comprised of still images using B- and PD-mode, representative of normal and pathologic findings. Assessment used intra-class correlation coefficient (ICC) with goal of 0.75 or greater for the lower confidence interval (CI) for each joint. [18,19] Education and scoring were repeated if this goal was not achieved per joint and view.

rheumatologist and ultrasonographer (PVF, 10 years of musculoskeletal POCUS experience). The methods are outlined in Figure 1.

The recorded educational videos were led by the musculoskeletal POCUS expert (PVF) and facilitator (YE), who helped guide discussion points during the recording and review sessions. The videos reviewed the sonographic anatomy as well as pathologic findings for B-mode and PD-mode of the elbow, wrist, finger, knee, and ankle joints. During these videos, the scoring system for each joint was also taught, using static images obtained from patients 2-17 years of age. Briefly, the definitions of pathology used by the scoring systems followed the recommendations proposed by the OMERACT Pediatric Ultrasound Group [7]. The scoring systems used a semi-quantitative scale (0-normal to 3-severe) to categorize the findings of synovitis in B-mode and power Doppler (PD) images of the aforementioned joints (Table 1) [13, 15-17].

The duration of each video ranged from 24 to 46 minutes in length. In addition, electronic handouts were provided to participants, which detailed the anatomy, pathology, and scoring system of each joint. Participants were encouraged to complete the videos prior to the virtual review sessions.

The two review sessions then took place via a virtual meet space, led by YE and PVF, which lasted approximately 1.5 – 2 hours total. During this review, participants asked questions regarding the anatomy, pathology, and scoring system. Then, participants were able to practice the scoring system, and real-time feedback and discussion were provided based on the score each participant chose. Following the review sessions, participants had more opportunities to individually review the material on their own time, and one-on-one question and answer sessions regarding the scoring system via phone or email were provided as needed.

All participants then underwent a scoring exercise which was conducted electronically, using B- and PD-mode static images from a previously existing pediatric musculoskeletal POCUS image bank obtained from children 2 – 17 years and representing the spectrum of pathology described by the scoring systems for each joint. The images were selected based on the quality of the image, specifically considering clear delineation of bony/cartilage landmarks and the least amount of anisotropy or artifact. The images selected for the review sessions were different than those selected for the scoring exercises. No identifiable patient information was presented with the images save for the age of the subject. The images were scored independently by each participant; statistical analysis followed each exercise.

*Table 1. Anatomical Views for Elbow, Wrist, Finger, Knee, and Ankle Joints [13,15-17]*

Joint	Anatomical Views (B-mode and PD-mode)
Elbow	Anterior humeroulnar joint recess Anterior humeroradial joint recess Posterior humeroulnar joint recess
Wrist	Radiocarpal and midcarpal joint recess – midline Radiocarpal and midcarpal joint recess – ulnar Distal radioulnar joint recess Extensor tendons
Finger	MCP dorsal joint recess in longitudinal MCP volar joint recess in longitudinal PIP volar joint recess in longitudinal PIP dorsal joint recess in longitudinal
Knee	Suprapatellar joint recess Medial parapatellar joint recess Lateral parapatellar joint recess
Ankle	Anterior tibiotalar joint recess Talonavicular joint recess Anterior subtalar joint recess (from medial aspect) Posterior subtalar joint recess (from lateral aspect) Anterior, medial, and lateral tendons
Anatomical views for the scoring protocol as determined by previous studies. [13,15-17]	

Based on the results from the first scoring exercise, participants underwent a second review session with emphasis on the areas that did not reach excellent reliability as defined by an intra-class correlation coefficient (ICC)  $\leq 0.75$  [18,19]. During this live virtual review session, additional sample images for scoring practice were provided, with participants providing scores followed by discussion as to why specific scores were chosen. Then, a second scoring exercise was performed which focused on those particular areas utilizing B- and PD-mode static images.

The interrater reliability was estimated using the two-way single score ICC, along with the 95% confidence intervals (CI). Excellent ICC was defined to be between 0.75 – 1.00, good 0.60 – 0.74, fair 0.40 – 0.59, and poor  $< 0.40$  [18,19]. ICC estimates and their 95% confidence intervals were calculated using SAS v9.4©, Cary, NC.

This study was submitted to the authors' Institutional Review Board (Cincinnati Children's Hospital Medical Center) and received exemption status: IRB# 2020-0700.

Table 2. Interrater Reliability of Pediatric-Specific musculoskeletal POCUS Scoring System– Exercise 1 and 2.

Joint View		Exercise 1		Exercise 2	
		B-mode ICC (95% CI)	Power Doppler- Mode ICC (95% CI)	B-mode ICC (95% CI)	Power Doppler- Mode ICC (95% CI)
Elbow	Anterior humeroulnar and humeroradial joint recesses	0.93 (0.89 – 0.95)	0.88 (0.77 - 0.94)	‡	‡
	Posterior humeroulnar joint recess	0.93 (0.89 - 0.95)	0.77 (0.61 - 0.87)	‡	‡
Wrist	Radiocarpal and midcarpal joint -- midline	0.86 (0.80 - 0.90)	0.96 (0.94 - 0.97)	‡	‡
	Radiocarpal and midcarpal joint -- ulnar	0.80 (0.65 - 0.89)	0.90 (0.71 - 0.97)	‡	‡
	Distal radioulnar joint recess	0.87 (0.78-0.92)	0.93 (0.94 – 0.97)	‡	‡
	Tendons -- extensor	0.74* (0.58 - 0.84)	0.66* (0.35 - 0.84)	0.5* (0.19 – 0.72)	0.52* (0.19 – 0.74)
Finger	MCP dorsal joint recess in longitudinal	0.94 (0.90 - 0.96)	0.98 (0.97 - 0.99)	‡	‡
	MCP volar joint recess in longitudinal	0.82 (0.73 - 0.88)	0.89 (0.83 - 0.93)	‡	0.95 (0.93-0.97)
	PIP volar joint recess in longitudinal	0.91 (0.87 - 0.94)	0.63* (0.48 - 0.74)		
	PIP dorsal joint recess in longitudinal	0.94 (0.88-0.97)	0.84 (0.70 - 0.92)	‡	‡
Knee	Suprapatellar joint recess	0.93 (0.89 - 0.95)	0.88 (0.82 - 0.92)	‡	‡
	Medial parapatellar joint recess	0.92 (0.88 - 0.95)	0.90 (0.85 – 0.93)	‡	‡
	Lateral parapatellar joint recess	0.94 (0.91 – 0.96)	0.90 (0.84 – 0.93)	‡	‡
Ankle	Anterior tibiotalar joint recess	0.92 (0.88 – 0.95)	0.87 (0.75 – 0.93)	‡	‡
	Talonavicular joint recess	0.66* (0.41 - 0.82)	0.91 (0.8 - 0.96)	0.84 (0.71-0.91)	‡
	Anterior subtalar joint recess (medial aspect)	0.77 (0.63 - 0.86)	0.83 (0.59 - 0.94)	‡	‡
	Posterior subtalar joint recess (lateral aspect)	0.73* (0.57 - 0.84)	†	0.90 (0.85-0.96)	0.91 (0.83-0.95)
	Tendons—Medial, lateral and anterior	0.53* (0.26 - 0.73)	0.55* (0.1 - 0.81)	0.82 (0.73-0.88)	0.95 (0.91-0.97)

\*Desired reliability of  $\geq 0.75$  not obtained. †Insufficient data to assess. ‡Not applicable

Interrater reliability was estimated using ICC. Excellent ICC was defined to be between 0.75-1.00, good 0.60-0.74, fair 0.40 – 0.59, and poor  $< 0.40$ . [18, 19]air 0.40 – 0.59, and poor  $< 0.40$ . [18, 19]

## Results

A total of four raters participated in this proof-of-concept study. A total of two rounds of educational and scoring sessions were completed. The results from the first educational and scoring exercise are listed in Table 2. For this scoring exercise, a total number of 588 images representing both normal sonographic anatomy as well

as varying degrees of pathology related to the scoring system (including 352 B-mode and 236 PD-mode still images) were scored. Based on these results, excellent interrater reliability (ICC  $\geq 0.75$ ) was achieved for most of the B-mode and PD mode views of the elbow, wrist, finger, knee and ankle as delineated in Table 2.

For the remaining views in which excellent reliability was

not reached, a second round of education and scoring exercises was performed, with the results listed in Table 2. For this scoring exercise, a total number of 234 B-mode and PD-mode still images were scored. Desired excellent interrater reliability was obtained for the remaining B-mode and PD-mode views with the exception of those delineating the tendons of the wrists. For this area, a fair reliability was obtained.

Feedback regarding the educational sessions was obtained in real-time from participants. Positive feedback included the flexibility of the curriculum given the video format with electronic handouts, as well as the structure of educational sessions. Suggestions for improvement included incorporating more examples of image scoring for both B-mode and PD-mode views during the interactive virtual review sessions.

### Discussion

This proof-of-concept study explored the ability of pediatric physicians with varying degrees of expertise to learn and demonstrate a novel pediatric musculoskeletal POCUS scoring system. From an educational standpoint, the information provided to participants built upon basic musculoskeletal anatomy, and participants were able to gain or fine tune knowledge regarding joint pathology as visualized on B- and PD-modes. Knowledge of the scoring protocol was also imparted. The format of the educational sessions, which included video lectures encompassing the related sonographic anatomy, pathology, and scoring system of each joint, allowed participants to learn independently. In addition, during the virtual, interactive review sessions the participants were able to practice scoring, concept review, and discussion of the scoring systems in real-time. Immediate, informal feedback at the end of each session allowed incorporation of suggestions into subsequent educational sessions.

Use of musculoskeletal POCUS facilitates real-time diagnosis, intervention, and monitoring by the clinician ultrasonographer [20, 21]. In addition, the evolution of technology has provided the medical community with multiple portable options, which has allowed pediatric providers increased access to this mode of imaging [21]. In terms of musculoskeletal POCUS, there are multiple routes of education including rheumatology fellowship training, mentored training that is either structured or unstructured, or self-directed and non-mentored training [20]. For pediatric musculoskeletal POCUS, basic educational opportunities include the training program offered by the Ultrasound School of North American Rheumatologists (USSONAR), workshops and courses previously offered by the American College of Rheumatology (ACR) or Childhood Arthritis Rheumatology Research Alliance (CARRA) in the pre-

COVID era, as well as self-directed online resources such as Ped-MUS [6; 22-23]. Twenty pediatric rheumatology fellowship programs also offer musculoskeletal POCUS training [8].

To our knowledge, this is the first effort to investigate a virtual educational format to train pediatricians in the assessment of musculoskeletal POCUS studies as they pertain to JIA using advanced concepts. While it is possible that the size and flexibility of this participant group facilitated this investigation, it is feasible that these educational sessions can be replicated among larger participant groups in the future. The pandemic has accelerated the era of virtual meetings, which some have found to be beneficial in radiological education [3], and our demonstration of teachability and reproducibility of this scoring system via a virtual meet space is likewise encouraging. The era of COVID-19 proved to be a new obstacle in live in-person musculoskeletal POCUS training but also provided the impetus for developing virtual, remote learning options, which will likely continue to be an integral part of this training [24]. This also highlights the potential to provide virtual education for clinicians in underserved areas, including global outreach programs.

The limitations of this study included the reduced number of participants involved. A lower ICC may reflect not only the degree of interrater agreement, but also a smaller number of raters or the diverse experience of the raters. In our particular study, we had four participants, which could have contributed to this finding. Competency assessment of the proposed online curriculum was not pursued mainly given the size of the team evaluated. In addition, solicited feedback was not anonymous given the size of the group.

The one area that only attained fair interrater reliability after the second round of training in this study was B-mode and PD-mode views for the tendons of the wrists. One possible explanation for this is that scoring involved static images, as opposed to cine clips which can better distinguish hypoechoic muscle surrounding a tendon at the myotendinous junction from fluid. In addition, the presence of the retinaculum adjacent to the dorsal wrist tendons can exhibit a hypoechoic appearance, which without dynamic study to assess for anisotropy or compressibility, could potentially affect interpretation by mimicking tenosynovitis [25].

Finally, as this was a proof-of-concept study, we did not perform longitudinal follow-up of participant knowledge recall and therefore cannot comment on retention. Future qualitative studies should investigate areas of optimization in education of this pediatric musculoskeletal scoring system among varying levels of expertise, including pre- and post-curriculum knowledge

assessment, long-term follow-up, and where applicable, impact on clinical practice.

## Conclusion

Our study showed that virtual educational exercises covering normal musculoskeletal POCUS anatomy and pathologic variations related to pediatric arthritis can provide a knowledge base to physicians from different subspecialties at varying points in their training and careers. Further qualitative studies should be performed to assess areas of optimization in education of pediatric musculoskeletal POCUS and pediatric-specific musculoskeletal POCUS scoring systems. Finally, our study demonstrated that a virtual platform for pediatric musculoskeletal POCUS curricula is a feasible option, and could be implemented for pediatric rheumatology fellowship programs that do not have ready access to trained faculty or resources.

## Disclosures

Dr. Vega-Fernandez's work was supported by the Center for Clinical & Translational Science & Training (CCTST) at the University of Cincinnati funded by the National Institutes of Health (NIH) Clinical and Translational Science Award (CTSA) program, grant 2UL1TR001425-05A1 and KL2 (2KL2TR001426-05A). The content is solely the responsibility of the authors and does not necessarily represent the official views of the NIH.

## References:

1. Tarique U, Tang B, Singh M, Kulasegaram KM, Ailon J. Ultrasound Curricula in Undergraduate Medical Education: A Scoping Review. *J Ultrasound Med.* 2018 Jan;37(1):69-82. doi: 10.1002/jum.14333. Epub 2017 Jul 27. PMID: 28748549.
2. Zavitz J, Sarwal A, Schoeneck J, Glass C, Hays B, Shen E, Bryant C, Gupta K. Virtual multispecialty point-of-care ultrasound rotation for fourth-year medical students during COVID-19: Innovative teaching techniques improve ultrasound knowledge and image interpretation. *AEM Educ Train.* 2021 Aug 1;5(4):e10632. doi: 10.1002/aet2.10632. PMID: 34179677; PMCID: PMC8209882.
3. Larocque N, Shenoy-Bhangle A, Brook A, Eisenberg R, Chang YM, Mehta P. Resident Experiences With Virtual Radiology Learning During the COVID-19 Pandemic. *Acad Radiol.* 2021 May;28(5):704-710. doi: 10.1016/j.acra.2021.02.006. Epub 2021 Feb 15. PMID: 33640229; PMCID: PMC7883720.
4. Wright SA, Bell AL. Enhancement of undergraduate rheumatology teaching through the use of musculoskeletal ultrasound. *Rheumatology (Oxford).* 2008 Oct;47(10):1564-6. doi: 10.1093/rheumatology/ken324. Epub 2008 Aug 13. PMID: 18703529.
5. Torralba KD, Cannella AC, Kissin EY, Bolster MB, Salto LM, Higgs J, Samuels J, Nishio MJ, Kaeley GS, Evangelisto A, De Marco P, Kohler MJ. Musculoskeletal Ultrasound Instruction in Adult Rheumatology Fellowship Programs. *Arthritis Care Res (Hoboken).* 2020 Jun;72(6):859-870. doi: 10.1002/acr.23336. Epub 2020 May 25. PMID: 28777891.
6. Cannella AC, Kissin EY, Torralba KD, Lin C, Higgs JB, Bolster M, et al. 2019 Rheumatologic Ultrasound (RhUS) Curriculum Supplement. American College of Rheumatology; 2019. <https://assets.contentstack.io/v3/assets/bltee37abb6b278ab2c/blt457aaaf0d1d7e7a0/rheumatologic-ultrasound-curriculum-supplement.pdf>. Accessed April 11, 2022.

7. Widener BB, Cannella A, Martirosian L, Kissin EY. Modern Landscapes and Strategies for Learning Ultrasound in Rheumatology. *Rheum Dis Clin North Am.* 2020 Feb;46(1):61-71. doi: 10.1016/j.rdc.2019.09.002. PMID: 31757287.
8. Lin C, Oberle E, Curran M, Roth J, Vega-Fernandez P, DeRanieri D, Ting T, Benham H, Salto L, Torralba K. Musculoskeletal Ultrasound Instruction in US and Canadian Pediatric Rheumatology Fellowship Programs. Poster presented at: ACR Convergence 2021; 2021 November 8; Virtual. <https://acrabstracts.org/abstract/musculoskeletal-ultrasound-instruction-in-us-and-canadian-pediatric-rheumatology-fellowship-programs/>. Accessed April 11, 2022.
9. Roth J, Ravagnani V, Backhaus M, Balint P, Bruns A, Bruyn GA, Collado P, De la Cruz L, Guillaume-Czitrom S, Herlin T, Hernandez C, Iagnocco A, Jousse-Joulin S, Lanni S, Lilleby V, Malattia C, Magni-Manzoni S, Modesto C, Rodriguez A, Nieto JC, Ohndorf S, Rossi-Semerano L, Selvaag AM, Swen N, Ting TV, Tzaribachev N, Vega-Fernandez P, Vojinovic J, Windschall D, D'Agostino MA, Naredo E; OMERACT Ultrasound Group. Preliminary Definitions for the Sonographic Features of Synovitis in Children. *Arthritis Care Res (Hoboken).* 2017 Aug;69(8):1217-1223. doi: 10.1002/acr.23130. PMID: 27748074.
10. Roth J, Jousse-Joulin S, Magni-Manzoni S, Rodriguez A, Tzaribachev N, Iagnocco A, Naredo E, D'Agostino MA, Collado P; Outcome Measures in Rheumatology Ultrasound Group. Definitions for the sonographic features of joints in healthy children. *Arthritis Care Res (Hoboken).* 2015 Jan;67(1):136-42. doi: 10.1002/acr.22410. PMID: 25047864.
11. Collado P, Windschall D, Vojinovic J, Magni-Manzoni S, Balint P, Bruyn GAW, Hernandez-Diaz C, Nieto JC, Ravagnani V, Tzaribachev N, Iagnocco A, D'Agostino MA, Naredo E; OMERACT ultrasound subtask force on pediatric. Amendment of the OMERACT ultrasound definitions of joints' features in healthy children when using the DOPPLER technique. *Pediatr Rheumatol Online J.* 2018 Apr 10;16(1):23. doi: 10.1186/s12969-018-0240-2. PMID: 29631610; PMCID: PMC5892017.
12. Sande NK, Bøyesen P, Aga AB, Hammer HB, Flatø B, Roth J, Lilleby V. Development and reliability of a novel ultrasonographic joint-specific scoring system for synovitis with reference atlas for patients with juvenile idiopathic arthritis. *RMD Open.* 2021 Apr;7(2):e001581. doi: 10.1136/rmdopen-2021-001581. PMID: 33883255; PMCID: PMC8061832.
13. Ting TV, Vega-Fernandez P, Oberle EJ, De Ranieri D, Bukulmez H, Lin C, Moser D, Barrowman NJ, Zhao Y, Benham HM, Tazan L, Thatayatikom A, Roth J; Childhood Arthritis and Rheumatology Research Alliance Juvenile Idiopathic Arthritis Ultrasound Workgroup. Novel Ultrasound Image Acquisition Protocol and Scoring System for the Pediatric Knee. *Arthritis Care Res (Hoboken).* 2019 Jul;71(7):977-985. doi: 10.1002/acr.23746. Epub 2019 Jun 12. PMID: 30192069.
14. Rossi-Semerano L, Breton S, Semerano L, Boubaya M, Ohanyan H, Bossert M, Boiu S, Chatelus E, Durand G, Jean S, Goumy L, Mathiot A, Mouterde G, Nugues F, Ould Hennia A, Rey B, Von Scheven A, Sparsa L, Devauchelle-Pensec V, Jousse-Joulin S. Application of the OMERACT synovitis ultrasound scoring system in juvenile idiopathic arthritis: a multicenter reliability exercise. *Rheumatology (Oxford).* 2021 Aug 2;60(8):3579-3587. doi: 10.1093/rheumatology/keaa804. PMID: 33374013.
15. Vega-Fernandez P, Ting TV, Oberle EJ, McCracken C, Figueroa J, Altaye M, Cassedy A, Kaeley GS, Roth J; CARRA Musculoskeletal Ultrasound Workgroup. The MUSICAL pediatric ultrasound examination - a comprehensive, reliable, time efficient assessment of synovitis. *Arthritis Care Res (Hoboken).* 2021 Jul 30;10.1002/acr.24759. doi: 10.1002/acr.24759. Epub ahead of print. PMID: 34328679; PMCID: PMC8800943.
16. Vega-Fernandez P, De Ranieri D, Oberle E, Clark M, Bukulmez H, Lin C, Shenoi S, Thatayatikom A, Woolnough L, Benham H, Brunner E, Henrickson M, Pratt LR, Proulx-Gauthier JP, Janow G, Cassedy A, Ting TV, Roth J; CARRA JIA Ultrasound Workgroup. Comprehensive and reliable sonographic assessment and scoring system for inflammatory lesions of the pediatric ankle. *Rheumatology (Oxford).* 2022 Oct 29;keac622. doi: 10.1093/rheumatology/keac622. Epub ahead of print. PMID: 36308429.
17. Vega-Fernandez P, Esteban Y, Oberle E, Proulx-Gauthier JP, Clark M, Shenoi S, Thatayatikom A, Benham H, Brunner EJ, Woolnough L, Henrickson M, Pratt LR, De Ranieri D, Hoffmann S, Janow G, Bukulmez H, Altaye M, Cassedy A, Ting TV, Roth J; CARRA JIA Ultrasound Workgroup. Reliability of the Pediatric Specific

Musculoskeletal Ultrasound Scoring Systems for the Elbow, Wrist, and Finger Joints. *J Rheumatol*. 2022 Oct 1;jrheum.220382. doi: 10.3899/jrheum.220382. Epub ahead of print. PMID: 36182106.

18. Cicchetti DV. Guidelines, criteria, and rules of thumb for evaluating normed and standardized assessment instruments in psychology. *Psychological Assessment*. 1994;6(4):284–90.

19. Hallgren KA. Computing Inter-Rater Reliability for Observational Data: An Overview and Tutorial. *Tutor Quant Methods Psychol*. 2012;8(1):23-34. doi: 10.20982/tqmp.08.1.p023. PMID: 22833776; PMCID: PMC3402032.

20. Widener BB, Cannella A, Martirosian L, Kissin EY. Modern Landscapes and Strategies for Learning Ultrasound in Rheumatology. *Rheum Dis Clin North Am*. 2020 Feb;46(1):61-71. doi: 10.1016/j.rdc.2019.09.002. PMID: 31757287.

21. Conlon TW, Nishisaki A, Singh Y, Bhombal S, De Luca D, Kessler DO, Su ER, Chen AE, Fraga MV. Moving Beyond the Stethoscope: Diagnostic Point-of-Care Ultrasound in Pediatric Practice. *Pediatrics*. 2019 Oct;144(4):e20191402. doi: 10.1542/peds.2019-1402. Epub 2019 Sep 3. PMID: 31481415.

22. Childhood Arthritis and Rheumatology Research Alliance. (2019). Childhood Arthritis and Rheumatology Research Alliance 2019 Annual Meeting. CARRA - Childhood Arthritis and Rheumatology Research Alliance. Retrieved June 8, 2022, from <https://carragroup.org/meetings-events/past-carra-annual-scientific-meetings/2019-annual-meeting>

23. Roth J, Malattia C, Windschall D. Abbvie - ped-mus [Internet]. *Ped-MUS*. [cited 2022Sep8]. Available from: <https://www.ped-mus.com/>

24. Di Matteo A, Mankia K, Filippucci E, Grassi W, Rowbotham E, Wakefield RJ. Facing the challenges of running a rheumatology-based ultrasound service in the COVID-19 era. *Rheumatology (Oxford)*. 2021 Mar 2;60(3):1013-1015. doi: 10.1093/rheumatology/keaa844. PMID: 33331890; PMCID: PMC7798732.

25. Chiavaras MM, Jacobson JA, Yablon CM, Brigido MK, Girish G. Pitfalls in wrist and hand ultrasound. *AJR Am J Roentgenol*. 2014 Sep;203(3):531-40. doi: 10.2214/AJR.14.12711. PMID: 25148155.

# A Prospective Cohort Study to Evaluate Needle Passes Using a Portable Ultrasound Device versus Traditional Landmark Approach for Epidural Anesthesia in a Busy Obstetric Tertiary Care Center

Antonio Gonzalez Fiol, MD<sup>1\*</sup>; Pedro Acevedo Rodriguez, MD<sup>1</sup>; Xiwen, Zhao, PhD<sup>1</sup>; Robert Gaiser, MD<sup>1</sup>; Adriana Herrera, MD<sup>1</sup>; Aymen Alian, MD<sup>1</sup>

(1) Department of Anesthesiology, Yale School of Medicine, New Haven, Connecticut

## Abstract

Despite its many cited benefits, ultrasound guidance for neuraxial procedures is not widespread in anesthesiology. Some cited limitations include device cost and accessibility. We test the hypothesis that a handheld and relatively inexpensive ultrasound can improve neuraxial proficiency (e.g., decreased needle manipulations and block time). This prospective study compared the number of needle passes, redirections, and procedural time between epidural placed with a handheld ultrasound versus landmarks. Needle passes and attempts were defined as the number of times the Tuohy needle was redirected, and the times skin was punctured (re-insertion). Procedural time was defined as the time from local anesthetic infiltration until loss of resistance was obtained. The impact of level of training and accuracy of the device were also analyzed. 302 patients receiving labor epidural were included in the study. No difference in body mass index (BMI) nor distribution of level of training was noted between the groups. Regression analysis adjusted for BMI demonstrated a decrease in needle passes (-1.75 (95% CI -2.62, -0.89),  $p < 0.001$ ), needle attempts (-0.51 (95% CI -0.97, -0.04),  $p = 0.032$ ) and procedural time (-154.67s 95% CI -303.49s, -5.85s),  $p = 0.042$ ) when a handheld ultrasound was utilized. The mean (95% Confidence interval) difference between needle depth and ultrasound depth was 0.39 cm (0.32, 0.46),  $p < 0.001$ . The use of a handheld device resulted in statistically significant decrease of needle manipulations and block time. More research is needed to evaluate the impact of and increase in accessibility of ultrasound technology.

## Introduction

Neuraxial anesthesia procedures are one of the few procedures anesthesiologists perform that mainly rely on proceduralists tactile feedback without needle visualization. Many of the techniques that once were performed by utilizing anatomic landmark (e.g., central line placement) or nerve block using stimulators are now performed with ultrasound (US) guidance. The first description of US guidance for neuraxial anesthesia occurred in 1980, demonstrating good correlation between estimated depth from skin to epidural space [1,2]. Proponents of ultrasound-guided neuraxial block, including the National Institute for Health and Care Excellence (NICE) have cited improved efficacy of block placement (e.g., first attempt success), decreased

epidural catheter failure rate, and better localization of the epidural space in patients with poor anatomical landmarks or abnormal anatomy (e.g., scoliosis) [3–6].

Despite the benefits of US guided neuraxial blockade, its use has not gained traction over the years. Some limitations to the incorporation of its use includes time constraints, lack of formal training, limited availability, high cost of ultrasound devices, ease of use and storage space [7,8]. Technological advancements, such as the utilization of capacitive micro-machined ultrasound transducers (CMUTs) instead of piezoelectric crystals has allowed for the creation of more portable and affordable devices. The Butterfly iQ ultrasound (Butterfly Network, Burlington, MA) device is a handheld that utilizes this technology and the image quality produced by their

---

\*Corresponding Author: Antonio Gonzalez Fiol, MD (email: antonio.gonzalez-fiol@yale.edu)

This work is licensed under a [Creative Commons Attribution 4.0 International License](https://creativecommons.org/licenses/by/4.0/).

Author(s) retain the copyright for their work. At the time of submission to POCUS Journal the author(s) grant the journal a limited and non revokable right to publish in the Journal under a [Creative Commons Attribution 4.0 International License](https://creativecommons.org/licenses/by/4.0/).

DOI: <https://doi.org/10.24908/pocus.v8i2.16298>

device is comparable to that of cart-based US devices, particularly for basic obstetric and anesthesiology ultrasound imaging [9]. The primary aim of this study was to evaluate the number of needle passes (redirections). Secondary outcomes include feasibility, time from start of procedure to loss of resistance, and number of needle attempts. Secondary outcomes included accuracy of the device (defined as the difference between the actual depth from skin to epidural space minus the estimated depth from skin to epidural space calculated by the Butterfly iQ device) and impact of level of training over the primary and secondary outcomes with and without neuraxial US guidance.

**Methods**

After approval by the Internal Review Board (IRB) at Yale New Haven Hospital (ID# - 2000030405), this prospective cohort study was conducted from September 2021 to May 2022. The strengthening the reporting of observational studies in epidemiology (STROBE) guidelines were followed. Laboring women requesting epidural analgesia were recruited after giving verbal consent. Patients were assigned to one of two groups: landmark, or US guided neuraxial placement according to attending anesthesiologist preference. Inclusion criteria was laboring parturient ASA Physical Status I-III. Exclusion criteria were patients with a contraindication for neuraxial anesthesia (e.g., coagulopathy), known diagnosis of scoliosis, or history of spinal surgery.

**Ultrasound and landmark assessment**

Patients were placed in the seated position and instructed to flex their lumbar spine. For patients in the landmark approach (LM) cohort, the iliac crest was palpated, and spaces were determined at that intersection point. An anesthesia provider (resident, fellow or Certified Registered Nurse Anesthetists) level of training (LOT) 1 – 4 performed the labor epidural utilizing a loss of resistance technique at the level that was the most favorable to them. Level of training was defined according to years of experience in the field of anesthesia, with residents in the first clinical year of anesthesia being LOT 1, LOT 2 or 3 if on their second or third year, respectively. Fellows, attendings and Certified Registered Nurse Anesthetists (CRNAs) were considered – LOT 4, given at least 4 years of experience in the field. In the ultrasound cohort, the iliac crest was identified, and a transverse ultrasound scan was performed starting at the intercrystal line (also known as the Tuffier’s line). The US technique was performed utilizing a handheld second-generation Butterfly iQ + US device (Figure 1), with the abdomen preset, and performed by one of two researchers (AG-F or AA), both with > 5 years of experience performing US guided neuraxial anesthesia procedures. The US probe was moved vertically upward until the posterior and anterior complexes were clearly visualized. A line was drawn at the midpoint of the probe in the horizontal and vertical plane as previously described by Balki et al [10]. The image was frozen, and

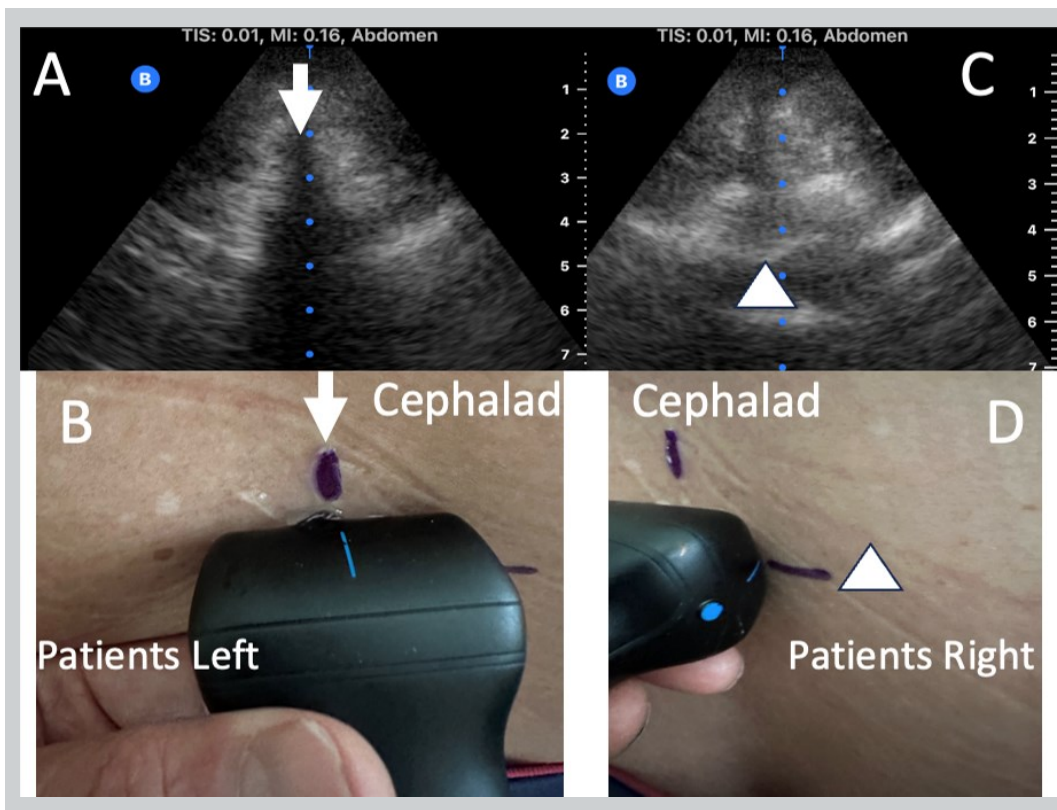


Figure 1. Image A demonstrates the acoustic shadow that characterizes the spinous process (arrow). Image B depicts the marking of the patients midline (arrow). Image C. can be obtained by moving the ultrasound in a cephalad or caudad position after obtaining image A. The arrowhead tip is pointing at the posterior complex which is composed of the ligamentum flavum and the dura. This view is utilized to mark the interspace as demonstrated by Image D, depicting the marking of the interspace (arrowhead).



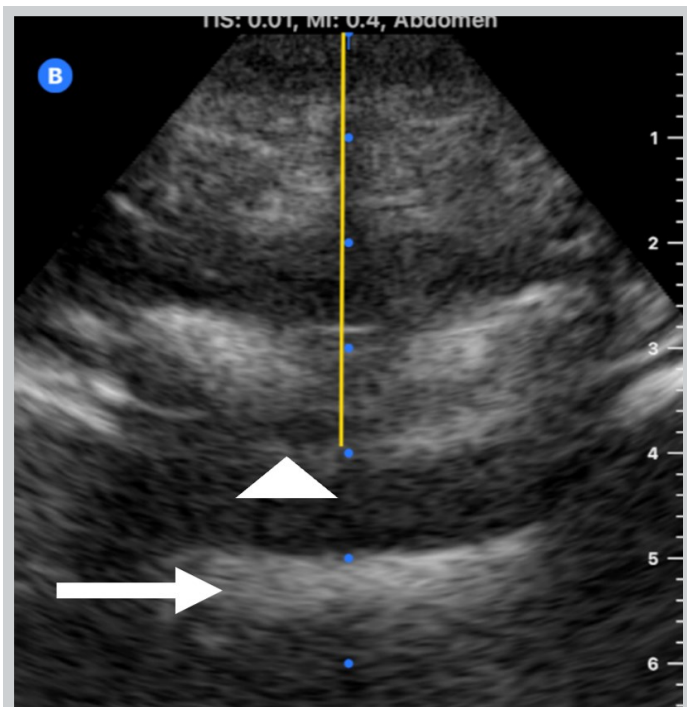


Figure 2. Butterfly US image showing posterior complex (arrow head) that represents Ligamentum flavum and dura, and anterior complex (arrow) which represents vertebral body. Yellow line represents the caliper measuring the distance between skin and posterior complex.

the built-in caliper was utilized to measure (to the 2nd tenth of a decimal point) the estimated distance from skin to the posterior complex (Figure 2). To limit collection bias, the times and number of needle passes and attempts (for both groups) were recorded by a third person not involved in the care of the patient.

### Epidural procedure

With the patient in the sitting position and with their lumbar spine flexed, the back was cleaned and draped. After infiltration of the skin with a 1% solution lidocaine, a 17-gauge Tuohy needle (8.9 cm) with 1 cm markings was utilized using a loss of resistance to saline or air technique. In the landmark group anesthesia providers palpated the patients back and proceeded at the location they thought were most easily palpated. In the ultrasound group, the anesthesia providers, who were blinded to the estimated distance, were asked to refrain from palpating and to proceed with the epidural at the intersection point between the horizontal and vertical markings. Upon loss of resistance the depth from skin to epidural space was visually estimated to the tenth of a decimal point. The primary outcome of needle passes was defined as any change in the angle of the Tuohy needle. Secondary outcomes for time for epidural placement (procedure time) were defined as time from local anesthetic until

time at which loss of resistance was achieved, and a needle attempt was defined as the number of times the needle was re-inserted at the skin.

### Statistical analysis

Based on previous studies that demonstrated a mean number of 4 needle passes (standard deviation of 2) in patients with “difficult backs”, and considering a difference of two passes between groups as clinically significant, a calculated 20 patients per group was needed to provide a power of 80% at a two-sided significance level of 0.05 [11,12]. Given that one of these studies demonstrated to be underpowered, we were unaware of our mean (SD) for number of needle of passes, and to account for the differences in level of training we opted to increase the number of patients to 35 per each level of training patients per group, and up to 310 patients total would be recruited to account for missing data or protocol violations. A total of 302 patients were included in the data analysis (150 US vs. 152 LM). Demographics characteristics were summarized by mean (SD) for continuous variables and count (%) for categorical variables. The difference between US and LM were tested using 2 sample test, Wilcoxon rank sum test, person’s chi square test, or fisher’s exact test when appropriate. We also run linear regression models to study association of US to attempts, passes, and block time after adjusting for the BMI and level of training. All tests were 2-sided with a significance level of 0.05. All statistical analysis were conducted in R version 4.0.2 (R core Team).

### Results

We enrolled 302 patients during the study period. One hundred fifty patients were included in the US group and 152 in the LM group. No statistically significant difference was noted regarding body mass index (BMI) between the groups. Table 1 summarizes the patients and level of training characteristics data as well as the differences in the number of needle pass, attempts and time to perform the block and percentage of success upon first attempt and pass. The unadjusted number of needle pass attempts and time to perform the block and percentage of success upon first attempt and pass by level of training are summarized in Table 2.

For the primary outcome of needle pass, after adjusting for BMI, the regression analysis demonstrated that the use of US resulted in a decrease in needle passes of -1.75 (95% CI -2.62, -0.89),  $p < 0.001$ . For the secondary outcomes of needle attempts and procedure time, the use of US also resulted in a reduction in these variables ([-0.51 (95% CI -0.97, -0.04),  $p = 0.032$ ] and [-154.67 s 95% CI -303.49s, -5.85s),  $p = 0.042$ ], respectively). When examining level of training, the regression analysis

*Table 1. Patient body mass index, level of training distribution and overall impact of handheld ultrasound over needle attempts, passes and block time.*

Characteristic	Landmark group (LM)	Ultrasound group (US)	p-value*
BMI (Kg/m <sup>2</sup> )			
Mean (SD)	32.86 (7.78)	32.82 (7.99)	> 0.9
Level of training	n/N (%)		0.6
1	3/152 (2%)	3/152 (2%)	
2	41/152 (27%)	35/150 (23%)	
3	58/152 (38%)	51/150 (34%)	
4	50/152 (33%)	61/150 (41%)	
First needle pass success	70/152 (46%)	113/150 (75%)	<0.001
First needle attempt success	91/152 (60%)	126/150 (84%)	<0.001
Needle Passes			<0.001
Mean (SD)	2.80 (2.45)	1.43 (0.55)	
Median (IQR)	2.00 (1.00 – 4.00)	1.00 (1.00 – 1.00)	
Range	2.00 (1.00 – 13.00)	1.00 (1.00 – 6.00)	
Needle Attempts			<0.001
Mean (SD)	1.79 (1.30)	1.22 (0.55)	
Median (IQR)	1.00 (1.00 – 2.00)	1.00 (1.00 – 1.00)	
Range	1 - 7	1 - 4	
Block time in seconds			<0.001
Mean (SD)	342.20 (414.62)	184 (174.28)	
Median (IQR)	215 (98.75 – 447.00)	120 (84.25 – 193.50)	

*BMI—Body mass index; IQR – Interquartile ratio; LM – landmark group; US – handheld ultrasound group; SD – Standard deviation; \*Welch Two Sample t-test; Fisher's exact test; Pearson's Chi-squared test.*

demonstrated that only LOT4 with and without the aid of US resulted in a decrease in number of needle pass [1.17 (95% CI 0.06 – 2.28), p = 0.039 and -1.39 (95% CI -2.16, -0.61), p < 0.001], respectively (Table 3).

When further evaluating procedure time, the mean (SD) time for US image acquisition was 82.10 (65.25) s. After factoring in the US-total block time (scanning + block time), the US device group time from local anesthetic to loss of resistance was faster than that of the LM group (266.06 (181.33) and 342.20 (414.62) seconds, p = 0.04, respectively). The regression analysis model (adjusted for BMI) demonstrated that BMI added 0.03 (95% CI

0.00, 0.06), p = 0.033 passes and approximately 5 seconds (95% CI 0.20, 9.58), p = 0.041, for every 1 kg/m<sup>2</sup> above 25 kg/m<sup>2</sup>. Furthermore, when all variables (e.g., BMI, LOT, use of US, LOT + use of US) were compared to LOT 2, the only factor that consistently provided statistically significant difference in the number of passes, attempts and block time was the use of US. Overall, the variables herein reported (BMI, level of training, use of ultrasound) explain less than 20% of the variance when evaluating their impact over needle passes (R<sup>2</sup>/ R<sup>2</sup> adjusted 0.165/0.147), attempts (R<sup>2</sup>/ R<sup>2</sup> adjusted 0.072/0.052) and block time (R<sup>2</sup>/ R<sup>2</sup> adjusted 0.084/0.064). Lastly, the mean difference between needle depth and US device estimated depth was 0.39 cm (95% CI: 0.32, 0.46), p < 0.001.

**Discussion**

The most important finding in our study was that the use of ultrasound halved the number of needle passes and decreased the overall number of attempts and procedural time for epidural anesthesia. Our first needle pass and attempt success rate increased by 84% and 40%, respectively. These results echo those previously reported in several studies [11,13–16] and meta-analysis [17–19]. Time constraint is usually mentioned as a limitation for the use of US [3]. In our study the mean

*Table 2. Impact of level of training (LOT) over needle passes, attempts and block time.*

	LM group	US group	p-value
Needle Passes			
LOT 2	3.39 (2.54)	1.63 (1.09)	<0.001
LOT 3	2.90 (2.70)	1.31 (0.97)	<0.001
LOT 4	1.98 (1.71)	1.41 (0.78)	0.033
Needle attempts			
LOT 2	1.88 (1.31)	1.31 (0.63)	0.017
LOT 3	1.74 (1.29)	1.14 (0.45)	0.001
LOT 4	1.62 (1.09)	1.25 (0.60)	0.032
Procedure time in seconds			
LOT 2	402.78 (291.10)	232.82 (192.93)	0.003
LOT 3	328.66 (494.62)	132.41 (106.15)	0.005
LOT 4	264.74 (357.63)	203.28 (201.88)	0.3

*US – Handheld Ultrasound group. LM – landmark group; LOT2 – resident with 2 clinical years of experience; LOT3 – resident with 3 years of clinical experience; LOT4 – anesthesiology provider with at least 4 years of experience (e.g., Attending, fellow) or Certified Registered Nurse .*

*Table 3. Summary of the statistically significant predictors noted on the regression analysis.*

Predictors	Estimates (Confidence interval)	p-value
Needle passes		
Intercept*	3.18 (2.56 – 3.80)	<0.001
BMI	0.03 (0.00 – 0.06)	0.033
LOT4	-1.39 (-2.16 - -0.061)	<0.001
US	-1.75 (-2.62- -0.89)	<0.001
US and LOT4	1.17 (0.06 – 2.28)	0.039
Needle attempts		
Intercept*	1.80 (1.47 – 2.14)	<0.001
US	-0.51 (-0.97 - -0.04)	0.032
Block time in seconds		
Intercept*	361.17 (254.39 – 467.95)	<0.001
BMI	4.89 (0.20 – 9.58)	0.041
US	-154.67 (-303.49 - -5.85)	0.042

\* Level of training 2 – residents with at least 2 years of clinical experience were defined as the intercept. BMI – body mass index; LOT4 – anesthesiology provider with at least 4 years of experience (e.g., Attending, fellow) or Certified Registered Nurse.

scanning time was < 2min, and the addition of this time is unlikely to be of important clinical significance to the total block time. Although not evaluated in our study, other studies suggest that this decrease in needle passes and attempts has been associated with a 50% reduction technical failure (relative risk 0.51; 95% CI 0.32 – 0.80), improved maternal satisfaction, better analgesia and a decrease in reported headaches, and back pain [17–19]. These benefits may not be as evident in the concomitant presence of palpable anatomy and an experienced sonographer and provider [17–19].

The use of US guidance is more likely to yield significant improvement in the presence of abnormal or poorly palpable anatomy [5,6]. Yet, it is important to recognize that several experts in the field of neuraxial US guidance agree that this is a technique that requires practice, and perhaps unlikely to yield noticeable outcomes without a priori normal anatomy pattern recognition and marking skills [3,20]. A study by Arzola et al. [21], demonstrated that when US imaging acquisition and marking was performed by relatively inexperienced providers, there was no benefits to the use of this technology. Our study controlled for the experience of the sonographer, and it confirms an overall improvement in block insertion efficiency. As noted in Table 2, all LOT benefited from the use of US, yet this observation does not account for

the weight experience may carry. The regression analysis (Table 3) suggests that only the most experienced providers (LOT4) were able to decrease their number of needle passes with and without the use of US. These results suggests that LOT4 providers can make accurate anatomical determinations of midline and needle adjustments with and without US guidance, a finding that agrees with previous studies that suggest minimal benefit for the use of US when experienced providers perform the block [12].

Additionally, we found that the depth from skin to epidural depth was able to be estimated using handheld US within 0.46 cm. The mean and confidence intervals for the difference between needle depth and estimated US depth described in our study are in agreement with those previously cited in several studies [7,10,19,22]. Our findings also confirm that the estimated depth by US tends to underestimate the actual needle depth [3,7,21,23]. This discrepancy can be explained by a divergence between the US beam and the needle trajectory, soft tissue compression with the US probe, skin deformation by the needle, and inadvertent deviation of the needle from midline [4,10]. Overall, this technical limitation may provide an additional margin of safety for the provider [7].

Our study presents several limitations, the prospective and non-randomized study design may have predisposed to selection bias. The recording of the times and number of needle passes and attempts were recorded by a third person not involved in the care of the patient to limit data collection bias. Performer bias cannot be ruled out, it is possible that residents performed faster blocks in the US group thinking that this was the expected result, on the other hand LOT4 group may have skeptically approached the US markings. This may explain that overall LOT3 were faster than LOT4 when US was utilized. It is also possible that the most experienced providers (LOT 4), may have been requested to do blocks more for patients with suspected poorly palpable anatomy (e.g., history of a previous difficult block). Other limitations include classification of patients according to their anatomy (e.g., palpable versus poorly palpable). Another important limitation is that the needle depth was estimated, not measured. Lastly, we did not document early or late failed labor epidural which could have added information regarding the benefits or lack thereof for the use of US in establishing neuraxial analgesia.

In conclusion, the use of US in our study resulted in a decrease in the procedural time, and number of needle passes and attempts needed to locate the epidural space. These benefits were less evident when the blocks were performed by the most experienced provider, particularly in terms of procedural time. Our

study confirms that the use of handheld US, is a portable alternative to cart-based devices, and can be a useful tool in neuraxial anesthesia placement in a busy tertiary care center. Although our results regarding accuracy of depth are limited, our results suggest that the handheld US can provide information regarding depth within the previously cited margin of accuracy for cart-based and other handheld devices. Further studies are needed to assess handheld US guided epidural anesthesia's impact on failed labor epidural rate and patient satisfaction.

## Disclosures

The authors report no relevant disclosures related to this work.

## References

- Lee A. Ultrasound in obstetric anesthesia. *Semin Perinatol* 2014;**38**(6):349-358. Doi: 10.1053/j.semperi.2014.07.006.
- Sites BD, Chan VW, Neal JM, et al. The American Society of Regional Anesthesia and Pain Medicine and the European Society of Regional Anesthesia and Pain Therapy Joint Committee Recommendations for Education and Training in Ultrasound-Guided Regional Anesthesia. *Region Anesth Pain M* 2010;**35**(2):S74-80. Doi: 10.1097/aap.0b013e3181d34ff5.
- Arzola C. Preprocedure Ultrasonography Before Initiating a Neuraxial Anesthetic Procedure. *Anesthesia Analgesia* 2017;**124**(3):712-3. Doi: 10.1213/ane.0000000000001627.
- Vallejo MC, Phelps AL, Singh S, Orebaugh SL, Sah N. Ultrasound decreases the failed labor epidural rate in resident trainees. *Int J Obstet Anesth* 2010;**19**(4):373-378. Doi: 10.1016/j.ijoa.2010.04.002.
- Park S-K, Bae J, Yoo S, et al. Ultrasound-Assisted Versus Landmark-Guided Spinal Anesthesia in Patients With Abnormal Spinal Anatomy: A Randomized Controlled Trial. *Anesthesia & Analgesia* 2020;**130**(3). Doi: 10.1213/ane.0000000000004600.
- Chin KJ, Perlas A, Chan V, et al. Ultrasound imaging facilitates spinal anesthesia in adults with difficult surface anatomic landmarks. *Anesthesiology* 2011;**115**(1):94-101. Doi: 10.1097/aln.0b013e31821a8ad4.
- Carvalho B, Seligman KM, Weiniger CF. The comparative accuracy of a handheld and console ultrasound device for neuraxial depth and landmark assessment. *Int J Obstet Anesth* 2019;**39**:68-73. Doi: 10.1016/j.ijoa.2019.01.004.
- Gambling DR. Lumbar ultrasound: useful gadget or time-consuming gimmick? *Int J Obstet Anesth* 2011;**20**(4):318-20. Doi: 10.1016/j.ijoa.2010.10.001.
- Salimi N, Aymen A. Ultrasound Image Quality Comparison Between a Handheld Ultrasound Transducer and Mid-Range Ultrasound Machine. *POCUS* 2022.
- Balki M, Lee Y, Halpern S, Carvalho JCA. Ultrasound Imaging of the Lumbar Spine in the Transverse Plane; The Correlation Between Estimated and Actual Depth to the Epidural Space in Obese Parturients. *Anesthesia Analgesia* 2009;**108**(6):1876-81. Doi: 10.1213/ane.0b013e3181a323f6.
- Creaney M, Mullane D, Casby C, Tan T. Ultrasound to identify the lumbar space in women with impalpable bony landmarks presenting for elective caesarean delivery under spinal anaesthesia: a randomised trial. *Int J Obstet Anesth* 2016;**28**:12-6. Doi: 10.1016/j.ijoa.2016.07.007.
- Weiniger CF, Carvalho B, Ronel I, et al. A randomized trial to investigate needle redirections/re-insertions using a handheld ultrasound device versus traditional palpation for spinal anesthesia in obese women undergoing cesarean delivery. *Int J Obstet Anesth* 2021;**49**:103229. Doi: 10.1016/j.ijoa.2021.103229.
- Sahin T, Balaban O, Sahin L, Solak M, Toker K. A randomized controlled trial of preinsertion ultrasound guidance for spinal anaesthesia in pregnancy: outcomes among obese and lean parturients. *J Anesth* 2014;**28**(3):413-9. Doi: 10.1007/s00540-013-1726-1.
- Grau T, Leipold RW, Fatehi S, Martin E, Motsch J. Real-time ultrasonic observation of combined spinal-epidural anaesthesia. *Eur J Anaesth* 2004;**21**(1):25-31. Doi: 10.1097/00003643-200401000-00005.
- Grau T, Bartussek E, Conradi R, Martin E, Motsch J. Ultrasound imaging improves learning curves in obstetric epidural anesthesia: a preliminary study. *Can J Anesthesia* 2003;**50**(10):1047-1050. Doi: 10.1007/bf03018371.
- Singla P, Dixon AJ, Sheeran JL, et al. Feasibility of Spinal Anesthesia Placement Using Automated Interpretation of Lumbar Ultrasound Images: A Prospective Randomized Controlled Trial. *J Anesthesia Clin Res* 2019;**10**(2):878. Doi: 10.4172/2155-6148.1000878.
- Young B, Onwochei D, Desai N. Conventional landmark palpation vs. preprocedural ultrasound for neuraxial analgesia and anaesthesia in obstetrics – a systematic review and meta-analysis with trial sequential analyses. *Anaesthesia* 2021;**76**(6):818-31. Doi: 10.1111/anae.15255.
- Shaikh F, Brzezinski J, Alexander S, et al. Ultrasound imaging for lumbar punctures and epidural catheterisations: systematic review and meta-analysis. *Bmj Br Medical J* 2013;**346**(mar26 1):f1720. Doi: 10.1136/bmj.f1720.
- Perlas A, Chaparro LE, Chin KJ. Lumbar Neuraxial Ultrasound for Spinal and Epidural Anesthesia: A Systematic Review and Meta-Analysis. *Region Anesth Pain M* 2016;**41**(2):251-260. Doi: 10.1097/aap.000000000000184.
- Margarido CB, Arzola C, Balki M, Carvalho JCA. Anesthesiologists' learning curves for ultrasound assessment of the lumbar spine. *Can J Anesthesia J Can D'anesthésie* 2010;**57**(2):120-126. Doi: 10.1007/s12630-009-9219-2.
- Arzola C, Mikhael R, Margarido C, Carvalho JCA. Spinal ultrasound versus palpation for epidural catheter insertion in labour. *Eur J Anaesth* 2015;**32**(7):499-505. Doi: 10.1097/eja.0000000000000119.
- Arzola C, Davies S, Rofaeel A, Carvalho JCA. Ultrasound Using the Transverse Approach to the Lumbar Spine Provides Reliable Landmarks for Labor Epidurals. *Anesthesia Analgesia* 2007;**104**(5):1188-92. Doi: 10.1213/01.ane.0000250912.66057.41.
- Carvalho JCA. Ultrasound-facilitated epidurals and spinals in obstetrics. *Anesthesiol Clin* 2008;**26**(1):145-58-vii-viii. Doi: 10.1016/j.anclin.2007.11.007.

# Can Untrained Patients Perform Their Own Skin and Soft Tissue Ultrasound Examination by Teleguidance?

Ammar Saati, MD<sup>1\*</sup>; Arthur Au, MD<sup>2</sup>; Aditi U. Joshi, MD MSc<sup>3</sup>; Rebecca Davis, MD FACP<sup>4</sup>;  
Frances Mae West, MD MS<sup>5</sup>; Resa E Lewiss, MD<sup>6</sup>

- (1) Department of Cardiovascular Medicine Section of Vascular Medicine, Heart, Vascular and Thoracic Institute, Cleveland Clinic Foundation, Cleveland OH, USA  
(2) Department of Emergency Medicine, Thomas Jefferson University, Philadelphia PA, USA  
(3) Founder, Nagamed LLC, VP, Digital Health Intelligence, MDisrupt  
(4) Department of Internal Medicine, Thomas Jefferson University, Philadelphia PA, USA  
(5) Department of Internal Medicine, Division of Pulmonary, Allergy, & Critical Care Medicine, Thomas Jefferson University, Philadelphia PA, USA  
(6) Department of Emergency Medicine, University of Alabama at Birmingham, Birmingham AL, USA

## Abstract

**Objectives:** This pilot study aims to determine if patients untrained in performing ultrasound can self-scan to obtain images under remote clinician teleguidance during a simulated telehealth encounter. This study also seeks to describe the patients' comfort level and barriers to performing an ultrasound examination on themselves using a handheld ultrasound device. **Methods:** This was a single center prospective observational cohort study conducted over a 4-month period in 2021. Patients were eligible if they had no prior training in the use of ultrasound and in the use of teleguidance. They voluntarily consented to participate at a single ambulatory internal medicine clinic. **Results:** 20 participants were enrolled and underwent teleguidance to ultrasound their own skin and soft tissues at the antecubital fossae. Six second video clips were evaluated by 2 subject matter experts using the Point of Care Ultrasound Image Quality scale. A score >7 was considered adequate for diagnostic interpretation. The average score was 10.15/14, with a minimum score of 5/14, and maximum score of 14/14 and a standard deviation (SD) of 2.39 using a two tailed Z-score. Setting alpha at 0.05 the 95% CI was (5.47-14.83). **Conclusion:** In a pilot study of 20 participants with no ultrasound experience, untrained healthy volunteers were able to perform technically acceptable and interpretable ultrasound scans using teleguidance by a trained clinician.

## Introduction

The SARS-CoV-2 pandemic accelerated the use of telehealth with consumer adoption increasing from 11% in 2019 to 46% in 2020 [1,2]. A telehealth visit often replaced an in-person office visit for infection control and safety to the patient and healthcare team. Telehealth, the use of technology for remote medical encounters, can be an efficient way to connect doctor and patient synchronously or asynchronously. "Store and forward," a form of asynchronous telemedicine utilizes uploaded pictures by patients for evaluation by a clinician. This aids the patient evaluation and improves the diagnostic capacity of a virtual examination [3]. A systematic review

of meta-analyses from 2010 to 2019 demonstrated that telehealth can be equivalent or more clinically effective when compared to routine care [4]. One study showed that a caregiver can assist with the telehealth encounter when technology, education, or aptitude is a concern and the patient cannot manage the technology and imaging functioning themselves. Similarly, family member engagement in the telehealth encounter helps with a physical examination under clinician guidance [5].

Over the past 20 years, point of care ultrasound (POCUS) has proven to be an error-reducing tool, improving diagnostic accuracy for a variety of conditions [6-8]. Large, heavy, and difficult to operate ultrasound

---

\*Corresponding Author: Ammar Saati, MD (email: ammar.a.saati@gmail.com)

This work is licensed under a [Creative Commons Attribution 4.0 International License](https://creativecommons.org/licenses/by/4.0/).

Author(s) retain the copyright for their work. At the time of submission to POCUS Journal the author(s) grant the journal a limited and non revokable right to publish in the Journal under a [Creative Commons Attribution 4.0 International License](https://creativecommons.org/licenses/by/4.0/).

DOI: <https://doi.org/10.24908/pocus.v8i2.16454>

systems have been replaced by smaller, portable, and more affordable POCUS devices, which connect to a smartphone or a tablet. Advances in this portable technology make ultrasound more available to clinicians and patients in a variety of practice environments. As technology continues to improve, these hand-held ultrasound devices (HUS) will be ubiquitous and affordable to clinicians and patients. Telehealth physicians are primed to begin incorporating POCUS imaging into patient encounters to expand diagnostic capabilities. Studies of patients infected with SARS-CoV-2 suggest that trained patients can scan their own lungs [9]. Some HUS devices have a teleguidance feature, which allows real-time clinician guidance over video to assist the patient in image acquisition [10,11]. Artificial intelligence (AI) has also been developed for some HUS devices to assist novice sonographers in image acquisition [12]. To date, it has not been determined how HUS can effectively be integrated to support the evaluation and diagnostic accuracy during a telehealth visit.

Sargsyan et al. studied the focused assessment with sonography for trauma (FAST) examination performed by astronauts with remote guidance with excellent clinical results [13]. Jensen et al. evaluated the practical feasibility, performance, and acceptability of real-time supervision of tele-ultrasound. The authors found that distant supervision was feasible for both junior physicians and supervisors when applied to lung and cardiac ultrasound [14]. These studies support that POCUS can be incorporated into a telemedicine program under the real-time guidance from POCUS experts [15]. One case report described a patient infected with SARS-CoV-2. His clinicians monitored him from home based upon self-performed lung ultrasound examinations using a HUS device [16].

With the increased utility of telehealth and patient engagement with the use of HUS, we hypothesized that a POCUS trained clinician can remotely guide a patient to acquire clinically useful ultrasound images by self-scanning during a telehealth encounter.

Skin and soft tissue infections including cellulitis and abscesses account for nearly 4.2 million emergency department visits annually [17]. Clinicians evaluate soft tissue infections with visual inspection of the affected area for erythema, warmth, swelling and edema, followed by palpation of the area for warmth and fluctuance, suggesting an abscess or phlegmon. While the former may be indicative of cellulitis and be treated conservatively with antibiotics, abscesses may require an incision and drainage procedure for adequate source control. Studies show that POCUS aids in the accurate differentiation of cellulitis and abscess [18]. The POCUS

examination is typically straightforward where an affected part of the body is evaluated in two planes. An examination is then performed for comparison on the opposite side. The clinician looks for a cobble stoning pattern in the subcutaneous tissue concerning for cellulitis and a heterogeneous irregular bordered collection of fluid pattern suggestive of an abscess. Therefore, a single POCUS application, skin and soft tissue scan (STSS), was selected for this pilot study because cellulitis and abscess formation are common concerns prompting a visit for evaluation and because the examination tends to be straightforward.

## Materials and Methods

This was a prospective observational cohort study conducted from March to June 2021 at the Jefferson Internal Medicine Associates (JIMA) clinic in Philadelphia, PA. JIMA is an academic Internal Medicine primary care clinic with approximately 35,000 patient visits annually. The study was approved by the institutional review board committee.

### *Selection of participants*

Participants were drawn from patients with scheduled primary care visits at JIMA clinic. The principal investigator (PI = AS) attended a meeting with the primary care faculty and introduced the study with a request for assistance with patient enrollment. Each week, the JIMA physicians were contacted by the primary investigator (AS) via email. The email served as a reminder for the clinicians that the study was open for enrollment. At the end of the visit the JIMA doctor pre-screened healthy patient volunteers for enrollment. Patient inclusion criteria were: English speaking, age greater than 18, willing to participate and able to consent. The following patients were not eligible for inclusion: unstable vital signs, a rash over the area of interest, prisoners, and patients with HUS, POCUS, or teleguidance experience. The primary care physician, at the end of their regularly scheduled patient visit, would introduce the study opportunity. Interested participants were escorted to a simulated telehealth space within the clinic for consent and enrollment. The PI then confirmed that the patient met inclusion criteria and obtained written consent. Demographic variables were not collected.

### *POCUS application*

Five subject matter experts met and discussed a POCUS application felt to be straightforward for teleguidance. This application would serve as the example for the study. After three discussion sessions, the STSS application was selected by consensus. The group decided that the medial forearm in the antecubital fossa area would serve as the anatomic region for patients to self-scan.

### *HUS Equipment*

A Philips Lumify L12-4 Broadband linear array transducer (Koninklijke Philips N.V.) and a Samsung Galaxy Android tablet S6 (Samsung Electronics Co., Ltd.) constituted the HUS device. The Lumify SSTS application was pre-set, with gain and depth adjusted. For teleguidance, we used the REACTS (Remote Education, Augmented Communication, Training and Supervision) software (Innovative Imaging Technologies). This real-time, secure audio/video software enables a clinician to remotely guide another user performing a POCUS examination.

### *Scanning protocol*

The authors developed a standardized script when communicating with the participants. In the telehealth simulated room, the PI handed the HUS device to the participant and activated the REACTS application. Then the PI left the patient and moved to a separate location in the JIMA clinic. The PI started the session by making sure that the audio and visual were clear and by introducing the participants to the ultrasound probe. The PI guided the participant on how to apply gel to the probe, identify the probe marker and how to apply the probe to their own body. The participant was then, visually instructed to apply the transducer at the antecubital fossa and to slide the probe proximal and distal in the transverse position. Once that step was successful the participant was instructed to annotate (label) the ultrasound images (right or left, transverse or longitudinal). After the annotation, the participant was directed to press the record icon on the Samsung tablet to save a 10 second video clip. Participants performed self scan imaging of the right and left antecubital fossa in transverse and longitudinal planes. Participants were not taught or expected to adjust depth or gain (Video S1 and Video S2). The images were saved in a de-identified manner to the Samsung tablet and subsequently uploaded to a secured shared server at Thomas Jefferson University Hospitals.

### *Outcome measures*

The quality of the archived images was evaluated by two POCUS physician experts. They were not involved in participant enrollment and were blinded to each other's scores. They used a scoring system adapted from Dessie A, et al. to quantify the quality of the images [19]. The scoring system consists of 3 categories: 1) technical (probe choice, depth, gain), 2) scanning skills (probe control, anatomy/ landmarks), and 3) interpretability (labeling and completeness). For each subcategory the expert assigned a score of Poor (0 point), Adequate (1 Point), or Ideal (2 point). Fourteen (14) was the highest score possible. A score of <7 was considered an

inadequate study. The start time began the moment the participant established teleguidance with the PI. The end time was the moment the PI discontinued the teleguidance. Individual scores were collected through RedCap and calculated automatically. Participants were asked for feedback, and this was noted by the enrolling clinician. A descriptive statistical analysis was generated, and a two tailed Z score was calculated to measure the confidence interval (CI) of the average score. Finally, a 1 tailed t-test was calculated to compare the average score between the two evaluators.

### **Results**

Twenty-two participants were referred by the JIMA physicians. Two participants did not meet inclusion criteria and were excluded due to prior POCUS experience. Twenty final participants performed teleguided self-scanning. The two POCUS credentialed evaluators (AA, FMW) reviewed all images for the 20 participants.

The L12-4 Broadband linear array transducer was used by all the participants and received an ideal score representing 100%. With regard to depth the majority 62.5% had an ideal depth. The preset for gain was already set to soft tissue study, 20% had adequate gain for visualization of the area of interest and 80% had an ideal gain setting. Probe control was excellent in 30%, fair in 35% and poor in 35% of studies evaluated. Anatomy landmark recognition was excellent in 35%, fair in 52.5%, and poor in 12.5% of studies. Participant labeling was ideal in 45%, adequate in 42.5%, and poor in 12.5% of clips. For the completeness of viewing all clips 47.5% were ideal, 37.5% were adequate, and 15% were poor (Table 1).

The average duration spent scanning was 10.6 minutes with a minimum of 5 minutes and a maximum of 20 minutes (Figure 1).

The average total score was 10.15/14, minimum score 5/14, and maximum score 14/14 with a standard deviation (SD) of 2.39. Using a two tailed Z-score, setting alpha at 0.05 the 95% CI was (5.47-14.83).

For evaluator 1 the average score was 11.2/14 with a SD 2.11 and a 95% CI was (7.04-15.35). Evaluator 2 had an average score of 9.1/14; SD 3.14 and a 95% CI was (2.93-15.26). The results indicated a statistically significant difference between the mean scores of evaluator 1 and evaluator 2, as determined by a one-tailed T-test with a P value of 0.0005 (Figure 2).

Participants' provided feedback predominantly about the challenge of labeling the images. One participant felt the gel was difficult to apply. One participant commented that the application would be easier for a younger generation. Another participant forgot their eyeglasses. And finally,

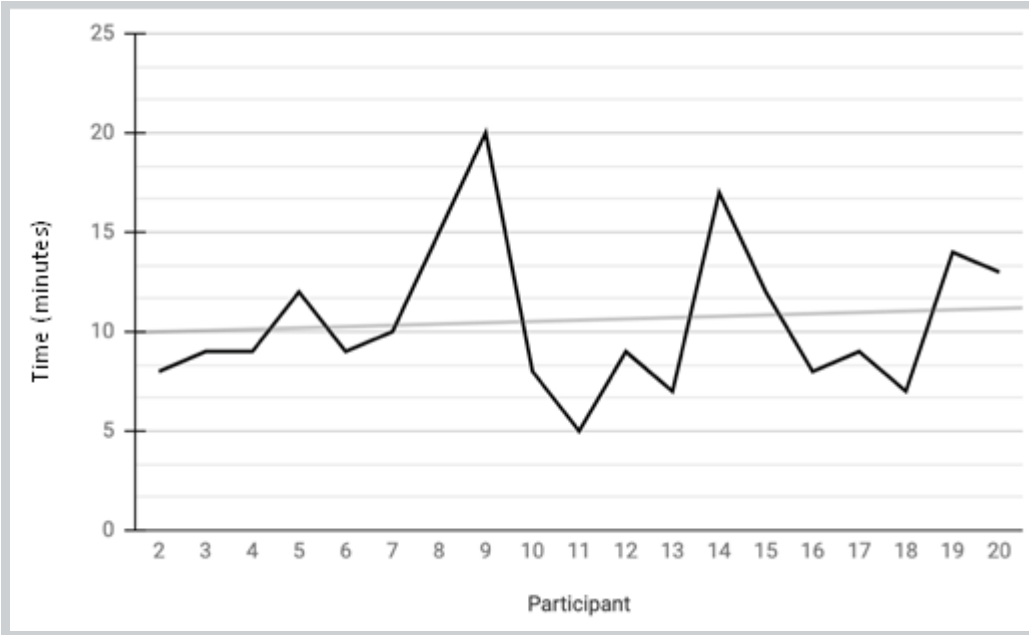


Figure 1. Line graph demonstrating the amount of time for each participant teleguidance encounter. In this figure, time in minutes is plotted along the Y axis. The participant is plotted on the X axis (n = 20). Participant 1 is the first patient enrolled. Participant 20 is the last patient enrolled. The encounters took an average of 10.6 minutes. The shortest encounter took 5 minutes. The longest encounter took 20 minutes.

one patient was hard of hearing and found teleguidance difficult. Anecdotally, participants expressed excitement about the technology. They expressed optimism that POCUS examinations performed with the assistance of teleguidance had promise to augment patient care.

**Discussion**

The primary aim of this study was to determine whether participants with no POCUS or teleguidance experience could perform an adequate and interpretable STSS of the antecubital fossae. We found that 85% of participants were able to obtain adequate images using the POCUS Image Quality Assessment Tool [19].

The SARS-CoV-2 pandemic accelerated the use, acceptance, and necessity for telehealth [20]. The use of

POCUS has been utilized by emergency physicians for three decades [21], allowing minimally invasive, quickly gathered information to improve diagnostic accuracy. The use of ultrasound by patients could enhance telemedicine care by improving evaluation and diagnostics, with studies showing feasibility with teleguidance.

It was previously observed that participants younger than 80 years old who use the internet daily can obtain ultrasound images with minimal instruction [22]. In our study, one participant noted that the application might be easier for a younger generation with more exposure to tablets and their associated application software. The average scan time duration of 10 minutes was thought to be reasonable and was acceptable to the participants.

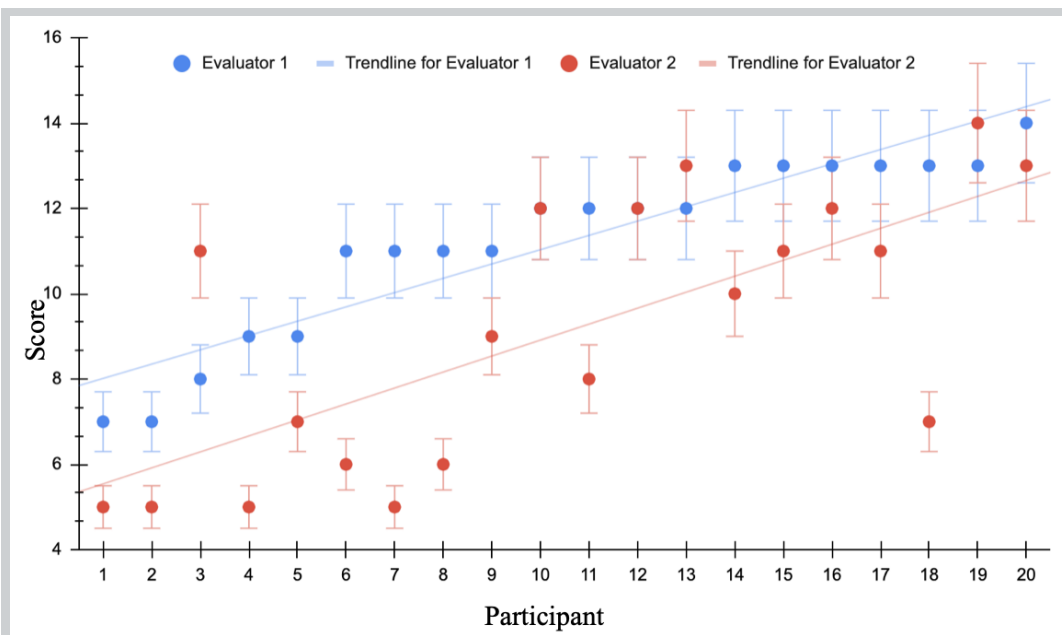


Figure 2. Scatter plot of each participant with their corresponding score for image quality of POCUS obtained via teleguidance. A maximum of 14 possible points could be obtained. Blue represents Evaluator 1. Red represents Evaluator 2. The X axis illustrates a participant with random assignment from 1 to 20. The Y axis represents the total score assigned by the evaluator.



*Table 1. Graded image quality of point of care ultrasound examinations obtained via teleguidance. Two POCUS expert clinicians scored the images for N = 20 participants. The quality scoring system falls into three categories: Technical, Scanning skills, and Interpretability.\**

<b>Technical</b>			
	Inadequate	Adequate	Ideal
1- Probe choice	0	0	100%
2- Depth	10%	27.5%	65.5%
3- Gain/preset	0	20%	80%
<b>Scanning Skills</b>			
	Poor	Fair	Excellent
1- Probe control	35%	35%	30%
2- Anatomy Landmarks	12.5%	52.5%	35%
<b>Interpretability</b>			
	Inadequate	Adequate	Ideal
1- Labeling	12.5%	42.5%	45%
2- Completeness	15%	37.5%	47.5%
* Permission granted from Almaz Dessie MD (6/3/2021) [19].			

Overall, these results suggest that HUS can be used by untrained participants over a telehealth encounter with instruction. Teleguidance has the potential to enhance remote care and improved access for patients in rural or resource limited and disaster areas. Teleguidance can also be utilized during telemedicine encounters to assist an untrained clinician to obtain ultrasound images for consultation and education. Further studies are needed to evaluate if patient-performed HUS studies are attainable for diagnostic utility. Such findings might suggest an expansion of ultrasound training and instruction in tele guidance.

In conclusion, participants in this pilot study were able to obtain adequate SSTS, utilizing HUS with teleguidance by a POCUS trained physician. This practice could prove valuable in telemedicine evaluations and diagnoses.

#### *Limitations*

There are several limitations to this pilot investigation. This was a single center study and the participant

enrollment was small in number and performed by one clinician. Participants were not randomized. Since skin and soft tissue ultrasound was the one application tested, the patient self-scan may not be generalizable to other ultrasound applications. It is unclear why the evaluator scores differed. Future studies could include more evaluators or more participants to see if this is a true discrepancy. In addition, more time could have been dedicated to educating the evaluators. Participants were observed to scan quickly over the anatomic area of interest despite instructions to move the probe slowly. All studies were of normal soft tissue. It is unclear how well patients would be able to self-scan over an affected area of cellulitis or abscess.

Although the average time to perform the POCUS examination was 10 minutes, it is not clear how this would affect the workflow of a telemedicine encounter. This study also made use of a simulated telemedicine encounter without the barriers of connectivity, devices, or ability to upload images. If telemedicine encounters and

HUS are used at home, further studies on home encounters are needed. Future investigations are needed with a larger sample size and more evaluators.

### Acknowledgments

The authors acknowledge the contributions of the following: Anna Marie Chang MD, Barry Ziring MD, and the Jefferson Internal Medicine Ambulatory clinicians and teams.

### Disclosures

This work has not been presented at meetings, no grant support was received. REL serves on the Medical Advisory Board for EchoNous, on the board of PURE, on the board of Society for Clinical Ultrasound Fellowships (SCUF), and previously received equipment support from Phillips Healthcare and Butterfly Network. Otherwise, there are no disclosures of relevant commercial interests.

### References

1. Telehealth: A quarter-trillion-dollar post-COVID-19 reality? Oleg Bestseny-Greg Gilbert-alex Harris-Jennifer Rost- <https://www.mckinsey.com/industries/healthcare-systems-and-services/our-insights/telehealth-a-quarter-trillion-dollar-post-covid-19-reality?cid=eml-web>
2. Bashshur R, Doarn CR, Frenk JM, Kvedar JC, Woolliscroft JO. Telemedicine and the COVID-19 Pandemic, Lessons for the Future. *Telemed J E Health*. 2020 May;26(5):571-573. doi: 10.1089/tmj.2020.29040.rb. Epub 2020 Apr 8. PMID: 32275485
3. Schwamm LH. Telehealth: seven strategies to successfully implement disruptive technology and transform health care. *Health Aff (Millwood)*. 2014 Feb;33(2):200-6. doi: 10.1377/hlthaff.2013.1021. PMID: 24493761
4. Snoswell CL, Chelberg G, De Guzman KR, Haydon HH, Thomas EE, Caffery LJ, SMith AC. The clinical effectiveness of telehealth: A systematic review of meta-analyses from 2010 to 2019. *J Telemed Telecare*. 2021 Jun 29;1357633X211022907. doi: 10.1177/1357633X211022907. Epub ahead of print. PMID: 34184580.
5. Benziger CP, Huffman MD, Sweis RN, Stone NJ. The Telehealth Ten: A Guide for a Patient-Assisted Virtual Physical Examination. *Am J Med*. 2021 Jan;134(1):48-51. doi: 10.1016/j.amjmed.2020.06.015. Epub 2020 Jul 18. PMID: 32687813; PMCID: PMC7368154.
6. Gaspari R, Weekes A, Adhikari S, Noble VE, Nomura JT, Theodoro D, Woo M, Atkinson P, Blehar D, Brown SM, Caffery T, Douglass E, Fraser J, Haines C, Lam S, Lanspa M, Lewis M, Liebmann O, Limkakeng A, Lopez F, Platz E, Mendoza M, Minnigan H, Moore C, Novik J, Rang L, Scruggs W, Raio C. Emergency department point-of-care ultrasound in out-of-hospital and in-ED cardiac arrest. *Resuscitation*. 2016 Dec;109:33-39. doi: 10.1016/j.resuscitation.2016.09.018. Epub 2016 Sep 28. PMID: 27693280
7. Hilsden R, Leeper R, Koichopolos J, Vandelinde JD, Parry N, Thompson D, Myslik F. Point-of-care biliary ultrasound in the emergency department (BUSED): implications for surgical referral and emergency department wait times. *Trauma Surg Acute Care Open*. 2018 Jul 30;3(1):e000164. doi: 10.1136/tsaco-2018-000164. PMID: 30109274; PMCID: PMC6078236
8. Kim SG, Jo IJ, Kim T, Hwang SY, Park JH, Shin TG, Sim MS, Cha WC, Yoon H. Usefulness of Protocolized Point-of-Care Ultrasonography for Patients with Acute Renal Colic Who Visited Emergency Department: A Randomized Controlled Study. *Medicina (Kaunas)*. 2019 Oct 28;55(11):717. doi: 10.3390/medicina55110717. PMID: 31661942; PMCID: PMC6915595.
9. Kirkpatrick AW, McKee JL, Moeini S, Conly JM, Ma IWY, Baylis B, Hawkins W. Pioneering Remotely Piloted Aerial Systems (Drone) Delivery of a Remotely Telementored Ultrasound Capability for Self Diagnosis and Assessment of Vulnerable Populations-the Sky Is the Limit. *J Digit Imaging*. 2021 Jun 25:1-5. doi: 10.1007/s10278-021-

00475-w. Epub ahead of print. PMID: 34173090; PMCID: PMC8232562

10. Tele-ultrasound solution: Lumify with Reacts: Philips Healthcare <https://www.usa.philips.com/healthcare/sites/lumify/tele-ultrasound-solutionhttps://www.usa.philips.com/healthcare/sites/lumify/tele-ultrasound-solution>
11. Teleguidance - Butterfly Network <https://www.butterflynetwork.com/teleguidance>
12. Kosmos Point-of-Care Ultrasound, AI-Powered, Ultralightweight Kosmos - [https://kosmosplatform.com/?\\_\\_hstc=87180615.1aa083cbe989c302d70ecdb9d9ce631b.1628454440462.1628454440462.1628454440462.1&\\_\\_hssc=87180615.1.1628454440463&\\_\\_hsfp=1611281314](https://kosmosplatform.com/?__hstc=87180615.1aa083cbe989c302d70ecdb9d9ce631b.1628454440462.1628454440462.1628454440462.1&__hssc=87180615.1.1628454440463&__hsfp=1611281314)
13. Sargsyan AE, Hamilton DR, Jones JA, Melton S, Whitson PA, Kirkpatrick AW, Martin D, Dulchavsky SA. FAST at MACH 20: clinical ultrasound aboard the International Space Station. *J Trauma*. 2005;58(1):35-39. doi:10.1097/01.ta.0000145083.47032.78
14. Jensen SH, Duvald I, Aagaard R, Primdahl SC, Petersen P, Kirkegaard H, Weile J. Remote Real-Time Ultrasound Supervision via Commercially Available and Low-Cost Tele-Ultrasound: A Mixed Methods Study of the Practical Feasibility and Users' Acceptability in an Emergency Department. *J Digit Imaging*. 2019;32(5):841-848. doi:10.1007/s10278-018-0157-9
15. Britton N, Miller MA, Safadi S, Siegel A, Levine AR, McCurdy MT. Tele-Ultrasound in Resource-Limited Settings: A Systematic Review. *Front Public Health*. 2019; 7:244. Published 2019 Sep 4. doi:10.3389/fpubh.2019.00244
16. Pivetta E, Girard E, Locascio F, Lupia E, Martin JD, Stone M. Self-Performed Lung Ultrasound for Home Monitoring of a Patient Positive for Coronavirus Disease 2019. *Chest*. 2020;158(3):e93-e97. doi: 10.1016/j.chest.2020.05.604
17. Prusakowski MK, Kuehl DR. Trends in emergency department management of skin abscesses. *Am J Infect Control*. 2015 Apr 1;43(4):336-40. doi: 10.1016/j.ajic.2015.01.012. Epub 2015 Feb 25. PMID: 25726132
18. Subramaniam S, Bober J, Chao J, Zehtabchi S. Point-of-care Ultrasound for Diagnosis of Abscess in Skin and Soft Tissue Infections. *Acad Emerg Med*. 2016 Nov;23(11):1298-1306. doi: 10.1111/acem.13049. Epub 2016 Nov 1. PMID: 27770490.
19. Dessie AS, Calhoun AW, Kanjanaptom P, Gilbert GE, Ekpenyong A, Lewiss RE, Rabiner JE, Tsze DS, Kessler DO. Development and Validation of a Point-of-Care-Ultrasound Image Quality Assessment Tool: The POCUS IQ Scale. *J Ultrasound Med*. 2022 Sep 27. doi: 10.1002/jum.16095. Epub ahead of print. PMID: 36165271.
20. Bashshur R, Doarn CR, Frenk JM, Kvedar JC, Woolliscroft JO. Telemedicine and the COVID-19 Pandemic, Lessons for the Future. *Telemed J E Health*. 2020 May;26(5):571-573. doi: 10.1089/tmj.2020.29040.rb. Epub 2020 Apr 8. PMID: 32275485
21. Emergency Ultrasound Imaging Criteria Compendium. *Ann Emerg Med*. 2016 Jul;68(1):e11-48. doi: 10.1016/j.annemergmed.2016.04.028. PMID: 27343675
22. Resnikoff PM, Shi R, Spierling Bagsic SR, Kimura BJ. The Novel Concept of Patient Self-Imaging: Success in COVID-19 and Cardiopulmonary Disorders. *Am J Med*. 2021 May;134(5):e360-e361. doi: 10.1016/j.amjmed.2021.01.010. PMID: 33962720; PMCID: PMC8095725.

# Brain Point of Care Ultrasound in Young Children Receiving Computed Tomography in the Emergency Department: A Proof of Concept Study

Stephanie R Davenport, MD, FRCPC<sup>1\*</sup>; Nadya Ben Fadel, MD, FRCPC, FAAP<sup>2</sup>; Jorge Davila MD, FRCPC<sup>3</sup>; Nick Barrowman, PhD<sup>4</sup>; Vid Bijelic, MSc<sup>4</sup>; Allan E Shefrin, MD, FRCPC<sup>1</sup>

- (1) Division of Emergency Medicine, University of Ottawa, Ottawa, Ontario, Canada
- (2) Division of Neonatology, University of Ottawa, Ottawa, Ontario, Canada
- (3) Division of Diagnostic Imaging, University of Ottawa, Ottawa, Ontario, Canada
- (4) Clinical Research Unit, University of Ottawa, Ottawa, Ontario, Canada

## Abstract

**Background:** Point of Care Ultrasound (POCUS) is an important tool in pediatric emergency medicine. In neonatal intensive care medicine ultrasound is often used to evaluate the brains of sick neonates. In theory, POCUS could be used in the ED in young children to evaluate the brain for abnormal pathology. **Objectives:** To examine the ability of PEM faculty to use brain POCUS to identify clinically significant brain injuries in children with head injuries and/or abnormal neurological exams, and generate sensitivity and specificity of brain POCUS in assessing such findings. **Methods:** This study used a convenience sample of patients seen in a tertiary care pediatric centre who required a CT head. A team of physicians who were trained at a workshop for brain POCUS were on call to perform the POCUS while being blinded to the results of the CT. **Results:** 21 children were enrolled in the study. Five (24%) of the patients had a CT that was positive for intracranial bleeds. Of the 5 patients with a positive CT, 3 had a brain POCUS scan that was also positive. The two false negative brain POCUS scans were on patients with small bleeds (no surgical intervention required) on CT, as reported by radiology. The sensitivity of brain POCUS was 60% (CI 15% - 95%) with a specificity of 94% (CI 70%-100%). The diagnostic accuracy of brain POCUS was 86% (CI 64% - 97%). **Conclusion:** This small proof of concept study shows that brain POCUS is an imaging modality with reasonable sensitivity and specificity in identifying intracranial pathologies that are present on CT. Its use may be most beneficial to expedite definitive imaging and subspecialty involvement.

## Introduction

Over the last 15 years, point of care ultrasound (POCUS) has emerged as one of the most important and most utilized tools in pediatric emergency medicine (PEM) [1,2]. What was initially used as a screening tool in the assessment of major traumas to help determine the requirements for further investigation or management is now used in over 40 clinical applications including the assessment of intra-abdominal hemorrhage, cardiac views to assess function and fluid, the identification of testicular torsion and the evaluation of skull fractures [1], to list a few.

In PEM, the main modality used to urgently investigate children presenting with acute symptoms or signs consistent with brain injury and/or other pathology is unenhanced computed tomography (CT) of the head.

Although CT provides clear and accurate results, it is accompanied by several downsides. First, CT uses ionizing radiation that in children has been associated with increased risk of secondary malignancy [3]. This is especially true in young children whose tissues are particularly vulnerable to radiation [3]. Second, CT can be resource-intensive, especially in the middle of the night, when CT technicians and radiologists may not be readily available in hospital, which can lead to delays. Finally, some patients need to be sedated to transfer safely to CT and to acquire high quality images, exposing these patients to the additional risks of sedation. In contrast, POCUS is readily available at the bedside without delays and many PEM physicians are already comfortable using it for a wide variety of applications [4]. Physicians can repeat the assessment as often as clinically indicated as it imparts no radiation risk and requires no sedation or

---

\*Corresponding Author: Stephanie Davenport, MD (email: sdavenport@cheo.on.ca)

This work is licensed under a [Creative Commons Attribution 4.0 International License](https://creativecommons.org/licenses/by/4.0/).

Author(s) retain the copyright for their work. At the time of submission to POCUS Journal the author(s) grant the journal a limited and non revokable right to publish in the Journal under a [Creative Commons Attribution 4.0 International License](https://creativecommons.org/licenses/by/4.0/).

DOI: <https://doi.org/10.24908/pocus.v8i2.16435>

patient transportation. Finally, POCUS provides information immediately to the treating physicians which streamlines care, decreases length of stay, and increases patient satisfaction [1].

In neonatal intensive care, POCUS brain (described as cranial ultrasound in the neonatal literature) has become the primary imaging modality to evaluate intracranial pathology for many of the same reasons noted above [5]. POCUS is preferred over other modalities like MRI (considered the gold standard) or CT, (rarely used due to radiation) because POCUS offers ease of use and portability to the bedside of often critically ill neonates for whom moving or sedating them for alternate imaging proves potentially dangerous [5]. Furthermore, it has been shown in the neonatal literature to have high sensitivity and specificity for detecting intracranial pathology when compared to post-mortem examination of the brain [5].

The use of brain POCUS in the emergency department setting has been largely unstudied. There have been two studies published thus far in the literature that examine the use of brain POCUS as a point of care modality in the setting of trauma. The first study published by Elkunovich et al, was a retrospective study looking at brain POCUS versus CT [3] and a second study published by McCormick et al. looked at infants under two years of age presenting with closed head trauma and positive CT findings [6]. To date, no one has attempted to see if brain POCUS can be used in the emergency department to evaluate the brain of children presenting with head trauma and/or abnormal neurological exams.

In this pilot study, our primary aim was to examine the ability of brain POCUS to identify clinically significant brain injuries as defined by the Pediatric Emergency Care Applied Research Network (PECARN) as traumatic brain injuries that require neurosurgical intervention, intubation, hospital admission, or result in death [7]. Our secondary aim was to determine the sensitivity and specificity of brain POCUS in our population of children <15mo. compared to CT.

## Methods

### *Setting/Study Population*

This was a prospective feasibility study using a convenience sample of patients seen in the ED at an academic tertiary care pediatric hospital over a 2-year period. This hospital has an annual ED census of over 72,000 Patients. Over the last five years there has been an average of 30-50 children per year under the age of two who have undergone a CT of their head from the ED to evaluate for acute intracranial pathology secondary to trauma or infection. All pediatric emergency physicians who were POCUS-trained were invited to participate in a

two-hour POCUS brain workshop, designed with expertise and input from a NICU staff physician (NBF), who is formally trained in ultrasound. The brain POCUS protocol and study parameters were discussed during the workshop and there was opportunity for hands-on practice on infants. The ethics review board at this hospital reviewed and approved all aspects of this study. Please see appendix 1 for full details of POCUS training.

### *Data Collection*

All children <15 months of age presenting to the Emergency Department with head trauma or abnormal neurological signs and symptoms deemed to require a CT head by the treating ED staff physician were eligible to participate in the study. After enrollment and informed consent, each child that the treating physician sent for CT head also received a brain POCUS scan when a member of the brain POCUS team was available. The lead brain POCUS physician (SD) was on call for the department evenings and weekends most days of the month. The physicians performing the brain POCUS were blinded to the results of the CT head. The brain POCUS team physician then recorded whether they saw any abnormalities on a standardized form (Supplementary Appendix 1). This form also contained demographic information as well as other measures like the size of the fontanelle. After the results were compiled the lead author would review the CT formal reports and record any differences between the findings from the POCUS brain documentation and the formal CT radiology report (e.g., bleeds). Both the CT and brain POCUS images were then read by the radiologist on our team to ensure quality of the brain POCUS images as well as to see if additional findings on brain POCUS were missed by the performing physician. The radiologist was blinded to the results of the CT until analysis of the brain POCUS results were documented.

### *Statistical Analysis*

Sensitivity and specificity were calculated using the positive and negative findings reported on brain POCUS versus those formally reported on CT. Positive and negative predictive values were obtained similarly. The diagnostic accuracy was calculated comparing the positive findings on CT and the positive findings on brain POCUS. The kappa coefficient was calculated using the positive and negative reported findings on brain POCUS by the brain POCUS physicians and compared to the findings as reported by our radiologist who interpreted the brain POCUS results.

## Results

During the study period 21 children were enrolled. The mean age was 3 weeks and half of the patients were

Table 1. Participant characteristics (n=21).

Characteristic:	Result:
Age (weeks): Mean (SD) [range]	3.1 (2.8) [0.5, 13]
Sex:	11 F (52%), 10 M (48%)
Indication for CT/POCUS:	76% (16/21) Trauma 14% (3/21) Abnormal Neurological exam (e.g., Abnormal eye movement, seizure etc.) 5% (1/21) Cephalohematoma 5% (1/21) Subgaleal Hematoma
Anterior Fontanelle open by palpation:	95% (20/21)
Images obtained (%)	100%

female. The most common indication for patients to receive a head CT was for trauma. The other indications were primarily for abnormal neurological exams. 95% of the patients were thought to have an open fontanelle by palpation, but we were able to obtain coronal and sagittal views in 100% of the patients enrolled through the anterior fontanelle window (Table 1).

Overall, 18 (86%) of the CTs performed in our study population had a positive finding, though most were not necessarily of clinical significance. Five patients (24%) had a positive CT that showed a skull fracture. Five (24%) of the patients had a CT that was positive for intracranial bleeds. The remainder of the positive CT findings (8/18) were for incidental findings like ethmoid opacification, asymmetrical ventricles, or prominence of the extra-axial space etc. (Table 2). Of the five patients with CT that had significant findings (intracranial bleeds), 3 had a brain POCUS scan that was also positive. Two patients had false negatives on brain POCUS where CT revealed small bleeds. The first was an extra-axial hemorrhage in the occipital area and the second had a small subdural hematoma in the parietal region. Among the study patients, there was one patient who had a false positive scan by brain POCUS for a bleed not seen on CT.

The sensitivity of brain POCUS using only the clinically significant positive CT scans for bleeds was 60% (95% confidence interval [CI] 15%-95%) with a specificity of 94% (CI 70%-100%). The positive predictive value and negative predictive value were 75% (CI 19%-99%) and 88% (CI 64%-99%) respectively. The diagnostic accuracy of brain POCUS was 86% (CI 64%-97%).

When the radiologist reviewed all the images obtained by the clinician there was overall agreement of 86%. There

were 4 instances (19%) where the POCUS clinician was able to identify positive pathology that were not visible to the radiologist on repeat analysis of the POCUS brain images. The inter-rater reliability was 35% (CI 17%-97% p=0.05).

## Discussion

In this study we were able to demonstrate that brain POCUS can identify intracranial abnormalities in children under 15 months of age. All of the children in this study that had ICH identified on CT/POCUS brain were admitted to hospital for observation, thus meeting the PECARN definition of clinically significant injury. None to our knowledge required neurosurgical intervention. The most common indication for obtaining a scan where a patient had a positive brain POCUS result was trauma in assessing for intracranial hemorrhage (Figure 1, Figure 2). Additionally, the most common non-fracture positive result on CT was intracranial hemorrhage. This study did not look at skull fracture on POCUS as this has been previously studied and has shown to have good sensitivity [8]. Although still a rare event, we had a relatively high percentage of patients with a positive CT for hemorrhage and of those, brain POCUS was positive in most cases. Two patients had a positive CT scan but a negative brain POCUS. The first patient had a small occipital extra-axial hemorrhage, as reported by radiology that was not seen on POCUS brain. The second patient had a small subdural in the parietal region. These cases highlight some of the limitations of brain POCUS when assessing the convexities of the head, which are hidden due to boundaries in the sonographic window. None of the extra-axial hemorrhages had a mass effect over the adjacent brain

Table 2. Positive findings on CT.

Findings	Number of positives (%)
Positive CT findings overall	18 (85.7)
Positive CT for fracture only	5 (23.8)
Positive for Bleed	5 (23.8)
Positive for incidental findings	8 (38.1) <ul style="list-style-type: none"> <li>• Ethmoid sinus opacification (2)</li> <li>• Inflammatory changes in the maxillary and ethmoid sinuses</li> <li>• Subgaleal hematomas (2)</li> <li>• Asymmetrical ventricles (2)</li> <li>• Mild prominence of the extra-axial space in frontal regions</li> </ul>

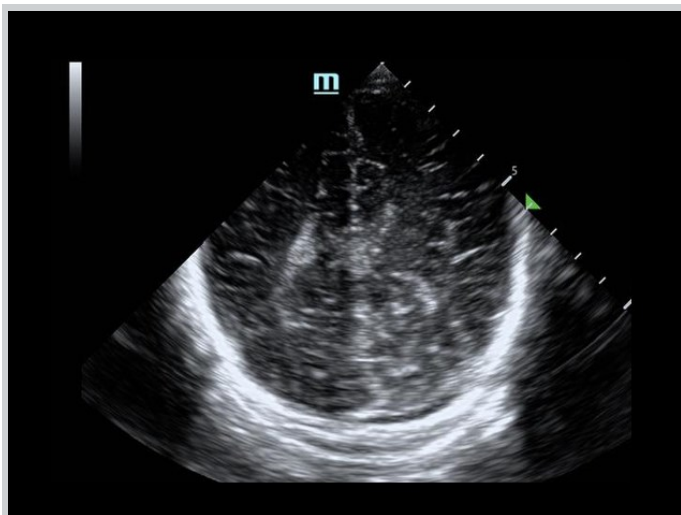


Figure 1. brain POCUS of a patient with a subdural hemorrhage, coronal view.

parenchyma. None of the patients that had a false-negative brain POCUS underwent surgical intervention. All patients with intracranial hemorrhage were admitted to our hospital for observation by the neurosurgical team. Most infants with head trauma that have not returned to baseline (more irritable, tired, poor feeding etc.) will be admitted to hospital regardless of imaging findings for observation as is our protocol at our institution.

The main barrier to routine use of brain POCUS in the ED is the patency of the anterior fontanelle, which serves as the necessary acoustic window. The anterior fontanelle is patent in more than 75% of infants at 12 months with a steady decline in patency over the next year and only 10% of infants having a patent fontanel by the age of 2 [9]. Furthermore the view through the anterior fontanelle alone limits views of the infratentorial structures including the cerebellum [10]. This is overcome by using the mastoid fossa as a second acoustic window to examine fully the brain of the infant/neonate.[10,11]. Despite this view being used in the neonatal literature, we did not detect any abnormalities with this view, and in most children >4 weeks old, the opacification of the mastoid limited anatomical views significantly.

When developing this study, we decided to have a radiologist over-read all our brain POCUS images. We anticipated that the radiologist might be able to pick up subtle findings on brain POCUS that may not have been diagnosed by the clinician. Although the radiologist found the images obtained were of sufficient quality, he was not able to see all the positive findings attained by the POCUS brain clinician. This may have been for several reasons, but is likely because POCUS is dynamic, and the clinician cannot be blinded to the patient's clinical status (e.g., knowing where the injury is on the head,

may help to focus on where to look for findings on POCUS). They may be in a better position to read the images than someone not involved in the care who only has select clips or images. As a result, the inter-rater reliability was lower than anticipated, but arguably could have been predicted due to different clinical circumstances between the ER physician and radiologist. This further highlights the added benefit of POCUS; it allows one individual to do multiple tasks that normally depend on many specialists. This increases efficiency and may improve workflow.

Literature on the use of POCUS to identify intracranial anomalies is limited despite emergency room physicians expanding its use. A recent study by Subramaniam et. al. reviewed the use and technique of transfontanelar sonography in the emergency department to identify hydrocephalus and highlights its importance as an easy to learn technique as well as a quick and accurate modality [12]. Several other studies have retrospectively looked at POCUS of the brain and compared it to the findings on CT. Elkhunovich et. Al. completed their study reviewing the sensitivity and specificity of POCUS brain in conjunction with CT or MRI done for infants presenting to hospital with suspected intra-cranial hemorrhage [3]. Although this study was performed retrospectively and

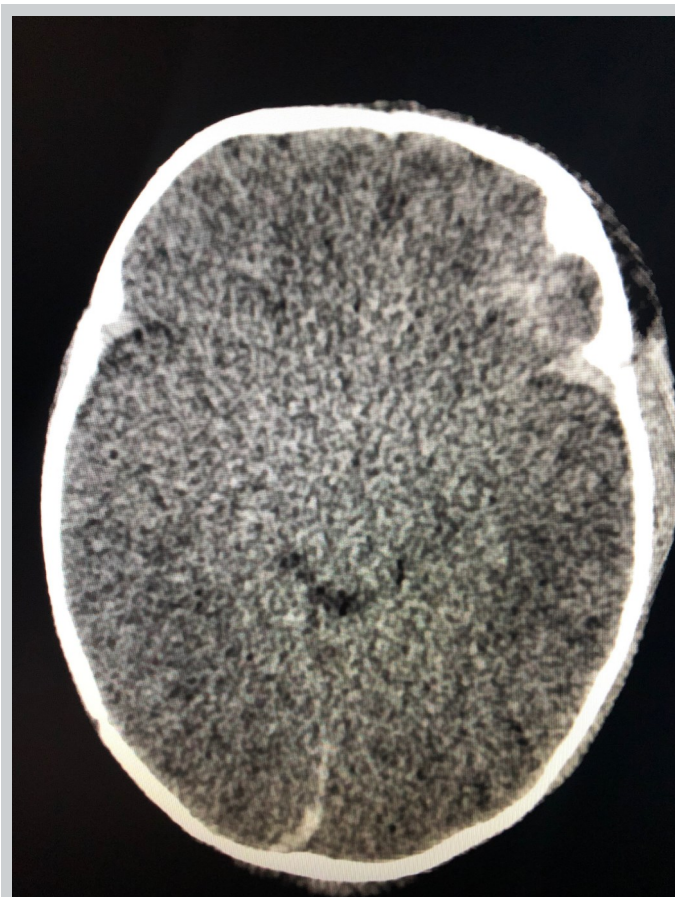


Figure 2. CT of the same patient with a subdural hemorrhage.

POCUS brain was not being done with the direct purpose of looking acutely for intracranial pathology, they found a similar sensitivity at 67% and specificity of 99% [3]. In a non-blinded study, McCormick et al performed a prospective study where POCUS was used after positive CT showed evidence of hemorrhage [6]. This study only had 12 patients, 4 of whom had CT imaging done for the direct purpose of evaluating for ICH.

To our knowledge, our study is the first to prospectively perform brain POCUS and compare it to CT on patients presenting to the ED. This study is the only study to capture the use of POCUS for the brain used in the same context that other ED POCUS modalities are used for: to attain additional information about a patient that can help determine diagnosis or disposition. We limited our brain POCUS scans to be done within a 2-hour time frame on either side of the CT scan to not favourably bias brain POCUS if a bleed progressed and therefore would have been easier to see several hours later. Further, we had PEM POCUS trained staff performing the brain POCUS in the clinical setting which is how POCUS is used every day in the ED. Unlike CT, POCUS brain can be repeated as many times as necessary to further evaluate the patient if there is a clinical need. This may be useful, particularly in PECARN intermediate risk patients who require a period of observation. As both CT and POCUS brain can be falsely negative if performed too early after a bleed, this would be a safe and efficient way to repeat imaging over time.

The limitations of our study include that most of the brain POCUS scans were performed by the primary investigator (SD). We also had a very high CT positivity rate which is much higher than the published positivity rates of 3-5% [3] and this may have led to selection bias. Halfway through our study our department upgraded our POCUS machine resulting in much better-quality images. This may have affected the false negative rate in the first year of this study and may speak to the potential that newer machines, with better technology, could improve the results of studies like ours. Lastly, there were no positive findings in our study that were picked up in the mastoid view. This could be from lack of experience using this acoustic window, or decreased sensitivity of this view in our patient population. Further studies may be required to further elucidate this difference.

## Conclusion

This study shows that brain POCUS is an imaging modality with reasonable sensitivity and specificity in identifying intracranial pathologies that are present on CT in the ED setting. Its use would be most beneficial to expedite definitive imaging and subspecialty involvement, and for patients that have had a clinical change during a period of observation. For example, an infant that

presents with decreased level of consciousness in an ED in whom a bleed is picked up on brain POCUS could have the neurosurgical and intensive-care physicians notified of their status while awaiting CT which could potentially expedite definitive management. Future research should be aimed at multicentre studies that could further elucidate the precision of POCUS brain in the setting of young infants presenting to the ED.

## Disclosures

The authors have no conflicts of interest to disclose. All funding was awarded through the Research Institute at the Children's Hospital of Eastern Ontario, Fellow Research Grant.

## Patient Consent

Patient consent was obtained by the authors in addition to approval from the hospital ethics department.

## References

1. Marin JR, Abo AM, Arroyo AC, Doniger SJ, Fischer JW, Rempell R, et al. Pediatric emergency medicine point-of-care ultrasound: summary of the evidence. *Crit Ultrasound J* [Internet]. 2016;8(1):16. Available from: <http://criticalultrasoundjournal.springeropen.com/articles/10.1186/s13089-016-0049-5>
2. Marin JR, Lewiss RE, Shook JE, Ackerman AD, Chun TH, Conners GP, et al. Point-of-care ultrasonography by Pediatric Emergency medicine physicians. *Pediatrics*. 2015;135(4):e1113–22.
3. Elkhunovich M, Sirody J, McCormick T, Goodarzi F, Claudius I (2018). The utility of cranial ultrasound for detection of intracranial hemorrhage in infants. *Pediatric Emergency Care* 34(2): 96-101.
4. Halm BM, Franke A a. Diagnosis of an intraventricular hemorrhage by a pediatric emergency medicine attending using point-of-care ultrasound: a case report. *Pediatr Emerg Care*. 2011;27(5):425–7.
5. Adcock, Lisa M; Moore PJ. 1998. - Lisa M Adcock - Correlation of Ultrasound With Postmortem Neuropathology [retrieved 2016-11-05].pdf. *Pediatr Neurol*. 1998;19(4).
6. McCormick T, Chilstrom M, Childs J, McGarry R, Seif D, Mailhot T, et al. Point-of-Care Ultrasound for the Detection of Traumatic Intracranial Hemorrhage in Infants: A Pilot Study. *Pediatr Emerg Care* [Internet]. 2015;00(00):1–3. Available from: <http://www.ncbi.nlm.nih.gov/pubmed/26308609>
7. Bressan S, Eapen N, Phillips N, Gilhotra Y, Kochar A, Dalton S, et al. PECARN algorithms for minor head trauma: Risk stratification estimates from a prospective PREDICT cohort study. *Acad Emerg Med*. 2021;28(10):1124–33.
8. Alexandridis G, Verschuuren EW, Rosendaal A V., Kanhai DA. Evidence base for point-of-care ultrasound (POCUS) for diagnosis of skull fractures in children: A systematic review and meta-analysis. *Emerg Med J*. 2020;1–7.
9. Pindrik J, Ye XB, Ji BG, Pendleton C, Ahn ES. Anterior Fontanelle Closure and Size in Full-Term Children Based on Head Computed Tomography. *Clin Pediatr (Phila)*. 2014;53(12):1149–57.
10. Steggerda SJ, de Bruïne FT, Smits-Wintjens VEJ, Walthers FJ, van Wezel-Meijler G. Ultrasound detection of posterior fossa abnormalities in full-term neonates. *Early Hum Dev* [Internet]. 2012;88(4):233–9. Available from: <http://dx.doi.org/10.1016/j.earlhumdev.2011.08.011>
11. Parodi A, Rossi A, Severino M, Morana G, Sannia A, Calevo MG, et al. Accuracy of ultrasound in assessing cerebellar haemorrhages in very low birthweight babies. *Arch Dis Child - Fetal Neonatal Ed* [Internet]. 2015;100(4):F289–92. Available from: <http://fn.bmj.com/content/100/4/F289.abstract>
12. Subramaniam S, Chen AE, Khwaja A, Rempell R. Identifying infant hydrocephalus in the emergency department with transfontanelle POCUS. *Am J Emerg Med* [Internet]. 2019;37(1):127–32. Available from: <https://doi.org/10.1016/j.ajem.2018.10.012>

# The Use of POCUS-Obtained Optic Nerve Sheath Diameter in Intracerebral Hemorrhage

Alireza Nathani, DO<sup>1\*</sup>; Shekhar A Ghamande, MD<sup>1</sup>; Sarita Kambhampati, MD<sup>1</sup>; Braden Anderson, DO<sup>1</sup>; Matthew Lohse, MD<sup>1</sup>; Heath D White, DO<sup>1</sup>

(1) Baylor Scott & White Health, Baylor College of Medicine, Temple, TX, USA.

## Abstract

**Background:** Intracerebral hemorrhage (ICH) is associated with high morbidity and mortality. ICH causes increased intracranial pressure (ICP), leading to brain herniation as the disease progresses. Neurological physical exam and monitoring of the disease progression can be challenging due to the impaired consciousness and routine clinical management in this patient population. Given the continuity of the intracranial cavity with the optic nerve subarachnoid space, an increased ICH leads to distension of the optic nerve sheath. We herein examined the correlation between the ICH volume and the optic nerve sheath diameter (ONSD) measured by point of care ultrasound (POCUS).

**Methods:** Patients with ICH diagnosed with a head computed tomography (CT) scan were prospectively enrolled in this study. A portable ultrasound was used to measure the (ONSD); the volume of ICH hematoma, the Acute Physiology And Chronic Health Evaluation IV score, and the Intracerebral Hemorrhage score were collected. A Spearman rank correlation coefficient test was used to assess the relationship between continuous variables. A Wilcoxon rank sum test was used to assess differences in continuous variables between two groups. A *p-value* less than 0.05 was deemed as statistically significant. **Results:** A total of 28 subjects were enrolled. A moderate positive correlation was detected between hemorrhage volume and the average ONSD (correlation = 0.4214, *p* = 0.0255). A weak positive correlation was detected between average ONSD and APACHE IV (correlation = 0.2347, *p* = 0.2294). A weak moderate positive correlation was detected between average ONSD and ICH score (correlation = 0.1160, *p* = 0.5566). **Conclusions:** In this study we demonstrate that ONSD is moderately correlated with hematoma size. A potential application may include serial measurements of the ONSD with ultrasound. This may offer a quick, non-invasive technique that can be used in an intracerebral hemorrhage to monitor the stability or expansion of a hematoma indirectly, and potentially catch a catastrophic event like cerebral herniation.

## Introduction

Intracerebral hemorrhage (ICH) results in spontaneous bleeding into the brain. In the United States, it accounts for 10-15% of all strokes [1]. It is associated with very high morbidity and in-hospital mortality of 32.4% [2]. In adults, the intracranial compartment is protected by the skull. The contents of the intracranial compartment include brain parenchyma, cerebrospinal fluid, and blood. Homeostasis of all three components is required to keep intracranial pressure less than 15mmHg. In an ICH, additional blood is now enclosed in the cranium which can apply pressure to normal structures of the brain. Additionally, cerebral edema will occur through a variety of mechanisms including cytotoxic cell injury that will cause further compression on normal structures. The

neurological physical exam is crucial in detecting cerebral edema, particularly compression of the brain stem, which regulates most of the body's automatic functions that are essential for life. Hence, the rapid diagnosis of increased intracranial pressure is crucial for diagnostic and therapeutic purposes in this population. The optic nerve, also known as cranial nerve II, transmits visual information from the retina to the brain. The optic nerve is surrounded by the optic nerve sheath, which is directly linked to the intracranial subarachnoid space. An increase in intracranial pressure (ICP) causes cerebral spinal fluid to move from the intracranial cavity into the optic subarachnoid space, thereby resulting in distension of the optic nerve sheath and widening of its diameter [3]. Given this physiologic relationship, our team was interested in determining if there was a direct correlation

\*Corresponding Author: Alireza Nathani, MD (email: natha027@umn.edu)

This work is licensed under a [Creative Commons Attribution 4.0 International License](https://creativecommons.org/licenses/by/4.0/).

Author(s) retain the copyright for their work. At the time of submission to POCUS Journal the author(s) grant the journal a limited and non revokable right to publish in the Journal under a [Creative Commons Attribution 4.0 International License](https://creativecommons.org/licenses/by/4.0/).

DOI: <https://doi.org/10.24908/pocus.v8i2.16563>



between the volume of hematoma in an ICH and the size of optic nerve sheath diameter (ONSD) as measured by point of care ultrasound (POCUS). For reference a normal ultrasound obtained ONSD in males is 4.66mm and 4.47mm in females [4], although there are numerous studies that have reported different values of a normal ONSD.

### Materials and Methods

This study was a prospective trial conducted at Baylor Scott & White Medical Center – Temple, TX. The study protocol was approved by and conducted under the supervision of the Baylor Scott & White Research Institute Institutional Review Boards. The study was funded by the department of neurology. Twenty-eight patients were enrolled in this study. All patients included were over the age of 18 and had the diagnosis of ICH confirmed with a non-contrast head computed tomography (CT) scan. All patients were admitted to the neurointensive care unit and managed according to the standard of care. Within six hours of the patient's admission, informed consent would be obtained from the patient or legally authorized representative to obtain POCUS images of their optic nerves. Excluded were patients with obvious ocular pathology including ocular trauma, foreign bodies in the eye, or a glass eye. Also excluded were subarachnoid hemorrhages and ischemic strokes.

A portable ultrasound device (Sonosite) was used to measure the optic nerve sheath diameter. A high frequency (5-14 MHz) probe was used to obtain images. A thin film of gel was applied to each eyelid. The optic nerve was visualized in transverse and longitudinal

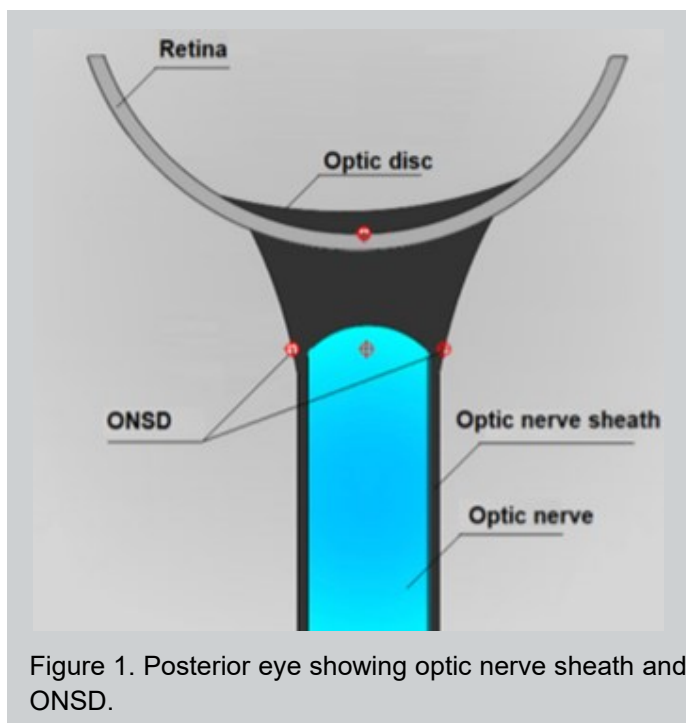


Figure 1. Posterior eye showing optic nerve sheath and ONSD.

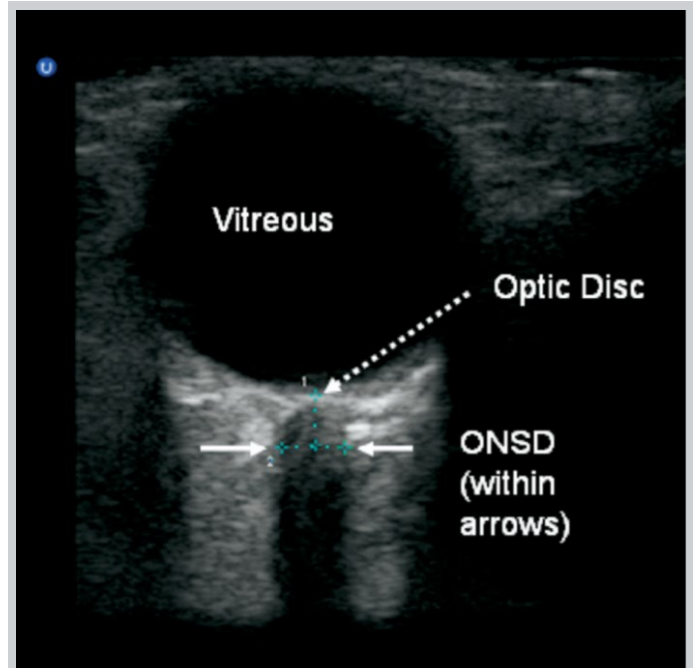


Figure 2. Ultrasound image showing components of optic nerve sheath exam.

planes. We measured from the inner edge to inner edge of the optic nerve sheath 3mm behind the optic globe [3,5]. Figure 1 is a pictorial view describing the relevant anatomic components of the posterior eye and Figure 2 illustrates what the operator sees while performing an exam [5,6]. After the exam was complete, the excess gel was wiped off the patient. Transverse and longitudinal values were obtained for each optic nerve. These values were averaged, and a single value was obtained for the left and right optic nerve. Other data collected include the volume of ICH (calculated based on the head CT scan), the APACHE (Acute Physiology And Chronic Health Evaluation) IV score, and the ICH (intracerebral hemorrhage) score. A Spearman rank correlation coefficient test was used to assess the relationship between continuous variables. A Wilcoxon rank sum test was used to assess differences in continuous variables between two groups. Statistical significance was set at  $p < 0.05$ . All statistical analyses were performed in SAS 9.4.

### Results

A total number of 28 subjects were enrolled in the study. There were 16 females and 12 males with a mean age of 67.5 years (mean: 67.5, SD: 15.0). The mean optic nerve sheath diameter was 6.36mm. The median hemorrhage volume was 7.70mL. A moderate positive correlation was detected between hemorrhage volume and the average ONSD (correlation = 0.4214,  $p = 0.0255$ , Figure 3). A weak positive correlation was detected between average ONSD and APACHE IV

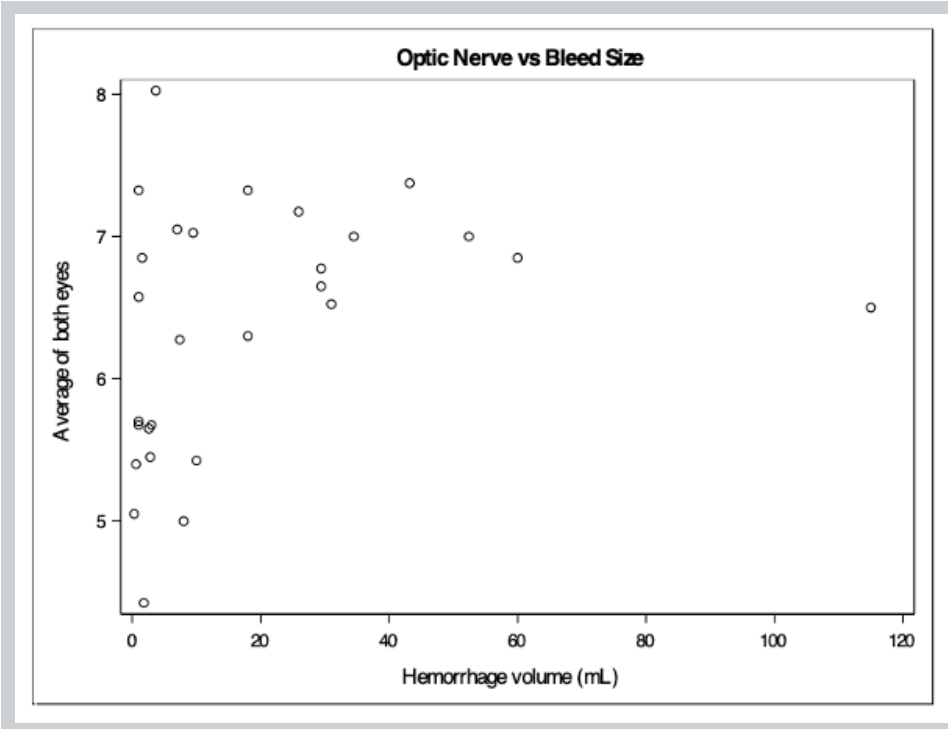


Figure 3. Average ONSD vs hemorrhage volume.

(correlation = 0.2347,  $p = 0.2294$ , Figure 4). A weak moderate positive correlation was detected between average ONSD and ICH score (correlation = 0.1160,  $p = 0.5566$ , Figure 5).

**Discussion**

Growth of an intracranial hematoma in the first twenty-four hours is an independent predictor of mortality and poor outcome [4]. The neurological exam is crucial in determining the progression of swelling in the brain. However, the accuracy and reliability of neurological

physical exams are frequently limited in these particular type of patients. Neuroanatomical areas maintaining alertness or consciousness are oftentimes damaged, and patients undergo endotracheal intubation to protect the airway and routinely require analgesia to succumb agitation. All of these can confound the neurological exam. Additionally, there are a number of teams working with the patient including the critical care team, stroke neurology, and neurosurgery, each of which may record different physical exam findings. Using POCUS to measure the ONSD in these specific situations can be an

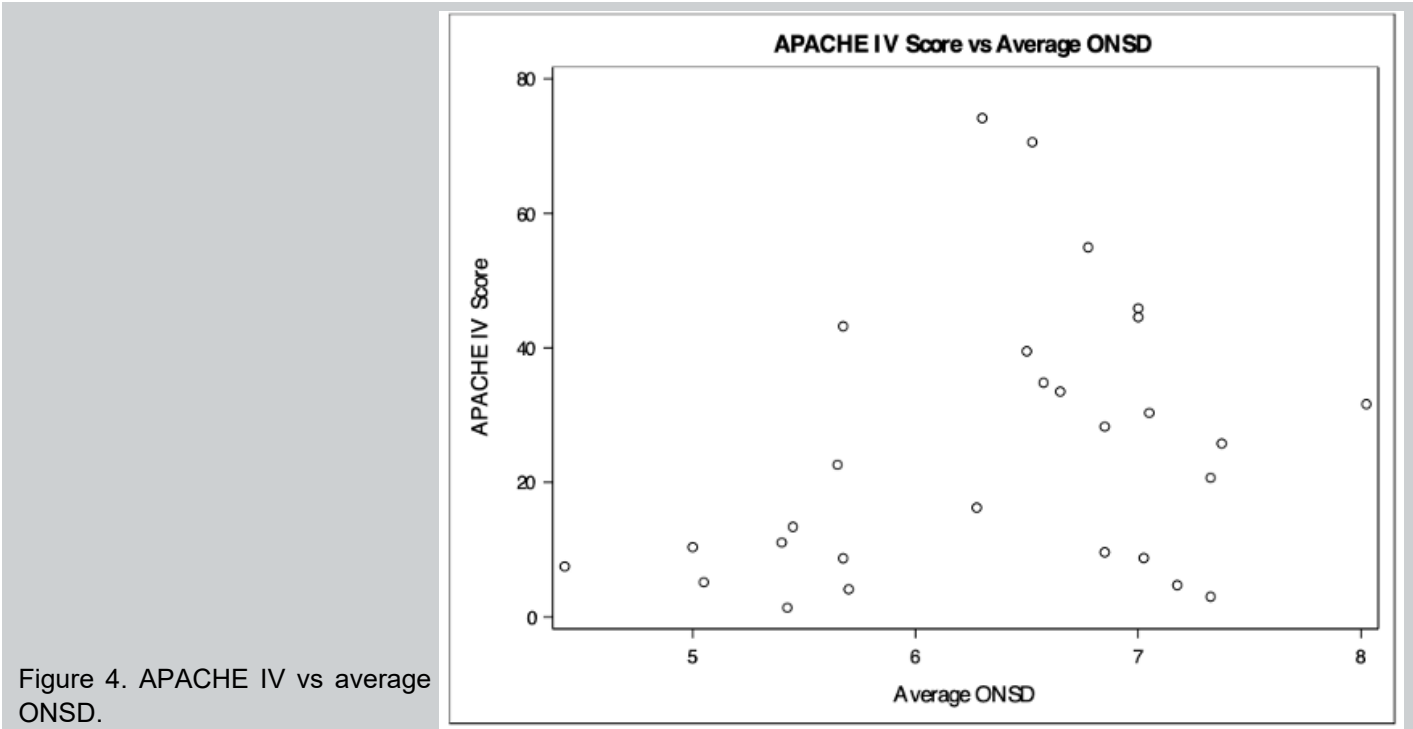


Figure 4. APACHE IV vs average ONSD.

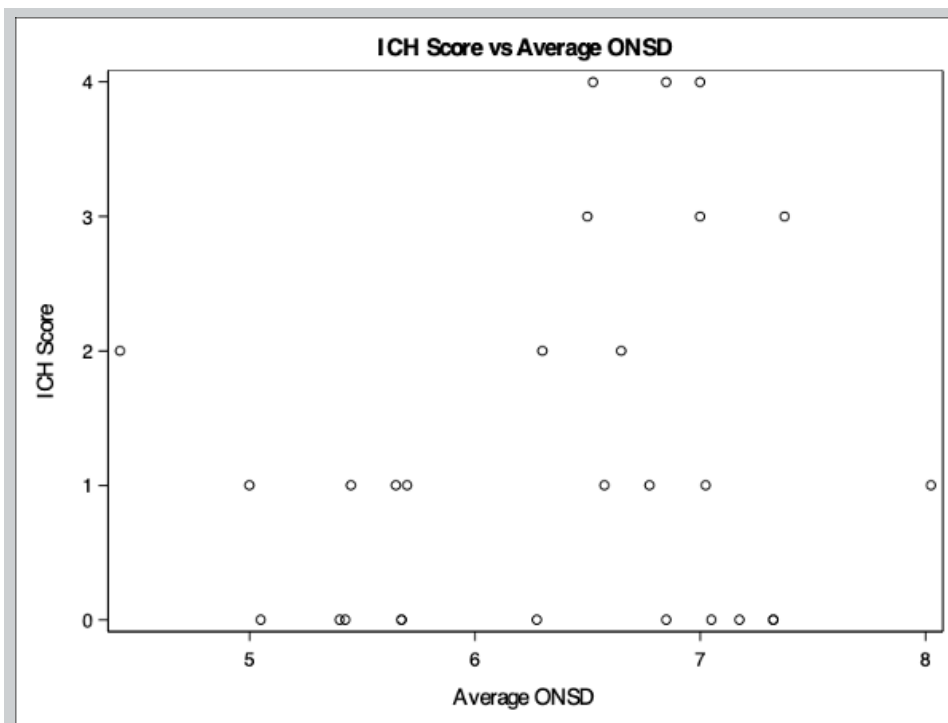


Figure 5. ICH score vs average ONSD.

objective adjunct to the physical examination. A common scenario where we foresee this being useful is during the first twenty-four hours of admission for ICH when hematoma expansion risk is greatest. Performing serial optic nerve exams with ultrasound may be useful to observe a trend in the ONSD. A significant increase in the ONSD compared to previous values can alert the physician that the ICH may be expanding, and that further imaging may be required to assess hematoma stability. Moreover, in patients who are critically ill and unstable for transport, bedside ONSD examination can potentially be used by clinicians to assess for hematoma expansion. Finally, invasive intracranial pressure monitoring devices may be contraindicated for various reasons including but not limited to coagulopathy. A bedside exam of the optic nerve in this situation may be helpful for monitoring. A weak positive correlation was also detected between average ONSD and ICH score as well as APACHE IV score. This weak correlation is likely because several components of the ICH score may not correlate with hematoma size, such as presence of intraventricular hemorrhage, age greater than 80, and infratentorial location of hemorrhage. The APACHE IV score uses variables derived from values from the first twenty-four hours of ICU admission. It is a hospital mortality predictor. There was a weak positive correlation that was not statistically significant. The variables included in the APACHE IV also contain chronic health conditions and lab chemistries, which may or may not be directly related to the ICH. The ICH score is based on age and CT findings and has been validated to estimate mortality. We found a weak moderate positive correlation

between ICH score and average ONSD which was not statistically significant. This is likely because the ONSD is a surrogate for intracranial pressure, whereas the ICH score is a mortality marker. Not all patients with a high intracranial pressure have a poor outcome and vice versa.

There are several limitations to this study. During enrolment of patients, the CT head was viewed prior to measuring the optic nerves. This potentially created a bias as the physician looking at the imaging and performing the ultrasound exam was the same individual. 27 of 28 ultrasound exams were performed by the same physician, and one exam was performed by another physician; therefore, inter-rater reliability was not assessed, which potentially limits the generalization of the conclusion.

### Conclusion

Measuring the optic nerve sheath diameter with POCUS is a quick noninvasive tool that can be used in the context of acute intracerebral hemorrhage to assess the volume of an ICH at a given point in time. We found a moderate positive correlation between the ONSD and volume of hematoma. This may be taken further, to monitor the stability or expansion of a hematoma indirectly, although this is a potential application of this technique and was not directly examined in this study. This POCUS exam is particularly useful in populations where performing neurological exams is challenging due to sedation or lack of patient cooperation. The ONSD is not meant to replace the physical exam but rather be an objective adjunct tool. A future study needs to be

performed where serial measurements of ONSD are performed and compared with ICH volume.

### Disclosures

The authors report no disclosures related to this work.

### References

1. Sahni, R. & Weinberger, J. Management of intracerebral hemorrhage. *Vasc Health Risk Manag* **3**, 701–709 (2007).
2. Fernando, S. M. et al. Intracerebral Hemorrhage Incidence, Mortality, and Association With Oral Anticoagulation Use. *Stroke* **52**, 1673–1681 (2021).
3. Lin, J.-J. et al. Point-of-care ultrasound of optic nerve sheath diameter to detect intracranial pressure in neurocritically ill children - A narrative review. *Biomed J* **43**, 231–239 (2020).
4. Gurav S, Zirpe K, Bhoyar A, Deshmukh A, Pote P, Kapse U, Tiwari A, Suryawanshi P, Malhotra R, Khan A, Dixit S. Utility of Bedside Ultrasound Measurement of Optic Nerve Sheath Diameter as a Screening Tool for raised Intracranial Pressure in Neurocritical Care Prospective Observational Study. *J Assoc Physicians India*. 2023 Jul;71(7):11-12. doi: 10.59556/japi.71.0287. PMID: 37449686.
5. Cannata G, Pezzato S, Esposito S, Moscatelli A. Optic Nerve Sheath Diameter Ultrasound: A Non-Invasive Approach to Evaluate Increased Intracranial Pressure in Critically Ill Pediatric Patients. *Diagnostics (Basel)*. 2022 Mar 21;12(3):767. doi: 10.3390/diagnostics12030767. PMID: 35328319; PMCID: PMC8946972.
6. Tayal, V.S., Neulander, M., Norton, H.J., Foster, T., Saunders, T., & Blaivas, M. (2007). Emergency department sonographic measurement of optic nerve sheath diameter to detect findings of increased intracranial pressure in adult head injury patients. *Annals of emergency medicine*, 49 4, 508-14 .

# Handheld Lung Ultrasound to Detect COVID-19 Pneumonia in Inpatients: A Prospective Cohort Study

Thomas F. Heyne, MD, MSt<sup>1,2\*</sup>; Kay Negishi, MD<sup>1</sup>; Daniel S. Choi, MD<sup>3</sup>; Ahad A. Al Saud, MBBS<sup>3,4</sup>; Lucas X. Marinacci, MD<sup>5</sup>; Patrick Y. Smithedajkul, MD<sup>1</sup>; Lily R. Devaraj, MD<sup>1,2</sup>; Brent P. Little, MD<sup>6</sup>; Dexter P. Mendoza, MD<sup>6</sup>; Efren J. Flores, MD<sup>6</sup>; Milena Petranovic, MD<sup>6</sup>; Steven P. Toal, MSc<sup>1</sup>; Hamid Shokoohi, MD, MPH<sup>3</sup>; Andrew S. Liteplo, MD<sup>3</sup>; Benjamin P. Geisler, MD, MPH<sup>1,7</sup>

(1) Department of Medicine, Massachusetts General Hospital, Boston, MA, USA

(2) Department of Pediatrics, Massachusetts General Hospital, Boston, MA, USA

(3) Department of Emergency Medicine, Massachusetts General Hospital, Boston, MA, USA

(4) Department of Emergency Medicine, King Saud University College of Medicine, Riyadh, Saudi Arabia

(5) Richard A. and Susan F. Smith Center for Outcomes Research, Beth Israel Deaconess Medical Center, Boston, MA, USA

(6) Department of Radiology, Massachusetts General Hospital, Boston, MA, USA

(7) Institute for Medical Information Processing, Biometry, and Epidemiology, Ludwig Maximilian University, Munich, Germany

## Abstract

**Background:** Chest imaging, including chest X-ray (CXR) and computed tomography (CT), can be a helpful adjunct to nucleic acid test (NAT) in the diagnosis and management of Coronavirus Disease 2019 (COVID-19). Lung point of care ultrasound (POCUS), particularly with handheld devices, is an imaging alternative that is rapid, highly portable, and more accessible in low-resource settings. A standardized POCUS scanning protocol has been proposed to assess the severity of COVID-19 pneumonia, but it has not been sufficiently validated to assess diagnostic accuracy for COVID-19 pneumonia. **Purpose:** To assess the diagnostic performance of a standardized lung POCUS protocol using a handheld POCUS device to detect patients with either a positive NAT or a COVID-19-typical pattern on CT scan. **Methods:** Adult inpatients with confirmed or suspected COVID-19 and a recent CT were recruited from April to July 2020. Twelve lung zones were scanned with a handheld POCUS machine. Images were reviewed independently by blinded experts and scored according to the proposed protocol. Patients were divided into low, intermediate, and high suspicion based on their POCUS score. **Results:** Of 79 subjects, 26.6% had a positive NAT and 31.6% had a typical CT pattern. The receiver operator curve for POCUS had an area under the curve (AUC) of 0.787 for positive NAT and 0.820 for a typical CT. Using a two-point cutoff system, POCUS had a sensitivity of 0.90 and 1.00 compared to NAT and typical CT pattern, respectively, at the lower cutoff; it had a specificity of 0.90 and 0.89 compared to NAT and typical CT pattern at the higher cutoff, respectively. **Conclusions:** The proposed lung POCUS protocol with a handheld device showed reasonable diagnostic performance to detect inpatients with a positive NAT or typical CT pattern for COVID-19. Particularly in low-resource settings, POCUS with handheld devices may serve as a helpful adjunct for persons under investigation for COVID-19 pneumonia.

## Background

Even as newer viral variants have proven less deadly than the initial waves, Coronavirus Disease 2019 (COVID-19) continues to affect our world. Although critical to mitigate the spread of disease, rapid and accurate diagnosis of COVID-19 can be challenging. The current gold standard test to detect Severe Acute Respiratory Syndrome Coronavirus-2 (SARS-CoV-2) infection is a nucleic acid amplification test (NAT) via reverse-transcription polymerase chain reaction. NAT has

excellent specificity but variable sensitivity (70-97%) [1]. Indeed, a not insignificant number of patients (perhaps 2-3.5%) may be infected even with an initial negative NAT [2-4]. Additionally, NAT may be expensive and require hours to result. Rapid antigen testing provides results in minutes but has lower sensitivity [5]. Computed tomography (CT) of the chest, which can detect typical patterns of lung findings for COVID-19, has good sensitivity (86-97%) but lower specificity (25-81%) [6-9]. In some locations, CT scan is used as a diagnostic

\*Corresponding Author: Thomas F. Heyne (email: theyne@mgb.org)

This work is licensed under a [Creative Commons Attribution 4.0 International License](https://creativecommons.org/licenses/by/4.0/).

Author(s) retain the copyright for their work. At the time of submission to POCUS Journal the author(s) grant the journal a limited and non-revokable right to publish in the Journal under a [Creative Commons Attribution 4.0 International License](https://creativecommons.org/licenses/by/4.0/).

DOI: <https://doi.org/10.24908/pocus.v8i2.16484>

adjunct, e.g., for patients with a pending NAT test or an initial negative NAT but high clinical concern for COVID-19 [10, 11]. Both the World Health Organization and the Fleischner Society have recommended chest imaging for patients with moderate or severe symptoms of suspected COVID-19, even if NAT is negative [12, 13]. Several validated reporting systems are used by radiologists in assessing likelihood of COVID-19 pneumonia on chest CT. A commonly used consensus guideline from the Radiological Society of North America (RSNA) classifies CT morphologies as “typical” (highest suspicion), “indeterminate”, “atypical”, or “negative” for COVID-19 pneumonia [14]. For example, typical CT findings include peripheral bilateral ground-glass opacities [15]. Despite its utility, CT scan has drawbacks; it requires significant healthcare resources and time, exposes the patient to ionizing radiation, poses infection control risks, and may be unsafe for unstable, hypoxemic patients. Chest X-ray (CXR) reduces some of these drawbacks but has a low sensitivity for detecting COVID-19, particularly early in the disease course (55-83%) [16]. Thus, some hospitals rely on more than one category of diagnostic test, as well as patient history and risk factors, to attempt to rule out COVID-19 infection and decide on isolation precautions. In our quaternary hospital system, both CXR and CT are used in an evidence-based algorithm for admitted persons under investigation (PUIs); for example, CT is often required to allow a clinician to “rule out” COVID-19 (and remove a patient from isolation) if initial CXR findings are concerning [11]. Thus, in daily clinical practice, CXR and CT are sometimes used as helpful adjuncts to help rule out and rule in COVID-19 [8, 17].

Point of care ultrasound (POCUS) has been increasingly studied as a viable alternative diagnostic modality. POCUS is inexpensive, rapid, ionizing radiation-free, widely available, and does not require travel to and possible infectious exposure of a radiology suite. Ultraportable, handheld machines are typically less expensive and easier to disinfect than traditional, larger ultrasound machines. In low-resource settings, POCUS may be available when CXR or CT are not. Importantly, COVID-19 tends to affect the lung periphery, which is visualized well by POCUS. Numerous studies have described characteristic features for COVID-19 on lung ultrasound, including bilateral B-lines (particularly “confluent” B-lines) and an irregular (or “serrated”) pleural line. [15 18-20]. B-lines, similar in appearance to movie premier searchlights, appear as hyperechoic laser-like reverberation artifacts that arise from the pleural line, obliterate A-lines, and extend to the bottom of the screen (Figure 1). They can coalesce into “confluent” B-lines, which appear as a broader beam of light (appearing less as a laser and more as a broad flashlight in the fog); this artifact has also been called “light beam artifact,”

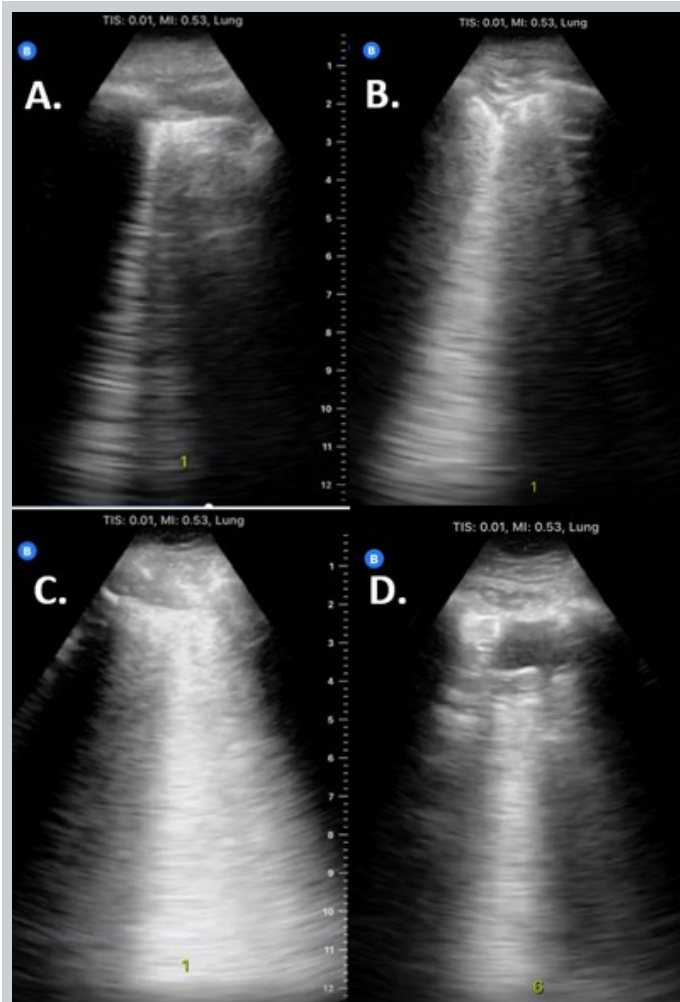


Figure 1. Examples of Lung Pathology. A) 1-2 B-lines. B) Broken pleural line/small subpleural consolidation. C) Confluent B-lines (light-beam artifact). D) Large subpleural consolidation. In the proposed protocol, these findings merit 1 point (A), 2 points (B), and 3 points (C or D).

“waterfall” B-line, or “white lung.” Compared to a normal pleural line, which is distinct and unbroken (something that could be drawn in one stroke by an imaginary white pencil), an irregular or “serrated” pleural line appears jagged and/or broken. Of note, while these ultrasound findings raise suspicion for COVID-19 pneumonia, they are not specific and can be seen in other pulmonary disease processes such as acute respiratory distress syndrome, cardiogenic pulmonary edema, interstitial lung disease, or pneumonia from other microbial etiologies. Of course, some CXR or CT findings suggestive of COVID-19 are similarly non-specific.

Therefore, different stratifying scoring systems to assess COVID-19 disease severity have been proposed. A widely-cited article from Soldati *et al.* proposed scanning 14 lung zones and assigning a score between zero to

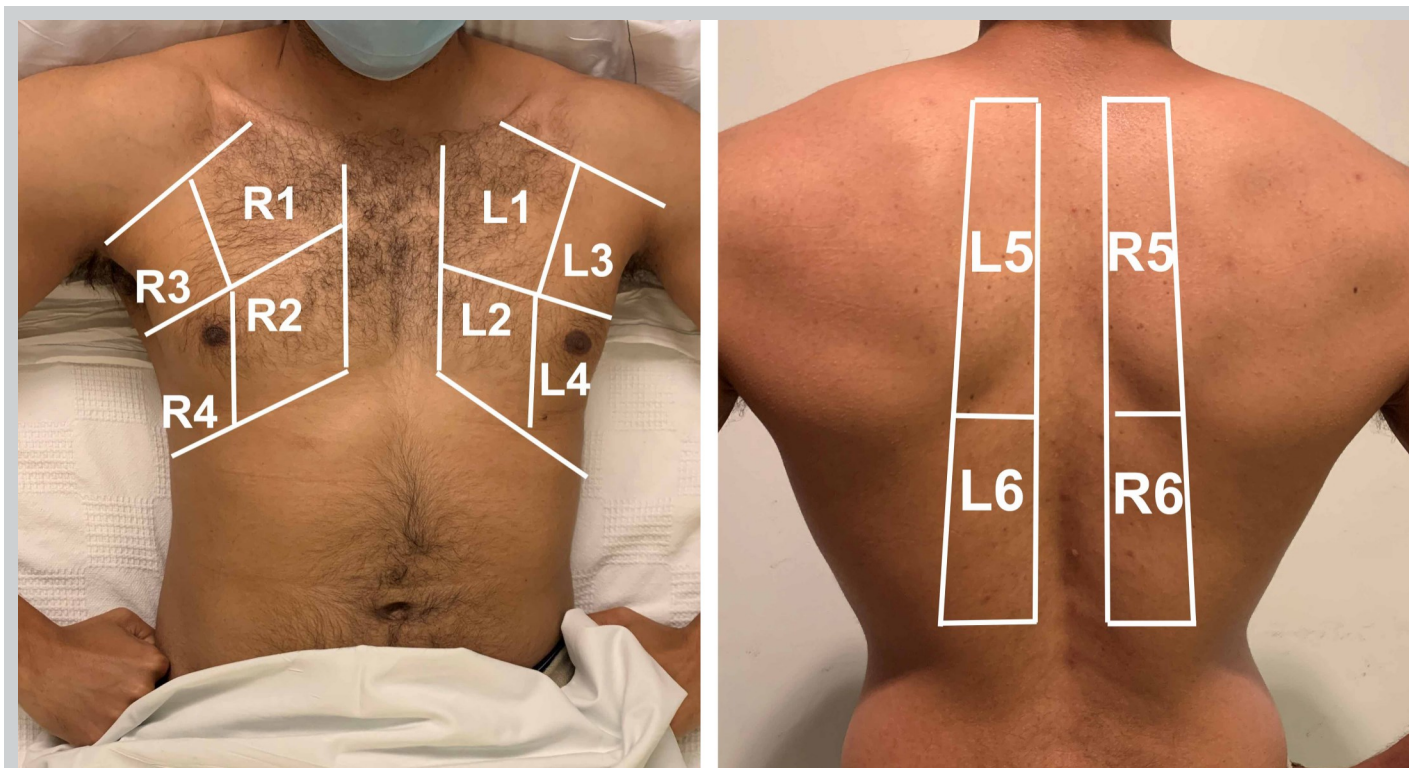


Figure 2. Lung Ultrasound Zones. Anterior lung zones (R1, R2, L1, L2) were scanned along the mid-clavicular line; lateral zones (R3, R3, L3, L4) were scanned along the mid-axillary line; the fourth rib separated the upper and lower anterior-lateral zones. Posterior lung zones (R5, R6, L5, L6) were scanned between the spine and the scapula; upper and lower posterior zones were separated by the inferior border of the scapula. Pictured is one of our physicians.

three points per zone; the total number of points would correlate with the severity of COVID-19 pneumonia [21]. The same group analyzed protocols with fewer lung zones (e.g., four to twelve zones), given that an abbreviated protocol could help reduce exposure time of the scanner with infectious patients; the study concluded that a 12-zone protocol (including 4 posterior zones) was optimal to assess COVID-19 severity [22]. The same group has validated their protocol for prognosis of COVID-19 pneumonia [23], but to our knowledge none has attempted to validate it for diagnosis of COVID-19 pneumonia (particularly for with a 12-zone protocol following Soldati's score). Notably, there are several valuable studies suggesting the utility of POCUS for possible diagnosis of COVID-19 [24-29]. However, these studies have limitations which hinder their generalizability, such as using a single operator, relying on the scanner's overall subjective gestalt for COVID-19 pneumonia, not comparing to CT scan, or excluding patients with heart failure (which may have similar POCUS findings as COVID-19 pneumonia). In addition, few studies have gathered all data using handheld, ultra-portable devices.

Our aim was to validate a 12-zone protocol following Soldati *et al.* with a handheld device, assessing the

diagnostic accuracy of lung POCUS performed with a handheld ultrasound machine to detect either (1) a high-suspicion ("typical") pattern for COVID-19 on CT scan or (2) a positive COVID-19 NAT. We hypothesized that handheld lung POCUS has superior sensitivity and specificity compared to CXR for both outcomes.

## Methods

### Study design and setting

This prospective cohort study took place in a 1,000-bed quaternary care hospital in the Northeastern U.S., from April to July 2020 (the first wave of the pandemic). We included a convenience sample of adult patients who were admitted to either the medical ward or intensive care unit (ICU). We calculated that we would need to recruit 70 patients, estimating a prevalence of 50% of cases with typical CT pattern (see Supplementary Material). A query of the electronic medical record system, roughly twice a week based on scanner availability, identified patients who had either confirmed or suspected COVID-19 infection (i.e., "PUI" status and awaiting further testing) and who had completed or were planned to complete a chest CT within 24 hours of the POCUS scan. Patients with a history of interstitial lung disease (ILD) were excluded, given these patients are

Table 1. Patient characteristics at the time of POCUS scan

	All n=79	COVID-19 NAT positive n=21 (26.6%)	COVID-19 NAT negative n=58 (73.4%)	p-value
Age (years); mean (95% CI)	62.5 (58.6-66.4)	58.6 (50.0-67.2)	63.9 (59.7-68.2)	0.231
Gender female; %	32.9%	28.6%	34.5%	0.788
Scanned in ICU; %	5.1%	14.3%	1.7%	0.055
Body mass index (kg/m <sup>2</sup> ); median (95% CI)	26 (25-27.7)	29 (25.5-31)	25.5 (24-26.9)	0.125
History of CHF; %	21.5%	14.3%	24.1%	0.537
Supplemental O <sub>2</sub> (L/min) <sup>1</sup> ; mean (95% CI)	2.7 (2.2-3.3)	2.6 (1.2-3.9)	2.8 (2.3-3.4)	0.670
Absolute lymphocyte count (per $\mu$ L); median (95% CI)	1,125 (972-1,360)	1,280 (814-1,545)	1,110 (943-1,447)	0.710
Ferritin (ng/mL); median (95% CI)	353 (230-510)	691 (426-870)	220 (142-353)	0.001
CRP (mg/L); median (95% CI)	62.1 (38.5-84.8)	71.8 (48.7-132.8)	52.8 (11.6-85.9)	0.145
LDH (U/L); median (95% CI)	258 (226-326)	327 (266-394)	224 (180-258)	0.003
D-dimer (ng/mL); median (95% CI)	1,341 (1,066-1,577)	1,431 (891-2,435)	1,314 (1,010-1,573)	0.738
NT-proBNP (pg/mL); median (95% CI)	548 (307-2,044)	307 (34-1,843)	600 (322-2,844)	0.139
In-hospital death; %	7.6%	14.3%	5.2%	0.333
Discharged to hospice; %	1.3%	0.0%	1.7%	1.000

<sup>1</sup> Includes only 28 patients on nasal cannula. Abbreviations: NAT, nucleic acid test; CI; confidence interval; CHF, congestive heart failure; ICU, intensive care unit; CRP, C-reactive protein; LDH, Lactate dehydrogenase; NT pro-BNP, N-terminal pro B-type natriuretic peptide.

relatively rare, typically know their underlying diagnosis, and at baseline will have quite abnormal lung POCUS scans. Otherwise, we attempted to recruit all consecutive patients. The protocol was approved by the local Partners Healthcare Institutional Review Board.

### **Selection of participants, interventions, and measurements**

After obtaining assent from the treating team and verbal consent from the patient or proxy, a research physician scanned 12 lung zones (Figure 2), similar to prior protocols [24]. The patient wore a surgical mask, and the scanning physician wore hospital-recommended personal protective equipment (N-95 respirator, eye protection, gown, and gloves; Appendix Figure S1). The probe was held longitudinally and perpendicular to the

ribs to obtain the “bat sign” view [25]. Scanning physicians attempted to capture at least two intercostal spaces for each zone (and at least three intercostal spaces for each of the four posterior zones). For posterior lung zones, patients either sat upright or lay in lateral decubitus position. Scanning was completed using a handheld Butterfly iQ ultrasound machine (Butterfly Network, Inc., Guilford, CT) connected to an iPhone (Apple Inc., Cupertino, CA). The lung preset was used for all zones; a second clip was obtained using the abdominal preset for zones R4 and L4 (to investigate for pleural effusion). Single-use gel packets were used for ultrasound gel, to avoid cross-contamination. After scanning, machines were sanitized with hospital-approved disinfectant wipes. Scanning physicians included four internal medicine and two emergency



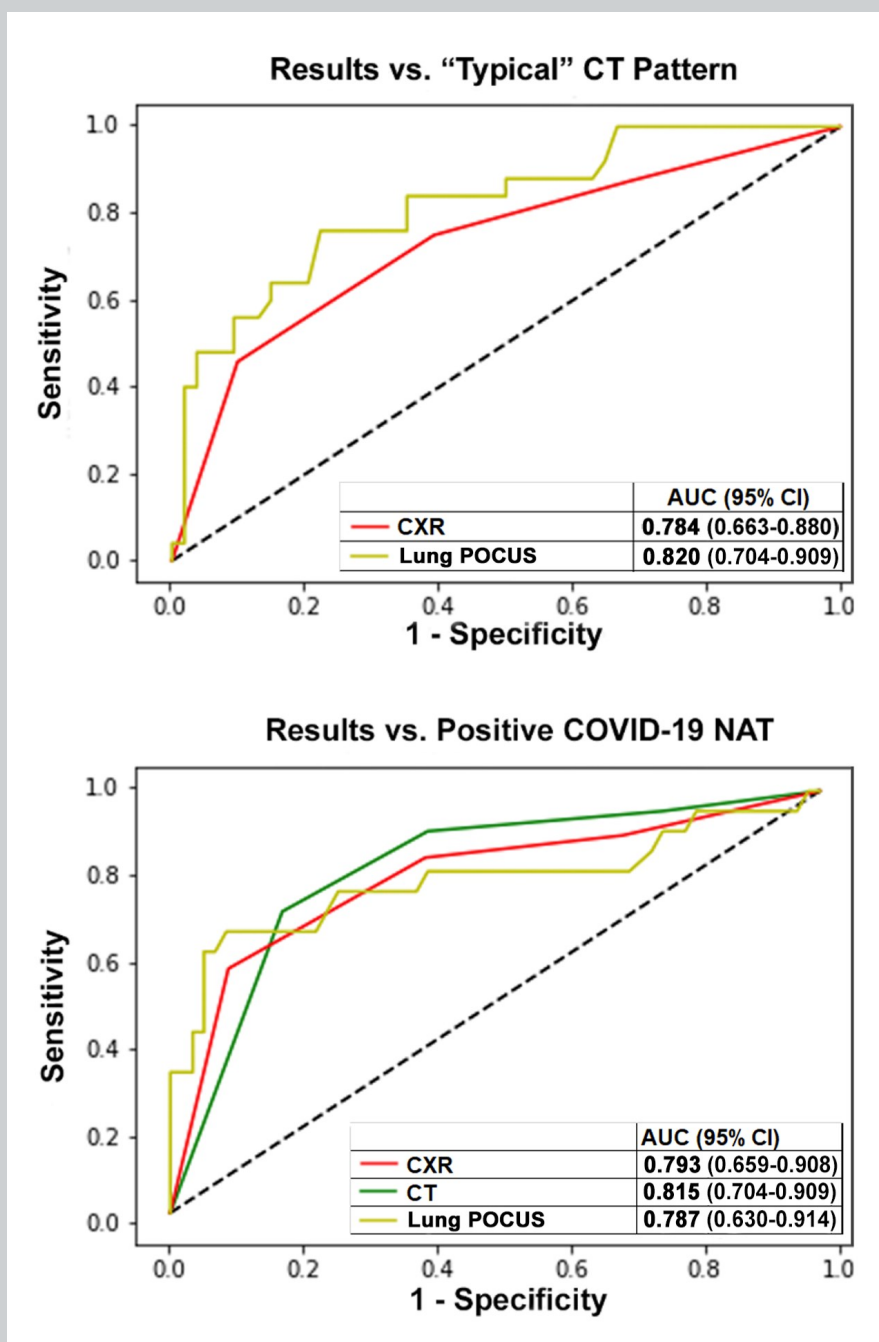


Figure 3. Receiver operating characteristic curves. Abbreviations: AUC, area under the curve; CI, confidence interval; CT, computed tomography; CXR, chest X-ray; NAT, nucleic acid test

medicine physicians, all of whom had completed formal POCUS training, including a minimum of 25 lung scans reviewed by a POCUS expert. All scanners were blinded to CT results, though not to NAT results (positive results are prominently displayed in the chart), at the time of scanning. Patient demographics, vital signs, amount of supplemental oxygen, and lab values were recorded by non-scanning research staff.

POCUS clips were reviewed by two Emergency Ultrasound Fellowship-trained physicians, who were blinded to CT and NAT results. Scans were scored along numerous criteria, including categories of B-lines, pleural line irregularity, and consolidation, selecting the most

severe pathology in each of these 3 categories for each lung zone (see Appendix Figure S2). Examples are pictured (Figure 1). Similarly, CTs and CXRs were reviewed by two board-certified radiologists specialized in thoracic imaging and blinded to clinical and POCUS information. Radiologists were blinded to CT images when reading CXRs, and vice versa. Radiologists gave each CT and CXR a COVID-19 suspicion grade, following consensus criteria (namely, RSNA criteria for CT scans and British Society of Thoracic Imaging (BSTI) criteria for CXRs): namely, (1) typical/high suspicion, (2) indeterminate, (3) atypical/low suspicion, or (4) negative [14, 26]. A third radiologist provided an interpretation in the case of discordant interpretations (as a tiebreaker).

Table 2. Test characteristics of POCUS protocol

	Sensitivity	Specificity	PPV	NPV
<b>All Patients (n=79)</b>				
For "Typical" CT Pattern:				
Score $\geq 24$	0.56	0.89	0.70	0.81
Score $\geq 6$	1.00	0.30	0.40	1.00
For Positive NAT:				
Score $\geq 24$	0.67	0.90	0.70	0.88
Score $\geq 6$	0.90	0.24	0.30	0.88
Abbreviations: CT, computed tomography; NAT, nucleic acid test; NPV, negative predictive value; PPV, positive predictive value.				

For both CT and CXR, the mode of the three interpretations was considered the consensus. For cases in which the third reader assigned a grade different from the primary two readers, the grade corresponding to the value closest to the median of the three observer grades was used as the consensus.

### Analysis

For all imaging modalities, we calculated a Cohen's kappa to compare the interrater reliability between the first two readers (not including the "tiebreaker"). An ordinal scale was used for CT, CXR, and POCUS interpretations. For POCUS scans, we recorded the duration of time spent scanning (from the start of the first clip to the final clip).

We assessed the accuracy of the 12-zone POCUS protocol to detect either (1) typical CT pattern or (2) positive NAT (by the time of discharge). The Soldati protocol assigned a score between zero to three for each of the lung zones (thus, for our 12 zones, the maximum score for a patient was 36) [21].

To calculate individual test characteristics (sensitivity, specificity, positive and negative predictive value) for our simplified POCUS score, we created two score cutoffs. These cutoffs allowed us to create low, intermediate, and high COVID-suspicion categories from the ordinal POCUS score (i.e., 0-36 points); these categories would mirror the RSNA CT and BSTI CXR categories. Data analysis was performed in Python 3.8.3 (Python Software Foundation, Beaverton, OR) [27].

Receiver operating characteristic (ROC) curves were created to compare the performance of POCUS and CXR for our first outcome: a typical pattern for COVID-19 on CT. Additional ROC curves compared Soldati score,

CXR, and CT against our second outcome: positive NAT. Areas under the curve (AUCs) were generated with the algorithm suggested by DeLong, DeLong, and Clark-Pearson [28]. AUCs were compared with the test of equality of receiver operating areas in STATA IC 14.2 (Stata Corp LLC, College Station, TX).

### Results

Ninety patients were initially screened, and 79 were scanned and included in the final analysis. The remaining eleven were excluded based on lack of consent, presence of exclusion criteria (namely ILD), or CT scan not completed (Appendix Figure S3). Patient characteristics at the time of scan are given in Table 1. Most subjects were male (67.1%), of advanced age (mean age 62.5 years), overweight (mean BMI 27.0 kg/m<sup>2</sup>), and with elevated inflammatory markers.

Overall, 26.6% (21/79) of patients were NAT positive. All tested positive on their initial NAT. No patient who had an initial negative NAT tested subsequently tested positive during the study period. For CT scan, patients received the following RSNA grades (consensus interpretation): 18.9% (15/79) negative, 27.8% atypical/low (22/79), 21.5% indeterminate (17/79), and 31.6% typical (25/79). Fifteen patients (18.9%) had both positive NAT and a typical CT pattern. Seventy-five patients (94.9%) had CXRs completed; of these, the radiology consensus was 25.3% (19/75) negative, 24.0% (18/75) atypical/low, 29.3% indeterminate (22/75), and 21.3% (16/75) typical for COVID-19. For POCUS scan, 20.2% (16/79) of patients were categorized as low-risk, 53.2% (42/79) were intermediate, and 26.6% (21/79) were high-risk (based on scoring system, below). Interrater reliability between the two readers for each of the imaging modalities was as follows:  $\kappa = 0.822$  for CT scan,  $\kappa = 0.559$  for CXR,  $\kappa = 0.704$  for POCUS. The median time between POCUS exam and CT scan completion was 13 hours (95% confidence interval [CI]: 11.1, 16.8). For ten patients, >24 hours elapsed between scans, typically from delays in obtaining CT scan after initial order. The POCUS exam took a median of 10 (95% CI: 9.4; 10.8) minutes. There was no statistically significant difference in the POCUS scan time between NAT-positive and negative patients ( $p=0.845$ ).

The ROC curves with corresponding AUCs for CXR, CT, and POCUS are given in Figure 3. The AUC for POCUS was numerically higher than the AUC for CXR for the outcome of typical pattern on CT scan, but this difference did not reach statistical significance ( $p = 0.1201$ ). To mirror the consensus categories used for CT and CXR, we created two cutoffs for the POCUS protocol, to divide patients into low, intermediate, and high suspicion for COVID. We set low suspicion at 6 or fewer points; intermediate at >6 and <24 points, and high suspicion at

Table 3: POCUS protocol adapted from Soldati, et al.

-Scan 12 zones with probe perpendicular to ribs, recording at least 2 intercostal spaces per zone (and 3 intercostal spaces per posterior zone)	
-Scoring: select the highest-scoring pathology for each zone. Points for the 12 zones are added to create a total score for each patient (maximum score = 36).	
<b>Score per zone:</b>	
<b>Finding</b>	<b>Points</b>
No B-lines or pleural line breaks	0
Any B-lines	1
Broken/irregular pleural line, or small (<1cm) subpleural consolidation	2
Light-beam artifact (confluent B-lines), or large subpleural consolidation, or hepatization	3
<b>Interpretation:</b>	
<b>Score</b>	<b>Interpretation</b>
< 6	Low suspicion for COVID-19
≥ 6 and < 24	Intermediate suspicion for COVID-19
≥ 24	High suspicion for COVID-19

24 or greater points. These cutoffs were chosen as practical method so that this protocol could be used to “rule-in” and “rule-out”; namely, to maximize sensitivity and NPV below the lower cutoff and maximize specificity and PPV above the higher cutoff--while also including a sizeable number of patients within each category. Operating characteristics are summarized in Table 2. The entire protocol is delineated in Table 3.

### Discussion

A 12-zone lung POCUS protocol adapted from Soldati *et al.* and using handheld devices had reasonable diagnostic performance to detect either a typical CT pattern or a positive NAT for COVID-19. For patients with a higher POCUS score (high risk of COVID-19), the specificity was approximately 90% for detecting either typical CT pattern or positive NAT. For patients above the lower cut-off point, the sensitivities and negative predictive values for typical CT pattern and for positive NAT were all quite high (88-100%). There was no statistically significant difference in the diagnostic accuracy among POCUS, CT, and CXR. Thus, arguably patients with a high POCUS score could be considered

high risk for having COVID-19, and further imaging with a CT might be avoided. Similarly, one might extrapolate that patients below the low cut-off could be considered to have a low risk for COVID-19 pneumonia (and might be able to forgo a CT scan that might be ordered to check for typical signs of COVID-19 pneumonia).

The study results add to the literature that POCUS can assist in the diagnosis or risk stratification of PUIs for COVID-19 [29-33]. Namely, handheld lung POCUS may be a helpful adjunct to history and risk factors both to “rule in” or “rule out” COVID-19 pneumonia. Certainly, some of the more typical POCUS findings of COVID-19 can also be seen in other pulmonary conditions; but the same is true of typical CXR findings. The interrater reliability for readers for the POCUS score was overall good, notably higher than CXR ( $\kappa = 0.704$  vs.  $\kappa = 0.559$ ). Handheld POCUS, as used in this study, is relatively inexpensive and easy to disinfect, and may be particularly helpful in resource-limited settings, where access to CT or NAT may be limited or results may be delayed. In addition, the vast majority of scans were completed by internists with extra training in POCUS: notably, internists represent the largest medical specialty group in the United States [34]. Finally, lung POCUS is rapid. Our 12-zone POCUS mean scanning time was ten minutes. However, this is not an insignificant amount of exposure time with an infectious patient, and it is a limitation of using POCUS. We plan to perform a subgroup analysis to assess whether a protocol with fewer lung zones would still perform well.

Our study is subject to several limitations. First, this was a single-center study, using a convenience sample of inpatients based on scanning physician availability. However, there have been relatively few prospective studies to date, particularly multi-center studies. Further validation studies performed at other centers are warranted and welcome. Second, this study was completed in 2020 in an earlier wave of the COVID-19 pandemic; newer variants seem to be causing severe disease and viral pneumonia less frequently [35]. However, imaging is still useful and *de facto* being used. The presence of typical findings for COVID-19 pneumonia (whether on CT scan, or a high lung POCUS score) should still heighten concern for infection or complications, and some quaternary centers (including ours) continue to use chest imaging (CXR and CT) as part of the workflow to rule in and out COVID-19 infection [11]. Whether the test characteristics described herein apply to current variants, vaccinated patients, and generally lower prevalence and disease severity is questionable and should be explored in newer cohorts. Third, our study examined only inpatients (mostly from the ward, with a small number of ICU patients); it is

unknown whether this scanning protocol would yield similar results for outpatients or ED patients. Fourth, our sample size had a relatively narrow BMI range. Fifth, the relatively high positivity rate (26.6%) could lead to a spectrum effect. However, this incidence is lower than some other studies, and our sample did include many patients with low-suspicion CXR and CT results. Sixth, although scanning physicians were blinded to CT results, they were not blinded to NAT status (positive COVID status is displayed prominently in our hospital electronic record); it is possible that sampling bias of the lung zones was introduced. However, COVID-positive and PUI patients had similar POCUS scan times. Seventh, there is certainly a degree of subjectivity in interpreting different POCUS findings as described in the protocol from Soldati *et al.* (or any lung protocol). Our interrater reliability for POCUS readers was excellent, but the subjectivity could make the protocol less generalizable worldwide. Finally, none of the patients with an initial negative NAT subsequently had a positive NAT. However, this was an inpatient study, and initial NAT is always performed in the Emergency Department in our institution. Incidence of positive NAT after initial negative NAT is very low [2]. Thus, it would be extremely challenging to capture an appreciable number of NAT-positive patients if we had limited our study to only those patients with an initial negative NAT.

## Conclusions

Handheld lung POCUS could be a valuable tool in assessing the likelihood of COVID-19 pneumonia. A 12-zone protocol following Soldati *et al.* and using handheld devices performed well to detect patients with either a high-suspicion CT pattern for COVID-19 or a positive NAT. In patients under investigation for COVID-19, particularly in low-resource settings, a lung POCUS exam with an inexpensive, handheld machine could potentially replace other chest imaging as a helpful adjunct for clinicians to decide whether a diagnosis of COVID-19 pneumonia should be further entertained or no.

## Ethics approval and consent to participate

The protocol was approved by our local Partners Healthcare (MassGeneral Brigham) Institutional Review Board. Verbal consent was obtained for every patient (via patient or patient proxy) to be scanned and participate in the study.

## Availability of data and material

The datasets used and analyzed during the current study are available from the corresponding author on reasonable request.

## Competing interests

The authors declare that they have no competing interests.

## Funding

The authors did not receive any funding for this research.

## Acknowledgements

We greatly appreciate assistance from Dr. Irene Ma and Dr. Emily Hyle for advice in planning this project and revising the manuscript. We are also grateful to Dr. Nicole Duggan and Dr. Daniel Restrepo for assistance in early stages of this project.

## References

- Kortela E, Kirjavainen V, Ahava MJ, Jokiranta ST, But A, Lindahl A, et al. Real-life clinical sensitivity of SARS-CoV-2 RT-PCR test in symptomatic patients. *PLoS One*. 2021;16(5):e0251661.
- Dugdale CM, Anahtar MN, Chiosi JJ, Lazarus JE, McCluskey SM, Ciaranello AL, et al. Clinical, laboratory, and radiologic characteristics of patients with initial false-negative SARS-CoV-2 nucleic acid amplification test results. *Open Forum Infect Dis*. 2021, 8(1):ofaa559.
- Patrucco F, Carriero A, Falaschi Z, Pasché A, Gavelli F, Airoldi C, et al. COVID-19 diagnosis in case of two negative nasopharyngeal swabs: association between chest CT and bronchoalveolar lavage results. *Radiology*. 2021, 298(3):E152-155.
- Long DR, Gombar S, Hogan CA, Greninger AL, Shah VOR, Bryson-Cahn C, et al. Occurrence and timing of subsequent SARS-CoV-2 RT-PCR positivity among initially negative patients. *Clinical Infectious Diseases*. 2020, 27(2):323-326.
- Dinnes J, Deeks JJ, Berhane S, Taylor M, Adriano A, Davenport C, et al. Rapid, point-of-care antigen and molecular-based tests for diagnosis of SARS-CoV-2 infection. *Cochrane Database Syst Rev*. 2021;3(3):Cd013705.
- Fang Y, Zhang H, Xie J, Lin M, Ying L, Pang P, et al. Sensitivity of Chest CT for COVID-19: Comparison to RT-PCR. *Radiology*. 2020, 296(2):E115-E117.
- Ai T, Yang Z, Hou H, Zhan C, Chen C, Lv W, et al. Correlation of Chest CT and RT-PCR Testing in Coronavirus Disease 2019 (COVID-19) in China: A Report of 1014 Cases. *Radiology*. 2020, 296(2):E32-E40.
- Schalekamp S, Bleeker-Rovers CP, Beenen LFM, Quarles van Ufford HME, Gietema HA, Stöger JL, et al. Chest CT in the Emergency Department for Diagnosis of COVID-19 Pneumonia: Dutch Experience. *Radiology*. 2020, 298(2):E98-E106.
- Som A, Lang M, Yeung T, Carey D, Garrana S, Mendoza DP, et al. Implementation of the Radiological Society of North America Expert Consensus Guidelines on Reporting Chest CT Findings Related to COVID-19: A Multireader Performance Study. *Radiology: Cardiothoracic Imaging*. 2020;2(5):e200276.
- Schalekamp S, Bleeker-Rovers CP, Beenen LFM, Ufford HMEQv, Gietema HA, Stöger JL, et al. Chest CT in the Emergency Department for Diagnosis of COVID-19 Pneumonia: Dutch Experience. *Radiology*. 2021;298(2):E98-E106.
- Dugdale CM, Rubins DM, Lee H, McCluskey SM, Ryan ET, Kotton CN, et al. Coronavirus Disease 2019 (COVID-19) Diagnostic Clinical Decision Support: A Pre-Post Implementation Study of CORAL (Covid Risk cALculator). *Clinical Infectious Diseases*. 2021, 73(12):2248-2256.
- Rubin GD, Ryerson CJ, Haramati LB, Sverzellati N, Kanne JP, Raouf S, et al. The Role of Chest Imaging in Patient Management during the COVID-19 Pandemic: A Multinational Consensus Statement from the Fleischner Society. *Radiology*. 2020;296(1):172-80.
- Akl EA, Blažić I, Yaacoub S, Frijia G, Chou R, Appiah JA, et al. Use of Chest Imaging in the Diagnosis and Management of COVID-19: A WHO Rapid Advice Guide. *Radiology*. 2021;298(2):E63-E9.
- Simpson S, Kay FU, Abbara S, Bhalla S, Chung JH, Chung M, et al.

- Radiological society of north America expert consensus document on reporting chest CT findings related to COVID-19: endorsed by the society of thoracic Radiology, the American college of Radiology, and RSNA. *Radiology: Cardiothoracic Imaging*. 2020;2(2):e200152.
15. Volpicelli G, Gargani L. Sonographic signs and patterns of COVID-19 pneumonia. *The Ultrasound Journal*. 2020;12(1):1-3.
16. Stephanie S, Shum T, Cleveland H, Challa SR, Herring A, Jacobson FL, et al. Determinants of chest x-ray sensitivity for covid-19: A multi-institutional study in the united states. *Radiology: Cardiothoracic Imaging*. 2020;2(5):e200337.
17. Little BP. False-Negative Nasopharyngeal Swabs and Positive Bronchoalveolar Lavage: Implications for Chest CT in Diagnosis of COVID-19 Pneumonia. *Radiological Society of North America*; 2021, 298(3): E160–E161.
18. Huang Y, Wang S, Liu Y, Zhang Y, Zheng C, Zheng Y, et al. A preliminary study on the ultrasonic manifestations of peripulmonary lesions of non-critical novel coronavirus pneumonia (COVID-19). Available at SSRN 3544750. 2020.
19. Smith MJ, Hayward SA, Innes SM, Miller ASC. Point-of-care lung ultrasound in patients with COVID-19—a narrative review. *Anaesthesia*. 2020, 75(8):1096-1104.
20. Peng Q-Y, Wang X-T, Zhang L-N, Chinese Critical Care Ultrasound Study G. Findings of lung ultrasonography of novel corona virus pneumonia during the 2019–2020 epidemic. *Intensive care medicine*. 2020, 46(5):849-850.
21. Soldati G, Smargiassi A, Inchingolo R, Buonsenso D, Perrone T, Briganti DF, et al. Proposal for International Standardization of the Use of Lung Ultrasound for Patients With COVID-19: A Simple, Quantitative, Reproducible Method. *Journal of Ultrasound in Medicine*. 2020, 39(7):1413-1419.
22. Mento F, Perrone T, Macioce VN, Tursi F, Buonsenso D, Torri E, et al. On the Impact of Different Lung Ultrasound Imaging Protocols in the Evaluation of Patients Affected by Coronavirus Disease 2019: How Many Acquisitions Are Needed? *J Ultrasound Med*; 2021, 40(10):2235-2238.
23. Soldati G, Smargiassi A, Perrone T, Torri E, Mento F, Demi L, et al. There is a Validated Acquisition Protocol for Lung Ultrasonography in COVID-19 Pneumonia. *J Ultrasound Med*. 2021;40(12):2783-.
24. Haak SL, Renken IJE, Jager LC, Lameijer H, van der Kolk BYM. Diagnostic accuracy of point-of-care lung ultrasound in COVID-19. *Emergency Medicine Journal*. 2021;38(2):94.
25. Lichtenstein DA. Lung ultrasound in the critically ill. *Annals of Intensive Care*. 2014;4(1):1.
26. Hare SS, Tavare AN, Dattani V, Musaddaq B, Beal I, Cleverley J, et al. Validation of the British Society of Thoracic Imaging guidelines for COVID-19 chest radiograph reporting. *Clin Radiol*. 2020;75(9):710.e9-.e14.
27. McKinney W, editor *Data structures for statistical computing in python*, 2010: Austin, TX.
28. DeLong ER, DeLong DM, Clarke-Pearson DL. Comparing the areas under two or more correlated receiver operating characteristic curves: a nonparametric approach. *Biometrics*. 1988;44(3):837-45.
29. Pivetta E, Goffi A, Tizzani M, Locatelli SM, Porrino G, Losano I, et al. Lung Ultrasonography for the Diagnosis of SARS-CoV-2 Pneumonia in the Emergency Department. *Ann emerg med*. 201, 77(4): 385–394.
30. Lieveld AWE, Kok B, Schuit FH, Azijli K, Heijmans J, van Laarhoven A, et al. Diagnosing COVID-19 pneumonia in a pandemic setting: Lung Ultrasound versus CT (LUVCT)—a multicentre, prospective, observational study. *ERJ Open Research*. 2020;6(4): 00539-2020.
31. Volpicelli G, Gargani L, Perlini S, Spinelli S, Barbieri G, Lanotte A, et al. Lung ultrasound for the early diagnosis of COVID-19 pneumonia: an international multicenter study. *Intensive care medicine*. 2021;47(4):444-54.
32. Peixoto AO, Costa RM, Uzun R, Fraga AMA, Ribeiro JD, Marson FAL. Applicability of lung ultrasound in COVID-19 diagnosis and evaluation of the disease progression: A systematic review. *Pulmonology*. 2021;27(6):529-62.
33. Haak SL, Renken IJE, Jager LC, Lameijer H, van der Kolk BBYM. Diagnostic accuracy of point-of-care lung ultrasound in COVID-19. *Emergency Medicine Journal*. 2021;38(2):94-9.
34. Association of American Medical Colleges. Active Physicians in the Largest Specialties, 2019 [Available from: <https://www.aamc.org/data-reports/workforce/interactive-data/active-physicians-largest-specialties-2019>].
35. Nyberg T, Ferguson NM, Nash SG, et al. Comparative analysis of the risks of hospitalisation and death associated with SARS-CoV-2 omicron (B.1.1.529) and delta (B.1.617.2) variants in England: a cohort study. *Lancet*. 2022;399(10332):1303-1312. doi:10.1016/S0140-6736(22)00462-7

# Association of Internal Medicine Point of Care Ultrasound (POCUS) with Length of Stay, Hospitalization Costs, and Formal Imaging: a Prospective Cohort Study

David M Tierney, MD, FACP<sup>1\*</sup>; Terry K Rosborough, MD, FACP<sup>1</sup>; Lynn M Sipse, MD<sup>1</sup>; Kai Hanson, MS<sup>2</sup>; Claire S Smith, MS<sup>2</sup>; Lori L Boland, MPH<sup>2</sup>; Robert Miner, MD, FACP<sup>1</sup>

(1) Abbott Northwestern Hospital, Department of Graduate Medical Education; Minneapolis, MN USA

(2) Allina Health Care Delivery Research; Minneapolis, MN USA

## Abstract

**Background:** Point of care ultrasound (POCUS) use has rapidly expanded among internal medicine (IM) physicians in practice and residency training programs. Many benefits have been established; however, studies demonstrating the impact of POCUS on system metrics are few and mostly limited to the emergency department or intensive care setting. The study objective was to evaluate the impact of inpatient POCUS on patient outcomes and hospitalization metrics.

**Methods:** Prospective cohort study of 12,399 consecutive adult admissions to 22 IM teaching attendings, at a quaternary care teaching hospital (7/1/2011-6/30/2015), with or without POCUS available during a given hospitalization. Multivariable regression and propensity score matching (PSM) analyses compared multiple hospital metric outcomes (costs, length of stay, radiology-based imaging, satisfaction, etc.) between the “POCUS available” vs. “POCUS unavailable” groups as well as the “POCUS available” subgroups of “POCUS used” vs. “POCUS not used”.

**Results:** Patients in the “POCUS available” vs. “POCUS unavailable” group had lower mean total and per-day hospital costs (\$17,474 vs. \$21,803,  $p < 0.001$ ; \$2,805.88 vs. \$3,557.53,  $p < 0.001$ ), lower total and per-day radiology cost (\$705.41 vs. \$829.12,  $p < 0.001$ ; \$163.11 vs. \$198.53,  $p < 0.001$ ), fewer total chest X-rays (1.31 vs. 1.55,  $p = 0.01$ ), but more chest CTs (0.22 vs 0.15;  $p = 0.001$ ). Mean length of stay (LOS) was 5.77 days (95% CI = 5.63, 5.91) in the “POCUS available” group vs. 6.08 95% CI (5.66, 6.51) in the “POCUS unavailable” group ( $p = 0.14$ ). Within the “POCUS available” group, cost analysis with a 4:1 PSM (including LOS as a covariate) compared patients receiving POCUS vs. those that could have but did not, and *also* showed total and per-day cost savings in the “POCUS used” subgroup (\$15,082 vs. 15,746;  $p < 0.001$  and \$2,685 vs. \$2,753;  $p = 0.04$ ). **Conclusions:** Availability and selected use of POCUS was associated with a meaningful reduction in total hospitalization cost, radiology cost, and chest X-rays for hospitalized patients.

## Background

Point of care ultrasound (POCUS) is quickly being adopted by internal medicine (IM) physicians in practice and being increasingly taught in the majority of IM residencies due to its impact on procedural safety, diagnostic accuracy and efficiency, provider and patient satisfaction, and use as a teaching adjunct in medical education [1–8]. Despite these benefits, studies demonstrating its impact on system efficiency and cost of care are few, difficult to perform, and mostly in the emergency department (ED) and intensive care unit (ICU) settings [9–11].

A randomized trial to evaluate the impact of POCUS on clinical and system outcomes is impracticable and potentially unethical within a controlled IM setting as it would require withdrawal of POCUS from well-trained, regular users who rely on the tool for optimal care, and in such an environment clinical equipoise would no longer exist [12]. We had a unique natural situation that introduced some aspects of a randomized trial within a single group of POCUS-trained teaching hospitalists. Our study objective was to use this environment to compare cost and other metrics among hospitalized patients cared for with and without POCUS availability.

\*Corresponding Author: Dr. David Tierney (email: david.tierney@allina.com)

This work is licensed under a [Creative Commons Attribution 4.0 International License](https://creativecommons.org/licenses/by/4.0/).

Author(s) retain the copyright for their work. At the time of submission to POCUS Journal the author(s) grant the journal a limited and non revokable right to publish in the Journal under a [Creative Commons Attribution 4.0 International License](https://creativecommons.org/licenses/by/4.0/).

DOI: <https://doi.org/10.24908/pocus.v8i2.16791>

**Methods**

*Setting*

This prospective observational cohort study took place within a 670-bed teaching hospital with a long-standing inpatient and outpatient IM residency-based POCUS curriculum since 2010. The study period (7/1/2011-6/30/2015) was chosen due to the natural randomization of POCUS device availability among a single group of hospitalists as described below and to evaluate outcomes during the earlier years of a POCUS program. The study was approved by our external IRB (Schulman IRB; Reference 201306503).

*IM POCUS Curriculum & Infrastructure*

All first-year IM residents participated in a 5-day, 40-hour internal POCUS course, and completed a 1-month ultrasound rotation—a 1:1 intensive POCUS experience with a core POCUS faculty. Core hospitalist teaching faculty at that time all participated in a 2-day hands-on POCUS course and most proceeded through a mentored, 5+-day, bedside, hands-on experience. All resident-performed exams were mentored by certified faculty at the bedside until the resident was certified. Certification is by individual body area and requires 1) a minimum exam quantity within each body area sub-area (Appendix 1: IMBUS certification criteria), followed by 2) a bedside assessment for POCUS interpretation and clinical integration competency within the body area

being certified [13].

*POCUS Devices and Use*

During the initial years of our POCUS program, six IM resident teams carried portable ultrasound devices (SonoSite NanoMaxx and EDGE devices with P21 [1-5mHz] phased-array and L25 [13-6mHz] linear transducers; FUJIFILM SonoSite Inc., Bothell, WA), resulting in the potential use of diagnostic POCUS for general ward patients limited to patients assigned to resident teams (hospitalist attending, PGY1 and PGY2 resident, and medical students). POCUS exams were prospectively tracked on a smartphone-based application that recorded a unique patient identifier, exam time and location, body areas and items evaluated, findings, type of ultrasound device, and faculty mentor [14]. POCUS was available to intensivists in the ICU and emergency medicine providers in the ED without restriction; exams performed by these *non-IM* providers *were not* included in this study. However, POCUS exams performed by the *IM team* in the ED (such as during the admission exam) or ICU setting *were* included in the study. POCUS for procedural guidance was not included in this study. POCUS examinations were not billed.

*Patient Group Assignments*

Consecutive patients, age >18 years, admitted to IM were sequentially assigned to a hospitalist attending (Figure 1; N=44,213 patients, N=67 hospitalists). The

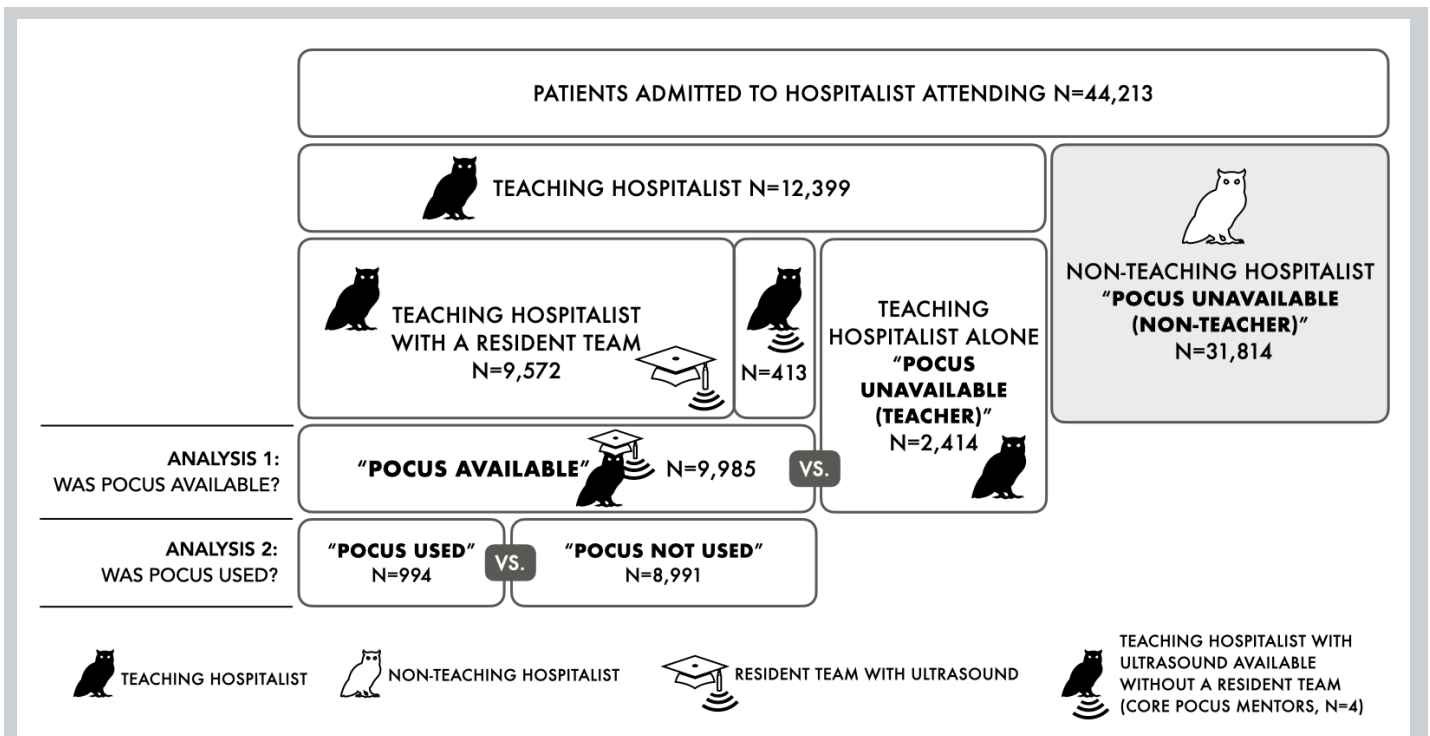


Figure 1. Overall and subgroup patient populations during the study time period with icons denoting the hospitalist type and presence of internal medicine resident teams with POCUS available for patient care. Subgroups analyzed in analyses 1 and 2 (see Methods: Statistical Analysis section) are also depicted in the figure. All n values represent number of patients in the subgroup. POCUS: point of care ultrasound.

hospitalist was either part of the resident faculty (“teaching hospitalist”; n=22) or not (“non-teaching hospitalist”, n=45). Among patients assigned to a teaching hospitalist, concomitant assignment to a resident team was based on whether the teaching hospitalist was 1) actively attending with a resident team that week (versus working independent of a resident team), and 2) if actively attending whether their resident team was available for admissions. So within a given attending week, a teaching hospitalist routinely cared for patients both with a resident team and without. Additionally, within a given month, a teaching hospitalist had weeks where they were not attending and cared for an entire census of patients without resident team involvement. All teaching hospitalists were full time, and spent roughly the same amount of time as each other in their roles as active resident team attending and independent hospitalist. Pertinent to this study, only patients cared for by a teaching hospitalist with a resident team had POCUS available and were classified as “POCUS available”. In addition, four teaching hospitalists who were core ultrasound mentors had constant POCUS access regardless of resident involvement, so patients cared for by these hospitalists were included in the “POCUS available” group even without resident team involvement. Patients assigned to all other *teaching* hospitalists without resident team involvement, and those assigned to *non-teaching* hospitalists were classified as “POCUS unavailable”. Patients with “POCUS unavailable” were further classified into subgroups of “POCUS unavailable (teacher)” and “POCUS unavailable (non-teacher)”, respectively.

Among patients in the “POCUS available” group (Figure 1), those who received at least one POCUS exam during their hospital stay were classified as “POCUS used” while those that did not undergo a recorded exam were classified as “POCUS not used”.

#### Primary and Secondary Outcomes

The study’s co-primary outcomes were difference in total and per-day hospital costs between patients cared for with or without POCUS available. Secondary outcomes included the difference in the major cost subcomponents and key hospitalization metrics of LOS, formal imaging volumes and costs, patient satisfaction, 30-day readmission, and ED visits between patients cared for with vs. without POCUS available (analysis 1 below) and also between patients cared for with POCUS used vs. POCUS available but not used (analysis 2 below). Secondary outcomes also included difference in total and per-day hospital costs (primary outcome) but for the subgroups of POCUS used vs. POCUS available but not used. All study outcomes were pre-specified.

#### Data Sources and Measures

Data were extracted from our POCUS smartphone application (all POCUS-related variables), the hospital’s electronic health record (EHR) (patient demographics, admission diagnosis, formal imaging studies, utilization and outcomes, care team identifiers), and the hospital billing database (costs). Care team identifiers determined involvement of hospitalist type (teaching, non-teaching) and resident team (yes, no) for each admission. In addition to POCUS exams, other imaging utilization variables included chest X-ray (CXR), chest computed tomography (CT), echocardiogram, and radiology-based ultrasound. Patient EHR data were used to compute a severity of illness (SOI) index using an established algorithm [15, 16]. Outcomes included imaging utilization, hospital length-of-stay (LOS), Hospital Consumer Assessment of Healthcare Providers and Systems (HCAHPS) survey scores [17], and total hospitalization and radiology costs. Total hospitalization costs included all fixed and variable costs charged for these subcategories: drug supply, lab, radiology, room, operating room, respiratory care, therapy, other, and unclassified. Prespecified active hospital diagnosis subgroups included pneumonia, congestive heart failure (CHF), and acute kidney injury (AKI). These 3 subgroups were chosen a priori in light of our predominant cardiac, pulmonary, and bladder/kidney POCUS use patterns (Figure 2) and the potential of POCUS to impact those 3 patient populations differently.

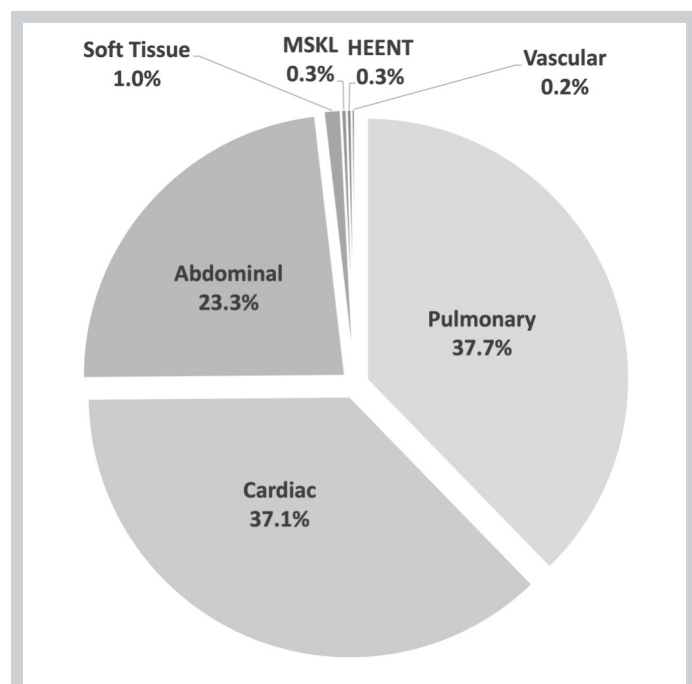


Figure 2. 8,110 total body areas examined within 5,353 POCUS exams performed on 994 patients. HEENT: head, eyes, ears, nose, throat; MSKL: musculoskeletal.



### Statistical Analysis

Prior to outcome comparisons based on POCUS availability or use, two potential confounders associated with the availability of POCUS were assessed: impact of resident involvement in a patient's care irrespective of their tie to POCUS availability/use (the "resident confounder"), and the impact of a hospitalist who is part of the teaching faculty vs. a non-teaching hospitalist caring for a patient irrespective of their tie to the presence of a resident team (the "teacher confounder"). The resident confounder was accounted for by matching patients on assignment to a resident team (yes, no) and subsequent gamma distribution or negative binomial regression to adjust for other variables. Similarly, the teacher confounder was accounted for by matching patients on whether care was provided by a teaching hospitalist (yes, no). The teacher confounder would have only needed to be accounted for in analyses involving non-teaching hospitalist patients (Figure 1, shaded box) as the comparison group—which we chose not to use for the analyses below (see Discussion section for rationale).

Analysis 1a (Figure 1) compared outcomes for patients with POCUS *available* (teaching hospitalist with a resident team, or one of the four core POCUS mentors alone) vs. patients cared for by the same teaching hospitalists with POCUS *unavailable* using multivariable analyses. This eliminated the need to account for the significant and complex "teacher confounder" introduced if using the "POCUS unavailable, non-teacher" group of patients and allowed attendings to serve as their own comparator. However, the "resident confounder" was present and needed to be accounted for in analysis 1a and 1b (below). Multivariable outcome analyses including patient age, sex, admission diagnosis grouping, SOI index [15, 16], and the "resident confounder" were performed. After adjusting for variables, least square means were established with gamma distribution for cost analyses, negative binomial regression for LOS analyses, Poisson distribution for imaging counts, and ordered logistic regression for HCAHPS scores. The same (1a) multivariable analysis was also performed by active diagnosis subgroup (CHF, pneumonia, AKI).

Analysis 1b compared the primary outcomes of total and per-day hospital costs for the same groups as 1a but instead used a 1:1 propensity score matching (PSM) analysis and now *included* LOS in the matching criteria: age, sex, race, admission diagnosis category, SOI, and LOS.

Analysis 2 compared patients within the POCUS available group that actually received at least one POCUS exam, of at least one body area, at any point during hospitalization vs. patients within the POCUS

available group for whom the team elected to never utilize POCUS. A 1:4 PSM analysis was performed including the same covariates as analysis 1b.

Unless otherwise stated, all summary statistics are predicted means from the regression models accompanied by their 95% confidence interval that estimate the degree of precision in the predicted means.

### Results

Patients (N=12,399) were consecutively admitted to the group of 22 teaching hospitalists during the study period (Table 1) with POCUS available for 80% of admissions (n=9,985). Active hospital diagnoses of pneumonia, CHF, and AKI were present in 11%, 22%, and 22% of patients, respectively. Most patients had a SOI index of 2 (37%) or 3 (38%) [15, 16].

For the 9,985 hospitalizations POCUS was available, it was used for 994 patients who underwent 5,353 exams covering 8,110 areas (Figure 2). Pulmonary (37%), cardiac (36%), and abdominal (23%) areas were most frequently performed. Exams combined pulmonary and cardiac areas 56% of the time.

#### *Analysis 1: POCUS available vs. not available*

All values in analysis 1 and 2 are means unless otherwise specified. Their associated 95%CI can be found in the referenced tables 2 and 3.

Analysis 1a, multivariable analyses comparing hospitalizations where POCUS was available vs. not available (Figure 1), showed a LOS of 5.77 vs. 6.08 days (P=0.14), respectively (Table 2). Total and per-day hospitalization costs were significantly lower in the POCUS available group (\$-4,329, P<0.001; \$-751, P<0.001, respectively) as were total and per-day radiology costs (\$-124, P<0.001; \$-35, P<0.001, respectively). Radiology cost reduction among POCUS available patients was driven by a decrease in total CXRs (1.31 vs. 1.55, P=0.005) and tempered by an increase in total chest CT (0.22 vs. 0.15, P=0.001) and total formal ultrasounds (0.35 vs. 0.30, P=0.04).

When imaging outcomes were analyzed by diagnosis subgroups, total CXR use was reduced by 36% in CHF patients with POCUS available (1.63 vs. 2.56, P<0.001); however, formal echocardiograms were not significantly reduced (1.28 vs. 1.59, P=0.145). The AKI subgroup had 42% lower total CXR use when POCUS was available (1.62 vs. 2.79, P=0.001). Patients with pneumonia accounted for most of the chest CT increase seen in the POCUS available cohort (0.51 vs. 0.12, P<0.001) (Appendix 2: Admission subgroup analysis).

Analysis 1b re-analyzed the primary outcome of hospital costs between POCUS available and not available cohorts using a 1:1 PSM analysis *including* LOS as a

Table 1. Patient characteristics

Characteristic	Analysis 1a - MVR			Analysis 1b - 1:1 PSM			Analysis 2 - 1:4 PSM		
	POCUS available	POCUS not available	P	POCUS available	POCUS not available	P	POCUS used	POCUS not used	P
n	9,985	2,414	--	2,402	2,402	--	869	3,476	--
Age, mean (sd)	65.4 (18.5)	61.2 (17.8)	< 0.001	61.41 (18.47)	61.23 (18.54)	0.73	67.5 (17.0)	67.7 (17.1)	0.76
Sex, female, n (%)	5,260 (52.7)	1,235 (51.2)	0.18	1,221 (50.8)	1,228 (51.1)	0.84	416 (47.9)	1,743 (50.1)	0.23
Race, white, n (%)	8,077 (80.9)	2,076 (86.0)	<0.001	2,080 (86.6)	2,066 (86.0)	0.56	702 (80.8)	2,840 (81.7)	0.53
In-hospital mortality, n (%)	223 (2.2)	115 (4.8)	<0.001	95 (4.0)	114 (4.8)	0.18	33 (3.8)	109 (3.1)	0.33
Diagnosis subgroups, n (%)	--	--	--	--	--	--	--	--	--
Pneumonia	1,055 (10.6)	277 (11.5)	0.20	292 (12.2)	276 (11.5)	0.48	171 (19.7)	609 (17.5)	0.14
Congestive heart failure	2,215 (22.2)	504 (20.9)	0.16	474 (19.7)	498 (20.7)	0.39	310 (35.7)	1,306 (37.6)	0.30
Acute kidney injury	2,204 (22.1)	562 (23.3)	0.20	590 (24.6)	557 (23.2)	0.26	255 (29.3)	1,027 (29.6)	0.91
Severity of illness, n (%)	--	--	<0.001	--	--	0.90	--	--	0.96
1	1,320 (13.3)	341 (14.2)	N/D	336 (14.0)	341 (14.2)	N/D	48 (5.5)	203 (5.8)	N/D
2	3,816 (38.4)	769 (32.0)	N/D	769 (32.0)	769 (32.0)	N/D	230 (26.5)	928 (26.7)	N/D
3	3,915 (39.4)	814 (33.9)	N/D	837 (34.9)	814 (33.9)	N/D	457 (52.6)	1,831 (52.7)	N/D
4	896 (9.0)	478 (19.9)	N/D	460 (19.2)	478 (19.9)	N/D	134 (15.4)	514 (14.8)	N/D

Diagnosis subgroups represent prespecified diagnoses that were active during a given patient's hospitalization. MVR: multivariable regression; N/D: not determined; POCUS: point-of-care ultrasound; PSM: propensity score matched

covariate (unlike 1a where LOS was a dependent variable) and demonstrated total hospital and per-day costs remained significantly lower with POCUS available (\$19,905 vs. \$21,490,  $P=0.008$ ; \$2,776 vs. \$3,441,  $P<0.001$ ).

30-day hospital readmission, ED visits, and HCAHPS question scores (Appendix 3: HCAHPS survey) targeting physician courtesy/respect, listening, explaining understandably, as well as overall hospitalization ratings did not differ significantly between groups.

*Analysis 2: POCUS available and used vs. available but not used*

In this cohort design, providers with POCUS available chose to use it on some patients but not others for unknown reasons that may impact outcomes. Therefore, comparison of these two groups does not directly assess the value of POCUS and introduces potential

confounding. This 1:4 PSM analysis (including LOS as a covariate because of its non-linear impact on variable costs and potential influence on decisions to use ultrasound) was chosen to compare the two subgroups of patients to minimize unaccounted for confounders (Table 1). It showed a significant reduction in total and per-day hospitalization costs, a reduction in total and per-day costs, a reduction in total and per-day hospitalization costs, a reduction in total and per-day CXRs, as well as a small increase in chest CT and formal echocardiograms in the subgroup where POCUS was chosen for use (Table 3).

## Discussion

Through multiple analytic lenses, POCUS availability and selected use by IM hospitalist teaching teams was significantly, and meaningfully associated with reduced hospital costs and CXR use with a slight increase in chest CT. The "POCUS available vs. not available" analysis (1a) probably best reflects a real-world, system-

Table 2. Patient and system outcomes – analysis 1a and 1b

Outcome	Analysis 1a - Multivariable Regression Analysis			
	POCUS available	POCUS not available	Difference	P
n	9,985	2,414	--	--
Length of stay (days)	5.77 (5.63 - 5.91)	6.08 (5.66 - 6.51)	-0.31	0.14
Total hospitalization cost (\$)	17,474 (16,397 - 18,010)	21,803 (20,212 - 23,393)	-4,329	<0.001
Hospitalization cost per day (\$)	2,805.88 (2,761.63 - 2,850.13)	3,557.53 (3,426.33 - 3,688.72)	-751.65	<0.001
Total hospitalization radiology cost (\$)	705.41 (680.57 - 730.25)	829.12 (755.38 - 902.67)	-123.71	<0.001
Radiology cost per day (\$)	163.11 (155.59 - 170.62)	198.53 (176.23 - 220.84)	-35.42	<0.001
Chest X-Ray total/hospitalization	1.31 (1.26 - 1.37)	1.55 (1.38 - 1.72)	-0.24	0.01
Chest X-Ray per day	0.22 (0.22 - 0.23)	0.27 (0.24 - 0.29)	-0.04	0.09
Chest CT total/hospital stay	0.22 (0.21 - 0.23)	0.15 (0.11 - 0.19)	0.07	0.001
Chest CT per day	0.04 (0.04 - 0.05)	0.03 (0.02 - 0.04)	0.01	0.26
Echocardiogram total/hospital stay	1.21 (1.17 - 1.24)	1.36 (1.26 - 1.46)	-0.15	0.19
Echocardiogram per day	0.38 (0.37 - 0.40)	0.41 (0.37 - 0.45)	-0.03	0.62
Ultrasound total/hospital stay	0.35 (0.33 - 0.37)	0.30 (0.24 - 0.35)	0.05	0.04
Ultrasound per day	0.08 (0.07 - 0.08)	0.07 (0.05 - 0.09)	0.01	0.73
	Analysis 1b - 1:1 Propensity Score Matched			
n	2,402	2,402	--	--
Total hospitalization cost (\$)	19,905 (17,508 - 22,301)	21,490 (19,093 - 23,888)	-1,585	0.01
Hospitalization cost per day (\$)	2,776.46 (2,606.55 - 2,946.38)	3,441.35 (3,271.39 - 3,611.32)	-664.89	<0.001

*Analysis 1a and 1b compare outcomes between patients cared for by hospitalists with POCUS available but not necessarily used, and those cared for without POCUS available using multivariable regression (length of stay as dependent variable) and 1:1 propensity score matched (length of stay as covariate) analyses. All values are mean (95% CI) unless otherwise noted. POCUS: point-of-care ultrasound; PSM: propensity score matched*

level approach to a POCUS implementation's per-day cost savings in which devices are available for provider use based on clinical circumstance, but where POCUS isn't mandated for a group of patients. Total hospital cost savings in this primary analysis is certainly driven partly by lower LOS which, importantly, may be in part due to POCUS but is at risk for confounding overestimating its benefit. However, the 1:1 PSM re-analysis (1b) containing LOS as a covariate maintained significant differences in both total and per-day costs increasing the probability that POCUS was impacting outcomes and likely underestimating its benefit through some reduction in LOS. In every environment there will be patients who would have benefited from POCUS but did not receive it, and patients who did not benefit or even had additional

cost or LOS because of an incidental finding. This study design and analysis 1 accounts for those aspects of a real-world POCUS implementation better than a randomized trial might.

The primary cost endpoints were further evaluated between the "POCUS available" subgroups that had "POCUS used" vs. those that "could have but didn't" (Analysis 2) and included LOS as a covariate instead of a dependent variable. The more modest cost savings seen in this analysis likely reflects the non-linear relationship of LOS (covariate in this analysis, dependent variable in analysis 1a) vs. variable hospital costs, significantly lower total and daily hospitalization costs in the "POCUS not used" cohort, and the presence of other cost or LOS-increasing confounders triggering POCUS

Table 3. Patient and system outcomes – analysis 2

	Analysis 2 - 1:4 Propensity Score Matched			
Outcome	POCUS used	POCUS not used	Difference	P
n	869	3,476	--	--
Total hospitalization cost (\$)	15,082 (14,439 - 15,725)	15,746 (15,364 - 16,127)	-664	<0.001
Hospitalization cost per day (\$)	2,685 (2,592 - 2,778)	2,753 (2,698 - 2,808)	-68	0.04
Total hospitalization radiology cost (\$)	642 (590 - 694)	630 (599 - 661)	12	0.23
Radiology cost per day (\$)	146 (132 - 161)	154 (145 - 163)	-7	0.17
Chest X-Ray total/hospitalization	1.64 (1.51 - 1.77)	1.16 (1.08 - 1.24)	0.48	< 0.001
Chest X-Ray per day	0.31 (0.28 - 0.33)	0.25 (0.23 - 0.26)	0.06	0.001
Chest CT total/hospital stay	0.30 (0.26 - 0.33)	0.20 (0.18 - 0.22)	0.10	< 0.001
Chest CT per day	0.06 (0.05 - 0.07)	0.05 (0.04 - 0.05)	0.01	0.07
Echocardiogram total/hospital stay	0.43 (0.38 - 0.48)	0.34 (0.31 - 0.37)	0.10	< 0.001
Echocardiogram per day	0.09 (0.08 - 0.11)	0.07 (0.07 - 0.08)	0.02	0.10
Ultrasound total/hospital stay	1.30 (1.23 - 1.37)	1.17 (1.12 - 1.22)	0.13	0.05
Ultrasound per day	0.33 (0.30 - 0.35)	0.37 (0.35 - 0.38)	-0.04	0.86

Analysis 2 includes patients cared for by hospitalists with POCUS available for use and compares outcomes between patients where POCUS was chosen to be used and patients where POCUS was available but not chosen to be used using 1:4 propensity score matched (length of stay as covariate) analyses. All values are mean (95% CI) unless otherwise noted. POCUS: point-of-care ultrasound; PSM: propensity score matched

use by providers such as higher illness burden (not captured by SOI index), lack of timely improvement prompting POCUS use, etc. Despite these potential cost-increasing selection biases for POCUS use, savings associated with POCUS use were maintained.

CXR reduction is a well-known POCUS benefit, has been shown in ICU and pediatric studies[18, 19], and is consistent with our results. The small but identifiable increase in chest CT is also congruent with our clinical experience. Rarely is CXR additive to a thorough pulmonary POCUS exam, so a CT is typically the appropriate next test. The diagnostic testing sequence of POCUS + CT is overall less radiation and cost compared to CXR + CT with better test characteristics [20]. The minimal reduction in CXR seen in the pneumonia “POCUS available” subgroup may seem counterintuitive; however, these CXRs are usually obtained in the ED or outpatient setting prior to hospital admissions and rarely repeated. The largest reduction in CXR use was seen in patients with CHF and AKI active during their

hospitalization where volume status and ongoing diuresis decisions may traditionally prompt a CXR—information more accurately gathered with a cardiopulmonary POCUS exam [20–24].

There is a paucity of POCUS cost effectiveness research with virtually none within IM. Cost’s main determinant, LOS, has more, but still very limited data. Recently, Matthews et al. presented a \$743 reduction in patient cost for *each* POCUS exam performed by a hospitalist (n=50) [25]. An Italian cost modeling study in 2015 demonstrated the equivalence of ~\$128 cost savings per hospital exam and a break-even point for a program of 734 exams [26]. An Australian trial in hospitalized patients with cardiopulmonary symptoms receiving cardiac, lung, and vascular POCUS at admission (n=124) vs. no POCUS demonstrated no significant difference in LOS (113 vs. 125 hr), 30-day readmission (16% vs. 12%), or total costs (~\$6,030 vs. ~\$6,079, respectively) [21]. Mozzini et al. found a 1 day reduction in LOS in hospitalized CHF patients receiving multiple lung

ultrasound exams vs. CXR guiding diuresis [27]. Lucas et al. did not identify a significant decrease in LOS for hospital patients receiving hand-carried echocardiography (n=226), but did identify a significant 17% reduction in a subgroup of patients with CHF [10]. In contrast to these previous studies, our study includes the most patients of any published study, with any admission diagnosis, a large amount (23%) of abdominal POCUS, and multiple patients receiving repeat exams compared to single admission exams. An important efficiency gained from IM POCUS may be in following changes with treatment or use when patients are not responding as expected after admission—not captured in studies with a single admission POCUS.

Our results represent a diverse, quaternary-care, patient population at a large urban teaching hospital with a robust POCUS training program, but should be cautiously extrapolated to other settings. We show outcomes from the early years of our program because it availed the unique setting of attendings functioning as their own “control”. Secondly, the outcomes of a program after 8-10 years of maturation may be less meaningful for programs attempting to justify initial POCUS implementation. As a program matures, provider skill and recognition of normal variation increases, POCUS as a language of communication becomes fluent between providers, and system efficiencies likely increase.

A decision was made to compare patients cared for with and without POCUS (n=12,399) among the *same* group of teaching hospitalists (comparing teaching hospitalists to themselves in the 4 study cohorts and 2 analyses) rather than the alternative of comparing patients cared for with POCUS by *teaching* hospitalists to the much larger cohort of patients (n=31,814) cared for without ultrasound by *non-teaching* hospitalists. The subgroup of teaching hospitalists invited to that teaching role differ on average from our non-teaching hospitalists in complex ways, some of which (experience, efficiency, personality, test ordering patterns, etc.) have potential to impact chosen study outcomes in ways unrelated to POCUS. The use of a regression analysis that attempted to adjust for this complex set of characteristics between 2 different groups of hospitalists (using the “teacher confounder”) with the goal of ultimately isolating POCUS as the variable impacting study outcomes such as LOS, radiology test ordering, patient satisfaction, etc. was methodologically weak. We believe the methodologic decision to compare teaching hospitalists to themselves, despite decreasing the overall number of patients in the study, results in a more valid assessment of POCUS’ impact on our study outcomes.

Two audits during our program’s evolution demonstrated recording rates for POCUS exams were 87-91%; thus,

there were likely patients misassigned to the analysis 2 “was not used” group (~10%)—theoretically underestimating POCUS’ benefit in analysis 2 but not impacting analysis 1. Proportion of exams changing management was not tracked; however, it likely resembles that of most POCUS programs during the early years of development. Program implementation costs (equipment, training, consumables, physician time) were not analyzed as this is institution-specific and rapidly changing. We did not compile all hospital diagnoses in this study but expect over the 4-year study period that the diagnosis mix would be reasonably balanced between the POCUS available and not available cohorts due to the allocation algorithm of patient admissions to hospitalists and resident teams. Thus, the actual diagnosis mix within a cohort should not impact the primary and secondary outcomes assessing difference between the POCUS available and not available cohorts. Additional savings from LOS reduction when POCUS can replace the need to wait for formal imaging studies may be seen in other settings, but contributed minimally in our setting where imaging was readily available [26]. Similarly, POCUS for procedural guidance can decrease LOS when delays in radiology-based scheduling exist, reduce unnecessary procedures, and reduce complications associated with landmark-based procedures [28, 29]. These potential benefits for other groups were not part of our analysis as all patients had readily accessible ultrasound-guided bedside procedures through our procedure team. Potential unaccounted for confounders contributing to over- or under-estimation of POCUS’ benefit are possible in the PSM analyses. Finally, this study did not evaluate potential harm from POCUS specifically, but there was no difference in 30-day readmission or ED visits for patients in the POCUS group, and most other potential harms would otherwise be reflected in additional LOS and cost.

Acknowledging these limitations, this study builds on currently available anecdotal experience and smaller studies demonstrating the impact of POCUS within IM. Actual system and patient benefits attributable to IM POCUS *alone* likely resides somewhere between the two lenses it has been examined through in this large prospective cohort study. However, like for many other tools physicians utilize daily with great benefit, we are unlikely to see a randomized trial that is capable of truly isolating the causal impact of POCUS on hospital metrics for the reasons previously discussed and limitations of randomized trials.

## Declarations

*Ethics approval and consent to participate:* Patient

consent obtained for research participation; ethics approval waived. IRB approval Reference 201306503

**Competing Interests:** TR, LS, KH, CS, LB, RM all declare no potential conflicts of interest related to the content of this manuscript. DT serves on the POCUS Task Force for the Society of Hospital Medicine and American College of Physicians (ACP), is the co-director for the ACP Fundamentals of POCUS course with honoraria, has previously served on the medical advisory board for EchoNous, Inc. and currently holds stock and stock options.

**Funding:** The Abbott Northwestern Hospital Foundation provided funding for study design consultation and statistical analysis. The source had no role in conducting the study, analysis, or manuscript prep/review.

**Author Contributions:** All authors have contributed significantly to and approved the final manuscript. DT, TR, RM contributed to study design and writing & revision of the manuscript. KH contributed to study design, data analysis. CS, LB contributed to study design, data analysis, and writing & revision of the manuscript. LS contributed significantly to writing & revision of the manuscript.

**Acknowledgements:** none

## References

- LoPresti CM, Schnobrich D, Novak W et al. Current Point of Care Ultrasound Use and Training Among Internal Medicine Residency Programs from the 2020 APDIM Program Director's Survey. *Am J Med.* 2022;135(3):397-404.
- Soni NJ, Schnobrich D, Matthews BK et al. Point-of-Care Ultrasound for Hospitalists: A Position Statement of the Society of Hospital Medicine. *J Hosp Med.* 2019;14:E1-E6.
- Lucas BP, Tierney DM, Jensen TP et al. Credentialing of Hospitalists in Ultrasound-Guided Bedside Procedures: A Position Statement of the Society of Hospital Medicine. *J Hosp Med.* 2018;13:117-125.
- Cho J, Jensen TP, Rierson K et al. Recommendations on the Use of Ultrasound Guidance for Adult Abdominal Paracentesis: A Position Statement of the Society of Hospital Medicine. *J Hosp Med.* 2019;14:E7-E15.
- Dancel R, Schnobrich D, Puri N et al. Recommendations on the Use of Ultrasound Guidance for Adult Thoracentesis: A Position Statement of the Society of Hospital Medicine. *J Hosp Med.* 2018;13:126-135.
- Soni NJ, Franco-Sadud R, Kobaidze K et al. Recommendations on the Use of Ultrasound Guidance for Adult Lumbar Puncture: A Position Statement of the Society of Hospital Medicine. *J Hosp Med.* 2019;14:591-601.
- Franco-Sadud R, Schnobrich D, Mathews BK et al. Recommendations on the Use of Ultrasound Guidance for Central and Peripheral Vascular Access in Adults: A Position Statement of the Society of Hospital Medicine. *J Hosp Med.* 2019;14:E1-E22.
- Bhagra A, Tierney DM, Sekiguchi H, Soni NJ. Point-of-Care Ultrasonography for Primary Care Physicians and General Internists. *Mayo Clin Proc.* 2016;91:1811-1827.
- Pontet J, Yic C, Díaz-Gómez JL et al. Impact of an ultrasound-driven diagnostic protocol at early intensive-care stay: a randomized-controlled trial. *Ultrasound J.* 2019;11:24.
- Lucas BP, Candotti C, Margeta B et al. Hand-carried echocardiography by hospitalists: a randomized trial. *Am J Med.* 2011;124:766-774.
- Chen Z, Hong Y, Dai J, Xing L. Incorporation of point-of-care ultrasound into morning round is associated with improvement in clinical outcomes in critically ill patients with sepsis. *J Clin Anesth.* 2018;48:62-66.
- Feinstein AR. An additional basic science for clinical medicine: II. The limitations of randomized trials. *Ann Intern Med.* 1983;99:544-550.
- Tierney D. Competency Cut-Point Identification Derived From A Mastery Learning Cohort Approach: A Hybrid Model. *Ultrasound in Medicine and Biology.* 2015;41:S19.
- Tierney D. 2090531 Development & Analysis of a Mobile POCUS Tracking Tool. *Ultrasound in Medicine and Biology.* 2015;41:S31.
- Horn SD, Sharkey PD, Bertram DA. Measuring severity of illness: homogeneous case mix groups. *Med Care.* 1983;21:14-30.
- 3M All Patient Refined Diagnosis Related Groups (APR DRG) Methodology Overview. [https://apps.3mhis.com/docs/Groupers/All\\_Patient\\_Refined\\_DRG/Methodology\\_overview\\_GRP041/grp041\\_aprdrg\\_meth\\_overview.pdf](https://apps.3mhis.com/docs/Groupers/All_Patient_Refined_DRG/Methodology_overview_GRP041/grp041_aprdrg_meth_overview.pdf). Updated 2022. Accessed 9/11/2023.
- Hospital Consumer Assessment of Healthcare Providers and Systems (HCAHPS) Survey. <https://hcahpsonline.org>. Accessed 10/21/2023.
- Brogi E, Bignami E, Sidoti A et al. Could the use of bedside lung ultrasound reduce the number of chest x-rays in the intensive care unit. *Cardiovasc Ultrasound.* 2017;15:23.
- Jones BP, Tay ET, Eilikashvili I et al. Feasibility and Safety of Substituting Lung Ultrasonography for Chest Radiography When Diagnosing Pneumonia in Children: A Randomized Controlled Trial. *Chest.* 2016;150:131-138.
- Tierney DM, Huelster JS, Overgaard JD et al. Comparative Performance of Pulmonary Ultrasound, Chest Radiograph, and CT Among Patients With Acute Respiratory Failure. *Crit Care Med.* 2020;48:151-157.
- Cid-Serra X, Roysse A, Cauty D et al. Effect of a Multiorgan Focused Clinical Ultrasonography on Length of Stay in Patients Admitted With a Cardiopulmonary Diagnosis: A Randomized Clinical Trial. *JAMA Netw Open.* 2021;4:e2138228.
- Maw AM, Hassanin A, Ho PM et al. Diagnostic Accuracy of Point-of-Care Lung Ultrasonography and Chest Radiography in Adults With Symptoms Suggestive of Acute Decompensated Heart Failure: A Systematic Review and Meta-analysis. *JAMA Netw Open.* 2019;2:e190703.
- Platz E, Merz AA, Jhund PS, Vazir A, Campbell R, McMurray JJ. Dynamic changes and prognostic value of pulmonary congestion by lung ultrasound in acute and chronic heart failure: a systematic review. *Eur J Heart Fail.* 2017;19:1154-1163.
- Beaubien-Souligny W, Rola P, Haycock K et al. Quantifying systemic congestion with Point-Of-Care ultrasound: development of the venous excess ultrasound grading system. *Ultrasound J.* 2020;12:16.
- Mathews BK, Mehta A, Verner J, Dickinson O, Vuong K, Reiersen K. Value of point-of-care-ultrasound (POCUS) in a hospital medicine department: an analysis of decision making and cost savings. *Journal of Hospital Medicine.* 2022;Abstract published at SHM Converge 2021:Abstract 215.
- Testa A, Francesconi A, Giannuzzi R, Berardi S, Sbraccia P. Economic analysis of bedside ultrasonography (US) implementation in an Internal Medicine department. *Intern Emerg Med.* 2015;10:1015-1024.
- Mozzini C, Di Dio Perna M, Pesce G et al. Lung ultrasound in internal medicine efficiently drives the management of patients with heart failure and speeds up the discharge time. *Intern Emerg Med.* 2018;13:27-33.
- Mercaldi CJ, Lanes SF. Ultrasound guidance decreases complications and improves the cost of care among patients undergoing thoracentesis and paracentesis. *Chest.* 2013;143:532-538.
- Nazeer SR, Dewbre H, Miller AH. Ultrasound-assisted paracentesis performed by emergency physicians vs the traditional technique: a prospective, randomized study. *Am J Emerg Med.* 2005;23:363-367.

# The Impact of a Handheld Ultrasound Device in a Rheumatic Heart Disease Screening Program in Ethiopia

Zachary P Kaltborn, MD<sup>1\*</sup>; Anteneh Zewde, MD<sup>2</sup>; Jonathan D Kirsch, MD<sup>2</sup>; Michelle Yates, MD<sup>3</sup>;  
Katelyn M Tessier, MS<sup>4</sup>; Eileen Nemec, RDCS FASE<sup>5</sup>; Ronald A Johannsen, MD<sup>6</sup>

(1) University of Minnesota Medical School, Departments of General Internal Medicine and Pediatrics, Minneapolis, MN, USA

(2) University of Minnesota Medical School, Department of General Internal Medicine, Minneapolis, MN, USA

(3) Soddo Christian Hospital, Soddo, Ethiopia

(4) University of Minnesota, Masonic Cancer Center, Biostatistics Core, Minneapolis, MN, USA

(5) Children's Minnesota, Minneapolis, MN, USA

(6) Hennepin Health Care, Division of Cardiology, Minneapolis, MN, USA

## Abstract

**Background:** Rheumatic heart disease (RHD) affects 33 million people in low and middle income countries and is the leading cause of cardiovascular death among children and young adults. Penicillin prophylaxis prevents progression in asymptomatic disease. Efforts to expand echocardiographic screening are focusing on simplified protocols, non-physician ultrasonographers, and portable ultrasound devices, including handheld ultrasound. Recent advances support the use of single-view screening protocols. With the increasing availability and low cost of handheld devices, studies are needed to evaluate their performance in these settings. **Methods:** We conducted a retrospective study comparing the rate of screen positive ultrasounds before and after the use of a handheld ultrasound in an RHD screening program in Ethiopia. We also performed a cross-sectional device comparison in 19 at-risk school-children participating in the rheumatic heart disease screening program. **Results:** Between March of 2019 and January of 2022, 6631 children were screened for rheumatic heart disease of whom 4029 were screened after the introduction of a handheld device. Before the use of the handheld ultrasound device 291 (11.2%) children had a screen positive ultrasounds compared with 167 (4.1%) afterwards ( $p < 0.001$ ). We also compared non-expert to expert interpretation by device and found a significant difference in interpretation for the Lumify ( $p = 0.025$ ). There was a trend towards shorter jet length by color Doppler in the handheld ultrasound device for both expert and non-expert review. **Conclusions:** Our study highlights that the screen-positive rate in a RHD screening program is influenced by the device being used in the screening process.

## Background

Rheumatic heart disease (RHD) affects 33 million people in low and middle income countries and is the leading cause of cardiovascular death among children and young adults [1]. RHD develops as a consequence of acute rheumatic fever which primarily affects children and will lead to RHD in 60% of cases [2]. Early identification of RHD has become a cornerstone of prevention strategies and echocardiography can identify ten times the number of affected children when compared to physical exam [3]. In 2012, the World Heart Federation (WHF) updated their guideline for the diagnosis of asymptomatic or latent RHD including criteria for 'definite' and 'borderline' disease [4].

Using this guideline, cross-sectional echocardiographic studies have found a substantial burden of disease around the globe [5-9]. Once identified, latent RHD appears to follow a heterogeneous course but recent evidence supports the benefit of secondary prophylaxis with penicillin [10].

While the WHF criteria serve as the gold standard for making a diagnosis of RHD, they are impractical for population-based screening programs due to time, cost, and resource availability [11]. Efforts to expand echocardiographic screening are focusing on simplified protocols, non-physician ultrasonographers, and portable ultrasound devices, including handheld ultrasound [12].

\*Corresponding Author: Zachary P. Kaltborn, MD (email: kalt0020@umn.edu)

This work is licensed under a [Creative Commons Attribution 4.0 International License](https://creativecommons.org/licenses/by/4.0/).

Author(s) retain the copyright for their work. At the time of submission to POCUS Journal the author(s) grant the journal a limited and non-revokable right to publish in the Journal under a [Creative Commons Attribution 4.0 International License](https://creativecommons.org/licenses/by/4.0/).

DOI: <https://doi.org/10.24908/pocus.v8i2.16390>

For example, Beaton et al. demonstrated that pediatric cardiologists employing a simplified handheld ultrasound protocol can achieve high diagnostic accuracy [13]. However, shortages of echocardiographers and cardiologists in many endemic regions limit the expansion of population-based screening programs [14]. Efforts to expand the screening responsibilities to include a non-physician workforce could overcome this limitation [15]. Through focused training, non-physician ultrasonographers using simplified screening protocols can achieve sensitivities and specificities for detecting early RHD ranging between 74-84% and 78-90% respectively [16-19]. Studies evaluating single image protocols with color Doppler of the mitral and aortic valves have demonstrated sensitivity of 73-92% and specificity of 75-100% for latent RHD and screening times of 1-4 minutes [20-23]. More recently, an augmented single-view screening protocol was prospectively evaluated in a cohort of school-children in Timor-Leste and demonstrated a sensitivity of 100% and a specificity of 95% when completed by an expert cardiologist using standard echocardiography equipment [24]. While there is increasing evidence that single view screening protocols can adequately detect latent RHD, there is no consensus on the criteria that define a positive screen [21,24,25]. Furthermore, implementation of handheld ultrasound protocols have not been widely evaluated and the real-world sensitivity and specificity may miss numerous cases of latent RHD while still referring multiple normal children for confirmatory echocardiograms [26]. Our study aims to expand what is known about the performance of handheld devices in RHD screening programs and how they impact referrals for confirmatory echocardiograms.

## Methods

### Study Setting

In April of 2019, Soddo Christian Hospital began operating a RHD screening program following our previously described protocol [23]. The screening team consists of six locally trained *RHD screeners* under the supervision of an onsite physician. The screeners were recruited from a wide range of hospital staff including nurses, technicians, receptionists, and sanitation personnel. These personnel were selected through an internal application process. All screeners completed a mentored training program to become proficient in executing a single parasternal long-axis view of the heart with and without color-Doppler.

### Study Design

From April 2019 through December 2019, the screening team used a portable Sonosite M-turbo ultrasound

machine. Starting in December 2019, the screening team began to use a Philips Lumify hand-held ultrasound device. Over a two-day period in November 2019, we conducted a comparison study between ultrasound devices after which time the screening team began to use the handheld device for all future school-based screenings. On both study days, all children screened were between the ages of 15-18 and from the same school. For the screening, a portable Sonosite M-turbo ultrasound machine was used with a 5-1Mhz phased array ultrasound probe. A Nyquist limit of 72 cm/s was used for color Doppler images with a frame rate of 16.667 Hz. All children determined to be positive by the screening team, as well as a random sample of children undergoing screening, were selected for a device comparison study. To minimize differences observed between devices, all children underwent repeat screening echocardiogram using the Sonosite M-turbo by a trained pediatric cardiac sonographer. This same echocardiographer then used a Philips Lumify hand-held ultrasound device using a S4-1 Mhz phased array probe. For color Doppler imaging, the Lumify device has a fixed Nyquist limit of 60 cm/s and an auto-adjusting frame rate. Two and three second video clips were stored on the Sonosite and Philips devices respectively. Images were then transferred onto encrypted flash drives and transferred onto secure hard drives for analysis. Clips contained a parasternal long-axis view of the heart with and without color Doppler. No associated demographic information was stored, and a random number was used to link the individual between devices. Where appropriate, separate images were saved for the aortic and mitral valves. Our study intervention did not alter the recommendations of the screening team and all children determined to be positive by the screening team were referred per protocol for confirmatory echocardiogram using a modified WHF criteria as the gold standard as described previously [23]. This study was reviewed and approved by the Institutional Review Boards of Soddo Christian Hospital and the University of Minnesota.

### Study Tool

All identifying information was removed from the stored video clips. Due to obvious differences in image quality and clip duration, interpretation could not be blinded by device. All images were randomly arranged for analysis so that the interpreting study investigator was not able to compare images from one individual to another. Interpretation data were collected and managed using REDCap electronic data capture tools hosted at the University of Minnesota [27]. A 16-item interpretation survey was designed to capture the required elements for determining if the ultrasound was screen positive or screen negative. For the purposes of this study and



within the RHD screening program, a screening ultrasound was positive if the following criteria were met: (1) A pansystolic and multicolored regurgitation at the mitral valve by color Doppler estimated at a length of more than 1.5 cm. If the regurgitation was eccentric, an estimated length of more than 1 cm was considered positive; (2) Any regurgitation at the aortic valve; (3) Any valvular abnormalities consistent with RHD. These criteria were derived from the findings of published studies and expert consensus [10,20,21,23,24]. Two study investigators reviewed all ultrasounds, one an experienced cardiologist (R.J., expert) and the other an internal medicine and pediatric hospitalist (Z.K., non-expert) with experience in the use of point of care ultrasound. This design was used to capture differences in non-expert interpretation as might occur during routine school-based screenings.

### Statistical Analysis

The primary objective of the comparison study was to determine the agreement between devices for each reader. For each reader, the agreement between devices was summarized and compared using McNemar's test for paired samples. A secondary objective was to determine the agreement between reviewers for each device. Demographics were compared before and after the Lumify device was implemented using Wilcoxon rank sum, Chi-square or Fisher's exact tests, when appropriate. Screen-positive rate before and after the transition to using the handheld device was summarized and compared using logistic regression. Odds ratios (OR) and 95% confidence intervals (CI) were obtained.

All reported p-values are two-sided and significance level of 0.05 was used. Statistical analyses were performed using R (version 3.6.1, R Core Team) and SAS (version 9.4, SAS Institute Inc., Cary, North Carolina).

### Results

Between April 2019 and December 2019, 2602 children ages 6-18 underwent screening for RHD (Table 1). During this time, 291 (11.2%) children had a positive screen and were referred for a confirmatory echocardiogram. Between December 2019 and January 2022, 4027 children ages 6-18 underwent screening for RHD. During this time, 167 (4.1%) had a positive screen and were referred for a confirmatory echocardiogram which was statistically significantly different than before the Lumify device was implemented ( $p < 0.001$ ). Logistic regression demonstrated a significantly lower odds of a positive screening exam following the introduction of the Lumify device, even after adjusting for age and gender (adjusted OR: 0.25, 95% CI: 0.2, 0.31,  $p < 0.001$ , Table 2). More of the schools were classified as public following the transition (85.4% vs 19.3%,  $p < 0.001$ ). We also performed an analysis of the rates of screen positivity for each school over time, including the time of the transition in device which shows an abrupt change in screening positive even within the same school ( $p < 0.001$ , Figure 1). Screen-positive children were referred for a confirmatory ultrasound. Complete data was not available for each confirmatory echocardiogram but there was a statistically significant change in the distribution of MR jet lengths (for those with a measurable value) as assessed by color Doppler ( $p < 0.001$ , Table 3).

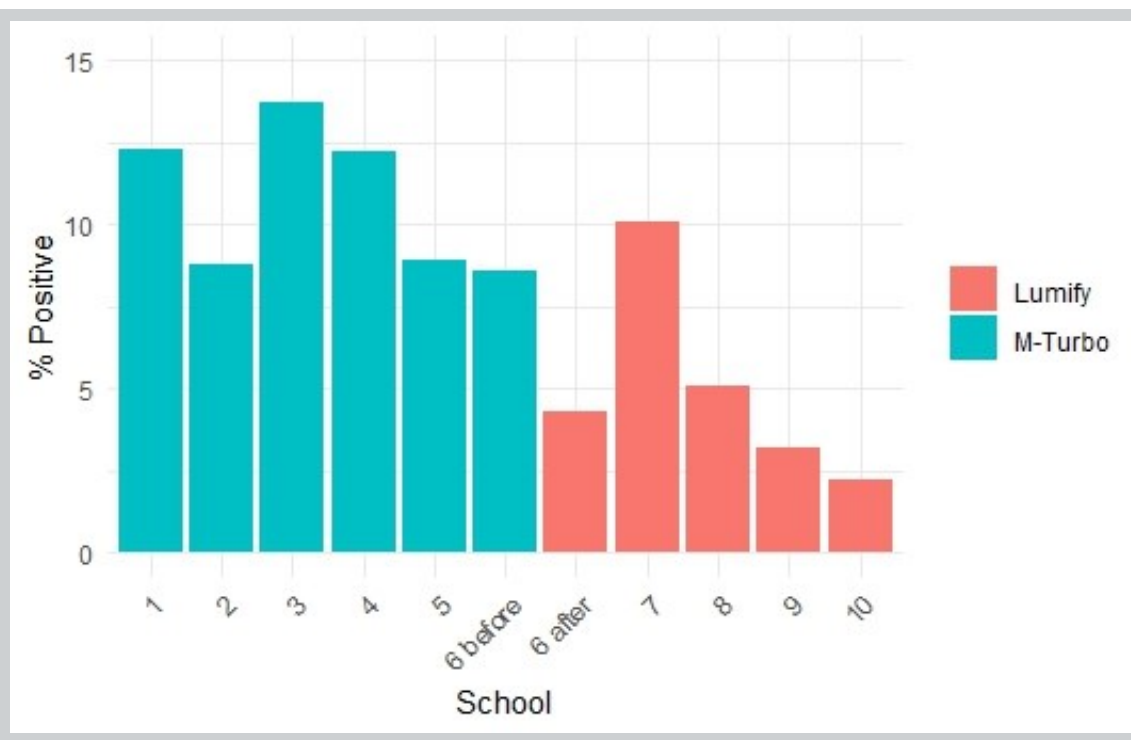


Figure 1. Rate of screening positivity for each school, including the school in which the transition occurred. ( $p < 0.001$ ).

Table 1. Comparison of demographics and screening results for all children before and after Lumify device.

Variable	All children (N=6629)	All children screened before Lumify device (N=2602)	All children screened after Lumify device (N=4027)	P-value*
<b>Age</b>				<0.001
Mean (SD)	14.3 (2.9)	13.1 (3.1)	15.2 (2.4)	
Median (Range)	15.0 (1.0, 18.0)	13.0 (1.0, 18.0)	15.0 (7.0, 18.0)	
<b>Gender, n (%)</b>				<0.001
Number missing	2	1	1	
Female	5422 (81.8%)	2374 (91.3%)	3048 (75.7%)	
Male	1204 (18.2%)	227 (8.7%)	977 (24.3%)	
Other	1 (0.0%)	0 (0.0%)	1 (0.0%)	
<b>Echo screening result, n (%)</b>				<0.001
Negative	6171 (93.1%)	2311 (88.8%)	3860 (95.9%)	
Positive	458 (6.9%)	291 (11.2%)	167 (4.1%)	
<b>Confirmatory echo, n (%)</b>				0.110
Number missing	6202	2317	3885	
Abnormal	425 (99.5%)	285 (100.0%)	140 (98.6%)	
Normal	2 (0.5%)	0 (0.0%)	2 (1.4%)	
<b>MR jet length, n (%)</b>				<0.001
Number missing	6204	2317	3887	
1-1.4 cm	130 (30.6%)	51 (17.9%)	79 (56.4%)	
1.5-2 cm	287 (67.5%)	229 (80.4%)	58 (41.4%)	
>2 cm	8 (1.9%)	5 (1.8%)	3 (2.1%)	
<b>School, n (%)</b>				-
1	335 (5.1%)	0 (0.0%)	335 (8.3%)	
2	600 (9.1%)	600 (23.1%)	0 (0.0%)	
3	508 (7.7%)	255 (9.8%)	253 (6.3%)	
4	501 (7.6%)	501 (19.3%)	0 (0.0%)	
5	502 (7.6%)	502 (19.3%)	0 (0.0%)	
6	247 (3.7%)	247 (9.5%)	0 (0.0%)	
7	1285 (19.4%)	0 (0.0%)	1285 (31.9%)	
8	497 (7.5%)	497 (19.1%)	0 (0.0%)	
9	897 (13.5%)	0 (0.0%)	897 (22.3%)	
10	1257 (19.0%)	0 (0.0%)	1257 (31.2%)	
<b>School location, n (%)</b>				-
Urban	6629 (100.0%)	2602 (100.0%)	4027 (100.0%)	
<b>School type, n (%)</b>				<0.001
Private	2688 (40.5%)	2100 (80.7%)	588 (14.6%)	
Public	3941 (59.5%)	502 (19.3%)	3439 (85.4%)	

\*P-value is for Wilcoxon rank-sum test for age and Chi-square or Fisher's exact test for categorical variables.

Table 2. Logistic regression results for echo screening result for all children before and after Lumify device.

	Unadjusted		Adjusted	
	OR (95% CI)	P-value*	OR (95% CI)	P-value*
Before Lumify device	Reference	<0.001	Reference	<0.001
After Lumify device	0.34 (0.28, 0.42)		0.25 (0.20, 0.31)	

\*Logistic regression models with and without adjustment for age and gender were used.

During the two-day in-field comparison, 202 children underwent screening ultrasounds. A total of 13 children had screen positive exams. An additional 5 children were randomly selected to have an ultrasound with both devices for a total of 19 children were included in the device comparison. All study ultrasounds contained adequate visualization of the mitral valve to assess for soft tissue and color Doppler abnormalities. All ultrasounds contained adequate imaging of the aortic valve. Four ultrasounds (3 M-turbo and 1 Lumify) contained inadequate color Doppler of the aortic valve by expert review secondary to imperfect capture of the aortic valve by the Doppler window.

When comparing non-expert to expert interpretation by device, the Lumify was more likely to be interpreted as screen negative ( $p=0.025$ , Table 4). We undertook a detailed evaluation of the three children in which non-expert interpretation was in agreement with the M-turbo but not the Lumify (Table 5). There were important differences between expert and non-expert interpretation of the color Doppler images which impacted the screen status. Review of the observed mitral regurgitation in these children demonstrated more subtle color Doppler findings when viewed using the Lumify device (Figure 2).

## Discussion

Introduction of a handheld ultrasound device into an active school-based RHD screening program in Ethiopia significantly decreased the number of screen-positive ultrasounds. Among a small-sample of adolescent children, our device comparison highlights important and measurable differences between the handheld Philips Lumify and the Sonosite M-Turbo. When comparing screen status by device, there was a statistically significant difference between expert and non-expert interpretation using the Lumify. Overall, mitral jets trended towards appearing shorter when viewed on the Lumify.

Single-view screening protocols for the detection of latent RHD are increasingly demonstrating strong sensitivity and specificity [21,24]. However, most studies to date have not evaluated the impact of handheld devices in the field. With the increasing availability and low cost of these devices, teams around the world have already started to employ modified versions of published single-view screening criteria [6]. While these efforts are needed to help realize the potential of population based screening for RHD, our study demonstrates that there are important differences between ultrasound devices

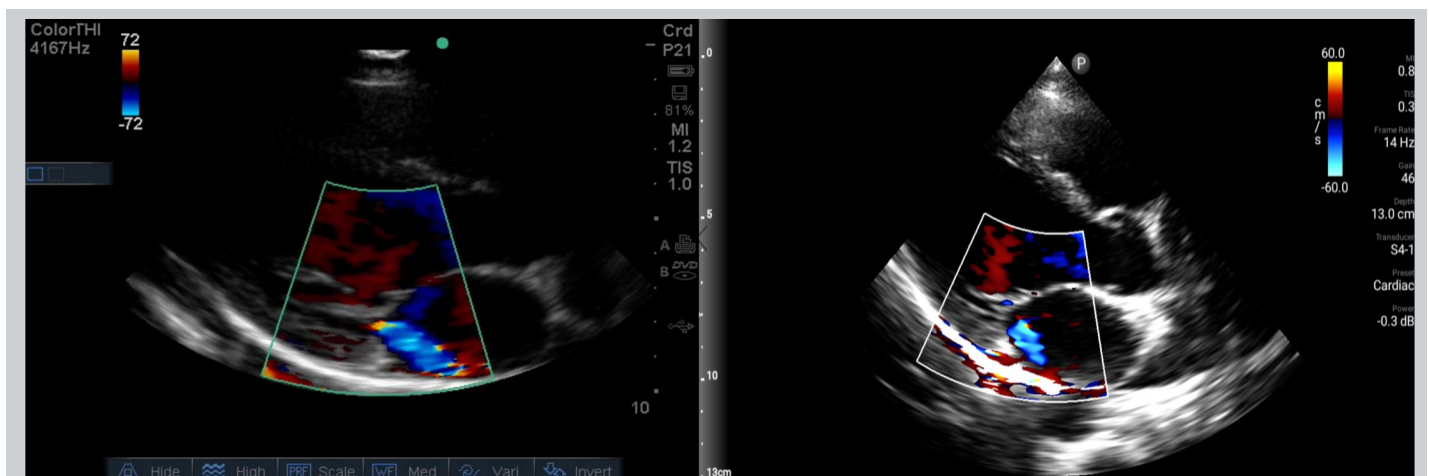


Figure 2. Side-by-side images from the same child illustrating the differential appearance of mitral regurgitation by color Doppler between the M-turbo (A) and the Lumify (B). These images represent the most abnormal jet from the respective video clips as determined by expert review.

Table 3. Summary of MR jet lengths as determined by color Doppler for those children who underwent confirmatory echocardiogram following device transition.

Variable	MR jet lengths before Lumify transition (N=291)	MR jet lengths after Lumify transition (N=167)	P-Value*
MR jet length, n (%)			
Did not receive confirmatory echocardiogram	6	25	<0.001
1-1.4 cm	51 (17.9%)	79 (55.6%)	
1.5-2 cm	229 (80.4%)	60 (42.3%)	
>2 cm	5 (1.8%)	3 (2.1%)	

\*P-value is for Fisher's exact test.

that may impact the rate of screen-positivity even when the screening protocol remains constant.

#### Limitations

Our study has many important limitations. While all images were captured by the same experienced pediatric cardiac sonographer, differences in image acquisition may explain some of the differences observed. Some differences are expected between expert and non-expert interpretation of echocardiograms for RHD screening [16,18,28,29]. However, it is notable that agreement regarding screen status on the M-turbo device was extremely high between reviewers with no case of screen-positive valvular regurgitation being missed by non-expert review suggesting that differences in appearance between the ultrasound devices explains the discordance in screen status. However, the careful and nuanced review as performed by study personnel may not accurately capture the more rapid in-field interpretation

done by the screening team which may favor referral, even for cases where the screening test does not meet rigorous criteria. Given the importance of mitral regurgitation in the early detection of RHD, we believe this trend is largely responsible for the observed change in screen-positive ultrasounds.

There are inherent differences between the devices. The Phillips Lumify has a fixed Nyquist limit of 60 cm/s whereas the Sonosite M-turbo can be adjusted. For the purposes of this study, the Nyquist limit on the M-turbo was set a 72 cm/s. The Nyquist limit on the M-turbo was not adjusted to minimize interruptions to the standard imaging settings already employed by the screening team. Interestingly, our observed trend towards lower jet lengths in the Lumify are not readily explained by the lower Nyquist limit as one would expect increased aliasing and artifact given the high velocities being observed [30]. Reducing the Nyquist limit in the M-turbo

Table 4. Comparison of screen status by reviewer for each device.

M-Turbo			
	Non-expert review positive	Non-expert review negative	P-value*
Expert review positive	5 (26.3%)	1 (5.3%)	0.317
Expert review negative	0 (0.0%)	13 (68.4%)	
Lumify			
	Non-expert review positive	Non-expert review negative	P-value*
Expert review positive	2 (10.5%)	5 (26.3%)	0.025
Expert review negative	0 (0.0%)	12 (63.2%)	

\*P-value is for McNemar's test for paired samples.

Table 5. Comparison of the mitral valve regurgitation in three children where there was disagreement in screen status between expert and non-expert review.

	Expert		Non-expert	
Device	M-Turbo	Lumify **	M-turbo	Lumify
<b>Child 1</b>				
Mitral jet length	1-1.5 cm	1-1.5 cm	1.5-2 cm	1.5-2 cm
Pansystolic	Yes	Yes	Yes	No
Eccentric	Yes	Yes	Yes	No
Multi-colored	No	Yes	Yes	Yes
Screen Positive	Yes	Yes	Yes	No
<b>Child 2</b>				
Mitral jet length	1.5-2 cm	1-1.5 cm	> 2 cm	< 1 cm
Pansystolic	Yes	Yes	Yes	No
Eccentric	Yes	Yes	Yes	No
Multicolored	Yes	Yes	Yes	No
Screen Positive	Yes	Yes	Yes	No
<b>Child 3*</b>				
Mitral jet length	1-1.5 cm	1-1.5 cm	1.5-2 cm	1-1.5 cm
Pansystolic	Yes	Yes	Yes	No
Eccentric	Yes	No	Yes	No
Multicolored	Yes	No	Yes	No
Screen positive	Yes	Yes	Yes	No

\* Child 3: On Lumify device, thickening was noted on the mitral valve but not seen on corresponding M-turbo image for expert review. \*\* Lumify: Color Doppler Frame rates varied per child: 1. 17 Hz., 2. 14 Hz., 3. 15 Hz.

would have exacerbated the observed discrepancies in jet length which suggest the jet length discrepancy is related to other factors.

Most importantly, we report primarily on the impact of the handheld device on the rate of screen-positivity from the schools. As described, all children with a screen-positive exam were referred for a confirmatory echocardiogram using a modified version of the WHF criteria. Complete confirmatory results were not available for all children but we did observe a significant change in the distribution of MR as estimated by color Doppler. Our team has since developed a more complete and accurate process of capturing the complete results of the confirmatory echocardiograms. However, the lower number of referrals with a smaller number of intermediate jet

lengths does imply a higher degree of specificity. How the Lumify device may have impacted sensitivity and this important question is not well answered by this study. Rigorous studies evaluating non-expert ultra sonographers typically show a high-degree of sensitivity with most limitations found in the specificity. However, recent work by others in the field using a similar handheld device have also found that programs may need to consider impacts that are device specific [31]. Our observed change in screen-positivity appeared to persist even after controlling for important confounding variables such as age and gender. Ongoing quality improvement monitoring within our program is notable for extremely rare falsely negative screening echocardiograms with increasing specificity noted overtime which is an important source of confounding.

However, when analyzed by school, there was an abrupt change in the screen-positive rate. Sequential improvement in screener sensitivity would likely have been observed to occur over a longer and more gradual period of time. It is important to note that the distribution of public versus private schools varied across the time of device transition and may have impacted the rate of screen-positivity we observed. Our program also started in the center of town for ease of access by car. We then sequentially worked our way to the outskirts of town and then into the surrounding areas. The definitions of urban versus rural are challenging to define in this environment. Though all schools presented in this study were categorized as urban, many were located on the outskirts of town and still required rough travel by dirt roads and off-road vehicle.

### Conclusion

The differences observed in our study suggest that the thresholds used to determine the ideal positive screen may be influenced by unique and unpredictable performance characteristics of the ultrasound device being utilized. Our study highlights that the ideal criteria for determining a screen positive ultrasound may vary by ultrasound device as well as screener experience and skill. Criteria that move away from length based estimations of color Doppler jets and focus on other characteristics of pathological regurgitation seen in latent RHD may be preferable [24]. Even among expert cardiologists, length based estimations of mitral and aortic regurgitation are subject to variability when making a confirmatory diagnosis [32]. Until further evidence is available, the use of handheld devices for RHD screening should be approached cautiously to avoid missing cases that would otherwise be referred for confirmatory echocardiograms.

### Acknowledgments

We acknowledge the hard work of the RHD screening team and support staff of Soddo Christian Hospital.

### Disclosures

Zachary P. Kaltenborn received Funding for this project from the University of Minnesota Center for Global Health and Social Responsibility Faculty Travel Awards Program

Jonathan D Kirsch obtained the Philips Lumify used in this study through the University of Minnesota Foundation, Faculty Research and Equipment Grant, 2018

Research reported in this publication was supported by NIH grant P30 CA77598 utilizing the Biostatistics Core shared resource of the Masonic Cancer Center, University of Minnesota and by the National Center for

Advancing Translational Sciences of the National Institutes of Health Award Number UL1TR002494. The content is solely the responsibility of the authors and does not necessarily represent the official views of the National Institutes of Health.

### Conflicts of Interest

All authors have reviewed the above manuscript and attest that they have no financial or non-financial conflicts of interest.

### Ethical Approval and Consent to Participate

This study was reviewed and approved by the Institutional Review Board at the University of Minnesota and determined to be a non-human research subjects study (STUDY00008308). The IRB determined that the proposed activity is not research involving human subjects as defined by DHHS and FDA regulations. The RHD screening program is done in cooperation with local educational and health ministries. The consent process for participation in the screening program is described above and was not altered by this study.

### Availability of data and materials

All data generated or analyzed during this study are included in this published article and its supplementary information files.

### References

1. Watkins DA, Johnson CO, Colquhoun SM, et al. Global, Regional, and National Burden of Rheumatic Heart Disease, 1990-2015. *N Engl J Med.* 08 2017;377(8):713-722. doi:10.1056/NEJMoa1603693
2. Carapetis JR, Steer AC, Mulholland EK, Weber M. The global burden of group A streptococcal diseases. *Lancet Infect Dis.* Nov 2005;5(11):685-94. doi:10.1016/S1473-3099(05)70267-X
3. Marijon E, Ou P, Celermajer DS, et al. Prevalence of rheumatic heart disease detected by echocardiographic screening. *N Engl J Med.* Aug 2007;357(5):470-6. doi:10.1056/NEJMoa065085
4. Reményi B, Wilson N, Steer A, et al. World Heart Federation criteria for echocardiographic diagnosis of rheumatic heart disease--an evidence-based guideline. *Nat Rev Cardiol.* Feb 2012;9(5):297-309. doi:10.1038/nrcardio.2012.7
5. Yadeta D, Hailu A, Haileamlak A, et al. Prevalence of rheumatic heart disease among school children in Ethiopia: A multisite echocardiography-based screening. *Int J Cardiol.* Oct 2016;221:260-3. doi:10.1016/j.ijcard.2016.06.232
6. Ali S, Domi S, Abbo B, et al. Echocardiographic screening for rheumatic heart disease in 4 515 Sudanese school children: marked disparity between two communities. *Cardiovasc J Afr.* 2018 Sep/Oct 23 2018;29(5):273-277. doi:10.5830/CVJA-2018-022
7. Beaton A, Okello E, Lwabi P, Mondo C, McCarter R, Sable C. Echocardiography screening for rheumatic heart disease in Ugandan schoolchildren. *Circulation.* Jun 2012;125(25):3127-32. doi:10.1161/CIRCULATIONAHA.112.092312
8. Kane A, Mirabel M, Touré K, et al. Echocardiographic screening for rheumatic heart disease: age matters. *Int J Cardiol.* Sep 2013;168(2):888-91. doi:10.1016/j.ijcard.2012.10.090
9. Sims Sanyahumbi A, Sable CA, Beaton A, et al. School and Community Screening Shows Malawi, Africa, to Have a High Prevalence of Latent Rheumatic Heart Disease. *Congenit Heart Dis.* Dec 2016;11(6):615-621. doi:10.1111/chd.12353

10. Beaton A, Okello E, Rwebembera J, et al. Secondary Antibiotic Prophylaxis for Latent Rheumatic Heart Disease. *N Engl J Med*. Nov 2021;doi:10.1056/NEJMoa2102074
11. Hunter LD, Monaghan M, Lloyd G, Pecoraro AJK, Doubell AF, Herbst PG. Screening for rheumatic heart disease: is a paradigm shift required? *Echo Res Pract*. Dec 2017;4(4):R43-R52. doi:10.1530/ERP-17-0037
12. Dougherty S, Khorsandi M, Herbst P. Rheumatic heart disease screening: Current concepts and challenges. *Ann Pediatr Cardiol*. 2017 Jan-Apr 2017;10(1):39-49. doi:10.4103/0974-2069.197051
13. Beaton A, Lu JC, Aliku T, et al. The utility of handheld echocardiography for early rheumatic heart disease diagnosis: a field study. *Eur Heart J Cardiovasc Imaging*. May 2015;16(5):475-82. doi:10.1093/ehjci/jeu296
14. Carapetis JR, Zühlke LJ. Global research priorities in rheumatic fever and rheumatic heart disease. *Ann Pediatr Cardiol*. Jan 2011;4(1):4-12. doi:10.4103/0974-2069.79616
15. Campbell J DG, Buchan J, Pozo-Martin F, Guerra Arias M, Leone C, Siyam A, Cometto G. A universal truth: no health without a workforce. 2013.
16. Ploutz M, Lu JC, Scheel J, et al. Handheld echocardiographic screening for rheumatic heart disease by non-experts. *Heart*. Jan 2016;102(1):35-9. doi:10.1136/heartjnl-2015-308236
17. Mirabel M, Bacquelin R, Tafflet M, et al. Screening for rheumatic heart disease: evaluation of a focused cardiac ultrasound approach. *Circ Cardiovasc Imaging*. Jan 2015;8(1)doi:10.1161/CIRCIMAGING.114.002324
18. Engelman D, Kado JH, Reményi B, et al. Focused cardiac ultrasound screening for rheumatic heart disease by briefly trained health workers: a study of diagnostic accuracy. *Lancet Glob Health*. 06 2016;4(6):e386-94. doi:10.1016/S2214-109X(16)30065-1
19. Beaton A, Nascimento BR, Diamantino AC, et al. Efficacy of a Standardized Computer-Based Training Curriculum to Teach Echocardiographic Identification of Rheumatic Heart Disease to Nonexpert Users. *Am J Cardiol*. 06 2016;117(11):1783-9. doi:10.1016/j.amjcard.2016.03.006
20. Zühlke LJ, Engel ME, Nkepu S, Mayosi BM. Evaluation of a focussed protocol for hand-held echocardiography and computer-assisted auscultation in detecting latent rheumatic heart disease in scholars. *Cardiol Young*. Aug 2016;26(6):1097-106. doi:10.1017/S1047951115001857
21. Diamantino A, Beaton A, Aliku T, et al. A focussed single-view hand-held echocardiography protocol for the detection of rheumatic heart disease. *Cardiol Young*. 01 2018;28(1):108-117. doi:10.1017/S1047951117001676
22. Lu JC, Sable C, Ensing GJ, et al. Simplified rheumatic heart disease screening criteria for handheld echocardiography. *J Am Soc Echocardiogr*. Apr 2015;28(4):463-9. doi:10.1016/j.echo.2015.01.001
23. Johannsen RA, Kaltenborn ZP, Shroff GR. Saving time saves lives! A time focused evaluation of a single-view echocardiographic screening protocol for subclinical rheumatic heart disease. *Int J Cardiol*. Dec 20 2021;doi:10.1016/j.ijcard.2021.12.031
24. Remenyi B, Davis K, Draper A, et al. Single Parasternal-Long-Axis-View-Sweep Screening Echocardiographic Protocol to Detect Rheumatic Heart Disease: A Prospective Study of Diagnostic Accuracy. *Heart Lung Circ*. Jun 2019;doi:10.1016/j.hlc.2019.02.196
25. Nunes MCP, Sable C, Nascimento BR, et al. Simplified Echocardiography Screening Criteria for Diagnosing and Predicting Progression of Latent Rheumatic Heart Disease. *Circ Cardiovasc Imaging*. Feb 2019;12(2):e007928. doi:10.1161/CIRCIMAGING.118.007928
26. Francis JR, Whalley GA, Kaethner A, et al. Single-View Echocardiography by Nonexpert Practitioners to Detect Rheumatic Heart Disease: A Prospective Study of Diagnostic Accuracy. *Circulation: Cardiovascular Imaging*. 2021-08-01 2021;14(8) doi:10.1161/circimaging.120.011790
27. Harris PA, Taylor R, Thielke R, Payne J, Gonzalez N, Conde JG. Research electronic data capture (REDCap)--a metadata-driven methodology and workflow process for providing translational research informatics support. *J Biomed Inform*. Apr 2009;42(2):377-81. doi:10.1016/j.jbi.2008.08.010
28. Nascimento BR, Beaton AZ, Nunes MC, et al. Echocardiographic prevalence of rheumatic heart disease in Brazilian schoolchildren: Data from the PROVAR study. *Int J Cardiol*. Sep 2016;219:439-45. doi:10.1016/j.ijcard.2016.06.088
29. Engelman D, Kado JH, Reményi B, et al. Screening for rheumatic heart disease: quality and agreement of focused cardiac ultrasound by briefly trained health workers. *BMC Cardiovasc Disord*. Feb 2016;16:30. doi:10.1186/s12872-016-0205-7
30. McCulloch M, Cleve J. Echocardiography. Chapter 3: Machine Controls and Optimizing images. Second ed. Springer, Cham; 2018.
31. Francis JR, Whalley GA, Kaethner A, et al. Single-View Echocardiography by Nonexpert Practitioners to Detect Rheumatic Heart Disease: A Prospective Study of Diagnostic Accuracy. *Circ Cardiovasc Imaging*. Aug 2021;14(8):e011790. doi:10.1161/CIRCIMAGING.120.011790
32. Scheel A, Mirabel M, Nunes MCP, et al. The inter-rater reliability and individual reviewer performance of the 2012 world heart federation guidelines for the echocardiographic diagnosis of latent rheumatic heart disease. *Int J Cardiol*. Apr 01 2021;328:146-151. doi:10.1016/j.ijcard.2020.11.013

# Critical Care Ultrasound Competency of Fellows and Faculty in Pulmonary and Critical Care Medicine: A Nationwide Survey

Mark H Adelman, MD<sup>1</sup>; Himanshu Deshwal, MD<sup>2</sup>; Deepak Pradhan, MD, MHPE, FCCP, ATSF<sup>3\*</sup>

- (1) Division of Pulmonary, Critical Care & Sleep Medicine, New York University Grossman School of Medicine, New York, NY, USA
- (2) Division of Pulmonary, Critical Care, and Sleep Medicine, West Virginia University Health Sciences Center, Morgantown, WV, USA

## Abstract

**Purpose:** Competency assessment standards for Critical Care Ultrasonography (CCUS) for Graduate Medical Education (GME) trainees in pulmonary/critical care medicine (PCCM) fellowship programs are lacking. We sought to answer the following research questions: How are PCCM fellows and teaching faculty assessed for CCUS competency? Which CCUS teaching methods are perceived as most effective by program directors (PDs) and fellows. **Methods:** Cross-sectional, nationwide, electronic survey of PCCM PDs and fellows in accredited GME training programs. **Results:** PDs and fellows both reported the highest rates of fellow competence to use CCUS for invasive procedural guidance, but lower rates for assessment of deep vein thrombosis and abdominal organs. 54% and 90% of PDs reported never assessing fellows or teaching faculty for CCUS competency, respectively. PDs and fellows perceived hands-on workshops and directly supervised CCUS exams as more effective learning methods than unsupervised CCUS archival with subsequent review and self-directed learning. **Conclusions:** There is substantial variation in CCUS competency assessment among PCCM fellows and teaching faculty nationwide. The majority of training programs do not formally assess fellows or teaching faculty for CCUS competence. Guidelines are needed to formulate standardized competency assessment tools for PCCM fellowship programs.

## Background

Goal-directed critical care ultrasound (CCUS) has become a necessary skill set for clinicians managing critically ill patients. The Accreditation Council for Graduate Medical Education (ACGME) includes CCUS among the core procedural requirements specifically for trainees in anesthesia and emergency medicine residencies [1,2]. However, the Program Requirements for ACGME-accredited pulmonary and critical care medicine (PCCM) fellowships are less specific and more limited in scope [3]. The ACGME requires that trainees demonstrate competence in the use of ultrasound to guide invasive procedures, and knowledge of imaging techniques that are used to evaluate pulmonary disease and critical illness, including ultrasound, but does not specify further which specific CCUS exams should be learned, how bedside CCUS exams should be supervised, nor how competency should be assessed. Several international pulmonary and critical care societies have since provided detailed guidelines and expectations

in achieving competency in CCUS that have not been uniformly adopted across training programs [4-6]. These guidelines are based on expert consensus as there is little evidence on which to base recommendations currently.

Previous surveys of pulmonary and critical care medicine program directors demonstrated a heavy emphasis on informal bedside teaching of ultrasonography skills despite low reported levels of CCUS competency among faculty (i.e. PCCM attendings that routinely work and train fellows in the workplace setting) [7,8]. There currently exists a knowledge gap in the literature in the following areas of CCUS competency in PCCM training programs: identifying the effectiveness of commonly utilized teaching methods for CCUS; the specific assessment tools by which training programs assess for competency in CCUS; and the frequency with which these assessments occur during fellowship training [9]. Additionally, little is known about methods being used to assess CCUS competency of teaching faculty in PCCM.

---

\*Corresponding Author: Dr. Deepak Pradhan (email: [deepak.pradhan@nyulangone.org](mailto:deepak.pradhan@nyulangone.org))

This work is licensed under a [Creative Commons Attribution 4.0 International License](https://creativecommons.org/licenses/by/4.0/).

Author(s) retain the copyright for their work. At the time of submission to POCUS Journal the author(s) grant the journal a limited and non revokable right to publish in the Journal under a [Creative Commons Attribution 4.0 International License](https://creativecommons.org/licenses/by/4.0/).

DOI: <https://doi.org/10.24908/pocus.v8i2.16640>



Better understanding of these gaps will allow for more transparency among pulmonary-critical care fellowship training programs regarding CCUS competency assessment of fellows and faculty, and allow for better standardization among programs nationwide. Our objectives were to investigate perceptions and methods utilized by fellows and teaching faculty in U.S. training programs to achieve and assess competency in CCUS.

## Methods

This study was approved by the New York University Grossman School of Medicine (NYUGSOM) Institutional Review Board (s18-00282). We conducted two cross-sectional surveys on CCUS competency from September to December of 2018: a survey of ACGME-accredited PCCM fellowship program directors or their designees, and a survey of PCCM fellows in ACGME-accredited programs.

Surveys were designed through an iterative process of development that incorporated feedback from three groups at our institution: faculty experts in CCUS, PCCM fellowship program key clinical faculty, and senior PCCM fellows. The surveys were distributed via email to 148 PCCM fellowship program directors in the U.S. and Canada by the Association of Pulmonary and Critical Care Medicine Program Directors (APCCMPD). We asked PDs or their designee to complete the online PD survey, and forward a link to a second online survey to their fellows. We sent follow-up emails once a month for two months.

The PD survey asked questions regarding methods used to teach CCUS to their fellows and their perceived effectiveness, perceived CCUS competency of their fellows and their teaching faculty that work with their fellows, and methods used to assess CCUS competency of their fellows and teaching faculty (see Appendix A for full PD survey). The Fellows survey asked questions regarding methods used to learn CCUS and their perceived effectiveness, their performance numbers of CCUS examinations, their perceived CCUS competency, and methods of CCUS competency assessment used by their programs (see Appendix B for full Fellows survey). Both surveys captured basic demographic information about respondents and training programs. Survey responses were anonymous and no personally identifiable information was collected. Survey study data was collected and managed using REDCap® (Research Electronic Data Capture) electronic data capture tools hosted at NYU Grossman School of Medicine [10,11]. We analyzed survey responses with IBM SPSS Statistics for Macintosh (Version 27.0, Armonk, NY) using descriptive statistics [12].

## Results

### *Program Director and Fellow Surveys: Demographics*

Forty program directors completed the PD survey (response rate of 27% of all programs); the total number of fellows that received survey invitations is unknown and a response rate cannot be definitively calculated but we estimated a response rate of 18%. Program and fellow

*Table 1. Fellowship Program and Fellow Demographics*

	From PD Survey (n, %)	From Fellows Survey (n, %)
<b>Program Type</b>		
Combined Pulmonary/Critical Care Medicine	36 (90%)	95 (86%)
Critical Care Medicine only	4 (10%)	16 (14%)
<b>Program Setting</b>		
Academic (University-based) Hospital	35 (88%)	87 (78%)
Community (University-affiliated) Hospital	5 (13%)	20 (18%)
Community Hospital	0 (0%)	4 (4%)
<b>Size of Fellowship</b>		
1-5 Fellows	5 (13%)	10 (9%)
6-15 Fellows	26 (65%)	67 (60%)
>15 Fellows	9 (23%)	34 (31%)
<b>Year of Fellowship</b>		
First year		38 (34%)
Second year		43 (39%)
Third year		25 (23%)
Fourth year or greater		5 (5%)

*Values shown as number of and percentage of respondents*

demographics are described in Table 1. The vast majority were combined PCCM fellowship programs (90% on PD survey, 86% on fellow survey), academic (88%, 78%), and moderately sized (6-15 fellows, 65%, 60%). Responding fellows represented a spectrum of training years (1st year—34%, 2nd year—39%, 3rd year—23%, 4th year—5%).

#### *Program Director and Fellow Surveys: Perceived Faculty Competence*

The majority of PDs thought the vast majority (76-100%) of their faculty were competent to perform US-guided vascular access (62%) and US-guided drainage catheter placement (64%). The majority of PDs (59%) felt that the majority or vast majority (51%-100%) were competent in lung/pleural US. However, only a minority of PDs believed that the majority or vast majority (51%-100%) of their faculty were competent in goal-directed cardiac echo (36% of PDs), abdominal/kidney US (23%), and lower extremity DVT studies (18%).

We also performed a sub-analysis to explore if PD's perception of faculty CCUS competence correlated with their perception of fellow CCUS competence and the strength of that correlation. Spearman's rank correlation was computed to assess the relationship between PD's perception of faculty competence and fellow competence for the 5 different CCUS examinations. There was a

statistically significant positive correlation for goal-directed echo,  $r(38) = [0.436]$ ,  $p=0.006$ ; and DVT studies,  $r(38) = [0.624]$ ,  $p < 0.001$ . It was not statistically significant for US-guided vascular access ( $p=0.05$ ), US-guided drainage catheter placement ( $p=0.271$ ), or lung/pleural US ( $p=0.089$ ).

#### *Methods of Teaching and Learning CCUS, and Number of CCUS Exams Performed by Fellows*

Methods of teaching and learning CCUS and their perceived effectiveness are documented in Table 2. Utilized methods of teaching CCUS (PD survey) and methods of learning CCUS (Fellow survey) were similar for the two surveys--local lecture-based teaching (88%, 74% respectively), directly supervised bedside CCUS exams with feedback (85%, 74%), local hands-on workshops (73%, 69%), and self-directed learning (70%, 77%). Slightly lesser use included regional/national courses (58%, 48%), case-based didactics (65%, 52%), and unsupervised archival of images with subsequent review for teaching (60%, 51%). PD and Fellow perceptions of usefulness for these different teaching/learning methods were similar. Percentage of PDs and Fellows that perceived the different teaching/learning methods as "very" or "extremely useful" on 5-point Likert scale were: hands-on local workshops (100% of PDs, 83% of fellows), directly supervised bedside CCUS

*Table 2. Methods of Teaching and Learning CCUS.*

	From PD Survey (n, %)	From Fellows Survey (n, %)	From PD Survey (n, %)	From Fellows Survey (n, %)
<b>Teaching and Learning Method</b>	Utilized by Programs to Teach CCUS (n, %)	Utilized by Fellows to Learn CCUS (n, %)	PD Perceived "Very" to "Extremely Useful" (n, %)*	Fellow Perceived "Very" to "Extremely Useful" (n, %)*
Regional/national courses	23 (58%)	53 (48%)	17 (70%)	47 (89%)
Lectures at your institution	35 (88%)	82 (74%)	19 (60%)	46 (57%)
Case-based conferences at your institution	26 (65%)	58 (52%)	19 (70%)	34 (59%)
Hands-on workshops at your institution	29 (73%)	77 (69%)	29 (100%)	63 (83%)
Directly supervised bedside CCUS exams	34 (85%)	82 (74%)	31 (90%)	77 (94%)
Unsupervised CCUS exams with saved images and subsequent review	24 (60%)	57 (51%)	17 (43%)	29 (51%)
Self-directed learning	28 (70%)	85 (77%)	9 (30%)	41 (49%)
Other (blogs, US/echo tech rotation, simulation, US elective)	4 (10%)	2 (2%)	N/A	N/A

*5-point Usefulness scale (1= Useless, 2= Not Very Useful, 3= Somewhat Useful, 4= Very Useful, 5= Extremely Useful); values shown as number of and percentage of respondents;*

*\*Percentage calculation--Numerator reflects number of respondents reporting "Very" or "Extremely Useful", and denominator reflects number of respondents actually utilizing the teaching/learning method.*

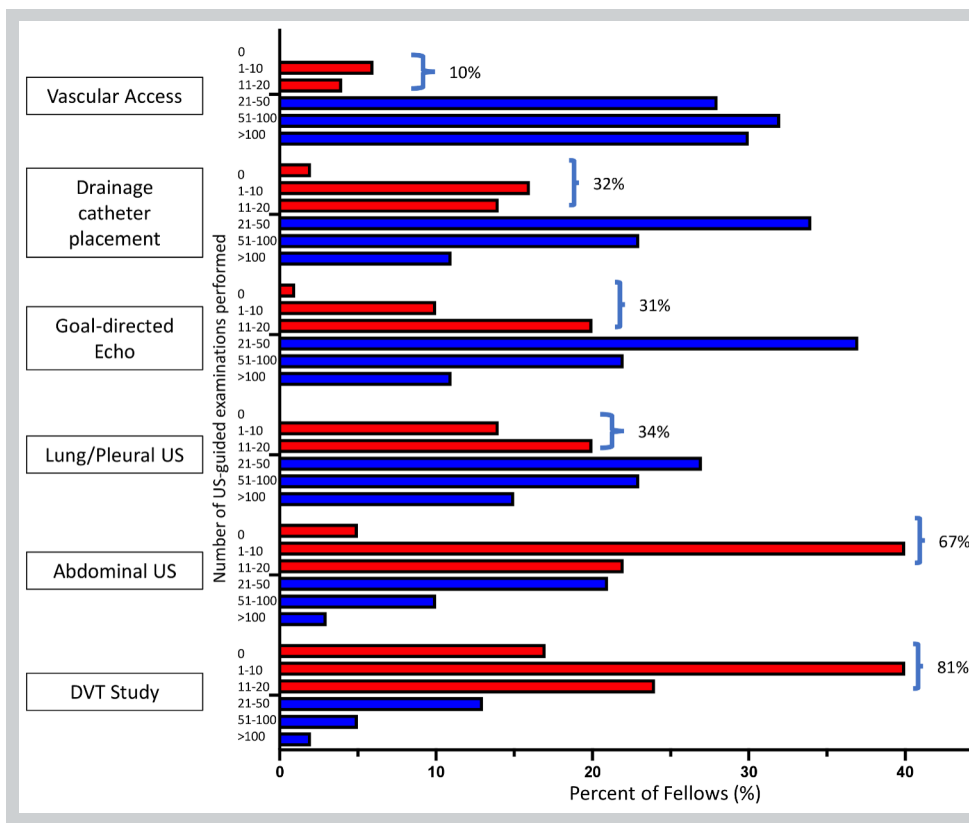


Figure 1. Reported Number of Each CCUS Examination Performed by Fellows Over the Course of Fellowship Training.

Fellows were asked the number of each CCUS examination (US-guided vascular access, US-guided drainage catheter placement, goal-directed echocardiogram, lung/pleural US, abdominal US, and DVT study) that they had performed during their fellowship. Results are displayed in bar graph format with X-axis representing the percentage of fellows (%), and the Y-axis the number of each examination performed. Percentage of fellows performing 20 exams or fewer varied by specific CCUS exam— 10% for vascular access, 32% drainage catheter placement, 31% goal-directed Echo, 34% lung/pleural US, 67% abdominal US, and 81% DVT study.

exams with feedback (90%, 94%), regional/national courses (70%, 89%), local lectures (60%, 57%), local case-based conferences (70%, 59%); unsupervised CCUS with archival of images and subsequent review (43%, 51%) and self-directed learning (30%, 49%) were rated as less useful.

Number of each CCUS examination performed by fellows over their fellowship is displayed in Figure 1. Percentage of fellows performing greater than 20 examinations varied by specific CCUS examination type: 90% for US-guided vascular access, 68% for US-guided drainage catheter placement, 69% for goal-directed echocardiography, 66% for lung/pleural US, 33% for abdominal US, and 19% for DVT studies.

#### *Program Director and Fellow Surveys: Methods of Assessing Fellow and Faculty CCUS Competency*

Methods of assessing fellows for CCUS competency are detailed in Table 3. The majority of PDs (54%) report never formally assessing fellows for CCUS competency, and the majority of fellows (67%) also reported never receiving formal competency assessment. Of the programs that do assess their fellows for CCUS competency, the most used method was global assessment by expert faculty (67% on PD survey, 70% on fellow survey). Half of PDs who engage in fellow CCUS assessments reported using formal review of

archived real patient images, practical exam on real patients, and use of a standardized assessment tool. However, fellows report all methods other than global assessment by faculty to be used in the minority of their programs. Of the programs that do assess their fellows for CCUS competency, the specific CCUS exams being tested varied: procedural guidance 61% use on PD survey and 46% use on fellow survey; goal-directed Echo 78% and 62% respectively; lung/pleural US 67% and 59%; abdominal/kidney US 33% and 38%, and lower extremity DVT study 50% and 35% respectively.

Ninety percent of PDs reported never assessing their teaching faculty for competence in performing CCUS examinations, and 8% did so only pre-employment. Given the very low prevalence of faculty competency assessment in general, data on methods of assessing faculty competence or specific examinations being assessed were deemed too small to draw conclusions and thus not reported.

Regarding the documentation of CCUS competency, only 28% of PDs and 7% of fellows reported having a requirement for completion of a designated number of CCUS examinations prior to fellowship graduation, and only a small minority utilize an electronic portfolio to save their clips and images (18% per PDs and 6% per fellows).

Table 3: Assessing CCUS Competency

	PD Survey		Fellow Survey
	Fellows (n, %)	Teaching Faculty (n, %)	Fellows (n, %)
<b>Frequency of formal CCUS competency assessments (n= 39 for PD survey; n= 111 for Fellow survey)</b>			
More than once a year	7 (18%)	N/A	14 (13%)
Every year	7 (18%)	N/A	19 (17%)
Once at the end of training	4 (10%)	N/A	4 (4%)
Pre-employment	N/A	3 (8%)	N/A
More than once, but not yearly	N/A	1 (3%)	N/A
Never	21 (54%)	35 (90%)	74 (67%)
<b>Methods of assessing CCUS competency* (n= 18 for PD survey; n= 37 for Fellow survey)</b>			
Global assessment by expert faculty	12 (67%)		26 (70%)
Multiple-choice question exam	5 (28%)		12 (32%)
Formal review of archived real patient images	9 (50%)		11 (30%)
Practical exam on mannequin/simulator	5 (28%)		3 (8%)
Practical exam on standardized patient	5 (28%)		8 (22%)
Practical exam on real patient (s)	9 (50%)		8 (22%)
Use of a standardized assessment tool	9 (50%)		12 (32%)
<b>Formal assessment by specific CCUS Exam type* (n= 18 for PD survey; n= 37 for Fellow survey)</b>			
Procedural guidance	11 (61%)		17 (46%)
Goal-directed Echo	14 (78%)		23 (62%)
Lung/Pleural US	12 (67%)		22 (59%)
Abdominal/Kidney US	6 (33%)		14 (38%)
Lower extremity DVT Study	9 (50%)		13 (35%)
<b>Documenting CCUS competency (n= 39 for PD survey; n= 111 for Fellow survey)</b>			
Use of an electronic portfolio of clips/images	7 (18%)		7 (6%)
Required number of exams prior to fellowship completion	11 (28%)		8 (7%)

Values shown as number of and percentage of fellowship programs and fellows

\*Faculty numbers too low to report (given scarcity of programs assessing their faculty)

Table 4. Percentage of Fellows and Teaching Faculty Perceived Competent to Independently Perform CCUS Exams.

CCUS Examination or Procedure	From PD Survey (n=40)						From Fellow Survey (n=111)			
	Vast majority [76-100%] (n, %)	Majority [51-75%] (n, %)	Less than Half [26-50%] (n, %)	Minority [1-25%] (n, %)	None [0%] (n, %)	Perceived Competency ("Agree" or "Strongly Agree")				
						All fellows (n=111)	1st-year fellows (n=38)	2nd-year fellows (n=43)	3rd-year or greater fellows (n=30)	
Vascular access (CVL, A-line)	Fellow	37 (97%)	1 (3%)	0 (0%)	0 (0%)	0 (0%)	110 (99%)	37 (97%)	43 (100%)	30 (100%)
	Faculty	24 (62%)	7 (18%)	5 (13%)	2 (5%)	1 (3%)				
Drainage catheter placement (thora, para, chest tube)	Fellow	37 (97%)	1 (3%)	0 (0%)	0 (0%)	0 (0%)	109 (98%)	36 (95%)	43 (100%)	30 (100%)
	Faculty	25 (64%)	2 (5%)	7 (18%)	5 (13%)	0 (0%)				
Goal-directed Echocardiography	Fellow	18 (47%)	15 (40%)	3 (8%)	1 (3%)	1 (3%)	86 (77%)	25 (66%)	34 (79%)	27 (90%)
	Faculty	4 (10%)	10 (26%)	16 (41%)	7 (18%)	2 (5%)				
Lung/Pleural US	Fellow	27 (71%)	10 (26%)	1 (3%)	0 (0%)	0 (0%)	95 (86%)	26 (68%)	39 (91%)	30 (100%)
	Faculty	9 (23%)	14 (36%)	12 (31%)	4 (10%)	0 (0%)				
Abdominal and kidney US	Fellow	10 (26%)	9 (24%)	7 (18%)	10 (26%)	2 (5%)	49 (44%)	16 (42%)	20 (47%)	13 (43%)
	Faculty	2 (5%)	7 (18%)	9 (23%)	17 (44%)	4 (10%)				
Lower Extremity DVT study	Fellow	14 (37%)	6 (16%)	7 (18%)	8 (21%)	3 (8%)	56 (50%)	16 (42%)	24 (56%)	16 (53%)
	Faculty	2 (5%)	5 (13%)	11 (28%)	17 (44%)	4 (10%)				

Values shown as number of and percentage of respondents; Ordinal categories of "Vast majority" to "None" refer to the percent of fellows or teaching faculty competent within that training program; 5-point Agreement scale (1= Strongly disagree, 2= Disagree, 3= Neither agree nor disagree, 4= Agree, 5= Strongly agree)

### *Program Director and Fellow Surveys: Perceived Fellow Competence*

Table 4 details the percentage of fellows at a given fellowship program who attain competency to independently perform basic CCUS examinations by the end of fellowship training, as well as percentage of teaching pulmonary and/or critical care faculty at a given institution currently competent to perform these same CCUS exams.

The percentage of PDs that believed the vast majority (76-100%) of their fellows attain competence varied by the specific CCUS examination type—very high perceived percentage of competence for vascular access and drainage catheter placement (97% of PDs for both), moderately perceived percentage of competence for lung/pleural US (71%), and lesser perceived percentage of competence for goal-directed echocardiography (47%), lower extremity DVT study (37%), and abdominal/kidney US (26%). Fellows' perceptions generally agreed with PD competency perceptions for vascular access and drainage catheter placement, with fellows agreeing or strongly agreeing in their competence (99% and 98% respectively for these two procedural exams), as well as for lung/pleural exam (86% agreement with competence) and lesser perceived competence in DVT studies (50%) and abdominal/kidney US (44%). However, fellows perceived their competence higher for goal-directed echo (77% agree or strongly agree with competence) compared with PD perceptions. Breaking down fellow perceived competency by year of training, all years reported high perceived competency in US-guided vascular access (97%, 100%, 100% for 1st, 2nd, and 3rd year fellows respectively) and US-guided drainage catheter placement (95%, 100%, 100% respectively). A stepwise pattern of increasing perceived competency was seen for goal-directed Echo (66%, 79%, 90% respectively) and lung/pleural US (68%, 91%, 100%). However, rates of competence by year remained relatively flat/plateaued regardless of year of training for abdominal US (42%, 47%, 43% respectively) and DVT study (42%, 56%, 53% respectively).

### **Discussion**

CCUS is a complex skill that combines cognitive knowledge along with psychomotor image acquisition skills and affective attitudes, and has become essential in daily practice for intensivists at the bedside [5]. As such, in the era of competency-based medical education, it is important for medical educators to assess successful learning of this complex skill by their trainees, the ability to transfer this skill into the workplace environment, and be entrusted for independent practice [13,14]. Assessment provides transparency and a shared mental

model for both teachers and learners of expectations for skills and abilities, allows for tailored learning plans dependent on skill progression, and drives learning through formative feedback [15]. Unfortunately, the field of assessment in CCUS is in its relative infancy of development, with several deficiencies in standardized guidelines for longitudinal competency assessment [16]. A recent systematic review found little high-quality evidence on longitudinal CCUS competence in the literature, with only 8 studies rated as “good” or “excellent” in methodologic quality and over 34 studies rated as “average” or “poor” among the 42 included studies, highlighting the need for increased and improved quality of research regarding CCUS competency [17].

Prior surveys of PCCM faculty and trainees have demonstrated heterogeneous institutional practices and methodologies to assess competency [18-20]. Our study highlights important details of these methodologies and some general trends among U.S. fellowship programs including university-based, university-affiliated, and community-based hospital programs. We found general agreement between program directors and fellows regarding perceived high competency to perform CCUS for procedural guidance and lung/pleural ultrasound and perceived lower competency to perform CCUS for DVT studies and abdominal ultrasound. We saw a stepwise, incremental increase in perceived competency based on year of fellowship for goal-directed echo and lung/pleural ultrasound, high competency in procedural US throughout the years, and sustained low competence in DVT studies and abdominal ultrasound, suggesting learning curves and need for more programmatic focuses on DVT studies and abdominal ultrasound throughout all years of training.

Interestingly, these levels of perceived competence were mirrored by fellow-reported experience with the different CCUS examinations, as most fellows reported greater experience with US-guided placement of vascular access devices or drainage catheters (e.g. thoracentesis, tube thoracostomy, paracentesis), goal-directed echocardiography and lung/pleura assessment but less abdominal and DVT ultrasound experience. About half of fellows reported performing fewer than 10 abdominal or DVT ultrasounds. ACCP/SRLF expert consensus guidelines do not specify the number of each US examination type recommended for CCUS competence [4]. However, Canadian CCUS guidelines recommend at least 20 lung/pleural, 25 abdominal, and 25 vascular diagnostic ultrasound exams, and Canadian guidelines along with the European Society of Intensive Care Medicine (ESICM) guidelines recommend at least 30 TTEs for competence [25,6]. Thus, while the number of CCUS studies needed for competence is uncertain, it is

clear from Figure 1 that a large number of fellows in the survey were performing fewer abdominal and DVT studies than recommended for competence.

A survey of 67 surgical critical care fellowship program directors reported the following exams as “very important”—FAST exam (75%), central venous access (80%), transthoracic echo (47%), DVT study (3%), and abdominal US for biliary pathology (1.5%) [21]. These findings further highlight the lack of valuation of DVT studies and non-procedural abdominal US examinations in critical care training programs.

Regarding CCUS competency assessment, we found in this study 54% of PDs and 67% of fellows reported that their programs never conduct formal competency assessments for CCUS. Among the programs that reported conducting formal assessments, a global assessment by expert faculty was the most common method cited by both PDs and fellows. Among those programs that do formally assess their fellows, the majority do not test specifically for competency in DVT studies or abdominal ultrasound. Additionally, there is a lack of use of archival review with feedback as well as development of ultrasound portfolios. Prior studies have documented the issue of poor faculty competence in CCUS as a barrier to training [7-9], and our study adds to our understanding the additional problem of paucity of faculty assessment in CCUS, as the vast majority (90%) of PDs reported never assessing their teaching faculty for CCUS competency.

Given the lack of formal assessment of CCUS competency of faculty, it is uncertain what information or data PDs used to answer our survey questions on faculty competence— institutional delineation of privileges, direct observation, gestalt, or other. Of note, we saw a correlation with PD perception of faculty CCUS competency with their perception of fellow CCUS competency for goal-directed echo (moderate correlation) and DVT studies (strong correlation). This is of uncertain significance, as it could reflect causality (competence of one group leading to competence of the other group through improved educational environment and community of practice), or could represent PD’s inability to differentiate fellow from faculty competence due to lack of tangible metrics for the latter. Future studies to better understand the relationship between fellow and teaching faculty CCUS competency are warranted.

PDs and fellows agreed on preferred methodologies for learning CCUS. Both groups reported that regional/national ultrasound courses, hands-on institutional workshops and directly supervised bedside CCUS exams were their most preferred approaches to learning CCUS,

reinforcing concepts of learning through active processes. Regional CCUS courses including hands-on workshops with expert faculty have been found to be feasible and efficient in providing much needed hands-on training in CCUS [22]. Although introductory CCUS courses have become ubiquitous and are attractive for time-constrained faculty development, it must be cautioned that the vast majority (93% in one study) of physicians engaging in such primer courses do not achieve sustained competence [23], and thus the focus should be on longitudinal programs for sustained competence.

Unsupervised CCUS exams, self-directed learning and lecture-based teaching were the least favored approaches to CCUS education. Brady et al. had determined through their 20-item survey of PCCM program directors that the most common method of learning CCUS was in fact unsupervised, independent bedside learning [9]. Rajamani et al., in their multi-center, global study of 99 ICUs found that only 5.1% of centers provided a structured CCUS competence program for their trainees, and nearly 20.2% allowed trainees to perform unsupervised scans for clinical management without assessment of any competency. They also reported that nineteen intensivists perceived diagnostic or management errors due to misinterpretation of echocardiographic findings [24], thus cautioning against the notion that utilizing CCUS without documented competency is without potential for harm.

#### *Strengths and Limitations*

Our survey has several strengths and limitations. Unlike previous studies, our survey included perceptions of both program directors and fellows and found a general agreement on most topics. Our findings on the perceptions of program directors with respect to the competency of clinical teaching faculty to perform CCUS have not been described previously. The major limitation of our study was the small sample size compared to all PCCM training programs which could introduce selection bias and limit the overall generalizability to all current practices. However, the consistent data from both fellows and faculty does help with overall validity of the themes that emerged from the results, and the heterogeneous distribution of academic and affiliated hospitals improves the generalizability of the findings. However, given the small sample size of this study, we would caution that the results should be viewed as intriguing but ultimately hypothesis-generating and in need of future targeted studies to expand upon this work. Also, as this is a cross-sectional survey, there could be recall biases from the PD or fellow respondents. As stated above, it is uncertain what information PDs used particularly for faculty

competence given the overall lack of faculty assessment. We also relied on PDs to forward a survey link to their fellows, introducing another element of potential sampling bias to fellow responses as there was a potential gatekeeper deciding to forward or not the survey to their fellows. Thus the assumption we made is that the responding PDs and fellows likely represent the same training programs, and thus the aggregate data is representative of the same training programs. This assumption is bolstered by the Demographic information detailed in Table 1 which shows very similar PD and Fellow survey demographics (for program type, setting, and size of fellowship). However, as the data collected were anonymous, we expect the fellows to have been truthful and accurate in their responses. Lastly, given the anonymous nature of the data collection, we were able only to carry out analyses in aggregate, but unable to carry out detailed analyses of associations between PD and fellow responses from the same program.

### *Future Directions*

Our survey lays a foundation for future directions in the applicability and training of CCUS in clinical practice. Our exploratory analysis suggests that program director and fellow perspectives on CCUS competency overlap substantially; future surveys of PDs only might therefore be sufficient. It is also currently unknown how the COVID-19 pandemic may have impacted CCUS training despite high utilization of CCUS in intensive care units. This may help further improve our teaching practices and develop methodologies using advanced tools such as portable ultrasounds with remote access capabilities in the setting of contact precautions, virtual training and feedback sessions. It is currently unknown if CCUS training methodologies differ between CCM only programs vs PCCM programs and country-wide, survey-based studies are needed to include more CCM only programs.

### **Conclusions**

Our study highlights substantial heterogeneity in the CCUS teaching and competency assessment methods among ACGME-accredited PCCM programs in the United States. We found the perceptions of PDs and fellows were in general agreement with high levels of perceived competency to perform CCUS-guided procedures and lung/pleura assessment but deficiencies in the competent performance and interpretation of abdominal and lower extremity diagnostic venous ultrasonography. We also found that the majority and vast majority of programs do not assess their fellows and teaching faculty respectively for competence in CCUS, highlighting a major area of programmatic and curricular need. Our survey also demonstrates that active learning through regional and local hands-on workshops and directly supervised bedside

CCUS exams were perceived as extremely useful, whereas, unsupervised CCUS exam, self-directed learning and lecture-based learning were perceived as less useful by both PDs and fellows. These findings suggest that further studies and guidelines are needed to formulate standardized competency assessment tools across all PCCM/CCM fellowship programs.

### **Disclosures**

MHA had full access to all of the data in the study and takes responsibility for the integrity of the data and the accuracy of the data analysis. MHA and DP contributed substantially to the study design, data analysis and interpretation. MHA, HD and DP contributed substantially to the writing of the manuscript. The authors have no relevant conflicts of interest to disclose.

### **References**

1. ACGME. ACGME Program Requirements for Graduate Medical Education In Anesthesiology. Web. Accreditation Council for Graduate Medical Education (ACGME). June, 13, 2020 2020;
2. ACGME. ACGME Program Requirements for Graduate Medical Education in Emergency Medicine. Webpage. Accreditation Council for Graduate Medical Education (ACGME). 6/13/2021 2020;
3. ACGME. ACGME Program Requirements for Graduate Medical Education in Pulmonary Disease and Critical Care Medicine. Webpage. Accreditation Council for Graduate Medical Education. 6/13/2020 2020;
4. Mayo PH, Beaulieu Y, Doelken P, et al. American College of Chest Physicians/La Societe de Reanimation de Langue Francaise statement on competence in critical care ultrasonography. *Chest*. Apr 2009;135(4):1050-1060. doi:10.1378/chest.08-2305
5. Wong A, Galarza L, Forni L, et al. Recommendations for core critical care ultrasound competencies as a part of specialist training in multidisciplinary intensive care: a framework proposed by the European Society of Intensive Care Medicine (ESICM). *Critical Care*. 2020/07/03 2020;24(1):393. doi:10.1186/s13054-020-03099-8
6. International expert statement on training standards for critical care ultrasonography. *Intensive care medicine*. Jul 2011;37(7):1077-83. doi:10.1007/s00134-011-2246-9
7. Eisen LA, Leung S, Gallagher AE, Kvetan V. Barriers to ultrasound training in critical care medicine fellowships: a survey of program directors. *Critical care medicine*. Oct 2010;38(10):1978-83. doi:10.1097/CCM.0b013e3181eeda53
8. Mosier JM, Malo J, Stolz LA, et al. Critical care ultrasound training: a survey of US fellowship directors. *Journal of critical care*. Aug 2014;29(4):645-9. doi:10.1016/j.jcrc.2014.03.006
9. Brady AK, Spitzer CR, Kelm D, Brosnahan SB, Latifi M, Burkart KM. Pulmonary Critical Care Fellows' Use of and Self-reported Barriers to Learning Bedside Ultrasound During Training: Results of a National Survey. *Chest*. 2021;160(1):231-237. doi:10.1016/j.chest.2021.01.068
10. Harris PA, Taylor R, Thielke R, Payne J, Gonzalez N, Conde JG. Research electronic data capture (REDCap)--a metadata-driven methodology and workflow process for providing translational research informatics support. *Journal of biomedical informatics*. Apr 2009;42(2):377-81. doi:10.1016/j.jbi.2008.08.010
11. Harris PA, Taylor R, Minor BL, et al. The REDCap consortium: Building an international community of software platform partners. *Journal of biomedical informatics*. Jul 2019;95:103208. doi:10.1016/j.jbi.2019.103208
12. IBM SPSS Statistics for Windows, Version 27.0. Armonk, NY.
13. Ten Cate O. Competency-Based Postgraduate Medical Education: Past, Present and Future. *GMS J Med Educ*. 2017;34(5):Doc69. doi:10.3205/zma001146



14. Harris P, Bhanji F, Topps M, et al. Evolving concepts of assessment in a competency-based world. *Med Teach.* Jun 2017;39(6):603-608. doi:10.1080/0142159X.2017.1315071
15. van der Vleuten CP, Schuwirth LW, Driessen EW, et al. A model for programmatic assessment fit for purpose. *Med Teach.* 2012;34(3):205-14. doi:10.3109/0142159X.2012.652239
16. Rajamani A, Smith L, Gunawan S, et al. Methodologic Quality of Guidelines for Training or Competence Processes for Basic Point-of-Care Echocardiography in Critical Care: A Systematic Review of the Literature. *Chest.* 2021;160(2):616-623. doi:10.1016/j.chest.2021.02.020
17. Rajamani A, Shetty K, Parmar J, et al. Longitudinal Competence Programs for Basic Point-of-Care Ultrasound in Critical Care: A Systematic Review. *Chest.* Sep 2020;158(3):1079-1089. doi:10.1016/j.chest.2020.03.071
18. Russell FM, Zakeri B, Herbert A, Ferre RM, Leiser A, Wallach PM. The State of Point-of-Care Ultrasound Training in Undergraduate Medical Education: Findings From a National Survey. *Academic Medicine.* 9000;
19. Stowell JR, Kessler R, Lewiss RE, et al. Critical care ultrasound: A national survey across specialties. *Journal of clinical ultrasound : JCU.* Mar 2018;46(3):167-177. doi:10.1002/jcu.22559
20. Wong J, Montague S, Wallace P, et al. Barriers to learning and using point-of-care ultrasound: a survey of practicing internists in six North American institutions. *Ultrasound J.* 2020;12(1):19-19. doi:10.1186/s13089-020-00167-6
21. Carver TW. Ultrasound Training in Surgical Critical Care Fellowship: A Survey of Program Directors. *Journal of surgical education.* Sep-Oct 2018;75(5):1250-1255. doi:10.1016/j.jsurg.2018.01.017
22. Patrawalla P, Narasimhan M, Eisen L, Shiloh AL, Koenig S, Mayo P. A Regional, Cost-Effective, Collaborative Model for Critical Care Fellows' Ultrasonography Education. *Journal of intensive care medicine.* Dec 2020;35(12):1447-1452. doi:10.1177/0885066619828951
23. Rajamani A, Miu M, Huang S, et al. Impact of Critical Care Point-of-Care Ultrasound Short-Courses on Trainee Competence. *Critical care medicine.* Sep 2019;47(9):e782-e784. doi:10.1097/CCM.0000000000003867
24. Rajamani A, Knudsen S, Ngoc Bich Ha Huynh K, et al. Basic echocardiography competence program in intensive care units: A multinational survey of intensive care units accredited by the College of Intensive Care Medicine. *Anaesthesia and intensive care.* Mar 2020;48(2):150-154. doi:10.1177/0310057x20911663
25. Arntfield, R., Millington, S., Ainsworth, C., Arora, R., Boyd, J., Finlayson, G., Gallagher, W., Gebhardt, C., Goffi, A., Hockman, E., Kirkpatrick, A., McDermid, R., Waechter, J., Wong, N., Zavalkoff, S., & Beaulieu, Y. (2014). Canadian recommendations for critical care ultrasound training and competency. *Canadian respiratory journal,* 21(6), 341–345. <https://doi.org/10.1155/2014/216591>

# Carotid Flow Time Compared with Invasive Monitoring as a Predictor of Volume Responsiveness in ICU patients

Tomislav Jelic, MD<sup>1\*</sup>; Jordan Chenkin, MD<sup>2</sup>

(1) Department of Emergency Medicine, University of Manitoba, Winnipeg, Canada

(2) Sunnybrook Health Sciences Centre, Division of Emergency Medicine, Department of Internal Medicine, University of Toronto

## Abstract

**Objectives:** Identifying patients who will have an increase in their cardiac output from volume administration is difficult to identify. We propose the use of carotid flow time, which is a non-invasive means to determine if a patient is volume responsive. **Methods:** Patients admitted to a critical care unit with a pulmonary artery catheter in place were enrolled. We perform a carotid flow time and pulmonary artery catheter measurement of cardiac output pre and post-passive leg raise and comparing the two. An increase of 10% change in the pre- vs. post-passive leg raise measurement would be indicative of a patient who is volume responsive. **Results:** We identified 8 patients who were volume responsive as determined by the gold standard pulmonary artery catheter. The sensitivity 87.5% and specificity 90.9%. Pearson correlation coefficient between PA-CO measurements and CFT was  $r=0.8316$ , indicative of strong correlation between the two measurements. **Conclusion:** In our patient sample of critically ill patients with pulmonary artery catheters, we found a strong correlation between corrected carotid flow times and cardiac output measurements from pulmonary artery catheters.

## Background

The use of intravenous fluids to improve cardiac output and restore euvolemia is one of the cornerstones of resuscitation. However, the responsiveness to a fluid challenge is determined by where the patient lies on the Frank-Starling curve. Determining fluid responsiveness can be very challenging when relying on clinical examination or non-invasive measurement [1]. Under-resuscitating critically ill patients may cause worsened tissue hypoperfusion and cellular death. On the other hand, the over-resuscitation of these patients can lead to prolonged intensive care stays, ventilator dependence and potentially increased mortality [2,3].

Carotid flow time (CFT) has been described as a potentially accurate non-invasive method of determining a patient's fluid responsiveness [4]. CFT is a measurement of the duration of time spent in systole and acts as a surrogate for cardiac output. In fluid responsive patients, a fluid challenge will increase the amount of time the heart spends in systole, therefore increasing the CFT. Carotid flow time can be easily assessed using relatively simple measurements at the bedside using portable

ultrasound machines. A study by Blehar et al demonstrated that carotid flow time (CFT) changes significantly with the administration of fluids to patients deemed volume deplete [5], further raising the prospect that carotid flow time may indeed be a useful and reliable measurement of volume responsiveness.

This proof-of-concept study aims to compare the accuracy of CFT for predicting volume responsiveness for patients in the intensive care unit (ICU) when compared with invasive monitoring.

## Methods

This was a prospective study of patients admitted to an intensive care unit at a large Academic Health Sciences Centre in Toronto, Canada. The institutional review board approved the study.

A convenience sample of patients were recruited to participate according to investigator availability. Inclusion criteria were ICU patients admitted within the past 24 hours with a pulmonary artery catheter (PAC) inserted for monitoring. This time frame was selected to attempt to capture patients in the most acute phase of their illness.

---

\*Corresponding Author: Dr. Tomislav Jelic (email: [tjelic@gmail.com](mailto:tjelic@gmail.com))

This work is licensed under a [Creative Commons Attribution 4.0 International License](https://creativecommons.org/licenses/by/4.0/).

Author(s) retain the copyright for their work. At the time of submission to POCUS Journal the author(s) grant the journal a limited and non revokable right to publish in the Journal under a [Creative Commons Attribution 4.0 International License](https://creativecommons.org/licenses/by/4.0/).

DOI: <https://doi.org/10.24908/pocus.v8i2.16545>

Patients were excluded if they had any cardiac dysrhythmia, known severe valvular lesions and if they were deemed too hemodynamically unstable to participate by intensive care staff.

Two emergency physicians with significant point of care ultrasound (POCUS) experience enrolled patients in the study. A 10-5 high frequency linear probe (Mindray Medical Ltd, Shenzhen, China) was placed over the carotid artery and the carotid bulb was identified. Pulsed wave doppler tracings were obtained with the patient at 30 degrees of head elevation. As previously described, the CFT was measured from the beginning of systole to the dicrotic notch [6]. As the CFT measurement was being obtained, a PAC measurement of cardiac output was performed. The ultrasonographer was blinded to the PAC cardiac output measurements. All images were saved for subsequent review. PAC measurements were performed using the thermodilution method.

After initial measurements were obtained, a passive leg raise was performed as per a standardized protocol [7]. A repeat carotid flow time and PAC cardiac output measurement was taken. A total of three CFT and PAC cardiac output measurements were taken during the pre and post-leg raise and were averaged. If there was significant variability (>10%) between the readings of the PAC, five measurements were taken, with the two outlying measurements removed and the three remaining measurements were averaged. The patient's hemodynamic parameters were also monitored pre and post-passive leg raise. A difference of 10% between the PAC cardiac output readings was considered positive for volume responsiveness as defined in previous literature [8].

A corrected CFT was calculated as systole time/ $\sqrt{\text{cycle time}}$  to correct for changes in heart rate. Changes in PAC and CFT cardiac output measurements after the passive leg raise were compared using a two-sided t-test. The changes in CFT were assessed using ROC analysis. Cohen's kappa coefficient was calculated to assess the agreement between PAC and CFT. Statistical significance was set at  $p < 0.05$ .

## Results

28 patients were approached for enrollment. Six patients were not enrolled due to consent not being provided by next of kin. One patient was not enrolled as the treating physician felt they were too unstable to participate. A total of 21 patients were subsequently enrolled in the study. Of the 21 patients enrolled, 2 patients were excluded due to a malfunctioning pulmonary artery catheter. Baseline demographics and patient information can be found in Table 1.

Table 1. Patient demographics and baseline data.

Baseline Patient Demographics	Value (%)
Gender	Male 12 (63.2)
	Female 7 (36.8)
BMI	25.47+/- 1.735
Neck Circumference	Mean 46.6cm +/-6.78cm
Reason for PA Catheter *	Shock of unclear etiology 2 (10.5)
	Post CABG 12 (63.2)
	Post Valvular replacement 4 (21.1)
Number of Patients on Ventilator Support	17 (89.5)
Number of Patients on Vasoactive Agents	10 (52.6)
Vasoactive Agents Used	Norepinephrine 3 (14) *two patients receiving both norepinephrine and milrinone
	Milrinone 3 (14) *two patients receiving both norepinephrine and milrinone
	Nitroglycerin 6 (29)
Number of Patients Who Were Volume Responders per Gold Standard	8 (42.1)

The pre and post-leg raise hemodynamic measurements are described in Table 2. Overall, 8/19 (38%) patients exhibited a 10% increase in cardiac output as determined by PAC and were therefore considered volume responsive.

Table 3 highlights changes in hemodynamics in those who were deemed volume responsive. It is noted that while a change in cardiac output was demonstrated with the CFT and PAC, the patients heart rate and blood pressure did not change significantly, highlighting that an improvement in blood pressure for example, does not necessarily reflect the cardiac output status of the patient.

The receiver operating curve for carotid flow time measurements had an area under the curve (AUC) of 0.9. The odds ratio is 1.6098, p-value 0.043 (95% CI) (Sensitivity 87.5%, specificity 90.9%, PPV 0.875, NPV

*Table 2. Difference Between Pre- and Post- Passive Leg Raise Measurements for Mean Arterial Blood Pressure, Pulse and Corrected Carotid Flow Times for all patients.*

Measurement	Pre-Leg Raise	Post-Leg Raise	p-Value
Mean Arterial Blood Pressure	84.10 mmHg +/- 20.62	81.95 +/-4.66	0.65
Pulse	87.6 bpm +/- 15.3	87.1 bpm +/- 7.32	0.89
Mean Corrected Carotid Flow Time	303.65ms +/- 32.85	321.85ms +/- 23.56	0.0728
Cardiac Output	4.467 +/- 0.59	5.649 +/- 0.83	0.0678

0.909). The ideal change in CFT to predict volume responsiveness was 9.1% change in CFT pre and post passive leg raise. Pearson correlation coefficient between PA-CO measurements and CFT was  $r=0.8316$ , indicative of strong correlation between the two measurements. Carotid flow measurements were feasible for all patients, regardless of BMI and neck circumference.

### Discussion

In this study, CFT was highly accurate at predicting fluid responsiveness among critically ill patients when compared with invasive measurement techniques. Using a change of 9.1%, CFT had a 87.5% sensitivity and 90.9% specificity for predicting fluid responsiveness. Other clinical parameters such as change in heart rate and mean arterial pressure did not change significantly with a fluid challenge. Given its non-invasive nature and easy repeatability, CFT measurements show promise to help guide the clinician on fluid management strategies for critically ill patients.

The ability of the physician to accurately predict the volume needs of patient remains a difficult clinical skill. With the advent of invasive monitoring, more accurate methods of determining volume status have become available. Over the years however, several of these tools have fallen out of favor, particularly the use of central venous pressure (CVP) and the Swan-Ganz pulmonary artery catheter. Recently, POCUS has been evaluated as a non-invasive means of determining fluid responsiveness. The inferior vena cava (IVC) and its respirophasic variability in the spontaneously breathing patient has shown some promise [9], however there are uncertainties about its utility [10,11] and ability to accurately predict volume responsiveness. Other methods such as measurements of cardiac output using transthoracic echocardiography can be technically challenging due to the difficulty in obtaining adequate views in critically ill patients [12].

The rationale for evaluating changes in the CFT is based on common physiologic principles. The CFT measures the time spent in ventricular systole and corrected for

*Table 3. Mean difference between pre- and post- passive leg raise measurements for mean arterial blood pressure, pulse and correct carotid flow times in volume responders.*

Measurement	Fluid-responsive (n=8)		Not fluid-responsive (n=11)	
	Pre-leg raise	Post-leg raise	Pre-leg raise	Post-leg raise
MAP, mmHg (SD)	88.75 (+/-32.06)	82.14 (+/-9.91)	80.45 (+/-8.76)	80.36 (+/-8.96)
Heart rate (SD)	83.75 (+/-13.50)	84.25 (+/-11.02)	89.64 (+/-17.36)	88.27 (+/-18.63)
CFT, ms (SD)	288.85 (+/-42.30)	340.86 (+/-75.86)	310.17 (+/-23.94)	309.57 (+/-29.24)
Change in CFT, ms (SD)	52.01ms (+/-39.96)		14.23ms (+/-10.50)	
CO, L/min (SD)	5.46 (+/-0.93)	6.23 (+/-1.57)	4.52 (+/-1.01)	4.46 (+/-1.07)
Change in CO, % (SD)	0.87 L/min (+/-0.73)		0.21 L/min (+/-0.15)	

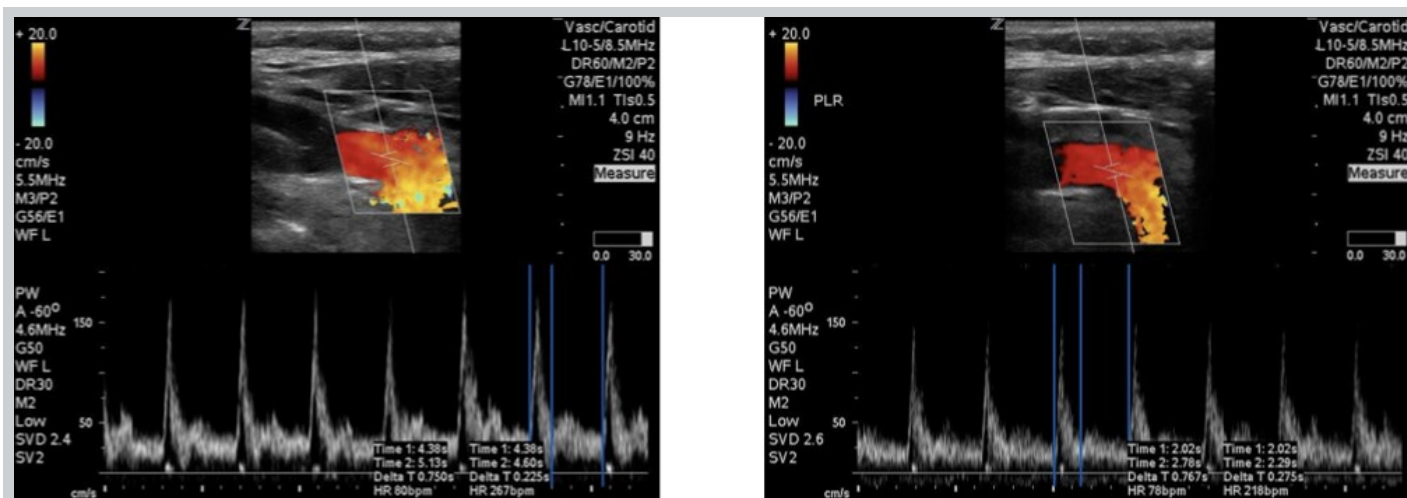


Figure 1. Corrected carotid flow time measurement in a volume non-responder.

changes in heart rate. If a patient is fluid responsive, then their time spent in ventricular systole should increase when faced with a fluid challenge due to increased ventricular filling. This indicates that increased cardiac filling during ventricular diastole results in an increased stroke volume. The time spent in systole is easily measured on a carotid artery pulse waveform from the beginning of the carotid upstroke to the diastolic notch on the Doppler waveform. See Figure 1 for an example of CFT measurement in a volume non-responder and Figure 2 for a volume responder. In the volume responder example, the image on the left is pre-passive leg raise with CFT calculated at 244.05ms. The image on the right is post-passive leg raise with CFT calculated at 314.00ms. This increase of greater than 10% indicated a volume responsive patient that was corroborated by our gold standard.

Recently, the CFT has been evaluated for its potential use in determining fluid responsiveness. In a study by

Mackenzie et al in 2015 demonstrated that in blood donors, a demonstrated change in corrected carotid flow time after blood loss with a passive leg raise maneuver [6]. A study by Ma et al published in 2017 compared various carotid blood flow measurements to invasive pulmonary artery catheter measurements in non-critically ill patients. Their study found that an average of three waveforms measuring the corrected flow time had a high degree of correlation with cardiac output measurements [13]. In 2018, a study by Barjaktarevic et al in a critical care patient population demonstrated that CFT could demonstrate fluid responsiveness compared to a non-invasive gold standard. The study also found that a 7ms change in CFT had a high positive predictive value for identifying patients who will be fluid responder. Barjaktarevic also demonstrated that mechanical ventilation, respiratory rate and variable positive end expiratory pressure had no impact on the performance of CFT [14].

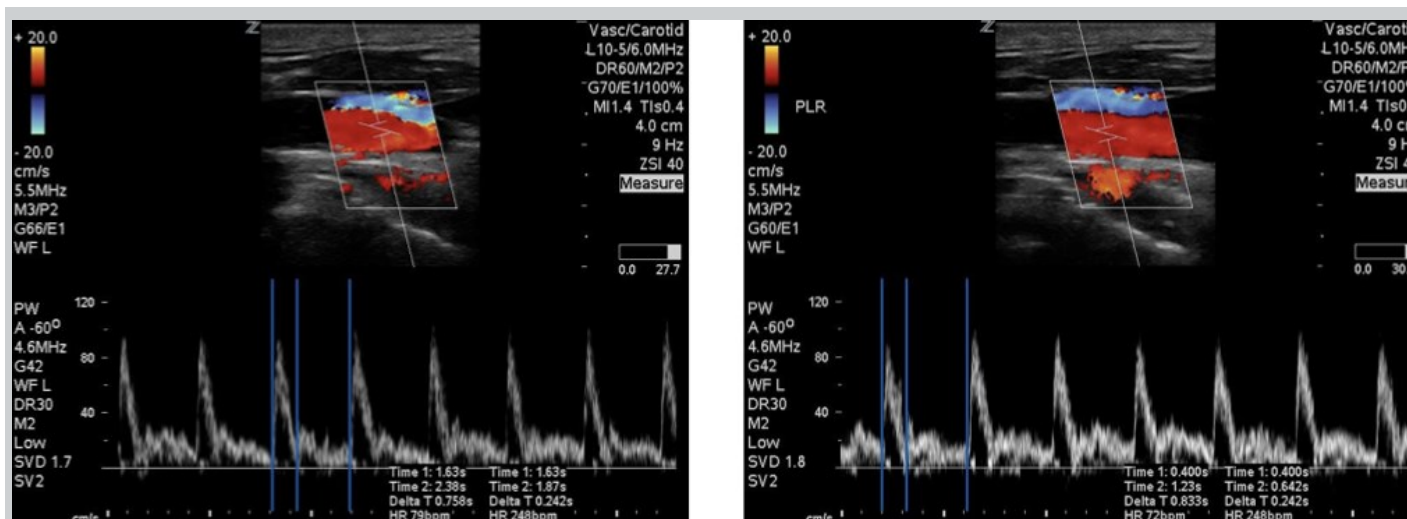


Figure 2. Corrected carotid flow time measurement in volume responder.

Our study has unique aspects compared to other previously published papers on carotid flow time. First, this study uses a critically ill patient population of which 17/19 were mechanically ventilated and 10/19 on vasoactive agents. Secondly, this study used an invasive means to assess cardiac output with a pulmonary artery catheter. Other published studies used non-invasive means to assess cardiac output [14], which has been shown to be a potentially non-reliable method to assess changes in cardiac output [15].

### Limitations

This study has several important limitations. The sample size was small, which limits the generalizability of our findings. Larger studies should be performed to confirm these findings. Due to investigator availability, a convenience sample was included. However, all eligible patients were approached for enrollment when the investigators were available. Study participants were primarily composed of recent post-operative cardiac surgery patients. These patients may have had unique causes of shock that may not generalize to a broader patient population. We did not measure inter-rater reliability of the CFT measurements. The time taken to complete the scans was not recorded, however it was noted that the measurements could all be completed in less than 10 minutes.

### Conclusion

The corrected carotid flow time has a high accuracy for predicting volume responsiveness in ICU patients when compared with invasive measurements. An increase in CFT of 9.1% was predictive of a significant increase in cardiac output. Future studies with larger and more heterogeneous patient populations should be performed to validate these findings.

### Conflicts of interest

There are no conflicts of interest to disclose for either author.

### References

1. Hiemstra B, Eck RJ, Keus F, van der Horst ICC. Clinical examination for diagnosing circulatory shock. *Curr Opin Crit Care*. 2017 Aug;23(4):293-301. doi: 10.1097/MCC.0000000000000420. PMID: 28570301; PMCID: PMC5495551
2. Boyd JH, Forbes J, Nakada TA, Walley KR, Russell JA. Fluid resuscitation in septic shock: a positive fluid balance and elevated central venous pressure are associated with increased mortality. *Critical Care Medicine*. 2011;39: 259-265
3. The ARDSNet Group. Comparison of two fluid-management strategies in acute lung injury. *New England Journal of Medicine* 2006; 354:2564–2575.
4. Marik P, Levitov A et al. The use of bioreactance and carotid Doppler to determine volume responsiveness and blood flow redistribution following passive leg raising in hemodynamically unstable patients. *Chest* 2013; 143:364-370
5. Blehar D, Glazier S et al. Correlation of corrected flow time in the carotid artery with changes in intravascular volume status. *Critical Care*

2014;29:486-488

6. Mackenzie DC, Khan NA, Blehar D, Glazier S, Chang Y, Stowell CP, Noble VE, Liteplo AS (2015) Carotid flow time changes with volume status in acute blood loss. *Ann Emerg Med* 66:277–282
7. Monnet X, Teboul JL (2015) Passive leg raising: five rules, not a drop of fluid! *Crit Care* 19:18
8. Bendjelid K, Romand JA (2012) Fluid responsiveness in mechanically ventilated patients: a review of indices used in intensive care. *Intensive Care Med* 29:352–360
9. Nagdev AD, Merchant RC, et al. Emergency department bedside ultrasonographic measurement of the caval index for noninvasive determination of low central venous pressure. *Annals of Emergency Medicine* 2010;55:290–295.
10. Dipti A, Soucy Z et al. Role of inferior vena cava diameter in assessment of volume status: a meta-analysis. *American Journal of Emergency Medicine*, 2012; 30:1414-1419.
11. Muller L, Bobbia X, Toumi M, et al. Respiratory variations of inferior vena cava diameter to predict fluid responsiveness in spontaneously breathing patients with acute circulatory failure: need for a cautious use. *Critical Care* 2012;16:R188.
12. Feltracco P, Biancofiore G, Ori C, Saner Fuat H, Della Rocca G. Limits and pitfalls of haemodynamic monitoring systems in liver transplantation surgery. *Minerva Anesthesiol* 2012;78:1372-84
13. Ma IWY, Caplin JD, Azad A, et al. Correlation of carotid blood flow and corrected carotid flow time with invasive cardiac output measurements *Crit Ultrasound J*. 2017; 9(1):10.
14. Barjaktarevic I, Toppen WE, Hu S, Aquije Montoya E, Ong S, Buhr R, David IJ, Wang T, Rezayat T, Chang SY, Elashoff D, Markovic D, Berlin D, Cannesson M. Ultrasound Assessment of the Change in Carotid Corrected Flow Time in Fluid Responsiveness in Undifferentiated Shock. *Crit Care Med*. 2018 Nov;46(11):e1040-e1046.
15. E. Kupersztych-Hagege, J.-L. Teboul, A. Artigas, A. Talbot, C. Sabatier, C. Richard, X. Monnet, Bioreactance is not reliable for estimating cardiac output and the effects of passive leg raising in critically ill patients, *Br J Anaesth*. 2013; 111(6): 961-966.

# Prevalence of Phantom Scanning in Cardiac Arrest and Trauma Resuscitations: The Scary Truth

Zachary Boivin, MD<sup>1\*</sup>; Curtis Xu, MD<sup>1\*</sup>; Donias Doko, MD<sup>1</sup>; Meghan Kelly Herbst, MD<sup>2</sup>; Trent She, MD<sup>3</sup>

(1) University of Connecticut Emergency Medicine Residency, University of Connecticut School of Medicine, Farmington, CT, USA

(2) Department of Emergency Medicine, University of Connecticut School of Medicine, Farmington CT, USA

(3) Department of Emergency Medicine, Hartford Hospital, Hartford, CT,

## Abstract

**Background:** The prevalence of phantom scanning, or point of care ultrasound (POCUS) performed without saving images, has not been well studied. Phantom scanning can negatively affect patient care, reduce billed revenue, and can increase medicolegal liability. We sought to quantify and compare the prevalence of phantom scanning among emergency department (ED) cardiac arrests and trauma resuscitations. **Methods:** This was a single center, retrospective cohort study from July 1, 2019, to July 1, 2021, of all occurrences of POCUS examination documented on the resuscitation run sheet during cardiac arrest and trauma resuscitations. Two investigators reviewed the run sheets to screen for POCUS documentation. Instances where documentation was present were matched with saved images in the picture archiving and communication system. Instances where documentation was present but no images could be located were considered phantom scans. A two-tailed student's t test was utilized to compare the phantom scanning rate between cardiac arrest and trauma resuscitations. **Results:** A total of 1,862 patients were included in the study period, with 329 cardiac arrests and 401 trauma resuscitations having run sheet documentation of POCUS performance. The phantom scanning rate in cardiac arrests and trauma resuscitations was 70.5% (232/329) and 86.5% (347/401), respectively ( $p < 0.001$ ). **Conclusion:** Phantom scanning is common in both cardiac arrests and trauma resuscitations in the ED at our institution, but is significantly higher in trauma resuscitations. Further research is needed to assess causes and develop potential solutions to reduce the high prevalence of phantom scanning.

## Background

Performing point of care ultrasound (POCUS) examinations without saving images is both understudied and problematic for emergency departments. Although there is no consensus on the terminology for this practice, it is commonly referred to as phantom scanning [1-4]. Phantom scanning can result in substandard patient care, billing deficiencies, quality assurance and improvement (QA/QI) concerns, and can lead to medicolegal issues. Guidelines from the Centers for Medicare and Medicaid, the American Institute of Ultrasound in Medicine, as well as the American College of Emergency Physicians recommend that all POCUS examinations should include a representative image saved with clinically relevant anatomy and pathology [5,6]. Of note, the American College of Surgeons, which accredits trauma centers, does not have a defined guideline for the performance and saving of Focused Assessment with Sonography for Trauma (FAST) examinations [7].

POCUS plays an important role in cardiac arrest and

trauma resuscitations [8,9]. While it is important to consistently save POCUS images, this may not occur for a few reasons. Emergency physicians have time-sensitive responsibilities to care for critically ill patients during resuscitations, which may shift their priorities away from saving images [10-12]. Critically ill patients are often not registered in the electronic medical record (EMR) prior to POCUS examination, which may discourage providers from saving images. The culture of an institution may be more focused on performing POCUS and less focused on the saving of POCUS images. Physicians may not realize the benefit of saving images or may think that if no images are saved, then further documentation is not needed.

There is a lack of research on the underlying causes of phantom scanning in the emergency department (ED), even though it is commonly acknowledged in POCUS studies [3,13,14]. Previous studies have shown that improving POCUS workflow or offering physician incentives have led to increased compliance with POCUS documentation, but none have looked at their effect on

---

\*Corresponding Author: Dr. Zachary Boivin (email: [Zboivin.md@gmail.com](mailto:Zboivin.md@gmail.com))

This work is licensed under a [Creative Commons Attribution 4.0 International License](https://creativecommons.org/licenses/by/4.0/).

Author(s) retain the copyright for their work. At the time of submission to POCUS Journal the author(s) grant the journal a limited and non revokable right to publish in the Journal under a [Creative Commons Attribution 4.0 International License](https://creativecommons.org/licenses/by/4.0/).

DOI: <https://doi.org/10.24908/pocus.v8i2.16690>

phantom scanning [2,15-17]. Our aims were to determine the prevalence of phantom scanning among cardiac arrests and trauma resuscitations and compare these two groups. We focused on cardiac arrests and trauma resuscitations because comprehensive documentation of events is recorded in real time by a dedicated ED nurse in both settings, and the need for rapid and timely POCUS performance makes these resuscitations susceptible to phantom scanning. Our *a priori* hypothesis was that the phantom scanning prevalence would be higher among cardiac arrest than trauma resuscitations because the FAST examination is an adjunct to the trauma primary survey, whereas POCUS during cardiac arrest is not as broadly or formally recommended [18,19].

**Methods**

*Study Design*

This was a single center, retrospective cohort study between July 1, 2019, and July 1, 2021. Inclusion criteria were ED patients ≥18 years old who arrived as a trauma or cardiac arrest resuscitation. Patients were excluded if they did not have a POCUS documented by a nurse in

the resuscitation run sheet, or if the timestamp of POCUS performance on the run sheet occurred after return of spontaneous circulation (ROSC) among cardiac arrest patients, as the time-sensitive nature of a cardiac arrest POCUS is no longer present. A trauma resuscitation was defined as a patient with a life-threatening traumatic injury or meeting specific trauma criteria defined by the institution (Table 1), and a cardiac arrest resuscitation was defined as loss of pulses requiring initiation of Advanced Cardiac Life Support. In both cases, a critical care trained ED nurse was present and dedicated to documenting on an electronic run sheet in real time all patient interventions such as medications administered, procedures, and POCUS performance with timestamps. During documentation, our nurses are also trained to ask about POCUS findings if they are not explicitly mentioned by providers during the resuscitation. As each resuscitation always had one nurse assigned to documentation and because each resuscitation had an electronic run sheet recorded, this run sheet documentation was used as a surrogate for a POCUS examination occurring during the resuscitation.

*Table 1: Trauma Activation Criteria*

• Glasgow Coma Scale ≤ 12
• Systolic Blood Pressure < 90 mmHg
• Respiratory rate < 10 or > 29, intubated or with threatened airway
• Any penetrating injury to the head, neck, torso, or extremities proximal to the elbows or knees
• Motor Vehicle Collision with patient ejected from vehicle
• Fall > 20 feet
• Major deep burns (20% body surface area)
• Chest wall instability
• Two or more proximal long bone fractures
• Suspected unstable pelvic fracture
• Open or depressed skull fracture
• Paralysis secondary to injury
• Amputation proximal to wrist or ankle
• Crushed, degloved, or mangled extremity at or proximal to elbows or knees
• Pregnant patient 20 weeks or greater with vaginal bleeding, abdominal tenderness, and/or injury
• Transfer patients receiving blood to maintain vital signs, positive Focused Assessment with Sonography for Trauma examination, or chest tube insertion
• Emergency Department Physician’s discretion



### *Setting*

The study was performed at a Level 1 trauma center with over 110,000 annual patient visit, and an active ED POCUS program with approximately 4,500 POCUS examinations performed annually. The ED is staffed by 48 emergency medicine attendings, 54 rotating emergency medicine residents, and five emergency medicine fellows (one ultrasound, two resuscitation, and two simulation fellows). Residents participate in 16 hours of ultrasound training during their residency orientation, spend four weeks on a dedicated POCUS rotation, and must perform a minimum of 500 POCUS examinations as a requirement for graduation.

There is a six-bed critical care area where resuscitations take place, including trauma and cardiac arrest resuscitations, with a dedicated Sonosite X-porte (FUJIFILM Sonosite, Inc., Bothell, WA) ultrasound machine. This area also has a dedicated three-person nursing team as well as a care team consisting of an attending emergency medicine physician and frequently a resident, fellow, or both. POCUS examinations are primarily performed by an emergency medicine resident with supervision by an emergency medicine attending, unless there are no emergency medicine residents in the department, which occurs during weekly resident conference and occasional residency events. During these rare occasions, FAST examinations are performed by a member of the trauma team (an advanced practice provider, surgery resident, trauma fellow, or the attending trauma surgeon) with supervision by the emergency medicine attending.

Our institution's current POCUS workflow is order-based. First, an order needs to be placed by an emergency medicine provider in the EMR, then the patient information is queried on the ultrasound machine and the correct patient is selected. Images are acquired and saved by an operator, and when the examination is ended on the machine, they upload to the picture archival and communication system (PACS). Emergency physicians document their findings in the EMR, which is linked to the images stored in the PACS. If POCUS images are saved without patient information, the images are still uploaded to the PACS and available for viewing under an anonymous designation, and can later be merged with the patient's chart in the EMR.

### *Chart Review*

Patients with cardiac arrest were determined by ICD-10 coding in the EMR. Trauma resuscitations were identified utilizing a pre-existing trauma registry in the EMR documenting all trauma team activations. Manual chart review and abstraction was completed by two investigators (ZB, CX) unblinded to the research

question, and the principal investigator (TS) randomly selected 10% of cases to review for accuracy. Study investigators met prior to chart review to develop a systematic review process for both the chart and the ultrasound image review process.

A phantom scan was defined as a POCUS scan that was performed on a patient, where no subsequent images were saved. Performance of a POCUS was defined as any POCUS notation that was documented on the resuscitation run sheet by a nurse. Images were considered saved if an examination was located on our PACS that could be corroborated with the patient.

Specifically, for patients who had either a cardiac arrest or trauma resuscitation, the study investigators first determined whether there was a POCUS examination documented in the resuscitation run sheet. If documentation stated a POCUS was performed, the investigators then reviewed the PACS for POCUS images that corresponded with the patient according to timestamp, examination type, and POCUS findings. If there were no images that matched the run sheet documentation, the POCUS examination was categorized as a phantom scan. Investigators only evaluated the initial POCUS examination performed in a resuscitation; subsequent POCUS examinations were not evaluated.

To ensure the resuscitation run sheet was accurate in documenting the performance of a POCUS examination, the investigators reviewed the PACS system for 10% of all resuscitations, both trauma and cardiac arrest, where there was no documented POCUS on the resuscitation run sheet for images in our PACS. This was done to ensure that our screening method of using the resuscitation sheet for a performed POCUS was accurate.

### *Outcomes*

The primary outcome for the study was the prevalence of phantom scanning, which was calculated by dividing the number of patients with POCUS images linked to the patient encounter by the total number of patients with a POCUS examination documented in the resuscitation run sheet. The secondary outcome was the comparison of phantom scanning between cardiac arrest and trauma resuscitations.

### *Data Analysis*

The prevalence of phantom scanning was calculated in Microsoft Excel (Redmond, WA). A two-tailed Mann-Whitney U test using IBM SPSS version 27 (Armonk, NY) was performed to assess for a difference between phantom scanning in cardiac arrest and trauma resuscitations, with alpha <0.05 indicating significance.

**Results**

We reviewed 1,862 patient resuscitations for this study: 861 cardiac arrests and 1001 trauma resuscitations. A total of 1,130 patients were excluded due to a lack of POCUS documentation in the run sheet, and two patients were excluded for a POCUS performed after ROSC was obtained, leaving 730 patients (329 cardiac arrests and 401 trauma resuscitations) for analysis (Figure 1). To test for accuracy of resuscitation run sheet documentation for POCUS performance, we looked at a randomized 10% selection of the previously excluded resuscitations due to a lack of POCUS documentation on the resuscitation run sheet. The PACS was reviewed for these patients and found POCUS was performed for 1/60 (1.7%) of traumas and 0/50 (0%) of cardiac arrest resuscitations.

A total of 151 patients had identified POCUS images in the PACS. For cardiac arrests, POCUS images were identified in 29.5% of included cases (n=97) resulting in a 70.5% phantom scanning rate among cases with POCUS documented as performed. In trauma resuscitations, POCUS images were identified in 13.5% of included cases (n=54), resulting in an 86.5% phantom scanning rate among cases with POCUS documented as performed. The prevalence of phantom scanning was significantly higher in trauma resuscitations compared to cardiac arrest resuscitations (p<0.001).

**Discussion**

To our knowledge, this is the first study to quantify the rate of phantom POCUS scanning, however, this study took place at a single institution, which limits its generalizability. While phantom scanning is a known problem in the POCUS field, the extent to which it occurs has not been well studied. Our results support that phantom scanning during resuscitations is common at our institution, which raises several concerns for our institution and other EDs with similar POCUS workflows. First, despite being able to readily utilize POCUS at the bedside, decreased adherence to emergency medicine societal guidelines for image retention and documentation could negatively impact patient care [3,6]. Second, phantom scanning exposes physicians to QA/QI concerns, as providers are unable to obtain feedback on their acquisition and interpretation of POCUS images, and thus are unable to improve. Third, phantom scanning presents several medicolegal issues [3]. This issue is apparent when considering that POCUS, especially in the setting of critically ill patients, provides vital information for clinical decision-making when other tests or evaluations are not yet available or are nondiagnostic [20]. When major decisions to transport a patient to the OR, cease resuscitation, or perform procedures such as a thoracotomy or pericardiocentesis are based on POCUS, it is paramount that evidence of the legitimacy

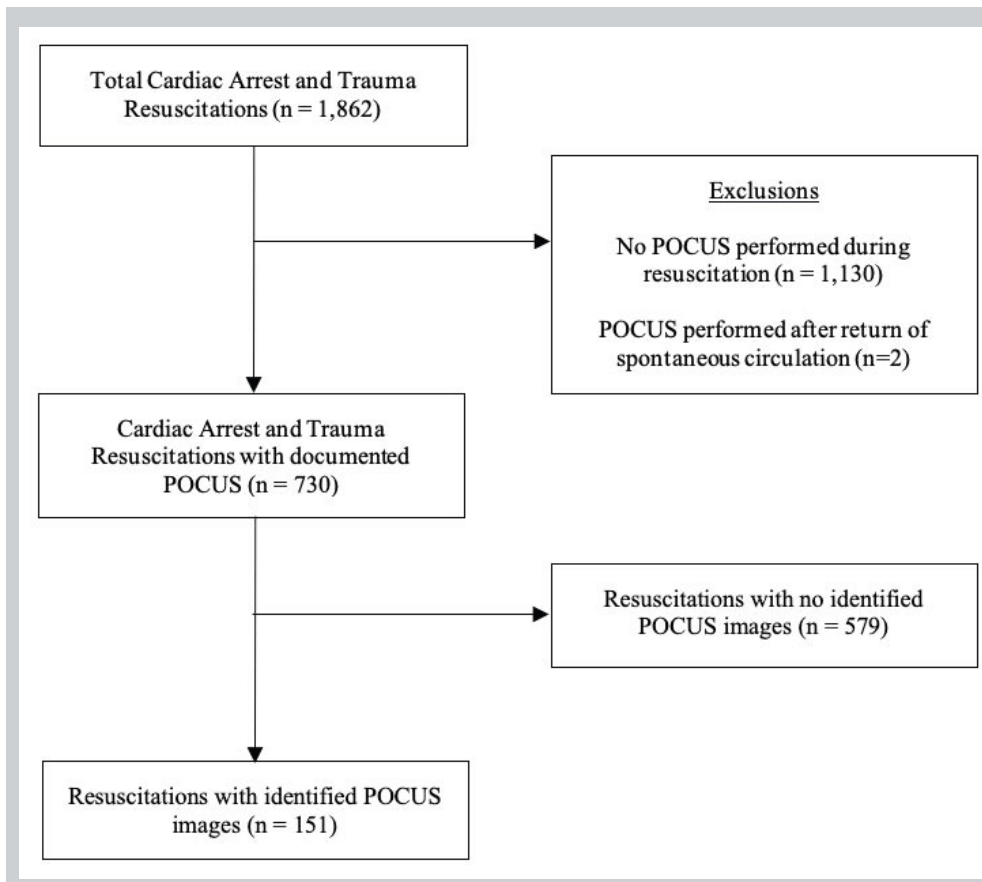


Figure 1. Flowchart describing inclusion and exclusion criteria.

of those decisions are readily available for future case review. Without images available for review, medical decisions may appear unwarranted. Finally, phantom scanning eliminates the potential to bill for the POCUS examination [5]. As POCUS use increases in the ED, the number of consulting and admitting providers who review images obtained by emergency physicians to direct patient care will continue to increase [21]. As more robust POCUS programs expand from academic emergency medicine into the community setting, limiting the amount of phantom scanning will ensure continued growth of POCUS within the specialty of emergency medicine [22].

When comparing the rate of phantom scanning in trauma resuscitations to cardiac arrest, our initial hypothesis that there would be a lower phantom scanning rate for the FAST examination was incorrect. This finding caused us to give further thought as to why the FAST examination phantom scanning rate was significantly higher than in cardiac arrest resuscitations. While the trauma team at our institution only occasionally performs the FAST examination, their involvement poses several issues pertaining to POCUS phantom scanning rate. The trauma team receives no formal education on the ED POCUS workflow and the need to save images. Additionally, the trauma providers use a different set of ultrasound machines when not in the ED and so may be unfamiliar with the ED ultrasound machines and the process of saving images on them. Finally, members of the trauma team are unable to access the POCUS ordering system as the system is only available for ED providers, and the lack of an order may deter the provider performing the FAST from saving images. The FAST examination may take longer to acquire as there are four standard views instead of a minimum two views (oftentimes one view) for cardiac arrest POCUS, there is no dedicated pause in care for the FAST examination as there is in cardiac arrest pulse checks, and the FAST examination may be interrupted to take the patient for a computed tomography examination or to the operating room. The differences between how POCUS is performed during a cardiac arrest and trauma resuscitation could have caused the difference in phantom scanning rate, but does not change the overall high phantom scanning rate at our institution for these resuscitations.

We propose the following interventions to decrease phantom scanning rates at institutions with similar processes. First, formal education to avoid phantom scanning presented to both emergency medicine physicians and consultants who perform POCUS examinations in the ED. While emergency physicians are aware of the POCUS workflow, educating consultants may help reduce the rate of phantom scanning by

providing insight into the POCUS workflow and increasing familiarity with the ED POCUS machines, which is recommended in the American College of Emergency Physicians ultrasound guidelines [6]. Second, scheduled reminders to physicians about saving images should be made at regular intervals. Finally, simple interventions such as labeling the ultrasound machine in the resuscitation area reminding physicians to order and save POCUS images, or saving unordered examinations under a common name such as “Code” or “Trauma” to assist with image review and QA/QI. These interventions, and their effect on the prevalence of phantom scanning, offer an opportunity for further research to help minimize phantom scanning and to optimize patient care.

### *Limitations*

The major limitation of this study was that it only looks at a single POCUS workflow at a single institution, making it difficult to generalize our conclusions to other departments. Other institutions workflow may differ in how orders are placed, the type of workflow, or who performs the FAST examination. We hope, however, this study provides a replicable methodology that encourages other institutions to review their own POCUS workflows, assess their own rates of phantom scanning, and—most importantly—encourage their physicians to save their obtained POCUS images. An additional limitation was its retrospective nature, which meant we were unable to definitively establish any causal relationships as to why there was such a high prevalence of phantom scanning at our institution. We also had to use resuscitation run sheet documentation as a surrogate for POCUS performance rather than direct visualization or acknowledgment of POCUS performance. It is possible there were other cardiac arrest or trauma resuscitations where POCUS was utilized but was not documented in the run sheet, but our review of 10% of randomly selected resuscitations where POCUS was not documented in the run sheet found less than one percent (1/110) discrepancy, suggesting our surrogate marker for POCUS performance was accurate. Additionally, there could have been POCUS images saved under a different patient name if the previous POCUS examination was not ended, or the images could have been saved but failed to upload to the PACS, but we attempted to mitigate this by searching by time performed in the PACS, allowing investigators to review all POCUS examinations conducted at approximately the time as the resuscitation.

### **Conclusion**

At our institution, we found a 70.5% phantom scanning prevalence during cardiac arrest resuscitations, and an 86.5% phantom scanning prevalence for trauma

resuscitations. Trauma resuscitations had a significantly higher phantom scanning prevalence and lower number of formal POCUS orders when compared to cardiac arrest resuscitations.

## Statement of Ethics

IRB approval was obtained for this study.

## Disclosures

The authors report no disclosures related to this work.

## References

- Hughes D, Corrado MM, Mynatt I, Prats M, Royall NA, Boulger C, et al. Billing I-AIM: a novel framework for ultrasound billing. *The ultrasound journal*. 2020;12(1):8-. <https://doi.org/10.1186/s13089-020-0157-0>.
- Rong K, Chimileski B, Kaloudis P, Herbst MK. Impact of an epic-integrated point-of-care ultrasound workflow on ultrasound performance, compliance, and potential revenue. *Am J Emerg Med*. 2021;49:233-9. <https://doi.org/10.1016/j.ajem.2021.06.009>.
- Lewiss R. "The Ultrasound Looked Fine": Point-of-Care Ultrasound and Patient Safety. 2023. PSNet: ARHQ; 2018.
- Nomura JT. Consensus Terminology for Point of Care Ultrasound Studies with Incomplete Documentation and Workflow Elements *POCUS Journal*. 2022;7(1):116-117 <https://doi.org/10.24908/pocus.v7i1.15017>
- McKenzie D. Ultrasound Reimbursement FAQ. ACEP; 2022.
- Ultrasound Guidelines: Emergency, Point-of-Care and Clinical Ultrasound Guidelines in Medicine. *Ann Emerg Med*. 2017;69(5):e27-e54. <https://doi.org/10.1016/j.annemergmed.2016.08.457>.
- Resources for Optimal Care of the Injured Patient: American College of Surgeons; 2022.
- Gaspari R, Weekes A, Adhikari S, Noble VE, Nomura JT, Theodoro D, et al. Emergency department point-of-care ultrasound in out-of-hospital and in-ED cardiac arrest. *Resuscitation*. 2016;109:33-9. <https://doi.org/10.1016/j.resuscitation.2016.09.018>.
- Desai N, Harris T. Extended focused assessment with sonography in trauma. *BJA Educ*. 2018;18(2):57-62. <https://doi.org/10.1016/j.bjae.2017.10.003>.
- Grossman MD. The role of emergency medicine physicians in trauma care in North America: evolution of a specialty. *Scandinavian Journal of Trauma, Resuscitation and Emergency Medicine*. 2009;17(1):37. <https://doi.org/10.1186/1757-7241-17-37>.
- Hunziker S, Johansson AC, Tschan F, Semmer NK, Rock L, Howell MD, et al. Teamwork and Leadership in Cardiopulmonary Resuscitation. *J Am Coll Cardiol*. 2011;57(24):2381-8. <https://doi.org/https://doi.org/10.1016/j.jacc.2011.03.017>.
- Singh MR, Jackson JS, Newberry MA, Riopelle C, Tran VH, PoSaw LL. Barriers to point-of-care ultrasound utilization during cardiac arrest in the emergency department: a regional survey of emergency physicians. *Am J Emerg Med*. 2021;41:28-34. <https://doi.org/10.1016/j.ajem.2020.12.040>.
- Douflé G, Teijeiro-Paradis R, Morales-Castro D, Urner M, Goffi A, Dragoi L, et al. Point-of-Care Ultrasound: A Case Series of Potential Pitfalls. *CASE (Philadelphia, Pa)*. 2022;6(6):284-92. <https://doi.org/10.1016/j.case.2022.05.002>.
- Khosravian K, Boniface K, Dearing E, Drake A, Ogle K, Pyle M, et al. eFAST exam errors at a level 1 trauma center: A retrospective cohort study. *Am J Emerg Med*. 2021;49:393-8. <https://doi.org/10.1016/j.ajem.2021.07.036>.
- Lewiss RE, Cook J, Sauler A, Avitabile N, Kaban NL, Rabrich J, et al. A workflow task force affects emergency physician compliance for point-of-care ultrasound documentation and billing. *Crit Ultrasound J*. 2016;8(1):5. <https://doi.org/10.1186/s13089-016-0041-0>.
- Melton M, Rupp JD, Blatt MI, Boyd JS, Barrett TW, Swarm M, et al. Ultrasound Documentation Compliance in an Academic Emergency Department. *Cureus*. 2021;13(7):e16199. <https://doi.org/10.7759/cureus.16199>.
- Thompson B, Schoenfeld E, Westafer L, Visintainer P, Budhram G. Implementation of an automated, user-centered point-of-care ultrasound workflow improves documentation and billing. *Acad Emerg Med*. 2023;30(3):180-6. <https://doi.org/10.1111/acem.14654>.
- Singh MR, Jackson JS, Newberry MA, Riopelle C, Tran VH, PoSaw LL. Barriers to point-of-care ultrasound utilization during cardiac arrest in the emergency department: a regional survey of emergency physicians. *The American Journal of Emergency Medicine*. 2021;41:28-34. <https://doi.org/https://doi.org/10.1016/j.ajem.2020.12.040>.
- Kumar S, Kumar A, Joshi MK, Rathi V. Comparison of diagnostic peritoneal lavage and focused assessment by sonography in trauma as an adjunct to primary survey in torso trauma: a prospective randomized clinical trial. *Ulus Travma Acil Cerrahi Derg*. 2014;20(2):101-6. <https://doi.org/10.5505/tjtes.2014.37336>.
- Rice JA, Brewer J, Speaks T, Choi C, Lahsaei P, Romito BT. The POCUS Consult: How Point of Care Ultrasound Helps Guide Medical Decision Making. *Int J Gen Med*. 2021;14:9789-806. <https://doi.org/10.2147/ijgm.S339476>.
- Hansen W, Mitchell CE, Bhattarai B, Ayutyanont N, Stowell JR. Perception of point-of-care ultrasound performed by emergency medicine physicians. *J Clin Ultrasound*. 2017;45(7):408-15. <https://doi.org/10.1002/jcu.22443>.
- Leschyna M, Hatam E, Britton S, Myslik F, Thompson D, Sedran R, et al. Current State of Point-of-care Ultrasound Usage in Canadian Emergency Departments. *Cureus*. 2019;11(3):e4246. <https://doi.org/10.7759/cureus.4246>.

# Venous Excess Ultrasound (VExUS) Grading to Assess Perioperative Fluid Status for Noncardiac Surgeries: a Prospective Observational Pilot Study

Justin C. Magin, BS<sup>1\*</sup>; Jacob R. Wrobel, BS<sup>1</sup>; Xinming An, PhD<sup>2</sup>; Jacob Acton, MD<sup>2</sup>; Alexander Doyal, MD, MPH,<sup>2</sup>; Shawn Jia, MD<sup>2</sup>; James C. Krakowski, MD<sup>2</sup>; Jay Schoenherr, MD<sup>2</sup>; Ricardo Serrano MD<sup>2</sup>; David Flynn, MD<sup>2</sup>; Duncan McLean, MBChB<sup>2</sup>; Stuart A. Grant, MBChB<sup>2</sup>

(1) University of North Carolina School of Medicine, Chapel Hill, NC, USA  
(2) University of North Carolina Department of Anesthesiology, Chapel Hill, NC, USA

## Abstract

**Objectives:** Perioperative fluid administration impacts the rate of complications following surgery. VExUS grading system is a standardized point of care ultrasound (POCUS)-based, comprehensive method to assess volume status. VExUS could serve as a tool to guide fluid management, if validated perioperatively. The primary aim was to assess the success rate of obtaining required windows for VExUS grading, as well as the feasibility within a perioperative setting among noncardiac surgery. Further, this study describes the incidence of perioperative venous congestion and associations with 30-day postoperative complications. **Methods:** This observational study was conducted in non-critically ill adults undergoing noncardiac surgery. Patients were scanned preoperatively, in the post anesthesia care unit (PACU), and 24 hours postoperatively for venous congestion. Researchers retrospectively captured 30-day complications for multivariate analyses. **Results:** The cohort included 69 participants. Ninety-one percent of scans over all timepoints were successfully completed. Pre-operatively, 57 (83%) scans were Grade 0, and 11 (16%) were Grade 1. Venous congestion was observed in 29 (44%) patients in the PACU ( $n=66$ ). 22 (33%) patients were Grade 1, while 7 (11%) were Grade 2. At 24 hours ( $n=63$ ), 31 patients (49%) had venous congestion: 20 (32%) Grade 1 and 11 (17%) Grade 2. Of the pre-operative Grade 0, 28 (50%) had at least one postoperative scan with venous congestion. No patients were Grade 3 at any timepoint. The 30-day complication rate was 32% ( $n=22$ ). Eleven (16%) patients developed acute kidney injury (AKI). There was no statistically significant association between VExUS grading and all-cause complications or AKI. **Conclusion:** This study demonstrates that perioperative VExUS scoring is a feasible tool among a variety of noncardiac surgeries. We highlight that venous congestion is common and increases postoperatively within non-ICU populations. Larger studies are needed to assess the relationship between VExUS grading and postoperative complications.

## Introduction

### *Developing an Understanding of Volume Status*

Despite significant improvements in perioperative safety, surgery continues to carry significant risks of major morbidity and mortality. Moreover, 30-day complication rates following major abdominal surgery range between 5.8-43.5% [1].

Perioperative fluid administration can impact the rate of complications following surgery. Hypovolemia is common due to 8-hour fasts before surgery, intraoperative blood loss, and evaporative losses that occur during surgery [2]. However, excessive fluid administration can lead to hypervolemia, precipitating organ dysfunction, respiratory

failure, and delayed wound healing [2,3]. Implementing enhanced recovery after surgery (ERAS) pathways has been associated with improved surgical outcomes and decreased length of stay [2]. Though these methods may improve care on the population level, it is unclear how often patients experience hypo- or hypervolemia following surgery.

Current volume status assessments via physical exam, urine output, and vital signs are poor. Quantitative assessment is traditionally performed through invasive measurement via central venous or pulmonary artery catheters. Echocardiography can be used to estimate volume status, but the application of perioperative transesophageal echocardiography remains primarily

\*Corresponding Author: Justin C. Magin (email: Justin\_magin@med.unc.edu)

This work is licensed under a [Creative Commons Attribution 4.0 International License](https://creativecommons.org/licenses/by/4.0/).

Author(s) retain the copyright for their work. At the time of submission to POCUS Journal the author(s) grant the journal a limited and non-revokable right to publish in the Journal under a [Creative Commons Attribution 4.0 International License](https://creativecommons.org/licenses/by/4.0/).

DOI: <https://doi.org/10.24908/pocus.v8i2.16792>

limited to cardiac surgery. Furthermore, noninvasive ultrasound measurement of the inferior vena cava (IVC) collapsibility does not reliably capture hypervolemia.

### *The emergence of POCUS techniques*

Point of care ultrasound (POCUS) is expanding due to the decreased cost of diagnostic ultrasound machines. In critical care, heart, lung, and venous protocols have been described to identify fluid imbalances [4,5]. POCUS has improved the fluid assessment and has even influenced decisions that significantly decreased volume status and ventilator dependence [6].

The venous excess ultrasound (VExUS) grading protocol is a standardized POCUS-based method that incorporates measurements of the IVC along with Doppler scans of the portal, hepatic, and intrarenal veins. The IVC measurement and Doppler scans correlate to minimal, moderate, severe, or no venous congestion. High VExUS scores have been associated with acute kidney injury after cardiac surgeries [7]. Further, VExUS has been used in ICUs to guide clinical decision-making in patients experiencing clinical deterioration [8] and recently showed that patients who had a reduction in VExUS score did clinically better in terms of having more renal replacement therapy-free days in an ICU population [9]. However, VExUS grading has yet to be studied immediately around noncardiac surgery. VExUS ultrasound views might not be obtainable in the perioperative period following open and laparoscopic abdominal surgery because abdominal gas deteriorates ultrasound imaging. VExUS, if practical in the immediate postoperative period and validated in a clinical setting, could provide a noninvasive, individualized method to optimize fluid management in surgical patients.

We hypothesized that after losing the tight control of fluid administration in the operating room, a percentage of patients would develop volume overload over time. This study's main aim was to evaluate if VExUS windows are possible to obtain perioperatively following abdominal surgeries and subsequently assess both venous congestion and the incidence of volume overload. Secondly, our study assessed the risk of surgical complications with the incidence of venous congestion by VExUS grade in the pre-operative, immediate postoperative, and 24-hour postoperative time intervals.

### **Methods**

We conducted a single center, prospective study enrolling non-critically ill adults 18 years and older undergoing gynecologic, thoracic, urologic, laparoscopic colorectal, or vascular surgery at the University of North Carolina Medical Center from June 1, 2022 to August 1, 2022. We obtained institutional review board (IRB) approval in April 2022 and operated under institutional

guidelines. A written informed consent and HIPAA Authorization form was completed for each enrolled patient. VExUS scans were performed using a Kosmos Ultraportable Torso-One device (Echonus Inc. Bothell WA) or a Fujifilm Sonosite LX device (Fujifilm Sonosite Inc. Bothell WA). Patients with pre-surgical AKI, delirium, portal thrombus, end-stage cirrhosis, as well as those undergoing cardiac surgery or open exploratory laparotomy abdominal surgery were excluded.

Non-mechanically ventilated subjects received VExUS protocol-guided ultrasound scanning pre-operatively, postoperatively (0-6 hours after surgery, in PACU), and approximately 24 hours postoperatively (18-30 hours after surgery). An operator did a qualitative cardiac scan with a phased array probe on cardiac preset before each VExUS scan to assess for obvious right ventricle dysfunction or other major cardiac abnormalities. EKGs were not regularly completed with VExUS scans, since the study scanned amongst routine clinical care downtime. Scans were completed using the curvilinear probe or the abdominal preset depending on whether the Echonus portable probe or Sonosite was used, respectively. The operator first attempted to visualize IVC in the subxiphoid window but then would elect for midaxillary, if necessary. The IVC was viewed in long axis with special attention taken to observe widest perpendicular diameter. The hepatic, portal, and intrarenal veins were visualized in the midaxillary window. Focused effort was made to scan the main hepatic, main portal, and interlobar renal veins and not the possible other branches of each respective vessel. To obtain sufficient doppler signals, breath holding was conducted by the participant to stabilize the diaphragm and secure adequate windows. This brief breath holding was done at various points throughout the respiratory cycle depending on what would elicit the best anatomical views for using doppler. Scans were completed by medical students that have undergone thorough POCUS training through scholarly concentration and operated under the guidance of anesthesiologists. Before conducting the study, adequate institutional training, and experience on obtaining views and assessing sufficiency of doppler was performed. Although all members are thoroughly trained in ultrasound, no physicians hold unique certifications. VExUS grades were confirmed by two operators. Any discrepancy in scoring was decided by a third interpretation, the principal investigator. We collected patients' ASA Physical classification scores [10] and 30-day complications were observed according to ACS NSQIP definitions [11] and measured using the ACS NSQIP risk calculator [12]. Postoperative complications were confirmed by electronic medical record chart review after at least 30 days from operative date. AKI was defined according to KDIGO as SCr

>0.3mg/dl from baseline within 48hr, greater than or equal to 1.5 times baseline SCr within 7 days, or urine output less than 0.5mL/kg/hr for greater than 6 hours [13]. Notably, the National Institutes of Health supported funding for this study with grant number T35-DK007386.

### Statistical Analysis

Previous pilot data around gastric ultrasound scanning identified initial success rates up to 68% and that with training scanning could reach 95% success rate [14,15]. With this in mind, we defined feasibility as postoperative scanning success of 95% or better. VExUS grades were treated as ordinal variables in the R code, and the Kruskal-Wallis rank sum test was used to test the association. Scans that were not scorable were excluded from the analyses. A P-value of 0.05 was used to determine statistical significance. This manuscript adheres to the applicable CONSORT/STROBE guidelines.

### Ethics

Ethical approval for this study (IRB number 22-0796) was provided by the Institutional Review Board Committee at the University of North Carolina, Chapel Hill, North Carolina, United States (Approved by Sherry Whittaker) on 20 May 2022.

## Results

### Demographics and Practicality

Seventy-six patients were approached for this study, of which 69 consented and enrolled. The median age of the cohort was 62 (range 19, 88). Forty-one (59%) identified as female, and 46 (67%) identified as white. The cohort's median BMI was 28 (range 16, 44). Additional demographic data are presented in Table 1. VExUS scanning was successfully completed across all three timepoints in 91% of patients. Over the three timepoints, only 12 scans could not be scored. In the immediate postoperative period, 66 (96%) scans were successfully graded, and only three scans could not be obtained: one due to intra-abdominal gas accumulation after a laparoscopic procedure and two due to patient refusal in the setting of poorly controlled pain. At the 24-hour timepoint, 63 (91%) were successfully graded and scans were not obtained on six patients. One due to intra-abdominal gas and five due to early patient discharge. The two scans that were unable to be scored due to intra-abdominal gas were both due to inability to measure the IVC. In scans where the IVC could be measured, we were able to complete all other views successfully. Excluding the early discharges, at 24-hour timepoint, 63 (98%) of the 64 non-discharged patients were successfully scanned. The median calculated NSQIP risk score for any 30-day complication was 10.9%, along with a calculated risk for serious 30-day complications of 9.6%.

Table 1. Demographic and Clinical Characteristics in the Overall Study Cohort

	Entire Cohort (N = 69)
Age	62 (48, 67)
Female	41 (59%)
Race	
Black	18 (26%)
White	46 (67%)
Other	5 (7%)
BMI	28 (24, 32)
Length of Stay, days	2 (1, 4)
Median Baseline Serum Creatinine, mg/dL	0.89 (0.7, 1.1)
ASA	3 (3, 3)
NSQIP risk, mean	10.9%
NSQIP serious risk, mean	9.6%
Any 30-day complication	22 (32%)
*IQR within parentheses unless otherwise specified	

### Incidence of Volume Overload

The incidence of congestion on individual scanning views is described in Supplemental Table 1-3. Of the 69 scans obtained pre-operatively, 13 (19%) had positive VExUS grades. Of these, 12 (92%) were identified as mild congestion (Grade 1) and one as moderate (Grade 2). Of the 66 available PACU scans, positive VExUS grades were observed in 29 (44%) patients. Twenty-two (33%) had mild congestion, while 7 (11%) had moderate congestion. Figure 1 highlights an example of mild venous congestion in the PACU. Of the 63 patients that received a 24-hour scan, nearly half (31 patients) had evidence of venous congestion based on VExUS score. Of these, 20 patients had mild congestion (Grade 1) and 11 had moderate congestion (Grade 2). No patients were assessed to have VExUS Grade 3, indicating severe congestion. General VExUS grading increased over time, as shown in Figure 2. Of the 56 patients with Grade 0 before surgery, 28 (50%) had at least one scan indicating venous congestion post-operatively. The incidence of Grade 2 congestion was highest at the 24-hour timepoint ( $n=11$ , 17%), and of those, 10 (91%) were due to severe pulsatile congestion observed in the portal vein.

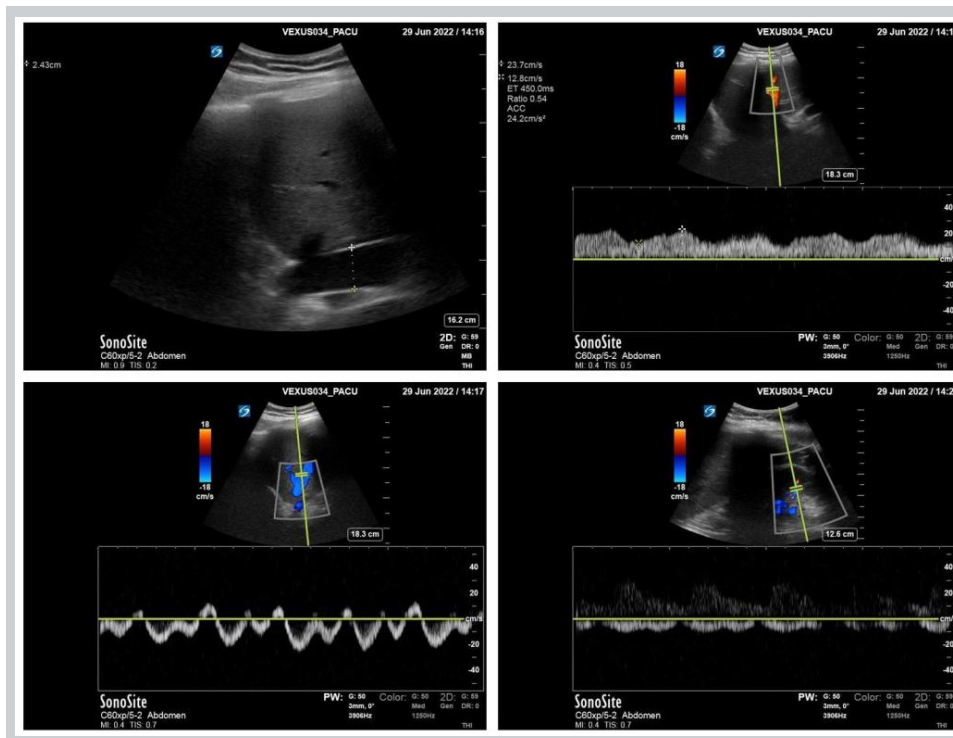


Figure 1. Example of a PACU VExUS scan with Grade 1: mild congestion. A) IVC measured at 2.43 cm through hepatic window. B) Doppler waveform on hepatic vein. C) Doppler waveform of portal vein with pulsatility measurement. D) Doppler waveform on intrarenal vein.

**Outcomes, Complications, and Statistical Analysis**

Of the 69 patients, 22 (32%) had at least one 30-day complication. Eleven (16%) individuals met the criteria for postoperative AKI, and 8 (72%) of the 11 were either partial or radical nephrectomies. Other complications included 5 (7%) readmissions, 4 (6%) surgical site infections, 3 (4%) return to OR, 3 (4%) post-op hemorrhages, 1 (1%) pulmonary embolism, and 2 (3%) episodes of cardiac arrest with one resulting in death (1%).

VExUS grade at the scanning period was assessed for an association with postoperative 30-day complications as well as AKI, individually. However, no statistically significant association was observed between grading and complications or AKI (Table 2-3). Moreover, no covariates (age, sex, race, LOS, ASA) had a statistically significant association with complications (Table 2-3). VExUS grading

scores of those with and without complications over the three scanning timepoints are depicted in Figures 3-4.

**Discussion**

Our study demonstrates that the VExUS grading system can be used to assess perioperative intravascular volume status in patients undergoing abdominal surgery. Our results indicate that venous congestion is common following surgery, increasing at 24 hours compared to the immediate postoperative period. Our study did not demonstrate an association between VExUS grade and 30-day complications.

The current literature on VExUS use is scant and mainly revolves around feasibility at the bedside in critical care settings or by nephrologists. Beaubien-Souligny *et al.* described the first specifically post-surgical use of VExUS in the ICU after cardiac surgeries. They demonstrated the association of higher VExUS grades with an increased risk of AKI [8]. Similar studies in intensive care settings have shown that VExUS can predict adverse kidney events and aid decision-making on whether to continue volume depletion in cardiorenal syndrome [16,17].

It was previously uncertain whether VExUS could be used in the PACU and surgical floors so soon after a wide scope of surgeries. This study exceeded the predefined feasibility target metric of 95% completed scans postoperatively. Thus, we confirm the feasibility and utility of VExUS use by anesthesiologists in this perioperative setting for noncardiac surgery patients. We found that VExUS grading could be successfully

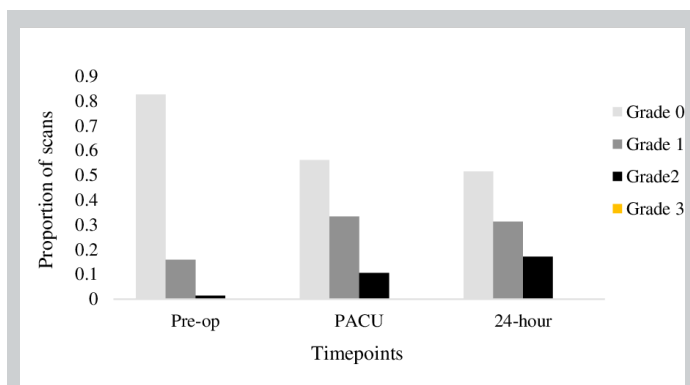


Figure 2. VExUS grading scores over study timepoints.



Table 2. VExUS scores associations with 30-day complications

	No Complication (n=47)	Any Complication (n=22)	Overall (N=69)	P-value
Pre-op VExUS <sup>a</sup> – mean (SD)	0.23 (0.48)	0.09 (0.30)	0.19 (0.43)	0.436
PACU <sup>b</sup> VExUS <sup>a</sup> –mean (SD)	0.47 (0.65)	0.70 (0.73)	0.54 (0.68)	0.444
24-hr VExUS <sup>a</sup> – mean (SD)	0.65 (0.75)	0.67 (0.80)	0.66 (0.76)	0.997
Age–median [IQR]	63 [50, 68]	58 [41, 66]	62 [48, 67]	0.490
<b>Sex</b>				
Female	31 (66%)	10 (46%)	41 (59%)	0.271
Male	16 (34%)	12 (54%)	28 (41%)	
<b>Race</b>				
Black	12 (25%)	6 (27%)	18 (26%)	
White	30 (64%)	16 (73%)	46 (67%)	
Other	5 (11%)	0 (0%)	5 (7%)	
ASA score- mean (SD)	2.8 (0.51)	2.7 (0.70)	2.8 (0.57)	0.922
Length of Stay - mean (SD)	2.7 (2.0)	3.7 (2.8)	3.0 (2.3)	0.216

<sup>a</sup>VExUS- venous excess ultrasound score  
<sup>b</sup>PACU- post-anaesthesia care unit

performed on most patients pre-operatively, in the post-anaesthesia care unit (PACU), and the day after surgery. Moreover, each scanning session took under 10 minutes, was well-received by patients, and did not lead to delays in the pre- or postoperative holding areas. Although not an objective aim of the study, both ultrasound devices were sufficient in quality and feasibility of obtained images. Due to the larger screen and ease in seeing smaller vessels, we did elect to use the Sonosite more towards the end of the study. Venous congestion was common, occurring in 44% of patients in the PACU and 49% of patients 24 hours after surgery. Mild and

moderate venous congestion has been associated with increased kidney injury, but the true extent of this risk is unknown. These findings suggest that perioperative fluid management may be excessive in some patients, and further refinement of goal-directed fluid management protocols at our institution is warranted.

We did not observe an association between positive VExUS grades and perioperative complications. However, we studied a heterogeneous group of surgical procedures and looked at 30-day postoperative surgical complications. Moreover, we used a convenience sample for this feasibility study, which lacked the power to detect

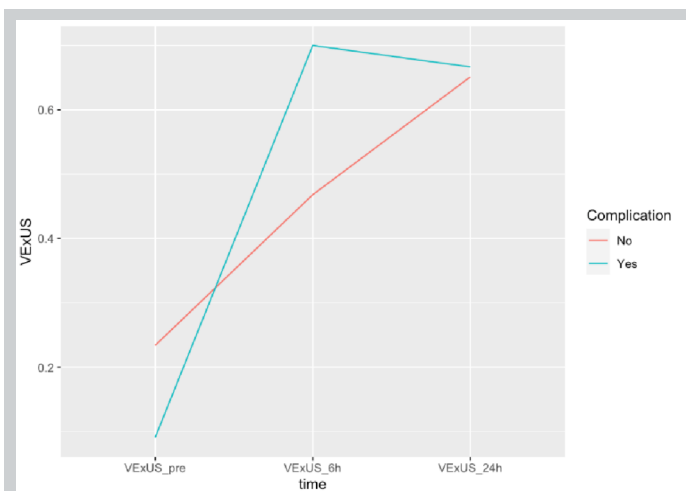


Figure 3. Ordinal VExUS grades over study timepoints stratified by all-cause 30-day complications cohort and no complication cohort

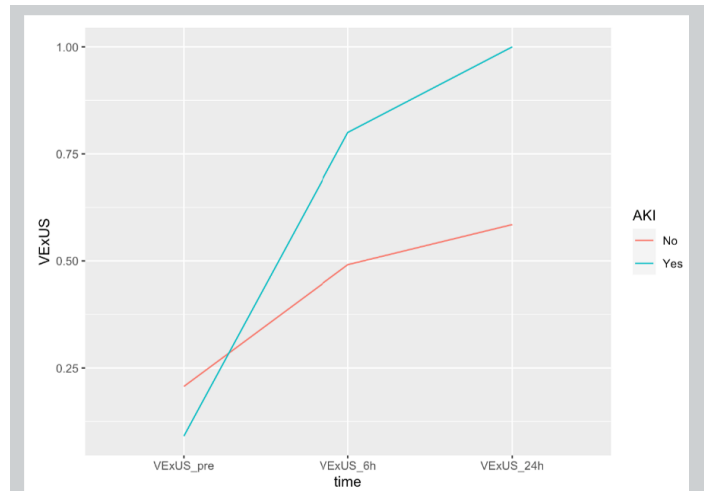


Figure 4. Ordinal VExUS grades over study timepoints stratified by AKI cohort and no AKI cohort

Table 3. VExUS scores associations with AKI outcome

	No Complication (n=58)	Any Complication (n=11)	Overall (N=69)	P-value
Pre-op VExUS – mean (SD)	0.21 (0.45)	0.09 (0.30)	0.19 (0.43)	0.715
PACU VExUS – mean (SD)	0.49 (0.66)	0.80 (0.79)	0.54 (0.68)	0.418
24-hr VExUS – mean (SD)	0.59 (0.75)	1.00 (0.78)	0.66 (0.76)	0.256
Age–median [IQR]	62 [49, 67]	62 [44, 67]	62 [48, 67]	0.961
<b>Sex</b>				0.236
Female	37 (64%)	4 (36%)	41 (59%)	
Male	21 (36%)	7 (64%)	28 (41%)	
<b>Race</b>				
Black	15 (26%)	3 (27%)	18 (26%)	
White	38 (66%)	8 (73%)	46 (67%)	
Other	5 (8%)	0 (0%)	5 (7%)	
ASA- mean (SD)	2.8 (0.55)	2.6 (0.67)	2.8 (0.57)	0.708
Length of Stay - mean (SD)	2.9 (2.1)	3.6 (3.4)	3.0 (2.3)	0.688
<sup>a</sup> VExUS- venous excess ultrasound score				
<sup>b</sup> PACU- post-anaesthesia care unit				

meaningful differences. A prospective study sufficiently powered that would intervene when positive VExUS scans were discovered requires hundreds of patients if the complication rate was similar to our 30%. Also, at this stage the definitive effective interventions after positive VExUS scans following abdominal surgery are not yet understood. A prospective randomized intervention study would be important because of the large number of major abdominal surgeries performed each year. The results presented here do fall in line similarly with a 150 subject, prospective general ICU cohort that also did not see associations with AKI or month long outcomes [18]. This was also probably underpowered for this outcome.

Our study is limited by the narrow study window. Further, our secondary complication outcomes are limited by relatively small sample size for such generalizable outcomes. Moreover, due to the potential ambiguity of Doppler scanning results, there is a possibility for bias in the grading based on other clinical presentations at the time of scanning. However, we mitigated this risk by using two individuals for scanning who came to a consensus on all grades.

Limitations of the VExUS scans are present at various parts of the protocol. For instance, hepatic vein flow can be affected by tricuspid insufficiency [19], while intrarenal vein waveform can be challenging to capture and is the most common reason for failed scoring. Moreover, although we were attuned to common pitfalls with hepatic vein interpretations, since we did not use ECG tracing with hepatic veins there could be episodes of error with

interpretation of doppler wave patterns thus introducing further limitations to this study. Although the qualitative cardiac views would have detected significant right ventricle (RV) or tricuspid dysfunction, we cannot be certain that no patients had tricuspid or RV pathology that may have impacted VExUS grading. Portal vein pulsatility can be seen without underlying pathology in an inverse relationship to body mass and thus could cause higher skewed scoring to occur [20]. At the 24-hour timepoint, 91% of the Grade 2 scores were due to portal vein pulsatility. Yet, the portal vein pulsatility could be due to iatrogenic causes such as increased abdominal pressure from laparoscopic procedures causing pulsatile mimicry or unnoticed interference from the hepatic artery.

### Conclusion

This study demonstrates that the VExUS protocol is feasible and can be performed by anesthesiologists to assess venous congestion in noncardiac surgery during the perioperative period. Further, this study demonstrates that venous congestion increases following abdominal surgery and venous congestion is a problem that should be considered beyond cardiac surgery or in an ICU. In the future, larger studies should be performed to evaluate the impact of venous congestion on perioperative complications. Additional research should be conducted to determine if VExUS can be used not only as a diagnostic tool but for patient intervention in the perioperative period to target fluid administration or diuresis.

## Acknowledgements

The National Institutes of Health, by way of the National Institute of Diabetes and Digestive and Kidney Diseases, supported funding for this study with grant number T35-DK007386.

This study was previously presented, in part, at 2023 IARS Conference Denver, CO.

## Disclosures

The authors report no conflicts of interest related to this work.

## References

1. Tevis SE, Kennedy GD. Postoperative complications and implications on patient-centered outcomes. *J Surg Res.* 2013;181(1):106-113. doi:10.1016/j.jss.2013.01.032
2. Kendrick JB, Kaye AD, Tong Y, et al. Goal-directed fluid therapy in the perioperative setting. *J Anaesthesiol Clin Pharmacol.* 2019;35(Suppl 1):S29-S34. doi:10.4103/joacp.JOACP\_26\_18
3. Van Dessel E, Moons J, Naftoux P, et al. Perioperative fluid management in esophagectomy for cancer and its relation to postoperative respiratory complications. *Dis Esophagus.* 2021;34(7):doaa111. doi:10.1093/dote/doaa111
4. Lichtenstein DA. BLUE-Protocol and FALLS-Protocol: Two Applications of Lung Ultrasound in the Critically Ill. *Chest.* 2015;147(6):1659-1670. doi:10.1378/chest.14-1313
5. Robba C, Wong A, Poole D, et al. Basic ultrasound head-to-toe skills for intensivists in the general and neuro intensive care unit population: consensus and expert recommendations of the European Society of Intensive Care Medicine. *Intensive Care Med.* 2021;47(12):1347-1367. doi:10.1007/s00134-021-06486-z
6. Pontet J, Yic C, Díaz-Gómez JL, et al. Impact of an ultrasound-driven diagnostic protocol at early intensive-care stay: a randomized-controlled trial. *Ultrasound J.* 2019;11:24. doi:10.1186/s13089-019-0139-2
7. Beaubien-Souligny W, Rola P, Haycock K, et al. Quantifying systemic congestion with Point-Of-Care ultrasound: development of the venous excess ultrasound grading system. *Ultrasound J.* 2020;12:16. doi:10.1186/s13089-020-00163-w
8. Rola P, Miralles-Aguiar F, Argaiz E, et al. Clinical applications of the venous excess ultrasound (VExUS) score: conceptual review and case series. *Ultrasound J.* 2021;13(1):32. doi:10.1186/s13089-021-00232-8
9. Rihl MF, Pellegrini JAS, Boniatti MM. VExUS Score in the Management of Patients With Acute Kidney Injury in the Intensive Care Unit. *J Ultrasound Med.* n/a(n/a). doi:10.1002/jum.16288
10. ASA Physical Status Classification System. Accessed January 25, 2022. <https://www.asahq.org/standards-and-guidelines/asa-physical-status-classification-system>
11. Cohen ME, Bilimoria KY, Ko CY, Hall BL. Development of an American College of Surgeons National Surgery Quality Improvement Program: Morbidity and Mortality Risk Calculator for Colorectal Surgery. *J Am Coll Surg.* 2009;208(6):1009-1016. doi:10.1016/j.jamcollsurg.2009.01.043
12. ACS NSQIP Surgical Risk Calculator.
13. Acute Kidney Injury (AKI) – KDIGO. Accessed October 20, 2023. <https://kdigo.org/guidelines/acute-kidney-injury/>
14. Perlas A, Chan VWS, Lupu CM, Mitsakakis N, Hanbidge A. Ultrasound Assessment of Gastric Content and Volume. *Anesthesiology.* 2009;111(1):82-89. doi:10.1097/ALN.0b013e3181a97250
15. Zhang G, Huang X, Shui Y, Luo C, Zhang L. Ultrasound to guide the individual medical decision by evaluating the gastric contents and risk of aspiration: A literature review. *Asian J Surg.* 2020;43(12):1142-1148. doi:10.1016/j.asjsur.2020.02.008
16. Bhardwaj V, Vikneswaran G, Rola P, et al. Combination of Inferior Vena Cava Diameter, Hepatic Venous Flow, and Portal Vein Pulsatility Index: Venous Excess Ultrasound Score (VEXUS Score) in Predicting Acute Kidney Injury in Patients with Cardiorenal Syndrome: A Prospective Cohort Study. *Indian J Crit Care Med Peer-Rev Off Publ Indian Soc Crit Care Med.* 2020;24(9):783-789. doi:10.5005/jp-journals-10071-23570
17. Spiegel R, Teeter W, Sullivan S, et al. The use of venous Doppler to predict adverse kidney events in a general ICU cohort. *Crit Care Lond Engl.* 2020;24(1):615. doi:10.1186/s13054-020-03330-6
18. Andrei S, Bahr PA, Nguyen M, Bouhemad B, Guinot PG. Prevalence of systemic venous congestion assessed by Venous Excess Ultrasound Grading System (VEXUS) and association with acute kidney injury in a general ICU cohort: a prospective multicentric study. *Crit Care.* 2023;27(1):224. doi:10.1186/s13054-023-04524-4
19. Scheinfeld MH, Bilali A, Koenigsberg M. Understanding the spectral Doppler waveform of the hepatic veins in health and disease. *Radiogr Rev Publ Radiol Soc N Am Inc.* 2009;29(7):2081-2098. doi:10.1148/rg.297095715
20. Gallix BP, Taourel P, Dauzat M, Bruel JM, Lafortune M. Flow pulsatility in the portal venous system: a study of Doppler sonography in healthy adults. *AJR Am J Roentgenol.* 1997;169(1):141-144. doi:10.2214/ajr.169.1.9207514

# Effectiveness of Ultrasound-guided versus Landmark-based Glucocorticoid Injection in the Treatment of First Carpometacarpal Joint Osteoarthritis

Shamma Ahmad Al-Nokhatha, MD<sup>1,2,3\*</sup>; Sinead Maguire, MD<sup>1</sup>; Luke Corcoran, MD<sup>1</sup>; Neil Mac Eoin, MD<sup>1</sup>; Richard Conway, MB BCh BAO, PhD, CCD, FRCPI<sup>1</sup>; Ciaran Johnson, MB, FFR RCSI, FRCR (UK)<sup>4</sup>

- (1) Department of Rheumatology, St. James's Hospital, Dublin, Ireland  
 (2) Department of Rheumatology, Tawam Hospital, Al Ain, United Arab Emirates  
 (3) College of Medicine and Health Sciences, UAE University, Al Ain, United Arab Emirates  
 (4) Department of Radiology, St. James's Hospital, Dublin, Ireland

## Abstract

**Background:** Osteoarthritis is a debilitating degenerative disease more pronounced in elderly affecting many joints. The first carpometacarpal joint (CMC1) is commonly affected. Pain is the major complaint, which can impact patient's daily activities. Intra-articular glucocorticoid injection can be considered if conservative measures fail and ultrasound guided injection might be superior to the traditional anatomic landmark-guided technique. **Objective:** The aim of this study is to evaluate the effectiveness of ultrasound-guided versus landmark-based approach to intra-articular CMC1 injection using the Australian Canadian osteoarthritis hand index (AUSCAN). **Methods:** Adult patients diagnosed with symptomatic CMC1 osteoarthritis who failed conservative measures were enrolled. In this prospective observational cohort study, utilizing a convenience sample, intra-articular corticosteroid injection was administered either by ultrasound-guided technique or landmark-based approach. Pain, stiffness and function in 10-points scale at baseline, 6 and 12 weeks were collected and analyzed using descriptive analysis. **Results:** There were 33 patients enrolled. Mean age was 63 years, with females making up the majority of participants (n = 28, 84.8%). Mean duration of CMC1 pain was 10 months (SD=2.5) up to the point of receiving the injection. Ultrasound guided injection was performed in 60.6% (n=20), while 39.4% (n=13) had the landmark approach. Both groups achieved a statistically and clinically significant level of change in AUSCAN score at week 6 ( $P \leq 0.05$ ) but with a recurrence of symptoms at week 12 ( $P \leq 0.05$ ). At both intervals the AUSCAN scores were better than baseline ( $P \leq 0.05$ ). There was no difference between the two groups regarding baseline pain VAS score (mean ultrasound group= 6.6 vs landmark group= 7.5;  $P = 0.18$ ). No significant differences were identified between two groups in terms of changes from baseline to 6, 12 and between 6 to 12 weeks in pain, stiffness and hand function ( $P > 0.05$ ). **Conclusion:** No difference was found between the ultrasound-guided and landmark-based approaches for CMC1 injection on pain score, stiffness, or function.

## Background

Osteoarthritis (OA) is a debilitating degenerative disease that affects many joints. The carpometacarpal is one of the commonly affected sites (Figure 1). Pain in particular is a major component and this can significantly impact patients' activities of daily living [1]. The prevalence of symptomatic thumb OA as recorded by the Framingham study is 2.7% and 5% for males and females, respectively. More recent studies have reported a prevalence of erosive OA of the first CMC (CMC1) of 2.2% [2,3]. According to the recent 2019 American College of Rheumatology and Arthritis Foundation guidelines, in patients who fail non-pharmacological

management, medication can be considered, among which intra-articular glucocorticoid injection is noted to be more efficacious in comparison to other compounds. Ultrasound (US) guidance can facilitate the accuracy at the target point, which may improve outcomes [4]. The aim of this study is to evaluate the effectiveness of ultrasound-guided compared to landmark-based intra-articular injection of CMC1.

## Methods

A prospective, observational cohort study was conducted at St James's hospital in Ireland between January and July 2021. The study employed a convenience sample,

\*Corresponding Author: Dr. Shamma Al Nokhatha (email: shamma.alnokhatha@gmail.com)

This work is licensed under a [Creative Commons Attribution 4.0 International License](https://creativecommons.org/licenses/by/4.0/).

Author(s) retain the copyright for their work. At the time of submission to POCUS Journal the author(s) grant the journal a limited and non-revokable right to publish in the Journal under a [Creative Commons Attribution 4.0 International License](https://creativecommons.org/licenses/by/4.0/).

DOI: <https://doi.org/10.24908/pocus.v8i2.16594>

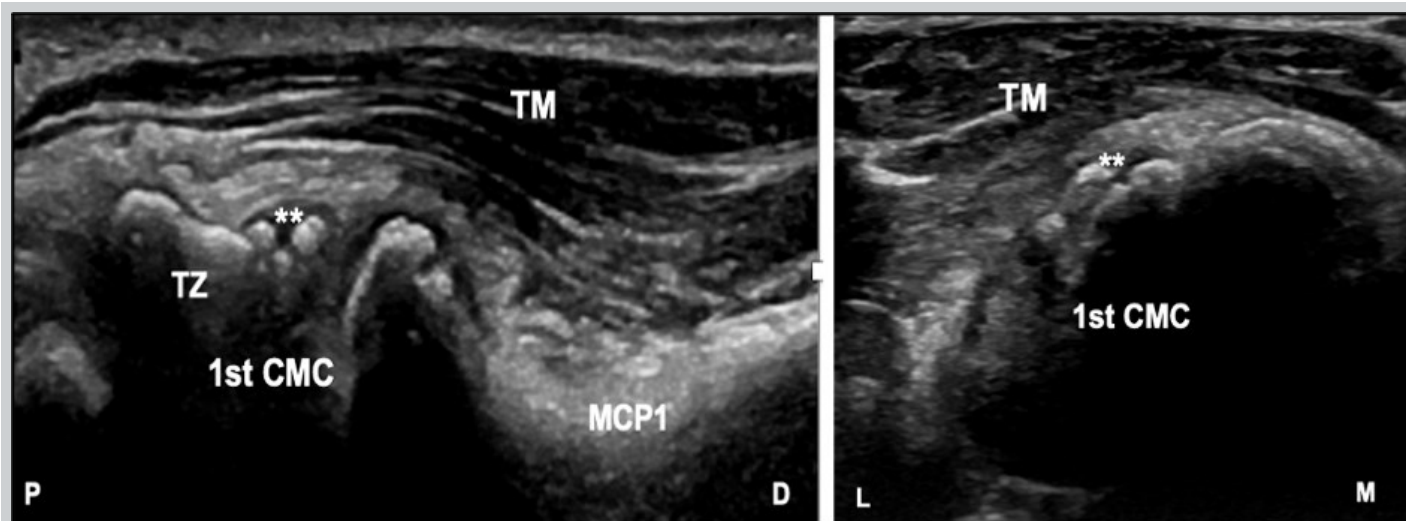


Figure 1. Transverse (right) and longitudinal (left) scans of the left first CMC demonstrating osteophytes \*\*. Thenar muscle (TM), First metacarpal bone (MCP1), Trapezium (TZ), L: lateral, M: medial, P, proximal, D, distal.

comprising patients from the dedicated patient lists of two expert doctors who routinely perform therapeutic injections. Ethical approval was obtained from the St James' and Tallaght Hospital Joint Ethics Committee. To be included the following inclusion criteria was required of all participants: adults (aged  $\geq 18$  years) diagnosed with symptomatic first CMC osteoarthritis with Eaton-Littler stage 2 and greater [5] who had failed conservative measures such as anti-inflammatory treatment and occupational therapy, with or without splint usage). Those who had received a glucocorticoid injection in the past three months were excluded. All injections consisted of 20mg of depomedrone with a local anesthetic (0.5 ml 1% lidocaine). One of two techniques were performed: the landmark approach, which involved identifying the anatomical landmarks for the carpometacarpal joint, and the ultrasound-guided technique (using GE Logiq P9 machine). Demographic, smoking history and employment data were collected at the time of injection. Participants completed the Visual Analogue Scale (VAS) for pain severity assessment (range: 0-10) and the Australian Canadian Osteoarthritis Hand Index (AUSCAN) questionnaire, which assessed hand pain, stiffness and function on a scale of 0 to 10. This questionnaire was completed by all participants at baseline, 6 weeks and 12 weeks, which aligns with the average duration of injection's effect [6,7].

#### Statistical analysis

Data were entered into JASP software and then were analyzed. The efficacy of the two methods were compared based on the pain severity, stiffness, and function of the patient using t-tests and ANOVA. The relation between qualitative variables was assessed using chi-squared tests.

#### Results

There were 33 patients enrolled in this study. The mean age was 63 years (SD = 9.5). There was a higher proportion of females (84.8%,  $n = 28$ ) compared to males. At the time of injection majority (81.8%,  $n = 27$ ) were unemployed, and (72.7%,  $n = 24$ ) were non-smokers. One patient was left-handed (3%) while the rest were right-handed ( $n = 32$ , 97%). The mean duration of CMC1 pain was 10 months (SD = 2.5). There was no difference in baseline pain VAS scores between the two groups (mean US group = 6.6 vs landmark group = 7.5;  $P = 0.18$ ).

Over one third of the participants (36.4%,  $n = 12$ ) did not use a hand splint and, 45.5% ( $n = 15$ ) had a previous glucocorticoid injection to the joint of interest. The majority of patients (69.7%,  $n = 23$ ) had a right CMC1 glucocorticoid injection. Overall, 60.6% ( $n = 20$ ) had ultrasound-guided injection and 39.4% ( $n = 13$ ) had a landmark-based injection.

Both groups achieved a statistically significant improvement in AUSCAN score at week 6 ( $P \leq 0.05$ ) but with a recurrence of symptoms at week 12 ( $P \leq 0.05$ ), at both intervals the AUSCAN scores were better than baseline ( $P \leq 0.05$ ) (Figure 2). No significant differences were identified between two groups in terms of changes from baseline to 6, 12, and between 6 to 12 weeks in pain, stiffness and hand function. The US-guided injection group and the standard approach group had significant better results in pain score at rest, gripping, lifting, turning, squeezing, and stiffness in 6 weeks' time as highlighted in Table 1. In the US-guided injection group hand function improved significantly at weeks 6 and 12 ( $P < 0.05$ ) in all aspects assessed apart from carrying a full pot with one hand ( $P = 0.06$ ). While in the

Table 1. Comparison changes between two groups (ultrasound-guided vs landmark-based approach) in CMC1 pain, stiffness and function.

	Group	Mean difference	Std. deviation	P value	P value (US vs landmark)
Pain at rest (Vas score)	US	3.5	0.599	<0.001	0.094
<b>Change after 6 weeks</b>	Landmark	2.5	0.879	<b>0.047</b>	
<b>Change after 12 weeks</b>	US	1.55	0.599	0.084	
	Landmark	0.115	0.879	0.896	
<b>Change between 6-12 weeks</b>	US	-1.95	0.599	<b>0.020</b>	
	Landmark	-2.385	0.743	<b>0.021</b>	
Pain in gripping	US	4.8	0.547	<0.001	0.373
<b>Change after 6 weeks</b>	Landmark	4.23	0.678	<0.001	
<b>Change after 12 weeks</b>	US	2.5	0.547	<0.001	
	Landmark	1.92	0.678	<b>0.037</b>	
<b>Change between 6-12 weeks</b>	US	-2.3	0.547	<0.001	
	Landmark	-2.3	0.678	<b>0.008</b>	
Pain in lifting	US	4.65	0.542	<0.001	0.109
<b>Change after 6 weeks</b>	Landmark	4.462	0.673	<0.001	
<b>Change after 12 weeks</b>	US	2.95	0.542	<0.001	
	Landmark	2.077	0.673	<b>0.018</b>	
<b>Change between 6-12 weeks</b>	US	-1.7	0.542	<b>0.018</b>	
	Landmark	-2.385	0.673	<b>0.006</b>	
Pain in turning	US	4.750	0.607	<0.001	0.197
<b>Change after 6 weeks</b>	Landmark	3.923	0.753	<0.001	
<b>Change after 12 weeks</b>	US	2.950	0.607	<0.001	
	Landmark	1.615	0.753	0.214	
<b>Change between 6-12 weeks</b>	US	-1.800	0.607	<b>0.030</b>	
	Landmark	-2.308	0.753	<b>0.026</b>	
Pain in squeezing	US	4.650	0.615	<0.001	0.153
<b>Change after 6 weeks</b>	Landmark	4.154	0.762	<0.001	
<b>Change after 12 weeks</b>	US	2.550	0.615	<b>0.001</b>	
	Landmark	2.077	0.762	0.059	
<b>Change between 6-12 weeks</b>	US	-2.1	0.615	<b>0.009</b>	
	Landmark	-2.077	0.762	0.059	
Stiffness	US	2.950	0.581	<0.001	0.124
<b>Change after 6 weeks</b>	Landmark	3.462	0.721	<0.001	
<b>Change after 12 weeks</b>	US	1.6	0.581	0.070	
	Landmark	0.846	0.721	1.00	
<b>Change between 6-12 weeks</b>	US	-1.350	0.581	0.188	
	Landmark	-2.615	0.721	<b>0.007</b>	
Turning taps/faucets on	US	4.200	0.538	<0.001	0.751
<b>Change after 6 weeks</b>	Landmark	2.615	0.667	<b>0.003</b>	
<b>Change after 12 weeks</b>	US	2.500	4.651	<0.001	
	Landmark	0.769	0.667	0.759	
<b>Change between 6-12 weeks</b>	US	-1.700	0.538	<b>0.024</b>	
	Landmark	-1.846	0.667	0.067	

Table 1 (con't).

Turning around doorknob or handle	US	3.850	0.576	<0.001	0.964
<b>Change after 6 weeks</b>	Landmark	3.692	0.715	<0.001	
<b>Change after 12 weeks</b>	US	2	0.576	<b>0.010</b>	
	Landmark	1.615	0.715	0.192	
<b>Change between 6-12 weeks</b>	US	-1.850	0.576	<b>0.021</b>	
	Landmark	-2.077	0.715	<b>0.046</b>	
Doing up buttons	US	4.050	0.651	<0.001	0.742
<b>Change after 6 weeks</b>	Landmark	3.154	0.808	<b>0.003</b>	
<b>Change after 12 weeks</b>	US	2.150	0.651	<b>0.018</b>	
	Landmark	1.077	0.808	0.822	
<b>Change between 6-12 weeks</b>	US	-1.900	0.651	<b>0.049</b>	
	Landmark	-2.077	0.808	0.113	
Fastening jewellery	US	4	0.557	<0.001	0.947
<b>Change after 6 weeks</b>	Landmark	4.602	0.691	<0.001	
<b>Change after 12 weeks</b>	US	2.050	0.557	<b>0.005</b>	
	Landmark	2.296	0.891	0.074	
<b>Change between 6-12 weeks</b>	US	-1.950	0.557	<b>0.008</b>	
	Landmark	-2	0.691	<b>0.042</b>	
Opening a new jar	US	4.550	0.603	<0.001	0.691
<b>Change after 6 weeks</b>	Landmark	4.308	0.748	<0.001	
<b>Change after 12 weeks</b>	US	2.350	0.603	<b>0.003</b>	
	Landmark	2.077	0.748	<b>0.044</b>	
<b>Change between 6-12 weeks</b>	US	-2.200	0.603	<b>0.005</b>	
	Landmark	-2.231	0.748	<b>0.033</b>	
Carrying a full pot with one hand	US	3.850	0.651	<0.001	
<b>Change after 6 weeks</b>	Landmark	4.154	0.808	<0.001	
<b>Change after 12 weeks</b>	US	1.8	0.651	0.060	
	Landmark	1.692	0.808	0.241	
<b>Change between 6-12 weeks</b>	US	-2.050	0.651	<b>0.028</b>	
	Landmark	-2.462	0.808	<b>0.034</b>	
Peeling vegetables/fruits	US	4.7	0.633	<0.001	0.607
<b>Change after 6 weeks</b>	Landmark	3.769	0.785	<0.001	
<b>Change after 12 weeks</b>	US	2.8	0.633	<0.001	
	Landmark	2	0.785	0.082	
<b>Change between 6-12 weeks</b>	US	-1.9	0.633	<b>0.039</b>	
	Landmark	-1.769	0.785	0.139	
Picking up large heavy objects	US	3.950	0.615	<0.001	0.879
<b>Change after 6 weeks</b>	Landmark	4	0.762	<0.001	
<b>Change after 12 weeks</b>	US	2	0.615	<b>0.020</b>	
	Landmark	1.538	0.762	0.239	
<b>Change between 6-12 weeks</b>	US	-1.950	0.615	<b>0.021</b>	
	Landmark	-2.462	0.762	<b>0.020</b>	
Wringing out wash cloths	US	3.8	0.611	<0.001	0.645
<b>Change after 6 weeks</b>	Landmark	3.462	0.757	<0.001	
<b>Change after 12 weeks</b>	US	1.750	0.611	<b>0.051</b>	
	Landmark	1.154	0.757	0.664	
<b>Change between 6-12 weeks</b>	US	-2.050	0.611	<b>0.015</b>	
	Landmark	-2.308	0.757	<b>0.034</b>	

landmark-based approach group significant improvements were captured at week 6 ( $P < 0.05$ ) (Table 1). No injection side reactions or complications were reported during the duration of this study.

### Discussion

Osteoarthritis involving the first CMC is a degenerative joint condition for which patients seek intervention to alleviate pain and improve hand function. In this study,

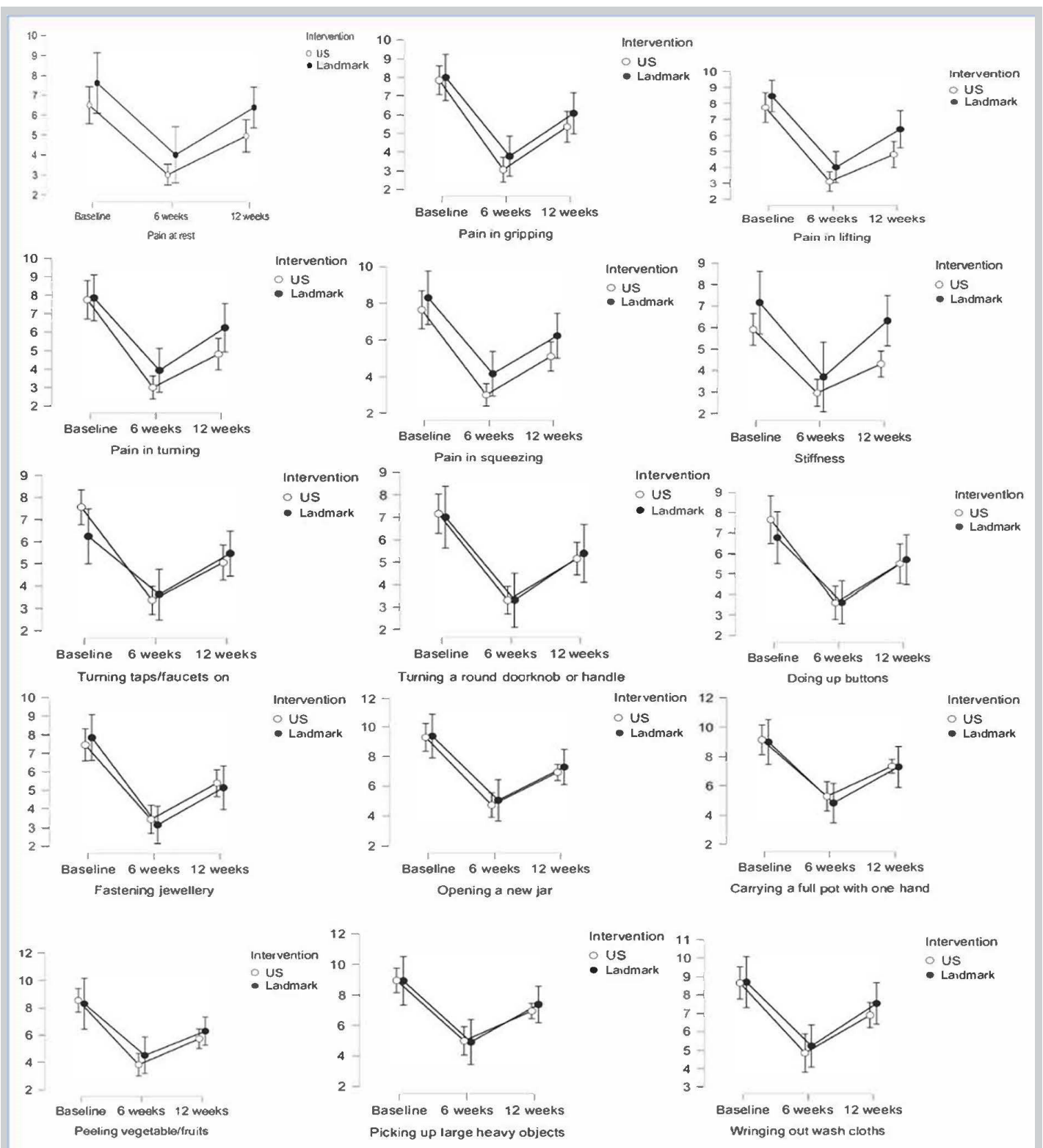


Figure 2. Changes in Australian Canadian osteoarthritis hand index (AUSCAN) scores at week 6 with a recurrence of symptoms at week 12 in the study groups ultrasound (US) vs landmark based injection technique.



33 participants with symptomatic CMC1 arthritis were prospectively evaluated for response to either ultrasound-guided or landmark-based joint injection. Both cohorts were predominantly female, with a median age of 65 years consistent with baseline demographics of previous studies [4,6,8]. Previous research has shown that intra-articular corticosteroid injections can improve hand pain and function regardless of osteoarthritis stages. However, they have also been shown to be more efficacious for longer durations (beyond 3 months) for early (Eaton 1-2) than late (Eaton 3-4) osteoarthritis stages [8,9], similar to the outcome of using hand splint [10].

In addition, a case series of 43 patients with grade 2 or higher Eaton classification were assessed following ultrasound-guided injection to the CMC1 and a strong correlation was found between patients who had persistent pain following glucocorticoid and local anesthesia injection at one week and the progression to surgery, (odd ratio 3.1) [11]. Factors influencing the likelihood of a repeat injection or surgical intervention are beyond the scope of this study.

Several studies have been done comparing use of ultrasound-guided versus landmark-based approach in small joint or structures [12-14]. To et al. performed a similar study on cadavers, they found that the success rate by injection site was higher for ultrasound-guided participants than for non-ultrasound participants for thumb CMC arthrosis (72% vs. 38%), which was confirmed by fluoroscopy and later by dissection and localizing the blue dye mix in the cadavers [12]. On the other hand, Derian et al. found no statistically significant difference in accuracy between the two methods (ultrasound vs. landmark approach) in cadaver investigations [15], although no clinical conclusion could be drawn from these studies.

In this study, we found that the effect of intra-articular corticosteroid injection is satisfactory but transient for both ultrasound-guided and landmark based CMC1 injection

#### *Limitations*

Our study had limitations, including a small sample size, convenience sample of doctor's own patients, lack of blinding, and two experts performing the injection in both arms.

#### **Conclusion**

In a small study of ultrasound versus landmark based CMC1 injection for OA, both techniques provided similar transient pain relief.

#### **Ethics approval and consent to participate**

Ethical approval was obtained from the St James' and Tallaght Hospital Joint Ethics Committee, Written informed consent was obtained from all individual patients included in the study.

#### **Availability of data and material**

The data supporting the study's findings are available from the corresponding author upon a reasonable request.

#### **Competing interests**

The authors declare that they have no competing interests.

#### **Funding**

No author received funding for this study.

#### **Authors' contributions**

SAA: data collection, data analysis, manuscript writing. SM: data collection and manuscript writing. LC and NME: data collection. RC and CJ: manuscript writing/editing. All authors read and approved the final manuscript.

#### **References**

1. Firestein, G., Gabriel, S., McInnes, I. and O'Dell, J., 2017. Kelley And Firestein's Textbook Of Rheumatology Volumes I And II. Philadelphia, PA: Elsevier.
2. Niu J. Symmetry and clustering of symptomatic hand osteoarthritis in elderly men and women: the Framingham Study. *Rheumatology*. 2003;42(2):343-348.
3. Kwok WY, Kloppenburg M, Marshall M, Nicholls E, Rosendaal FR, Peat G. The prevalence of erosive osteoarthritis in carpometacarpal joints and its clinical burden in symptomatic community-dwelling adults. *Osteoarthritis Cartilage*. 2014;22(6):756-763.
4. Kolasinski SL, Neogi T, Hochberg MC, et al. 2019 American College of Rheumatology/Arthritis Foundation Guideline for the Management of Osteoarthritis of the Hand, Hip, and Knee. *Arthritis & Rheumatology*. 2020;72(2):220-233.
5. Kennedy CD, Manske MC, Huang JI. Classifications in Brief: The Eaton-Littler Classification of Thumb Carpometacarpal Joint Arthrosis. *Clin Orthop Relat Res*. 2016;474(12):2729-2733. doi:10.1007/s11999-016-4864-6
6. Day CS, Gelberman R, Patel AA, Vogt MT, Ditsios K, Boyer MI. Basal joint osteoarthritis of the thumb: a prospective trial of steroid injection and splinting. *J Hand Surg Am*. 2004;29(2):247-251.
7. Yavuz U, Sökücü S, Albayrak A, Öztürk K. Efficacy comparisons of the intraarticular steroidal agents in the patients with knee osteoarthritis. *Rheumatol Int*. 2012;32(11):3391-3396. doi:10.1007/s00296-011-2188-0
8. Ostergaard PJ, Hall MJ, Dowlatshahi AS, Harper CM, Rozental TD. Thumb Carpometacarpal Arthritis: Prognostic Indicators and Timing of Further Intervention Following Corticosteroid Injection. *J Hand Surg Am*. 2020;45(10):986.e1-986.e9. doi:10.1016/j.jhsa.2020.03.025
9. Khan M, Waseem M, Raza A, Derham D. Quantitative Assessment of Improvement with Single Corticosteroid Injection in Thumb CMC Joint Osteoarthritis?. *Open Orthop J*. 2009;3:48-51. Published 2009 Jun 19. doi:10.2174/1874325000903010048
10. Kumar N, Newman RJ. Complications of intra- and peri-articular steroid injections. *Br J Gen Pract*. 1999;49(443):465-466.
11. McCann P, Wakeley C, Amirfeyz R. THE EFFECT OF

ULTRASOUND GUIDED STEROID INJECTION ON PROGRESSION TO SURGERY IN THUMB CMC ARTHRITIS. *Hand Surgery*. 2014;19(01):49-52.

12. To P, McClary KN, Sinclair MK, et al. The Accuracy of Common Hand Injections With and Without Ultrasound: An Anatomical Study. *Hand (N Y)*. 2017;12(6):591-596. doi:10.1177/1558944717692086

13. Karaahmet ÖZ, Gürçay E, Kara M, Serçe A, Kıraç Ünal Z, Çakıcı A. Comparing the effectiveness of ultrasound-guided versus blind steroid injection in the treatment of severe carpal tunnel syndrome. *Turk J Med Sci*. 2017;47(6):1785-1790. Published 2017 Dec 19. doi:10.3906/sag-1704-97

14. Gutierrez M, Di Matteo A, Rosemffet M, et al. Short-term efficacy to conventional blind injection versus ultrasound-guided injection of local corticosteroids in tenosynovitis in patients with inflammatory chronic arthritis: A randomized comparative study. *Joint Bone Spine*. 2016;83(2):161-166. doi:10.1016/j.jbspin.2015.04.017

15. Derian A, Amundson J, Abi-Aad K, Vasquez-Duarte R, Johnson-Greene D. Accuracy of ultrasound-guided versus palpation-based carpometacarpal joint injections: A randomized pilot study in cadavers. *Ultrasound*. 2018;26(4):245-250. doi:10.1177/1742271X18789711

# Exploring the Applicability of Pre-Anesthetic Cardiac POCUS in Unexpected Conditions: Could it be Helpful?

Rodolfo C Sabogal, MD<sup>1</sup>

(1) Department of Anesthesiology and Critical Care, Universidad de Cartagena, Universidad de Antioquia, Cartagena, Colombia

## Abstract

Formal preoperative echocardiography has traditionally been recommended when there is substantial cardiovascular disease without recent follow up, unexplained dyspnea, a functional class less than 4 METS or a Duke Activity Status Index less than 34. However, it is important to note that certain patients may present with a variety of cardiac abnormalities due to their preexisting condition or multiple treatments, and these individuals warrant consideration. The objective of pre-anesthetic cardiac POCUS is to provide clinical information in a timely manner. Although it does not aim to replace conventional echocardiography, cardiac POCUS can undoubtedly assist anesthesia practitioners in identifying asymptomatic and potentially hazardous conditions, allowing for more accurate risk allocation and individualized patient care.

## Rationale for preoperative cardiac POCUS

Pre-anesthetic evaluation aims to collect data that will enable us to establish rational strategies and enhance interventions to improve care and reduce perioperative risks providing greater safety to the perioperative process. In order to determine if the patient is suitable for anesthesia, typically a series of tests are usually required, including many laboratories and images. Consequently, in place of a one-size-fits-all approach, our objective is to personalize medicine to the greatest extent feasible through the evaluation of each case separately and the provision of a treatment that is tailored to the patient's needs [1]. Currently, ultrasonography has experienced greater availability, portability, and cost-effectiveness, enabling health care specialists, including anesthesiologists, to provide meticulous and individualized decisions. In this context, an expert level of ultrasonography understanding and comprehension is necessary in order to incorporate it into daily activities and base actions on the findings [2].

Cardiac point of care ultrasonography (POCUS) has been designed to provide rapid clinical information [3]. Formerly known as focused cardiac ultrasonography

(FOCUS), the term cardiac POCUS is now commonly used, yet the terms are frequently interchanged in the literature. Different specialties, including emergency medicine, family medicine, pediatrics, and critical care medicine, among others, have influenced the development and application of this relatively novel technique [4]. Cardiac POCUS does not replace formal echocardiography, which usually falls under the scope of cardiologists and cardiac anesthesiologists, but it can be helpful in providing crucial information in the preoperative phase to rapidly evaluate of biventricular dimensions and function, recognize extreme volume states, detect pericardial effusion, and identify morphologic markers of severe valvular disease [5].

Formal preoperative echocardiography has traditionally been recommended when there is substantial cardiovascular disease without recent follow-up, unexplained dyspnea, a functional class less than 4 METS or a Duke Activity Status Index less than 34 [6–8]. Nevertheless, cardiac POCUS can aid in the recognition of dangerous, often silent, and unexpected conditions, thereby enabling for improved risk allocation and individualized patient care.

---

\*Corresponding Author: Dr. Rodolfo C Sabogal (email: rsabogalr1@unicartagena.edu.co)

This work is licensed under a [Creative Commons Attribution 4.0 International License](https://creativecommons.org/licenses/by/4.0/).

Author(s) retain the copyright for their work. At the time of submission to POCUS Journal the author(s) grant the journal a limited and non revokable right to publish in the Journal under a [Creative Commons Attribution 4.0 International License](https://creativecommons.org/licenses/by/4.0/).

DOI: <https://doi.org/10.24908/pocus.v8i2.16519>

## Evidence supporting preoperative cardiac POCUS

A prospective observational study in which preoperative cardiac POCUS was performed by an anesthesiologist and validated by a cardiologist in 100 patients older than 65 years or with suspected cardiac disease, 54 patients had their anesthetic plan altered; some were referred to a cardiologist, others had their anesthetic or surgical technique altered, and others were referred to highly dependent facilities in the postoperative period [9]. In a separate observational study, anesthesiologists performed preoperative cardiac POCUS on 170 patients, obtaining adequate images in 167 (98%) and detecting significant alterations such as mitral valve disease, pulmonary hypertension, and aortic stenosis, pathologies that could alter perioperative management [10]. Another prospective observational study involving 99 patients with previous cardiac diagnoses (systolic or diastolic left ventricular failure, vasodilatation, hypovolemia or pericardial effusion) scheduled for non-cardiac emergency surgery, 44% of patients had their treatment modified after preoperative cardiac POCUS [11]. An additional prospective cohort study of 100 patients older than 60 years assessed hemodynamics, biventricular function, valvular competence, pericardial effusion, and pulmonary pressures using preoperative cardiac POCUS. They found 26% of patients with LVEF alterations, 18% of patients with valvular lesions, and 40% of patients with diastolic dysfunction. Additionally, the anesthetic behavior of 20% of patients was altered, and 4% of patients were cancelled [12]. A separate large database of transthoracic echocardiography (TTE) conducted by the department of anesthesia at the Memorial Sloan Kettering Cancer Center in the United States revealed that cardiac POCUS patterns provided significant responses that guided management in a substantial percentage of patients [13].

Following these observational studies, two randomized controlled trials (RCTs) have recently been conducted. In a pilot RCT led in Australia, anesthesiologists were instructed to perform cardiac POCUS in 100 patients undergoing femoral neck fracture surgery. Cardiac POCUS resulted in a significant decrease in death, acute kidney injury, myocardial infarction, and cerebrovascular accidents [14,15]. In contrast, cardiac POCUS did not appear to reduce postoperative hospitalization days or mortality in the PREOPFOCUS RCT, which included 327 high-risk patients over the age of 65 undergoing abdominal or orthopedic surgery and ASA 3 – 4 [16]. Unfortunately, this trial had to be terminated early due to COVID-19 restrictions. Perioperative evaluation of cardiac morphology and function is clearly plausible [17]. However, conducting real-world studies in the field of pre-operative cardiac POCUS can be challenging due to the heterogeneity of the patient population.

Recent studies indicate that practitioners can comprehend cardiac POCUS after receiving 20 to 30 cases of guided cardiac POCUS education [18]. However, it is unknown how many are required for accurate interpretation, though this could be overcome through consistent training. The majority of residency programs in anesthesiology do not include a formal curriculum in the use of perioperative cardiac POCUS, which is typically designated for residents who voluntarily choose to expand their knowledge of cardiac anesthetic or critical care [19].

## Certain clinical settings in which preoperative cardiac POCUS could be appropriate

### *Elderly patients (over 65 years)*

The global population is advancing in age and elderly individuals warrant particular attention [20]. As a result of aging, geriatric patients experience stiffening of their arterial circulatory system and heart chambers which might result in a variety of illnesses, notably heart failure [21]. Valve thickening specifically at mitral or aortic positions (i.e., degenerative, rheumatic, calcific, others) [22], is an additional significant structural change that can occur over time and occasionally lead to stenosis or insufficiencies with potential hemodynamic effects. Arrhythmias are common, especially atrial fibrillation (AF), which worsens with age and may affect 1 in every 5 people by the age of 80, significantly increasing the risk of stroke [23].

Using cardiac POCUS, we can visually determine if the chambers of the heart are enlarged, which indicates the presence of a chronic cardiac condition. Prior to administering anesthesia, a rough estimate of the left ventricle ejection fraction (LVEF) is essential, either qualitatively by eyeballing [24] or quantitatively using Simpson's biplane method [25].

In addition, certain findings can aid in determining of an increased thromboembolic risk, predominantly in patients with AF. Left atrial enlargement is a significant indicator of chronic remodeling that provides clues to underlying cardiac disease and is a strong predictor of future events. Using 2D imaging during cardiac POCUS, we will be able to roughly estimate the increase in atrial size, as well as the possible deviation of the interatrial septum and the enlargement of the left atrial appendage [26]. There is evidence that a volume increase exceeding 34 ml/m<sup>2</sup> is associated with an increased risk of ischemic stroke and mortality [27].

Moreover, spontaneous echo contrast resembling the appearance of smoke within the LA indicates blood stasis and stagnation and appears to be a precursor of intracavitary thrombi [28]. Reduced velocity (less than 20cm/s) and the presence of a thrombus in the LA

*Table 1. Preoperative cardiac POCUS for elderly patients.*

Cardiac POCUS utility	Critical findings
<ul style="list-style-type: none"> <li>Left ventricular function</li> </ul>	<ul style="list-style-type: none"> <li>Diastolic and/or systolic dysfunction</li> </ul>
<ul style="list-style-type: none"> <li>Valvular disease</li> </ul>	<ul style="list-style-type: none"> <li>Stenosis/regurgitation</li> <li>Spectral doppler and advance training often required</li> </ul>
<ul style="list-style-type: none"> <li>Left atrial area and volume</li> </ul>	<ul style="list-style-type: none"> <li>Severe dilation can be seen in diastolic dysfunction, mitral valve disease</li> </ul>

appendage are extremely high-risk characteristics; however, transesophageal echocardiography (TEE) is required for detecting them [29].

Additionally, the assessment of mitral and aortic valves can be performed in order to determine the presence of notable stenosis or regurgitation. However, in these instances, spectral doppler and advanced training are required (Table 1).

#### *Patients with cancer*

According to the World Health Organization, cancer is the second leading cause of death worldwide, only behind cardiovascular disease [30]. This subgroup of patients frequently necessitates preoperative consultation [31].

Patients with cancer may develop a variety of cardiovascular complications, including effects of mediastinal metastatic disease [32-34], less frequently encountered are primary intracardiac tumors such as sarcomas or myxomas.

Moreover, while new cancer medicines have made remarkable improvements in terms of quality of life and mortality, short- and long-term direct cardiotoxicity is strongly linked to cancer treatment [35], including anthracyclines (i.e. doxorubicin), alkylating agents (i.e. cyclophosphamide), monoclonal antibodies (i.e. trastuzumab, imatinib, bortezomib), among others routinely used in a wide range of hematological and solids tumors. Cancer related coagulation disorders increase the risk of deep vein thrombosis (DVT) and pulmonary embolism (PE) [36], which remain an additional important factor to take into account prior to surgery.

Cardiac POCUS can play a pivotal role in the necessary preoperative assessment [37]. It is crucial to promptly exclude the presence of significant left ventricular (LV)

dysfunction (e.g., cardiotoxicity due to chemotherapy). In addition, it is extremely important to look for tumor extension and pericardial effusion, which can go undetected in mild cases and lead to life-threatening tamponade in others.

Although cardiac POCUS does not replace computed tomography in the diagnosis of PE, severe cases can present with acute dilatation and dysfunction of the right ventricle (RV) (low TAPSE and fractional area change [FAC]), and McConnell's sign [38] (Table 2).

#### *Patients in the intensive care unit*

Critically ill patients are faced with life-threatening multisystem processes and routinely necessitate central vascular access and multiorgan support (e.g., mechanical ventilation and dialysis) [39], which may result in some adverse effects for which cardiac POCUS may be beneficial. Due to the performance of various surgical procedures during their stay in the intensive care unit, this subgroup of patients often requires anesthesiology consultation as part of their multidisciplinary management, and cardiac POCUS can aid cardiovascular evaluation.

Mechanical ventilation support may cause a decrease in RV preload by decreasing right atrial transmural pressure and cause an increase in RV afterload by increasing pulmonary vasculature resistance (e.g., high PEEP), resulting in RV dysfunction in severe cases [40-42]. Cardiac POCUS can also be used to identify increased ventricular interdependence [43].

*Table 2. Preoperative cardiac POCUS for patients with cancer.*

Cardiac POCUS utility	Critical findings
<ul style="list-style-type: none"> <li>Left ventricular function</li> </ul>	<ul style="list-style-type: none"> <li>Diastolic dysfunction and systolic dysfunction due to cardiotoxicity</li> </ul>
<ul style="list-style-type: none"> <li>Pericardial evaluation</li> </ul>	<ul style="list-style-type: none"> <li>Pericardial effusion</li> <li>Tamponade physiology</li> </ul>
<ul style="list-style-type: none"> <li>Signs of pulmonary embolism</li> </ul>	<ul style="list-style-type: none"> <li>Right ventricular dilation</li> <li>Right ventricular dysfunction</li> <li>Ventricular interdependence</li> <li>Thrombus in transit</li> <li>McConnell's sign</li> </ul>

To evaluate the right atrial (RA) pressure of the patient at the bedside, the diameter of the inferior vena cava (IVC) in proximity to the cavo-atrial junction (CAJ) can be measured [44]. Simplified, if the IVC measures less than 10 millimeters with collapse on inspiration, the patient is has low RA pressure (often due to hypovolemia). Conversely, if the IVC exceeds 20 millimeters and does not have respiratory variation, RA pressure is elevated, which can be due to hypervolemia; therefore, perioperative fluid restriction or diuretic use may be required. It is also possible to calculate the velocity time integral (VTI) of the left outflow tract and estimate the cardiac output in order to better comprehend the hemodynamic profile at a fixed point [45,46].

Takotsubo syndrome, common but not exclusive to critically ill patients, is a reversible heart failure characterized by apical segment akinesia and basal segment hyperkinesia, resembling the Japanese octopus trap from which it derives its name; however, other atypical patterns can occur. Pre-anesthetic cardiac POCUS can be used to assess left ventricular (LV) function and identify the typical apical-midventricular ballooning pattern, as well as the circumferential pattern of Takotsubo cardiomyopathy [47,48].

Cardiac manifestations of septic cardiomyopathy affect 10% to 80% of septic patients [49], involving a variety of patterns ranging from hyperdynamic profiles to biventricular dysfunction; consequently, cardiac POCUS is useful in recognizing some of these features. Catheter-related endocarditis is an uncommon but serious complication associated with central venous catheter infections [50], primarily caused by highly prevalent microorganisms in intensive care units such as *staphylococcus aureus* and *candida spp.*, hence a high level of suspicion must always be maintained. During the preanesthetic phase, cardiac POCUS has the potential to recognize these endocardial changes (Table 3).

#### Patients with comorbidities

A wide range of diseases, including autoimmune conditions, sickle cell disease, chronic obstructive pulmonary disease, liver cirrhosis, chronic kidney disease, malnutrition, and HIV, among others, may result in latent cardiac conditions. These include pulmonary hypertension with RV compromise (i.e. tricuspid valve regurgitation jet velocity greater 2.8m/s), right atrial and ventricle enlargement, flattened septum caused by volume or pressure overload, cardiomyopathies such as diastolic and systolic biventricular heart failure, pericardial effusions, and other life-threatening complications, many of which are detectable by cardiac POCUS [51–53].

**Table 3. Preoperative cardiac POCUS for critically ill patients, comorbid patients, and users of illicit psychoactive substances.**

Cardiac POCUS utility	Critical findings
<ul style="list-style-type: none"> <li>Right ventricle morphology and function</li> </ul>	<ul style="list-style-type: none"> <li>RV dilation and dysfunction</li> <li>Tricuspid valve regurgitation jet velocity greater than 2.8m/s, flattened septum, RA enlargement</li> <li>Ventricular interdependence</li> </ul>
<ul style="list-style-type: none"> <li>Inferior vena cava assessment</li> </ul>	<ul style="list-style-type: none"> <li>RA pressure estimate (to aid in assessment of volume status)</li> </ul>
<ul style="list-style-type: none"> <li>Examination of wall motion</li> </ul>	<ul style="list-style-type: none"> <li>Global or regional LV dysfunction</li> </ul>
<ul style="list-style-type: none"> <li>Valve and endocardium morphology</li> </ul>	<ul style="list-style-type: none"> <li>Valve thickening, masses, thrombi (critically ill, intravenous drug users, comorbid)</li> </ul>
<ul style="list-style-type: none"> <li>Left atrial dimension</li> </ul>	<ul style="list-style-type: none"> <li>Diastolic dysfunction parameter</li> </ul>

RV: Right ventricle; RA: Right atrial; TAPSE: tricuspid annular plane systolic excursion; VTI: left ventricle outflow tract velocity time integral; LVEF: left ventricle ejection fraction.

Coronary artery disease may be suspected if there is the presence of regional wall motion abnormalities, predominantly hypokinesia or akinesia of segments corresponding to a specific vascular territory [54]. Furthermore, cardiac POCUS enables a quick estimation of LV systolic function and identification of secondary complications such as free wall or septal rupture, LV aneurysms, intracavitary thrombi, and chronic myocardial remodeling.

#### Users of illicit psychoactive substances

Illicit and prohibited substances are widespread in modern society, affecting individuals of all ages, genders, and socioeconomic backgrounds [55]. A considerable number of these substances have the potential to directly impair cardiac function. Cocaine is a sympathomimetic

substance that can cause long-term myocardial damage due to vasoconstriction, coronary spasm, and platelet aggregation, among other factors. Chronically increased left ventricle mass can result in diastolic heart failure and a significant reduction in LVEF [56]. Injection drug-related infective endocarditis can affect individuals who inject drugs [57]. It is critical to consider this condition during the pre-anesthetic period.

## Conclusion

Cardiac POCUS is a rapidly available tool that may assist us in detecting potentially silent and dangerous preoperative conditions, allowing anesthesiologists to provide timely perioperative management. Cardiac POCUS is not intended to replace a formal echocardiogram, traditionally considered the domain of specialists such as cardiologists and cardiac anesthesiologists. However, there are situations in which perioperative management requires the assessment of patients for specific conditions that may have immediate cardiac implications.

## Disclosures

Support was provided solely from personal sources. This research did not receive any specific grant from funding agencies in the public, commercial, or not-for-profit sectors.

## References

- Pelter MN, Druz RS. Precision medicine: Hype or hope? *Trends Cardiovasc Med*. Published online November 2022;S1050173822001396. doi:10.1016/j.tcm.2022.11.001
- Royse CF, Canty DJ, Faris J, Haji DL, Veltman M, Royse A. Core Review: Physician-Performed Ultrasound The Time Has Come for Routine Use in Acute Care Medicine. *Anesth Analg*. 2012;115(5):1007-1028. doi:10.1213/ANE.0b013e31826a79c1
- Wong A, Chew M, Hernandez G. Using ultrasound in ICU. *Intensive Care Med*. Published online March 16, 2023;s00134-023-07023-w. doi:10.1007/s00134-023-07023-w
- Johri AM, Glass C, Hill B, et al. The Evolution of Cardiovascular Ultrasound: A Review of Cardiac Point-of-Care Ultrasound (POCUS) Across Specialties. *Am J Med*. 2023;136(7):621-628. doi:10.1016/j.amjmed.2023.02.020
- Lenk T, Whittle J, Miller TE, Williams DGA, Bronshteyn YS. Focused cardiac ultrasound in preoperative assessment: the perioperative provider's new stethoscope? *Perioper Med*. 2019;8(1):16. doi:10.1186/s13741-019-0129-8
- Halvorsen S, Mehilli J, Cassese S, et al. 2022 ESC Guidelines on cardiovascular assessment and management of patients undergoing non-cardiac surgery. *Eur Heart J*. 2022;43(39):3826-3924. doi:10.1093/eurheartj/ehac270
- Smilowitz NR, Berger JS. Perioperative Cardiovascular Risk Assessment and Management for Noncardiac Surgery: A Review. *JAMA*. 2020;324(3):279. doi:10.1001/jama.2020.7840
- Steeds RP, Garbi M, Cardim N, et al. EACVI appropriateness criteria for the use of transthoracic echocardiography in adults: a report of literature and current practice review. *Eur Heart J - Cardiovasc Imaging*. 2017;18(11):1191-1204. doi:10.1093/ehjci/jew333
- Canty DJ, Royse CF, Kilpatrick D, Bowman L, Royse AG. The impact of focused transthoracic echocardiography in the pre-operative clinic:

Transthoracic echocardiography in the pre-operative clinic. *Anaesthesia*. 2012;67(6):618-625. doi:10.1111/j.1365-2044.2012.07074.x

- Cowie B. Three years' experience of focused cardiovascular ultrasound in the peri-operative period: Focused peri-operative cardiovascular ultrasound. *Anaesthesia*. 2011;66(4):268-273. doi:10.1111/j.1365-2044.2011.06622.x
- Canty DJ, Royse CF, Kilpatrick D, Williams DL, Royse AG. The impact of pre-operative focused transthoracic echocardiography in emergency non-cardiac surgery patients with known or risk of cardiac disease: Pre-operative echocardiography in emergency surgery. *Anaesthesia*. 2012;67(7):714-720. doi:10.1111/j.1365-2044.2012.07118.x
- Af AE, Hs M. The Role of Pre-Operative Focused Transthoracic Echocardiography in Anesthetic Management of Old Age Patients with Potential Risk of Post-Operative Cardiac Complications.
- Sheth MD A, Trubelja MD FASA AD. Perioperative focused cardiac ultrasound: a brief report. *J Anesth Crit Care Open Access*. 2021;13(1):55-60. doi:10.15406/jaccoa.2021.13.00469
- Canty DJ, Heiberg J, Yang Y, et al. One-year results of the pilot multicentre randomised trial of preoperative focused cardiac ultrasound in hip fracture surgery. *Anaesth Intensive Care*. 2019;47(2):207-208. doi:10.1177/0310057X19838699
- Canty DJ, Heiberg J, Yang Y, et al. Pilot multi-centre randomised trial of the impact of pre-operative focused cardiac ultrasound on mortality and morbidity in patients having surgery for femoral neck fractures (ECHONOF-2 pilot). *Anaesthesia*. 2018;73(4):428-437. doi:10.1111/anae.14130
- Pallesen J, Bhavsar R, Fjølner J, et al. The effects of PREOPERATIVE FOCUSED cardiac ultrasound in high-risk patients: A randomised controlled trial ( PREOPFOCUS ). *Acta Anaesthesiol Scand*. 2022;66(10):1174-1184. doi:10.1111/aas.14134
- Barber RL, Fletcher SN. A review of echocardiography in anaesthetic and peri-operative practice. Part 1: impact and utility. *Anaesthesia*. 2014;69(7):764-776. doi:10.1111/anae.12663
- Millington SJ, Hewak M, Arntfield RT, et al. Outcomes from extensive training in critical care echocardiography: Identifying the optimal number of practice studies required to achieve competency. *J Crit Care*. 2017;40:99-102. doi:10.1016/j.jcrc.2017.03.020
- Mahmood F, Matyal R, Skubas N, et al. Perioperative Ultrasound Training in Anesthesiology: A Call to Action. *Anesth Analg*. 2016;122(6):1794-1804. doi:10.1213/ANE.0000000000001134
- Calcinotto A, Kohli J, Zagato E, Pellegrini L, Demaria M, Alimonti A. Cellular Senescence: Aging, Cancer, and Injury. *Physiol Rev*. 2019;99(2):1047-1078. doi:10.1152/physrev.00020.2018
- Brunker LB, Boncyk CS, Rengel KF, Hughes CG. Elderly Patients and Management in Intensive Care Units (ICU): Clinical Challenges. *Clin Interv Aging*. 2023;Volume 18:93-112. doi:10.2147/CIA.S365968
- Zern EK, Frank RC, Yucel E. Valvular Heart Disease in the Cardiac Intensive Care Unit. *Crit Care Clin*. Published online September 2023;S0749070423000362. doi:10.1016/j.ccc.2023.05.002
- Chyou JY, Barkoudah E, Dukes JW, et al. Atrial Fibrillation Occurring During Acute Hospitalization: A Scientific Statement From the American Heart Association. *Circulation*. Published online March 13, 2023;CIR.0000000000001133. doi:10.1161/CIR.0000000000001133
- Bergenzaun L, Gudmundsson P, Öhlin H, et al. Assessing left ventricular systolic function in shock: evaluation of echocardiographic parameters in intensive care. *Crit Care*. 2011;15(4):R200. doi:10.1186/cc10368
- Mohsin M, Farooq MU, Akhtar W, et al. Echocardiography in a critical care unit: a contemporary review. *Expert Rev Cardiovasc Ther*. 2022;20(1):55-63. doi:10.1080/14779072.2022.2036124
- Inciardi RM, Bonelli A, Biering Sorensen T, et al. Left atrial disease and left atrial reverse remodelling across different stages of heart failure development and progression: a new target for prevention and treatment. *Eur J Heart Fail*. 2022;24(6):959-975. doi:10.1002/ehfj.2562
- Lang RM, Badano LP, Mor-Avi V, et al. Recommendations for Cardiac Chamber Quantification by Echocardiography in Adults: An Update from the American Society of Echocardiography and the European Association of Cardiovascular Imaging. *J Am Soc Echocardiogr*. 2015;28(1):1-39.e14. doi:10.1016/j.echo.2014.10.003

28. Ito T, Suwa M. Left atrial spontaneous echo contrast: relationship with clinical and echocardiographic parameters. *Echo Res Pract*. 2019;6(2):R65-R73. doi:10.1530/ERP-18-0083
29. Rich MW. CONGESTIVE HEART FAILURE IN OLDER ADULTS\*: Epidemiology, Pathophysiology, and Etiology of Congestive Heart Failure in Older Adults. *J Am Geriatr Soc*. 1997;45(8):968-974. doi:10.1111/j.1532-5415.1997.tb02968.x
30. Siegel RL, Miller KD, Wagle NS, Jemal A. Cancer statistics, 2023. *CA Cancer J Clin*. 2023;73(1):17-48. doi:10.3322/caac.21763
31. Gómez-Henao PA, Carreño-Dueñas JA. Cardiovascular pre-anesthesia evaluation in oncological surgery. *Colomb J Anesthesiol*. 2016;44(1):17-22. doi:10.1016/j.rcae.2015.05.005
32. D'Cruz IA, Feghali N, Gross CM. Echocardiographic Manifestations of Mediastinal Masses Compressing or Encroaching on the Heart. *Echocardiography*. 1994;11(5):523-533. doi:10.1111/j.1540-8175.1994.tb01093.x
33. Rodríguez C, Fortich F, Quintero ED. Invasión cardiaca de carcinoma sarcomatoide pulmonar a través de las venas pulmonares. *Rev Colomb Cardiol*. 2014;21(4):241-245. doi:10.1016/j.rccar.2014.05.004
34. Seca L, Barra S, Matos H. Invasión cardiaca de tumor de esófago. *Rev Esp Cardiol*. 2013;66(8):664. doi:10.1016/j.recesp.2011.10.036
35. Herrmann J. Adverse cardiac effects of cancer therapies: cardiotoxicity and arrhythmia. *Nat Rev Cardiol*. 2020;17(8):474-502. doi:10.1038/s41569-020-0348-1
36. Khorana AA, Mackman N, Falanga A, et al. Cancer-associated venous thromboembolism. *Nat Rev Dis Primer*. 2022;8(1):11. doi:10.1038/s41572-022-00336-y
37. Bhasin-Chhabra B, Koratala A. Point of care ultrasonography in onco-nephrology: A stride toward better physical examination. *World J Nephrol*. 2023;12(2):29-39. doi:10.5527/wjn.v12.i2.29
38. Ávila-Reyes D, Acevedo-Cardona AO, Gómez-González JF, Echeverry-Piedrahita DR, Aguirre-Flórez M, Giraldo-Diaconeasa A. Point-of-care ultrasound in cardiorespiratory arrest (POCUS-CA): narrative review article. *Ultrasound J*. 2021;13(1):46. doi:10.1186/s13089-021-00248-0
39. Robertson LC, Al-Haddad M. Recognizing the critically ill patient. *Anaesth Intensive Care Med*. 2013;14(1):11-14. doi:10.1016/j.mpac.2012.11.010
40. Zhao Y, Zhang H, Zhang D. Effect of positive end-expiratory pressure on right heart function in mechanically ventilated patients: An ultrasonography based study. *KUWAIT Med J*. Published online 2020.
41. Pérez Nieto OR, Zamarrón López EI, Guerrero Gutiérrez MA, et al. PEEP: dos lados de la misma moneda. *Med Crítica*. 2021;35(1):34-46. doi:10.35366/99152
42. Disselkamp M, Adkins D, Pandey S, Coz Yataco AO. Physiologic Approach to Mechanical Ventilation in Right Ventricular Failure. *Ann Am Thorac Soc*. 2018;15(3):383-389. doi:10.1513/AnnalsATS.201707-533CC
43. Zaidi A, Knight DS, Augustine DX, et al. Echocardiographic Assessment of the Right Heart in Adults: A Practical Guideline from the British Society of Echocardiography. *Echo Res Pract*. 2020;7(1):G19-G41. doi:10.1530/ERP-19-0051
44. Kearney D, Reisinger N, Lohani S. Integrative Volume Status Assessment. *POCUS J*. 2022;7(Kidney):65-77. doi:10.24908/pocus.v7i1Kidney.15023
45. Lescroart M, Pequignot B, Janah D, Levy B. The medical treatment of cardiogenic shock. *J Intensive Med*. Published online January 2023:S2667100X22001219. doi:10.1016/j.jointm.2022.12.001
46. Sattin M, Burhani Z, Jaidka A, Millington SJ, Arntfield RT. Stroke Volume Determination by Echocardiography. *Chest*. 2022;161(6):1598-1605. doi:10.1016/j.chest.2022.01.022
47. Santoro F, Mallardi A, Leopizzi A, et al. Stepwise approach for diagnosis and management of Takotsubo syndrome with cardiac imaging tools. *Heart Fail Rev*. 2022;27(2):545-558. doi:10.1007/s10741-021-10205-7
48. Citro R, Okura H, Ghadri JR, et al. Multimodality imaging in takotsubo syndrome: a joint consensus document of the European Association of Cardiovascular Imaging (EACVI) and the Japanese Society of Echocardiography (JSE). *J Echocardiogr*. 2020;18(4):199-224. doi:10.1007/s12574-020-00480-y
49. Carbone F, Liberale L, Preda A, Schindler TH, Montecucco F. Septic Cardiomyopathy: From Pathophysiology to the Clinical Setting. *Cells*. 2022;11(18):2833. doi:10.3390/cells11182833
50. Chrissoheris MP, Libertin C, Ali RG, Ghantous A, Bekui A, Donohue T. Endocarditis Complicating Central Venous Catheter Bloodstream Infections: A Unique Form of Health Care Associated Endocarditis: Endocarditis complicating CVC-BSI. *Clin Cardiol*. 2009;32(12):E48-E54. doi:10.1002/clc.20498
51. Kalagara H, Coker B, Gerstein NS, et al. Point-of-Care Ultrasound (POCUS) for the Cardiothoracic Anesthesiologist. *J Cardiothorac Vasc Anesth*. 2022;36(4):1132-1147. doi:10.1053/j.jvca.2021.01.018
52. Rajagopal S, Ruetzler K, Ghadimi K, et al. Evaluation and Management of Pulmonary Hypertension in Noncardiac Surgery: A Scientific Statement From the American Heart Association. *Circulation*. Published online March 16, 2023:CIR.000000000001136. doi:10.1161/CIR.0000000000001136
53. Chayanupatkul M, Liangpunsakul S. Cirrhotic cardiomyopathy: review of pathophysiology and treatment. *Hepatol Int*. 2014;8(3):308-315. doi:10.1007/s12072-014-9531-y
54. Esmaeilzadeh M, Parsaee M. The Role of Echocardiography in Coronary Artery Disease and Acute Myocardial Infarction. Published online 2013.
55. Prisco L, Sarwal A, Ganau M, Rubulotta F. Toxicology of Psychoactive Substances. *Crit Care Clin*. 2021;37(3):517-541. doi:10.1016/j.ccc.2021.03.013
56. Pergolizzi JV, Magnusson P, LeQuang JAK, Breve F, Varrassi G. Cocaine and Cardiotoxicity: A Literature Review. *Cureus*. Published online April 20, 2021. doi:10.7759/cureus.14594
57. Schranz A, Barocas JA. Infective Endocarditis in Persons Who Use Drugs. *Infect Dis Clin North Am*. 2020;34(3):479-493. doi:10.1016/j.idc.2020.06.004



## Editorial Board

### Editor In Chief

Benjamin Galen, MD

*Bronx, NY*

### Former Editor In Chief and Founder

Amer Johri, MD

*Kingston, ON*

### Anesthesiology

Wilfredo Puentes, MD

*London, ON*

Rob Tanzola, MD

*Kingston, ON*

### Cardiology

Nidhish Tiwari, MD

*Bronx, NY*

Ritu Thamman, MD

*Pittsburgh, PA*

### Emergency Medicine

Wilma Chan, MD

*Philadelphia, PA*

Casey Glass, MD

*Winston-Salem, NC*

### Global Health

Michelle Fleshner, MD

*Aurora, CO*

Gordon Johnson, MD

*Portland, OR*

### Internal Medicine

Trevor Jensen, MD

*San Francisco, CA*

Tanping Wong, MD

*New York, NY*

### Nephrology

Abhilash Koratala, MD

*Milwaukee, WI*

Nathaniel Reisinger, MD

*Philadelphia, PA*

### Pediatrics

Ria Dancel, MD

*Chapel Hill, NC*

Beryl Greywoode, MD

*Philadelphia, PA*

### Pulmonary and Critical Care

Cameron Baston, MD

*Philadelphia, PA*

Segun Olusanya, MD

*London, UK*

### Managing Editor

Julia Herr, MSc

*Brandon, MB*

### Co-Managing Editor / Social Media Editor

Braeden Hill, BHSc

*Kingston, ON*

## Call for Submissions

Physicians, Researchers, and Educators are invited to contribute articles to upcoming issues of POCUS Journal.

For detailed information, visit [pocusjournal.com/about/instructions-to-authors](http://pocusjournal.com/about/instructions-to-authors).

For inquiries or proposed topics, please contact the editors at [submit@pocusjournal.com](mailto:submit@pocusjournal.com).

## About Us

**POCUS Journal** is dedicated to the advancement of research and the promotion of education in the field of point of care ultrasound.

POCUS journal can be found online at [pocusjournal.com](http://pocusjournal.com).

You can receive email updates when a new issues is available by subscribing to the POCUS Journal email newsletter. Visit [pocusjournal.com/subscribe](http://pocusjournal.com/subscribe).

To submit your case study or letter for publication in POCUS Journal, visit [pocusjournal.com/submit](http://pocusjournal.com/submit).

**If you would like to advertise in POCUS Journal, make a donation or announcement, email at [info@pocusjournal.com](mailto:info@pocusjournal.com)**

All online versions of POCUS Journal are available at [ojs.library.queensu.ca/index.php/pocus/index](http://ojs.library.queensu.ca/index.php/pocus/index) as well as all supplementary material.

**POCUS Journal is a publication by CINQUILL**

POCUS Journal is published by CINQUILL Medical Publishers Inc. with support from the Queen's University Library.

CINQUILL  
76 Stuart St.,  
Kingston, ON, Canada  
K7L 2V7



**CARDIOVASCULAR  
IMAGING NETWORK**  
at Queen's University