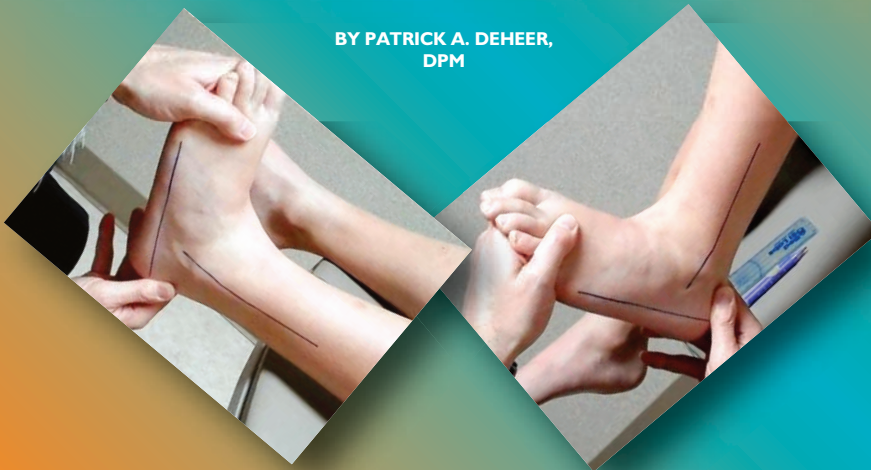

# Understanding Equinus

This profound causal agent is commonly overlooked and under-treated.

BY PATRICK A. DEHEER,  
DPM



## Goals and Objectives

After completing this CME, the reader should:

- 1) Understand the definition of equinus.
- 2) Understand the evaluation of equinus.
- 3) Understand the treatment of equinus based on evidence based medicine.
- 4) Become more aware of the role of equinus in foot and ankle pathology.
- 5) Include equinus treatment as part of a global treatment plan, when indicated.

Welcome to Podiatry Management's CME Instructional program. Our journal has been approved as a sponsor of Continuing Medical Education by the Council on Podiatric Medical Education.

You may enroll: 1) on a per issue basis (at \$22.00 per topic) or 2) per year, for the special rate of \$169 (you save \$51). You may submit the answer sheet, along with the other information requested, via mail, fax, or phone. You can also take this and other exams on the Internet at [www.podiatrym.com/cme](http://www.podiatrym.com/cme).

If you correctly answer seventy (70%) of the questions correctly, you will receive a certificate attesting to your earned credits. You will also receive a record of any incorrectly answered questions. If you score less than 70%, you can retake the test at no additional cost. A list of states currently honoring CPME approved credits is listed on pg. 166. Other than those entities currently accepting CPME-approved credit, Podiatry Management cannot guarantee that these CME credits will be acceptable by any state licensing agency, hospital, managed care organization or other entity. PM will, however, use its best efforts to ensure the widest acceptance of this program possible.

**This instructional CME program is designed to supplement, NOT replace, existing CME seminars.** The goal of this program is to advance the knowledge of practicing podiatrists. We will endeavor to publish high quality manuscripts by noted authors and researchers. If you have any questions or comments about this program, you can write or call us at: **Podiatry Management, P.O. Box 490, East Islip, NY 11730, (631) 563-1604 or e-mail us at [bblock@podiatrym.com](mailto:bblock@podiatrym.com).**

Following this article, an answer sheet and full set of instructions are provided (pg. 166).—*Editor*

**E**quinus has been described as “the most profound causal agent in foot pathomechanics and is frequently linked to common

foot pathology,” and also has been described as “the greatest symptom producer of the human foot;” yet it is commonly overlooked and under-treated. The importance of equinus

cannot be overstated, and its management is crucial to treating of the underlying pathology of all the following foot and ankle conditions as

*Continued on page 158*

documented in the literature:

Heel spur syndrome/plantar fasciitis, Achilles tendinopathy, posterior tibial tendon dysfunction, diabetic foot ulcers, Charcot neuropathy, metatarsalgia, Morton's neuroma, lesser MPJ pathologies—PDS, capsulitis, hallux valgus, hammer digit syndrome, ankle fracture/sprains, Sever's disease, pediatric flatfoot deformity, osteoarthritis forefoot/midfoot, 1st ray hypermobility, pes plano valgus, hallux limitus, sesamoiditis, lateral column syndrome, Freiberg's infarction, and forefoot callus. So, if equinus is so prevalent, how come there is often a failure in recognition, association to pathology, and treatment of this condition?

There are several factors at play that all lead to this underappreciation and lack of treatment with equinus. It all starts with the definition of equines, as there is no standard definition. The next crucial factor is the lack of appreciation of the relationship between equinus and the above-listed pathologies. Finally, the lack of treatment is related directly to ineffectual conservative management of the condition. Let's take a journey through equinus to fully understand the condition, and hopefully therefore bring to it the respect it is due.

### Anatomy

Most pathologies of the foot and ankle start with anatomy. The anatomy of the triceps surae consists of the gastrocnemius, soleus, and plantaris muscles. The gastrocnemius muscle originates on the posterior aspect of the

muscle crosses the knee, ankle, and subtalar joints. This is a very important factor; the multi-joint crossing is

The soleus originates on the posterior aspect of the head of the fibular, the middle one-third of the medial

## There is a well-documented zone of hypovascularity 4-5 cm proximal to the insertion of the Achilles tendon.

directly related to the most common form of equinus, gastrocnemius equinus. The aponeurosis of the gastroc-

border of the tibia, the soleal line, and the interosseous membrane. The aponeurosis of the soleus is posterior to the muscle. The soleus only crosses the ankle and subtalar joints. The soleus is innervated by the tibial nerve and its arterial supply is that of the tibial, peroneal, and sural arteries. The primary function of the sural artery is to stabilize the leg onto the foot and plantarflex the ankle joint.

The plantaris tendon originates medial and superior to the lateral head of the gastrocnemius muscle at the lateral head of the femoral condyle, coursing lateral to the gastrosoleal complex and medial to it. The plantaris tendon can be absent 7 % of the time.

The Achilles tendon is the continuation of the aponeurosis of the gastrocnemius and soleus merging together, forming the largest, thickest, strongest tendon in the body, approximately 15 centimeters long. The tendon inserts into the middle one-third of the posterior aspect of the calcaneus with the plantaris tendon inserting medial to the Achilles tendon.

There is a retrocalcaneal bursa between the Achilles tendon and the calcaneus. The fibers of the Achilles tendon rotate laterally approximately 90° so that the gastrocnemius fibers insert primarily laterally and the soleus fibers insert primarily medially. The tendon is surrounded by a tendon sheath which allows gliding of the tendon, and below this sheath is the paratenon, which protects and nourishes the tendon. The vascular

*Continued on page 159*

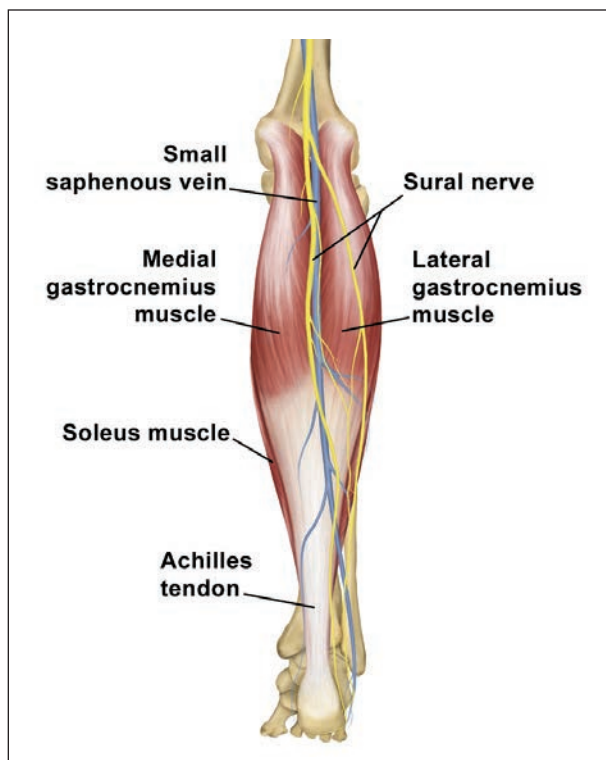


Figure 1: Posterior view of the GSC complex and related anatomical structures.

nemius muscle is anterior to the muscle. Its primary blood supply is from the popliteal and sural arteries, and it is innervated by the tibial nerve. The

## The gastrocnemius muscle crosses the knee, ankle, and subtalar joints.

femoral condyles and posterior knee capsule with the medial head being the larger of the two, and descending further distally. The gastrocnemius

gastrocnemius primary act to supply power for propulsion, knee flexion, and plantarflexion of the ankle joint (Figure 1).

supply of the Achilles tendon is from the myotendinous junction, the paratenon, and the calcaneal periosteum. There is a well-documented zone of hypovascularity 4-5 cm proximal to the insertion of the tendon.

### Definition

After understanding the anatomy, the definition becomes the next most crucial factor and is surprisingly difficult, especially among different specialties. The definition of equinus ranges from  $-10^{\circ}$  to  $+22^{\circ}$  in the literature, with  $+10^{\circ}$  as a consensus of thirteen different studies. Sgarlato<sup>36</sup> in *The Journal of American Podiatric Medical Association* in 1975 first described the definition as  $+10^{\circ}$  with the subtalar joint in neutral position and the midtarsal joint locked.

### Pseudoequinus

There are two primary types of equinus—muscular and osseous, with subgroups of each kind. In the muscular group there can be either spastic or non-spastic equinus. Either of these subgroups of spastic or non-spastic equinus can further be broken down into gastrocnemius or gastrosoleus equinus. The osseous forms of equinus include: anterior tibiotalar exostosis (best seen on a lateral charger view on X-ray), distal tibial-fibular osseous bridging from prior trauma, pseudoequinus and combined equinus. Pseudoequinus occurs in the cavus foot structure where ankle joint dorsiflexion occurs to dorsiflex the forefoot, which is plantarflexed to the rearfoot. The ankle dorsiflexion used to do this then limits the amount available for normal

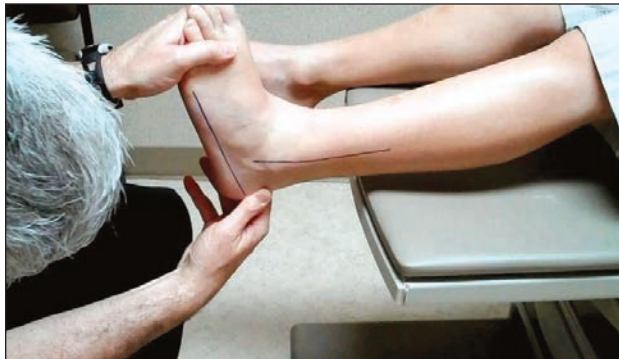

Figure 2: The Silverskiold test is used to evaluate for equinus. This demonstrates evaluation of the dorsiflexion of the ankle joint with the knee extended.

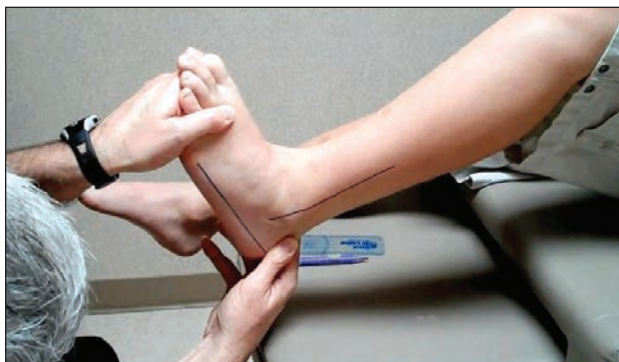

Figure 3: Evaluation of the ankle joint dorsiflexion with the knee bent removes the pull of the gastrocnemius muscle and allows the practitioner to determine whether equinus is gastrocnemius equinus or gastrosoleal equinus.

ambulation, therefore the term pseudoequinus. The combined equinus is just a combination of one type of muscular and osseous equinus.

### Clinical Evaluation

Evaluation of equinus clinically is one of the primary stumbling blocks

and ankle is dorsiflexed maximally with the knee in full extension and then checked with the knee in flexion (Figures 2 and 3). If the ankle joint dorsiflexes greater than  $90^{\circ}$  with both the knee extended and flexed, there is no equinus. If the ankle joint dorsiflexes greater than  $90^{\circ}$  with the knee flexed by less than  $90^{\circ}$  with the knee extended, the result is gastrocnemius equinus. If the ankle dorsiflexion is less than  $90^{\circ}$  with both the knee flexed and extended, then it can either be gastro-soleus equinus or osseous equinus. This is determined by the quality of the end range-of-motion and with a charger dorsiflexion stress lateral ankle x-ray. A soft end range-of-motion is more likely a gastrosoleus equinus, especially if no anterior or ankle impingement is noted on the x-ray.

### Biomechanics of Equinus

Understanding the biomechanics of equinus is crucial to getting an appreciation of the devastation it has on the foot pathomechanics. The center of pressure is about 6 cm anterior to the ankle, roughly over the dorsal 2nd metatarsal-cuneiform joint. This would make us fall forward in normal standing, but that reaction is negated by the pull of the plantarflexors. The triceps surae has been documented to be the primary plantarflexor of the ankle joint and therefore offsets the anteriorly displaced center of pressure. It has further been demonstrated with equinus that the center of pressure moves about 3 cm distally

**If the ankle joint dorsiflexes  
greater than  $90^{\circ}$  with the knee flexed by less than  $90^{\circ}$   
with the knee extended,  
the result is gastrocnemius equinus.**

between professions that inhibit effective communication. The Silverskiold test is what is used to determine the type of equinus. In this examination, the subtalar is placed in neutral position and the midtarsal joint is locked by supination of the forefoot. The

and 3 mm laterally (Figures 4 and 5).

The important concept lies in the relation of the subtalar axis to the center of pressure and the subtalar axis to the insertion of the Achilles tendon. The Achilles tendon inserts

*Continued on page 160*

medially to the subtalar axis and its distance from the axis is about the same as the laterally placed center of pressure to the subtalar axis in a foot with a normal subtalar axis and no equinus. The medial position of the Achilles creates a supinatory moment, while the lateral center of pressure due to ground reactive forces (GFR) creates a pronatory moment. These two cancel each other out, providing a rectus foot structure.

When equinus is present, the distal and lateral positioning of the center of pressure in relation to the subtalar axis creates an increased pronatory effect on the foot due to GRF, which is not offset by the supinatory effect of the Achilles tendon. When the subtalar joint axis is more medially deviated, such as in a pronated foot, this further distances the center of pressure from the subtalar axis, causing even more pronatory deformity due to GRF. The opposite occurs in the supinated foot, where the subtalar joint axis is more laterally deviated to the point where even the center of pressure is on the subtalar axis, medial to the subtalar axis or just lateral to the subtalar axis. This puts both the Achilles and center of pressure in supinatory moments (or at least is a lesser pronatory moment than the supinatory moment of the

Achilles tendon) due to GRF—therefore making a cavus foot worse over a period of time due to increased rear-foot varus, peroneal pathology, and subtalar instability.

Johnson and Christensen<sup>17</sup> examined the effects of equinus on first ray pathomechanics using cadaver

joint locking leads to the above described medial column instability. This study showed that the effect of equinus is not a stretching of the plantar ligaments over a period of time that leads to first ray instability but, in fact, is a dampening of the peroneus longus function that leads

**An important question that is often overlooked in the biomechanical discussion of equinus is the effect of pronation on the GSC.**

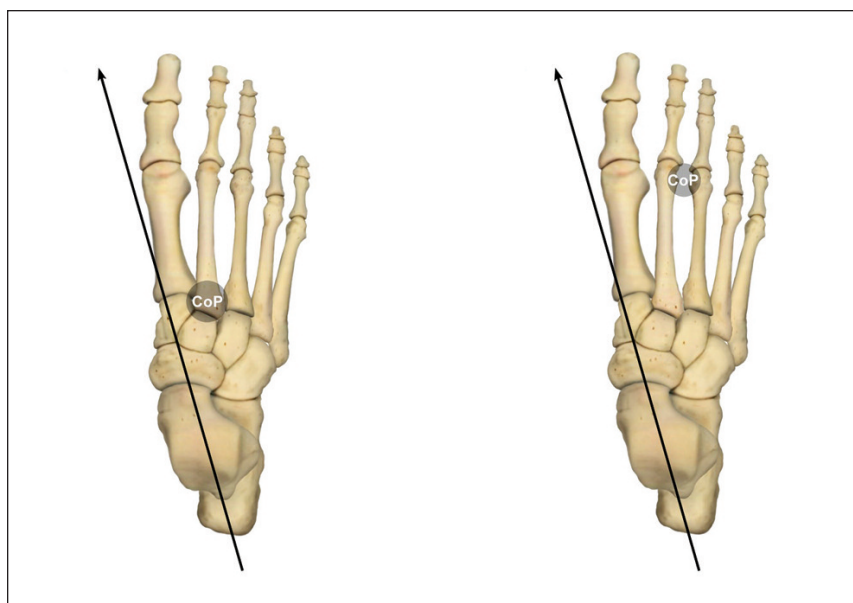
weight-bearing models in their landmark series on first ray pathomechanics. Sensors were applied to each of the individual bones making up the medial column of the foot. Loading of the Achilles tendon was applied and then three-dimensional data were recorded for each segment of the medial column. The results showed plantarflexion of the talus and navicular, and dorsiflexion of the medial cuneiform and 1st metatarsal occurring through the naviculacuneiform joint. This occurs due to dampening of the effect of the peroneal longus tendon eversion of the medial cuneiform that leads to locking of the midtarsal joint. This lack of midtarsal

to first ray hypermobility.

An important question that is often overlooked in the biomechanical discussion of equinus is the effect of pronation on the GSC. Kevin Kirby, DPM says via personal communication, “accommodative shortening of the GSC will occur with prolonged medial deviation of the STJ axis and flattening of the medial arch of the foot.”

Sgarlato<sup>36</sup> described three types of compensation for equinus. The uncompensated equinus deformity manifests itself as a toe walker due to lack of ankle joint dorsiflexion and/or MTJ pronation to get the heel down to the ground. This accounts for about only 1% of equinus cases. In the partially compensated equinus deformity, the heel is on the ground but the tibia does not achieve 10 degrees of flexion to the ground. This results in an early heel-off gait pattern. When the equinus deformity is fully compensated, the result is the severely pronated, hypermobile foot with heel contact to ground and the tibia achieving more than 10 degrees of flexion to the ground. Heel-off in the fully compensated equinus deformity is normal.

The proximal pathologies associated with equinus are numerous and easily overlooked due to the profound distal pathologies that often overshadow these proximal deformities. Lumbar lordosis, hip flexion, knee flexion, genu recurvatum, and hamstring contractures have all been attributed to equinus. The more obvious distal pathologies that directly result from



Figures 4 & 5: The center of pressure is located as shown on the left drawing approximately 6 cm distal to the ankle joint. With equinus deformity the center of pressure moves distal and lateral further away from the subtalar joint axis as shown on the right drawing.

*Continued on page 161*



Figure 6: In this side view of the EQ/IQ brace, you can see the hinge to be placed at the knee joint. When the brace crosses the knee joint, it allows for stretching of the entire GSC. The hinge allows for the brace to engage just the soleus if taken down or the entire GSC if left intact.

or have a relationship to equinus will be discussed with some of the well-documented literature.

In Hill's<sup>15</sup> article, the incidence of equinus with pathological conditions was studied by examining 209 new patient visits over a six week period of time. Twenty-nine patients were excluded from the study because they did not meet study criteria. Of

DiGiovanni<sup>8</sup> in the *Journal of Bone and Joint Surgery* (2002) examined ankle joint dorsiflexion in symptomatic patients and a control group, and the reliability of goniometer testing. The ankle joint dorsiflexion with the knee extended averaged 4.5 degrees in the symptomatic group and 13.1 degrees in the control group. The percentage of symptomatic patients with less than 5 degrees dorsiflexion was 65% and the control group was 24%, while the amount with less than 10 degrees dorsiflexion was 88% and 44%, respectively. The correct diagnosis via a goniometer, confirmed with an equinometer for the less than

findings of this study. Arriving at a standard definition is crucial for equinus and is the first step to standardized treatment protocols.

Aronow's<sup>1</sup> study was one of the first to not only explore the changes on forefoot and rearfoot pressures associated with equinus, but also to examine the midfoot changes as well. A load was applied to the GSC and then to just the gastrocnemius muscle, and then the changes in pressures were measured. In the GSC group, the rearfoot pressures decreased (18%) and the midfoot (38%) and forefoot (59%) increased. In the gastrocnemius group, the rearfoot pressures de-

### Patel and DiGiovanni<sup>25</sup> found that 83% of plantar fasciitis cases were associated with equinus.

5 degree group, was 76% for the symptomatic group and 94% for the control group, while the 10 degree group diagnosis was correct 88% and 79%, respectively.

This study has helped to clarify the definition of equinus, which has a wide range of definitions in the literature, with the most common definition being 10 degrees of dorsiflexion with the knee extended and the subtalar joint in neutral position and the midtarsal joint locked. This was originally described by Sgarlato<sup>36</sup> in

creased (16%) and the midfoot (32%) and forefoot (50%) increased. These numbers were very consistent with other studies on the effect of equinus and forefoot pressure changes, such as Jones<sup>18</sup> in *The American Journal of Anatomy* in 1941 and Ward<sup>43</sup> in *The Journal of the American Podiatric Medical Association* in 1998. When the loads were removed, the pressures on the forefoot decreased 32% and the rearfoot pressures increased 32%. These additional findings were similar to those of Mueller<sup>22</sup> in *The Journal Bone and Joint Surgery* 2003, who measured the effect of a tendo-Achilles lengthening on pressure changes in the foot. In Mueller's study, the forefoot pressures decreased 31% and the rearfoot pressures increased by 34%.

### In Mueller's study, the forefoot pressures decreased 31% and the rearfoot pressures increased by 34%.

the remaining 174 patients, six had normal ankle joint dorsiflexion, leaving 168 of the patients exhibiting equinus. Three of the patients had gastrocnemius equinus and 165 had GSC equinus. Their definition for equinus was less than 3-degrees dorsiflexion with knee extension. Their findings were that 96.5% of the patients with foot and ankle pathology exhibited equinus.

JAPMA 1975. According to DiGiovanni's<sup>8</sup> findings, with ankle joint dorsiflexion of less than 5 degrees, the correct diagnosis was made 76% of the time in the symptomatic group, and the incorrect diagnosis was avoided in 94% of the time in the control group. I believe the standard definition for equinus should therefore be 5 degrees of ankle joint dorsiflexion with the knee extended based on the

#### Plantar Fasciitis and Equinus

The relationship with plantar fasciitis and equinus is well documented in the literature, with an estimated 2,000,000 cases of plantar fasciitis per year in the United States. Patel and DiGiovanni<sup>25</sup> found that 83% of plantar fasciitis cases were associated with equinus. Cheung, et al.<sup>3</sup> showed that equinus caused twice the amount of strain on the plantar fascia

*Continued on page 162*

as body weight. This reaffirmed the close relationship between plantar fasciitis and equinus. Any treatment plan for plantar fasciitis must include equinus management.

Treatment of equinus can be broken down into either conservative

only mode of bracing for equinus treatment, but there are several flaws with them. First, they are designed to be used at night while sleeping and the most common sleeping position with these braces is on the side with knees bent. This means that the gas-

The hinge can be released to allow for ease of application and isolated stretching of the soleus. There is also a hinge at the ankle joint which allows the treating physician to set exactly the amount of dorsiflexion desired based on the patient's biomechanical exam (we see maybe 5 degrees the first month, going up to 10 degrees the second month, and if needed 15 degrees the third month).

The hinge goes from -30 degrees to +30 degrees, in 5 degree increments (Figure 7). As podiatrists, we measure everything from x-ray angles to forefoot varus position. Yet we slap on a night splint and tell our patients to pull as tight as they can. This makes no sense to us; we should have more control and precision over the treatment of this condition. We have made this brace ambulatory with a negative heel rocker sole, which allows ambulation with a fixed dorsiflexed position. The rocker soles are removable and come in different soles to match the amount of ankle joint dorsiflexion (i.e., 5, 10, and 15 degrees). There is an adjustable wedge that goes under the hallux to engage the windlass mechanism, which supinates the rearfoot and also puts additional stretch on the plantar fascia. The supination of the rearfoot is important as it puts the foot in the most desirable position for stretching of the GSC. These wedges come in various degrees (i.e., 35, 50, and 65 degrees) and Velcro to the foot bed (Figure 8). We made varying degrees

---

**According to Hill,  
It is critical that the foot be adducted 10 degrees  
during the stretching to lock the subtalar-mid tarsal  
joints for maximum benefit at the calf.**

---

care or surgical care. As with most pathologies, conservative care should be attempted initially. The two main forms of conservative care are manual stretching and bracing.

Radford, et al.<sup>28</sup> in a meta-analysis showed that calf muscle stretching provided a small but statistically significant increase in ankle joint dorsiflexion. Their analysis showed that 15 to 30 minutes per day provided the greatest amount of ankle joint dorsiflexion (3.03 degrees) for each of the three groups. Grady and Saxena<sup>12</sup> in their study had patients stretch once per day over a six-month period of time for 30 seconds, 2 minutes, or 5 minutes with the knee extended. The increase in ankle joint dorsiflexion for each group was 2.15, 2.3, and 2.7 degrees, respectively. These totals were not statistically significant, but when one takes into account the minimal amount of stretching done daily, the results are actually encouraging.

Hill<sup>15</sup> discussed the problems with manual stretching stating, "Active stretching requires detail in teaching the proper technique, and must be done at least four times a day at five-minute to eight-minute sessions. The most serious mistakes patients make during their previous attempts at stretching are inadequate stretch time and abducted foot position during the stretch. It is critical that the foot be adducted 10 degrees during the stretching to lock the subtalar-mid tarsal joints for maximum benefit at the calf."

Night splints have long been the

trocnemius muscle is not being stretched. Remembering that the gastrocnemius muscle crosses both the knee and ankle, it is most often the contracted structure. This accounts for the ineffective nature of night splints. Based on our personal experience, compliance with night splints is also very poor. These two factors led to the mediocre results attributed to night splints as described in the Evans<sup>9</sup> study, which showed only 6 of 20 patients achieving 10 degrees of dorsiflexion with the use of night splints.

#### **EQ/IQ Brace**

The answer we have developed to address ineffectual manual stretching and the failures of night splints is the EQ/IQ brace. This brace does not need to be slept in. We recommend

using it 30 minutes in the morning and 30 minutes in the evening (15 stretching the GSC, and 15 minutes stretching the soleus). Let's discuss features of the EQ/IQ brace from proximal to distal. There is an above-the-knee extension with a hinge at the knee (Figure 6). The extension allows the knee to be locked into extension to stretch the gastrocnemius muscle.

of wedges to allow for those with hallux limitus or rigidus. The femoral and tibial uprights are adjustable for leg and thigh length and should be set by the physician. Finally, the standard foot beds will fit a small/medium size, but it can be replaced to an extended version that will fit a large/extra-large size.

*Continued on page 163*

The time period we recommend is based on recommendations for manual stretching from the meta-analysis by Radford<sup>28</sup>, but doubled. Most manual stretching is recommended to be done about 30 minutes per day. An hour a day is reasonable from a compliance standpoint, compared to 6 to 8 hours at night while disturbing the patient's sleep. The ambulatory component of the brace is important also. We foresee patients getting dressed in the morning while then putting on the brace and then stretching while performing their morning rituals. A similar scenario would play itself out for the evening stretching. Additionally, the ambulatory nature of the brace provides an active stretching compo-

hemisection. This procedure employs three stab incisions starting one centimeter proximal to the insertion of the GSC, with two medial incisions and one lateral incision between the two medial incisions. The tendon is sectioned through the central portion and incised in the respective direction of the stab incisions. The tendon then slides to a lengthened position. This procedure is not without potential complications, such as under-lengthening, or much worse, over-lengthening.

The gastrocnemius recession is one of our favorite procedures and is well documented in the literature. We prefer the Bauman intramuscular approach to lengthening of the gastroc-

and *Ankle International* 2007.)

The pre-operative group had 1 degree of ankle joint dorsiflexion with the knee extended, and after gastrocnemius recession, single and double dorsiflexion increased significantly (9 and 15 degrees, respectively). Adding a soleus recession only increased dorsiflexion by one degree—thus it is more effective to perform a double gastrocnemius recession.

The treatment of equinus alone has shown to be effective for foot symptomatology without doing anything to the pathology within the foot. Maskill, et al.<sup>21</sup> examined the effect of an isolated gastrocnemius recession on 29 patients (34 feet) that failed six months of conservative therapy. The measure was the visual analog scale (VAS) and there were three categories of patients (plantar fasciitis, midfoot pain, and arch pain). The VAS scores pre-operatively and post-operatively were as follows for each group: plantar fasciitis 8.1 to 1.9, midfoot pain 7.5 to 2.2, and arch pain 9.3 to 3.3. These drastic pain scale changes were the result of only a gastrocnemius recession without doing anything to the foot.

Equinus is an underlying factor in most of the pathologies associated with the foot and ankle and must be addressed either conservatively or surgically as part of the overall treatment plan for any condition associated with it. If the equinus deformity is left untreated, the condition is never fully treated and outcomes are not as high as they should be. Education of patients to the importance of equinus treatment in their overall treatment plan must be discussed to ensure compliance and the highest overall outcomes. **PM**

## References

<sup>1</sup> Aronow, MS; Diaz-Doran, V; Sullivan, RJ; Adams, DJ. The effect of triceps surae contracture force on plantar foot pressure distribution. *Foot Ankle Int.* 27:43-52, 2006.

<sup>2</sup> Charles, J; Scutter, SD; Buckley, J. Static ankle joint equinus. *J Am Podiatr Med Assoc.* 100:195-203, 2010.

<sup>3</sup> Cheung, JT; Zhang, M; An, KN. Effect of Achilles tendon loading on plantar fascia tension in the standing foot. *Clin*

*Continued on page 164*

## The surgical approach to equinus is well documented in the literature and focuses mainly on two different procedures, the tendo-Achilles lengthening (TAL) or gastrocnemius recession.

nent as well as a static stretching component. A final consideration is that this is not a brace that patients will be able to buy at a drug store or on the Internet. We have had patients complain about the expense of a night splint when they can find the same thing for about 20% of what is charged for the brace. This is a technical device that must be set, monitored, and adjusted by a physician. This brace will have a significant positive impact on a practice management component of your practice. Most importantly, it will provide you a better way to treat the most significant producer of foot and ankle pathologies—equinus deformity.

### Surgical Approaches to Equinus

The surgical approach to equinus is well documented in the literature and focuses on mainly two different procedures, the tendo-Achilles lengthening (TAL) or gastrocnemius recession. The TAL approach most commonly utilized is the Hoke triple

nemius aponeurosis. This provides controlled, sequential lengthening. The incision is placed at the medial aspect of the calf, midway between the posterior calf and anterior border of the tibia. The incision is typically 3-4 cm long and is deepened to the level of the deep fascia. The fascia is incised, revealing the gastrocnemius and soleus muscle bellies. Using a finger to identify the natural separation between the aponeurosis of the two muscles, an anal speculum is inserted to spread them apart. The foot is dorsiflexed with the knee extended, and a long-handled #15 blade is used to cut the proximal portion of the gastrocnemius aponeurosis, including the intramuscular septum. This is a complete release from lateral to medial. The foot is dorsiflexed and the positioned examined. If inadequate dorsiflexion is noted, a second more distal (1 cm distal to the initial release) incision is recommended over a soleus recession (this is based on the study by Herzenberg and Lamm<sup>14</sup> in *Foot*

- Biomech. 21:194-203, 2006.
- <sup>4</sup> Chimera, NJ; Castro, M; Manal, K. Function and strength following gastrocnemius recession for isolated gastrocnemius contracture. *Foot Ankle Int.* 31:377-384, 2010.
- <sup>5</sup> Dananberg, HJ; Shearstone, J; Guiliano, M. Manipulation method for the treatment of ankle equinus. *J Am Podiatr Med Assoc.* 90:385-389, 2000.
- <sup>6</sup> Davis, PF; Severud, E; Baxter, DE. Painful heel syndrome: results of nonoperative treatment. *Foot Ankle Int.* 15:531-535, 1994.
- <sup>7</sup> Dietz, FR; Albright, JC; Dolan, L. Medium term follow up of Achilles tendon lengthening in the treatment of ankle equinus in cerebral palsy. *Iowa Orthop J.* 26:27-32, 2006.
- <sup>8</sup> DiGiovanni, CW; Kuo, R; Tejwani, N; Price, R; Hansen Jr, ST; Czerniecki, J; Sangeorzan, BJ. Isolated gastrocnemius tightness. *J Bone Joint Surg Am.* 84:962-970, 2002.
- <sup>9</sup> Evans, A. Podiatric medical applications of posterior night stretch splinting. *J Am Podiatr Med Assoc.* 91:356-360, 2001.
- <sup>10</sup> Flanigan, RM; Nawoczinski, DA; Chen, L; Wu, H; DiGiovanni, BF. The influence of foot position on stretching of the plantar fascia. *Foot Ankle Int.* 28:815-822, 2007.
- <sup>11</sup> Grady, JF; Kelly, C. Endoscopic gastrocnemius recession for treating equinus in pediatric patients. *Clin Orthop Relat Res.* 468:1033-1038, 2010.
- <sup>12</sup> Grady, JF; Saxena, A. Effects of stretching the gastrocnemius muscle. *J Foot Surg.* 30:465-469, 1991.
- <sup>13</sup> Grant, WP; Sullivan, R; Sonenshine, DE; Adam, M; Slusser, JH; Carson, KA; Vinik, AI. Electron microscopic investigation of the effects of diabetes mellitus on the Achilles tendon. *J Foot Ankle Surg.* 36:272-278, 1997.
- <sup>14</sup> Herzenberg, JE; Lamm, BM; Corwin, C; Sekel, J. Isolated recession of the gastrocnemius muscle: the Baumann procedure. *Foot Ankle Int.* 28:1154-1159, 2007.
- <sup>15</sup> Hill, RS. Prevalence and linkage to common foot pathology. *J Am Podiatr Assoc.* 85:295-300, 1995.
- <sup>16</sup> Holstein, A. Hallux Valgus—an acquired deformity of the foot in cerebral palsy. *Foot Ankle.* 1:33-38, 1980.
- <sup>17</sup> Johnson, CH; Christensen, JC. Biomechanics of the first ray part V: the effect of equinus deformity. *J Foot Ankle Surg.* 44:114-120, 2005.
- <sup>18</sup> Jones, RL. The human foot. An experimental study of its mechanics, and the role of its muscles and ligaments in the support of the arch. *Am J Anat.* 68:1-38, 1941.
- <sup>19</sup> Lamm, BM; Paley, D; Herzenberg, JE. Gastrocnemius soleus recession. A simpler, more limited approach. *J Am Podiatr Med Assoc.* 95:18-25, 2005.
- <sup>20</sup> Lavery, LA; Armstrong, DG; Boulton, AJ. Ankle equinus deformity and its relationship to high plantar pressure in a large population with diabetes mellitus. *J Am Podiatr Med Assoc.* 92:479-482, 2002.
- <sup>21</sup> Maskill, JD; Bohay, DR; Anderson, JG. Gastrocnemius recession to treat isolated foot pain. *Foot Ankle Int.* 31:19-23, 2010.
- <sup>22</sup> Mueller, MJ; Sinacore, DR; Hastings, MK; Strube, MJ; Johnson, JE. Effect of Achilles tendon lengthening on neuropathic plantar ulcers. A randomized clinical trial. *J Bone Joint Surg.* 85-A:1436-1445, 2003.
- <sup>23</sup> Myers, KA; Long, JT; Klein, JP; Wertsch, JJ; Janisse, D; Harris, GF. Biomechanical implications of the negative heel rocker sole shoe: Gait kinematics and kinetics. *Gait Posture.* 24:323-330, 2006.
- <sup>24</sup> Nemeč, SA; Habbu, RA; Anderson, JG; Bohay, DR. Outcomes following mid-foot arthrodesis for primary arthritis. *Foot Ankle Int.* 32:355-361, 2011.
- <sup>25</sup> Patel, A; DiGiovanni, B. Association between plantar fasciitis and isolated contracture of the gastrocnemius. *Foot Ankle Int.* 32:5-8, 2011.
- <sup>26</sup> Pinney, SJ; Sangeorzan, BJ; Hansen Jr, ST. Surgical anatomy of the gastrocnemius recession (Strayer procedure). *Foot Ankle Int.* 25:247-250, 2004.
- <sup>27</sup> Porter, D; Barrill, E; Oneacre, K; May, BD. The effects of duration and frequency of Achilles tendon stretching on dorsiflexion and outcome in painful heel syndrome: A randomized, blinded, control study. *Foot Ankle Int.* 23:619-624, 2002.
- <sup>28</sup> Radford, JA; Burns, J; Buchbinder, R; Landorf, KB; Cook, C. Does stretching increase ankle dorsiflexion range of motion? A systematic review. *Br J Sports Med.* 40:870-875, 2006.
- <sup>29</sup> Reimers, J; Pedersen, B; Brodersen, A. Foot deformity and the length of the triceps surae in Danish children between 3 and 17 years old. *J Pediatr Orthop [B].* 4:71-73, 1995.
- <sup>30</sup> Rompe, JD; Cacchio, A; Weil Jr, L; Furia, JP; Haist, J; Reiners, V; Schmitz, C; Maffulli, N. Plantar fascia-specific stretching versus radial shock-wave therapy as initial treatment of plantar fasciopathy. *J Bone Joint Surg Am.* 92:2514-2522, 2010.
- <sup>31</sup> Roukis, TS; Schweinberger, MH. Complications associated with uni-portal endoscopic gastrocnemius recession in a diabetic patient population: An observational case series. *J Foot Ankle Surg.* 49:68-70, 2010.
- <sup>32</sup> Rush, SM; Ford, LA; Hamilton, GA. Morbidity associated with high gastrocnemius recession: Retrospective review of 126 cases. *J Foot Ankle Surg.* 45:156-160, 2006.
- <sup>33</sup> Saxena, A; Kim, W. Ankle dorsiflexion in adolescent athletes. *J Am Podiatr Med Assoc.* 93:312-314, 2003.
- <sup>34</sup> Saxena, A; Ramdath, S; O'Halloran, P; Gerdesmeyer, L; Gollwitzer, H. Extracorporeal pulsed-activated therapy for Achilles tendinopathy: A prospective study. *J Foot Ankle Surg.* 50:315-319, 2011.
- <sup>35</sup> Scharfbillig, RW; Jones, S; Scutter, SD. Sever's disease: What does the literature really tell us? *J Am Podiatr Med Assoc.* 98:212-223, 2008.
- <sup>36</sup> Sgarlato, TE; Morgan, J; Shane, HS; Frenkenberg, A. Tendo Achilles lengthening and its effect on foot disorders. *J Am Podiatry Assoc.* 65:849-871, 1975.
- <sup>37</sup> Sheridan, L; Lopez, A; Perez, A; John, MM; Willis, FB; Shanmugam, R. Plantar fasciopathy treated with dynamic splinting. A randomized controlled trial. *J Am Podiatr Med Assoc.* 100:161-165, 2010.
- <sup>38</sup> Stovitz, SD; Coetzee, C. Hyperpronation and foot pain. *Phys Sportsmed.* 32:19-26, 2004.
- <sup>39</sup> Strayer, LM. Recession of the gastrocnemius: An operation to relieve spastic contracture of the calf muscles. *J Bone Joint Surg Am.* 32:671-676, 1950.
- <sup>40</sup> Tabrizi, P; McIntyre, WMJ; Quesnel, MB; Howard, AW. Limited dorsiflexion predisposes to injuries of the ankle in children. *J Bone Joint Surg Br.* 82:1103-1106, 2000.
- <sup>41</sup> Thordarson, DB; Schmotzer, H; Chon, J; Peters, J. Dynamic support of the human longitudinal arch. *Clin Orthop Rel Res.* 316:165-172, 1995.
- <sup>42</sup> Vallejo, RB; Iglesias, ME; Sanz, DR; Frutos, JC; Fuentes, PS; Chicharro, JL. Plantar pressures in children with and without Sever's disease. *J Am Podiatr Med Assoc.* 101:17-24, 2011.
- <sup>43</sup> Ward, ED; Phillips, RD; Patterson, PE; Werkhoven, GJ. The effects of extrinsic muscle forces on the forefoot-to-rear-foot loading relationship in vitro. *J Am Podiatr Med Assoc.* 88:471-482, 1998.



**Dr. DeHeer** is in private practice in Central Indiana. He is the team podiatrist for the Indiana Pacers and the Indiana Fever and is on the editorial Board of *Podiatry Today*. He is the inventor of the EQ/IQ brace, President and Founder of Wound Care Haiti, and a medical missionary. Dr. DeHeer is President of the Indiana Podiatric Medical Association and continuing education chairperson. He is recipient of the 2011 APMA Humanitarian of the Year Award.



**SEE ANSWER SHEET ON PAGE 167.**

- 1) The triceps surae consists of the following muscles:
  - A) Gastrocnemius
  - B) Soleus
  - C) Plantaris
  - D) All of the above
- 2) The gastrocnemius crosses which of the following joints?
  - A) Knee
  - B) Ankle
  - C) Subtalar
  - D) All of the above
- 3) Which of the following is NOT an action of the gastrocnemius?
  - A) Dorsiflex the ankle joint
  - B) Supply power for propulsion
  - C) Flex the knee
  - D) Plantarflex the ankle joint
- 4) Which of the following joints does the soleus cross?
  - A) Ankle
  - B) Knee
  - C) Subtalar
  - D) A & C
- 5) The zone of hypovascularity of the Achilles tendon is located:
  - A) 4-5 cm proximal to the insertion of the tendon
  - B) 7 cm proximal to the insertion of the tendon
  - C) 1 cm proximal to the insertion of the tendon
  - D) At the insertion of the tendon
- 6) Muscular equinus includes:
  - A) Spastic equinus
  - B) Non-spastic equinus
  - C) Distal tibial-fibular osseous bridging
  - D) A & B
- 7) Osseous equinus includes:
  - A) Anterior spurring of the ankle joint
  - B) Distal tibial-fibular osseous bridging
  - C) Pseudoequinus
  - D) All of the above
- 8) There is a gastrocnemius equinus when:
  - A) The ankle joint dorsiflexes greater than 90 degrees with the knee extended
  - B) The ankle joint dorsiflexes less than 90 degrees with the knee extended
  - C) The ankle joint dorsiflexes greater than 90 degrees with the knee flexed
  - D) B & C
- 9) The \_\_\_\_\_ test is used to determine the type of equinus.
  - A) Silfverskoild
  - B) Coleman block
  - C) Hubscher
  - D) Jack's
- 10) The proximal pathology NOT associated with equinus is:
  - A) Hamstring contractures
  - B) Quadriceps contractures
  - C) Genu recurvatum
  - D) Lumbar lordosis
- 11) Which of the following is NOT seen in a partially compensated equinus?
  - A) Early heel-off gait pattern
  - B) The heel is on the ground
  - C) Toe walking
  - D) Tibia does not achieve 10 degrees of flexion to the ground
- 12) The most common definition of equinus is 10 degrees of dorsiflexion with:
  - A) The knee extended
  - B) The subtalar joint in neutral
  - C) The midtarsal joint locked
  - D) All of the above
- 13) According to the study by Aronow, when a load was applied to the gastrocnemius muscle, which of the following did NOT happen?
  - A) Rearfoot pressures decreased
  - B) Midfoot pressures decreased
  - C) Midfoot pressures increased
  - D) Forefoot pressures increased
- 14) According to the study by Mueller, which occurred as an effect of a tendo-Achilles lengthening?
  - A) Forefoot pressures increased
  - B) Forefoot pressures decreased
  - C) Rearfoot pressures decreased
  - D) Rearfoot pressures remained the same
- 15) What percentage of plantar fasciitis cases was associated with equinus in the study by Patel and DiGiovanni?
  - A) 95%
  - B) 100%
  - C) 83%
  - D) 50%

*Continued on page 166*

16) Hill states that it is important to do which of the following when stretching the calf muscles:

- A) Adduct the foot 10 degrees
- B) Abduct the foot 10 degrees
- C) Keep the foot at 0 degrees
- D) Stretch for 30 seconds

17) According to Evans' study, how many patients (out of 20) achieved 10 degrees of dorsiflexion with the use of night splints?

- A) 10
- B) 15
- C) 16
- D) 6

18) What is the recommended stretching time period using the EQ/IQ brace?

- A) 30 minutes per day
- B) 30 minutes twice per day
- C) 60 minutes twice per day
- D) 6-8 hours while sleeping

19) Based on the study by Herzenberg and Lamm, which of the following is most effective?

- A) A double gastrocnemius recession
- B) A soleus recession
- C) A single gastroc recession
- D) A single gastroc with the addition of a single soleus recession

20) A meta-analysis by Radford, et al. showed that calf muscle stretching provided:

- A) A decrease in ankle joint dorsiflexion
- B) No change in the amount of ankle dorsiflexion achieved
- C) An increase in ankle joint dorsiflexion
- D) An increase in knee flexion

See answer sheet on page 167.

## PM's CPME Program

Welcome to the innovative Continuing Education Program brought to you by *Podiatry Management Magazine*. Our journal has been approved as a sponsor of Continuing Medical Education by the Council on Podiatric Medical Education.

**Now it's even easier and more convenient to enroll in PM's CE program!**

You can now enroll at any time during the year and submit eligible exams at any time during your enrollment period.

PM enrollees are entitled to submit ten exams published during their consecutive, twelve-month enrollment period. Your enrollment period begins with the month payment is received. For example, if your payment is received on September 1, 2006, your enrollment is valid through August 31, 2007.

If you're not enrolled, you may also submit any exam(s) published in PM magazine within the past twelve months. **CME articles and examination questions from past issues of *Podiatry Management* can be found on the Internet at <http://www.podiatrym.com/cme>.** Each lesson is approved for 1.5 hours continuing education contact hours. Please read the testing, grading and payment instructions to decide which method of participation is best for you.

Please call (631) 563-1604 if you have any questions. A personal operator will be happy to assist you.

Each of the 10 lessons will count as 1.5 credits; thus a maximum of 15 CME credits may be earned during any 12-month period. You may select any 10 in a 24-month period.

**The Podiatry Management Magazine CME program is approved by the Council on Podiatric Education in all states where credits in instructional media are accepted. This article is approved for 1.5 Continuing Education Contact Hours (or 0.15 CEU's) for each examination successfully completed.**

Home Study CME credits now  
accepted in Pennsylvania

# Enrollment/Testing Information and Answer Sheet

**Note:** If you are mailing your answer sheet, you must complete all info. on the front and back of this page and mail with your credit card information to: **Podiatry Management, P.O. Box 490, East Islip, NY 11730.**

## TESTING, GRADING AND PAYMENT INSTRUCTIONS

(1) Each participant achieving a passing grade of 70% or higher on any examination will receive an official computer form stating the number of CE credits earned. This form should be safeguarded and may be used as documentation of credits earned.

(2) Participants receiving a failing grade on any exam will be notified and permitted to take one re-examination at no extra cost.

(3) All answers should be recorded on the answer form below. For each question, decide which choice is the best answer, and circle the letter representing your choice.

(4) Complete all other information on the front and back of this page.

(5) Choose one out of the 3 options for testgrading: mail-in, fax, or phone. To select the type of service that best suits your needs, please read the following section, "Test Grading Options".

## TEST GRADING OPTIONS

### Mail-In Grading

To receive your CME certificate, complete all information and mail with your credit card information to:

**Podiatry Management**  
**P.O. Box 490, East Islip, NY 11730**

**PLEASE DO NOT SEND WITH SIGNATURE REQUIRED, AS THESE WILL NOT BE ACCEPTED.**

There is **no charge** for the mail-in service if you have already en-

rolled in the annual exam CPME program, and we receive this exam during your current enrollment period. If you are not enrolled, please send \$22.00 per exam, or \$169 to cover all 10 exams (thus saving \$51 over the cost of 10 individual exam fees).

### Facsimile Grading

To receive your CPME certificate, complete all information and fax 24 hours a day to 1-631-563-1907. Your CPME certificate will be dated and mailed within 48 hours. This service is available for \$2.50 per exam if you are currently enrolled in the annual 10-exam CPME program (and this exam falls within your enrollment period), and can be charged to your Visa, MasterCard, or American Express.

If you are *not* enrolled in the annual 10-exam CPME program, the fee is \$22 per exam.

### Phone-In Grading

You may also complete your exam by using the toll-free service. Call 1-800-232-4422 from 10 a.m. to 5 p.m. EST, Monday through Friday. Your CPME certificate will be dated the same day you call and mailed within 48 hours. There is a \$2.50 charge for this service if you are currently enrolled in the annual 10-exam CPME program (and this exam falls within your enrollment period), and this fee can be charged to your Visa, Mastercard, American Express, or Discover. If you are not currently enrolled, the fee is \$22 per exam. When you call, please have ready:

1. Program number (Month and Year)
2. The answers to the test
3. Your social security number
4. Credit card information

In the event you require additional CPME information, please contact PMS, Inc., at **1-631-563-1604**.

## ENROLLMENT FORM & ANSWER SHEET

Please print clearly...Certificate will be issued from information below.

Name \_\_\_\_\_ Soc. Sec. # \_\_\_\_\_  
Please Print: FIRST MI LAST

Address \_\_\_\_\_

City \_\_\_\_\_ State \_\_\_\_\_ Zip \_\_\_\_\_

Charge to:  Visa  MasterCard  American Express

Card # \_\_\_\_\_ Exp. Date \_\_\_\_\_

**Note: Credit card is the only method of payment. Checks are no longer accepted.**

Signature \_\_\_\_\_ Soc. Sec.# \_\_\_\_\_ Daytime Phone \_\_\_\_\_

State License(s) \_\_\_\_\_ Is this a new address? Yes \_\_\_\_\_ No \_\_\_\_\_

**Check one:**  I am currently enrolled. (If faxing or phoning in your answer form please note that \$2.50 will be charged to your credit card.)

I am not enrolled. Enclosed is my credit card information. Please charge my credit card \$22.00 for each exam submitted. (plus \$2.50 for each exam if submitting by fax or phone).

I am not enrolled and I wish to enroll for 10 courses at \$169.00 (thus saving me \$51 over the cost of 10 individual exam fees). I understand there will be an additional fee of \$2.50 for any exam I wish to submit via fax or phone.



**EXAM #7/12**  
**Understanding Equinus**  
**(DeHeer)**

**Circle:**

- |             |             |
|-------------|-------------|
| 1. A B C D  | 11. A B C D |
| 2. A B C D  | 12. A B C D |
| 3. A B C D  | 13. A B C D |
| 4. A B C D  | 14. A B C D |
| 5. A B C D  | 15. A B C D |
| 6. A B C D  | 16. A B C D |
| 7. A B C D  | 17. A B C D |
| 8. A B C D  | 18. A B C D |
| 9. A B C D  | 19. A B C D |
| 10. A B C D | 20. A B C D |

**LESSON EVALUATION**

Please indicate the date you completed this exam

\_\_\_\_\_

How much time did it take you to complete the lesson?

\_\_\_\_\_ hours \_\_\_\_\_ minutes

How well did this lesson achieve its educational objectives?

\_\_\_\_\_ Very well \_\_\_\_\_ Well

\_\_\_\_\_ Somewhat \_\_\_\_\_ Not at all

What overall grade would you assign this lesson?

A B C D

Degree \_\_\_\_\_

Additional comments and suggestions for future exams:

\_\_\_\_\_  
\_\_\_\_\_  
\_\_\_\_\_  
\_\_\_\_\_  
\_\_\_\_\_  
\_\_\_\_\_